

# **Study of anatomical position of appendix in normal population and inflamed cases**



**Dissertation submitted in partial fulfillment of regulation for the award**

**of**

**M.S. Degree in General Surgery (Branch I)**



**The Tamilnadu**

**Dr. M.G.R. Medical University**

**December, 2011**

## CERTIFICATE

Certified that this is the bonafide dissertation done by **Dr.ARAVINDH. R** and submitted in partial fulfillment of the requirements for the Degree of M.S., General Surgery, Branch I of The Tamilnadu Dr. M.G.R. Medical University, Chennai.

Date: Guide and Chief of Surgery Unit SI  
Professor & Head of the Department of General Surgery

Dean  
Coimbatore Medical College  
Date: Coimbatore - 641 010

## **DECLARATION**

I solemnly declare that the dissertation titled **Study of anatomical position of the appendix in normal population and in inflamed cases** was done by me from November 2009 to December 2011 under the guidance and supervision of Professor **Dr. P.V.VASANTHA KUMAR M.S.,**

This dissertation is submitted to the Tamilnadu Dr. MGR Medical University towards the partial fulfillment of the requirement for the award of MS Degree in General Surgery (Branch I).

Place: Coimbatore

Date:

**DR ARAVINDH.R**

## **ACKNOWLEDGEMENT**

I am privileged to express my thanks to Dr Vimala M.D., Dean of Coimbatore Medical College and Hospital in granting me permission to utilize the hospital facilities to undergo this Dissertation.

I am grateful to Dr P V Vasanthakumar M S., Professor and Head of the Department of Surgery for allowing me to carry out this Dissertation work in this department.

I would like to thank my previous Chiefs Rtd. Prof. Dr.P.Govindaraj M S, M ch., Rtd. Prof Dr A Ramamoorthy M S., Rtd. Prof. Dr G Mohan M S., Rtd. Prof Dr P M Nanjundappan M S., for their guidance and support.

I would also like to express my thanks to all surgery unit chief for allowing me to use their unit patients to indulge in the study.

I am happy to convey my thanks to all the Registrar and Assistant Professors for their advice and guidance.

I wish to thank all my co-Post Graduates and Interns for their help.

I am also happy to extend my thanks to the nursing faculties and other paramedical staffs for their support.

Finally with all happiness I thank all my patients for their kind co-operation all through the study.

## TABLE OF CONTENTS

<b>S.No</b>	<b>Particulars</b>	<b>Page No.</b>
1.	Introduction	1
2.	Objectives	2
3.	Review of Literature	3
4.	Methodology	44
5.	Results	49
6.	Discussion	60
7.	Conclusion	63
8.	Summary	66
9.	Bibliography	68
10.	Annexures	71

## LIST OF TABLES

<b>Sl.No</b>	<b>Particulars</b>	<b>Page No.</b>
1	Position of the appendix according to various authors	7
2	Alavarado Score	27
3	Teicher scoring system	28
4	Distribution of Age & position of Appendix in inflamed cases	51
5	Length of appendix in inflamed and normal cases	51
6	Distribution of sex in position of appendix	53
7	Typical and atypical presentation of appendix	54
8	Type of surgery in appendix	55
9	Position of appendix in normal population and in inflamed cases	56
10	Comparison of positions of appendix in inflamed and normal cases	57

## LIST OF FIGURES

Sl.No	Particulars	Page No
1	Artery supply of appendix	4
2	positions of appendix	6
3	ultrasound finding of appendix	24
4	Distribution of age in the position of appendix	52
5	Age of onset of acute appendicitis	52
6	Length of appendix	53
7	Typical and atypical presentation of appendix	54
8	Type of incision for appendectomy	55
9	Position of appendix in inflamed cases and normal group	56
10	Inflamed appendix with gall stones	58
11	Pelvic appendicitis	58
12	Thickened,elongated and perforated appendix	59
13	Retrocaecal appendix	59

# *Introduction*

---



## INTRODUCTION

Appendix is a vestigial organ present only in man, certain anthropoid apes and wombat. It is a mysterious structure, being the frequent site of inflammation, with no function. Acute appendicitis is most common surgical emergency. The diagnosis and position of appendix is elusive and needs high index of suspicion in preventing serious complication

The appendix present in various positions and each position has varying clinical signs making hard to diagnose.

There are few studies saying that position of appendix is related to the cause of inflammation like Varshney et-al have concluded that the retrocaecal position of the appendix is less prone for infection and Collins et-all has stated that perforation and inflammation is seen in retrocaecal cases. Collins et-al had told that pelvic as common position (78.5%)<sup>1</sup> and Pickens G et-al<sup>2</sup> as postileal and Wakeley et- al as retrocaecal (65.3%)<sup>3</sup> . Guidry SP<sup>4</sup> and Poole GV<sup>5</sup> et al have concluded that anatomic variations of the location of appendix are often responsible for delay in the diagnosing appendicitis.

Hence this study was conducted to know whether position of appendix has any relationship to inflammation.

Our study is performed in clinical cases representing the inflamed appendix group and other laporatomy group, which represents the normal appendix group. In the inflamed group the relation between the various positions of the appendix, the clinical presentation and complications is studied.

# *Objectives*

---

## **OBJECTIVES OF THE STUDY**

To study the position of the appendix in normal population and compare it with the position of inflamed cases.

To determine the relation of clinical presentation and management of appendix to that of various position of the appendix.

To analyse the age incidence, sex incidence, duration of onset, symptomatology, signs, USG findings and treatment of appendicitis.

# *Review of Literature*

---

## REVIEW OF LITERATURE

### HISTORICAL NOTE

To understand the present and foresee the future we must turn always to the past. Existence of appendicitis in remote times is evidenced by the acutely inflamed and perforated appendix found preserved in the mummy of a young royal princess of Egypt (Spencer).

BERENGE – ARIL – DE CARPI in 1521 first described the appendix. JANE FERNIL described it as ‘Caecum Intestinum’ in 1554. LORNEZ HEISTER described Appendicular Abscess in 1710<sup>6</sup>. CLAUDIUS AMYAND, surgeon to Westminster in St. George's Hospitals performed the first Appendicectomy in 1736 on a boy aged 11 years who had a right scrotal hernia accompanied by a fistula. In 1824, LOYER VILLERMAY described two examples of acute appendicitis leading to death. Description of symptoms of Appendicitis and appendicular perforation was published in the textbook by Bright and Addison in 1839. It was Fitz, Professor of Medicine at Harvard who in 1886 gave a lucid and logical description of the clinical features and pathological changes of the disease and termed “Appendicitis”.

In 1880, Tait of Birmingham operated and removed a gangrenous appendix with recovery of the patient. McBurney in New York pioneered early diagnosis and early operative intervention and devised the muscle splitting incision.

The operative death rate for the later cases of perforated appendix with peritonitis was distressingly high. Oschner in Chicago and Sherren at the London Hospital were both advocates in the conservative treatment in late cases.

## DEVELOPMENT AND ANATOMY

Appendix is the undeveloped distal end of caecum. It is pushed to the posteromedial aspect of caecum by about 2.5cm below the ileocaecal valve, by excessive growth of the right wall of caecum. It arises at the site where the three taeniae coli coalesce. It occupies various positions more commonly the Retrocaecal position, the rest being Pelvic, Postileal, Preileal, Paracaecal and Subcaecal.

It has the same coats as large gut. Its lumen which can admit a match stick is irregular encroached upon by multiple longitudinal mucosal folds. It contains an excess of lymphoid tissue in the sub mucosal layer beneath the columnar celled mucosa of colonic type with few crypts on the base of which lies the Kulchitzky cells. The mesentry of the appendix is contiguous with the lower leaf of mesentry of the ileum and posterior to it. An additional bloodless fold of peritoneum named after Treves connecting the terminal ileum to caecum and the mesentry of Appendix may be present. The Appendicular Artery runs in the free border of the mesentry and is a branch of the ileocolic Artery. An Accessory Appendicular artery may be present. The veins of the appendix drain into the ileocolic vein, then into the superior mesentric vein. Slender lymphatics drain into ileocaecal lymph nodes<sup>8</sup>.

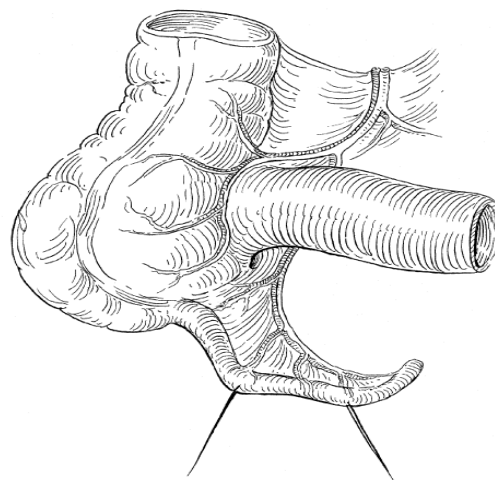


Fig No.1 Artery Supply of Appendix

## **INCIDENCE LENGTH OF APPENDIX**

Length of appendix varies between 1-20cms. The length of appendix gets apparently modified by the inflammatory process<sup>9</sup>.

## **POSITION OF APPENDIX**

The relation of the base of the appendix to the caecum is always constant where as the tip of it may lie in any of the following positions as per the study of Cecil Wakeley - Retrocaecal 74%, Pelvic 21%, Paracaecal 2%, Subcaecal 1.5%, Preileal 1%, and postileal 0.5%.

These are the various position of appendix as described by Sir Frederick Treaves<sup>8,9,10</sup>: **Retro-caecal or Retro-colic or 12 O' clock position** - Appendix lying behind the caecum or the ascending colon and can be intraparietal or extraparietal

**Splenic or 2 O' clock position** - Appendix directs towards the spleen this has two types i.e. it may pass either in front of the ileum (**Pre-ileal**) or behind the terminal part of the ileum (**Post-ileal**)

**Para-colic or Para-caecal or 11 O' clock position** - Appendix directs upwards & to the right to caecum. It can lie behind peritoneum or lie in front of kidney into the peritoneal cavity

**Promonteric or 3 O' clock position** - Appendix directs transversely inwards towards the sacral promontory.

**Pelvic or 4 O' clock position** - Appendix directs to the brim of the pelvis and projects into the pelvic cavity

**Midinguinal or 6 O' clock position or Sub-caecal position:** Appendix passes downward towards the middle of the inguinal ligament.

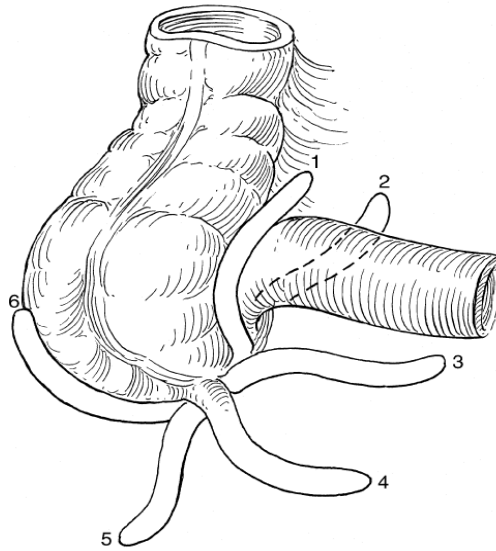


Fig No.2 Positions of Appendix



**TABLE - 1****Position of the appendix according to various authors<sup>1</sup>**

<b>Author</b>	<b>No. Of Specimens</b>	<b>Percentage occurrence of various positions of appendix.</b>					
		<b>Retro-caecal</b>	<b>Pelvic</b>	<b>Post-ileal</b>	<b>Pre-ileal</b>	<b>Sub-caecal</b>	<b>Para-caecal</b>
Varshney S. 1996	600	19%	53%	1%	2%	7%	18%
Shah &Shah, 1942	591	51.4%	16.6%	15.6%	11.7%	4.7%	-
Golalipour MJ. 2003	117	32.4%	33.3%	2.6%	18.8%	12.8%	-
Wakeley, 1933	10,000	62%	31%	0.4%	1%	2%	-
Solanke TF.	125	38.4%	31.2%	12%	4%	11.2%	2.4%

Normal variations in appendix<sup>10,11</sup>

1 - Extra-peritoneal retro-caecal, para-caecal fossa present

2 - Extra-peritoneal retro-caecal, para-caecal fossa absent

3- Extra-peritoneal retro-caecal, lying anterior to the right kidney & associated with subhepatic caecum

4 - Intra-peritoneal

5 - Intra-peritoneal retro-caecal with in paracaecal fossa

## **AGE INCIDENCE<sup>12,13</sup>**

Appendicitis is rare before the age of 2, becoming increasingly common during childhood and adolescence. The maximum incidence between the ages of 20 and 30 years. Thereafter, there is a gradual decline but no age is exempted. The patient often gives a history of previous slight attacks. The amount of lymphoid tissue in the appendix and the incidence of acute appendicitis, the peak for both occurring in the middle teens. About 72% of patients are under the age of 30 yrs and 4% are 50 yrs or above. With increasing age, the percentage of patients with simple appendicitis diminishes whereas the percentage of perforated appendicitis increases. In preschool age children, the rate of perforation is over 60% due to anatomical differences, difficulties in diagnosis and the habit of giving a purgative to any child with abdominal pain and fever.

## **SEX INCIDENCE**

The male-female ratio of appendicitis is about 1:1 prior to puberty, according to Edward.H.Storer. At puberty the frequency increases, so that the male to female ratio is about 2:1 between 15-25 years after which the male incidence gradually declines until the sex related incidence are again equal<sup>14</sup>. Acute appendicitis is generally more common in males and the mortality rate is also higher in males than females. The American Bureau of Census records a 3:2 ratio of this disease.

## **AETIOLOGICAL FACTORS**

The aetiology has not been completely clarified. The following factors are purely contributory.

### **I a) Anatomical factors<sup>15</sup>**

The Appendix is a blind tube with a narrow lumen with bacteria teamed contents. Its vestigeal character predisposes to troubles. Obstruction is (1) by the action of valve of Gerlach especially (2) When foreign bodies chiefly faecolith are present, (3) because of the mobility of appendix to the position of caecum (4) the effects of kinks, bands, adhesions and other causes of angulation. The presence of muscular hiatus in which areas, the mucosal tissue is in juxta position with serosal tissue, explains the possible spread of infective process once it has developed. Anamolous positions can cause considerable diagnostic confusions.

### **b) Race and Diet<sup>16</sup>**

Appendicitis is particularly common in the highly civilized European, American, and Australian countries while it is less common in Asians, Africans and Polynesians. If the latter races migrated to the former, they soon acquire the local susceptibility to the disease. This is due to the departure from a simple diet rich in cellulose to one relatively rich in meat, and it is not the whole explanation, for it occurs in lifelong vegetarians.

### **c) Social Status**

Acute appendicitis is more common in the upper and middle classes than in the so called working class.

#### **d) Familial Susceptibility**

This unusual but accepted fact is accounted for by a hereditary abnormality in position of the organ which predisposes to infection.

#### **e) Obstruction to the lumen of Appendix<sup>17</sup>**

Some form of obstruction to its lumen is usually demonstrated in 80% of cases.

- i) Faecolith : Faecal material commonly present in the normal and inflamed appendix is differentiated from a faecolith which is ovoid, laminated about 1-2 cm in length and faecal coloured. It is composed of inspissated faecal material, Ca and Mg PO<sub>4</sub>s, carbonates, bacteria and epithelial debris. Rarely an incorporated foreign body. They are Radio-opaque. Worms, and other intestinal parasites can injure the appendicular mucus membrane and occasionally, block its lumen, or act as a nidus for bacterial infection. If worms were causative of appendicitis then, the disease should be more prevalent in children while it is so in adolescents and young adults.
- ii) Other foreign bodies include vegetable seeds, cherry, stones, inspissated Barium, etc. In older patients a caecal carcinoma and in the young a carcinoid are occasional causes. Metastasis to the appendix from carcinoma breast especially may cause acute appendicitis. Our present study did not demonstrate any of these.

#### **f) Trauma**

Accepted when Appendicitis follows trauma almost immediately.

#### **g) Acute respiratory infection**

Acute Bronchitis, tonsillitis and acute sinusitis appear to be impressive antecedents in many of the statistics.

#### **h) Diverticula**

Efforts of Appendicular musculature to empty the occluded lumen due to previous inflammation, leads to marked increase of intraluminal pressure with occasional herniation of mucosa through the areas of least resistance.

#### **i) Primary Bacterial origin<sup>17</sup>**

As appendix lodges mixed bacterial flora its exact relationship could not be clearly made out. It has been reported in literature that the onset of ileocaecal tuberculosis is from the appendix. It is rare to find isolated involvement of Appendix in tuberculosis.

#### **j) Infection via Blood stream.**

Infection may be hematogenous, probably when it occurs during the course of measles or has followed upon acute tonsillitis or surgery.

#### **k) Amoebiasis**

This condition may mimic or be the cause of acute appendicitis as evidenced by Franklyn & Claysher. Amoebiasis may be an associated factor but not causative.

## PATHOLOGY<sup>18</sup>

Like any inflammatory process elsewhere, appendicitis is a reaction to an injury, but the exact manner with which the injury occurs is not known. Transient circulatory disturbances due to the normal efforts of caecum to expel its contents may change the position of Appendix and cause a pull or a twist of its mesentery, thereby temporarily impeding its blood supply. At the site of injury to the mucosa a minute ulcer occurs and fibrin, red cells, leucocytes and plasma oozed out into the lumen. A focal inflammation thus set in proceeds in succession or resolves even without treatment.

The menace of acute appendicitis lies in the frequency with which the peritoneal cavity is infected from this focus, by (1) perforation (2) transmigration of bacteria through the appendicular wall. The greater omentum, 'the abdominal policeman', attempts to arrest the spread of peritoneal infection, whilst violent peristalsis from ingested purgatives tends to spread it. Obviously the inflamed appendix lies dangling amidst coils of small intestine, the threat of peritonitis is increased, should early perforation occur, diffuse peritonitis is inevitable.

It is of great importance to recognise the following types of appendicitis:

1. Acute appendicitis without perforation.
2. Acute appendicitis with perforation
  - a) With local peritonitis
  - b) With local abscess
  - c) With appendicular mass

Examination of a series of fresh specimens of acutely inflamed appendices will show that these fall into two groups. It first demonstrates a "catarrhal" inflammation of the whole organ, while the second group demonstrates an "obstruction" of the appendix

beyond which there is acute inflammation, distension with pus, and in later cases progression to gangrene and eventually perforation.

### **1. CATARRHAL APPENDICITIS**

Is initially a mucosal and sub mucosal inflammation. In early cases the appendix may appear quite normal externally or merely shows hyperemia. On slitting it open, the mucosa will be seen thickened, oedematous and reddened; latter it becomes studded with dark brown haemorrhagic infarcts, patches of grey-green gangrene or small ulcers. Eventually the whole appendix becomes swollen and turgid and the serosa becomes roughened, loses its healthy sheen and is coated with a fibrinous exudate. The probable etiology of this condition is bacterial invasion of the lymphoid tissue in the appendix wall and indeed some cases are probably localised manifestation of generalised enteritis. Because the lumen of the appendix is not obstructed; these cases rarely progress to gangrene and in many instances the acute inflammatory attack resolves spontaneously. In other cases, however the swelling of the lymphoid tissue in the appendix wall may lead to obstruction of the lumen and the condition may then proceed to obstructive appendicitis and gangrene. Even when the acute inflammation process subsides; the appendix probably never regains its pristine state, adhesion formation and kinking of the appendix may lead to a final episode of acute obstructive appendicitis.

### **2. OBSTRUCTIVE APPENDICITIS<sup>19</sup>**

It is a dangerous type where appendix becomes a closed loop bowel containing decomposing faecal matter. The changes after obstruction depend upon the amount and character of the factor causing obstruction. Faecolith is the common cause of obstruction. When obstructed, there is accumulation of mucus that proceeds to proliferation of the contained bacteria and lead to atrophy of the mucosa, which allows

bacterial access to deeper tissue planes and continues with vessel thrombosis which leads to gangrene and then perforation. On other occasions, bacterial invasion occurs through pressure erosion of attained faecolith which may discharge into the peritoneal cavity through perforation.

### **MICROSCOPICAL EXAMINATION**

In the early state there is scanty neutrophilic exudation throughout the musoca, submucosa and muscularis. As a later stage, the neutrophilic exudation is more advanced through the wall and serosa. Still later, there is abscess formation within the wall along with foci of suppurative necrosis leading to Acute Suppurative Appendicitis. Further worsening produces green black gangrenous necrosis throughout the wall extending to the serosa – termed acute gangrenous appendicitis.

### **EFFECTS OF PERFORATION**

The appendices may rupture at any spot, but most frequently the site of perforation is along the antimesenteric border. Following perforation a localized abscess may form in the right iliac fossa or in the pelvis or diffuse peritonitis may ensue. Whether the peritonitis remains localised or becomes generalised depends on many factors, including the age of the patient, the virulence of the organisms, the rate at which the inflammatory condition has progressed within the appendix and the position of the appendix.

It is usually stated that poorer localisation of the infection occurs in infants, due to the fact that the omentum of the child is flimsy and less able to form a protective sheath around the inflamed appendix. A more likely explanation is that delays in diagnosis are more prone to occur in infants. A similar state of affairs occurs in the elderly. In the non obstructed type of acute appendicitis, the disease is comparatively limited in its course and the peritoneum has ample time for inflammatory adhesions to form. In contrast, in



the obstructive form, the rapidity of the process gives little time for defensive adhesions to develop before the sudden flood of infected contents. An appendix situated in the retrocaecal or pelvic location is more likely to form an abscess than the one in the preileal or subcaecal position.

## **BACTERIOLOGY<sup>17</sup>**

The bacteriology of the inflamed appendix is that of the normal bowel flora, suggesting secondary invasion of damaged tissue from the lumen of the bowel. A detailed study by Pieper and colleagues (1982) gave both aerobic and anaerobic isolates from all cases. The most common organisms present were *Escherichia coli* among the aerobic group. Other aerobic gram negative rods, including *Klebsiella*, *Proteus* and *Pseudomonas*. Less common were Enterococci and streptococci. Of the anaerobic group were *Bacteroides fragilis*, gram positive cocci, and *Clostridium perfringens*. But in the present study regular study of the swabs taken from the appendix was not done. Knowing the bacteriology of appendicitis is important to control wound infection. Anaerobic wound infections were much reduced by the routine use of prophylactic antibiotic of 500mg of i.v Metronidazole about half an hour before surgery. This was evidenced by the report in the British Journal of surgery (August 1980) by Bates Touquet Tutoon in the article, Prophylactic Metronidazole in Appendicectomy. Broad spectrum antibiotics namely Ampicillin which has got effect on both gram positive and gram negative organisms and Gentamycin against gram negative organisms is also used with Metronidazole.

# **CLINICAL MANIFESTATIONS<sup>17</sup>**

## **A) SYMPTOMS**

### **1.PAIN**

Usually the first symptom is pain around umbilicus, in the epigastrium or generalized. This is the vague visceral pain. It is due to distension of the appendix. It is constant in catarrhal type and colicky in obstructive appendicitis. After 6 - 12 hours, it localizes to the point where the inflamed appendix irritates the parietal peritoneum. This is the accurately localized constant somatic pain. The site and character of pain varies with the variable positions of Appendix i.e Retrocaecal appendix may cause loin pain, pelvic appendix may cause hypogastric pain and the pre and postileal appendices cause testicular pain from irritation of the spermatic vessels and ureter.

### **2.NAUSEA AND ANOREXIA**

Anorexia nearly always accompanies appendicitis. It is so constant that the diagnosis should be questioned if the patient is not anorectic. Nausea invariably accompanied the onset of appendicitis.

### **3. VOMITING**

Vomiting occurred in the early stages of appendicitis because reflex pyloro-spasm. So the characteristics are there are two to three hours of vomiting till the stomach empties and no more vomiting until the appendix perforates and causes peritonitis, paralytic ileus which occurs in late cases.

### **4. DIARRHOEA**

Diarrhoea may be a result or cause for appendicitis. It is invariably occurs in post-ileal and pelvic position of the appendix where it irritates bowel and there is passage of motion frequently.

## **5.CONSTIPATION**

Most of the patients with acute appendicitis have this form of symptom, even before the onset of pain. Approximately 7% of patients in Western countries develop this "Gas Stoppage Sign" in acute appendicitis has been described by Englebert Iphy and Lawrence.

## **6. FEVER**

According to Smith (1965) 60% of patients had a temperature 37.2 °C. During the first six hours there is rarely any alteration in the temperature. In severe cases, as time passes the temperature rises to about 38.3 C but seldom more.

## **7. BURNING MICTURITION**

Urinary symptoms and signs, chiefly dysuria,increased frequency, pain burning micturition and haematuria occur in small proportion of cases in acute appendicitis. These symptoms are due to the appendix impinging on the ureter or bladder.

## **B) SIGNS**

### **1.ELEVATED TEMPERATURE**

Temperature elevation of about 1° C is characteristic of acute appendicitis but if there is any complication the temperature shoots up fast. Pulse rate is greater than 100/min in most of the cases.

### **2. TENDERNESS**

#### **SHERREN'S TRIANGLE**

This is a triangle extending from the anterior superior iliac spine and pubic symphysis and converging toward the umbilicus. Tenderness anywhere in the region should evoke a suspicion of appendicitis.

### **TENDERNESS OVER MCBURNEY'S POINT**

This is a point in the spino-umbilical line at the junction of the medial 2/3rd and lateral 1/3rd. This tenderness is the most constant physical sign in acute appendicitis, though at times it is masked by generalized pain which was not yet localised. The tenderness is due to cutaneous hyperaesthesia or due to local peritoneal irritation from the stimulation of the sub-serous nerve plexus.

### **REBOUND TENDERNESS (PLUMBERG'S SIGN)**

Deep palpation and sudden release of pressure elicited this sign. In late stages and in obese patients, it is difficult to elicit this sign.

### **ROVSING'S SIGN**

Pressure over the left iliac fossa causes pain in the right iliac fossa. This is due to sudden shifting of coils of ileum to the right impinging upon the inflamed appendix.

### **BALDWIN'S TEST**

It is another test for retrocaecal appendicitis. While maintaining the finger tip pressure over the flank, the patient is asked to raise the right lower limb off the bed keeping the knee extended. The test is positive if the patient complains of an increase of pain or drops the limb with an expression of agony on the face. This test is useful in patients with heavy muscle abdomen in which the tenderness is always difficult to elicit.

### **ZACHARY COPE'S PSOAS TEST**

In retrocaecal appendicitis, since the inflamed organ lies on the psoas major, the patient experiences pain when this muscle is stretched by causing extension of the hip joint.

## **ZACHARY COPE'S OBTURATOR TEST**

In pelvic appendicitis, as the inflamed organ lies on the obturator internus, the patient complains of pain if this muscle is stretched by flexing and medially rotating the thigh.

### **3. GUARDING AND RIGIDITY**

Guarding was due to the irritation of the parietal peritoneum. So to prevent the pain occurring this protective reflex in the muscle was present. Rigidity is due to peritonitis setting in. The rigidity of the muscle vary from the degree of sensitivity of nervous system; degree of peritonitis, localisation of infection to the abdominal wall and the involvement of the nerve endings. The muscles cannot maintain a constant contraction beyond a certain point at which the neuromuscular reflex becomes fatigued. So the absence of rigidity in some cases can be explained on this basis. This reflex may also be affected by absorption of bacterial toxin. A patient with peritonitis often being intoxicated that tenderness and rigidity are both absent.

### **4. ABDOMINAL DISTENSION**

Whether localised or generalised it is a constant feature in early cases of acute appendicitis and it is not seen in advanced cases, though it may be prominent in ileus or diffuse peritonitis or localised distension.

### **5 COUGH SIGN**

Cough produces sharp localizing pain in cases of acute appendicitis.

### **6 RECTAL AND PELVIC EXAMINATION**

In rectal examination - the right index finger is introduced into the rectum and pelvis in all directions, while the left hand palpates the right iliac fossa. If there is no

tenderness on bimanual examination, the appendix is not inflamed, unless it lies in such a position over the pelvic brim that is missed entirely by the exploring finger. If peritonitis developed there was generalised tenderness in rectal examination. Pelvic examination was useful chiefly to differentiate from gynaecological causes of pain.

## **SPECIAL FEATURES**

### **ACUTE APPENDICITIS IN INFANTS & CHILDREN**

In infants under 3 years the chances of perforation is over 80% and the mortality considerably high as the greater omentum is short and undeveloped and unable to localize the infection.

In children, they usually have complete aversion to food. They do not sleep during the attack and bowel sounds are absent in the early stages. Early appendectomy or exploratory laparotomy in doubtful cases is advised.

### **ACUTE APPENDICITIS IN THE ELDERLY**

Gangrene and perforation occurs more frequently. The higher morbidity in the elderly is due to both delay by the patient in seeking medical care and delay in appropriate treatment, because of paucity of findings in the presence of severe disease. Impaired blood supply and structural weakness of the appendix are said to produce earlier perforation in older patients.

### **ACUTE APPENDICITIS IN PREGNANCY**

The Appendix shifts to the upper abdomen thus favoring peritonitis. Microscopic examination of urine will help to exclude pyelonephritis. In doubtful

cases it is best to perform early appendectomy due to 10 times greater mortality in over 6 months than in the first trimester.

## **DIAGNOSTIC STUDIES**

Acute appendicitis is more a clinical diagnosis, to be supported by the following investigations.

### **WHITE BLOOD CELL COUNT<sup>20</sup>**

A polymorph leucocytosis is stressed by American authors as an important feature of acute appendicitis. The differential count and total white blood cell count usually are abnormal in appendicitis, but the degree of abnormality does not correlate with the degree of abnormality in the appendix. Upto 1/3 of patients particularly older patients have a normal total count with a shift to the left in the differential count even when the total count is normal (Neutrophilia).

**1. C reactive protein levels:** It is an acute phase reactant. Eriksson et al<sup>(21)</sup>, in a study of 227 patients, found that CRP has a sensitivity of 87% and a specificity of 50%. This protein is persistently elevated unlike leukocyte count.

**2. Phospho-lipase A2 levels:** an acute phase reactant. Whereas leukocyte count is the investigation of choice in acute uncomplicated appendicitis, C-reactive protein and phospho-lipase A2 correlates better with protracted inflammation and appendicular perforation. Increased phospholipase A2 values did not unequivocally indicate diagnosis but when all the values were normal, appendicitis could be excluded with 100% certainty.

**3. Interleukin – 6 levels (IL-6):** IL-6 levels had found to correlate well with acute appendicitis, although specificity is uncertain.

## **URINE EXAMINATION**

This of course, should be a routine in every patient with acute abdominal pain. The presence of haematuria or pus cells in the urine point to a urinary tract infection but by no means exclude acute appendicitis, when found adherent to right ureter or bladder

## **RADIOGRAPHY<sup>22</sup>**

Plain x-ray of Abdomen in the supine and erect postures are of value in the differential diagnosis of acute abdominal pain. Brooks and Killen (1965) list the radiological signs that may be evident in the patients with acute appendicitis as follows:

- Fluid levels localized to the caecum and terminal ileum indicates local inflammation.
- Localized ileus with gas in the caecum, Ascending colon and terminal ileum is called Sentinel loop sign.
- Decreased soft tissue density in the right lower quadrant.
- Blurring of the preperitoneal radiolucent fat line.
- A faecolith in the right iliac fossa (differential diagnosis - Ureteric stone, gall stone, or a calcified mesentric lymphnode).
- Blurring of the psoas shadow on the right side.
- A gas filled appendix
- Free intraperitoneal gas.
- Deformity of caecal gas shadow due to an adjacent inflammatory mass.

Most of our patients 76% acute appendicitis showed localized ileus with or without fluid levels. Few patients (40%) showed absence of properitoneal fat line and decreased soft tissue density in the right lower quadrant. Faecolith was evident in 18% and free intraperitoneal gas in one case.



## **BARIUM ENEMA<sup>23, 24</sup>**

Its use as an emergency is almost confined to USA and UK. Smith et al 1979 enumerated the following findings.

1. Persistent non-visualisation of the appendix (although it can occur in 5 - 10 % of normal appendices).
2. Partial visualisation of the appendix.
3. Pressure defect on the caecum.
4. Irritability of the caecum and terminal ileum on screening.

## **ULTRASONOGRAPHY<sup>25, 26</sup>**

Pearson (1988) reviewed the use of high resolution ultrasonography with graded compression. The ultrasonographic appearances of acute appendicitis are of a non-compressible, aperistaltic tubular structure with a central dilated lumen surrounded by an inner echogenic mucosal layer and an outer oedematous wall that shows few echoes. Ultrasound has 93% accuracy in diagnosing appendicitis if a skilled radiologist is available.

The diagnostic criteria for the diagnosis of acute appendicitis by ultrasound :

(After Jeffrey)<sup>(25)</sup>

1. Sonographic Mc Burney's sign of maximum tenderness by the probe. This sign is lost in appendicular perforation.
2. Blind ending, immobile, non compressible, aperistaltic, tubular structure. Measuring the distance from the echogenic mucosa to the outer oedematous wall that shows few echoes assesses mural thickness
3. Cannot be displaced on pressure.

4. Faecolith in the lumen.
5. Peri-appendiceal collection.
6. Hypo or hyper – peristaltic loops in the right iliac fossa.
7. Bull's eye or target lesion visualized in the transverse plane with diameter  $> 6\text{mm}$ .
8. Miscellaneous signs: Cockade around target lesion. Tubular structure  $> 50\text{ mm}$  in length.

Poor results had been reported in the diagnosis of appendicular perforations. Reasons for it are:

1. Loss of localizing rebound tenderness.
2. Decompression of the target lesion and decrease in the diameter.
3. Ileus with dilated bowel loops within the right iliac fossa.

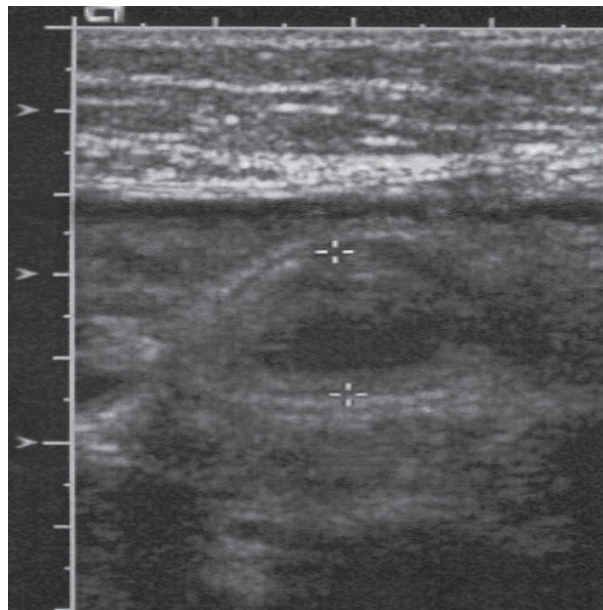


Fig No.3 Ultrasound Finding of Appendix

## **DIAGNOSTIC LAPAROSCOPY<sup>27</sup>**

Minimal invasive diagnostic procedure that can visualize the appendix and other pathological sites in the abdomen. Previous laparotomy is considered a contraindication.

The advantage of laparoscopy was positive visualisation and the exclusion of the differential diagnosis such as salpingitis, terminal ileitis, ectopic pregnancy, endometriosis, ruptured corpus-luteal cysts, tumour infiltrates, Para ovarian cysts and Mittelschmerz syndrome.

**Disadvantage are** ascitis , pregnancy ,previous laparotomy.

Signs of acute appendicitis on laparoscopy.

1. Partial or complete visualisation of inflamed appendix.
2. Pus in the right iliac fossa.
3. Omentum adherent to structure of the right iliac fossa.
4. Inflammation of the peri-caecal tissues.

## **CT SCANNING<sup>28,29</sup>**

It is accurate in diagnosing the advanced cases but inaccurate in early appendicitis.

They described the common findings in acute appendicitis on C.T as:

1. Peri-caecal inflammation. (58%)
2. Abscess formation. (65%)
3. Calcified appendicolith. (23%)
4. Abnormal appendix. (18%)

## **RADIO ACTIVE ISOTOPE IMAGING**

A patient's leucocytes may be incubated with radioactive isotope. After re-injection these leucocytes may be detected in an inflamed appendix. This investigation is unreliable in women. Navvaro et al<sup>(30)</sup> uses Indium 111 and found a sensitivity of 93% with an overall accuracy rate of 91%.

It was unreliable in women, as gynecological conditions may mimic the scan appearance of appendicitis.

## **DIAGNOSTIC PERITONEAL ASPIRATION CYTOLOGY**

**(Stewart et al, 1986)<sup>31, 32, 33</sup>**

Simple, Cheap, Safe and effective method. The aspirate is obtained by a fine umbilical catheter and placed on a glass slide, smeared, air dried and stained by Romanofsky method. On light microscopy, if neutrophils are accounted for more than 50% of the nucleated cells, the test was positive. False positive results may be obtained in acute salpingitis. Negative findings do not exclude pathology.

Apart from these investigations there are many scoring system. The important two are

**TABLE NO - 2**

**Mantrels or Alvarodo's Score<sup>34</sup>**

<b>SYMPTOMS</b>	<b>SCORE</b>
Migrating pain	1
Anorexia	1
Nausea, vomiting	1
<b>SIGNS</b>	
Tenderness in right lower quadrant	2
Rebound tenderness	1
Elevation of temperature	1
<b>LABORATORY CRITERIA</b>	
Leukocytosis	2
Shift to left	1
<b>TOTAL</b>	<b>10</b>

a score of less than or equal to 6 to be clinically dubious and more than or equal to 7 to be typical.

Teicher et al<sup>(35)</sup> described a scoring system, after retrospectively studying 100 cases of acute appendicitis.

**TABLE NO – 3**

<b>SCORE</b>	<b>POSITIVE PREDICTORS</b>	<b>SCORE</b>	<b>NEGATIVE PREDICTORS</b>
+2	Male	-1	Female
+3	Age 50 yrs	-1	20-39 yrs
+2	Duration ½ day	-3	Duration > 3 days
+1	Duration 2 days	-3	Genito-urinary symptoms
+3	Involuntary right lower quadrant spasm	-3	No right lower quadrant spasm
		-3	Rectal mass right side
		-3	TC < 10,000 cells/cu.mm

**TEICHER SCORING SYSTEM**

A score greater than 3 was taken as a positive predictor of acute appendicitis. These scoring system are used to prevent negative laparotomy in emergency situations without radiological investigation

## **DIFFERENTIAL DIAGNOSIS**

It is wise to consider carefully possible diseases of the chest, the abdomen, the pelvis, the genitourinary system, the central nervous system, and the spines because although acute appendicitis is the commonest abdominal emergency the diagnosis at times can be extremely difficult.

### **A) Nasopharynx and Thorax**

#### **1. TONSILLITIS**

In children abdominal colic may arise from swallowed exudate (tonsil tummy).

#### **2. PNEUMONIA AND PLEURISY**

Especially at the right base, gives rise to right sided abdominal pain but they are associated with an increased respiration rate and the pain prevents deep inspiration.

### **B) Diaphragm to the level of umbilicus**

#### **1. PERFORATED PEPTIC ULCER**

Contents pass from the perforated area to the right paracolic gutter. This may mimic appendicitis but the differentiating feature may be origin of pain and other localising signs.

#### **2. ACUTE CHOLECYSTITIS**

Murphy's sign and radiation of pain through to the right scapula are important features.

#### **3. CYCLICAL VOMITING**

It is seen in an infant or a young child. Rigidity is absent in these cases.

## **C) Umbilicus to the Brim of pelvis**

### **1. ENTERO-COLITIS**

Intestinal colic together with diarrhoea and vomiting but localised tenderness does not usually occur.

### **2. NONSPECIFIC MESENTRIC LYMPHADENITIS**

Shifting tenderness, when the child turns is very characteristic and other cervical lymph nodes may be enlarged.

### **3. INTESTINAL OBSTRUCTION**

Colicky pain and vomiting may be present. Plain X-ray shows fluid levels.

### **4. REGIONAL ILEITIS**

A history of diarrhoea with a doughy mass of inflamed ileum can be felt.

### **5. CARCINOMA CAECUM**

It is rare. H/O discomfort, altered bowel habits or unexplained anaemia. On examination mass is palpable in RIF.

### **6. MECKEL'S DIVERTICULITIS**

It is difficult to differentiate from acute appendicitis. However signs may be central or left sided. Occasionally history of lower gastro-intestinal bleeding may be present.

### **7. INTUSSUCEPTION**

Median age of onset is around 18 months. Presence of Psoas mass in Right Lower Quadrant



## **8. HENoch-SCHONLEIN PURPURA**

It is preceded by sore throat or respiratory tract infections.

## **9. ACUTE PANCREATITIS**

Ruled out by serum amylase measurement.

## **10. RECTUS SHEATH HEMATOMA**

Localised pain without gastro-intestinal symptoms.

## **D. The Pelvis**

### **1. SALPINGITIS**

Vaginal discharge, menstrual irregularities, and dysmenorrhoea and burning micturition are the differentiating points. Per vaginal examination reveals adnexal and cervical tenderness.

### **2. MITTLESCHMERZ PAIN**

Mid-cycle abdominal and pelvic pain

### **3. ECTOPIC GESTATION**

Tubal abortion resembles acute appendicitis. Pain commences on the right side and stay there. Cervix is softened. Referred pain to shoulder is present. H/O missed menstrual periods and positive pregnancy test are present.

### **4. RUPTURED OVARIAN FOLLICLE**

It is indicated by the history and ultrasound finding..

### **5. TWISTED RIGHT OVARIAN CYST**

Pain is severe, often referred to the loin, and is made worse when the patient rolls over.

## **6. SIGMOID DIVERTICULITIS**

Long sigmoid loop with diverticulitis lies to the right of midline. Impossible to differentiate. Abdominal CT is particularly useful.

## **E) The Retroperitoneal Structure**

### **1. RIGHT URETERIC COLIC**

It commences in the loin and spreads to groin. Plain X-ray may show stone and urine analysis may be helpful.

### **2. RIGHT SIDED ACUTE PYELONEPHRITIS**

There is increased frequency of micturition, fever, rigor and pyuria.

## **F) Central Nervous system**

### **1. POST-HERPETIC PAIN**

Marked hyperesthesia and herpetic eruption.

### **2. TABETIC CRISIS**

Pain and vomiting and other signs of tabes are present.

### **3. SPINAL CONDITIONS**

Pott's disease, carcinomatous deposits, osteoporosis and myelomatosis causes compression of the nerve roots. Other conditions include porphyria, and diabetic crisis of course can be well differentiated.

## **TREATMENT<sup>36</sup>**

The correct treatment of appendicitis in all its aspects is one of the most important subjects in abdominal surgery because it is the most common major abdominal condition calling for emergency operation. The treatment of acute appendicitis is appendicectomy and the sooner done the better. There are four exceptions to this excellent rule.

1. The patient is moribund with advanced peritonitis.
2. The attack has already resolved. Here appendicectomy can be done as an elective procedure to prevent recurrence.
3. Where circumstances make operation difficult or impossible for example in a small boat at sea. This condition deserves conservative line of treatment.
4. An appendicular mass has formed without evidence of general peritonitis.

### **CONSERVATIVE TREATMENT: OSCHNER SHERRAN'S REGIME**

This method of treatment is applicable to all types of acute appendicitis in which operation is withheld due to one reason or the other. The details of the method may be :

1. Patient is nursed in a propped up position, in order to encourage any peritoneal exudate to gravitate towards the pelvis. This is not widely practiced nowadays.
2. Intensive chemotherapy is instituted.
3. First 24 to 48 hours, nothing is administered by mouth except sips of water. Gastric suction is advocated. After 24 to 48 hours, provided that all the symptoms are subsiding, fluid diet is commenced and gradually supplemented.
4. Careful recording of pulse rate and temperature.
5. Sedatives are given.
6. Too frequent abdominal examination must be avoided as this may activate

infection.

7. No aperient until pulse, temperature and abdominal condition settles.

The majority of patients react favorably to this treatment.

### **INDICATION FOR OPERATION**

1. The most dangerous sign is a rising pulse rate. If this sign is present the conservative treatment should be discontinued and surgery adopted. A steady high pulse rate is also an indication for surgery.
2. High swinging temperature is also another indication.
3. Continuous pain, vomiting, diarrhoea are other features.
4. If there is spreading tenderness or resistance, surgery is preferred.
5. In certain group of patients, the abscess formation occurs which although is localised needs drainage if it becomes adherent to anterior abdominal wall and is pointing towards it.

In the present series, most of the cases were taken as emergency. Elective surgery was advocated in patients who had formation of mass or an abscess which was drained or treated conservatively due to other operative risk.

### **PRE-OPERATIVE PREPARATION**

In surgery, the preoperative preparation is very important for excellent operation and short convalescence. The steps include:

- (1) Re-expansion of intra vascular volume
- (2) Restoration of electrolyte balance
- (3) Resolution of fever
- (4) Antibiotic administration

(5) Continuous Ryle tube suction with no oral feeds

(6) No enema to be given.

A useful guideline to postpone surgery is till (1) temperature becomes less than 100° F (2) Pulse rate less than 120/mt. (3) The patient has voided urine atleast once. All these corrections can be done within 4 to 6 hours. The patients vital signs and clinical response form the ultimate test of satisfactory response.

In the present study, 80% of the cases were operated within 2-4 hours after admission; with initial pre-operative preparation like I.V. fluids, Ryle's tube aspiration; and antibiotics. The antibiotics commonly used were cefotaxime, Garamycin and Metronidazole injections. Bates in 1980 and Simons et al and Devitt et al indicate the potency of Metronidazole.

## **ANAESTHESIA**

The type of anaesthesia for appendicectomy is determined by the preference of surgeon and anaesthetist, whether general anaesthesia or spinal.

## **INCISIONS**

There is no one special incision for appendicectomy. Experience should enable the surgeon to determine with a fair degree of accuracy the position and the pathological changes in the appendix before operation. When the patient is fully anaesthetised the surgeon should once again systematically palpate the abdomen to locate the appendix, which may be felt as a circumscribed lump, diffuse thickening or as a movable tumor. The incision can then be planned to give adequate exposure, without being excessive. If

the appendix lies immediately beneath the abdominal wall in the right iliac fossa, then a McBurney's grid iron incision is the choice. If required, the incision may be extended inward through the sheath of the rectus muscle called the Fowler Weir incision. Morrison's modification or more correctly Kocher's modification of the McBurney's incision in which all the muscles are divided transversely or obliquely in line with the incision and is useful to gain access to a hidden adherent retrocaecal appendix in an obese patient. When appendix is thought to be central in position or is lying in the pelvic cavity a median or paramedian subumbilical incision is chosen. Battle's pararectal incision is preferred by some surgeons though not widely used as there are more chances of post operative wound dehiscence and incisional hernia. Transverse or Rockey-Davis incision gives rapid access to the right lower portion of abdomen, If the incision is appropriately placed centered in the midinguinal point 1-2cm below umbilicus. However, there was a theoretical objection to transverse incision. The medial end of the incision is relatively close to the midline, so that when localized pus was present and spillage occurs, there was a danger of dissemination.

In the present series three main incisions were chosen in the cases. They are (1) Lanz incision (2) McBurney s (3) Right Paramedian (4) Laproscopic

### **LANZ INCISION**

It is a skin crease Langer's line incision. It is made more or less transversely and curves so that it lies in the interspine crease. Thereafter the muscles are divided as in classical gridiron approach. This incision has a definite cosmetic value.

## **McBURNEY'S INCISION**

It is an incision perpendicular to the spinoumbilical line on the McBurney's point, 2/3 of the length below and 1/3 of the length above the line. The McBurney's incision was undoubtedly the most popular, but it is the Transverse or Rockey-Davis incision that meets the criteria for an appropriate incision most closely.

## **RIGHT MID OR LOWER PARAMEDIAN INCISION:**

Doubts as to the correctness of diagnosis could be tackled safely with this incision.

## **PROCEDURE**

By any of the above said incisions the abdomen is opened. Retractors are inserted beneath the peritoneum and the wound margins separated to permit inspection. Omentum will be seen and is a good evidence of acute appendicitis. The caecum is picked up with fingers or turtle's forceps. The appendix is lifted and coaxed gently on to the surface of the skin. The flimsy adhesions to the surrounding structures can often be atraumatically separated by dissection with a small swab or dissecting forceps this enables us to note the position of appendix.

The freed appendix can be brought out, with a Babcock's forceps. If the mesoappendix is long, they are ligated with silk. When the mesoappendix is gangrenous, careful ligature application is needed. It is essential to insert a single interrupted suture close to the base of the appendix at its mesenteric border in order to secure the intramural branch of the posterior caecal artery, a branch of appendicular artery. A purse string suture is applied around the base. The freed appendix is drawn upwards and the base is

crushed. After removal of the forceps, the crushed area is ligated with chromic catgut. Appendix is cut and the stump cauterised and invaginated by pulling the purse string. Few interrupted suture in the caecal wall as Z stitch can also be done. When the caecal wall is swollen and oedematous the purse string is omitted, instead two strong ligatures are applied to the base of the appendix, the sprouting mucous membrane is cauterised. When the base is inflamed, it should not be crushed for fear of distributing infection. It should be ligated close to the caecal wall just tight enough to occlude the lumen after which appendix is amputated.

The methods of treating the appendix stump:

1. Simple ligation of the stump.
2. Ligation and inversion of the stump.

**Wound closure:**

After removal, the operated area has been irrigated (in gangrenous or perforated appendix) each fascial and muscular layer was closed with an absorbable suture material. Skin was closed with non-absorbable sutures.

**RETROGRADE APPENDICECTOMY**

It is indicated when the appendix base is autoamputated or when appendix base is well visualised but the remaining portion is either in the paracolic or retrocaecal in position. The base of the appendix is held between finger and thumb and fine hemostat is passed between the caecum and appendix to create space and two similar instruments are applied across the appendix and divided. The mesoappendix is clamped and divided by traction on the distal clamp. The purse string is introduced and then the appendix is freed. Then a regular method of appendicectomy is followed.



## **PERITONEAL TOILETING**

This is done in cases of perforation, peritonitis, using normal saline and metronidazole.

## **DRAINAGE**

Drainage of the peritoneal cavity is not always necessary especially so in an imperforated appendix. Drainage is not advised even after excision of an inflammatory mass.

Aird felt that the mortality rate of the abscess could be reduced by drainage of the abscess. Campbell and Me.Phail are of the same view. Drainage is required when

1. Following the removal of a gangrenous appendix in a walled off abscess.
2. After appendicectomy for diffuse appendiceal peritonitis.
3. When appendicectomy could not be done and when in doubt, drain is kept,

Free peritoneal drains may be detrimental perpetuating the inflammatory process by foreign body reaction but also serving as a nidus for intra-abdominal adhesions.

## **LAPAROSCOPIC APPENDICECTOMY**<sup>37,38</sup>

Performed through three small incisions of 10 mm, 5 mm, and 10 mm, at the level of umbilicus through which the telescope is introduced, at the right costal margin in the mid axillary line and the left iliac fossa for operating instruments.

### **Advantages**

1. Procedure is done under direct vision.
2. Less pain and early recovery.
3. Reduced pulmonary complication post operatively.

4. Minimal handling of the small intestines which minimizes serosal damage which can lead on to adhesion formation.
5. Less tissue trauma because of small operating instruments.
6. Associated gynecological problems can be managed easily.
7. Short hospital stay.

**Disadvantages:**

1. Operative time required is more compared to open appendectomy.
2. Setting up of instruments and team is difficult for emergency appendectomy.
3. It is expensive compared to conventional method.
4. Expertise in technique is needed.
5. Procedure is not useful if perforation or peritonitis is present.

In summary, laparoscopic appendectomy is a safe alternative to open appendectomy.

## **COMPLICATIONS AND THEIR MANAGEMENT<sup>18</sup>**

### **1.PERITONITIS**

The symptoms and signs of peritonitis could be grouped into two. Reflex symptoms which occurs early and toxic which occurs late. Reflex symptoms and signs are pain, vomiting, anxious facies, abdominal muscular rigidity, collapse, fever etc. There is an increased relationship between the toxic and reflex symptoms. Severe toxemia diminishes the sensitivity of the reflex one. The progress of peritonitis is altered by the treatment and it may get localised in (1) Right iliac fossa (2) Cul-de-sac of Douglas (3) Sub-phrenic area. Most of the cases do not go in to generalised peritonitis because of

'walling off' of appendix by omentum and coils of intestines. Certain cases do develop generalised peritonitis with typical Hippocratic facies etc.

## **TREATMENT**

The preoperative preparation is similar. A right subumbilical paramedian incision is made. Verify the positions and condition of the appendix. Caecum is gently freed from adhesions. Appendix delivered and appendicectomy done. If caecal wall is inflamed the purse string burial may be difficult. Peritoneal cavity toileted and drained.

## **2. MECHANICAL INTESTINAL OBSTRUCTION AND ILEUS**

Ileus may be due to local or generalised peritonitis. Mechanical obstruction is due to formation of adhesions which are part of protective process. These adhesions are light and flimsy. Incorporation of a bowel in an appendiceal abscess is a frequent cause of ileus.

The distinction between mechanical obstruction and ileus is very important because the former needs surgical treatment whereas the latter can be treated conservatively.

## **1. PRIMARY PERIAPPENDICULAR ABSCESS**

A ruptured appendix in which the pathological process has localised or a diffuse peritonitis with signs of localisation is the formation of an abscess. Signs and symptoms are widely varied depending upon the site of the appendix and location of the abscess. There are two types of abscesses:-

### **i) Recent Abscess:**

This is a local collection of pus pooling around perforated appendix that is completely shut off by the greater omentum, the abdominal parietes and adjacent coils of intestine that are loosely gummed together.

**ii) Established abscess:**

This is a chronic abscess and the surrounding structures densely adherent.

**1. PELVIC ABSCESS:**

Easiest to diagnose once it is suspected. A repeated rectal examination every 48 hours is diagnostic. Before the formation of abscess the patient has bowel and bladder irritation due to pus tracking down due to gravity. Pelvic abscess if it points towards vagina, a posterior colpotomy can be done. It is always preferable to drain rectally.

**2. ILEOCAECAL ABSCESS**

Presents as a primary peri-appendiceal abscess.

**Technique of Drainage**

After anaesthesia, incision is made over the prominent and fluctuant area. Peritoneum is carefully entered as the intestines may be adherent. Index finger inserted and the pus evacuated. Drainage tube is placed. Tube is left in situ for about 72 hours. Abscesses are best approached by an incision immediately medial to the anterior superior iliac spine. The lateral edge of the peritoneum exposed and by stripping it medially with the finger and the mass is reached retro-peritoneally.

**OTHER POST-OPERATIVE COMPLICATIONS**

**1. Early Complications**

- a) Local 1.Woundsepsis, 2.Abscess, 3.Infected sinus, 4.Dehiscence,  
5. Faecal fistula, 6.Keloid, 7.Haematoma.
- b) Pulmonary : 1.Basal pneumonitis, 2. Atelectasis
- c) Coronary : Thrombosis
- d) Due to appendicular mass

1. Unresolving appendicular abscess rupturing into urinary bladder, ureter, rectum, small intestine, vagina.
2. Peritonitis.
3. Adhesive ileus.
4. Pyelophlebitis.
5. Thrombosis of major vessels.

## 2. **Late complications**

1. Incisional hernia
2. Right inguinal hernia.
3. Adhesive obstruction.
4. Pyelophlebitis, Liver abscess
5. Infertility (women).

# *Methodology*

---

## **METHODOLOGY**

### **STUDY DESIGN:**

This study is a prospective study.

### **FOR NON INFLAMMED CASES:**

These cases represents the normal population .These are patients admitted in Coimbatore medical college during the period of Nov 2009 to Dec 2011 for which laparotomy done for other conditions than appendectomy. All of these cases are opened as in any other laparotomy and appendix position and length noted first before disturbing any of the structure. This is recorded in the profoma.

Any patients with pathology in the caecum and terminal ileum were excuded in this study.

### **FOR CLINICAL CASES:**

All cases with diagnosis of appendicitis admitted in Coimbatore medical college during Nov 2009 to Dec 2011. All cases are subjected to clinical evaluations like signs, symptoms, and investigations like ultrasound if clinical findings are doubtful. History is elicited thoroughly regarding any atypical presentation. Clinical examination included head to foot examination and to look for clinical signs of appendicitis like Rovsing sign, Obturator sign, Baldwin sign, Psoas sign and per rectal examination. These are noted in the proforma .

During the surgery by any method appendix position, length, with or without complications like perforation and abscess formations were noted. The appendix specimen was sent for histopathological examination to the qualified pathologist. Those cases that are inflamed are included in the study and those not inflamed are excluded.

## **PROFORMA**

### **For clinical cases (representing inflamed cases)**

Serial No. Age: Sex

Name:                                      Ward:                                      Unit:

I.P.No.                                      Occupation:

Address:

Date of admission:

Date of operation:

Date of discharge:

#### **I. Presenting complaints:**

a) Pain:              Duration:              Nature: Typical /Atypical Radiation :

b) Vomiting: Duration: Frequency:

Projectile / Regurgitated / bile stained / Not bile stained /

Pain relief after vomiting / contents of vomitus.

c) Fever: Duration: Intermittant / continuous

Associated with chills & rigors.

d) Diarrhoea / Constipation / Tenesmus / Blood & mucous.

e) Urinary complaints: Duration: Frequency:

Dysuria / Burning / Haematuria / Radiation of pain.

f) Any other complaints:



## **II. Family history**

**III. Past history:** Number of similar attacks in the past:

Previous hospitalization & follow-up:

**IV. Menstrual history:** Regular / Irregular Spotting

\_\_\_\_\_ / \_\_\_\_\_ days

Deliveries:

## **V. Per - Abdomen**

**Inspection:** Normal / Fullness

Pointing test: Umbilicus / RIF

**Palpation:**

Site of maximum tenderness: RIF / Flank / Mc Burney's point.

Rebound tenderness

Rovsing's sign / Psoas sign / Baldwin's sign / Obturator sign:

Local temperature

**P.R:** Tenderness - Yes / No      Mass : Yes / No

## **VI. Investigations:**

Hb: \_\_\_\_\_ gm%    TC:      DC:      ESR:

Urine: Albumin \_\_\_\_\_ , Sugar \_\_\_\_\_ , Microscopy \_\_\_\_\_

### **Ultrasound Abdomen:**

RIF: APPENDIX - Length

- Diameter

- Mass / Abscess

- Appendicolith

- Probe tenderness

Pelvis:

Other findings:

## **VII. SURGERY:**

Date:            Time:            Emergency/Elective

Preoperative diagnosis:

Postoperative diagnosis:

Incision:

Type of anaesthesia:

**Operative findings: - Position:** Preileal / Postileal / Retrocaecal /

Paracaecal / Subcaecal / Pelvic / Promonteric

- Length

- Appearance

- Intraperitoneal / Extraperitoneal

- Fixed / Mobile

Caecum:

Ileum:

Other organs:

## **PROFORMA**

**For OTHER LAPAROTOMY cases (representing normal population)**

Serial No:

Age :

Sex:

Name IP. No.

Address :

Date of surgery:

Diagnosis:

Position of the appendix

- Retro-caecal

- Para-caecal

- Sub-caecal

- Pelvic

- Promonteric

- Post-ileal

- Pre-ileal

Length of the appendix

Intra-peritoneal / Extra-peritoneal

# *Results*

---

## RESULTS

Total number of cases studied were 125 cases of which 75 cases were normal population i.e. cases for which laparotomy done other than for appendicitis. Remaining 50 cases are inflamed group, patients with appendicitis whose histopathology report is positive.

In our series appendicitis is more common during the 2<sup>rd</sup> decade (36%), followed by the 3<sup>nd</sup> decade (30%). About 78% are male patients with appendicitis. Hence there is male dominance.

The chief complaints of most patients are fever and abdominal pain. Fever is present more than half the patients with appendicitis. Abdominal pain is severe in intensity in 72% of the population, 68% of patient shows typical right iliac pain and tenderness rest of them showed vague pain. About four cases (case no.16,22,24,44) presented with signs of diffuse peritonitis but peroperatively only two cases had perforation (Fig No.12) and two had abscess collection in right iliac fossa.

Anorexia is present only in 20% of patients while vomiting and nausea predominates the history in 48% of patients.

8 cases had atypical presentation and the position of those appendix are mostly retrocaecal and then comes ileal position in this 8 cases four had emergency surgery (Fig No.10).

Psoas test was positive in 2 case both had retrocaecal position ,obturator test is positive in two cases both had pelvic position of appendix. Tenderness on per rectal

examination is present in 5 cases in which 3 were pelvic (Fig No.11) and other 2 were gangrenous. No other test was positive in our patients.

Total number of emergency cases done were 33 nearly 67%. Two cases (no.14,27) presented with appendicular mass and interval appendectomy was done after 2 months. The position of appendix in these cases were retrocaecal (Fig No.13).

Length of appendix was variable and did not influence the position. Smallest was 6 cm and the lengthiest was 19 cm in our study. The average length was 10.3cm.

The position of the appendix influences the clinical presentation of the appendicitis with the retro-caecal position (30% of cases), post-ileal position (14% of cases), and the Pelvic position (20% of cases) presenting with atypical symptoms. 22% of cases presented atypically of which commonest position is retrocaecal. About 60% of retrocaecal position is fixed retro-caecal cases, which has got fixed, either because of the adhesions or the extra-peritoneal fixation of the appendix. This causes the atypical presentation.

One case(no.28) presented as right lumbar region pain and hence caecum was sub hepatic with retrocaecal position. There were 6 cases of perforation appendix of which two had abscess formation ,both had appendectomy and a drain was kept, about 5 cases of gangrene was seen all were taken up as emergency most of them were retrocaecal. Two cases had generalized peritonitis both were opened in lower midline incision . Their position were retrocaecal and preileal. There were no complications in both cases

**TABLE NO - 4****DISTRIBUTION OF AGE AND THE POSITION OF APPENDIX IN  
INFLAMMED CASES**

age	<20	21-30	31-40	41-50	>50
retrocaecal	8	7	6	1	1
preileal	5	2	2	1	1
postileal	1	4	2	-	-
subcaecal	1	1	-	-	-
Promontory		1	-	-	-
pelvic	2	-	2	-	-
paracaecal	1	-	-	-	-

**TABLE NO - 5****LENGTH OF APPENDIX IN INFLAMMED AND NORMAL CASES**

<b>Length</b>	<b>No. cases in inflamed</b>	<b>Percentage</b>	<b>No. of cases normal</b>	<b>Percentage</b>
<7 cm	13	26%	15	20%
7-12cm	30	60%	48	66%
>12cm	7	14%	12	16%

Fig No.4 Distribution of Age in The Position of Appendix in Inflamed Cases

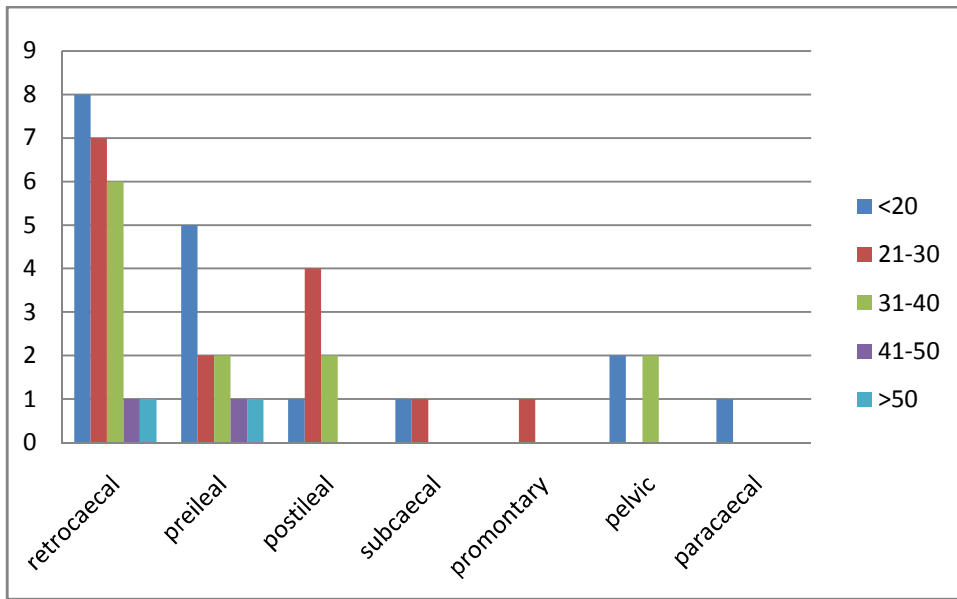


Fig No.5 Age of onset of Acute Appendicitis

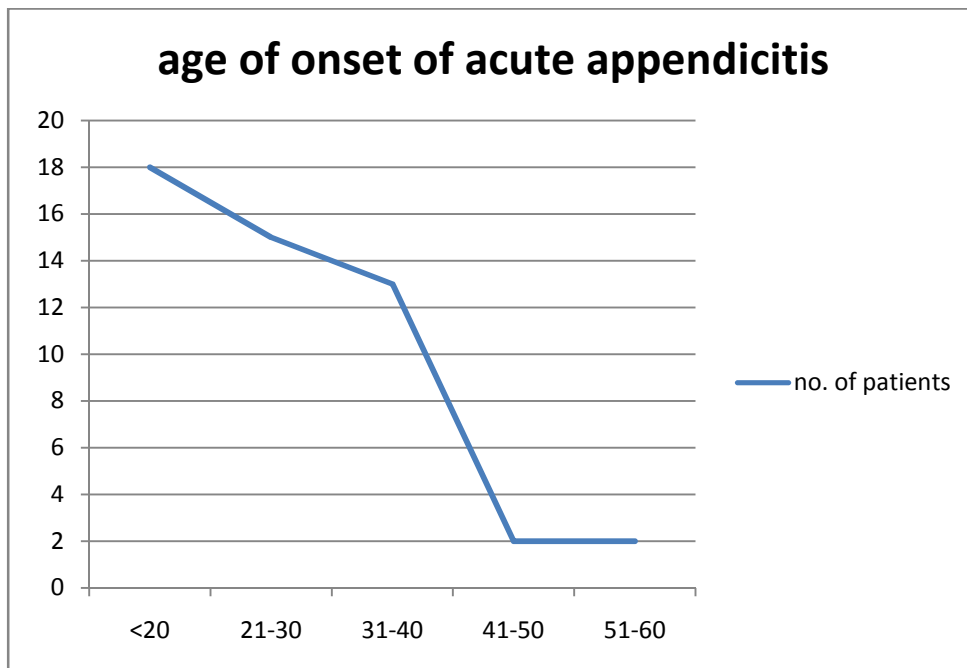
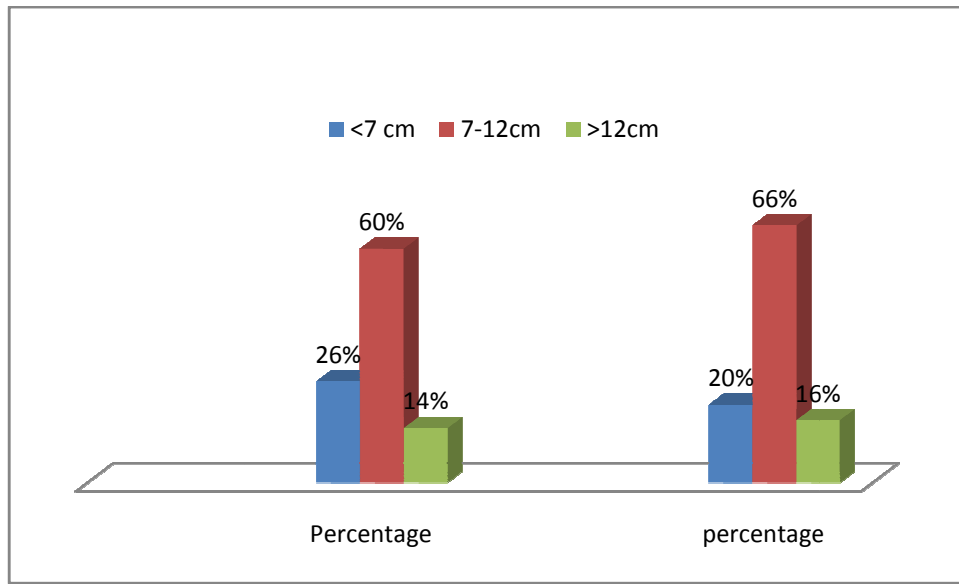




Fig No.6 Length of Appendix



**TABLE NO - 6**

**DISTRIBUTION OF SEX IN POSITION OF APPENDIX**

**INFLAMED CASES**

**NORMAL CASES**

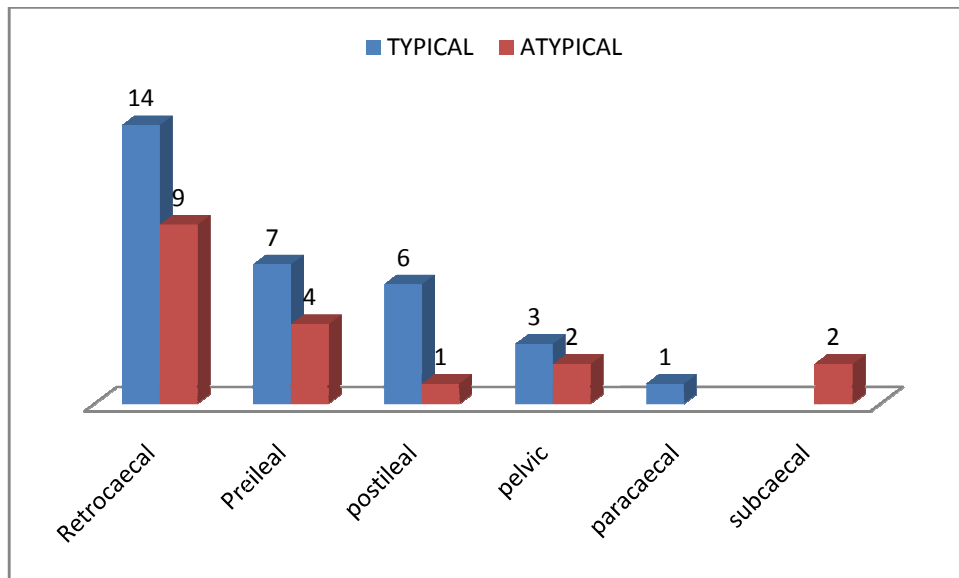
Position	Male	Female	Total	Male	Female	Total
Retrocaecal	19	4	23	26	7	33
preileal	9	2	11	4	1	5
Postileal	6	1	7	12	2	14
Paracaecal	0	1	1	1	0	1
Subcaecal	2	0	2	3	2	5
Pelvic	2	3	5	10	3	13
Promontory	1	0	1	4	0	4
<b>Total</b>	<b>39</b>	<b>11</b>	<b>50</b>	<b>60</b>	<b>15</b>	<b>75</b>

**TABLE NO - 7**

**TYPICAL AND ATYPICAL PRESENTATION OF APPENDICITIS**

<b>POSITION</b>	<b>TYPICAL</b>	<b>ATYPICAL</b>	<b>TOTAL</b>
Retrocaecal	14	9	23
Preileal	7	4	11
Postileal	6	1	7
Pelvic	3	2	5
Paracaecal	1		1
subcaecal		2	2

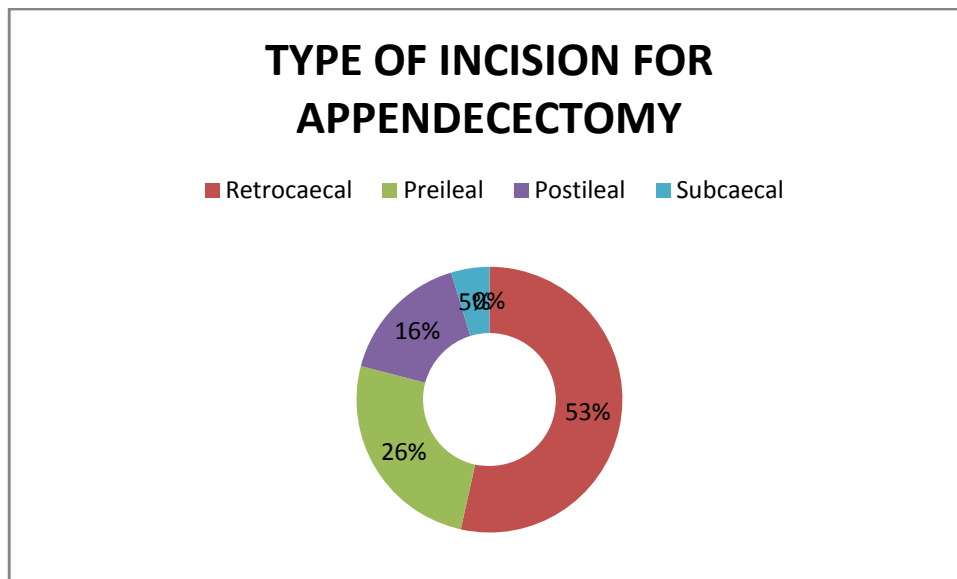
Fig No.7 Typical and Atypical Presentation OF Appendicitis



**TABLE NO - 8**

<b>surgery for appendicitis</b>	<b>No. cases</b>
McBurney's	25
Midline	6
Lanz	12
Laprosopic	7

Fig No.8 Type of Incision For Appendectomy



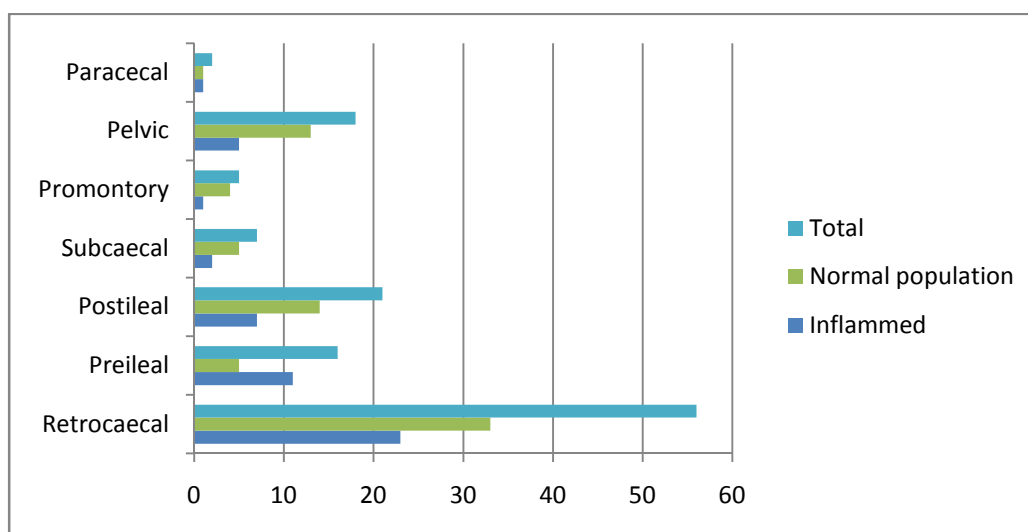
## STATISTICAL DATA FOR THE STUDY

### TABLE NO - 9

#### POSITION OF APPENDIX IN NORMAL POPULATION AND IN INFLAMMED CASES

Position	Inflammed	Percentage	Normal population	Percentage	Total
Retrocaecal	23	46%	33	44%	56
Preileal	11	22%	5	6.6%	16
Postileal	7	14%	14	18.6%	21
Subcaecal	2	4%	5	6.6%	7
Promontory	1	2%	4	5.3%	5
Pelvic	5	10%	13	17.3%	18
Paracecal	1	2%	1	1.3%	2

Fig No. 9 Position of Appendix in Normal Population and  
in Inflammed Cases



**TABLE NO - 10**

**COMPARISON OF POSITION OF APPENDIX IN INFLAMMED AND  
NORMAL CASES**

<b>Position</b>	<b>Inflamed</b>	<b>Normal</b>	<b>TOTAL</b>	<b>X<sup>2</sup></b>
Retrocaecal	23	33	56	0.0160
Preileal	11	5	16	3.3060
Postileal	7	14	21	0.2333
Paracaecal	1	1	2	0.0500
Subcaecal	2	5	7	0.2285
Pelvic	5	13	18	0.6722
Promontory	1	4	5	0.5000

P value = 0.9941 ,hence p value >0.1 i.e not significant.

Fig No.10 Inflammed Appendix with Gall Stone

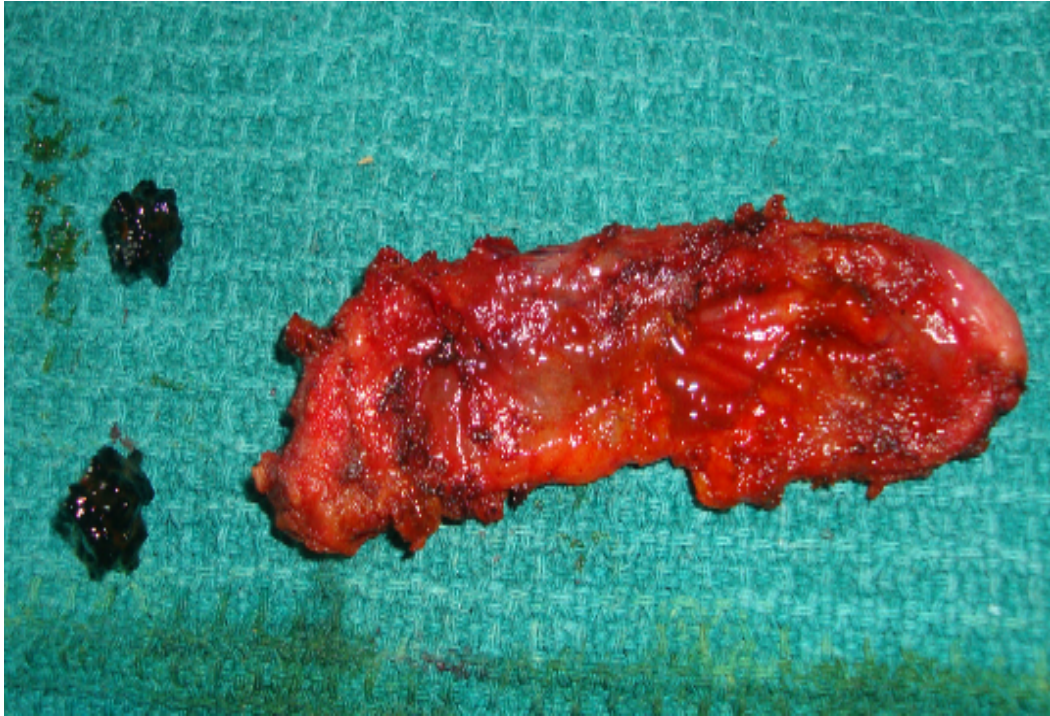


Fig No.11 Pelvic Appendicitis

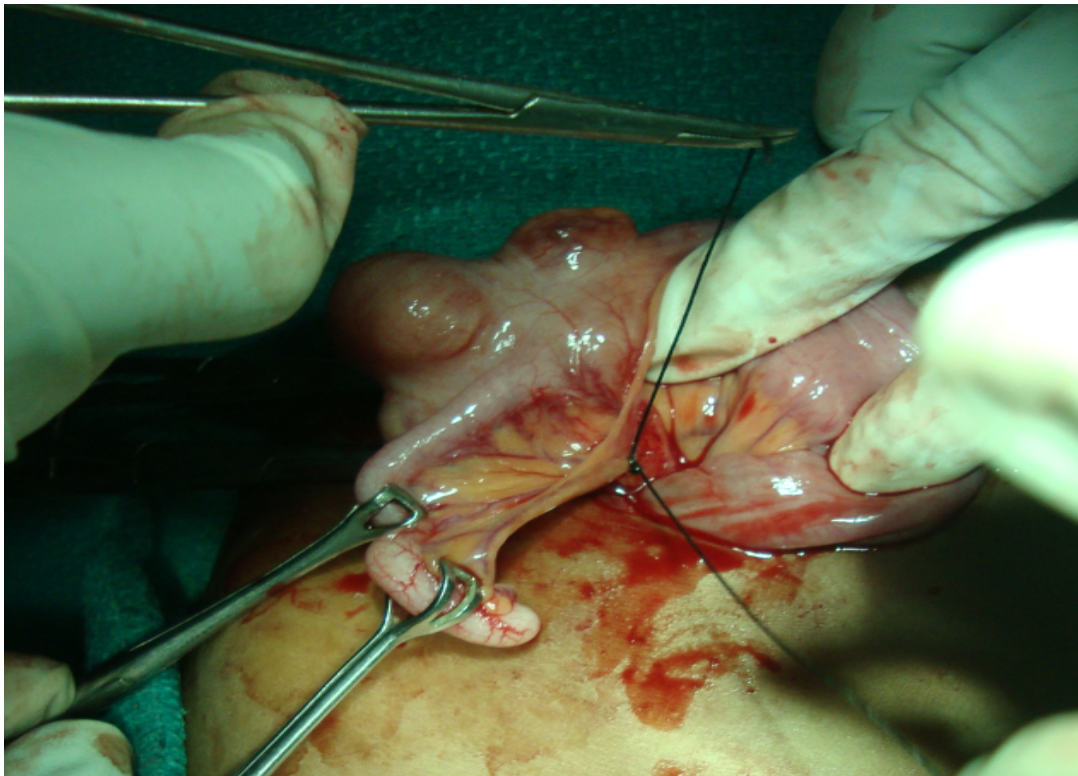




Fig No.12 Thickened, Elongated and Perforated Appendix

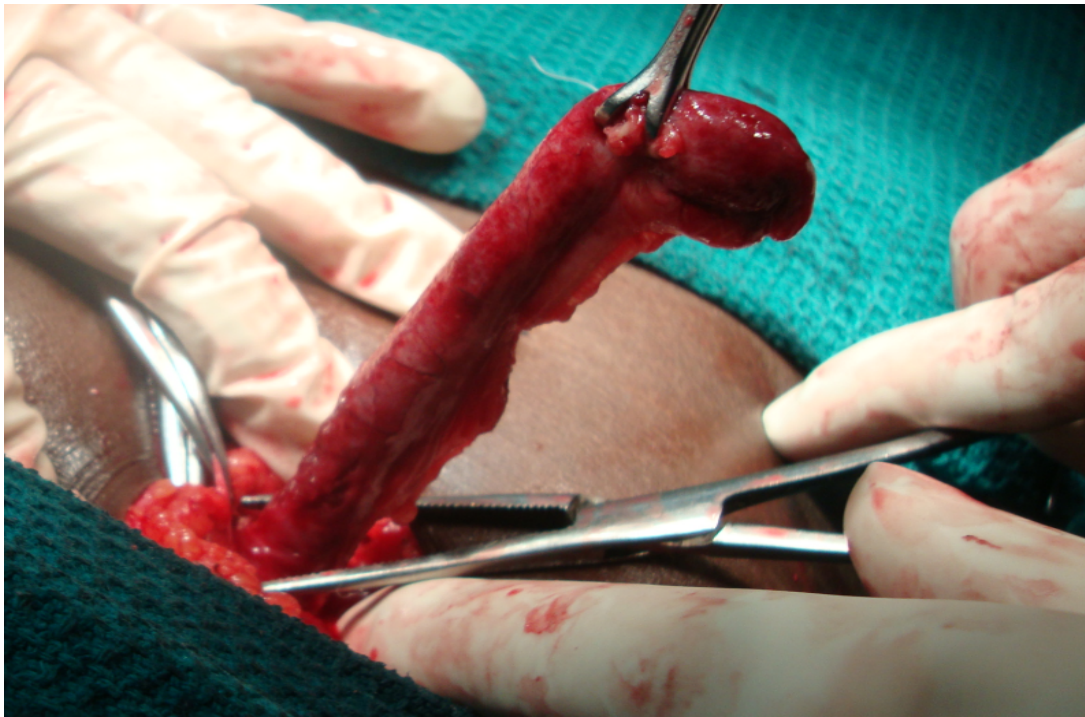
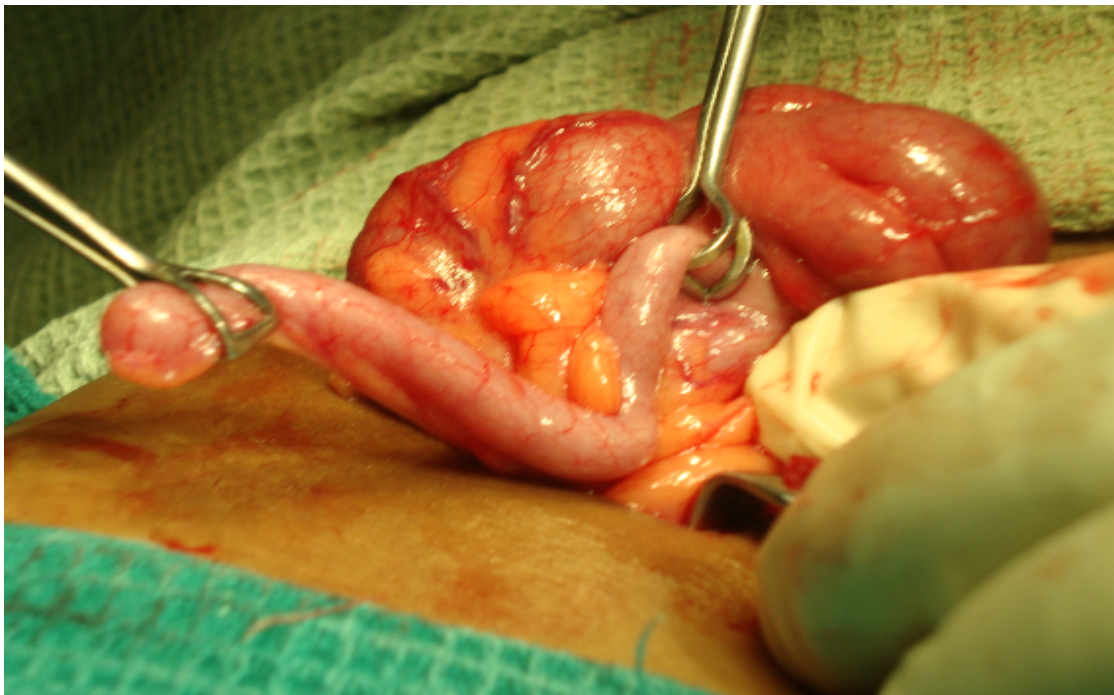

Fig No.13 Retro-Caecal Appendix



# *Discussion*

---



## DISCUSSION

Though acute appendicitis is a common condition, an accurate preoperative diagnosis remains a challenge because of the various other conditions, which mimic appendicitis. This is because of its variation in position and in presentation.

That is why I took this study for comparing position of appendix in inflamed cases and other laprotomy cases. The inflamed cases were evaluated with clinical features at presentation, the position of the appendix at laparotomy and also the associated complications. All cases in the clinical group was confirmed by histo-pathology.

The total no. of male patients in the clinical group were 39 and the total no of female patients were 11. Male to female ratio is 3.5: 1. Men outnumbered women in our study, men was believed to suffer from appendicitis more often because, probably the male are being subjected to more stress and strain, as highlighted by Boyd (1961). Addis et al & Korner et al, had reported a slight male preponderance (with male to female ratio of 1.2 to 1.3: 1).<sup>(39,40)</sup>

Our study found appendicitis to be more common in the second decade followed by the third decade

The average mean age of presentation was 25.1 years. Lewis et al<sup>(41)</sup> (1975) in their study found that the 2<sup>nd</sup> and 3rd decades to be the most common age groups for acute appendicitis.

Nausea was present in 76% of the cases and anorexia was present in 34%. Vomiting seen in 48%. Lewis et al<sup>(41)</sup>, in his analysis, found anorexia, nausea or vomiting to be present in 66% of the cases.

Fever was commonly encountered among patients in our study, being present in 56% of our patients; the fever is usually mild degree except in cases of abscess and generalized peritonitis. Berry et al<sup>(42)</sup> in 1984 have in their analysis; found that temperature elevation was rarely more than 1<sup>0</sup> C (1.8<sup>0</sup> F). Changes of greater magnitude indicate that the complication had occurred or some other diagnosis should be considered.

Varshney et-al<sup>(43)</sup>, had come to the conclusion that the retro-caecal position is less prone to infection, by comparing the incidence of retro-caecal appendix in operated cases with the previous autopsy studies. His hypothesis is that the retro-caecal position of the appendix is advantageous because, gravity aided drainage of the appendicular lumen, may reduce the episodes of luminal obstruction, which reduce the incidence of appendicitis. Shen GK, et-al<sup>(9)</sup>, Williamson WA, et-al<sup>(10)</sup>, has established that the retro-caecal position does not alter the clinical course of appendicitis.

The various positions in the inflamed group was compared with other laprotomy for condition other than appendicitis representing the normal group. This was done by Chi square test for each position of appendix. All position P-value was >0.1. Hence the difference observed was not significant, indicating that there is no increased predisposition of any position to get inflamed. The position of the appendix and its relation to the clinical presentation and course of acute appendicitis has been a subject of controversy with various authors giving various results and conclusions.

The theory of Varshney et-al<sup>(43)</sup> was not acceptable, as many of the autopsy studies do not accept that the retro-caecal position, as the most common position (Maisel et-al<sup>(12)</sup>, Peterson et-al, describe pelvic position to be the most common).

In our study there is an increased incidence in the complications in those with typical presentation, than those with atypical presentation. A patient with atypical presentation had less complication.

In case of retro-caecal position, the fixed appendix is associated with more complications (40%) as opposed to cases with mobile appendix (20%).

Poole GV<sup>(5)</sup> in 1990 has found that the appendix was in one of the three sites (extraperitoneal-retrocaecal, post-ileal, pelvic) in 69% of the patients were gangrenous or perforated appendicitis. In contrast only 2 patients with above position out of 50 patient had this complication.

In Collins<sup>(1)</sup> series of 751 patients with retro-caecal appendicitis, only 19% had typical symptoms, 18% had non-localizing pain, 28% had right flank pain and 12% had right shoulder pain. In our study only 6 of 33 cases of retrocaecal appendix were perforated.

Varshney et-al<sup>(43)</sup> had described that retro-caecal appendicitis goes for advanced appendicitis (perforation or gangrene). They had given the explanation that some early cases were misdiagnosed, as urinary tract infection, leading to delay in the diagnosis, and increased incidence of complications. In our study it was retrocaecal appendix had increased incidence of complications.

# *Conclusion*

---

## CONCLUSION

This study was conducted in COIMBATORE MEDICAL COLLEGE HOSPITAL during the period of November 2009 to December 2011 of about 24 months. Study group consist of two population they are inflamed population i.e. clinical group comprising of 50 cases of biopsy proved appendicitis and normal population comprising of patients for whom laprotomy done for other than appendectomy.

The following conclusions was drawn from the present study

- Appendicitis is slightly more common in males, M: F ratio is 3.5 : 1.
- Appendicitis is commonest during the 2<sup>nd</sup> decade (36%), followed by the 3<sup>rd</sup> decade (30%)
- Pain site is variable in appendix. In pelvic appendix patients had supra-pubic pain, in retro-caecal appendix patient has pain in the right lumbar region or right flank, in sub- hepatic position the patients has pain in the right hypochondriac region. These are typical pain seen in 76% and atypical presentation seen in 24%. Atypical pain was more common in cases of fixed retro-caecal appendix and in cases of pelvic appendicitis.
- Vomiting and nausea (48% of cases) is the most commonly seen in appendicitis, anorexia are seen less commonly.
- Incidence and severity of vomiting was more in patients with complicated appendicitis (48%) as compared to simple acute appendicitis.
- Patients with retro-caecal appendix have symptoms of upper urinary tract infection, due to irritation of the adjacent structures.

- Tenderness in Mc Burney's point was present in only 10 patients (20%) in other cases it was present first near to this point.
- Rebound tenderness was present in 50% and few patients presented with right lumbar pain as in ureteric colic that is differentiated by other signs.
- According to the position the site of tenderness may vary .In retro-caecal position tenderness are present in the right flank or in the right lumbar region more so if the appendix is fixed either by the adhesions or because of its extra-peritoneal location (in these cases tenderness will be more in this region rather than right liac fosasa). In case of pelvic position tenderness was present in the suprapubic region or patient had rectal tenderness. In sub-hepatic position patient had tenderness in the right hypochondriac region.
- Psoas test is not positive in all cases of retrocaecal appendix .But it is positive in appendix that is fixed.
- Obturator test is not positive in all pelvic appendix but it gives evidence if perforated or gangrenous appendix.
- Per Rectal examination is for pelvic appendicitis without abscess. Rectal tenderness is present in 3 of the 5 cases of pelvic appendicitis and in two cases of gangrenous appendix.

Patients with mobile appendix presents with typical signs and symptoms, whereas those with fixed appendix either by inflammatory process or by its extra-peritoneal location mostly presents with atypical signs and symptoms.

The most common position in both inflamed cases and non-inflamed cases are Retro-caecal, followed by splenic position ,pelvic,subcaecal and Para-caecal .

There was no increase in predisposition for any of the position of appendix to get inflamed. There was increased risk of complications in those with typical presentation than those with atypical presentation. Only 7 of 33 (21%) cases with typical presentation had complications whereas 4 of the 17 cases (76%) with atypical presentation had complications.

The patients with appendicular abscess and generalized peritonitis who were operated had delayed recovery; in all other patients there was no difference in the post-operative recovery of the patients whether they were complicated or uncomplicated.

# *Summary*

---



## SUMMARY

This study was conducted in COIMBATORE MEDICAL COLLEGE HOSPITAL during the period of November 2009 to December 2011 of about 24 months. Study group consist of two population they are inflamed population i.e. clinical group comprising of 50 cases of biopsy proved appendicitis and normal population comprising of 75 patients for whom laprotomy done for other than appendicectomy.

These two groups were compared and the following data obtained

- Appendicitis is slightly more common in males, M: F ratio is 3.5 : 1.
- Appendicitis is commonest during the 2<sup>nd</sup> decade (36%), followed by the 3<sup>rd</sup> decade (30%)
- The position of the appendix has influences on the clinical presentation of appendix .Most of the patients had McBurneys tenderness with few showing varied signs and symptoms leading to delayed diagnosis.
- Retrocaecal is the most common position by our study in both inflamed and normal group.
- This is in contrary to the study conducted by Varshney et-al the frequency of retro-caecal position is much less, also the frequency of the postileal appendix is more.
- There is no statistically significant difference in the position of the appendix in inflamed and normal group, suggesting that there was no predilection of any position of the appendix to get inflamed.
- The length of the appendix was more in male than females both in inflamed and normal group

- Patients with typical presentation have more complications than those with atypical presentation
- In pelvic appendicitis patients present with supra-pubic pain and other symptoms of lower urinary tract infection, patients usually present with subtle symptoms and may occasionally have bowel disturbances; tenderness on digital rectal examination are a constant feature.
- In retro-caecal appendicitis the patient may experience flank pain and tenderness and symptoms of upper urinary tract infection because of proximity of the appendix to the ureters, these features are more common if the appendix is fixed either because of adhesions or because of its extra-peritoneal location.

# *Bibliography*

---

## BIBLIOGRAPHY

1. **Collins DC.** 71,000 human appendix specimens: a final report, summarizing 40 years study. **Am J Proctol** 1963; 14:365-381.
2. **Pickens G, Ellis H,** The normal vermiform appendix at C.T visualization and anatomical location. **Clin. Anat**, 1993; 6:9.
3. **Wakeley CPG.** The position of vermiform appendix as ascertained by the analysis of 10,000 cases **J.Anat** 1933; 67: 277-283.
4. **Guidry SP, Poole GV.** The anatomy of appendicitis. **Am Surg.** 1994 Jan; 60(1): 68-71
5. **Poole GV.** Anatomic basis for delayed diagnosis of appendicitis. **South Med J.** 1990 Jul; 83(7): 771-773.
6. **SAHANA'S HUMAN ANATOMY,** Descriptive and Applied. Vol-II, Ankur edition Ankur Publications (AP): Jul 1994,362-367.
7. . Romanes, **CUNNINGHAM'S TEXT BOOK OF ANATOMY** 12<sup>th</sup> edition
8. **Williams Pl, Bannister LH, Berry MM, Collins P, Dyson M, Dussec JE,** et-al alimentary system In **GRAY'S ANATOMY**..36<sup>th</sup> edition, Churchill Livingstone, New York. 1995, 1353-1354.
9. **Treaves F,** Lectures on the anatomy of the intestinal canal and peritoneum in man. **Brit Med J**, 1885; 1:527-530.
10. **William B Marbury, Retrocaecal appendix.** **Ann Surg**, 1938; 107 : 819.
11. **Downs TMK.** Congenital malformations of Vermiform appendix: A Familial Disease. **Ann Surg**, 1942; 115: 21-24.
12. **Maisel H.** The position of vermiform appendix in fetal and adult age groups. **Anat Rec** 1960; 136: 385-389.
13. **Collins DC,** Agenesis of vermiform appendix. **Am J Surg.** 1951
14. R.C.G Russel, Norman S. Williams, Christopher J.K.Bulstrode, **Bailey & Love's SHORT PRACTICE OF SURGERY,** 24<sup>th</sup> edition. London: ARNOLD: 2004; 1203-1218.
15. **Nicholson, Percy:** Mechanical lesions of the Appendix in children as a basis for appendicitis. **Jour. Paediatrics**, 1936 Nov; 9:647-654.

16. **Harold Ellis, L. Keith Nathanson.** Appendix and Appendectomy in **Maingot's ABDOMINAL OPERATIONS**, Vol-II, 10th edition. APPLETON AND LANGE: 1997; 1191-1227.
17. John Sheperd, The appendix in, **ROB & SMITH'S CLINICAL SURGERY** Butter worth, London. 1960, Vol-10, 110-122.
18. Stanley L, Robbins et-al, **Basic pathology**. WB Saunders International, 5<sup>th</sup> edition, 1994, 519-520.
19. Theodore R. Schrock. Acute Appendicitis in **Sleisenger/ Fordtran Gastrointestinal diseases Pathophysiology, Diagnosis and management**, 4<sup>th</sup> edition Vol-II, SAUNDERS: 1989; 1382-1389.
20. **Doraiswamy NV.** Leukocyte counts in the diagnosis and prognosis of acute
21. appendicitis in children, **Br J Surg**, 1979; 60: 782-784.
22. **Eriksson S, Granstrom L, Carlstrom A.** The diagnostic value of repetitive pre-operative analysis of C reactive protein and total leukocyte count in patients with suspected acute appendicitis. **Scand J Gastroenterology** 1994; 29:1145-1149.
23. **Brooks DW, Vellein DR.** Roentgenographic findings in acute appendicitis. **Surgery** 1965; 57:377-384.
24. **Schisgall RM.** Use of Barium swallow, in the diagnosis of acute appendicitis **Am J Surg** 1983; 146: 633-637.
25. **Rajagopalan AE, Mason JH, Kennedy N, Pawlikowsky J.** The value of Barium enema in the diagnosis of acute appendicitis. **Arch Surg** 1977; 112:531-533.
26. **Jeffrey RB, Liang FC, Lewis FR.** Acute appendicitis High resolution realtime US findings. **Radiology** 1987; 163:11-14.
27. **Chesbrough RM, Burkhand TK, Barbara ZN.** Self-localization in US of appendicitis: an addition to graded compression. **Radiology** 1993; 187:349-357.
28. **Deutsch AA, Zelikovsky A, Reiss R.** Laparoscopy in the prevention of appendectomy: a prospective study. **Br J Surg** 1982; 69 : 336-337.
29. **Balthazaar EJ, Megibow AJ, Holnick et al.** C.T of appendicitis **AJR** 1986; 147:705-710.
30. **Shafi MI, Tarr RW, Partain CL, James AE.** Computer tomography and Magnetic resonance imaging of acute abdomen. **Surg Clin of North Am** 1988; 68:233-235

31. **Navarro DN, Weber PM, Kant.** Indium 111 leukocyte imaging in acute appendicitis. **AJR** 1987; 148: 733-736
32. **Evans C, Rashid A, Rosenberg IL,** An appraisal of peritoneal lavage in the diagnosis of acute abdomen. **Br J Surg** 1975; 62:119-120.
33. **Hoffman J.** Peritoneal lavage as an aid in the diagnosis of acute peritonitis of non-traumatic origin. **Dig Dis** 1988; 6:185-193.
34. **Caldwell MTP, Watson RGK.** Peritoneal aspiration cytology as a diagnostic aid in acute appendicitis. **Br J Surg** 1994; 81 :276-278.
35. **Alavarodo.** A practical score for the early diagnosis of appendicitis. **Ann of Em Med** 1986; 15: 557-564.
36. **Ramirez JM and Deus J.** Practical score to aid decision making in acute appendicitis. **Br J Surg** 1994; 81:680-683.
37. **Thomas V. Berne, Adrian Ortega.** Appendicitis and appendiceal abscess in **MASTERY OF SURGERY**, Little, Brown and company 3<sup>rd</sup> edition. Vol-II; 1997: P-1407-1411.
38. **Lori L Fritts, Rocco Orlando, Hartford Conn, Laparoscopic appendectomy:** A safety and cost effective analysis. **Arch Surg.**1993; 1(3): 208-212.
39. **Nowzardan Y et- al** Laparoscopic appendectomy for acute appendicitis; indications and current use, **J Laparoendosc Surg**, Oct 1991; 1(5) 247-257.
40. **Addis DG, Shaffer N, Fowler BS,** The epidemiology of acute appendicitis in United States. **Am J Epidemiol.**1990; 132:910.
41. **Korner H, Sondenna K, Soreide JA.** Incidence of acute non-perforated and perforated appendicitis: Age specific and sex specific analysis. **World J Surg.** 1997; 21:313.
42. **Lewis FR, Holcroft JW, Boey et-al.** Appendicitis: a critical review of the diagnosis and treatment in 1000 cases. **Arch Surg** 1975; 110: 677-684.
43. **Berry J, Malt RA:** Appendicitis near its centenary. **Ann Surg**1984; 200:567
44. **Varshney S, Jhonson CD, Rangnekar GV.** Retrocaecal appendix appears to be less prone to infection. **Br J Surg** 1996; 83:223-224

## MASTER CHART FOR NORMAL GROUP

S.No.	Name	Age/Sex	I.P. No.	Diagnosis	Date of surgery	Position	IP/EP	Length cm
1	Ponnammal	44F	42425	Cholecystitis	16-07-2010	REC	EP	12
2	Murugan	47M	9438	Cholilitiasis	16-02-2010	REC	IP	10
3	Dhanaban	40M	13483	Cholilithiasis	08-03-2010	REC	EP	10
4	Bose	45M	14653	SMA thrombus	14-03-2010	POIL	IP	8
5	Velan	38M	16722	DUP	23-03-2010	REC	EP	16
6	Jayaprakash	46M	18447	Ca stomach	27-03-2010	PLV	IP	7
7	Raju	35M	20901	Ileal per	05-04-2010	REC	IP	16
8	Manickam	35M	20824	DUP	05-04-2010	REC	IP	12
9	Samindev	35M	20717	GP	05-04-2010	SUBC	IP	10
10	Karuppan	60M	21532	ca rectum	08-04-2010	PARC	EP	11
11	Muthusamy	40M	20006	Cholilithiasis	11-04-2010	REC	IP	11
12	Siva	38M	23408	Ca colon	18-04-2010	PLV	IP	16
13	Irusappan	55M	24621	Ca stomach	24-04-2010	PRIL	IP	9
14	Murugasen	22M	25457	DUP	28-04-2010	POIL	IP	10
15	David	26M	27092	IO	07-05-2010	REC	EP	6
16	Subbaraj	45M	27586	OH	10-05-2010	PRM	IP	11
17	Ranganthan	55M	27865	IO	10-05-2010	PLV	IP	12
18	Palani	32M	28963	DUP	12-05-2010	REC	IP	6
19	Murugasen	55M	29216	IO	13-05-2010	PRIL	IP	9
20	Subramani	45M	26465	Ca colon	14-05-2010	POIL	IP	11
21	Noormohammed	50M	22798	Ca rectum	15-05-2010	REC	EP	13
22	Rajesh	30M	29438	DUP	16-05-2010	REC	IP	14
23	Subramani	44M	29654	Cholilitiasis	16-05-2010	REC	IP	9
24	Palanisamy	55M	30246	Ileal Per	17-05-2010	SUBC	EP	14
25	Annadurai	40M	30254	DUP	17-05-2010	PRM	IP	11
26	Myilsamy	40M	30453	IO	19-05-2010	REC	IP	6
27	Senthil kumar	37M	31045	IO	21-05-2010	REC	IP	10
28	David	70M	31962	OH	26-05-2010	PLV	IP	11
29	Jeyakumar	50M	32170	Ca stomach	27-05-2010	POIL	IP	9
30	Periyasamy	62M	32331	IO	28-05-2010	PRIL	IP	10
31	Nagaraj	44M	32312	DUP	28-05-2010	REC	EP	9
32	Palaniyappan	60M	32850	Ca rectum	31-05-2010	REC	IP	6
33	Sedumadhavan	65M	33416	Ca stomach	03-06-2010	PRM	IP	6
34	Paul raj	59M	35799	Ca colon	15-06-2010	PLV	IP	13
35	Pradeep	20M	36819	DUP	19-06-2010	REC	IP	12
36	Muthusamy	65M	36652	DUP	19-06-2010	REC	IP	6
37	Ponnmani	38F	37630	Ca stomach	23-06-2010	POIL	IP	10
38	Rajakumar	44M	39435	GOO	02-07-2010	POIL	IP	13

39	Vellaisamy	39M	40461	DUP	02-07-2010	REC	EP	11
40	Annadurai	38M	40558	DUP	02-07-2010	POIL	IP	6
41	Kalaivani	29F	40742	DUP	05-07-2010	PLV	IP	8
42	Pappu	30F	41399	Acute	05-07-2010	REC	IP	10
43	Suresh	25M	41246	BUA	11-07-2010	PLV	IP	11
44	Devya	32F	41360	Primary peritonitis	12-07-2010	SUBC	IP	9
45	Sinthamani	63F	41342	Ca ascending colon	12-07-2010	PLV	IP	19
46	Palaniammal	80F	42917	Ca sigmoid	19-07-2010	PRM	IP	11
47	Amaravathi	45F	44997	DUP	27-07-2010	REC	IP	10
48	Manimekali	51F	55779	Cholilitiasis	27-09-2010	REC	IP	10
49	Karuppathal	44F	57861	DLAP	30-09-2010	POIL	IP	10
50	Ayavu	75M	58530	DUP	04-10-2010	REC	IP	11
51	Jothi	40F	68936	DUP	06-10-2010	PLV	IP	6
52	Raman	40M	59727	CBD calculas	10-10-2010	POIL	IP	10
53	Anthony	27M	59870	DUP	11-10-2010	PRIL	IP	14
54	Senthil	26M	57029	DUP	27-10-2010	REC	EP	8
55	Natchimuthu	53M	63756	BUA	28-10-2010	POIL	IP	8
56	Logesh	30M	65154	DUP	01-11-2010	POIL	IP	6
57	Velligri	35M	65154	DUP	01-11-2010	PLV	IP	9
58	Ashok	17M	65175	DUP	07-11-2010	REC	IP	17
59	Sharamma	55F	69273	DUP	23-11-2010	SUBC	IP	11
60	Mary	56F	68847	Ca rectum	29-11-2010	REC	IP	12
61	Bathran	45M	5822	SMA thrombus	31-01-2011	REC	IP	8
62	Mahendran	37M	5879	Cholilitiasis	31-01-2011	PLV	IP	6
63	Kampathal	65F	73135	Ca stomach	14-02-2011	REC	EP	10
64	Sathish kumar	27M	14393	DUP	14-03-2011	PRIL	IP	11
65	Saravana kumar	27M	15925	DUP	21-03-2011	REC	EP	14
66	Dhandapani	65M	17268	SMA Thrombus	28-03-2011	SUBC	EP	10
67	Palanisamy	60M	3177	Ca stomach	18-04-2011	REC	IP	9
68	Kanagaraj	48M	27586	Cholilitiasis	16-05-2011	PLV	IP	6
69	Govindaraj	47M	27564	Ca rectum	16-05-2011	REC	EP	17
70	Palanisamy	42M	29124	Cholilitiasis	23-05-2011	POIL	IP	6
71	Bakiyam	70F	32126	Ca colon	27-05-2011	POIL	IP	14
72	Kaliyaperumal	55M	31917	Ca stomach	05-06-2011	POIL	IP	11
73	Mahalingam	24M	32211	DUP	06-06-2011	REC	EP	10
74	Ayyappan	43M	34818	Splenic abscess	20-06-2011	REC	IP	10
75	Saleem	38M	36265	Ca stomach	27-06-2011	PLV	IP	6



## MASTER CHART FOR CASES OF APPENDICITIS

S.No	Name	IP NO.	Date of surgery	Age/s ex	symptoms	Site of maximum tenderness	PR	usg	Elective/emergency	Incision	Position of appendix	Length	Intra/extra Peritoneal	findings
1.	Srinivasan	51291	30-08-2010	19M	F,V	RIF	NAD	Acute	EM	MC	PRIL	10cm	IP	T,I,G
2.	Ramalingam	51295	30-08-2010	34M	F,A	RIF	NAD	Acute	EM	MC	REC	8cm	IP	I,T,f
3.	Durai	51233	04-09-2010	35M	F,A	RIF	NAD	PT	EM	MC	REC	5 cm	IP	I,f
4.	Mohan	54015	13-09-2010	26M	A	NS	T R	Acute	EM	MC	PRM	7cm	IP	T,I
5.	Babu	54022	13-09-2010	35M	A	NS	NAD	subAcute	Elect	LAP	REC	8cm	IP	I,f
6.	Latha	54170	13-09-2010	32F	F,V,A	RLR	NAD	Acute	EM	MC	REC	8cm	EP	T,I
7.	Vadivel	54130	14-09-2010	32M	D	RIF	NAD	Acute	EM	Lanz	POIL	9cm	IP	T,I,P
8.	Daisy	54200	11-10-2010	26F	F,V	RIF	NAD	PT	EM	Lanz	REC	8cm	IP	T,I
9.	Shanjay	54312	13-10-2010	23M	F,A	RIF	NAD	AA	EM	Mc	REC	8cm	EP	I,P,A
10.	Puspa	54656	13-10-2010	40F	A	RIF	T	ND	EM	MC	PLV	5cm	IP	I
11.	Karthika	55001	15-10-2010	36F	A	RIF	NAD	Subacute	Elect	Lap	POIL	6cm	IP	I
12.	Kathrena	61046	29-10-2010	16F	D	R L F	NAD	PT	Elect	Lanz	PRIL	9cm	IP	I
13.	Raghunath	61567	10-11-2010	28M	F,A	NS	NAD	Subacute	Elect	Lap	POIL	7cm	IP	I
14.	Dhivya	65432	12-11-2010	20F	A	NS	NAD	Subacute	Elect	Lanz	REC	14cm	IP	I,f
15.	Pavithra	69012	24-11-2010	18F	F,A,V	RIF	NAD	ND	EM	MC	PARC	12cm	EP	I,G,P
16.	Ramachanra	76237	29-11-2010	48M	A,F	G,R,w	T	ND	EM	MLI	PRIL	8cm	IP	P,I
17.	Vetri	71693	06-12-2010	40M	F,V,U	R L F	NAD	Acute	EM	MC	REC	6cm	EP	I,f
18.	Balamurgan	74327	06-12-2010	18M	F,A	RIF	NAD	ND	EM	MC	REC	12cm	IP	I
19.	Vignesh	75594	20-12-2010	17M	F,V,A	RIF	NAD	ND	EM	MC	PRIL	8cm	IP	I
20.	Rohith	75510	27-12-2010	18M	A	RIF	NAD	Acute	EM	Lanz	PRIL	9cm	IP	I
21.	Devasiga	76523	29-12-2010	20M	A	NS	NAD	Subacute	Elect	Lap	REC	15cm	IP	I,f
22.	Karupasamy	1739	10-01-2011	21M	F,A	G,R,W	NAD	ND	EM	ML	REC	10cm	IP	I,T
23.	Ponnan	7068	11-02-2011	18M	A	RIF	NAD	Subacute	Elect	Lanz	REC	9cm	IP	I,f
24.	Abimanyan	8560	14-02-2011	20M	F,A	RIF	NAD	ND	EM	MC	SUBC	9cm	IP	I
25.	Samban	8881	14-02-2011	21M	F,A	W	NAD	ND	EM	ML	PRIL	10cm	IP	I,T,A,per
26.	Mahesh	9467	11-03-2011	22M	A	RIF	NAD	Subacute	Elect	Lanz	POIL	11cm	IP	I
27.	Balamani	11673	30-03-2011	30M	A	RIF	NAD	Subacute	Elect	Lanz	REC	10cm	IP	I,f
28.	Raju	15129	04-04-2011	48M	F,V	RIF,Ps	NAD	Acute	EM	MC	REC	8cm	IP	T,I
29.	Sundaraj	20520	11-04-2011	38M	F,V	R H F	NAD	Acute	EM	MC	SH,REC	7cm	IP	I,f
30.	Karthikeyan	22043	20-04-2011	23M	A	RIF	NAD	Subacute	Elect	Lap	SUBC	14cm	IP	I,f
31.	Subramani	31927	20-04-2011	35M	A	NS	NAD	Subacute	Elect	Lap	PLV	9cm	IP	I

32.	Jaikumar	33476	09-05-2011	16M	F,V	RIF	NAD	ND	EM	MC	POIL	10cm	EP	I
33.	Jensingh	22006	16-05-2011	19M	F,D	RIF,G,R	NAD	ND	EM	MID	REC	12cm	EP	P,I,G
34.	Kaliaperum a	26195	05-06-2011	55M	A	NS	NAD	Subacute	Elect	Lanz	PRIL	18cm	IP	I
35.	Manoj	27607	08-06-2011	21M	A	RIF	NAD	Subacute	Elect	Lap	PRIL	10cm	IP	I
36.	Sivakumar	32455	13-06-2011	23M	A	NS	NAD	Subacute	Elect	MC	REC	10cm	EP	I,f
37.	Udhaya	32025	21-06-2011	21M	F,A	RIF	T	ND	EM	MC	POIL	5cm	IP	I
38.	Hemansh	26271	29-06-2011	22M	A	RIF	NAD	SUacute	Elect	MC	POIL	10cm	IP	I
39.	Marthin	39152	05-07-2011	36M	A	RIF	NAD	subacute	Elect	Lanz	PRIL	13cm	IP	I
40.	Sakthivel	40748	08-07-2011	13M	F,A	RIF	NAD	ND	EM	MC	REC	11cm	IP	I,P,f
41.	Velusamy	38138	11-07-2011	42M	F,V	RIF,O	NAD	ND	EM	MC	PLV	7cm	IP	I
42.	Kamatchint h	39174	13-07-2011	55M	A	RIF	NAD	Acute	Elect	Lanz	REC	10cm	EP	I,f
43.	Kaviarasan	40652	18-07-2011	19M	F,D	RIF	T	Acute	EM	MC	PRIL	9cm	IP	I,T
44.	Manoj	43457	01-08-2011	20M	F,V	W,G	NAD	Acute	EM	MIL	REC	6cm	EP	I,Per,G
45.	Bhuvanew ari	43417	01-08-2011	13F	F,A	RIF,Ps	NAD	ND	EM	MC	REC	10cm	IP	I,f
46.	Kavitha	43403	01-08-2011	32F	F,A	RIF	NAD	ND	EM	MC	PRIL	8cm	IP	I
47.	Dharman	42783	02-08-2011	29M	F,A	RIF	NAD	ND	EM	MC	REC	15cm	IP	I,f
48.	Sarojini	97578	22-08-2011	20F	F,D	RIF,O	NAD	ND	EM	Lanz	PLV	18cm	IP	I
49.	Manonmani	47471	22-08-2011	20F	F,A	G,R	NAD	Acute	EM	MIL	PLV	7cm	IP	I,G,P
50.	Prakash	90872	21-11-2011	25M	F,A	RIF	NAD	ND	EM	MC	REC	8cm	IP	I,P,A