

**A Study on  
LAPAROSCOPIC vs. OPEN APPENDECTOMY –  
A Prospective Comparative Case Series**

**A DISSERTATION  
IN GENERAL SURGERY**

*Submitted in partial fulfillment*  
**of the Requirements for the Degree of  
M.S General Surgery (Branch I)**



**THE TAMILNADU DR.M.G.R. MEDICAL UNIVERSITY  
KILPAUK MEDICAL COLLEGE  
CHENNAI**

**APRIL - 2013**

## **CERTIFICATE**

This is to certify that this dissertation entitled '**Laparoscopic vs Open Appendectomy – a Prospective Comparative Case Series Study**' is the bonafide work of **Dr. D. MADHU** submitted as partial fulfilment of the requirements for the degree of M.S. General Surgery at Govt. Kilpauk Medical College – Govt. Royapettah hospital, Chennai.

**Prof. P.N.Shanmugasundaram M.S.**  
Professor and Head of the department,  
Dept. of General Surgery,  
Govt. Kilpauk Medical College  
Chennai

**Prof. K.Kuberan M.S.,**  
Dissertation guide and Unit Chief  
Dept. of General Surgery,  
Govt. Royapettah Hospital  
Chennai

**Prof .P . RAMAKRISHNAN MD DLO**  
**DEAN,**  
Govt. Kilpauk Medical College,  
Chennai - 10.

## **DECLARATION**

I **Dr. D. MADHU** solemnly declare that the dissertation submitted on the topic “**LAPAROSCOPIC vs. OPEN APPENDECTOMY – A PROSPECTIVE COMPARATIVE CASE SERIES**” is a bonafide work done by me from May 2010 to November 2012, towards partial fulfillment of the requirements of M.S Degree examinations, General Surgery, April 2013.

Chennai

**Dr. D. MADHU**

Date

## **ACKNOWLEDGEMENTS**

I am pleased to acknowledge **Prof. Dr. P. RAMAKRISHNAN M.D. DLO**, Dean, Govt. Kilpauk Medical College and Hospital for the opportunity to conduct this study in the Department of General Surgery, at Government Royapettah Hospital, Govt. Kilpauk Medical College, Chennai.

My sincere gratitude to my guide and mentor; **Prof. Dr. K. KUBERAN M.S.**, Professor of Surgical unit II, Government Royapettah Hospital, who has inspired and sculpted me as a surgeon during my training as a postgraduate student under him and guided through my dissertation.

I am most thankful to **Prof. Dr. P.N. SHANMUGASUNDARAM, M.S.**, Professor & Head of the Department of General Surgery, Govt. Kilpauk Medical College for the encouragement and permission to avail all the study materials in the Department of General Surgery for my dissertation.

I also acknowledge the invaluable advice and guidance in various aspects of my dissertation given by **Prof. Dr. R.A. PANDYARAJ M.S. and Dr. AFFEE ASMA M.S** and Former Professors of GRH – **Dr.S.UDAYAKUMAR M.S., & Dr.K.RAMASUBRAMANIAN M.S. ,** Department of General Surgery, Govt. Royapettah Hospital.

This study would have not been possible without the support of my Assistant professors, **Dr. S.MANISELVI M.S.,D.G.O.** **Dr. S.THIRUNAVUKKARASU M.S., Dr. S. SELVAKUMAR M.S.,** to whom I owe my initiation in surgical training.

I also thank my fellow post-graduates and interns who have been a source of immense help in many aspects.

I am indebted to all my patients for the co-operation and patience they showed to all the ordeal. I am most thankful to them to have helped me make this a meaningful work.

## TABLE OF CONTENTS

<b>S. No.</b>	<b>Title</b>	<b>Page No.</b>
1.	INTRODUCTION	1
2.	OBJECTIVES	5
3.	REVIEW OF LITERATURE	6
4.	MATERIALS & METHODS	71
5.	PROFORMA	78
6.	DATA ANALYSIS AND RESULTS	81
7.	STATISTICAL ANALYSIS	95
8.	DISCUSSION	96
9.	CONCLUSION	101
10.	FIGURE INDEX	i
11.	CHART INDEX	ii
12.	TABLE INDEX	iii
13	BIBLIOGRAPHY	iv
14.	MASTER CHART	

## FIGURE INDEX

<b>Fig No.</b>	<b>Name</b>	<b>Page No.</b>
1	REGINALD FITZ	2
2	KURT SEMM	4
3	Cut section of Normal Appendix-Histology	10
4	Normal anatomy and relations of the appendix	11
5	Variations in the position of the appendix	12
6	Blood supply of the Appendix	13
7	Charles McBurney	15
8	The McBurney's Point	15
9	USG showing appendicular lumen in appendicitis	27
10	CT scan showing inflamed appendic with periappendiceal fat stranding and fluid collection.	30
11	Position of Appendix in Pregnancy	34
12	Open appendectomy - Stump inversion	51
13	Open Appendectomy showing the delivered appendix with the caecum	74
14	Steps in Laparoscopic Appendectomy	75-76

## CHART INDEX

Chart No.	Name	Page No
1a	Age distribution in L.A	81
1b	Age distribution in O.A	81
1c	Age distribution comparison between L.A & O.A	81
2	Sex distribution between L.A and O.A	82
3a	Pathology Report in L.A	83
3b	Pathology Report in O.A	83
3c	Pathology Report of L.A & O.A	83
4	Operating time in mins between L.A & O.A	85
5a	Parenteral analgesic between L.A & O.A	86
5b	Oral Analgesic between L.A & O.A	86
6	Return of Bowel function in hours	87
7a	Wound infection between L.A & O.A	88
7b	Intra-abdominal abscess between L.A & O.A	88
8	Resumption of Liquids and Solids in L.A	89
9	Resumption of Liquids and Solids in O.A	90
10a	Length of stay in hospital in days in L.A	91
10b	Length of stay in hospital in days in O.A	91
10c	Length of stay in hospital in days between L.A & O.A	92
11a	Return to work in days in L.A	93
11b	Return to work in days in O.A	93
11c	Return to work in days between L.A & O.A	93



## TABLE INDEX

<b>Table No.</b>	<b>Name</b>	<b>Page No.</b>
1	Alvarado Score	47
2	Comparison of Sex Distribution btw. L.A and O.A	82
3	Comparison of Pathology Report bte L.A and O.A	84
4	Comparison of Operating time btw. L.A and O.A	85
5	Comparison of Parenteral and Oral Analgesic dose btw L.A and O.A	86
6	Comparison of Bowel function return btw L.A. & O.A	87
7	Comparison of Liquid & Solid Diet in L.A	89
8	Comparison of Liquid & Solid Diet in O.A	90
9	Comparison of Length of Stay btw L.A & O.A	92
10	Comparison of Return to Work btw L.A & O.A	94
11	Statistical Analysis	95

## BIBLIOGRAPHY

1. Laparoscopic vs open appendectomy A prospective comparative study of 227 patients M. Marzouk, M. Khater, M. Elsadek, A. Abdelmoghny Department of Surgery, Saudi German Hospitals Group—Jeddah, Post Office Box 2550, Jeddah 21461, Saudi Arabia Received: 1 April 2002/Accepted: 17 October 2002/Online publication: 6 March 2003
2. *Outcomes of Laparoscopic versus Open Appendectomy* ALFREDO M. CARBONELL, D.O., JUSTIN M. BURNS, M.D., AMY E. LINCOURT, PH.D., KRISTI L. HAROLD, M.D. From the Carolinas Laparoscopic and Advanced Surgery Program, Department of General Surgery, Carolinas Medical Center, Charlotte, North Carolina; and the Department of General Surgery, MayoClinic-Scottsdale, Scottsdale, Arizona Scientific Meeting in Atlanta, GA, January 31-February 3, 2004
3. Laparoscopic Versus Open Appendectomy A Prospective Randomized Double-Blind Study Namir Katkhouda, MD, Rodney J. Mason, MD, Shirin Towfigh, MD, Anna Gevorgyan, MD, and Rahila Essani, MD Posted: 09/15/2005; *Annals of Surgery*. 2005;242(3):439-450. © 2005 Lippincott Williams & Wilkins
4. ECAB Clinical Update Surgical Gastroenterology and Liver Transplantation – The Appendix Samiran Nundy, Sanjay Nagral
5. *Human Embryology* 7<sup>th</sup> edition Inderbir Singh; G.P.Pal

6. Schwartz's Principles Of Surgery 9<sup>th</sup> edition F.Charles Brunnicardi
7. Sabiston Textbook of Surgery 18<sup>th</sup> edition Volume 2
8. Bailey & Love's Short Practice Of Surgery 25<sup>th</sup> edition
9. Grading and Staging in Gastroenterology Guido N.J.Tytgat;  
Stefaan H.A.J. Tytgat
10. Evaluation of Laparoscopic Appendectomy vs. Open Appendectomy: A Retrospective Study Aga Khan University Hospital, Karachi, Pakistan Yasmin Vellani, Shaheena Bhatti, Ghina Shamsi, Yasmin Parpio, Tazeen Saeed Ali Department of Nursing Services, Department of Surgery, School of Nursing, Department of Community Health Sciences, The Aga Khan University Hospital, Karachi, Pakistan.
11. Laparoscopic versus Open Appendectomy: Is There a Difference? Long KH, Bannon MP, Zietlow SP, et al. A prospective randomized comparison of laparoscopic appendectomy with open appendectomy: clinical and economic analyses. Surgery 2001;129:390–400.
12. Laparoscopic versus conventional appendectomy - a meta-analysis of randomized controlled trials Xiaohang Li1 , Jialin Zhang, Lixuan Sang , Wenliang Zhang, Zhiqiang Chu, Xin Li and

Yongfeng Liu BMC Gastroenterology 2010, 10:129 doi:10.1186/1471-230X-10-129

13. Laparoscopic versus open appendectomy: prospective randomised trial J.J.T. Tate FRCS, J.W. Dawson FRCS, S.C.S. Chung FRCS, W.Y. Lau FRCS, A.K.C. Li FRCS The Lancet, Volume 342, Issue 8872, Pages 633 - 637, 11 September 1993 doi:10.1016/0140-6736(93)91757-D
14. Laparoscopic Versus Open Appendectomy: Outcomes Comparison Based on a Large Administrative Database Ulrich Guller, MD, MHS; Sheleika Hervey, BA; Harriett Purves, MPH, BS; Lawrence H. Muhlbaier, PhD; Eric D. Peterson, MD, MPH; Steve Eubanks, MD; Ricardo Pietrobon, MD Posted: 01/21/2004; Annals of Surgery. 2004;239(1) © 2004 Lippincott Williams & Wilkins
15. Laparoscopic versus open appendectomy in females with a clinical diagnosis of appendicitis Abdulrahman S. Al-Mulhim, FRCSI, FICS, Faisal M. Al-Mulhim, FRCSI, Abdulmohsen A. Al-Suwaiygh, MBBS, Nabil A. Al-Masaud, MBBS Saudi Med J 2002; Vol. 23 (11): 1339-1342

# INTRODUCTION

## HISTORY :

The appendix is considered historically as a vestige with no discernible function. However its inflammation produces one of the most common causes of acute abdomen presenting to the emergency department, the appendicitis leading to appendectomy the most commonly performed general surgical procedure till date.

The appendix described first by 1521 by the physician-anatomist Berengario DeCarpi. However as were many things that came to knowledge from the great Leonardo da Vinci so was the appendix which was illustrated by him in his drawings in 1492 published later in the 18<sup>th</sup> century. In 1824, Louyer-Villermay identified appendiceal inflammation in 2 autopsied cases. In 1827, Francois Melier was the first to report an antemortem case of appendicitis. Dupuytren discounted by arguing only inflammation of the caecum, 'typhilitis' was the primary cause of right lower quadrant pain. **Reginald H. Fitz**, a Surgical pathologist and pathologic anatomist at Harvard has the credit for coining the term 'appendicitis'. In humans the appendix has been long considered to be a vestigial organ in contrast to some animals like the rabbits where the

appendix secretes enzymes to degrade cellulose into carbohydrates and functions as an important adjunct to digestion and absorption.



**Fig. 1 Reginald H.Fitz**

### **VESTIGIALITY AND EVOLUTION :**

It has long been known that the human appendix and the terminus of the caecum of mammals are structurally homologous in the vertebrate comparative anatomy. A blind pouch, another name for the appendix is in fact the "true caecal apex". In primates particularly, the termination of the caecum and the vermiform appendix share the same relative position, both have a similar structure and form, both are blind ending structures containing an abundance of lymphatic tissue, both have a common developmental origin.

From the analysis of anatomy systematically and comparatively, it is known that in primates a large caecum with a small or absent appendix is the ancestral, primitive state. In general, the length of the caecum, relative to that of the colon, decreases as one travels down the phylogenetic tree of evolution from the monkeys to humans. Concurrently, the size of the appendix increases.. The human appendix has lost a major and previously essential function, which is cellulose digestion. Though it has decreased in size to a become a rudimentary organ, the appendix retains a structural originality specifically adapted for containing the cellulose digesting bacteriae and extending the time course of digestion. The appendix in humans though vestigial, functions in the development of the immune system in children as a source of antigen presenting lymphocytes in the gastrointestinal tract inducing memory cells for further defence against similar pathogens in the future. In humans the cellulose being a component of the diet is not actually digested but is useful as a bulk forming agent that ensures colonic transit and functional integrity with mucosal protection from the deleterious effects of refined foods and other pathogens. Thus the human appendix is a rudiment of the caecum that is useless as a normal mammalian, cellulose-digesting caecum. Thus to say, the topography of the appendix on a non-evolutionary basis being at the end of the caecum has lost its role and functional significance but remains to be a vestige.

## **SURGICAL HISTORY :**

The first recorded appendectomy was performed by Claudius Amyand (1681 – 1740), surgeon at St. George Hospital, London and Sergeant Surgeon to Queen Ann, King George I and II. A 11 yr old lad with scrotal hernia with a fecal fistula and containing a perforated appendix was operated by him in 1736. The initial surgical therapy for appendicitis was right lower quadrant drainage alone. The first surgical therapy for appendicitis without abscess was done by Hancock in 1848, which was peritoneal incision and drainage without appendectomy. The first elective appendectomy performed by Fergus in Canada in 1883. The first published account of emergency appendectomy for appendicitis was by Kronlein in 1886. The first laparoscopic appendectomy was performed in 1982, by Kurt Semm, a Professor of Gynaecology at the University of Kiel, Germany.



**Fig. 2 Kurt Semm**



## **OBJECTIVES OF THE STUDY**

- ❖ To compare the operative difficulties in terms of operating time between laparoscopic and open appendectomies.
  
- ❖ To prove the effectiveness of either of the procedures in reducing the postoperative morbidity in terms of
  - Postoperative pain and analgesic use
  
  - Return of bowel function
  
  - The resumption of liquid and subsequent solid diet
  
  - Rate of infection, both surgical site and intra-abdominal infections
  
  - Number of days of hospital stay
  
  - The number of days to return to near normal work.

## REVIEW OF LITERATURE

### EMBRYOLOGY :<sup>4,5</sup>

The caecal bud arises as a diverticulum from the post-arterial segment of the midgut loop from which the caecum and the appendix are formed. The proximal part of this bud grows rapidly to form the caecum while the distal part remains narrow giving rise to the appendix.

The rapid, asymmetric growth of the lateral wall more than the medial wall of the caecum results in medial displacement of the point of attachment of the appendix leading to the medial position of the same. In some cases the right colon and the caecum rotate about their long axis leading to the common position of the appendix retrocaecally.

The development occurs at around 8<sup>th</sup> week of gestation; at 4<sup>th</sup> / 5<sup>th</sup> month villi are found which disappear before birth. At about 7<sup>th</sup> month the lymphoid nodules develop in the lamina propria and remain active until puberty when they gradually decrease thereafter. At birth the appendix is short and broad, and by the differential caecal growth it becomes the typical tubular narrow structure by the end of two years of age.

## **Congenital anomalies and Duplication :<sup>4</sup>**

Eventhough it is a vestigial organ the frequency of anomalies is very low.

Duplications of appendix can be of three types :

1. Type A : Partial duplication of the tip with a single base to the caecum
2. Type B : Two completely separate appendices from a single caecum which can be one of the 2 subtypes :

Type B1 : one on either side of the ileo-caecal valve

Type B2 : one in normal location and other on one of the taenia coli – the ‘taenia-coli type’

3. Type C : Double caecum each with an appendix.

It is important to understand these duplications to look for a duplicate when u find a normal appendix during appendectomy and it may form a mass and even mimic colonic carcinoma.

**Left-sided appendicitis** rarely can occur with

1. Situs inversus viscerum
2. Midgut malrotation
3. Caecum with long mesentery
4. Long appendix

Interestingly in situs inversus and midgut malrotation the pain of the left sided appendicitis is felt in the right side in 30% of the cases

The advent of laparoscopy has obviated the need in these circumstances where one cannot find the appendix that is left sided by a classical McBurney's incision to convert into a laparotomy.

Rarer forms of congenital anomalies like total absence of appendix and ectopic appendix are also reported.

## **HISTOLOGY :** <sup>6</sup>

The appendix similar to the colon has four layers namely

1. Serosa
2. Muscularis externa / propria

### 3. Submucosa

### 4. Mucosa

#### a. Muscularis mucosa

#### b. Lamina propria

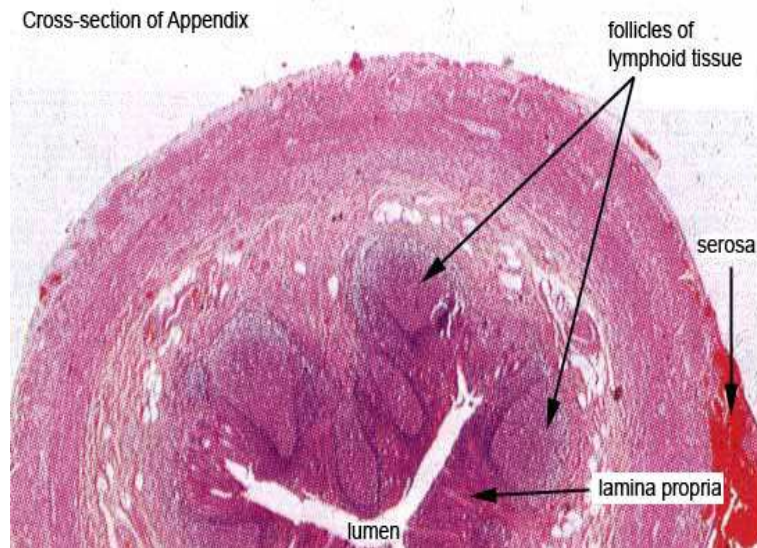
#### c. Epithelial layer

The muscularis propria consists of two layers of smooth muscles namely the outer longitudinal and inner circular layers

The submucosa and the lamina propria of the mucosa contain numerous lymph nodules as follicles and aggregations containing both B and T lymphocytes akin to the Peyer's patches as a part of the Gut Associated Lymphoid tissues (GALT) which are responsible for the mucosal immune function of the Gastrointestinal Tract.

The epithelium is columnar cells of the intestinal mucosa of colonic type.

The crypts contain argentaffin cells (Kulchitsky cells) at the base.



**Fig. 3 Cut section of normal appendix - histology**

**ANATOMY :** <sup>6,7,8</sup>

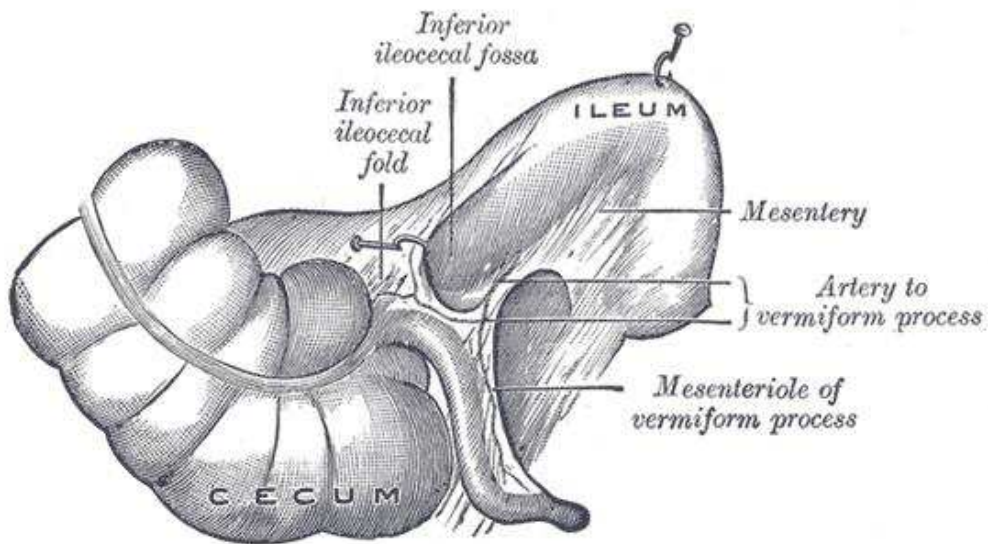
The vermiform (Ln : worm-like) appendix is a narrow tubular structure of varying size and shape arising from the caecum located in a posteromedial position around 2 cm inferior to the opening of the ileum.

The length of the appendix is highly variable and can be from 2 to 20 cm and average being 9 to 11 cm long.

The lumen is irregular being encroached upon by longitudinal folds of mucous membrane. A few crypts are present.

The valve of Gerlach guards the opening of the appendix via folds of mucosal membrane.

The base of the appendix can vary in location relative to the variable position of the caecum to posture, respiration and intestinal distension.

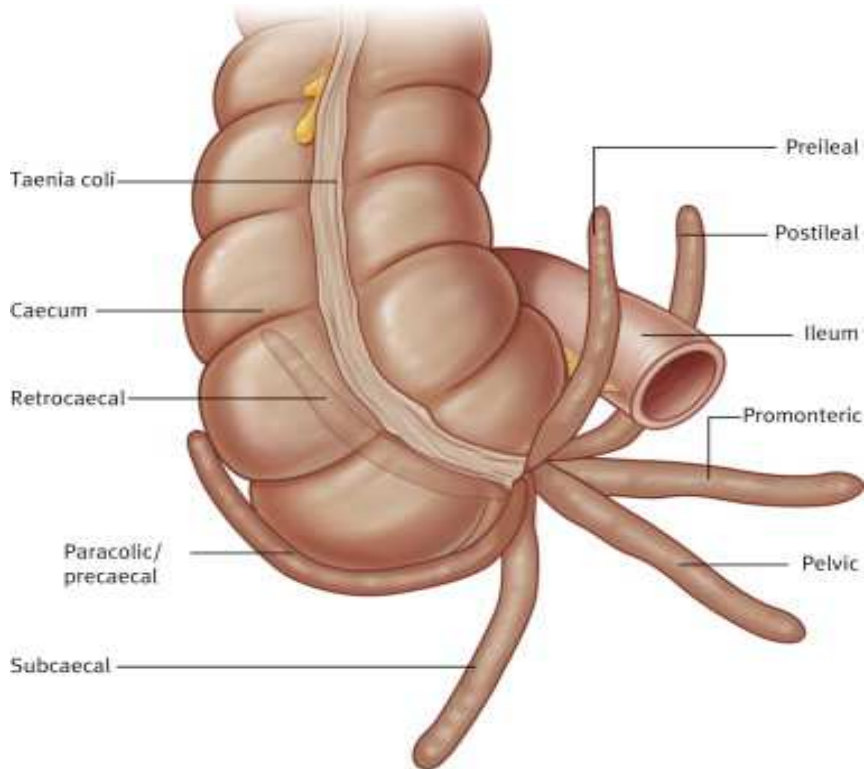


**Fig. 4 Normal anatomy and relations of the appendix**

The position of the tip of the appendix is highly variable and can be one of the following:

1. Retrocaecal – 75% being the commonest
2. Paracolic – 2%
3. Pre-ileal – 1%
4. Post-ileal – 0.5%
5. Subcaecal -1.5%
6. Pelvic – 21%

The appendix is usually intraperitoneal while in some rare circumstances its tip may be extraperitoneal also.



**Fig. 5 Variations in the position of the appendix**

**The mesentery of the appendix / Mesoappendix :**

It is a triangular fold derived from the mesentery of the terminal ileum, which is attached to the caecum and appendix. It contains the appendicular vessels, nerves and lymphatics.

The appendicular artery typically enters the mesoappendix a short distance from the base passing from behind the terminal ileum.

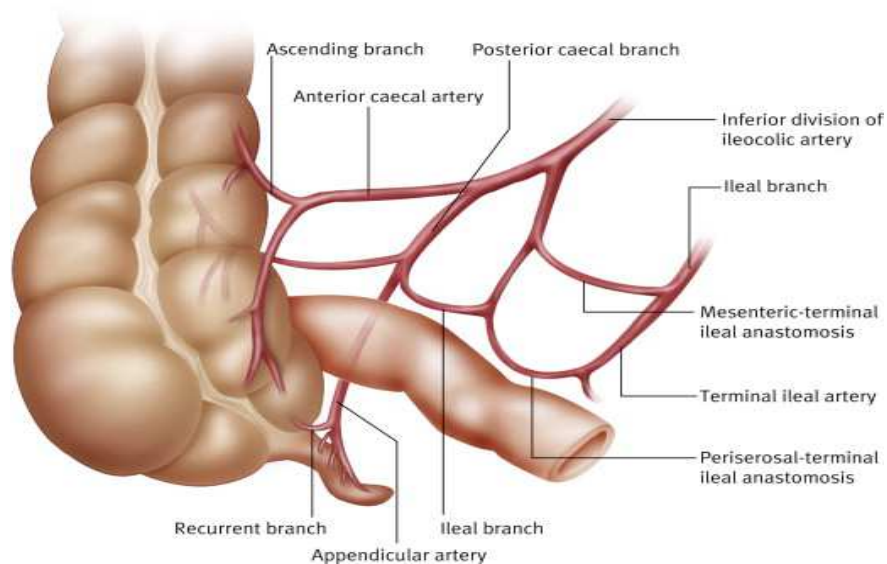


## Arterial Supply :

The appendicular artery is a branch of the ileocolic artery which is derived from the superior mesenteric artery. It is an end artery with no other anastomosing vessel and gangrene and perforation are early in acute appendicitis. Occasionally 2 appendicular arteries are present.

An accessory atypical appendicular artery derived from the caecal artery supplies the appendix.

The appendicular veins accompany the artery and drain into the superior mesenteric vein.



**Fig. 6 Blood supply of the Appendix**

**Lymphatic drainage :**

They drain directly into the ileo-colic nodes or into the appendicular nodes in the mesoappendix.

**Innervation :**


The sensory innervation of the appendix is carried by 8<sup>th</sup>, 10<sup>th</sup>, and 11<sup>th</sup> thoracic nerves.

The parasympathetic originates from the vagus.

The sympathetic originates from the celiac and superior mesenteric ganglia.

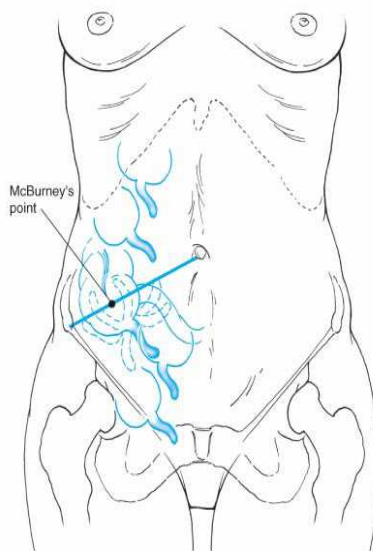
**SURFACE MARKING :**

The point of maximum tenderness in acute appendicitis is 1.5 to 2 inches from the right anterior superior iliac spine along a straight line from it to the umbilicus, the McBurney's point ( Charles McBurney US, 1889)



**Fig. 7 Charles McBurney**

*‘ maximum tenderness, when one examines with finger tips is, in adults, one half to two inches inside the right anterior spinous process of the ilium on a line drawn to the umbilicus’*



**Fig. 8 The McBurney's point**

Otto Lanz description of the surface marking of appendicular base is:

*‘The base of appendix being located at the point one-third distance from the right anterior superior iliac spine along a line joining the two anterior superior iliac spines’* (Otto Lanz Amsterdam, 1908)

## **ACUTE APPENDICITIS**

The inflammation of the appendix is called appendicitis or formerly called ‘epityphilitis’

### **INCIDENCE :** <sup>6</sup>

The lifetime incidence of appendicitis is around 12% for men and 25% for women with average rate of appendectomy for appendicitis around 7-8% in a lifetime. It is usually seen in second through fourth decade of life and peaking in 20-30 yrs of age. There is a slight male : female preponderance. (1.2 – 1.3:1) Appendectomy for appendicitis is the most commonly performed emergency operation in the world. The incidence is however lower in the regions of the world where there is a high dietary fibre intake as in Africa and Asia. The misdiagnosis of appendicitis has remained constant at a rate of 15.3% throughout the world in spite of the increase in the multitude and sophistication of the investigations. The percentage of misdiagnosed cases of appendicitis is

more in case of women with a bimodal distribution, one at 40 – 49 yrs of age and the other at >80 yrs of age leading to a similar percentage of negative appendectomies.

The rate of appendiceal rupture has also remained relatively constant.

**AETIOLOGY :** <sup>6,7,8</sup>

Fecaliths are the most common causes of appendiceal obstruction.

Other less common causes are :

1. Lymphoid hypertrophy
2. Inspissated barium from previous radiologic studies
3. Tumors
4. Vegetables
5. Fruit seeds
6. Intestinal parasites

## **PATHOPHYSIOLOGY :<sup>6</sup>**

There is a predictable sequence of events leading to the characteristic pathophysiology of appendicitis and its course.

There is a proximal obstruction of the appendiceal lumen leading to a closed loop obstruction, while the distal mucosa continues to secrete mucous leading to intraluminal distension.

The luminal capacity of the normal appendix is just around 0.1 ml and distension of the lumen by 0.5ml or more of secretions raises the intraluminal pressure to 60 cm of H<sub>2</sub>O.

The distension increases from continued mucosal secretions and from rapid multiplication of the resident bacteria. The venous pressure is exceeded and the capillaries and venules become occluded. The arterial inflow continues and results in engorgement and vascular congestion. The inflammatory process soon involves the serosa and the parietal peritoneum eventually gets inflamed.

As the vascular compromise occurs the areas with poorest blood supply i.e. concentric ellipsoidal infarcts of the anti-mesenteric border initially appear.

The three ominous components of distension, vascular compromise and bacterial invasion coexist and act in a vicious cycle, infarction progresses and perforation is the end point.

The area of perforation is just beyond the point of obstruction rather than the tip according to the physics of luminal / diametric proportions.

However perforation is not the only eventuality of appendiceal obstruction. This process can rather be dis coherent and discordant and the sequence could be disrupted at any point and the inflammation may burnout leading to chronic and recurrent appendicitis.

### **BACTERIOLOGY :** <sup>6</sup>

The bacteriology of the normal appendix is same as that of the normal colon. The appendiceal flora remains constant throughout life except *Porphyromonas gingivalis* which is seen only in adults. The bacteria cultured in cases of appendicitis are therefore similar to those seen in other colonic infections such as diverticulitis. The principal organisms seen in the normal appendix, in acute appendicitis, and in perforated appendicitis are *Escherichia coli* and *Bacteroides fragilis*. A wide variety of both facultative and anaerobic bacteria and mycobacteria

may be present. Appendicitis is a polymicrobial infection, with different organisms found in cases of perforation. Hence all the patients must be started on broad spectrum antibiotics that cover the normal colonic flora. Peritoneal culture should be reserved for patients who are immunocompromised as a result of either illness or medication, and for patients who develop an abscess after the treatment of appendicitis.

Antibiotic coverage is limited to 24 to 48 hours in cases of non-perforated appendicitis. For perforated appendicitis, 7 to 10 days is recommended. Intravenous antibiotics are usually given until the white blood cell count is normal and the patient is afebrile for 24 hours. The use of antibiotic irrigation of the peritoneal cavity and transperitoneal drainage through the wound are controversial.

### **CLINICAL FEATURES :** <sup>6,7,8</sup>

The classic patient presents with periumbilical pain 1 to 2 days prior and which has migrated to the right lower quadrant consequent to the involvement of parietal peritoneum leading to somatic visceral efferent irritation from the initial visceral afferent fibre stimulation caused by luminal distention alone.



There is a low grade fever owing to the inflammatory ongoing pathology, few episodes of vomiting which is self-limiting and the patient feels nauseated and early onset anorexia. Diarrhoea may occur but is unusual and some patients may have constipation also and hence the bowel function is of little significance in the diagnosis.

The vomiting is neither prolonged or prominent and is due to the presence of ileus. The anorexia is constant with appendicitis and a patient who feels hungry should be suspected of a different diagnosis.

The sequence is peri-umbilical pain followed by nausea vomiting and then fever.

The acute phase lasts for 2 to 3 days by which either the inflammation is burning down or has progressed to form an abscess/phlegmon or perforated complicating the clinical course.

On examination:

Vital signs are minimally changed. Temperature is elevated by rarely more than 1°C (1.8°F) and the pulse rate is normal or slightly elevated. Changes of greater magnitude usually indicate that a complication has occurred or that another diagnosis should be considered. Patients with appendicitis usually prefer to lie supine, with the thighs,

particularly the right thigh, drawn up, because any motion increases pain.

If asked to move, they do so slowly and with caution.

Focal tenderness over the right lower quadrant due to the parietal peritoneal irritation, usually at the McBurney's point but may be variable depending on the location of the appendix.

If an abscess has formed, a vague mass can be palpable.

If the appendix has perforated, then guarding and rigidity localized to the right lower quadrant can be made out.

There is tachycardia, fever, and signs of peritonism according to the stage of presentation.

**Few classical signs of appendicitis are :**

Unsolicited pain on

1. Palpation of the left lower quadrant - **ROVSING sign**
2. On cough - **DUNPHY sign**
3. Internal rotation of the flexed right thigh- **OBTURATOR sign**
4. Extension of the right hip - **ILIOPSOAS sign**
5. Rebound tenderness - **BLUMBERG's sign**

Cutaneous hyperesthesia in the area supplied by the spinal nerves on the right at T10, T11, and T12 frequently accompanies acute appendicitis.

### **LABAROTORY INVESTIGATIONS :**

Mild leukocytosis 10000-18000 cells/cu.mm with left shift to polymorphonuclear predominance in uncomplicated appendicitis is the only remarkable laboratory abnormality.

The elevation of leukocytes to more than 18000 cells/cu.mm is suggestive of onset of a complication either an abscess or perforation

C- reactive protein may be raised in cases of perforated appendix

Urinalysis may demonstrate pyuria when possibility of a pelvic appendicitis or a different diagnosis of urinary tract pathology.

### **RADIOLOGICAL INVESTIGATIONS :** <sup>4,6</sup>

The routine use of imaging modalities to confirm a suspected appendicitis in a patient with obvious clinical symptoms and signs is discouraged.

In certain high risk patients and in the extremes of age when the likelihood of appendicitis is in question due to a paucity in the symptoms

and signs necessitate the use of radiological imaging to help in establishing a diagnosis. In the event of operation without the aid of imaging modalities in the diagnosis the incidence of 20% negative appendectomies is accepted. The incidence of negative appendectomies is higher without imaging, especially in the females of reproductive age group which is up to 42%. In this specific group of patients, imaging can help reduce the incidence of a negative appendectomy. But the use of imaging delays the surgical procedure thereby increasing the risk of appendiceal perforation.

The two imaging modalities mainly used are the ultrasound and computerised tomography of the abdomen and pelvis

### **ULTRASOUND EXAMINATION:**

Graded compression sonography has a highly variable sensitivity and specificity due to the operator dependent outcome. It becomes most useful in female patients when the gynaecological causes of their symptoms mask the causes of appendicitis.

It is also the imaging of choice in pregnant patients in whom radiation exposure is to be avoided.

It can be both trans-abdominal (usually) or trans-vaginal.

The appendix whether normal or abnormal is often not found by the study which is why it is most often unhelpful and inconclusive

The variability in the position of the tip of the appendix makes it difficult to localize.

The bowel mass interpositioning and the body mass index of the patient makes the image quality and resolution poorer.

#### **FINDINGS on USG in Appendicitis :**

1. thickening of the appendiceal wall
2. loss of wall compressibility
3. increased echogenicity of the surrounding fat signifying inflammation and loculated pericaecal fluid

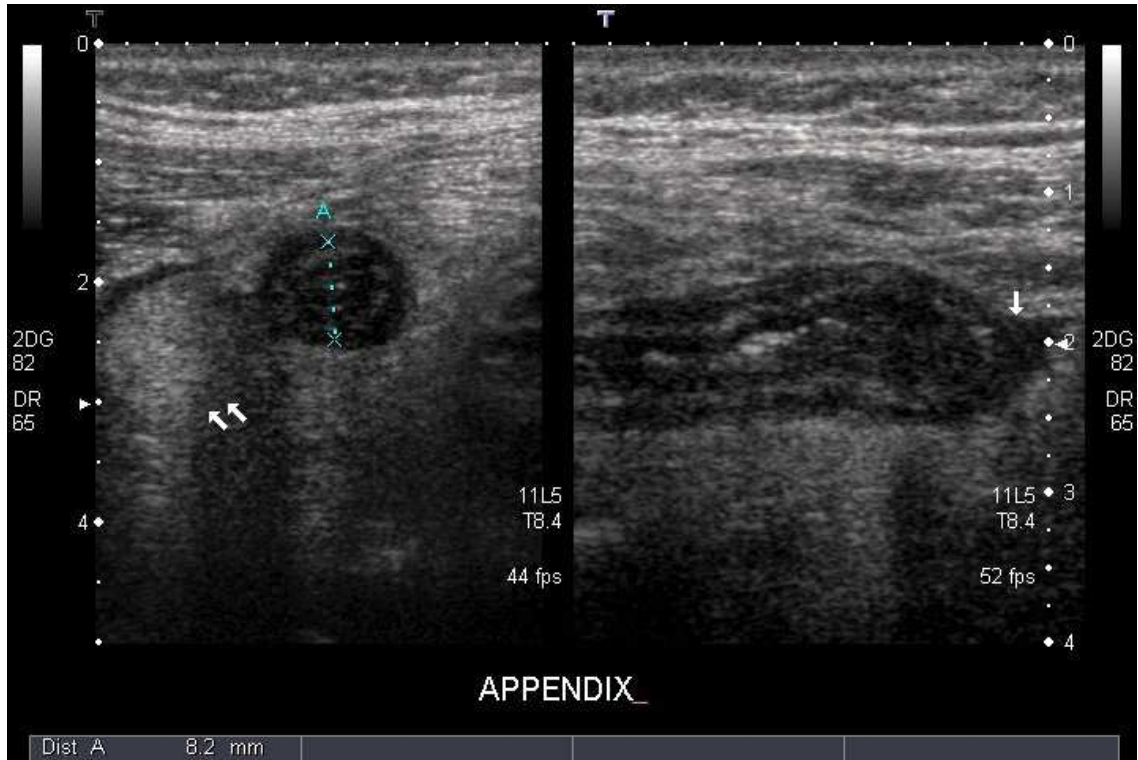
The appendix is identified sonographically as a blind-ending, nonperistaltic bowel loop originating from the cecum. With maximal compression, the diameter of the appendix is measured in the anteroposterior dimension. A scan is considered positive if a noncompressible appendix 6 mm or greater in the antero-posterior direction is demonstrated.

Oedema and free fluid are usually present. The compressibility of the appendix reduces with increasing inflammation and there may be air within the lumen.

The complications of appendicitis like mass formation or abscess can be visualized well with the ultrasound. In certain cases, free fluid alone in the right iliac fossa, right paracolic gutters or the pouch of Douglas suggest a positive diagnosis with clinical correlation. The presence of particulate matter especially pus or blood in the fluid may help preclude surgery and resort to conservative modality of treatment with ultrasound guided drainage of the pus in cases of appendiceal abscess or postoperative collections.

The probe tenderness elicited during the ultrasound examination in the right iliac fossa especially in a female may suggest either appendiceal inflammation or gynaecological pathology.

The adnexal structures such as Fallopian tubes and ovaries can be the cause of right iliac fossa pain. Often physiological changes in the ovaries like corpus luteum may explain the pain. In the instances of gynaecological pathologies a transvaginal probe may be more useful in arriving at a diagnosis.



**Fig. 9 USG showing appendicular lumen in appendicitis**

### **COMPUTERISED TOMOGRAPHY :**

The quality and reliability of CT scan has made it a reliable diagnostic tool when the ultrasound findings are inconclusive with sensitivity and specificity approaching 100%.

It allows better visualization of other intrabdominal organs particularly with oral / iv contrast. It is especially useful in the elderly when the likelihood of other conditions like diverticulitis, inflammatory bowel disease are more. It can also pick up small bowel pathology which may alter the course of management of the appendicitis.

### **Findings on a CT scan in Appendicitis :**

- An inflamed appendix is thickened with surrounding free fluid and inflammatory periappendiceal fat stranding seen as streaking and poorly defined increased attenuation.
- PHLEGMON
- Appendicolith (not pathognomonic)
- Arrow-head sign - This is caused by thickening of the cecum, which funnels contrast toward the orifice of the inflamed appendix.
- If free or localized gas is seen it may indicate the perforation of the appendix
- Small bowel ileus may be present with appendiceal perforation.
- Appendiceal abscesses are seen as a large inflammatory phlegmon.
- Features such as portal gas and soft tissue gas usually suggest a sick patient with sepsis progressing from prolonged and complicated appendicitis.

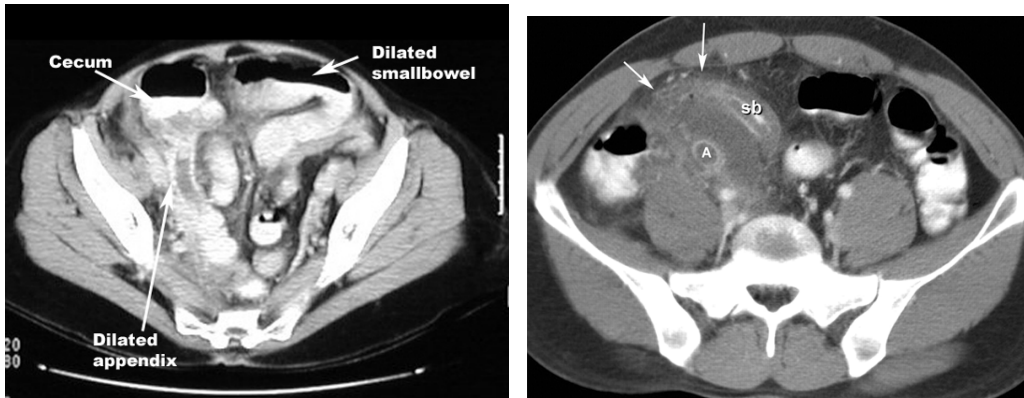


- CT is useful tool to guide percutaneous drainage of an abscess or collections and useful in assessing the postoperative complications like pelvic collections, stump leak, bleeding etc.,

### **LIMITATIONS :**

- Lack of availability
- Not cost effective
- Higher dose of ionizing radiation harmful to the patient especially the younger and pregnant.

The use of a CT scan must thus be limited to high risk patients for surgery and anaesthesia where the clinical suspicion of appendix is low and other pathologies need be ruled out. It is though useful in reducing the negative appendectomy rate and reducing needless admissions and diagnostic errors it is best used judiciously so that it doesn't prolong or delay surgery for a clinically obvious appendicitis.



**Fig. 10 CT scan showing inflamed appendix with periappendiceal fat stranding and fluid collection.**

#### **OTHER DIAGNOSTIC MODALITIES :**

#### **X-RAY ABDOMEN PLAIN :**

Dilated bowel loops suggest bowel obstruction or ileus from appendicitis.

#### **BARIUM Studies :**

Not useful unless a mechanical distal bowel obstruction is suspected. If the appendix is filled with barium appendicitis is ruled out, if not filled no determination can be made.

#### **MRI:**

Very sensitive and specific. The cost-benefit ratio precludes the routine use of MRI

## **RADIOISOTOPIC SCANS :**

Tc99 labelled leucocyte radioisotope scans may localize inflammation to the appendix but the sensitivity is less (82%) for acute appendicitis compared to CT scan and is maybe of diagnostic value in chronic appendicitis.

## **DIAGNOSTIC LAPAROSCOPY :**

The advent of laparoscopy for diagnosis in routine use makes the imaging modalities less useful for appendicitis.

To clearly emphasize, the diagnosis of appendicitis is always based primarily on clinical findings and physical examination and imaging should be used in specially warranted clinical situations.

## **COMPLICATIONS OF ACUTE APPENDICITIS : <sup>4</sup>**

The primary adverse outcome of appendicitis is perforation and its sequelae. The early exploration minimizes the chance of perforation but increases the incidence of negative appendectomies.

The rate of negative appendectomies is 10-15%

The rate of perforation ranges from 12% to 35% with more occurring in older patients.

The complications are related to the frequency of infection of the peritoneal cavity either by direct perforation or by bacterial translocation through the appendicular wall.

The pathology can either be obstructive or non-obstructive (catarrhal) inflammation. The inflammatory process beginning in the mucosa rapidly extends outwards once it reaches the loose submucosal tissues.

The vascular compromise occurs distally as the vessels are intramural toward the tip and jeopardized by the pressure and occluded.

The non-obstructive type progresses slowly and the protective adhesions form causing the peritonitis to be localized.

As gangrenous changes proceeds there are small infarcts occur permitting the escape of bacteria into the peritoneal cavity and accumulation of pus occurs.

When this occurs early as in obstruction induced gangrene the peritonitis is diffuse but when it occurs prolonged over a time the peritonitis is more localised and contained.

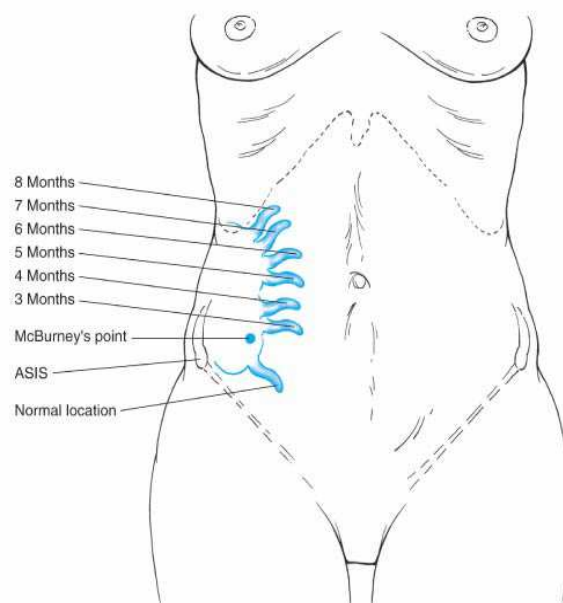
1. Gangrenous appendicitis
2. Appendicular mass
3. Perforated appendicitis with Localized abscess formation
4. Perforated appendicitis with Diffuse Peritonitis.
5. Cecal Gangrene
6. Pylephlebitis / Portal Pyemia
7. Intestinal obstruction due to contact with the inflamed appendix.

#### **APPENDICITIS IN SPECIAL CIRCUMSTANCES :<sup>4</sup>**

##### **APPENDICITIS IN PREGNANCY :**

Acute appendicitis is the most common non-obstetric indication for surgical intervention in pregnant women. The appendicitis occurring in pregnancy is difficult to diagnose due to atypical presentations and vague lower abdominal pain. The appendix and the caecum is displaced by the gravid uterus and come to lie in the right upper quadrant. The symptoms of nausea, vomiting and abdominal pain are attributable to the state of pregnancy and surgery for appendicitis carries risk of spontaneous abortion and miscarriage during pregnancy. The anaesthetic complications particularly to the fetus are least in the second trimester

which is the safe time to embark on an appendectomy. Diagnostic dilemma of misdiagnosing appendicitis and missing the diagnosis of appendicitis and leaving it to progress to complications is a great concern. Ultrasound helps delineate the appendix, its location and its involvement. CT scan should be avoided. Of the complications related to appendicitis in pregnancy, the most dreaded is the progressing sepsis which is most detrimental to the fetus and the pregnancy itself which outweighs the anaesthetic and operative risks involved.



**Fig. 11 Position of Appendix in Pregnancy**

### **APPENDICITIS IN CHILDREN :**

Acute appendicitis is the most common and most misdiagnosed surgical emergency in the children. It is most common in the second

decade of life. The diagnosis is difficult in the young patient. The etiology of appendicitis in children can be varied and the luminal obstruction by the well-formed lymphoid follicular hypertrophy induced by a viral infection and worm infestations are two different causes of appendicitis in these group of patients especially. The pathophysiology of the disease however is the same. However the incidence of complications of appendicitis is early and severe in children compared to the adults which stresses the need for prompt diagnosis and initiation of treatment.

The pain of appendicitis in children is not typically migrating and can be varied with increased micturition and loose stools, spasm of the psoas. The vomiting follows the onset of pain and can be differentiated from the more common disease of gastroenteritis in children where the vomiting is the presenting complaint. The elicitation of clinical signs in children is most difficult and rovsing's sign and psoas spasm are easily elicitable compared to rebound tenderness which would deter further examination. The investigations are the same as for adults and the ultrasound is diagnostic in most instances. CT should not be used unnecessarily due to the attendant risks. The management of appendicitis whether complicated or uncomplicated is essentially same as for adults with the use of antibiotics according to the level of complications and surgery immediately or interval. In case of abscesses and contained

inflammatory masses, percutaneous drainage by image guidance and antibiotic cover is indicated. Appendicitis in neonates is extremely rare and very difficult to diagnose as the presenting feature is irritability alone. Imaging is essential for the diagnosis. The cause of appendicitis in the neonates has to be identified and can be Hirschsprung disease, meconium-plug syndrome or cystic fibrosis.

### **DIFFERENTIAL DIAGNOSIS :** <sup>4,6</sup>

The differential diagnosis of acute appendicitis is the same as for the acute abdomen. The symptomatology is due to a perturbation of the physiological function rather than a specific organ induced. So clinically identical picture can result from a wide variety of acute conditions within or near the peritoneal cavity that produce the same alterations of function as acute appendicitis.

The rate of preoperative diagnosis of appendicitis in any particular centre should be around 85 – 90% and if more or less it indicates the need for a look into differential diagnosis.

There are a few conditions in which operation is contraindicated. Other disease processes that are confused with appendicitis are also surgical problems and might need surgical intervention.



The most common erroneous preoperative diagnoses accounting for more than

75% in descending order of frequency are

- acute mesenteric lymphadenitis,
- pelvic inflammatory disease,
- twisted ovarian cyst or
- ruptured graafian follicle, and
- acute gastroenteritis.

The differential diagnosis of acute appendicitis depends upon four major factors:

- The anatomic location of the inflamed appendix;
- The stage of the process (i.e., simple or ruptured);
- The patient's age; and
- The patient's sex.

### **ACUTE MESENTERIC ADENITIS :**

Acute mesenteric adenitis is the disease most often confused with acute appendicitis in especially children. A recent history of upper

respiratory tract infection is notable. The pain is usually diffuse and not localized.

Laboratory procedures indicate although a relative lymphocytosis, when present suggests mesenteric adenitis. Often *Campylobacter* or *Yersinia* is implicated in the causation. Observation for several hours likely points the diagnosis, because mesenteric adenitis is a self-limited disease. However, if the diagnosis remains in doubt, immediate exploration is clearly indicated.

#### **ACUTE GASTROENTERITIS :**

Acute gastroenteritis is common in childhood but can usually be easily differentiated from appendicitis. Viral gastroenteritis, an acute self-limited infection of diverse causes is characterized by profuse watery diarrhea, nausea, and vomiting. Abdominal cramps with tenesmus precede the watery stools. The abdomen is relaxed between cramps, and more importantly there are no localizing signs of peritonism. Laboratory values are normal. *Salmonella* gastroenteritis results from ingestion of contaminated food. Abdominal findings are usually similar to those in viral gastroenteritis, but in some cases, the abdominal pain is intense, localized, and associated with rebound tenderness. Chills and fever are common. The leukocyte count is usually normal. The causative

organisms can be isolated from nearly 100% of patients. However, cultures may take too long for differentiation to assist the clinician in making a timely differential diagnosis. Similar attacks in other persons eating the same food as the patient greatly strengthen the presumptive diagnosis of salmonella gastroenteritis. Because typhoid fever is now a rare disease, its diagnosis is frequently missed. The onset is less acute than in appendicitis, with a prodrome of several days. Differentiation is usually possible because of prostration, maculopapular rash, inappropriate bradycardia, and leukopenia. Diagnosis is confirmed by culture of *Salmonella typhosa* from stool or blood. Intestinal perforation, usually in the distal ileum, develops in 1% of cases and requires immediate surgical therapy.

### **GENITOURINARY INFECTIONS:**

The diseases of male urogenital tract form a most important differential diagnosis for appendicitis including torsion of the testis and acute epididymitis, because epigastric pain may overshadow local symptoms early in these diseases. Seminal vesiculitis may also mimic appendicitis, but can be diagnosed by palpating the enlarged, tender seminal vesicles on digital rectal examination.

## **MECKEL'S DIVERTICULITIS :**

The Meckel's diverticulum is located within the distal 2 feet of the ileum and is true diverticulum of the intestinal tract representing the junction of the midgut and hindgut namely the prearterial and postarterial segment of the embryologic gut. It can be the cause of variety of abdominal conditions but when present as a diverticulum arising out of the intestinal tract it may mimic appendicitis . Meckel's diverticulitis is due to the inflammation of the ectopic mucosa of the diverticulum and the nearby intestinal mucosa usually acid secreting gastric mucosa causing ulceration of the normal nearby intestinal mucosa. Resection of the segment of ileum bearing the the diverticulum with end-to-end anastomosis can nearly always be done through a McBurney incision, extended if necessary, as well as laparoscopically.

## **INTUSSUSCEPTION :**

In contrast to Meckel's diverticulitis, it is extremely important to differentiate intussusception from acute appendicitis as the treatment is entirely different. The age of the patient is important: appendicitis is very uncommon in children younger than age 2 years, whereas nearly all idiopathic intussusceptions occur in children younger than age 2 years. Intussusception occurs typically in a well-nourished infant who is

suddenly doubled up by apparent colicky pain. Between attacks of pain, the infant appears well. After several hours, the patient usually passes a bloody mucoid stool. A sausage-shaped mass may be palpable in the right lower quadrant. As the intussusception progresses distally, the right lower quadrant feels abnormally empty. The preferred treatment of intussusception, if seen before signs of peritonitis supervene, is reduction by barium enema, but treatment of acute appendicitis by barium enema may be catastrophic.

#### **CROHN'S ENTERITIS :**

Then manifestations of Crohn's regional enteritis of the distal ileum mainly causes symptoms of right lower quadrant pain with fever, vomiting and diarrhea. Without a antecedent diagnosis of inflammatory bowel disease the symptoms cannot be differentiated from that of appendicitis and if on operating, the appendix and caecum found to be normal with an inflamed distal ileum, appendectomy must be proceeded with.

#### **PERFORATION OF A PEPTIC ULCER :**

In a sealed perforation the contents that spilled from a gastro-duodenal perforation initially may induce peritonitis gravitating to the

right lower quadrant through the paracolic gutter and the upper abdominal symptoms minimized due to no more spillage, may mimic a appendicular pathology.

### **COLONIC LESIONS :**

Diverticulitis and perforation of caecal or right side lying sigmoid carcinoma can sometimes mimic appendicitis in the elderly with vague symptoms. Imaging modalities like CT are particularly suited for these groups of patients to clearly identify the pathology.

### **EPIPLOIC APPENDAGITIS :**

The epiploic appendages of the colonic wall may get torsed and infarcted producing inflammation and pain localized to the site and without the systemic upset or the sequence of events of appendicitis. The only symptom will be continuous pain at the location correspondingly with rebound tenderness but no rigidity. It is selflimiting and resolves, in around 25% patients exploration is undertaken for the continuous or recurrent pain and removal of the infarcted appendage will typically relieve the symptoms.

## **URINARY TRACT INFECTION :**

Acute upper urinary tract infection – pyelonephritis of the right kidney can present clinically with symptoms suggesting acute appendicitis of retrocaecal or postileal type, the accompanying renal angle tenderness, fever with chills and urinalysis abnormalities are sufficient enough to make a diagnosis.

## **URINARY CALCULI :**

A ureteral calculi most often mimics appendicitis particularly when lodged around the region of the appendix on the right side. The radiating pain from loin to groin, absence of leukocytosis and fever and the sequence of symptoms or clinical signs of rebound tenderness/rigidity points to the diagnosis. CT scan usually helps clinch the diagnosis.

## **PRIMARY PERITONITIS :**

In nephrotic syndrome patients, a primary peritonitis caused by gram-positive cocci may resemble the peritonitis of a perforated appendix, and the cultures from the peritoneal fluid may clearly point the diagnosis in these subset of patients.

## **YERSINIA INFECTION :**

Yersenia species like *Y.enterocolitica* and *Y.pseudotuberculosis* is spread by the feco-oral route and they predominantly cause infection of the terminal ileum, caecum, mesentery and appendix. Most are self-limiting and some may cause systemic sepsis if unrecognized. The clinical scenario of appendicitis must be intervened with appendectomy. The Yersinia species are responsible for 5% of the cases of acute appendicitis. *Campylobacter jejuni* induced diarrhea and abdominal pain may mimic appendicitis and *Salmonella typhi* can cause mesenteric adenitis mimicking appendicitis. Stool cultures and serology help to delineate the etiology.

## **GYNAECOLOGIC DISORDERS :**

The gynaecological disorders of young females are the most common differential diagnosis of appendicitis for which appendectomies are performed and they are the most common reason of high rate of false-negative appendectomies. Some of the commonest causes of the female reproductive tract pathologies that mimic appendicitis in the descending order of frequency are



## **PELVIC INFLAMMATORY DISEASE :**

The pelvic inflammatory disease which is most of the time bilateral when predominant on the right side may mimic appendicitis. The characteristic absence of symptoms and clinical signs of appendicitis and lower abdominal tenderness lower than that in appendicitis with cervical motion tenderness on per vaginal examination points to the diagnosis. The symptoms of PID might mimic appendicitis more so in the luteal phase of the menstrual cycle and vaginal smear will help rule out appendicitis.

## **RUPTURED GRAAFIAN FOLLICLE :**

Mittlesmerchz is the midcycle pain and tenderness in the lower abdomen caused by the rupture of a matured graafian follicle with the release of the ovum seen in young ovulating women. If it is from the right ovary and the amount of fluid released into the peritoneal cavity is sufficient enough it causes pain mimicking appendicitis. Ultrasound will aid in the diagnosis.

## **RUPTURED ECTOPIC PREGNANCY :**

The rupture of an ectopic pregnancy either tubal or ovarian classically is unrecognized and initially presents with abdominal pain in

the right lower quadrant. The history may reveal abnormal or missed menstrual cycles. The presence of a pelvic mass with leukocytosis, pallor and falling hematocrit along with tenderness on cervical motion in per vaginal examination indicates the diagnosis. Culdocentesis and fluid analysis will confirm the diagnosis. The clinical diagnosis is sufficient to warrant immediate exploration and it not prudent to wait for imaging modalities to confirm the diagnosis, as it is a gynaecological emergency.

### **TWISTED OVARIAN CYST :**

The ovarian cysts most commonly benign serous cyst may undergo torsion particularly when on the right side may mimic acute appendicitis. The presence of an abdominal mass and tenderness in a young women warrant the search for ovarian pathology and imaging modalities are sufficient to clinch the diagnosis. There may be pain, rebound tenderness, leukocytosis and fever. If the torsion has caused gangrene of the ovary, immediate resection is the treatment of choice.

### **OTHER CAUSES :**

Other diseases which may rarely mimic appendicitis are small bowel perforations, intestinal obstruction particularly closed loop obstructions, mesenteric vascular thrombosis, pleuritis of right lower

chest wall, acute cholecystitis, acute pancreatitis, abdominal wall hematomas, etc.,

## SCORING SYSTEMS OF APPENDICITIS :<sup>9</sup>

**Table 1. ALVARADO SCORE**

<b><u>ALVARADO SCORE :</u></b>	
<b>SYMPTOM / SIGN / TEST</b>	<b>SCORE</b>
Migration of Pain	1
Anorexia	1
Nausea-vomiting	1
Tenderness at right iliac fossa	2
Rebound pain	1
Raised temperature ( $\geq 37.3$ deg C)	1
Leucocyte count $\geq 10 \times 10^9/L$	2
Differential WBC count with neutrophils $\geq 75\%$	1
<b>Total score</b>	<b>10</b>

A score that is more than 6 is highly predictive of acute appendicitis and scores between 5 and 6 are prudent to be kept in observation. A score less than 5 indicates need to revise the diagnosis.<sup>9</sup>

## **MANAGEMENT OF ACUTE APPENDICITIS:** <sup>4,6</sup>

The management of acute appendicitis is essentially and primarily surgical. The patient must be prepared for surgery with adequate hydration and correction of electrolyte abnormalities. The use of antibiotics preoperatively has been largely studied and proved to be effective in reducing the postoperative infection rates.

For simple appendicitis without any complication, the antibiotic therapy is a single agent third generation cephalosporin for 24 hours alone. For appendicitis with complications, the antibiotic need to be continued till the fever subsides and the leukocyte count normalizes. For severe infections higher antibiotics like carbapenems, monobactams with aminoglycoside and metronidazole must be used.

### **TYPES OF SURGERY :**

#### ***OPEN APPENDECTOMY***

#### ***LAPAROSCOPIC APPENDECTOMY***

## OPEN APPENDECTOMY :

### INCISIONS :

- ***McBurney's incision :***

It is a gridiron incision obliquely at right angles to a line joining the right anterior superior iliac spine to the umbilicus and the center of the incision lies on the McBurney's point. The external oblique is cut and the internal oblique and transversus are split (the muscle-splitting incision), and retracted to reach the peritoneum.

The advantage of the incision is that regardless of the position of the appendix, the access to the caecum and appendix are superior and the incision also permits easy extension if necessary

- ***Lanz incision :***

This is a low incision for appendectomy than the classic gridiron incision, though this is cosmetic, the incision is difficult to extend. It is a transverse incision 1 inch above and medial to the anterior superior iliac spine extending to the lateral border of the rectus medially. This also is a muscle splitting incision.

- Other incisions:

- ***RUTHERFORD-MORRISON's incision :*** oblique muscle cutting incision along the lateral border of the rectus with the lower end at

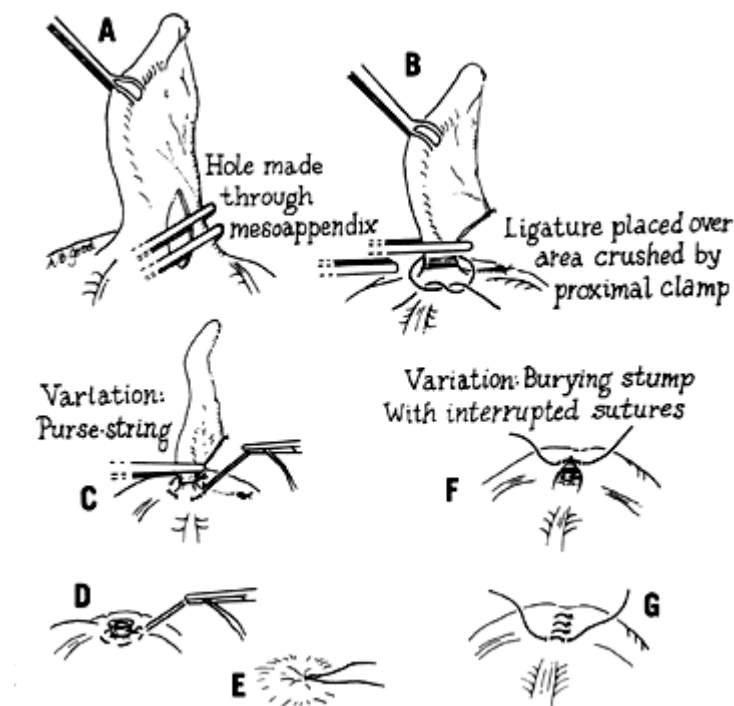
the McBurney's point with right paramedian incision of the rectus sheath vertically and retraction of the rectus muscle medially.

- ROCKEY-DAVIS incision; FOWLER WEIR incision
  - These are transverse incisions for better cosmesis and with extension medially when necessary.
- A lower midline laparotomy incision is considered when the diagnosis is in doubt particularly in elderly patients in whom carcinoma or diverticulitis is suspected and in selected group of female patients also.

#### **PROCEDURE :**

The incision is made and layers opened to reach the peritoneum. The peritoneum on opening, any intraperitoneal fluid assessed, if pus encountered it is taken for microscopy, culture and sensitivity. The taenia are traced along the caecum to their confluence to reach the base of the appendix. The lateral to medial movement helps to deliver the tip of the appendix. The delivery of the appendix out of the incision is the most tricky and difficult step of open appendectomy as the position of the tip is variable and may have adhesions to the neighbouring structures due to the inflammatory process involving the appendix. At times, a limited mobilization of the caecum is essential before one can deliver the

appendix particularly a retrocaecally placed one, the caecum can be delivered out by a rocking motion and then appendix can be traced. The appendix is mobilized by dividing the mesoappendix. Care must be taken to carefully ligate the appendicular artery. Once the appendix is freed from the mesoappendix. The base is double ligated and cut. An adequate stump must be left to ensure a secure ligation. The stump can be just ligated and left or ligated and inverted into the caecum by a purse-string or Z suture.



**Fig. 12 Open appendectomy - Stump inversion**

However this step is not followed nowadays because it does not confer any advantage in preventing stump leaks. The peritoneum is irrigated and hemostasis verified. All layers closed with absorbable sutures. Skin sutured with non-absorbable sutures.

In the event of encountering pus or fecal matter on opening the peritoneum, the need for a laparotomy or the extension of the incision should be assessed. The appendectomy must be proceeded with, and a careful handling of the friable tissues must be borne in mind. Once the appendectomy is completed, the distal ileum and caecum must be inspected to confirm their integrity, peritoneal irrigation with normal saline and metronidazole is indicated. The need for drainage of the peritoneal cavity must be assessed and a closed non-suction drain must be placed. If grossly infected or contaminated, the wound must be left open to heal by secondary intention or a delayed primary closure contemplated after 4 to 5 days when the infection is reduced.

If the appendix is found to be normal, then a thorough search for other pathologies must be made starting from the caecum, mesentery, the whole of small intestine must be checked as far as possible in a retrograde fashion starting from the ileo-caecal valve. In young females, the reproductive organs must be thoroughly felt to rule out pathology in



them. In the event of no other pathology being found the appendectomy must be proceeded with and the peritoneal fluid must be sent for microscopy, culture and sensitivity in the prospect of finding other pathologies.

### **LAPAROSCOPIC APPROACH :**

### **PREOPERATIVE WORKUP AND PREPARATION :**

The patient selection is very important in laparoscopic appendectomy as the role of LA in complicated appendicitis is controversial however in experienced hands they are forming valid indications these days. The main contraindications are in patients with peritonitis and those with comorbidities precluding general anaesthesia.

The preoperative preparation with resuscitation and investigations is the same as for open appendectomy. The patient must be informed of the likelihood of conversion of the procedure into an open approach if conditions warranted. A nasogastric tube may be used in the event of ileus complicating the appendicitis and a urinary catheterization to drain the bladder would help in the visualization of the pelvic organs.

## **PROCEDURE :**

The surgeon stands to the left of the patient and the camera assistant on the right of the surgeon near the left shoulder of the patient. The trolley and monitor on the right of the patient in front of the surgeon at the level of the umbilicus.

The patient is placed supine and the arms tucked by the sides, and patient secured to the table facilitating the rotation of the table to a Trendelenburg and right side up position for better visualization by allowing the abdominal viscera to gravitate to the left away from the right lower quadrant.

A 10 mm trocar is sited at the umbilicus or supraumbilical position by either an open method or close Veress needle insufflation (12 mm Hg). Two more working ports are established, one along the suprapubic region and the other along the left iliac fossa both being directed to the right iliac fossa. One 5 mm port along the right side of the abdomen lower down and the other on the lower midline also is used by some surgeons but this causes the surgeon's right hand to cross the cameraperson's arm making it difficult.

A 10 mm 30 degree telescope is introduced through the umbilical port and a diagnostic inspection of the entire abdomen is carried out in a step wise fashion. Using grasping forceps the appendix is located and if found normal, rest of the caecum, small intestine and pelvic organs in the female are visualized to delineate the pathology.

The omentum adhered in the region of the right iliac fossa being involved in the inflammatory process is gradually teased off and the appendix is traced if not readily located, the caecum is grasped and the taeniae are traced to the base of the appendix.

***Mesoappendix coagulation :***

The mesoappendix is coagulated by the use of bipolar coagulation in short bursts and teased with the grasper or cut with scissors. If the mesoappendix is bulky and inflamed then it must be completely coagulated before dividing to avoid bleeding of the appendicular artery. If in doubt the divided mesoappendix should be ligated with an endoloop. The mesoappendix is separated completely from the appendix till the base and the base clearly delineated to the caecum to avoid leaving behind a long stump.

### ***Appendix excision :***

Pre-readied endoloops of chromic catgut introduced through the 5 mm port closer to the surgeon and the appendix is guided through the loop and the knot secured around the base. The appendix is crushed and another endoloop is placed just above the previous one by the same method. The appendix is cut between the two endoloops. By preference one endoloop alone is sufficient and the appendix cut distally. There is no difference of outcome proven between the use of number of endoloops.

The use of stapler for division of the appendicular base is not widely practiced because of the cost and the need for a bigger 12 mm port. It is useful in special occasions where there is no healthy base to ligate or the caecal pole is also involved, wherein a stapler can resect that part of the caecum without compromising the ileo-caecal valve.

Saline lavage of the region or the whole of the peritoneal cavity may be carried out accordingly to minimize the postoperative infection rates.

### ***Extraction of the divided appendix :***

The appendix is extracted through the 10 mm port if not grossly infected by changing over to a 5mm laparoscope.

Usually, the left handed trocar with the appendix specimen is introduced retrogradely through the umbilical port and the laparoscope gradually withdrawn. As soon as it reached the flap valve, the laparoscope is removed and the appendix is caught with the hemostat releasing from the left hand grasper and the specimen is delivered. In case of bulky and grossly infected appendicular specimen, the same is placed in a plastic bag before extraction to avoid wound infection.

The placement of a drain is not always indicated. If the appendix was perforated and contamination was significant and the closure of the stump was precarious, small closed drain is placed in a separate incision in a dependent and direct contact to the right iliac fossa intraperitoneally.

The fascial closure at the 10 mm port is a must with a non-absorbable suture material to avoid port site herniation in the future. The skin is closed with non-absorbable simple or subcuticular sutures.

#### **DIFFICULT SITUATIONS :**

- Inflammation of the base of the appendix and involvement of the caecum by the inflammation may preclude the feasibility of endoloop ligation of the base and the need for partial resection of the caecum must be given consideration. In these circumstances,

the need for conversion to laparotomy is to be considered. If there is no stapler available or the surgeon is not competent with advanced laparoscopic skills, conversion to open procedure is the best course of action.

- A retrocaecally placed appendix is not easily identifiable and the mobilization of the caecum by lateral incision of the parietal peritoneum is needed. An additional 5 mm port to hold the caecum rotated medially using a bowel grasper facilitates better dissection of the retrocaecal plane and the ureter with gonadal vessels must be safeguarded.
- The appendicular tip may be difficult to locate due to inflammation and being buried deeper in the surrounding inflammatory mass. In such cases, the appendectomy must be proceeded retrograde from the base working toward the tip. All attempts must be made to completely remove the tip to prevent development of intraabdominal abscess in the postoperative period.
- The appendicular mass when found preoperatively can be dealt with by laparoscopy better than delaying to interval appendectomy but should be undertaken only with considerable experience and there must be a lower threshold for conversion to open procedure if the situation demands.

## **COMPLICATIONS OF APPENDECTOMY :<sup>4</sup>**

The complications of appendectomy in the recent times both with open and laparoscopic approaches have been reported to be between 10 and 20%. The wound infection is the most common complication post appendectomy and this has been minimized with laparoscopic approach. Independent risk factors that increase the incidence of postoperative complications are mainly obesity, smoking, and a perforated appendix.

### ***SURGICAL SITE INFECTIONS :***

This is the most commonly encountered postoperative complication of appendectomy. The infection may be incision related – wound infection superficial or deep, or intra-abdominal abscess and sepsis.

### ***WOUND INFECTION related to the INCISION :***

The incidence of postoperative wound infection remains high even with the use of prophylactic antibiotics and is more so with perforated appendix and diffuse peritonitis at operation. The incidence of wound infection for non-perforated appendix is < 10% compared to perforated appendix which can be from 15 – 35%. Primary closure or delayed primary closure of the wound doesn't make a difference while the

laparoscopic approach was found to have a better outcome compared to the open approach in terms of lesser wound infections

### ***INTRA-ABDOMINAL ABSCESS :***

The incidence of intra-abdominal abscess is one of the complications of appendectomy and it has risen recently particularly with the laparoscopic approach. The use of routine irrigation and suctioning of the irrigated fluid completely must be undertaken to prevent abscess formation as the retained fluid might gravitate to the pelvis forming collections which become infected to form abscesses. The mode of closure of the appendicular stump either by endoloop or stapler doesn't significantly influence the abscess formation. The conservative management of the abscesses with antibiotics and percutaneous image guided drainage is sufficient and most don't require further surgery.

### ***BOWEL OBSTRUCTION :***

The incidence of postoperative intestinal obstruction after appendectomy is mainly due to adhesions and accounts for 7% to 25% of all adhesive intestinal obstructions often being caused by a tight band. Complete obstruction occurs in about 50% cases. This is a definitive indication for re-operation and laparoscopic adhesiolysis is the treatment



of choice. The incidence of bowel obstruction is far less by the laparoscopic approach in the primary procedure. The other causes of bowel obstruction after appendectomy may be caeco-colic intussusception, caecal or midgut volvulus.

### ***STUMP COMPLICATIONS :***

Stump appendicitis is a complication of appendectomy and defined as repeated inflammation of the residual remaining appendiceal tissue after appendectomy and presents with pain, nausea, vomiting, and anorexia. It can be diagnosed with CT and more than half cases are associated with perforation of the appendicular stump and / or caecum. Re-operation with completion appendectomy and limited resection if there is contiguous involvement of the caecum and neighbouring structures is the treatment of choice. The incidence of stump appendicitis can be minimized by proper visualization of the appendicular base and leaving no more than 3 mm of stump behind.

### ***FECAL FISTULA :***

Fistula occurs when there is a gangrenous or perforated appendix at the time of the initial surgery with peri-appendicular inflammation and involvement of the base of the appendix and the caecal wall. The

appendiceal stump blow out and leakage is the major causative factor. Associated other factors increasing the chance of stump leak are malignancy of the appendix base and caecum, foreign bodies, infective bowel complications, Crohn's enteritis and distal mechanical obstruction. Most fistulas close spontaneously within a month, when the comorbidities and associated factors are dealt with. If not closed by 3 months then operative intervention is indicated after 4 – 6 weeks of nutritional support and sepsis control. The complete excision of the fistula tract and segmental resection of the involved bowel with primary anastomosis is the treatment. Other forms of treatment that have been tried without much success are vacuum assisted closure and fibrin glue injection.

### ***POSTOPERATIVE BLEEDING :***

Bleeding post appendectomy can be due to varied reasons namely in the descending order of frequency :

- Inadequately controlled appendicular artery in the mesoappendix
- Stump bleed manifesting as acute lower GI bleed
- Chronic, recurrent rectal bleed from a appendiceal stump granuloma
- Laparoscopic injury to the epigastric vessels of the abdominal wall; retroperitoneal major vessel bleed by trocar / veress needle injury.

The most important component of appendectomy both open and by laparoscopy is the proper control of the mesoappendix to avoid bleeding. Stump bleed can be controlled by colonoscopic methods and is due to a small intramural branch of the appendicular artery. Granuloma needs ileo-colic resection. Laparoscopic injuries are intrinsic to the technique and can be avoided by superior skills and precautions.

### ***HERNIATION :***

The incisional hernia at the appendectomy site particularly in open appendectomy is a rare entity and definitively associated with mode of presentation and wound complications at the time of the primary procedure and other comorbidities such as

- Perforated appendix and abscess formation
- Wound infection and seroma in the postoperative period
- Female
- Obesity
- Diabetes

Laparoscopic appendectomy is associated with a specific type of hernia namely the port site herniation due to fascial defects due to non-closure or incomplete closure of the port site >10 mm. These can be

avoided with non-absorbable suture closure of the fascial defects more than 10 mm formally.

Inguinal hernia post appendectomy :

The transverse abdominis muscle acts to close the deep inguinal ring during voluntary muscle contraction and found to be denervated and paralysed regionally in postappendectomy patients and predispose to inguinal hernia particularly of the indirect type. However the association is not absolute and it is only a contributory factor in the development of inguinal hernia in these already predisposed individuals.

#### ***INFLAMMATORY BOWEL DISEASE DEVELOPMENT RISK :***

Various studies have demonstrated a decrease in incidence of Ulcerative colitis in postappendectomy patients while an increase in incidence of Crohn's disease in these patients. The association of Crohn's disease to appendicitis is refuted by the association of a T cell helper type 1 dominated immune responsivity characteristic of Crohn's seen with perforated appendicitis.

#### ***MALIGNANCY IN APPENDECTOMY SPECIMENS :***

The incidence of malignant disease of the appendix in itself is rare accounting for < 1% of all GI malignancies. The incidence of malignancy

reported in post appendectomy specimens is found to be between 0.7 to 1.7% in all. The carcinoids form the most of this group. If the tumor in the resected specimen is < 2 cm and not involving the specimen margins and the mesoappendix, then appendectomy alone is enough. Pseudomyxoma peritonei typically involves the appendix presenting as appendicitis and the treatment is complete tumor resection and intra-peritoneal chemotherapy.

***COMPLICATIONS related to GYNAECOLOGY :***

Appendectomy for uncomplicated appendicitis in fertile women is not associated with fertility issues. In cases of perforated appendicitis in fertile women the rate of tubal infertility varies from 3.2 to 4.8%

The appendicitis occurring in pregnancy is around 0.9% and the risk of perforation is highest in the third trimester while postappendectomy abortion rate is highest in the first trimester. Hence the safest time to operate on a pregnant women with appendicitis is in the second trimester.

Laparoscopy is particularly suited in the first two trimesters of pregnancy as other causes of right lower quadrant pain can be clearly discerned, however the third trimester use of laparoscopy is not evaluated

well. The overall fetal loss and hospital stay was found to be longer with laparoscopic approach but the other complication rates were same as for the open approach. Complication of appendicitis is independently associated with increased fetal loss due to septicemia induced fetal malformations like microcephaly. The delay in surgery for appendicitis in pregnancy which is difficult to diagnose has been independently associated with increased mortality and morbidity. Hence prompt diagnosis and immediate treatment are most essential in particularly pregnant patients.

#### ***MISCELLANEOUS COMPLICATIONS :***

Pylephlebitis which is thrombophlebitis of the portal venous system can occur preoperatively in atypical and late presentations of appendicitis particularly in males and perforation of the appendix with sepsis inducing venous thrombosis. This was more common in the pre-antibiotic era and has been reduced with advent of antibiotics. Postoperatively it can occur from hematogenous spread of inflammation from the appendix but is quite rare. The management is antibiotics, and urgent exploration and appendectomy with control of sepsis. Without intervention the mortality can be 50%. Conservative management with higher antibiotics and anticoagulants can be tried but expeditiously.

Ureteric injury though rare have been documented with mid-ureter most commonly involved during appendectomy for a complicated appendix and ureteric obstruction consequent to inflammation extending to the bladder base causing plugging of the distal ureter has been documented which can be managed conservatively.

The extension of inflammation via a patent processus vaginalis to the scrotum causing abscess or pyocele of a previously present hydrocele has also been documented.

#### ***TUBERCULOUS APPENDICITIS :***

The incidence of gastrointestinal TB is less around 3%. Among these cases only less than 1% constitute appendicular involvement and that too by extension fo involvement of other intra-abdominal organs. The diagnosis is by high index of suspicion and presentation of tuberculosis of the appendix as appendicitis is a very rare occurrence and the diagnosis is often made from the histopathology report of an appendectomy specimen only.

#### ***NEGATIVE APPENDECTOMY :<sup>4</sup>***

As appendectomy is considered as the index operation in training junior residents and with the advent of laparoscopic appendectomy, there

seems to be an increased rare of appendectomies being performed leading eventually to a higher rate of negative appendectomies.

A negative appendectomy is more so in the extremes of age occurring in < 6 yr old patients to > 50 yr old patients and women in 70s are the most in whom negative appendectomies occurred. The negative appendectomy so called is not a benign procedure and has its own complications and morbidities which are more than that of appendectomy for true appendicitis as a negative appendectomy is more likely in an older age group with comorbidities to account for.

When we are encountered with a normal appearing appendix on exploration for a suspected appendix and there is no other discernible pathology whether laparoscopically or by open approach, it is mandatory to proceed with appendectomy as more than 26% normal looking appendix is proven to have inflammation.

**COMPARISON OF LAPAROSCOPIC APPENDECTOMY (LA) AND OPEN APPENDECTOMY (OA) :<sup>4</sup>**

***ACUTE APPENDICITIS :***

In the management of acute appendicitis the superiority of LA over OA has been demonstrated by various randomized control trials. A comparison of a variety of randomized control studies have concluded



that the operating time for LA is considerably more than that for OA. In terms of postoperative complications – the incidence of wound infection at the surgical site was more in the OA group than the LA. Other general infectious complications like UTI, pneumonia were no different. LA was significantly associated with lesser postoperative pain and shorter hospital stay, earlier return of bowel functions to normal, the cost of hospital stay and return to work earlier compared to OA.

### ***COMPLICATED APPENDICITIS :***

The laparoscopic versus open approach for complicated appendicitis showed no difference of operating time but a reduced hospital stay was seen with the laparoscopic approach. The surgical site infections were lesser for the LA and no statistical difference between the incidence of intra-abdominal abscesses with either procedure. The trials proving these differences were not strict in randomization and care protocols. Nevertheless the use of LA in complicated appendicitis depends on the surgeon's skill as a laparoscopist and recognizing the need to convert to open procedure of a laparoscopic approach when the situation demands.

### ***OBESITY :***

The abdominal wall thickness in the obese patients make the exposure and retraction difficult and increase the chance of seroma and wound infections in the postoperative period. The trials comparing LA to OA in obese patients have fallen short of demonstrating any significant benefit of one over the other and further studies need to be undertaken to conclude the advantage of one over the other.

### ***OLDER PATIENTS :***

The acute appendicitis occurring in elderly patients has increased consequent to the longer life spans. Older patients tend to have atypical presentations with significant comorbidities and go in for complications sooner than younger patients. Studies comparing LA and OA have demonstrated a better outcome in terms of earlier postoperative recovery, reduced hospital stay with the laparoscopic approach.

### ***PREGNANT WOMEN :***

There are conflicting reports for the use of LA over OA in pregnant women. The LA was found to have a significant fetal loss upto 6% compared to OA and the rate of negative appendectomies and complications with pneumoperitoneum creation were significant with LA. In account of high fetal loss, OA is still considered to be the standard of approach for appendectomy in acute appendicitis in pregnancy.

## **MATERIALS AND METHODS**

### ***MATERIALS :***

All patients presenting to the emergency department and out-patient department with acute appendicitis.

### ***METHODOLOGY :***

A record of all patients including age, sex, clinical history relevant and physical examination findings, past illnesses and prior major abdominal surgeries.

A detailed consent explaining both the open and laparoscopic approaches and the procedure and complications involved with each approach, the postoperative recovery and morbidity was obtained.

### ***INCLUSION CRITERIA :***

All patients presenting with right lower quadrant pain or periumbilical pain migrating to the right lower quadrant with nausea and / or vomiting and fever  $>38$  deg C and / or Leukocytosis  $> 10,000$  cells /cu.mm, right lower quadrant tenderness and / or guarding on physical examination or with graded compression sonographic probe tenderness or other diagnostic evidence of appendicitis.

***EXCLUSION CRITERIA :***

- Paediatric patients (< 12 yrs)
- Pregnant women
- Comorbid illness
- Contraindications to general anaesthesia / laparoscopy
- Patients with other intra-abdominal pathologies presenting as acute appendicitis found to be otherwise intra-operatively.

***STUDY GROUPS :***

50 patients chosen matching the inclusion and exclusion criteria from both the open and laparoscopic appendectomy groups and analysed for outcome and various parameters assessed and compared.

***PROCEDURE :***

All patients resuscitated with i.v fluids and nil by mouth for eight hours prior procedure.

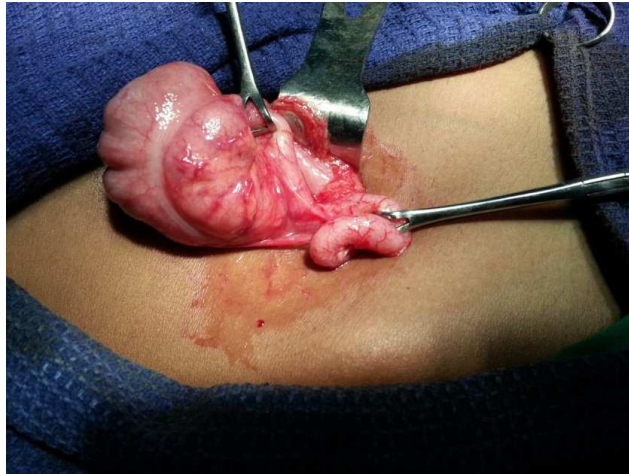
A dose of prophylactic antibiotics with cefotaxime 1 g iv from the time of diagnosis every 12<sup>th</sup> hourly and in cases of suspected complications, additional gentamicin 80 mg iv 12<sup>th</sup> hrly and Metronidazole 500mg iv 8<sup>th</sup> hrly were added.

Nasogastric aspiration was used when warranted by preoperative ileus and urinary catheterization were used in all female patients in laparoscopic surgery to facilitate pelvic organ visualization.

***SURGERY :***

***Open approach :***

The skin incision was either a McBurney's incision or Lanz incision according to the surgeon's preference. The external oblique was opened and the internal and transversus abdominis were split to reach the peritoneum. The peritoneum was incised and the appendix was searched from lateral to medial by displacing the small bowel loops medially. The caecum with the taenia coli was identified and traced to reach the base of the appendix. The appendix was delivered out and the mesoappendix was divided between ligatures and the base of the appendix was crushed and ligated with non-absorbable suture material. Hemostasis was verified. Distal ileum was traced for abnormalities and in females the pelvic organs were palpated for any other pathologies. Wound was closed in layers.



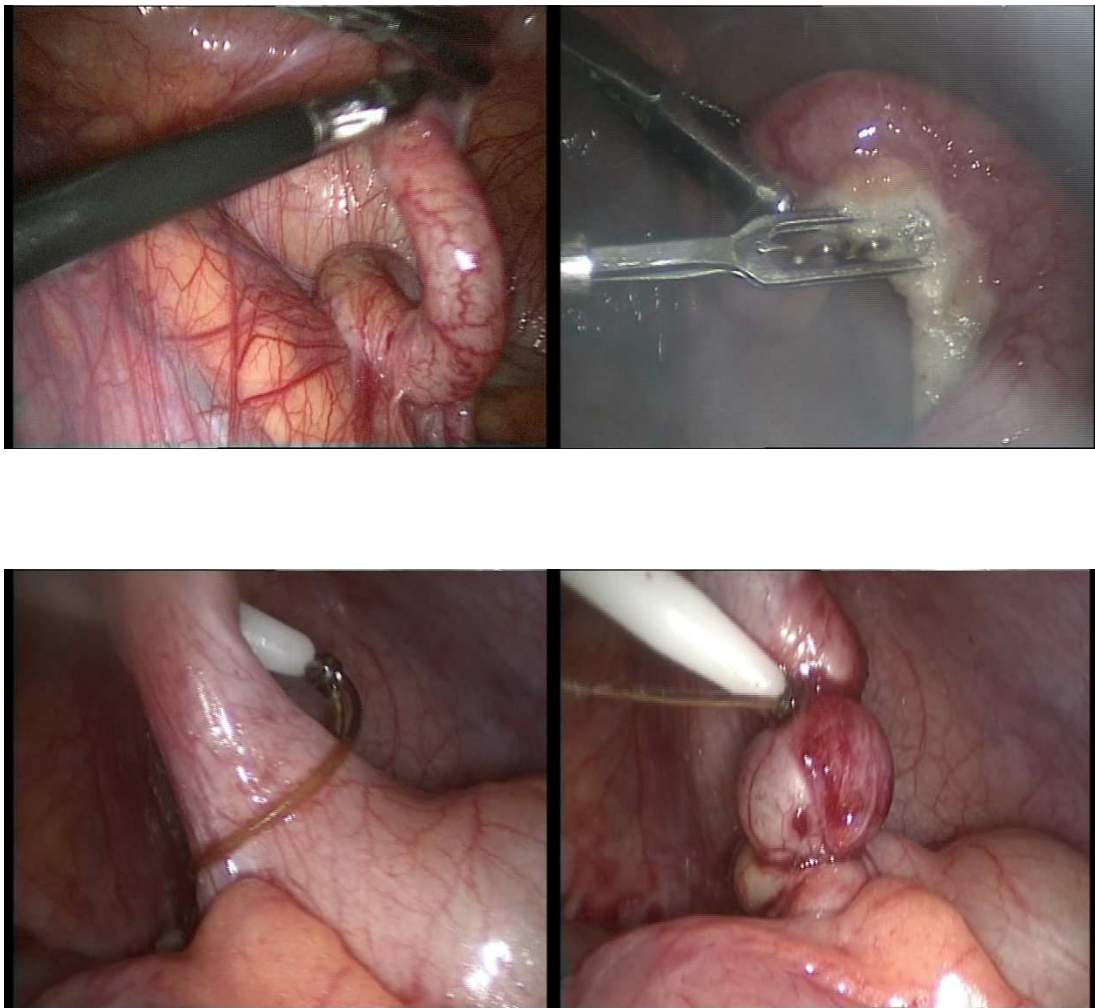
**Fig. 13 Open Appendectomy showing the delivered appendix with the caecum**

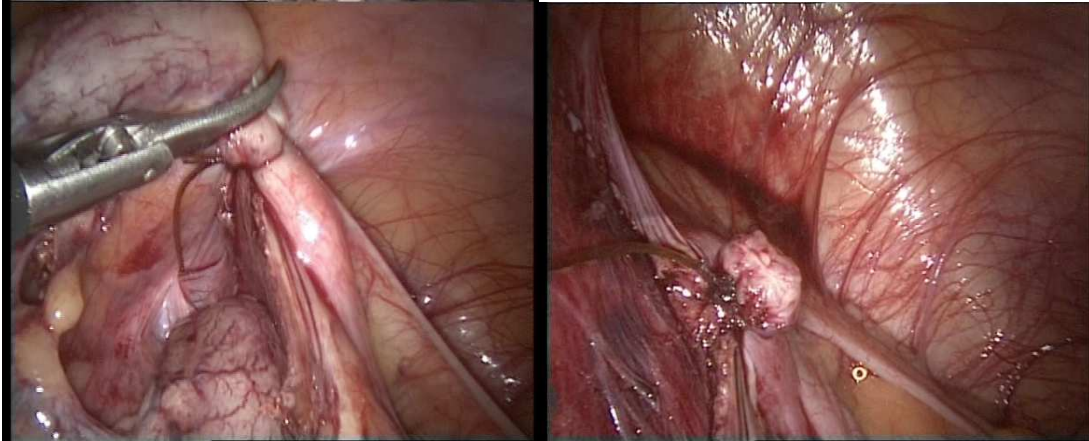
***Laparoscopic approach :***

A veress needle pneumoperitoneum created to 12 mm Hg. One 10mm umbilical port with 2 5 mm working ports one in the lower midline and the other in the left iliac fossa introduced under vision with a 30 degree laparoscope. The appendix visualized and pathology confirmed. If not a thorough search for other pathologies made out as in diagnostic laparoscopy. The appendix grasped with soft bowel grasper, the mesoappendix cauterized and teased with bipolar coagulation till the base of the appendix till it is completely free. The base crushed and endoloop pre-tied chromic catgut tied around the base of the appendix and cut. The field irrigated with saline and suctioned out in case of excessive dissection bleeding or soiling from the specimen. The specimen is delivered by aligning the lower left side port to the umbilical port and

withdrawn at the flap valve with a hemostat. Hemostasis at the port site checked as the two 5 mm ports are withdrawn and the camera port withdrawn. The fascial defect at the 10 mm port closed with non-absorbable suture materials. Skin closed with simple sutures.

**Fig. 14 Steps in Laparoscopic Appendectomy**





### ***POSTOPERATIVE PERIOD :***

All patients monitored for vitals and kept on nil by mouth with iv antibiotics till afebrile for 24 hrs and leukocyte count normalizes.

The analgesics used were parenterally NSAIDS – Diclofenac 75mg/ampoule intramuscularly twice daily with a minimum of two doses for either procedures and oral analgesics was started as soon as bowel function returns with oral diclofenac twice daily with a minimum of single dose switching over to as and when needed. The bowel functions were monitored on a hourly basis and the diet resumption started with liquids soon after the start of bowel sounds within 2 hours and solid diet started within 3 to 5 hours of tolerating liquid diet. The patients were discharged no less than 2 days of the procedure according to clinical status. All patients discharged were reviewed in a week for suture



removal according to the day of surgery and assessed for normality in terms of return to near normal work.

### ***ASSESSMENT OF PARAMETERS*** :<sup>1,2,3</sup>

- Operating time from skin to skin in minutes
- Indications for conversion of laparoscopy to open if any
- Postoperative pain needing analgesics in terms of dosage
- Time to return of bowel functions
- Normal diet intake both liquids and solids
- Number of days of stay at hospital
- Complications like wound infections and intra-abdominal sepsis
- Return to work in terms of number of days after surgery

## PROFORMA

Name :

Occupation :

Address :

D.O.A :

D.O.S :

D.O.D :

Age / Sex :

IP.No :

Phone No. :

Complaints :

Presenting illness :

Past history :

Previous abdominal surgeries :

Comorbid illness :

Treatment history :

GENERAL EXAMINATION :

SYSTEMIC EXAMINATION :

DIAGNOSIS :

PROVISIONAL:

FINAL:

INVESTIGATIONS :

- BLOOD INVESTIGATIONS :
  - COMPLETE BLOOD COUNT
  - RENAL FUNCTION TEST
- RADIOLOGY :
  - X-Ray Chest & Abdomen :
  - USG ABDOMEN & PELVIS :
  - CT ABDOMEN & PELVIS :
- E. C. G :

SURGERY :

- OPEN APPENDECTOMY
- LAPAROSCOPIC APPENDECTOMY

POST-OPERATIVE PERIOD :

CLINICAL OUTCOMES AND PARAMETERS ASSESSED :

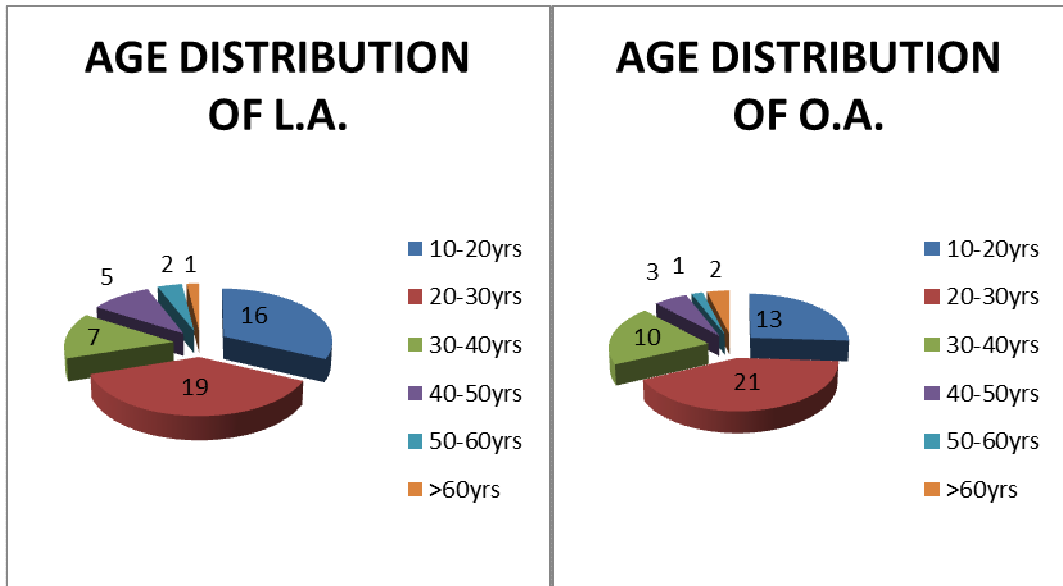
- PAIN – NO. OF DOSE OF PARENTERAL / ORAL  
ANALGESICS
- RETURN OF BOWEL FUNCTION IN HOURS
- RESUMPTION OF DIET LIQUID / SOLID IN HOURS  
EACH
- NO. OF DAYS OF HOSPITAL STAY IN DAYS
- NO. OF DAYS TO RETURN TO WORK IN DAYS
- WOUND INFECTION (Y/N)
- INTRA-ABDOMINAL ABSCESS EVIDENCE (Y/N)
- CONVERSION TO OPEN IN CASE OF LAPAROSCOPY
- NATURE OF PATHOLOGY SPECIMEN

# DATA ANALYSIS AND RESULTS

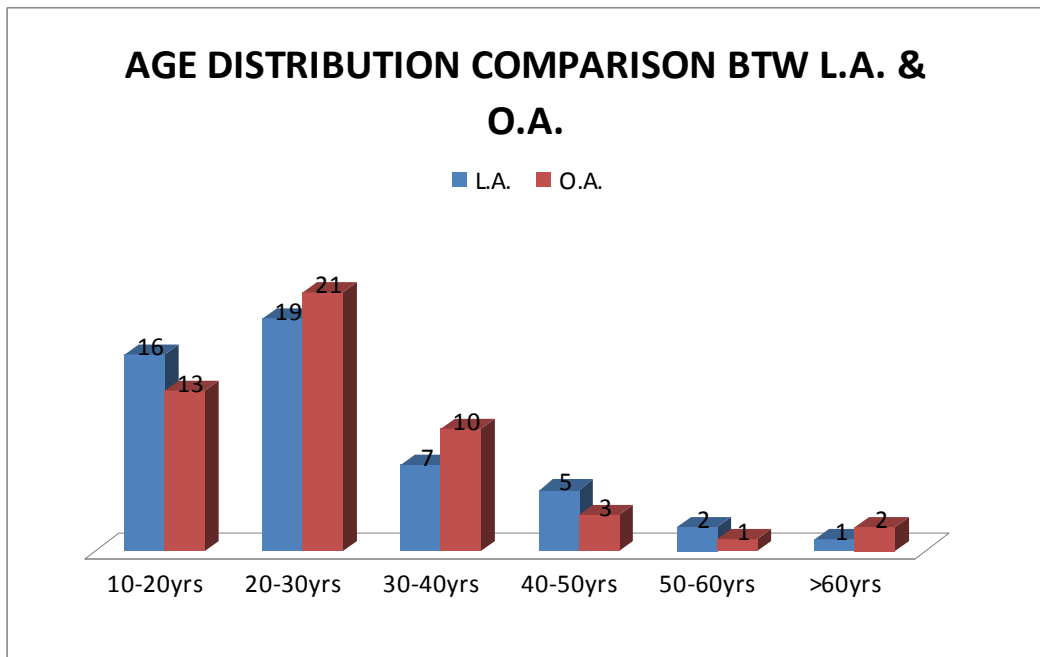
## AGE DISTRIBUTION :

**Chart 1a:**

**Chart 1b:**

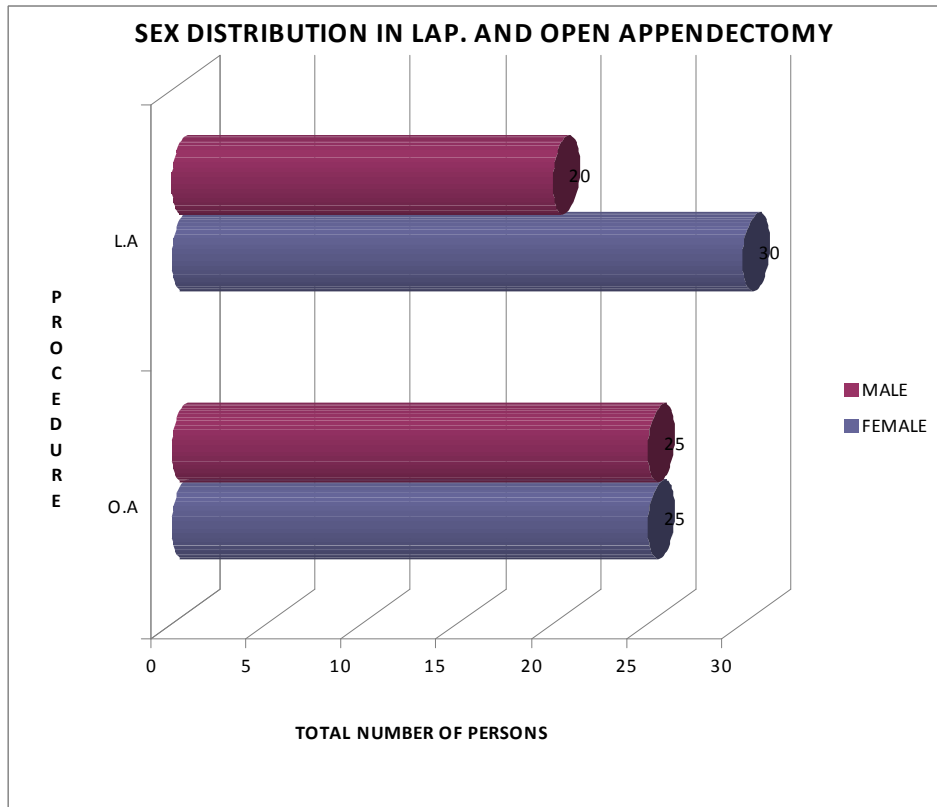


**Chart 1c :**



**SEX DISTRIBUTION :**

**Chart 2 :**



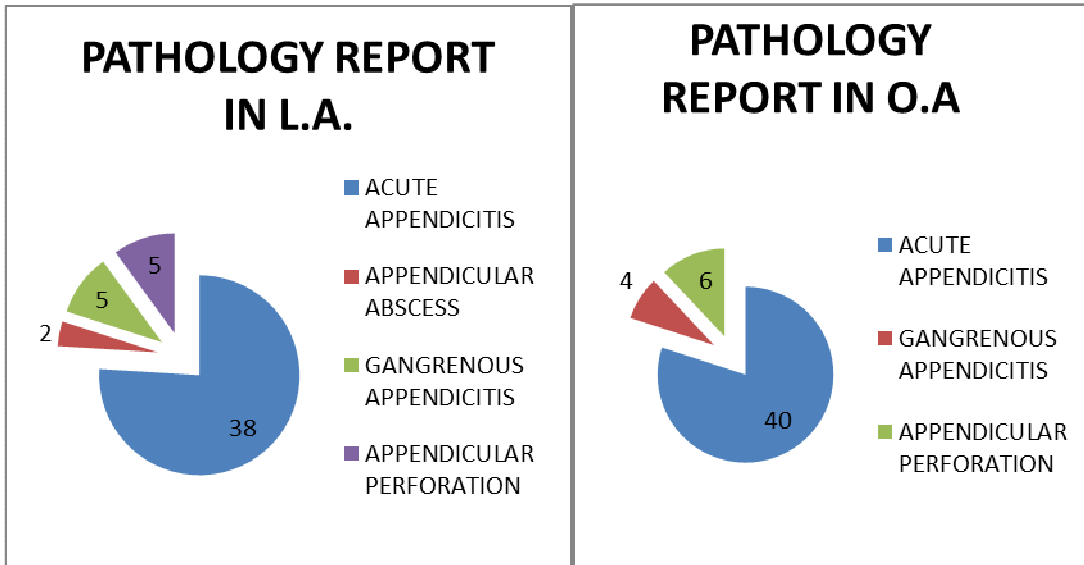
**Table 2 :**

LAPAROSCOPIC APPENDECTOMY		OPEN APPENDECTOMY	
MALE	40%	MALE	25%
FEMALE	60%	FEMALE	25%

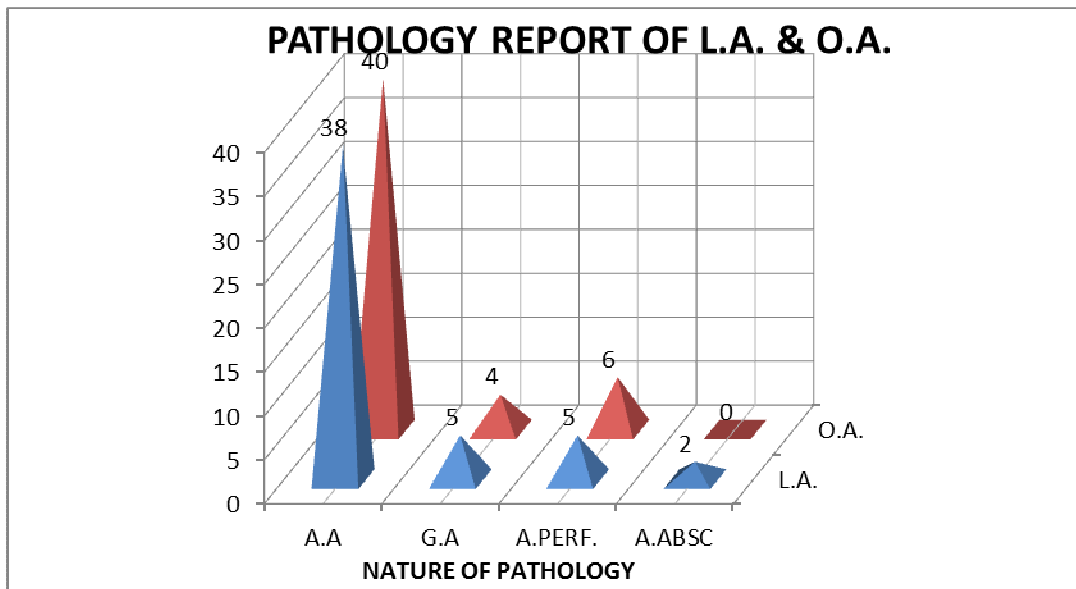
## PATHOLOGY REPORT OF THE SPECIMEN:

**Chart 3a:**

**Chart 3b:**



**Chart 3c:**



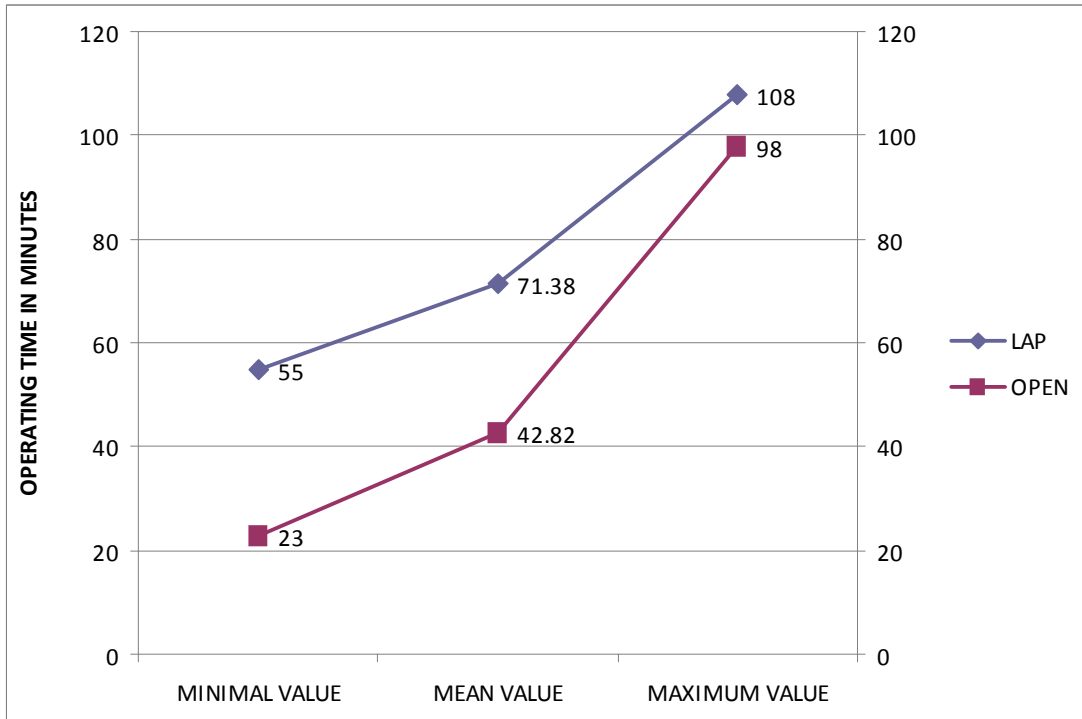
**Table 3:**

COMPLICATIONS	LAP APPENDECTOMY	OPEN APPENDECTOMY
ACUTE INFLAMMATION	76%	80%
GANGRENOUS	10%	8%
PERFORATION	10%	12%
ABSCESS FORMATION	4%	0%



**OPERATING TIME IN MINS :**

**Chart 4:**

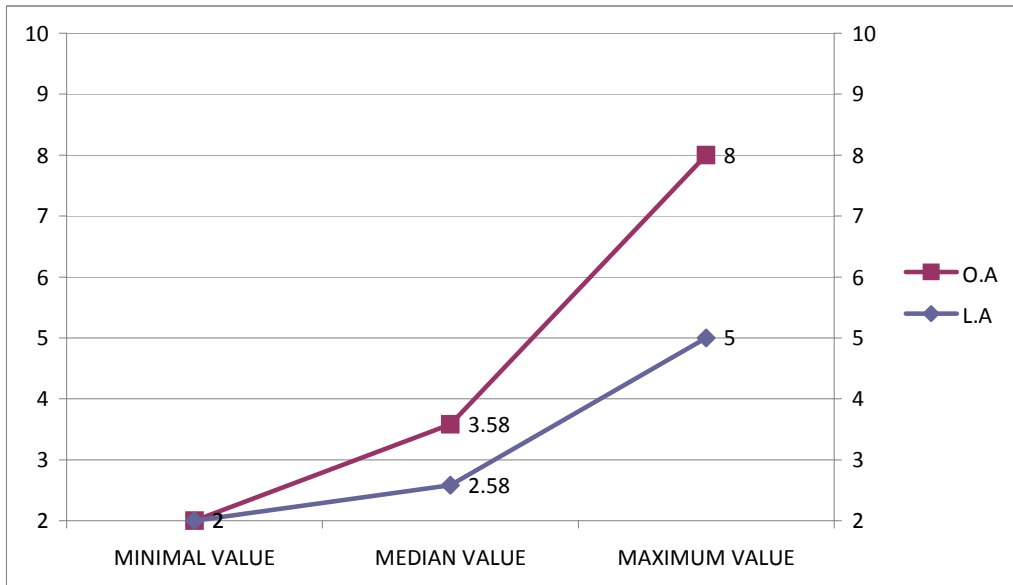


**Table 4 :**

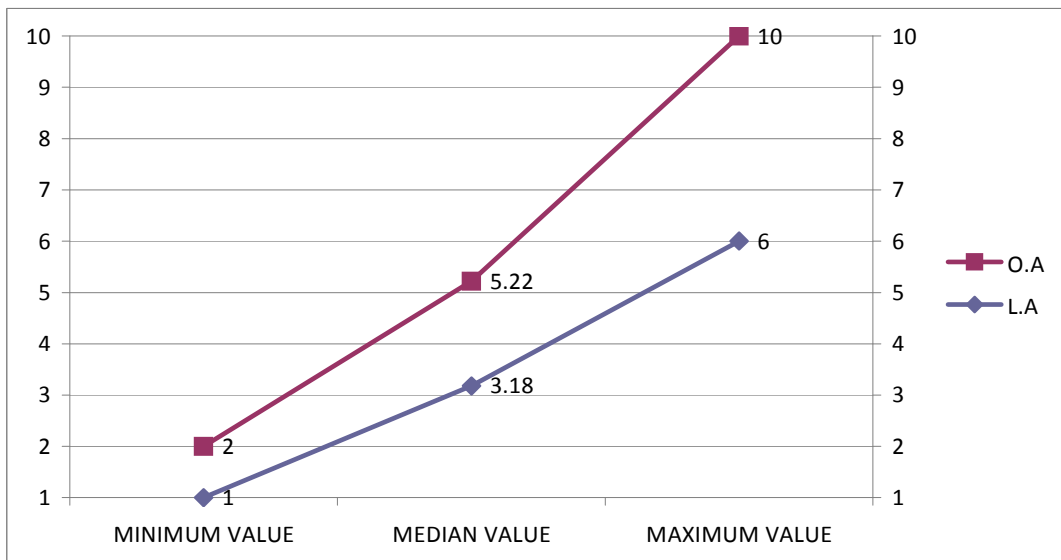
<b>OPERATING TIME IN MINUTES</b>	
LAPAROSCOPIC APPENDECTOMY	55 – 108 mins (71.38)
OPEN APPENDECTOMY	23 – 98 mins(42.82)

## POST-OPERATIVE PAIN AS ANALGESIC DOSES

**Chart 5a: PARENTRAL ANALGESIC BTW L.A AND O.A :**



**Chart 5b: ORAL ANALGESIC BTW L.A. AND O.A :**

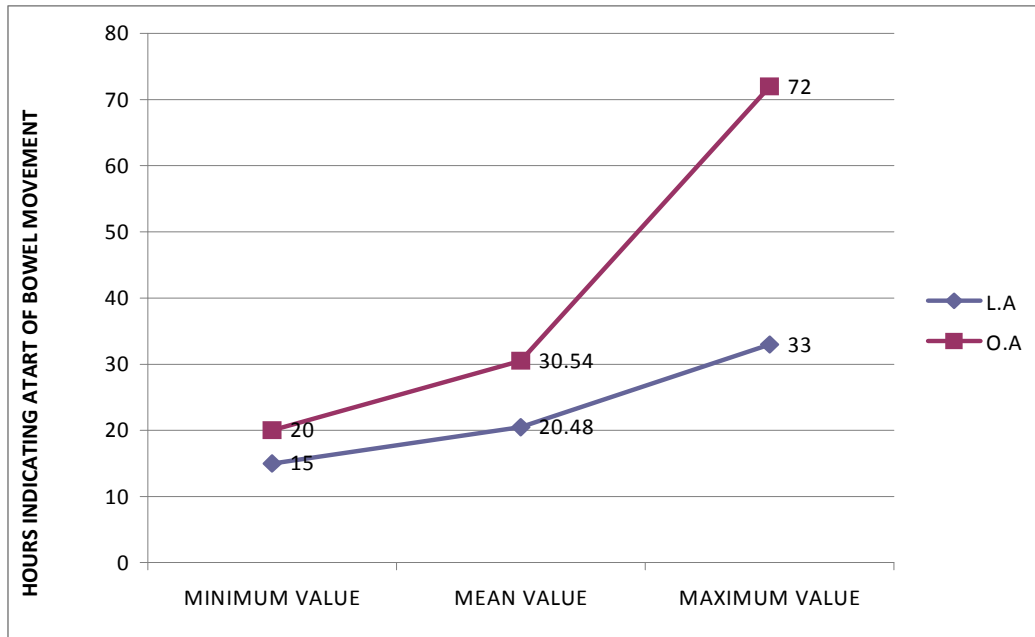


**Table 5:**

PROCEDURE	PARENTRAL	ORAL
LAP	2-5 doses (2.58)	1-6 doses(3.18)
OPEN	2-8 doses (5.22)	2-10 doses(3.58)

## RETURN OF BOWEL FUNCTIONS IN HOURS :

`Chart 6:

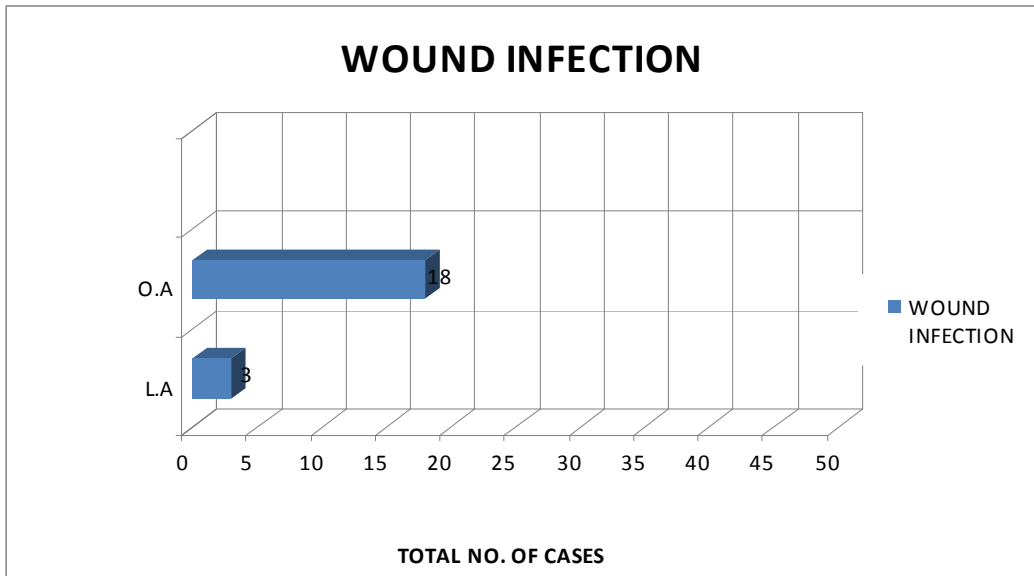


**Table 6:**

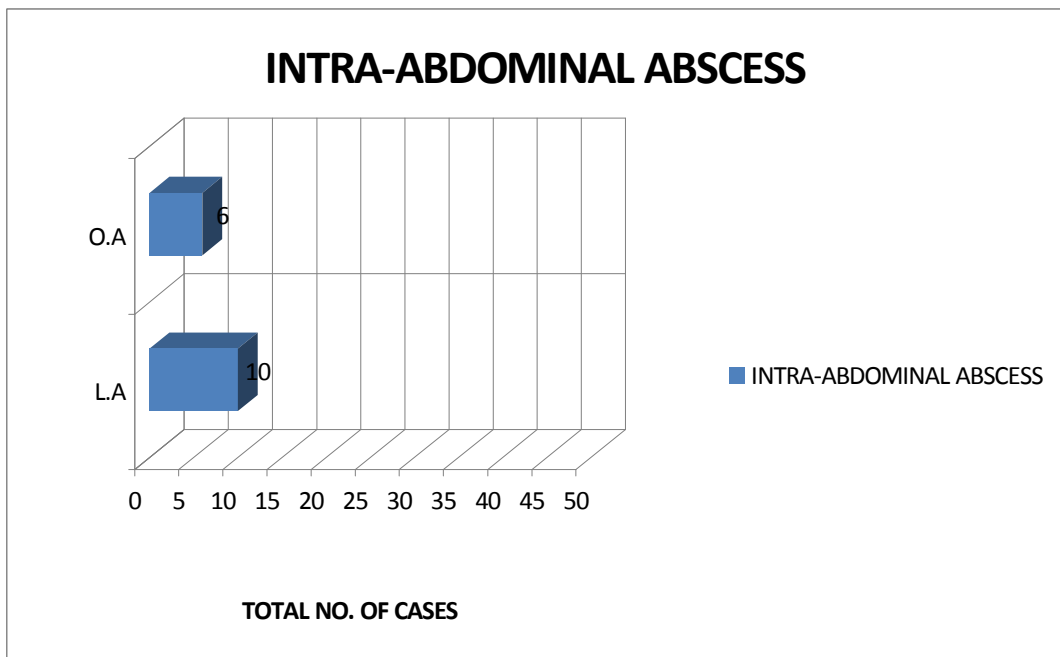
<b>Laparoscopic appendectomy</b>		<b>Open appendectomy</b>	
<b>Hrs</b>	<b>Percentage</b>	<b>Hrs</b>	<b>Percentage</b>
15	2%	20	4%
16	16%	22	18%
17	22%	23	10%
18	24%	24	10%
19	8%	25	16%
20	4%	26	7%
28	4%	27	4%
29	8%	30	2%
30	2%	32	2%
31	2%	33	2%
32	6%	44	2%
33	2%	45	4%
		46	2%
		66	2%
		68	4%
		69	2%
		72	2%

**COMPLICATIONS :**

**Chart 7a:**



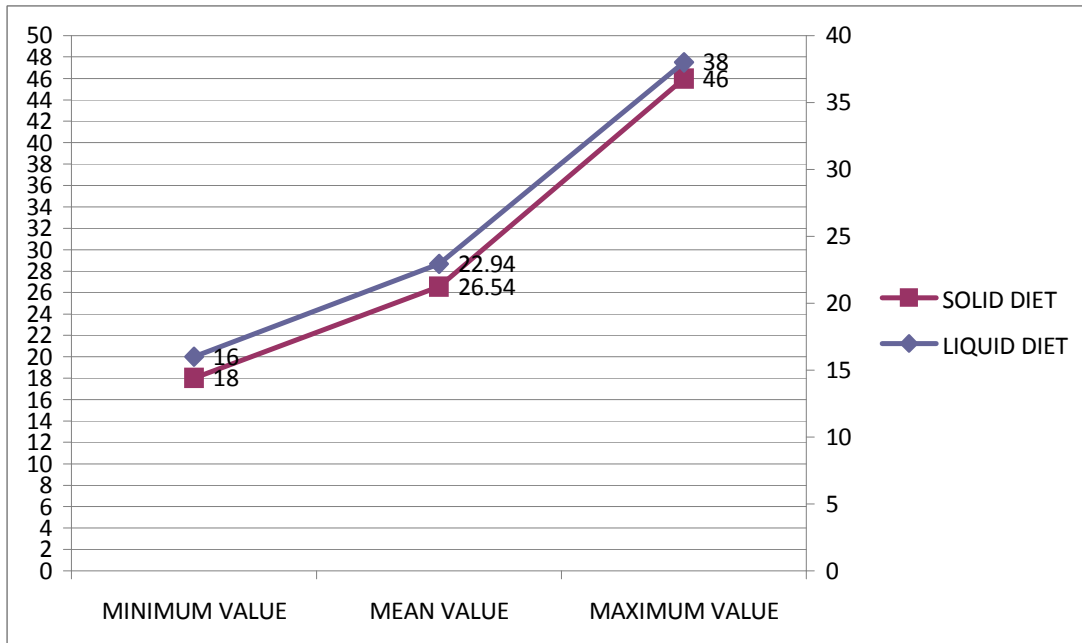
**Chart 7b:**



## RESUMPTION OF DIET BOTH LIQUIDS AND SOLIDS IN DAYS:

L.A.:

**Chart 8:**

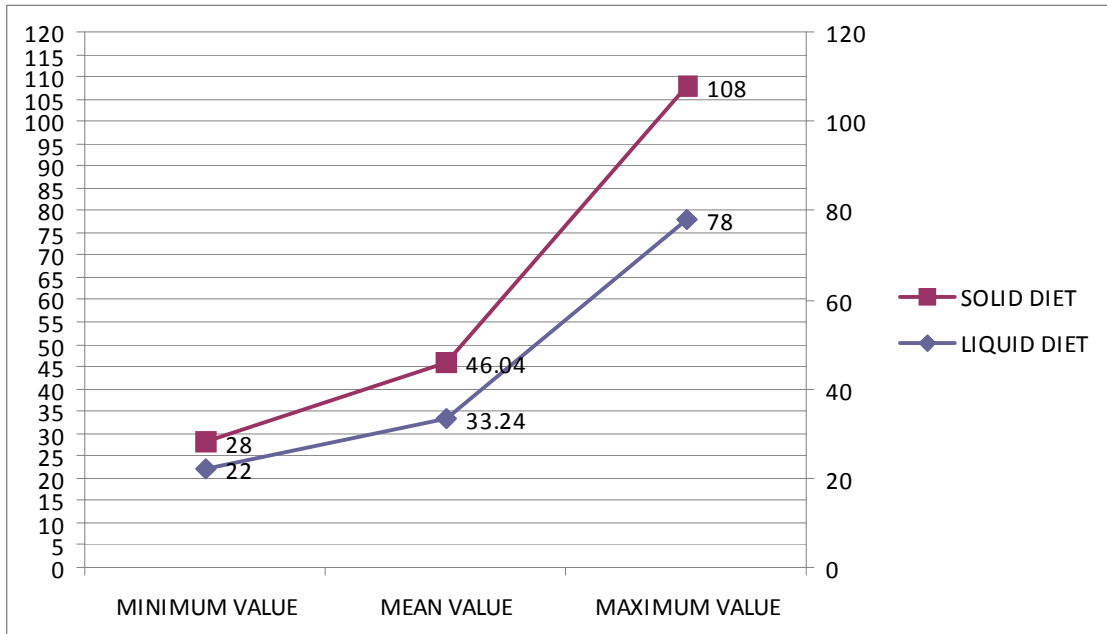


**Table 7:**

LIQUID DIET IN L.A		SOLID DIET IN L.A	
Hrs Range	No.	Hrs Range	No.
<20 hrs	18	<20 hrs	3
20-30 hrs	20	20-30 hrs	26
30-40 hrs	12	30-40 hrs	5
>/=40 hrs	0	>/=40 hrs	6

**O.A:**

**Chart 9:**

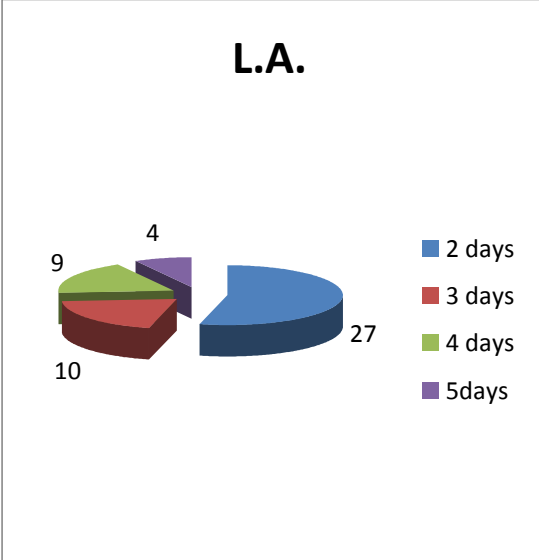


**Table 8:**

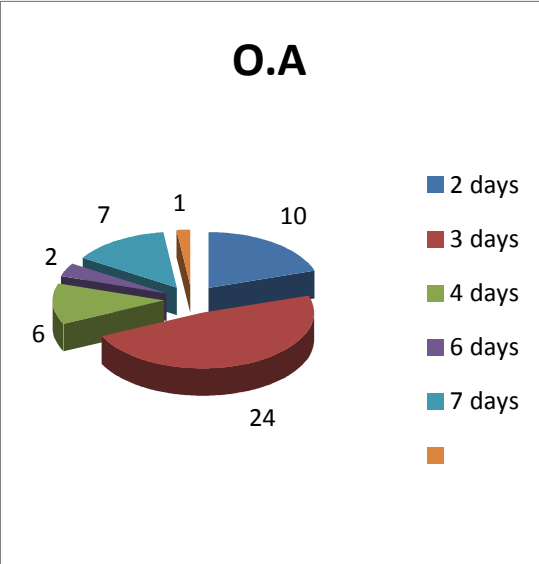
LIQUID DIET IN O.A		SOLID DIET IN O.A	
Hrs Range	No.	Hrs Range	No.
20-40 hrs	41	20-40 hrs	34
40-60 hrs	4	40-60 hrs	7
60-80 hrs	5	60-80 hrs	2
80-100 hrs	0	80-100 hrs	5
>100 hrs	0	> 100 hrs	2

**LENGTH OF STAY IN HOSPITAL IN DAYS :**

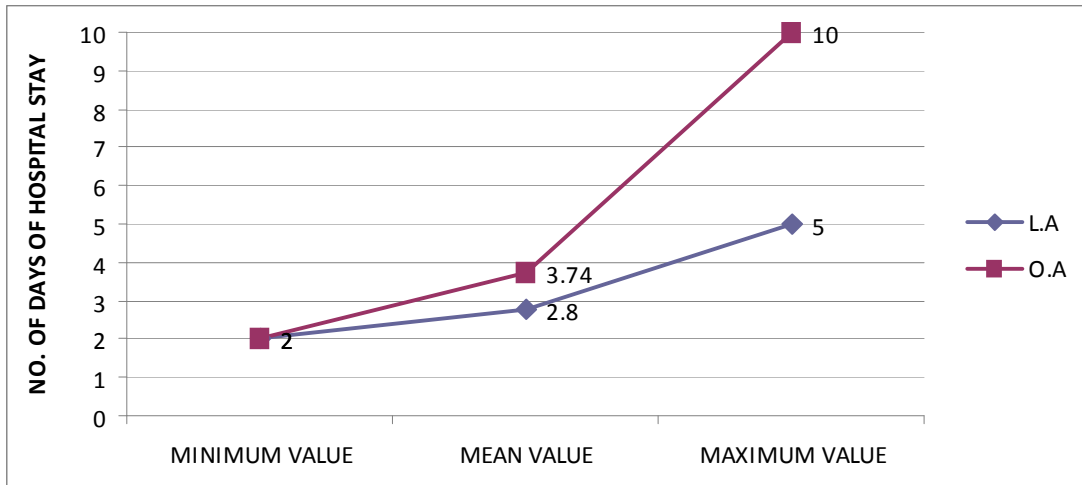
**Chart 10a:**



**Chart 10b:**



**Chart 10c:**



**Table 9:**

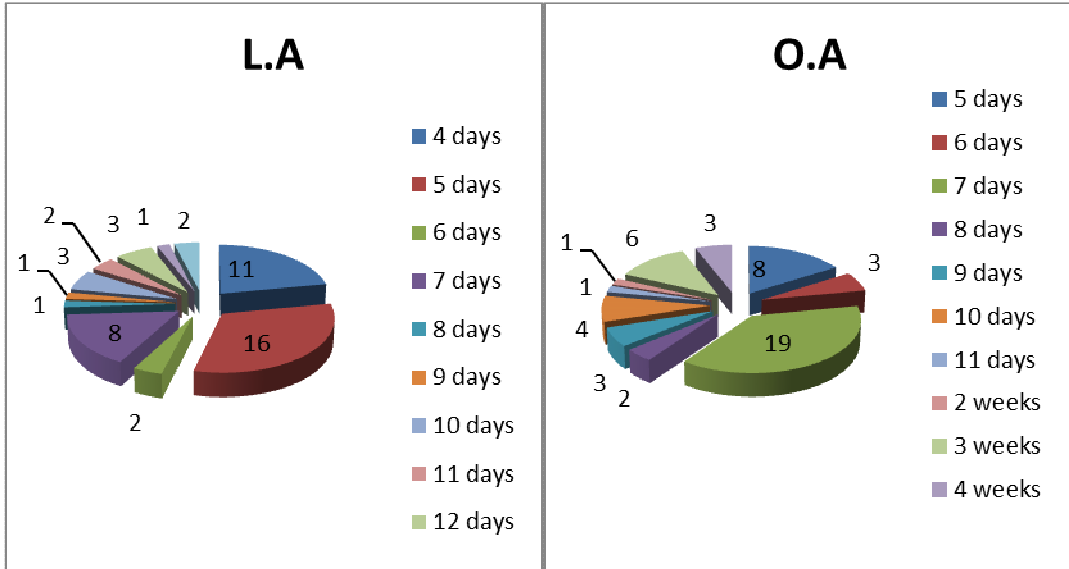
LAPAROSCOPIC APPENDECTOMY		OPEN APPENDECTOMY	
DAYS	PERCENTAGE	DAYS	PERCENTAGE
2	54%	2	20%
3	20%	3	48%
4	18%	4	12%
5	8%	6	4%
		7	14%
		10	2%



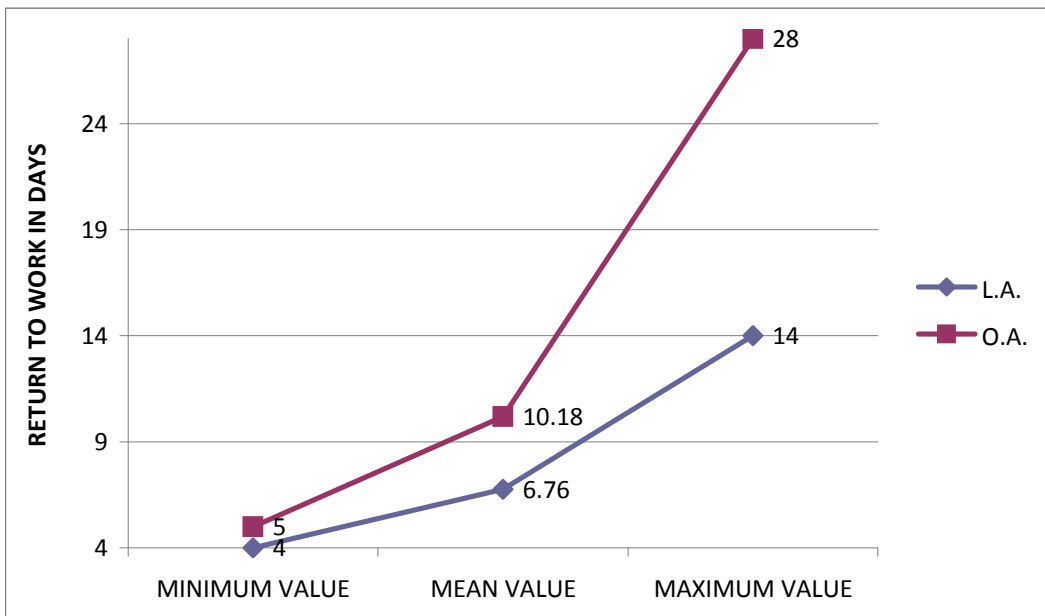
## RETURN TO WORK IN DAYS :

**Chart 11a:**

**Chart 11b:**



**Chart 11c:**



**Table 10:**

<b>LAPAROSCOPIC APPENDECTOMY</b>		<b>OPEN APPENDECTOMY</b>	
<b>WEEKS</b>	<b>PERCENTAGE</b>	<b>WEEKS</b>	<b>PERCENTAGE</b>
<1 wk	58%	<1wk	22%
1-2wks	38%	1-2wks	
2-3wks	4%	2-3wks	
>3wks	0%	>3wks	

## STATISTICAL ANALYSIS

**Table 11:**

	<b>Proc- edure</b>	<b>N</b>	<b>Mean</b>	<b>Std. Deviation</b>	<b>Std. Error Mean</b>	<b>P value</b>
TIME (in mins)	Open	50	42.82	19.409	2.745	< 0.001
	LAP	50	71.38	15.270	2.160	
ANALGESIC (P) NO.	Open	50	3.58	1.949	.276	0.002
	LAP	50	2.58	.992	.140	
ANALGESIC (O) NO.	Open	50	5.22	1.595	.225	<0.001
	LAP	50	3.18	1.190	.168	
BOWEL FN(at the hr postop.)	Open	50	30.54	14.214	2.010	<0.001
	LAP	50	20.48	5.654	.800	
DIET POP (L) hrs	Open	50	33.24	14.952	2.115	<0.001
	LAP	50	22.94	6.435	.910	
DIET POP (S) hrs	Open	50	46.04	21.946	3.104	<0.001
	LAP	50	26.54	7.789	1.101	
LENGTH OF STAY days	Open	50	3.74	1.850	.262	0.002
	LAP	50	2.80	1.010	.143	
RETURN TO WORK days	Open	50	10.18	6.614	.935	0.001
	LAP	50	6.76	2.980	.421	

## **DISCUSSION**

In the open (O.A.) and laparoscopic appendectomy (L.A.) groups, with 50 patients in each group, the age distribution between the groups was such that majority 19 of the 50 pts in the L.A. were between 20 and 30 yrs of age while the majority of patients in the O.A. group were also among the 20 and 30 yrs of a age group.

The gender distribution between the groups was that in L.A., 40% were males and 60% were females, while in the O.A., 50% of patients were males and the other 50% of patients were females.

The pathology report was acute appendicitis as the majority in both the groups with 76% in L.A. and 80% in O.A., while the incidence of other pathologies like gangrenous appendicitis and appendicular perforation were similar in both the groups 10% - L.A. & 8% -O.A and 10%-L.A. & 12% -O.A. respectively. The incidence of appendicular abscess in patients taken for both the procedures was negligible with 4% in L.A and none in the O.A group.

The operating time considered in minutes from skin to skin as noted in the procedures were on an average of 71 minutes (55–108 mins) in the laparoscopic appendectomy group while the average time taken for

the open appendectomy procedure was 43 minutes (23-98 mins). Thus mean time difference between both the procedures was around half an hour earlier with open than with the laparoscopic appendectomy.

In the postoperative period, the requirements of analgesic doses was significantly higher for the open procedure compared to the laparoscopic approach being average 5 doses for the open procedure and 3 doses for the laparoscopic procedure in terms of oral analgesic doses and average of 3 to 4 doses for the open procedure in parenteral analgesics compared to 2 to 3 doses for the laparoscopic procedure, with a minimum of 2 parenteral doses for both the procedures to a maximum of 8 doses for the open approach and single dose of oral analgesics in some cases of L.A to 10 doses in O.A

The return of bowel functions was on average 20 hours postoperatively after laparoscopic appendectomy while it took on an average of 30 hours for the bowel functions to return to normal in the open appendectomy patients postoperatively. This signifies a 10 hourly difference in the time of return of bowel functions between the 2 procedures. The majority of patients in the L.A. group moved their bowels around 16 to 18 hours while the majority in the O.A. group moved their bowels around 22 to 25 hours.

Regarding the wound infection rates with the two procedures, open appendectomy was associated with increased wound infection rates of around 36% of open appendectomy patients and only 6% in the laparoscopic appendectomy patients.

The intra-abdominal abscess rates however were more in the laparoscopic group with 20% incidence while only 12% in the open appendectomy groups.

The resumption of the diet in both groups were such that the liquids were started within 20 hours in the laparoscopic group while in the open group the majority was started with liquids more than 20 hours to 40 hours. The solids were started within 3 to 5 hours of starting on liquid diet in both the groups.

The length of hospital stay in the laparoscopic group was in the majority 54% patients within 2 days while in the open group it was 3 days in majority 48% of the patients. This signifies a difference of more than one day of additional stay in the hospital for the open appendectomy patients.

The laparoscopic appendectomy group, 32% patients were able to return to work within 5 days of the surgery while in the open group 38%

patients took around a week to return to work. On an average, it took 7 days for the laparoscopic group to return to work while 10 days for the open appendectomy group of patients.

The conversion from laparoscopy to open appendectomy was 6% due to complications such as one for gangrenous appendicitis and two cases of perforated appendicitis due to intraoperative difficulties mainly the mobilization and delineation of the appendix and in one case for intractable bleeding needing conversion to open procedure.

In the study SAUERLAND, 1998, among 2877 patients OR time and intra-abdominal infections were more with L.A. than O.A, while wound infections, postoperative pain, length of stay were lesser, return to activity was earlier in L.A than O.A.

In two more studies by CHUNG, 1999 and by GARBUTT, 1999, a similar outcome as that of the SAUERLAND, 1998 study was seen except that the length of hospital stay was similar in both the groups

In another study GOLUB, 1998, all parameters like wound infections, pain (postoperative), length of stay was lesser, and return to activity was earlier in L.A compared to O.A while the intra-abdominal infections and operating time longer with L.A.

The data analysis from our study thus signifies the following :

1. The use of postoperative analgesia in terms of parenteral and oral dosages of standard analgesics showed a significant decrease in the need for dosage between the two groups with laparoscopy requiring lesser dosages of both modes of analgesics
2. The return of bowel functions showed significant difference with bowel sounds returning earlier in the lap group compared to the open appendectomy.
3. The resumption of diet first liquid and then solids as tolerated by the patient showed significant difference in that the start of diet and tolerating feeds was earlier in the laparoscopic group.
4. The length of hospital stay was by 1 to 2 days lesser with the laparoscopic appendectomy compared to the open appendectomy
5. The return to work in the laparoscopic group was by 2 to 3 days average earlier than the open appendectomy patients.



## CONCLUSION

To conclude, the use of minimal access surgery in appendicitis significantly reduces the morbidity than with the open approach. The use of laparoscopy for the management of appendicitis has significantly increased the diagnosis of other pathologies mimicking acute appendicitis particularly in the young female patients with co-existent or masquerading gynaecological pathology. This has also led to the decrease in the rate of the negative appendectomy.

The use of laparoscopy in all patients has reduced the postoperative morbidity in terms of

- Postoperative Pain
- The use of pain medications
- The return of bowel functions
- The time to ambulation
- The resumption of normal diet
- The length of hospital stay
- The return to normal work

The rate of conversion of laparoscopy to open procedure however significantly increases the morbidity but no less than that of the open

procedure. The need for conversion is determined by the intra-operative factors like inability to trace a retro-caecal or highly placed appendicitis with adhesions hindering the mobilization or intractable bleeding consequent to the dissection and hindrance to visualization caused by the bleeding.

The complications in terms of the wound infection was significant with that of the open appendectomy due to the contact of the inflamed appendix and the infected fluid all through the layers while that of the intra-abdominal abscess occurring following appendectomy was more with the laparoscopic group compared to open due to an increase in the area of exposure of the specimen and inadvertent spillage of fecal contents into the pelvis or the paracolic gutter during accrual of the specimen after the procedure. This can in fact be reduced with the careful retrieval of the specimen without spillage and to provide adequate irrigation and suction in cases of spillage or bleeding or early abscess formation.

The operating time between the two procedures showed a significant difference of more time being taken for the laparoscopic group than the open group. This is probably due to the novel nature of the laparoscopic procedure and the learning curve associated with the

technique compared to the versatile and high level of experience in performing open appendectomy even with the junior resident surgeons. However the increase in operating time is compensated for by the reduced postoperative morbidity, recovery and hospital stay in the patients undergoing laparoscopic appendectomy.

Our study thus demonstrates a considerable and statistically significant difference ( $p < 0.001$ ) in almost all parameters and better outcome with the laparoscopic appendectomy compared to the open appendectomy in terms of clinical outcomes considered postoperatively particularly the patient benefits with regard to the morbidity and return to normal activity and quality of life at the earliest.

There is however a need for a comparative analysis between the two procedures with randomization and stringent selection criteria with blinding for a definitive proof of difference and superiority of one procedure over the other and to make laparoscopic appendectomy the standard surgery for appendicitis like laparoscopic cholecystectomy which has been proven to be the standard surgical treatment for cholecystitis and cholelithiasis.

## MASTER CHART

S.NO.	NAME	AGE	SEX	IP.NO.	PROCE DURE	NATURE	TIME (in mins)	PATHOLOGY	PAIN- analgesic dose	BOWEL FN (at the hr postop.)	DIET (postopd ay)	LENGTH OF STAY	WOUND INFECTION	INTRA- ABD. ABSCESS	RETURN TO WORK
1	THANYA	13	F	953145	LAP	UNCOMPLICATED	80	ACUTE	P-2;O-3	20	L-22;S-2	3	N	N	5
2	PRIYANKA	13	F	956961	LAP	COMPLICATED	88	PERFORATION	P-5;O-3	29	L-32;S-3	4	N	Y	5
3	NISHA BEGUM	13	F	106992	LAP	UNCOMPLICATED	61	ACUTE	P-2;O-3	16	L-18;S-2	2	N	Y	6
4	RAJASHREE	14	F	950042	LAP	COMPLICATED	100	PERFORATION	P-4;O-4	28	L-30;S-2	4	N	Y	10
5	SHARMILA	16	F	965226	LAP	UNCOMPLICATED	59	ACUTE	P-2;O-2	17	L-19;S-2	2	N	N	5
6	PAVITHRA	18	F	970010	LAP	UNCOMPLICATED	63	ACUTE	P-2;O-4	16	L-18;S-1	3	N	Y	8
7	VINODHA	18	F	974257	LAP	COMPLICATED	108	GANGRENE	P-5;O-4	33	L-38;S-4	4	N	N	12
8	SUNITHA	18	F	989754	LAP	UNCOMPLICATED	59	ACUTE	P-2;O-5	16	L-17;S-1	2	N	N	5
9	KOKILA	20	F	948779	LAP	UNCOMPLICATED	62	ACUTE	P-2;O-2	16	L-20;S-2	2	N	N	5
10	LAKSHMI	21	F	993992	LAP	UNCOMPLICATED	61	ACUTE	P-2;O-2	18	L-18;S-2	2	N	N	4
11	POONGAVANAM	22	F	965473	LAP	UNCOMPLICATED	67	ACUTE	P-2;O-4	18	L-20;S-2	2	N	Y	5
12	PREMALATHA	22	F	105340	LAP	COMPLICATED	93	ABSCESS	P-4;O-5	30	L-32;S-3	4	Y	Y	12
13	KASIAMMAL	25	F	988764	LAP	UNCOMPLICATED	62	ACUTE	P-2;O-3	17	L-19;S-2	2	N	N	4
14	MURUGESHWARI	25	F	965771	LAP TO OPEN	COMPLICATED	98	PERFORATION	P-5;O-3	29	L-32;S-3	5	N	N	14
15	FARIDA BEGUM	26	F	100801	LAP	UNCOMPLICATED	62	ACUTE	P-2;O-2	17	L-20;S-2	2	N	N	4
16	KALAIVANI	26	F	102405	LAP	COMPLICATED	99	GANGRENE	P-4;O-4	29	L-32;S-3	4	N	N	11
17	FATHIMA BEE	28	F	972197	LAP	UNCOMPLICATED	60	ACUTE	P-2;O-3	16	L-18;S-2	2	N	N	4
18	PARIMALA	29	F	948362	LAP	UNCOMPLICATED	60	ACUTE	P-2;O-2	18	L-20;S-2	2	N	N	5
19	SRIDEVI	30	F	954302	LAP	COMPLICATED	105	GANGRENE	P-4;O-4	29	L-32;S-4	5	Y	N	11
20	SATHYA	30	F	967389	LAP	UNCOMPLICATED	65	ACUTE	P-2;O-2	18	L-20;S-2	2	N	N	5
21	ANITHA	30	F	109428	LAP	UNCOMPLICATED	60	ACUTE	P-2;O-2	17	L-19;S-2	2	N	N	4
22	NIRMALADEVI	31	F	976125	LAP	COMPLICATED	97	PERFORATION	P-4;O-6	28	L-32;S-3	4	Y	N	13
23	NEELA	35	F	967483	LAP	UNCOMPLICATED	62	ACUTE	P-2;O-2	17	L-19;S-2	2	N	N	4
24	MAHESHWARI	35	F	994472	LAP	UNCOMPLICATED	63	ACUTE	P-2;O-3	18	L-20;S-2	2	N	N	5
25	KAMALADEVI	40	F	957918	LAP	UNCOMPLICATED	75	ACUTE	P-2;O-4	18	L-20;S-2	2	N	N	4
26	AMEENA	45	F	957371	LAP TO OPEN	COMPLICATED	95	ABSCESS	P-4;O-4	32	L-38;S-4	4	N	Y	10
27	INDIRA	47	F	108413	LAP	COMPLICATED	90	PERFORATION	P-4;O-5	32	L-36;S-4	5	N	Y	14
28	MOHINA	50	F	103721	LAP	UNCOMPLICATED	62	ACUTE	P-2;O-2	16	L-16;S-1	2	N	N	4
29	VANITHA	56	F	103913	LAP	UNCOMPLICATED	62	ACUTE	P-2;O-2	17	L-20;S-2	2	N	N	4
30	MEHRUNISHA	65	F	978080	LAP	UNCOMPLICATED	57	ACUTE	P-2;O-4	18	L-20;S-2	3	N	N	7
31	THIRUVENKATAM	13	M	955127	LAP	UNCOMPLICATED	63	ACUTE	P-2;O-4	17	L-20;S-2	4	N	N	10
32	DHARMASEKHAR	14	M	950039	LAP	UNCOMPLICATED	70	ACUTE	P-3;O-1	18	L-22;S-2	2	N	N	7
33	SHIVA	16	M	951875	LAP	UNCOMPLICATED	55	ACUTE	P-2;O-2	16	L-18;S-2	2	N	N	5
34	KAMALESH	18	M	962665	LAP	UNCOMPLICATED	55	ACUTE	P-2;O-2	19	L-21;S-2	2	N	N	4
35	SANTHOSHKUMAR	19	M	948366	LAP	UNCOMPLICATED	65	ACUTE	P-2;O-2	16	L-18;S-2	3	N	N	5
36	PRAVEENKUMAR	19	M	955617	LAP	UNCOMPLICATED	69	ACUTE	P-2;O-3	19	L-23;S-2	2	N	N	5
37	DEEPAK	20	M	951580	LAP	UNCOMPLICATED	65	ACUTE	P-2;O-4	18	L-20;S-2	3	N	N	7
38	KUMAR	21	M	960360	LAP	UNCOMPLICATED	58	ACUTE	P-3;O-3	18	L-20;S-2	3	N	N	7

39	SYED INAYADHULLA	23	M	948623	LAP	UNCOMPLICATED	66	ACUTE	P-2;O-2	17	L-19;S-2	2	N	N	7
40	KARTHICK	24	M	974070	LAP	UNCOMPLICATED	68	ACUTE	P-2;O-3	20	L-22;S-2	3	N	N	9
41	SARAVANAN	24	M	105742	LAP	UNCOMPLICATED	72	ACUTE	P-2;O-4	18	L-20;S-2	2	N	N	5
42	KALIMUTHU	26	M	107829	LAP	UNCOMPLICATED	63	ACUTE	P-2;O-2	19	L-22;S-2	3	N	N	7
43	NARAYANAN	27	M	998821	LAP TO OPEN	COMPLICATED	96	GANGRENE	P-4;O-5	31	L-35;S-4	5	N	y	12
44	PALANI	30	M	103874	LAP	UNCOMPLICATED	59	ACUTE	P-2;O-2	18	L-18;S-2	2	N	N	4
45	SHAHUL AHMED	32	M	103021	LAP	UNCOMPLICATED	64	ACUTE	P-2;O-3	17	L-19;S-2	2	N	N	5
46	GNANASEKAR	34	M	975311	LAP	UNCOMPLICATED	59	ACUTE	P-2;O-2	17	L-19;S-2	2	N	N	6
47	AROKYASAMY	40	M	954714	LAP	UNCOMPLICATED	70	ACUTE	P-2;O-4	19	L-23;S-2	3	N	N	7
48	SIVA	45	M	948943	LAP	UNCOMPLICATED	64	ACUTE	P-2;O-2	15	L-16;S-2	3	N	N	5
49	SARAVANAPRAKASH	50	M	106796	LAP	UNCOMPLICATED	63	ACUTE	P-2;O-4	17	L-19;S-2	2	N	N	5
50	KANNADASAN	53	M	966795	LAP	COMPLICATED	90	GANGRENE	P-4;O-4	32	L-36;S-4	4	N	y	7

S.NO	NAME	AGE	SEX	IP.NO.	PROCEDURE	NATURE	TIME (in mins)	PATHOLOGY	PAIN- analgesic dose	BOWEL FN (at the hr postop.)	DIET (postop hrs)	LENGTH OF STAY	WOUND INFECTION	INTRA-ABD. ABSCESS	RETURN TO WORK
1	INDUMATHI	20	F	976358	OPEN	UNCOMPLICATEI	35	ACUTE	P-4;O-4	22	L-24;S-29	3	N	N	7
2	SAMSUJINISHA	14	F	976465	OPEN	UNCOMPLICATEI	32	ACUTE	P-3;O-4	22	L-24;S-28	2	N	N	5
3	MANJU	30	F	976850	OPEN	UNCOMPLICATEI	34	ACUTE	P-2;O-5	23	L-25;S-30	3	Y	N	7
4	BHAVANI	16	F	977077	OPEN	UNCOMPLICATEI	40	ACUTE	P-4;O-4	23	L-26;S-33	3	N	N	7
5	SELVI	30	F	977116	OPEN	UNCOMPLICATEI	40	ACUTE	P-3;O-5	23	L-25;S-37	2	N	N	5
6	SUMATHI	31	F	977091	OPEN	UNCOMPLICATEI	35	ACUTE	P-2;O-5	24	L-26;S-38	3	N	N	5
7	KALA	35	F	973333	OPEN	UNCOMPLICATEI	38	ACUTE	P-2;O-6	22	L-24;S-34	4	N	N	8
8	VENDAMANI	42	F	973449	OPEN	UNCOMPLICATEI	45	ACUTE	P-3;O-4	23	L-25;S-36	3	N	N	7
9	VIJAYA	35	F	978757	OPEN	UNCOMPLICATEI	43	ACUTE	P-2;O-6	22	L-25;S-38	3	Y	N	7
10	MAHESHWARI	16	F	978968	OPEN	UNCOMPLICATEI	28	ACUTE	P-3;O-5	20	L-24;S-31	3	Y	N	7
11	PRIYA	20	F	978994	OPEN	UNCOMPLICATEI	32	ACUTE	P-2;O-6	25	L-27;S-36	2	Y	N	5
12	SUJATHA	26	F	979280	OPEN	UNCOMPLICATEI	33	ACUTE	P-4;O-3	25	L-28;S-38	2	N	N	6
13	KARTHIGA	13	F	979417	OPEN	UNCOMPLICATEI	29	ACUTE	P-4;O-2	22	L-25;S-35	2	N	N	6
14	MOHANA	32	F	981733	OPEN	UNCOMPLICATEI	35	ACUTE	P-2;O-6	26	L-28;S-39	4	N	N	10
15	MALLIGA	38	F	983178	OPEN	UNCOMPLICATEI	48	ACUTE	P-5;O-6	22	L-24;S-36	3	N	N	10
16	LOGANAYAKI	63	F	984541	OPEN	UNCOMPLICATEI	44	ACUTE	P-3;O-3	24	L-26;S-37	3	N	N	7
17	RAMANI	36	F	984607	OPEN	UNCOMPLICATEI	34	ACUTE	P-2;O-3	25	L-27;S-34	3	N	N	7
18	VELANKANNI	55	F	986613	OPEN	UNCOMPLICATEI	45	ACUTE	P-2;O-8	22	L-25;S-32	4	N	N	9
19	DEVI	65	F	986899	OPEN/LAPAROTOMY	COMPLICATED	98	PERFORATION	P-8;O-10	68	L-72;S-98	6	Y	N	14
20	NANDHINI	21	F	987409	OPEN	UNCOMPLICATEI	31	ACUTE	P-2;O-8	20	L-22;S-32	3	Y	N	9
21	LAKSHMI	34	F	987555	OPEN	UNCOMPLICATEI	39	ACUTE	P-4;O-4	26	L-28;S-39	3	Y	N	7
22	ANANDHI	25	F	987515	OPEN	UNCOMPLICATEI	33	ACUTE	P-4;O-4	25	L-27;S-34	3	N	N	7
23	INDUMATHI	15	F	987572	OPEN	UNCOMPLICATEI	29	ACUTE	P-3;O-5	22	L-24;S-32	2	N	N	5
24	JEEVITHA	17	F	987813	OPEN	UNCOMPLICATEI	28	ACUTE	P-2;O-6	26	L-28;S-36	2	N	N	5
25	THYIAGARAJAN	21	M	976364	OPEN	COMPLICATED	60	PERFORATION	P-6;O-6	32	L-36;S-48	7	Y	Y	21
26	RAMARAJ	22	M	976432	OPEN	UNCOMPLICATEI	42	ACUTE	P-2;O-6	24	L-25;S-32	3	N	N	7
27	VINODKUMAR	17	M	977052	OPEN	UNCOMPLICATEI	30	ACUTE	P-2;O-6	25	L-28;S-34	3	Y	N	7
28	SETHURAMAN	23	M	973337	OPEN	UNCOMPLICATEI	25	ACUTE	P-4;O-4	23	L-24;S-32	4	N	N	10
29	VEERAPPAN	46	M	979406	OPEN	UNCOMPLICATEI	35	ACUTE	P-2;O-5	27	L-29;S-39	2	Y	N	5
30	SHEIK FERAZ	30	M	979607	OPEN/DRAINAGE	COMPLICATED	65	GANGRENE	P-8;O-6	44	L-48;S-62	6	Y	N	21
31	SADIK HUSSAIN	13	M	980878	OPEN/LAPAROTOMY	COMPLICATED	90	PERFORATION	P-7;O-6	46	L-50;S-86	10	N	Y	28
32	ANAND	25	M	981175	OPEN	UNCOMPLICATEI	38	ACUTE	P-2;O-5	26	L-30;S-48	4	Y	N	10
33	KANNIAPPAN	16	M	981283	OPEN	UNCOMPLICATEI	30	ACUTE	P-4;O-3	27	L-29;S-45	3	N	N	7

34	LOGANATHAN	35	M	981265	OPEN	UNCOMPLICATED	45	ACUTE	P-2;O-6	33	L-36;S-45	3	N	N	7
35	RAJAMANIKAM	25	M	981278	OPEN	UNCOMPLICATED	43	ACUTE	P-2;O-5	30	L-32;S-36	3	N	N	6
36	MAJNU	25	M	981394	OPEN/LAPAROTOMY	COMPLICATED	85	GANGRENE	P-6;O-8	45	L-48;S-96	7	N	Y	28
37	MUTHUKUMAR	29	M	981792	OPEN	UNCOMPLICATED	34	ACUTE	P-3;O-4	24	L-28;S-38	3	N	Y	8
38	RAJKISHORE SHAR	28	M	983123	OPEN	UNCOMPLICATED	33	ACUTE	P-2;O-5	25	L-26;S-35	3	N	Y	9
39	DESINGH	27	M	983891	OPEN	UNCOMPLICATED	38	ACUTE	P-3;O-4	22	L-24;S-32	2	Y	N	5
40	KARTHIK	17	M	984502	OPEN	UNCOMPLICATED	23	ACUTE	P-2;O-4	26	L-29;S-42	3	Y	N	7
41	CHELLADURAI	25	M	984486	OPEN	UNCOMPLICATED	26	ACUTE	P-2;O-4	26	L-28;S-40	2	N	N	7
42	RAMAKRISHNAN	50	M	984643	OPEN/LAPAROTOMY	COMPLICATED	92	PERFORATION	P-8;O-8	68	L-72;S-105	7	Y	N	21
43	SABARINATHAN	21	M	984769	OPEN/LAPAROTOMY	COMPLICATED	88	PERFORATION	P-7;O-6	69	L-72;S-88	7	Y	Y	21
44	SIVAPRABHU	22	M	985321	OPEN	UNCOMPLICATED	35	ACUTE	P-2;O-5	25	L-27;S-35	4	N	N	11
45	DHARMAN	30	M	985941	OPEN	UNCOMPLICATED	33	ACUTE	P-4;O-4	24	L-28;S-39	3	N	N	7
46	AJITHKUMAR	17	M	986012	OPEN	UNCOMPLICATED	28	ACUTE	P-2;O-4	25	L-29;S-43	3	N	N	7
47	VIJAYASHANKAR	34	M	986210	OPEN/LAPAROTOMY	COMPLICATED	87	GANGRENE	P-8;O-7	72	L-78;S-108	7	Y	Y	28
48	PARTHASARATHY	21	M	986934	OPEN	UNCOMPLICATED	35	ACUTE	P-2;O-4	26	L-27;S-36	3	N	N	7
49	SHANKAR	32	M	987030	OPEN/DRAINAGE	COMPLICATED	48	GANGRENE	P-6;O-6	66	L-72;S-88	7	N	N	21
50	ABDUL REHMAN	28	M	987837	OPEN	COMPLICATED	25	PERFORATION	P-6;O-8	45	L-48;S-78	7	Y	Y	21

Originality GradelMark PeerMark

### LAPAROSCOPIC vs OPEN APPENDECTOMY

BY MADHU 22101111 M.S. GENERAL SURGERY



16%  
SIMILAR

--  
OUT OF 0

**THE TAMILNADU DR.M.G.R. MEDICAL UNIVERSITY**  
**KILPAUK MEDICAL COLLEGE**

STUDY ON LAPAROSCOPIC vs. OPEN  
APPENDECTOMY –  
A PROSPECTIVE COMPARATIVE CASE SERIES.

**A THESIS IN GENERAL SURGERY**

by

**Dr. D. MADHU**

#### Match Overview

1	<a href="http://www.ptolemy.ca">www.ptolemy.ca</a> Internet source	9%
2	<a href="http://www.freerepublic.com">www.freerepublic.com</a> Internet source	3%
3	<a href="http://fsurgery.dsmu.edu.ua">fsurgery.dsmu.edu.ua</a> Internet source	<1%
4	<a href="http://www.theplatoon.com">www.theplatoon.com</a> Internet source	<1%
5	<a href="http://www.pubmedcentral.nih.g">www.pubmedcentral.nih.g</a> Internet source	<1%
6	<a href="http://www.paperwritings.com">www.paperwritings.com</a> Internet source	<1%
7	Devarajan, S.. "Abdomi... Publication	<1%
8	Kingsley Agholor. "Rat... Publication	<1%