

# **ROLE OF EMERGENCY GASTRO INTESTINAL OSTOMIES IN PRESENT SCENARIO**

Dissertation submitted to

**THE TAMIL NADU  
DR. M.G.R. MEDICAL UNIVERSITY  
CHENNAI 600 032**

With fulfillment of the Regulations  
For the Award of the Degree of

**M.S. GENERAL SURGERY  
(BRANCH I)**



DEPARTMENT OF SURGERY  
GOVERNMENT KILPAUK MEDICAL COLLEGE  
CHENNAI 600 010

**MARCH 2009**

## **CERTIFICATE**

This is to certify that this dissertation in “**ROLE OF EMERGENCY GASTRO INTESTINAL OSTOMIES IN PRESENT SCENARIO**” is a work done by **Dr. V.T. SATHISH**, under my guidance during the period 2006-2008. This has been submitted in partial fulfillment of the award of M.S. Degree in General Surgery (Branch-I) by the Tamilnadu Dr. M.G.R. Medical University, Chennai 600 032.

**PROF. DR. G. GUNASEELAN,M.S.,  
PROFESSOR AND HEAD OF THE DEPARTMENT  
DEPARTMENT OF SURGERY  
GOVERNMENT KILPAUK MEDICAL COLLEGE  
CHENNAI**

**PROF. DR. S. JEYAKUMAR,M.S.,  
PROFESSOR AND UNIT CHIEF  
DEPARTMENT OF SURGERY  
GOVERNMENT ROYAPETTAH HOSPITAL  
GOVERNMENT KILPAUK MEDICAL COLLEGE  
CHENNAI**

**THE DEAN  
PROF. DR. M. DHANAPAL, M.D., D.M.,  
GOVERNMENT KILPAUK MEDICAL COLLEGE AND HOSPITAL  
CHENNAI 600 010**

## **ACKNOWLEDGEMENT**

I thank the DEAN of Kilpauk Medical College and Hospital, **Prof. Dr. M. DHANAPAL, M.D., D.M., (Cardiology)** for permitting me to conduct this study in the Department of General Surgery of the Government Kilpauk Medical College and Hospital, Chennai.

I thank **Prof. Dr. G. GUNASEELAN, M.S.**, Head of Department of General Surgery for helping and guiding me during the study.

My heartfelt gratitude to **Prof. Dr. S.JEYAKUMAR, M.S.**, for his esteemed guidance and valuable suggestions. It is my privileged duty to profusely thank my teacher, guide and mentor under whom I have the great honor to work as a postgraduate student.

I am greatly indebted to my Unit Assistant Professors **Dr.K.RAJENDRAN, M.S.(General Surgery), D.ORTHO.**, surgical registrar, **Dr.P.MADHIVADANAM, M.S.(General Surgery), D.L.O.**, who have put in countless hours in guiding me in many aspects of this study and also in honing my surgical skills.

Last but not the least, my heartfelt gratitude to my patients without whom this study could not have been possible and also to Medical Records Department of Government Royapettah Hospital for their timely help.

# **CONTENTS**

<b>INTRODUCTION</b>	<b>1</b>
<b>AIM OF STUDY</b>	<b>3</b>
<b>REVIEW OF LITERATURE</b>	
EVOLUTION OF FECAL DIVERSION	<b>4</b>
ETIOLOGY	<b>7</b>
STOMA CONSTRUCTION	<b>13</b>
STOMA MANAGEMENT & COMPLICATIONS	<b>28</b>
<b>MATERIALS AND METHODS</b>	<b>46</b>
<b>OBSERVATION</b>	<b>49</b>
<b>DISCUSSION</b>	<b>61</b>
<b>CONCLUSION</b>	<b>64</b>
<b>PROFORMA</b>	<b>65</b>
<b>BIBLIOGRAPHY</b>	<b>68</b>
<b>MASTER CHART</b>	<b>71</b>

# INTRODUCTION

## **INTRODUCTION**

Intestinal stomas are an integral part of gastrointestinal surgery. An intestinal stoma is an opening of the intestinal or urinary tract onto the abdominal wall, constructed surgically or appearing inadvertently.

A colostomy is a connection of the colon to the skin of the abdominal wall. An ileostomy involves exteriorization of the ileum on the abdominal skin. In rare instances, the proximal small bowel may be exteriorized as a jejunostomy.

Stomas may be life saving in the treatment of bowel perforation or severe sepsis. The burden of care to support and counsel these patients is considerable. Although short term support is needed for patients with temporary stoma, the impact on life is considerable.

Stomas may need to be permanent for treatment of low rectal cancer or crohn's disease.

Most stomas are temporary to protect a distal anastomosis, to bypass severe anorectal sepsis, to manage colorectal trauma or to decompress large bowel obstruction. The overall incidence of stoma construction appears to be decreasing and will probably continue to do so. There are now fewer abdominoperineal resections for cancer because of the advent of new surgical techniques, especially the use of stapling devices, as well as an increased use of local treatment for selected rectal tumours. The incidence of permanent ileostomies is decreasing because of the popularization of sphincter saving procedures for patients with ulcerative colitis and familial polyposis. The surgical procedures that eliminate permanent stomas, however, have resulted in an increasing use of temporary loop ileostomies, which are usually more difficult stomas to manage.

# AIM OF STUDY



## **AIM OF STUDY**

- To evaluate the epidemiology of emergency gastro intestinal ostomies
  
- To analyse the various etiology and commonest cause for emergency ostomies
  
- To study the various types of ostomies made
  
- To study the complications of ostomies
  
- To evaluate the morbidity and mortality of patients after ostomy.

# REVIEW OF LITERATURE

## **EVOLUTION OF FAECAL DIVERSION**

The very earliest stomas were not the result of surgical intervention, but fecal fistulas that developed spontaneously following abdominal trauma or bowel obstruction.

One surgeon in the mid 18<sup>th</sup> century noted that fistula formation was associated with survival and suggested that surgeons might take hints from nature and construct intentional openings (stomas) to manage traumatic bowel injury.

The first record of a colostomy was in 1710 by Littre for an obstructing colonic carcinoma managed by an iliac fossa stoma.

Extra peritoneal colostomy was devised by Amussat (1839) to reduce the high mortality from peritonitis, which occurred following intraperitoneal colostomy.

In 1884, Maydl revived the practice of intraperitoneal loop colostomy using a goose quill to support the stoma.

Allingham (1887) sutured the seromuscular layer of the colon to the abdominal wall to prevent retraction before opening the antimesenteric surface of the bowel. Surprisingly, immediate colocutaneous suture was not commonly practiced until later last century.

In 1897, a German surgeon reported on construction of a temporary diverting ileostomy in a patient with an obstructing malignancy of the ascending colon.

Early ileostomy stomas were typically constructed as skin level stomas and were associated with severe and painful skin breakdown.

The first major advance in ileostomy construction came in 1912, when a surgeon from St. Louis - Dr. John Brown reported on a series of 10 patients in whom he had constructed a protruding ileostomy stoma.

A persistent complication of ileostomy surgery was the condition known as ileostomy dysfunction, characterized by cramping abdominal pain and high volume ileostomy output, leading to severe fluid and electrolyte disturbances.

Warran and Mc Kittrick were the first to recognize that intestinal colic, dehydration and intermittent profuse ileostomy were the result of sepsis and obstruction because the ileum and skin were not protected.

In order to resolve this problem, Crile and Turnbull (1954) proposed that mucosal grafts should be placed on the sacrificed serosa of the ileum. Brooke (1952) resolved the problem by designing the eversion ileostomy. This technique of turning the end of ileum back over itself provided an immediate solution to problems of ileostomy stenosis and excoriated peristomal skin and has become the established method of ileostomy construction.

## **Gastro intestinal etiologies**

### **Infectious Enteritis.**

Typhoid fever is a life threatening problem, especially due to the emergence of multiresistant strains of salmonella typhi. Typhoid intestinal perforation is one of the most dreaded and common complication of typhoid fever, remarkably so in the developing countries where it usually leads to diffuse peritonitis. It was considered to be an almost fatal condition in the past and the mortality and morbidity still remains very high despite remarkable improvements in the surgical management. The current surgical options include primary double layered closure, segmental resection and end to end anastomosis and primary ileostomy.

### **Diverticular disease**

Most prevalent in developed nations. Diverticulitis occurs when diverticula become inflamed or infected. Likely cause of this infection, being

inflammatory process in stool or food particles becoming trapped in the pouches.

Diverticular disease may affect any part of the gastrointestinal tract. Diverticulum formation usually occurs in the colon, particularly the sigmoid segment where 95% to 98% of all diverticula occur. The course of diverticulitis becomes complicated and unresponsive to medical therapy with the occurrence of abscess, full perforation, fistula or obstruction.

Potential procedures include drainage of abscess with proximal diversion and creation of a Hartmann's pouch; disease segment resection and abscess drainage with proximal diversion and creation of a Hartmann's pouch, resection of the diseased bowel and colorectal anastomosis with or without a temporary diversion.

### **RADIATION ENTERITIS**

Radiation Enteritis is malfunction of the large and small bowel that arises during or after radiation therapy to the abdomen, pelvis or rectum.

Surgical treatment of extant radiation enteritis is usually associated with the manifestations of late changes. Complete or partial bowel obstructions, necrosis, strictures or perforation can occur. Most often, severe radiation enteropathy requires a bowel resection rather than a diverting ostomy. However, complete bowel obstruction may necessitate a temporary stoma.

### **ISCHEMIC COLITIS**

Ischemic colitis is an unusual condition of the bowel that results from hypoperfusion, usually seen in the elderly. The problem occurs when inadequate mesenteric blood flow causes an imbalance between metabolic demands of the colon and available oxygen, resulting in cellular injury. Although all segments of the bowel can be affected, ischemic colitis most often affects the left colon, especially the splenic flexure and sigmoid colon. Bowel perforation is the most common indication for surgery. The ischemic section of the colon is resected, including areas of dubious viability. An ileostomy or colostomy is performed. Primary anastomosis is not recommended in the acute phase, especially with colonic ischemia on the



left side. The distal segment can be matured as a mucous fistula or simply over sewn and left in the abdomen as a Hartmann's pouch. The reason for diversion is the high risk of suture dehiscence and anastomosis failure.

## **INTESTINAL OBSTRUCTION**

Intestinal obstruction is a disorder that is associated with significant morbidity and possible death. Causes of dynamic obstruction include adhesions, hernia, neoplasms, colonic polyps, intussusception, congenital anomalies, stricture, volvulus and idiopathic pseudo obstruction (Ogilvie's syndrome).

Surgical treatment of bowel obstruction is usually reserved for two situations. When the risk of perforation is strong or when bowel rupture has occurred.

If possible a bowel resection is performed to relieve the obstruction. If extensive bowel damage or ischemia is present a temporary or permanent ostomy may be necessary.

## **GASTROINTESTINAL TRAUMA**

Trauma to the GI tract generally occurs in two forms: blunt or penetrating. Blunt trauma is the most common mechanism of injury to the bowel. For blunt abdominal trauma the research suggests that delayed laprotomy (greater than 4 hours wait time) is being used appropriately, that is when GI tract damage has truly occurred or if medical management has failed.

More recent research suggests that colostomy is not always necessary except in rectal trauma. In penetrating colon trauma including injuries to the left colon, the preferred method of treatment is primary repair including resection without colostomy. Even in the situation of open pelvic fractures, colostomy may not be necessary for all patients.

## **NON GASTROINTESTINAL CAUSES FOR FECAL DIVERSION**

### **SPINAL CORD INJURY**

Intestinal obstruction frequently occurs as a complicating factor after acute spinal cord injury.

Adynamic obstruction will usually respond slowly to restoration of fluid and electrolyte balance and supportive therapy, when mechanical obstruction occurs after spinal cord injury, the treatment is almost always surgical. Fecal impaction that is severe and chronic may actually benefit from a fecal diversion.

### **OVARIAN CANCER.**

In ovarian cancer, reparative surgery on the GI tract may include removal of an impending obstruction or creation of a diversion to promote better quality of life in a palliative situation.

## **PROSTATE CANCER**

The disease process of prostate cancer or its accompanying therapy can result in the creation of a diversion.

## **STOMA CONSTRUCTION**

### **ILEOSTOMY**

The surgical construction of an ileostomy must be more precise than that for a colostomy because the content is liquid, high volume and corrosive to the peristomal skin. Therefore the stoma must be accurately located preoperatively and it must have a spigot configuration to allow an appliance to seal effectively and precisely around the stoma.

### **DETERMINATION OF ILEOSTOMY LOCATION**

The location of ileostomy should avoid any deep folds of fat, scars and bony prominences of the abdominal wall. The site is chosen by drawing

a vertical line through the umbilicus and a transverse line through the inferior margin of the umbilicus and applying a disk the size of a stoma faceplate (approximately 8 cm in diameter) to determine the location. The disk is allowed to abut on both of the lines, and the site is marked with the ink.

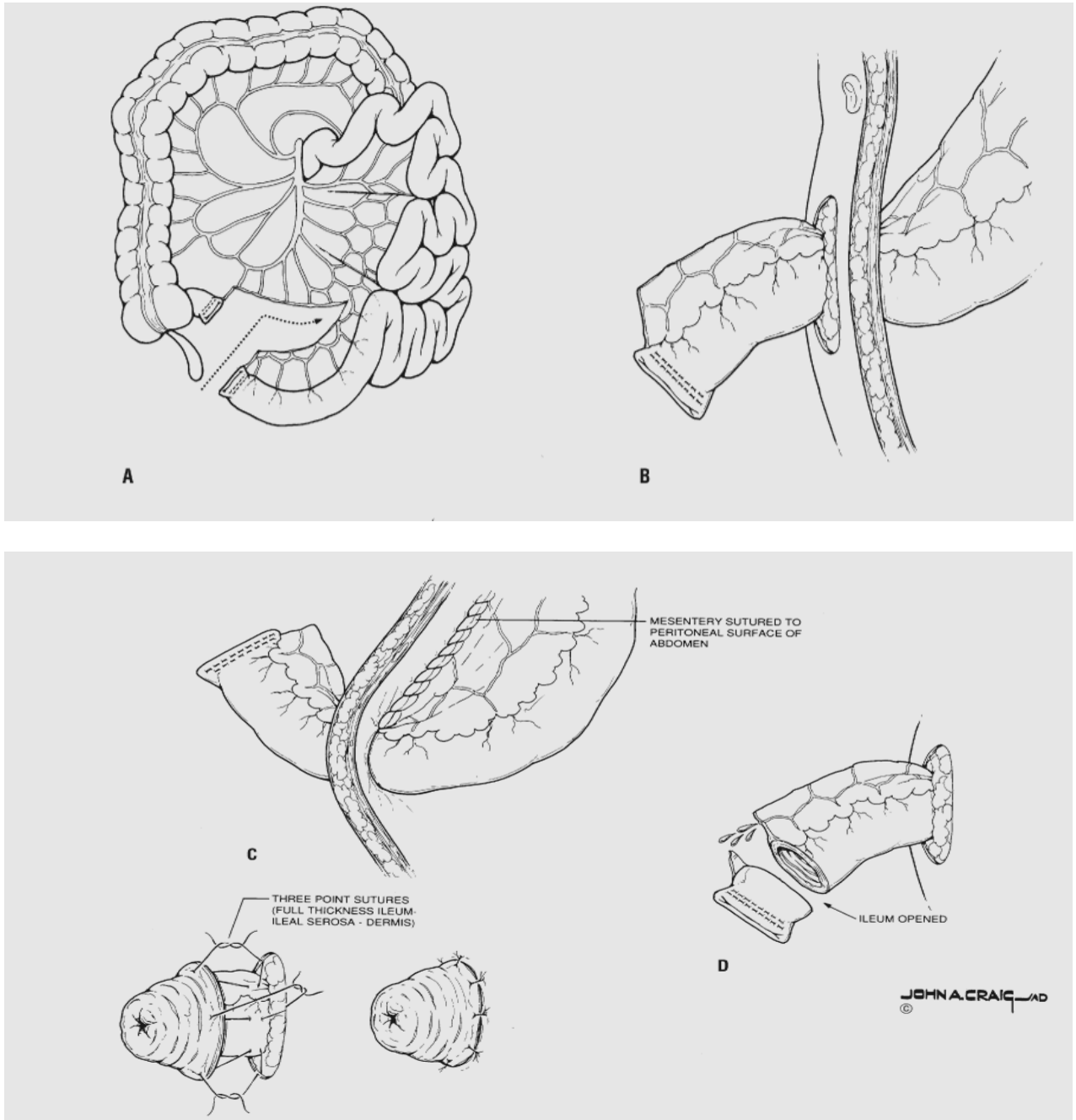
### **END ILEOSTOMY**

An end ileostomy may be used as a temporary stoma and is preferred by some over a loop ileostomy to function as an emergency measure for patients who have sustained injury or operative damage to the small or large intestine or severe sepsis.

End ileostomy used to be constructed as a permanent stoma for patients with ulcerative colitis, familial adenomatous polyposis or multiple large bowel cancer, but three decades of restorative proctocolectomy has completely changed the use of a permanent ileostomy. It is now largely confined to patients with severe Crohn's proctocolitis or after a failed pelvic pouch.

A midline laprotomy incision should be used whenever possible since this leaves both iliac fosse undisturbed if a revision procedure or reciting of the stoma is needed. The trephine is constructed by excising a circle of skin and subcutaneous fat, dividing the rectus sheath and either splitting or dividing a part of the rectus muscle before opening the peritoneum. In terminal ileum, the marginal vessels must be preserved. The space between the distal ileal arcade and the ileocaecal vessels is opened and the marginal artery is ligated opposite the proposed site of ileal transaction. In this way a 5 to 10 cm length of ileum with a good blood supply can be delivered to the abdominal wall to allow a 2 to 3 cm eversion ileostomy to be made. The ileum is pulled through the abdominal wall to a length of 6 cm. The adequacy of the blood supply is verified. The spigot configuration is achieved by placing sutures to include full thickness of intestine, the seromuscular layer at the base of the stoma and the dermis.

## Construction of an end ileostomy



**Construction of an end ileostomy.** **A.** The distal arcade of vessels and some mesentery are preserved on the segment to be used for ileostomy construction. **B.** The closed ileum is pulled through the abdominal wall to a length of 6 cm. **C.** The mesentery of the ileum is fixed to the abdominal wall. **D.** The adequacy of the blood supply is verified. **E.** The spigot configuration is achieved by placing sutures to include full thickness of intestine, the seromuscular layer at the base of the stoma, and the dermis.

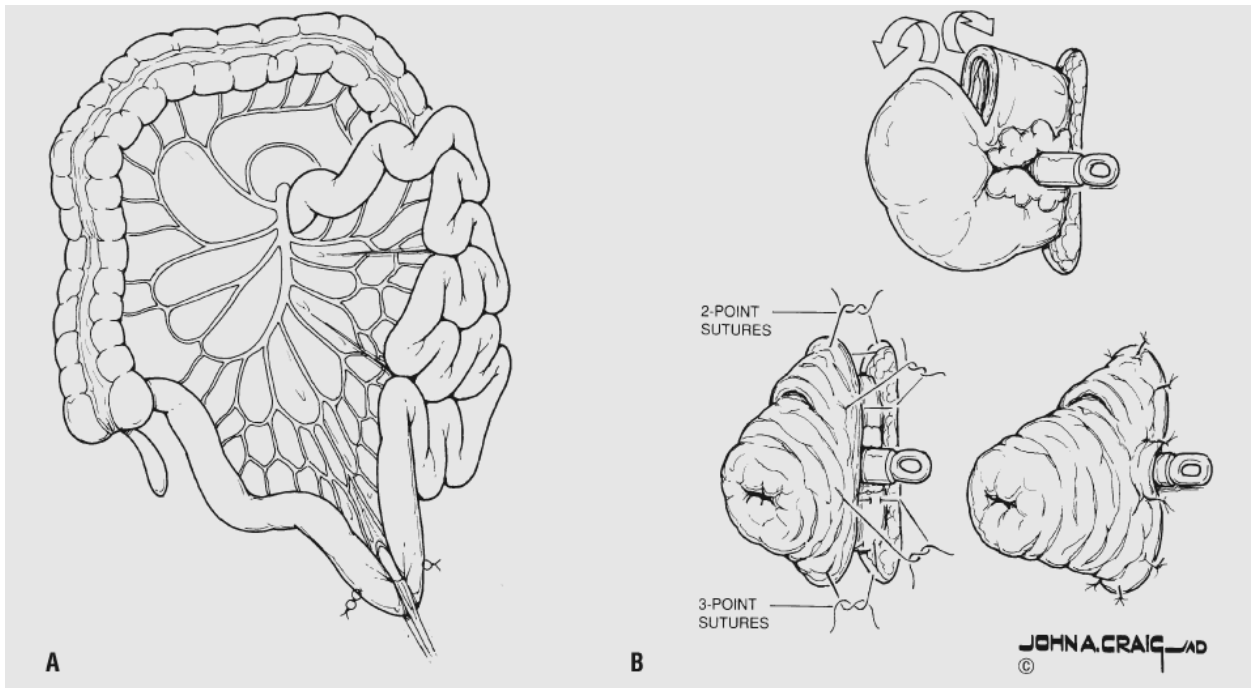
## **LOOP ILEOSTOMY**

Loop ileostomy was introduced by Turnbull as a means of providing a more satisfactory stoma for patients with a short or fat ileal mesentery and in the obese patient where the blood supply of a permanent end stoma might become compromised. The distal end of the ileum was oversewn and a loop of proximal ileum raised to the surface and everted over a rod. The use of rod is not always necessary. This stoma proved very effective not only as a permanent stoma, but as the optimal means of decompressing the distal ileum and colon.

It has become popular as a means of protecting kock pouches, ileoanal pouches and an ileorectal anastomosis if the rectum is diseased and in low anterior resection where there is a risk of leak from an anastomosis. The scope of the loop ileostomy has now been extended to include the management of complex anal fistula and occasionally as definitive therapy for megacolon and for protecting reconstructive anorectal procedures.



## Construction of a loop ileostomy



**Construction of a loop ileostomy.** **A.** A tracheostomy tape is placed at the segment for the intended ileostomy with sutures to identify proximal and distal limbs. **B.** The loop is pulled through the abdominal wall while its proper orientation is maintained. The tape is replaced by a plastic rod, and the spigot configuration is completed

The location is chosen exactly as one would choose the site for an end ileostomy. The opening in the abdominal wall is made the same as for an end ileostomy. The trephine must admit two fingers. The distal loop of the ileum must be marked for identification before it is delivered through the abdominal wall trephine. The loop is delivered through the abdominal wall by placing a tape under the mesenteric margin between the ileum and the marginal arcade

The use of rod under the loop of ileum to prevent retraction may be advised in the early postoperative period. A rod is indicated if there is risk of retraction or if there is tension on the bowel because of thick abdominal wall or a bulky mesentery.

The loop of intestine is opened by making a four fifths circumferential incision at the distal aspect of the loop, allowing 1 cm of ileum above the skin level in the superior aspect. The recessive limb thus is formed distally, and sutures are placed between the full thickness of ileum and dermis at this level. As the proximal aspect of stoma is constructed sutures are placed

between the full thickness of ileum, the seromuscular area at the base of the stoma and the dermis. As these sutures are tied, the stoma should assume a spigot configuration supported by the rod.

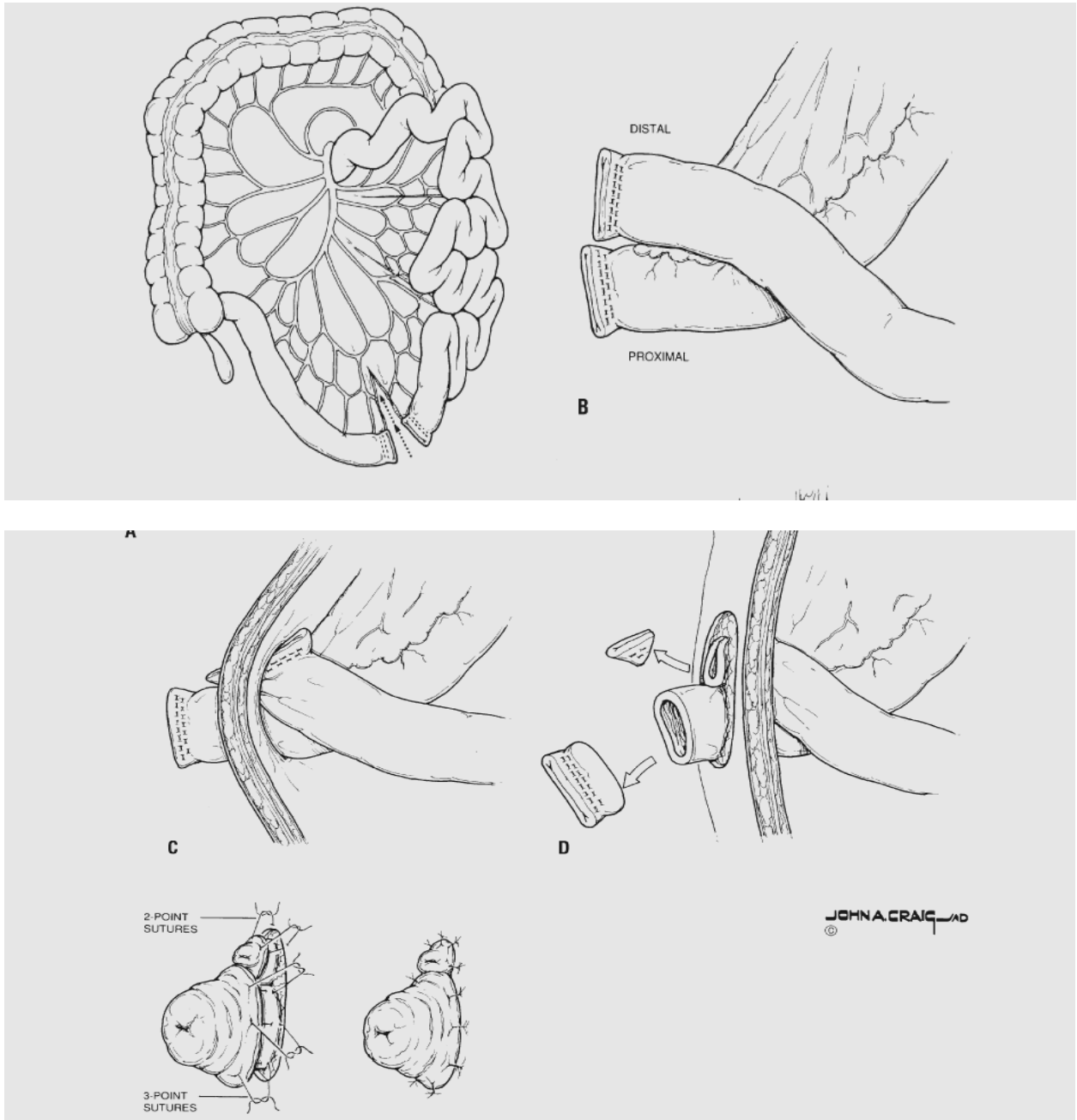
### **END LOOP ILEOSTOMY**

Rarely performed, useful when tension on the mesentery of the small intestine precludes construction of a viable End-Brooke ileostomy. The distal part of the small bowel is transferred as for an end ileostomy. The staple line may be over sewn and reinforced with absorbable seromuscular suture. A segment of bowel proximal to the closed end is chosen so that it can be exteriorised through the stoma opening. The construction then proceeds exactly as it would for a loop ileostomy. If the stoma is to be permanent, the bowel and its mesentery are anchored to the peritoneum and the posterior sheath with fine absorbable sutures.

## **SPLIT ILEOSTOMY**

This is a stoma that is not commonly recommended since the patient must manage an end ileostomy and a mucous fistula. Although a split ileostomy completely defunctions the distal bowel sometimes it is technically difficult to separate the two ends of the bowel and the procedure requires a laprotomy to restore intestinal continuity. If the site of ileal division lies close to the ileocaecal valve, the right colon must be mobilized. The mesentry must be quite extensively divided, leaving the ileum supplied by ileal arcades and the mucous fistula from the middle colic artery. The proximal end of the ileum is delivered through a trephine in the rectus muscle and the mucous fistula is raised either through the abdominal incision or preferably through a separate trephine in the ipsilateral or contralateral muscle.

## Construction of a separated loop ileostomy



**Construction of a separated loop ileostomy.** **A.** The distal ileum, but very little of the mesentery, is transected, using a linear-cutting staple device, in preparation for constructing the ileostomy. **B, C.** The proximal, functioning component is brought through for spigot construction, whereas only the corner of the distal component is brought through. **D.** The entire staple line of the proximal component and a corner of the distal component are excised. **E.** The functioning spigot and nonfunctioning recessive opening are completed

## **COLOSTOMY**

The most common indication for fashioning a colostomy is cancer of the rectum. Colostomies are also constructed as treatment for obstructing lesions of the distal large intestine and for actual or potential perforations.

### **DETERMINATION OF COLOSTOMY LOCATION**

The location of the colostomy must be carefully selected preoperatively. It should avoid any deep folds of fat, scars and bony prominences of the abdominal wall. The site is chosen by evaluating the patient in the standing, sitting and supine positions. Often abdominal skin and fat folds are only noted with the patient in sitting position. A stoma faceplate is applied to the abdominal wall with its medial margin at the midline, care is taken to not overlay any fold, scar or prominence, and the stoma site is marked. If a sigmoid or descending colostomy is contemplated the most desirable position is usually in the left lower quadrant of the abdomen. If a distal transverse colostomy is planned, the left upper quadrant is usually the preferable site.

## END COLOSTOMY

### TEMPORARY COLOSTOMY

Complicated diverticular disease is probably the principal indication for Hartmann resection and end colostomy. The operation may be used in obstructing and advanced rectosigmoid carcinoma. The Hartmann procedure is the operation of choice for fecal peritonitis. Temporary end colostomy may be appropriate for some penetrating colorectal injuries, as a staged approach in imperforate anus, infant Hirschsprung's disease and some form of inflammatory bowel disease.

### PERMANENT COLOSTOMY

The principal indication is abdominoperineal excision, where low anterior resection is not possible. Some patients with high defects from anorectal agenesis may elect to have a permanent end colostomy if function is poor. Some patients with end stage fecal incontinence may be served by a permanent colostomy.

## TECHNIQUE

An end colostomy most often is constructed after removal of the rectum for low-lying malignancy. The entire left colon is mobilized on its mesentery and depending on mobility of the colon and thickness of the abdominal wall, may require mobilization of the splenic flexure. If the patient has received neoadjuvant pelvic radiotherapy and or the inferior mesenteric artery is transected at its origin at the aorta, the entire sigmoid colon should be removed because of concerns regarding ischemia and a descending colostomy created.

If the colostomy is to be brought through the left lower quadrant, an opening in the abdominal wall is made at the previously marked site by excising a 3 cm disk of skin. The fat, fascia, muscle and posterior peritoneum are then incised longitudinally. No fat is excised. The opening is then dilated to allow passage of two fingers, and the closed end of the colon is pulled through the abdominal wall. Mesentery of the colon can be sutured to the lateral abdominal wall with a running suture. After the wound is closed and protected, attention is directed to completing the colostomy.



The stoma is completed by placing chromic catgut sutures between the full thickness of colon and skin.

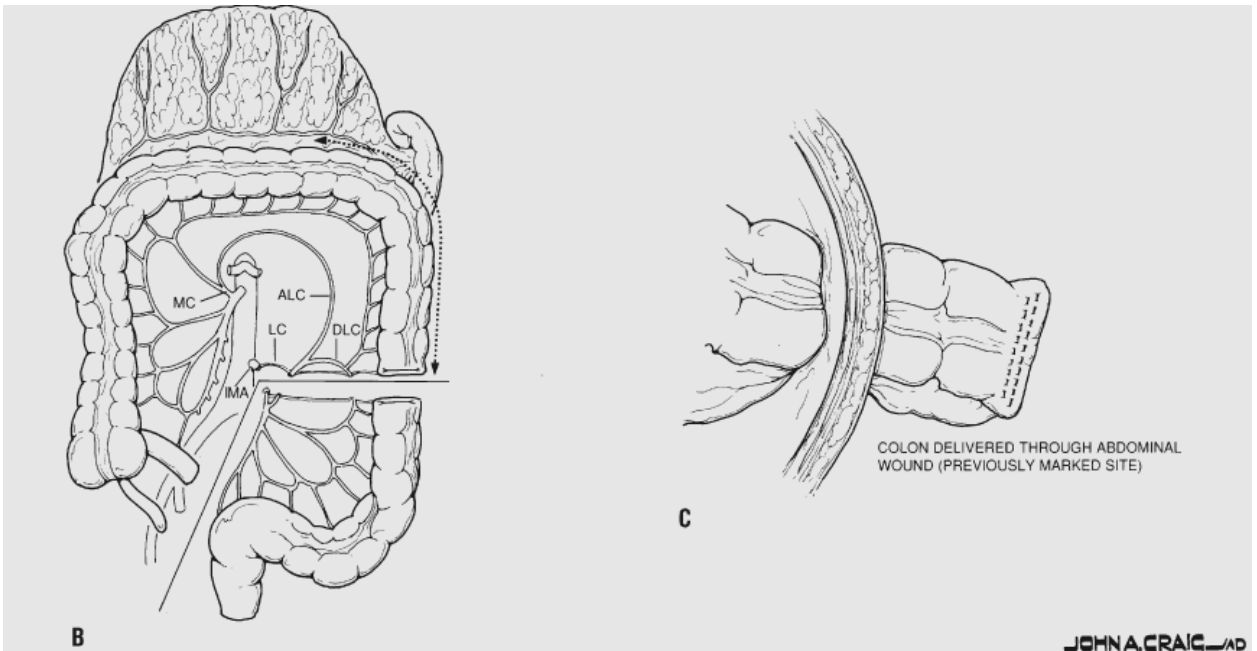
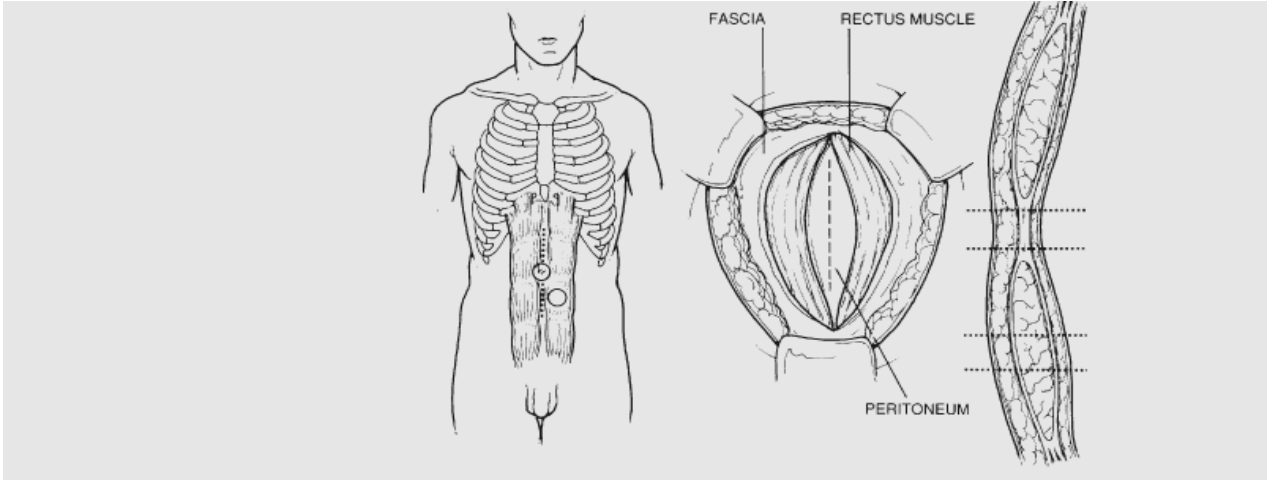
If a colostomy is being performed proximal to an obstructing lesion, to decompress the colon and divert the flow of stool, it is critical that the distal limb of the colostomy be vented to the atmosphere and not closed. If the distal limb is closed and there is complete obstruction distal to the colostomy, this will create a closed loop obstruction, and there is substantial risk of distention and perforation.

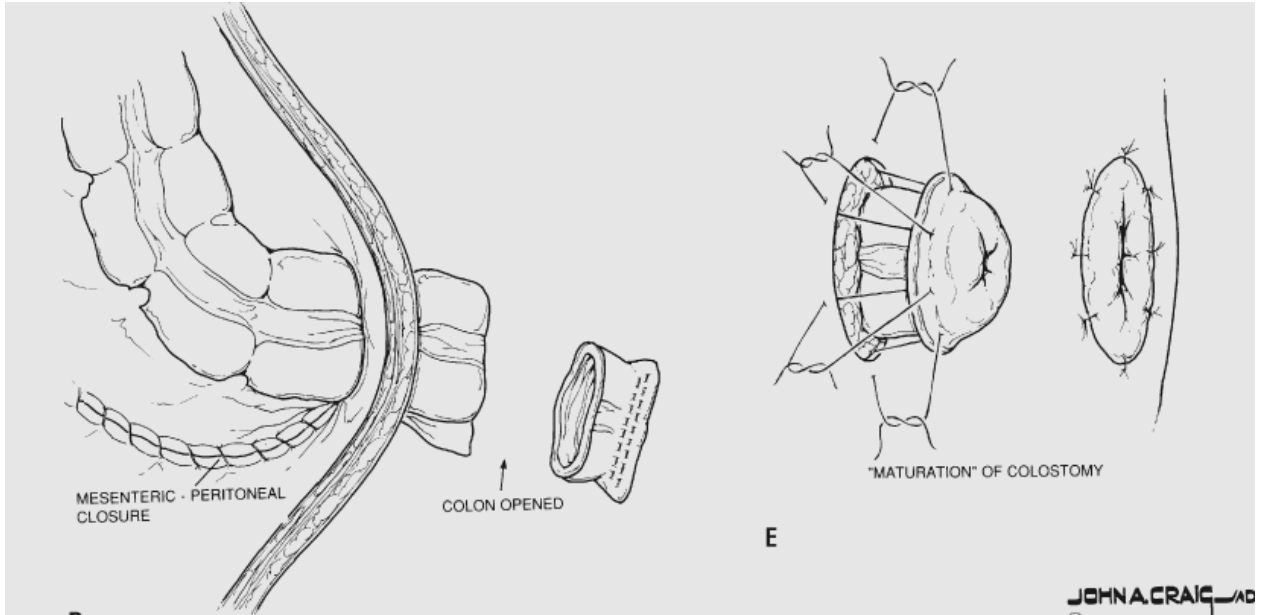
## **ALTERNATIVE TECHNIQUES**

### **EVERSION COLOSTOMY**

We do not normally evert a colostomy but leave it flush with the skin. However, if the patient has had a previous small bowel resection or radiation ileitis, or there is little proximal colon and the intestinal contents are liquid, or the patient cannot see a flush stoma, an eversion colostomy might be worth considering. This can be achieved by picking up the serosal surface of the colon before the edge of the bowel as in ileostomy construction.

## Construction of an end (diverting) colostomy





**Construction of an end (diverting) colostomy. A.** Selection of stoma location and technique of incision of the abdominal wall at the colostomy site. **B.** Technique of colonic mobilization and provision of adequate blood supply for the colostomy. **C, D, E.** Final stages of constructing a "mature" end colostomy. (LC, left colic artery; MC, middle colic artery; ALC, ascending left colic artery; DLC, descending left colic artery.)

## **DELAYED MUCOCUTANEOUS SUTURE**

If during an emergency operation for obstruction or sepsis, when there is doubt about the viability of the end of the colon, direct mucocutaneous suture is not advised. In these circumstances, the left colon should be fully mobilized and as much of the colon as possible, is delivered to the surface through a wide non compressible trephine. The serosa is then tacked to the skin with no more than two or three loose sutures so that the bowel end of doubtful viability is enclosed in a transparent colostomy bag. At some later date when the ischemic segment has declared it, the end of the colon can be amputated flush with the skin and sutured.

## **TREPINE END COLOSTOMY**

There are many circumstances in which end colostomy may need to be constructed without a laprotomy. A trephine end stoma may be desirable for incontinence, for palliation or even for protecting an end reconstruction. So as to avoid the risk of incomplete fecal diversion stapling the distal bowel end may be advisable. Can also be performed laproscopically.

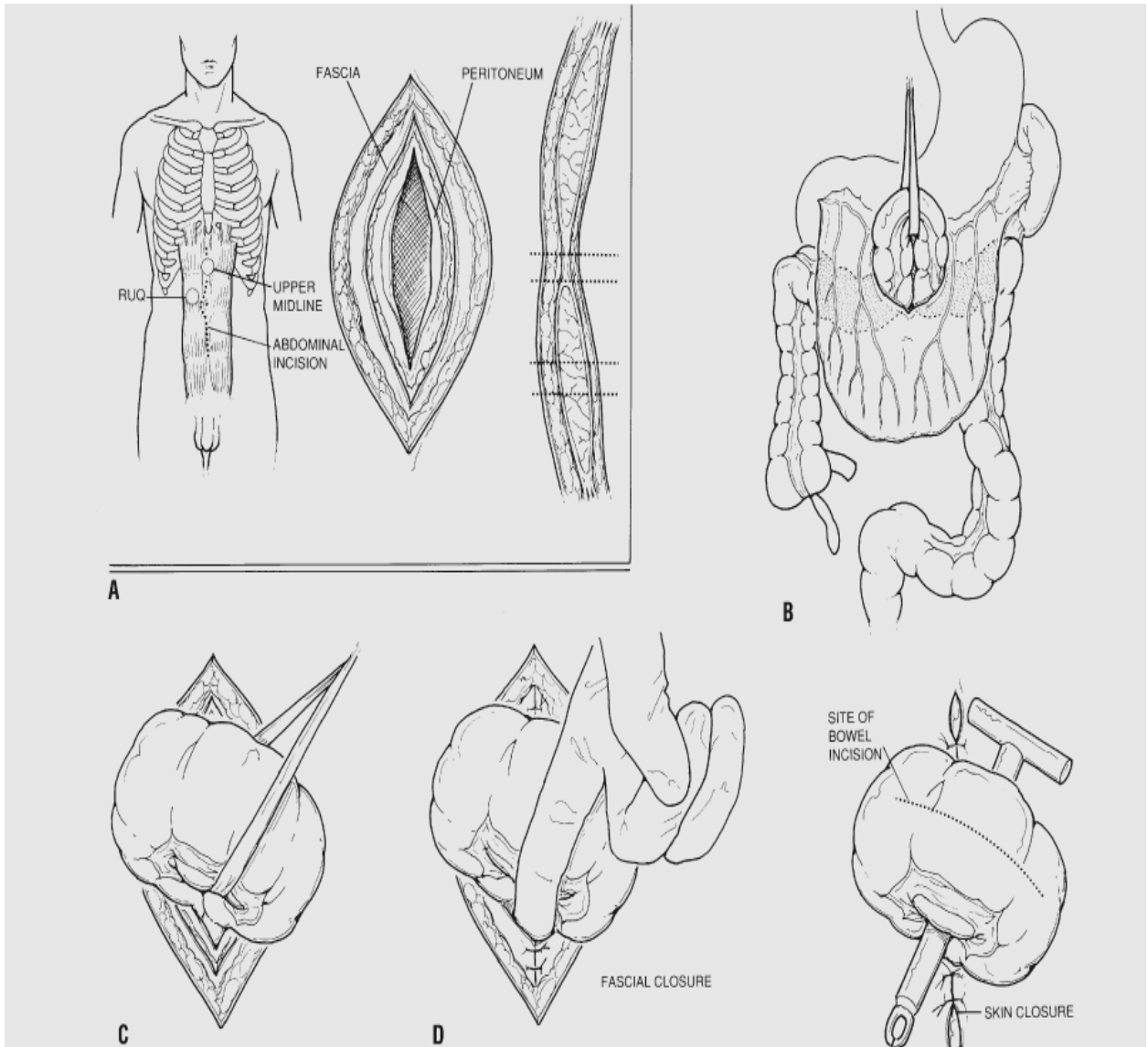
The technique may be difficult in grossly obese patients and definitely contraindicated in patients who have had previous complex abdominal surgery.

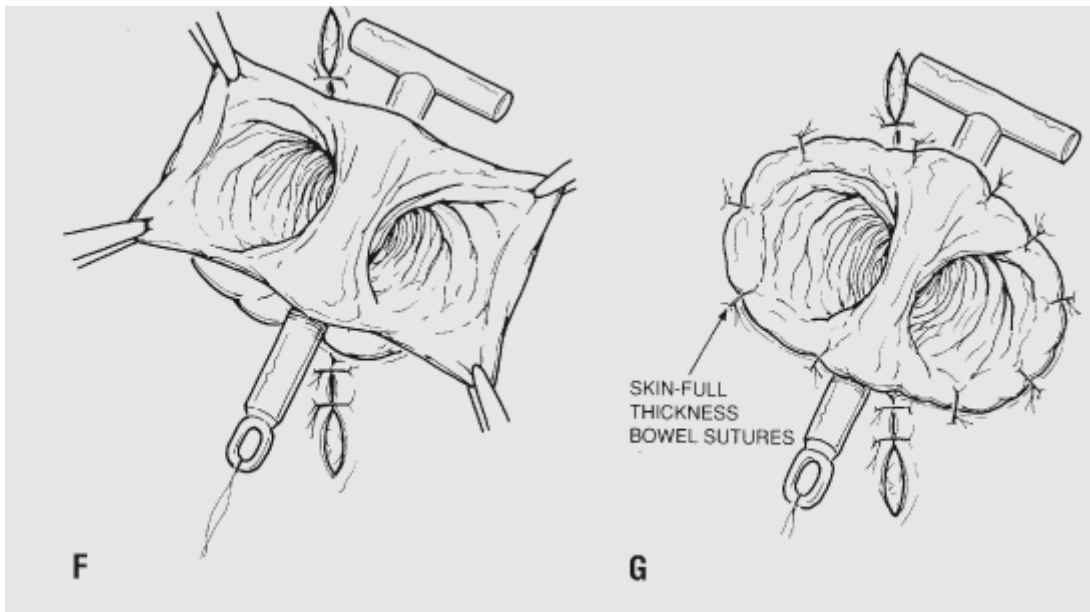
### **LOOP TRANSVERSE COLOSTOMY**

A loop transverse colostomy can be used as a decompressive stoma although it will usually divert the flow of stool from the distal colon. These stomas are constructed to provide temporary diversion for protection of complicated distal anastomosis. The other advantage is that when properly constructed a loop transverse colostomy can serve as a long term stoma. Loop colostomies may also be used to palliate an inoperable tumour or to relieve adult or neonatal distal large bowel obstruction.

However loop colostomies, particularly loop transverse colostomies are difficult to manage because of their bulk and are associated with a high incidence of hernia, retraction and prolapse. May not be the optimal stoma to protect a colorectal anastomosis if the bowel is not empty and when the marginal artery is critical for the blood supply of the distal colon.

## Construction of a loop-transverse colostomy





**Construction of a loop-transverse colostomy. A.** Choice of stomal location. **B, C.** Tracheostomy tape is used to pull the loop of colon through the incision. **D.** The fascia is closed tightly around the loop of intestine. **E, F, G.** The loop of colon is opened over a supporting rod and is sutured to the skin of the abdominal wall

For a loop colostomy, the abdominal wall trephine must be wide enough to admit two fingers. A loop colostomy may be fashioned for palliation or for large bowel obstruction without performing a laprotomy, provided there is no fear of colonic perforation or ischemia. Once the appropriate loop of colon has been identified, a small window is opened in the mesentery adjacent to the bowel, without damage to the vascular arcade and a nylon tape is placed under the colon to facilitate its delivery through the abdominal wall. In the case of a transverse loop colostomy, a window must be opened between the omentum and the colon through the transverse mesocolon and gastrocolic ligament. For the sigmoid colon a small opening is made near the bowel in the sigmoid mesentery. Once the bowel has been opened, immediate mucocutaneous suture is performed.

### **CECOSTOMY AND “BLOW HOLE” STOMA**

A caecostomy should be constructed only rarely because it is difficult to manage postoperatively. It should be reserved for the severely acutely ill patients with massive distention and impending perforation of the colon.



This is seen most often with distal obstructing cancer or in some of the pseudo obstruction syndromes seen in elderly or immunocompromised patients.

A disadvantage of a cecostomy or loop colostomy done through a small incision is that one cannot evaluate other parts of the colon for potential ischemic necrosis due to massive dilatation. The construction of a blow hole cecostomy or transverse colostomy is carried out by making a 4-6 cm transverse incision over the most dilated part of intestine and then placing a series of interrupted, seromuscular, absorbable sutures between the peritoneum and the seromuscular layer of the bowel to be decompressed.

Once the first layer of sutures has been placed and the intestine is sealed from the remainder of the abdominal cavity, needle decompression of the gas distended viscous is performed to reduce the tension on the intestinal wall. When this procedure is completed, a second layer of absorbable sutures is placed between the seromuscular layer of the intestine and the fascia of the abdominal wall. Subsequently, the colon is incised. The full thickness of intestine is then sutured to the full thickness of skin, again with

absorbable sutures and an appliance is placed over the stoma.

A tube cecostomy is constructed by making a similar incision or by approaching the caecum through a laprotomy incision. A purse-string suture is placed in the caecal wall, and a large mushroom tipped or malecot catheter is placed in the caecum.

## **STOMA MANAGEMENT**

### **MANAGEMENT OF AN ILEOSTOMY**

#### **THE APPLIANCE**

The surgeon should be responsible for fitting the appliance around the ileostomy at the end of the operation. The appliance should be transparent so that the stoma can be visualized. A good seal around the stoma is critical since confidence can be destroyed if leakage occurs early convalescence.

#### **FLUIDS**

Prolonged restriction of fluids is unnecessary in most patients who

have had an end or loop ileostomy, provided that ileus is not prolonged. The stoma will usually emit gas and then some fluid on the second or third postoperative day. As soon as this event has occurred the patient may be allowed increased oral fluids and then a light diet, provided the ileostomy continues to function.

### **SPECIAL CONSIDERATIONS**

#### **PROLONGED ILEUS OR MECHANICAL OBSTRUCTION**

After operation some patients may experience prolonged ileus with abdominal distention and vomiting. Sometimes the stoma may become edematous. This event is nearly always associated with profound dehydration, hyponatremia, hypokalemia, poor urine output and rising serum creatinine. Causes of the ileus include retroperitoneal and intraperitoneal bleeding, sepsis, small bowel ischemia, electrolyte disturbance, traumatic perforation, regional anesthesia and coexisting medical illness. Ileus may be difficult to distinguish from mechanical obstruction due to adhesions, entrapment of bowel through the lateral gutter in the perineum or through

the pelvic peritoneal closure line, a volvulus around the stoma or where the bowel has become adherent to the abdominal wall closure, an abscess or a walled off perforation.

Immediate management of the ileus or obstruction is by nasogastric decompression and replacement of large volumes of intravenous fluid using physiological saline and added potassium. Steroids should be recommended in full dose if the patient has received steroid therapy within a month of surgery. If after 10 days of intensive conservative management there is no improvement, serious consideration should be given to repeat laprotomy.

## **RETRACTION**

Early retraction of an ileostomy is troublesome since there is much greater risk of leakage and skin excoriation. Furthermore, retraction of a loop ileostomy usually results in inadequate function. If a retracted stoma can be resolved, for instance using convex appliances, there may be no need for surgical correction. Alternatively, if a loop ileostomy used to protect an

anastomosis retracts, then serious consideration should be given to closing the loop ileostomy at an earlier date since retraction in these circumstances no longer achieves fecal diversion. Early attempts at refashioning usually result in damage to the small bowel unless stapling refashioning is used.

## **ISCHAEMIA**

A great deal of concern is usually expressed when an ileostomy appears purple or even black when viewed through a transparent ileostomy appliance within 48 hours of the operation. Provided the patient general condition is satisfactory it is usually prudent to adopt a conservative policy. It is rarely necessary to reoperate for an infarcted ileostomy. The appearances are usually due to venous congestion and oedema from a relatively narrow abdominal wall or a tight appliance. Adequate postoperative analgesia should be provided and the appliance checked to ensure that, it is not obstructing the stoma. In nearly all cases, the stoma will resume its normal color within 48 hours. At worst, there may be some stenosis of the stoma at a later stage. Post operative discoloration appears to have no effect on long term function.

## **DYSFUNCTION**

Ileostomy dysfunction describes a syndrome of abdominal pain, high volume ileostomy output and vomiting, irregular ileostomy action occurring about a week after operation, exclusively in patients who did not have an eversion ileostomy. For this reason, the syndrome is now rare. Relief of symptoms can be achieved rapidly by passing a soft foley's catheter through the stoma to relieve the obstruction and subsequent refashioning of the stoma with an everted stoma.

## **SKIN PROBLEM**

Skin excoriation from leakage remains the most common complication of an ileostomy, particularly in a badly sited stoma, if the ileostomy has retracted and if the length of residual small bowel is short. Effluent dermatitis is characterized by peristomal excoriation, which delineates any skin furrows and scars near the ileostomy. Fecal dermatitis will cause marked erythema and may encourage secondary skin sepsis. Treatment involves careful cleaning of the skin, which is washed with water

and dried with tissues or a hair dryer. If the ileostomy contents are very liquid it is advisable to prescribe antidiarrhoeal preparations. The most common skin problems are due to poorly fitting appliances and allergy.

### **GAS PROBLEM**

Gas is derived from swallowed air or from bacterial fermentation of various dietary products. Pneumogenic foods include eggs, beans, onions cabbage and sprouts. Agents that may reduce odor by preventing bacterial overgrowth include chlorophyll tablets and bismuth subgallate. Gaseous odours are less troublesome for patients with an ileostomy than with a colostomy. Flatus patches consisting of activated charcoal are incorporated in most bags.

### **DRUGS**

Some drugs are inadequately absorbed in patients with an ileostomy, particularly when they have a short bowel. Enteric-coated tablets should not, therefore be prescribed in ileostomy patients. Contraceptive pills

particularly low dose agents are inadequately absorbed, hence ovulation will not be suppressed and the pill is ineffective. Antibiotics should be avoided because of the risk of bacterial and fungal overgrowth. Diuretics should be prescribed sparingly in ileostomy patients for fear of dehydration.

## **MANAGEMENT OF SPECIFIC COMPLICATIONS**

### **RETRACTION**

A retracted stoma is often responsible for leakage and peristomal excoriation. Retraction may be managed by local stapling procedure but more commonly it is corrected by a local refashioning procedure, with fixation of the serosa of the ileum to the rectus sheath.

### **PROLAPSED ILEOSTOMY**

Ileostomy prolapse while uncommon, is usually associated with inadequate fixation between the ileostomy and the abdominal wall, it is often associated with a peristomal hernia. It could be fixed or sliding. The fixed prolapse can be expected to resolve by amputation alone, whereas the sliding variety may have to be resited. The fixed type of prolapse is probably an



error of original construction, in that the stoma was made too long.

Amputation of a fixed prolapse is comparable to rectosigmoidectomy for rectal prolapse. The junction between the skin and the mucosa is carefully divided without mobilizing the emerging ileum. The everted limb is straightened. An appropriate length of ileum is excised, usually leaving 5-6 cm projecting above the skin, which is then everted and sutured to the skin.

For sliding prolapse, careful local revision with fixation of the serosa to the rectus and or stapling of the ileostomy bud is possible. Preferably, the stoma should be recited if a suitable alternative position can be found.

### **PARAILEOSTOMY HERNIA**

Parastomal hernias are usually the result of a badly sited stoma, obesity, age, a wide abdominal trephine or chronic obstructive airway disease. Parastomal hernias may be classified as being interstitial, subcutaneous or intrastomal. The small bowel may be damaged during

ileostomy closure or refashioning because of adherent loops in the hernial sac. Strangulation and infarction of small bowel within the sac is rare but obstruction is a common indication for surgical correction.

Local repair is usually considered unsatisfactory. Local repair may be performed by resuture of the musculoaponeurotic defect, or by placement of a mesh support around the stoma to repair the defect. Nonabsorbable mesh carries the risk of chronic sepsis, but absorbable mesh might overcome these disadvantages.

### **PARAILEOSTOMY FISTULA**

Fistulas in ulcerative colitis or familial adenomatous polyposis are nearly always due to a non-absorbable suture that has caused chronic sepsis and has eroded through the ileum. Alternatively the fistula may be due to trauma to the ileostomy, often as a result of erosion

Fistulas usually require surgical correction because of the difficulties encountered with stoma management. Even if the orifice lies adjacent to the stoma, intestinal discharge dislodges the flange and usually lifts the seals

within a few hours of application. If on the other hand, the orifice of the fistula is underneath the flange or outside it, skin excoriation rapidly ensues because intestinal loss either dislodges the appliance immediately or discharges on to the skin beside it.

Reoperation involves mobilizing the stoma from the abdominal wall, a procedure that may be extremely difficult if there is chronic peristomal sepsis and non absorbable sutures surrounded by an abscess, laprotomy or laprostomy is advisable. If the original stoma size is satisfactory and has not been excessively stretched or distorted by disease or operation, the new stoma may be fashioned at the same site. On the other hand there is usually chronic sepsis or a wide deficiency of the abdominal wall at the stoma site or the original stoma site is badly placed, in these circumstances the new stoma should be recited.

## **BLEEDING**

Bleeding may be from ulceration, trauma, polyps and recurrent crohn's disease or peristomal varies. Traumatic bleeding is nearly always associated with a long stoma, patient interference or too tight an ileostomy appliance.

## **ILEOSTOMY FLUX (DIARRHOEA)**

Flux is used to describe profuse ileostomy diarrhea. This is a common and important complication since patients may rapidly become dehydrated, hyponatraemic and hypokalemic.

Any patient who passes more than 1000ml of fluid ileostomy contents in 24 hours is in danger of becoming rapidly salt and water depleted. The volume of ileostomy effluent usually falls to less than 1200 ml within 48 to 72 hours and during this time the intravenous infusion should be the only source of fluid and electrolytes, since drinking fluids or even taking salt by mouth merely exacerbates the fluid and electrolyte losses. Once the fluid losses abate, oral fluids may be slowly administered. Drugs such as codeine and loperamide will reduce ileostomy output and conserve sodium. These drugs may be used after withdrawing intravenous fluids or be taken as a reserve if the ileostomy suddenly becomes overactive. Somatostatin analogues may have a place in patients with recurrent flux.

## **MANAGEMENT OF THE COLOSTOMY**

An appliance should be attached to the skin surrounding the edges of the stoma as soon as it has been sutured in theatre. A good seal is important for morale in the early days after operation. It is preferable to use a transparent bag for observing the stoma in the immediate postoperative period.

### **PROBLEMS**

#### **SKIN PROBLEMS AND ODOUR**

Skin protection is usually critical only to patients with a loop transverse colostomy. Between 200 and 2000 ml of intestinal gas is passed per day, the amount varying enormously with diet, activity, altitude and eating habits. Colostomy patients find that odour is a much greater problem than ileostomy patients do. Filters are now incorporated into most drainable and almost all non drainable stoma appliances; they are made of activated carbon or charcoal and are effective provided they do not become damp, which render them useless.

Oral preparations that may be used to control flatus include chlorophyll tablets, charcoal biscuits and bismuthsubgallate. An alternative is to place compounds such as aspirin in the stoma bag.

## **COMPLICATIONS OF COLOSTOMY**

The most common complications are skin excoriation, leakage, stomal sepsis, hernia and stenosis.

### **EARLY COMPLICATIONS**

Sepsis is a potentially serious early complication. It may be associated with impaired blood supply; either because a loop has been exteriorized under tension or because the vascular arcades supplying the end of the colon have been damaged or divided. In these circumstances the stoma is liable to retract or slough and may cause fecal contamination within the abdominal wall or the peritoneal cavity, resulting in secondary peritonitis or intra abdominal abscess. Secondary peritonitis is equally dangerous and both events require early laprotomy, resection of non viable bowel and

construction of a stoma sometimes at a new site. Furthermore it may be necessary to perform a radical debridement of the abdominal wall, which may need to be left open.

## **LATE COMPLICATIONS**

Late complications include prolapse, hernia, stenosis and skin excoriation. Skin excoriation is associated with liquid stomal effluent and a badly fitting appliance, which is most common with a loop transverse colostomy. Patients with skin excoriation should be managed in the same manner as those with an ileostomy, by cutting a stomahesive wafer close to the circumference of the stoma and filling in any skin depressions if leakage occurs beneath the flange.

## **STENOSIS**

Colostomy stenosis occurs almost exclusively in end colostomies and may be the result of peristomal sepsis, retraction or more commonly ischemia. A stenotic stoma will generally require refashioning, usually with a laprotomy in order to mobilize a sufficient length of viable colon.

## **PARASTOMAL HERNIA**

Paracolostomy hernia is usually caused by peristomal infection, poor abdominal wall support, as in the obese elderly patients, steroid medication or a wide abdominal defect. There was statistically significantly increased rate of colostomy hernia with wider apertures in the abdominal wall. Poor sitting of the stoma outside the rectus sheath has long been considered to be a common cause of hernia and / or prolapse.

Paracolostomy hernia is classified as being interstitial, subcutaneous, intrastomal or associated with a prolapse. Complications of paracolostomy hernia are usually mechanical. Colostomy appliances may become dislodged. Colostomy irrigation may be difficult or impossible. Obstructive symptoms are common owing to entrapment of small bowel or omentum within the hernia, but strangulation is rare.

In a temporary stoma, treatment of the hernia merely involves closing the defect when the colostomy is closed or when intestinal continuity is restored. With a permanent colostomy, surgical treatment is indicated if there are appliance problems or recurrent abdominal pain from obstruction.



Reciting of the stoma is usually advisable because local repair is often unsuccessful and there is a risk of local sepsis. Late recurrence of malignancy usually with ascites may present as a parastomal hernia in patients who have had their original operation for malignant disease.

Local repair without reciting the stoma may be occasionally successful. This approach may be the only option in patients who have had multiple operations or in whom a previous stoma site on the other side of the abdomen has already been used. The stoma is completely mobilized, the hernia excised and the defect in the abdominal wall repaired, leaving the sutures long so that the bowel can be brought out through the repaired trephine.

If the stoma can be recited, the recurrence rate is lower. The previous abdominal incision is reopened under antibiotic cover and the stoma brought out through a new trephine in the opposite rectus muscle.

Mesh may be placed in on intraperitoneal or preperitoneal position. It may be placed through the stoma wound or from a distance.

## **PROLAPSE**

Prolapse is thought to develop in patients with obstruction because of the discrepancy between the eventual size of the colon and the defect in the abdominal wall. Prolapse is usually intermittent and will reduce spontaneously. Prolapse of a transverse colostomy may be complicated by bleeding. Manual reduction may be necessary in patients who present with acute prolapse. This may be difficult if the prolapse has become odematous and occasionally requires amputation or surgical reduction. The prolapse may be treated in the same way as in rectal prolapse, but recurrence is high because there is persistent defect in the abdominal wall and a freely mobile colon within it.

## **THE QUEST FOR CONTINUENCE**

### **KOCK ILEOSTOMY**

The kock pouch may still provide the best chance of obtaining control over liquid and gaseous discharge from the small bowel. Serious complications such as obstruction, sepsis and fistula may jeopardize pouch function in 5-15%.

## **COLOSTOMY**

The quest for continence in patients with an end colostomy has also been explored. No device has yet proved satisfactory. Reservoir colostomy is inferior to reservoir ileostomy and has largely been abandoned. The smooth muscle collar popularized by Schmidt and Zoltan relies on colostomy irrigation. Implantable devices suffer the risk of sepsis and the quality of continence is disappointing.

# **MATERIALS AND METHODS**

## **MATERIALS AND METHODS**

This is a prospective study of 42 patients for whom emergency gastrointestinal ostomy was done, in the Department of General Surgery, Government Royapettah Hospital, Kilpauk Medical College, Chennai.

All the patients who underwent emergency gastro intestinal ostomy were studied prospectively, their demographic details, clinical features, past medical history, indications for surgery and type of ostomy performed, post operative complications, duration of stay in hospital and outcome.

The study period was 25 months from September 2006 to September 2008.

Admissions were carried out from outpatients department or through the casualty department as cases of acute abdomen. Majority of these patients (86.60%) presented with abdominal distention, tenderness and abdominal rigidity. There was marked dehydration and toxemia especially

in those who presented late in the course of illness. Immediate resuscitative measures were taken in all the patients regardless of age and sex. This comprised maintenance of intravenous line, nasogastric suction, catheterization, intravenous broad spectrum antibiotics and intravenous fluids. The principal diagnostic tools in all the patients were a detailed history and examination, basic blood biochemistry investigations, x-ray chest and x-ray abdomen erect and supine view. The other sophisticated investigations would not be done as majority of patients were taken up for emergency surgery, after due resuscitations laprotomy was performed by a midline incision, and depending upon the intraoperative findings and severity of contamination, type of ostomy was decided.

### **Inclusion**

All patients who required gastrointestinal ostomy in emergency abdominal surgery were included in the study

### **Exclusion**

Elective surgeries in which ostomies made were excluded

Emergency/Elective procedures like feeding jejunostomy/gastrostomy were excluded.

## **Limitations**

As the study period was short complete follow up of patients could not be done

## **Data collection**

The data of each patient was collected on a proforma specially designed for this study and included demographic details, clinical features, past medical history, interval between onset of symptoms and admission, operative findings, procedures performed, post operative complications and duration of stay in the hospital.

**OBSERVATION**



## **OBSERVATION**

A total of 42 patients were studied. There were 30 males and 13 females in this group. This gives a male to female ratio of 2.5:1. The age of the patients ranged from 14-82 years. Mean stay of patients in hospital was 28 days.

### **AGE DISTRIBUTION**

**TABLE - 1**

<b>AGE GROUP</b>	<b>NO. OF PATIENTS</b>	<b>PERCENTAGE%</b>
<b>&lt; 10</b>	<b>-</b>	<b>-</b>
<b>11 -2 0</b>	<b>5</b>	<b>11.90</b>
<b>21 – 30</b>	<b>9</b>	<b>21.42</b>
<b>31 – 40</b>	<b>6</b>	<b>14.28</b>
<b>41 – 50</b>	<b>13</b>	<b>30.95</b>
<b>51 – 60</b>	<b>5</b>	<b>11.90</b>
<b>&gt;60</b>	<b>4</b>	<b>9.52</b>
<b>TOTAL</b>	<b>42</b>	

Table 1 shows the age group involved in this study. In this, the majority of patients belonged to 41-50 years, followed by 21-30 age group.

### **SEX INCIDENCE**

**TABLE - 2**

<b>GENDER</b>	<b>NO. OF PATIENTS</b>	<b>PERCENTAGE %</b>
<b>MALE</b>	<b>30</b>	<b>71.42</b>
<b>FEMALE</b>	<b>12</b>	<b>28.57</b>
<b>TOTAL</b>	<b>42</b>	

Table 2 shows the gender distribution of the patients involved in the study.

Out of 42 patients for whom emergency gastro intestinal ostomy was done, primarily ostomy at the time of first surgery was done in 33 patients and for 8 patients ostomy was done for anastomosis leak either from primary closure of hollow viscous perforation or primary resection and anastomosis.

Out of the 42 patients studied, 22 patients had features of peritonitis for which emergency laprotomy was done, 19 patients presented with features of intestinal obstructions, 2 patients with blunt injury abdomen with pelvic fracture.

**PRESENTATION**

**TABLE - 3**

<b>PRESENTATION</b>	<b>NUMBER</b>	<b>PERCENTAGE %</b>
<b>PERITONITIS</b>	<b>22</b>	<b>52.38</b>
<b>INTESTINAL OBSTRUCTION</b>	<b>18</b>	<b>42.85</b>
<b>BLUNTINJURY ABDOMEN</b>	<b>2</b>	<b>4.76</b>
<b>TOTAL</b>	<b>42</b>	

Table 3 shows the clinical presentation of the patients involved in the study

Of the 22 patients presented with peritonitis 11 patients had ileal perforation for which, 6 patients were done split ileostomy primarily during the initial surgery due to severe contamination, rest 5 patients developed anastomotic leak from resection and anastomosis or primary closure of ileal perforation for which split ileostomy done during redolaprotomy.

Six patients presented with small bowel gangrene, jejunostomy was done in 3 patients and split ileostomy was done in 3 patients. Two patients developed anastomotic leak after resection and anastomosis done for strangulated inguinal hernia for which split ileostomy was done. Three patients had ileocaecal mass with perforation, resection of mass with ileostomy and mucous fistula of transverse colon was done in two patients due to severe sepsis, and one patient developed leak after initial resection and anastomosis for which ileostomy and mucous fistula was done in redolaprotomy.

**TABLE - 4**

<b>CASES</b>	<b>NUMBER OF PATIENTS</b>
<b>ILEAL PERFORATION</b>	<b>11</b>
<b>GANGRENE BOWEL</b>	<b>6</b>
<b>ILEOCAECAL MASS WITH PERFORATION</b>	<b>3</b>
<b>STRANGULATED INGUINAL HERNIA</b>	<b>2</b>

Table 4, shows the number of cases of different etiology presented with peritonitis.

### **ANASTONOTIC LEAK AFTER RESECTION AND ANASTONOSIS**

**TABLE - 5**

<b>CASES</b>	<b>NO. OF PATIENTS</b>
<b>ILEAL PERFORATION</b>	<b>5</b>
<b>ILEOCAECAL MASS WITH PERFORATION</b>	<b>1</b>
<b>STRANGULATED INGUINAL HERNIA</b>	<b>2</b>

Table 5 shows the number of patients with different causes presented with anastomotic leak.

### **INTESTINAL OBSTRUCTION**

**TABLE - 6**

<b>CONDITONS</b>	<b>NO. OF PATIENTS</b>
<b>SIGMOID GROWTH</b>	<b>6</b>
<b>SIGMOID VOLVULUS</b>	<b>3</b>
<b>CARCINOMA RECTUM</b>	<b>3</b>
<b>ILEOCACCAL MASS</b>	<b>2</b>
<b>CA CAECUM</b>	<b>1</b>
<b>CA ANAL CANAL</b>	<b>1</b>
<b>HEPATIC FLEXURE GROWTH</b>	<b>1</b>

Table 6 shows the number of patients with different etiologies presented as intestinal obstruction.

Of the 18 patients presented with features of intestinal obstruction for which ostomy was done, 12 patients had malignancy of which 6 patients

had sigmoid growth, in 2 patients the tumor was inoperable diversion transverse loop colostomy was done. For 2 patients, Hartmann’s procedure was done with transverse end colostomy. For 2 patients, after resection of sigmoid growth, primary anastomosis was done, with defunctioning loop transverse colostomy.

**SIGMOID GROWTH – TREATMENT**

**TABLE-7**

<b>INOPERABLE CASES WITH DIVERSION TRANSVERSE LOOP COLOSTONY</b>	<b>2</b>
<b>RESECTION AND ANASTOMOSIS WITH DEFUNCTIONING TRANSVERSE LOOP COLOSTOMY</b>	<b>2</b>
<b>HARTMANN’S PROCEDURE WITH TRANSVERSE END COLOSTOMY</b>	<b>2</b>
<b>TOTAL</b>	<b>6</b>

Table 7 shows the procedures done for patients with sigmoid growth depending upon the intraoperative findings.

Of the three patients with sigmoid volvulus, for two patients sigmoid end colostomy was done and for 1 patient transverse end colostomy was done.

Of the three patients with carcinoma rectum, two patients were inoperable and diversion transverse loop colostomy was done, for one patient resection and anastomosis with defunctioning transverse loop colostomy was done.

One patient had carcinoma anal canal, diversion sigmoid loop colostomy was done for that patient. One patient had carcinoma caecum, right hemicolectomy with ileotransverse anastomosis was done with defunctioning loop ileostomy. One patient had hepatic flexure growth; right extended hemicolectomy was done with ileotransverse anastomosis and defunctioning loop ileostomy.

One patient had multiple ileal strictures with perforation; split ileostomy was done for that patient. Two patients had ileocaecal mass, for which limited resection with split ileostomy was done due to contamination.



Two patients presented with Road traffic accident and pelvic fracture, both patients had rectal injury for which diversion loop transverse colostomy was done.

**TYPE OF OSTOMIES**

**TABLE – 8**

<b>TYPE OF STOMA</b>	<b>NUMBER</b>	<b>PERCENTAGE%</b>
<b>SPLIT ILEOSTOMY</b>	<b>22</b>	<b>52.38</b>
<b>TRANSVERSE LOOP COLOSTOMY</b>	<b>9</b>	<b>21.42</b>
<b>TRANSVERSE END COLOSTOMY</b>	<b>3</b>	<b>7.14</b>
<b>JEJUNOSTOMY</b>	<b>3</b>	<b>7.14</b>
<b>LOOP ILEOSTOMY</b>	<b>2</b>	<b>4.76</b>
<b>SIGMOID END COLOSTOMY</b>	<b>2</b>	<b>4.76</b>
<b>SIGMOID LOOP COLOSTOMY</b>	<b>1</b>	<b>2.38</b>
<b>TOTA.L</b>	<b>42</b>	

Table 8 shows the various types of ostomies done.

Out of the 42 patients studied, 22 split ileostomy, 9 transverse loop colostomy, 3 transverse end colostomy, 3 jejunostomy, 2 loop ileostomy, 2 sigmoid end colostomy and 1 sigmoid loop colostomy was done.

## **COMPLICATIONS**

### **ILEOSTOMY COMPLICATIONS**

**TABLE - 9**

**TOTAL NO. OF PATIENTS – 27**

<b>COMPLICATIONS</b>	<b>NUMBER OF PATINETS</b>	<b>PERCENTAGE %</b>
<b>SKIN IRRITATION</b>	<b>18</b>	<b>66.66</b>
<b>RETRACTION</b>	<b>5</b>	<b>18.51</b>
<b>ABSCCESS</b>	<b>10</b>	<b>37.03</b>
<b>PROLAPSE</b>	<b>3</b>	<b>11.11</b>
<b>STENOSIS</b>	<b>NIL</b>	<b>-</b>
<b>PERISTOMAL FISTULAS</b>	<b>1</b>	<b>3.70</b>
<b>OBSTRUCTION</b>	<b>NIL</b>	<b>-</b>
<b>PARASTOMAL HERNIA</b>	<b>NIL</b>	<b>-</b>
<b>NECROSIS</b>	<b>2</b>	<b>7.40</b>

Table 9 shows the complications of patients with ileostomy

Out of the 27 patients who had ileostomy (split ileostomy, loop ileostomy including jejunostomy), 18 patients (66.66%) had skin irritation like excoriation and peristomal ulceration, 10 patients (37.03%) had abscess either peristomal abscess or wound infection, 5 patients (18.51%) had retraction, 3 patients (11.11%) had prolapse, 1 patient had peristomal fistula (3.70%) and 2 patients (7.40%) had stomal necrosis.

### **COLOSTOMY COMPLICATIONS**

**TABLE - 10**

**TOTAL NO. OF PATIENTS - 15**

<b>COMPLICATIONS</b>	<b>NUMBER OF PATIENTS</b>	<b>PERCENTAGE</b>
<b>SKIN IRRITATION</b>	<b>4</b>	<b>26.66%</b>
<b>PERISTOMAL ABSCESS</b>	<b>2</b>	<b>13.33%</b>
<b>STOMAL NECROSIS</b>	<b>NIL</b>	<b>-</b>
<b>OBSTRUCTION</b>	<b>NIL</b>	<b>-</b>
<b>PARASTOMAL HERNIA</b>	<b>NIL</b>	<b>-</b>
<b>PROLAPSE</b>	<b>2</b>	<b>13.33%</b>
<b>FISTULA</b>	<b>NIL</b>	<b>-</b>
<b>RETRACTION</b>	<b>4</b>	<b>26.66%</b>

Table 10 shows the various complications of patients with colostomy

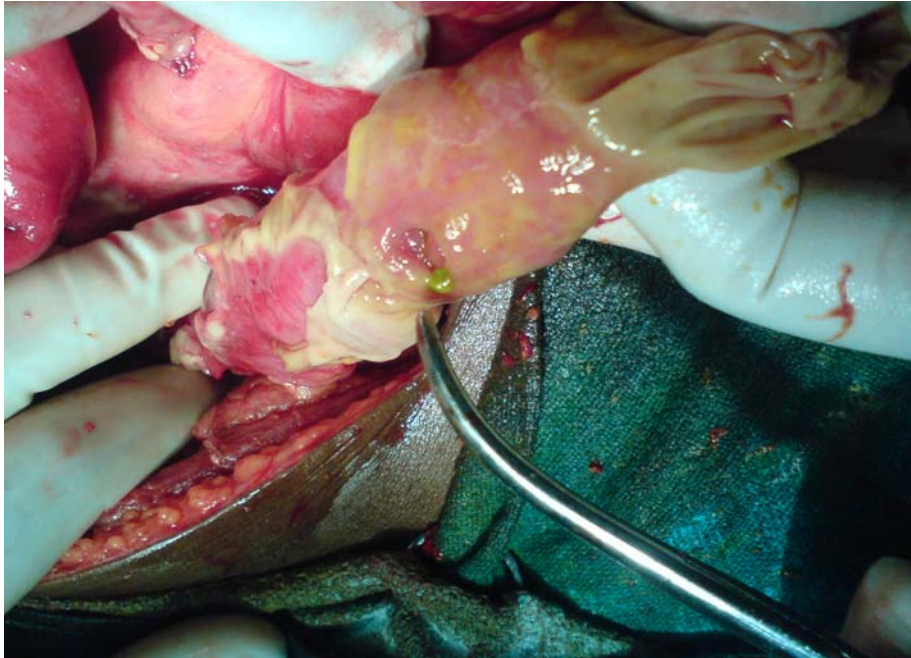Out of the 15 patients who had colostomy (including transverse loop colostomy, transverse end colostomy, Sigmoid end colostomy and sigmoid loop colostomy), 4 patients (26.66%) had skin irritation, 2 patients (13.33%) had peristomal abscess, 2 patients (13.33%) had prolapse and 4 patients (26.66%) had retraction.

During the hospital stay, two patients who were done ileostomy, one for patient with ileal perforation and another patient with caecal perforation died due to severe sepsis. Two more patients who were done ileostomy died due to denutrition and cachexy, 20 days after the surgery.

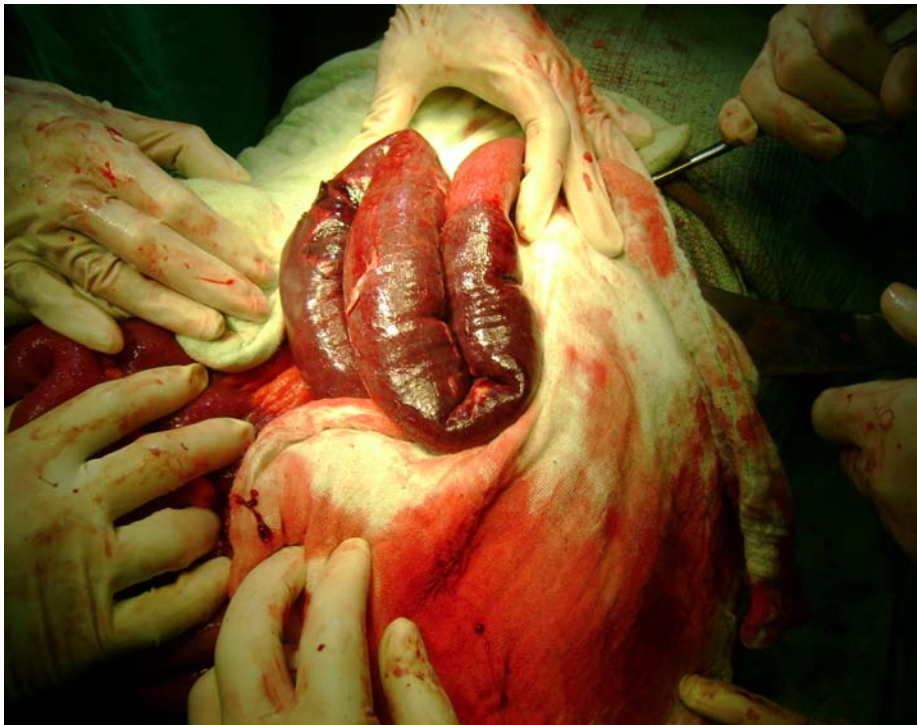
The mortality among the patients who had malignancy could not be followed up as the study period was short and some patients could not be followed up after discharge, but no patients with malignancy died during their hospital stay.

For patients with temporary ostomies restoration of bowel continuity was usually done 8-12 weeks after the previous surgery. Patients with malignancy were treated after further evaluation and staging the disease.

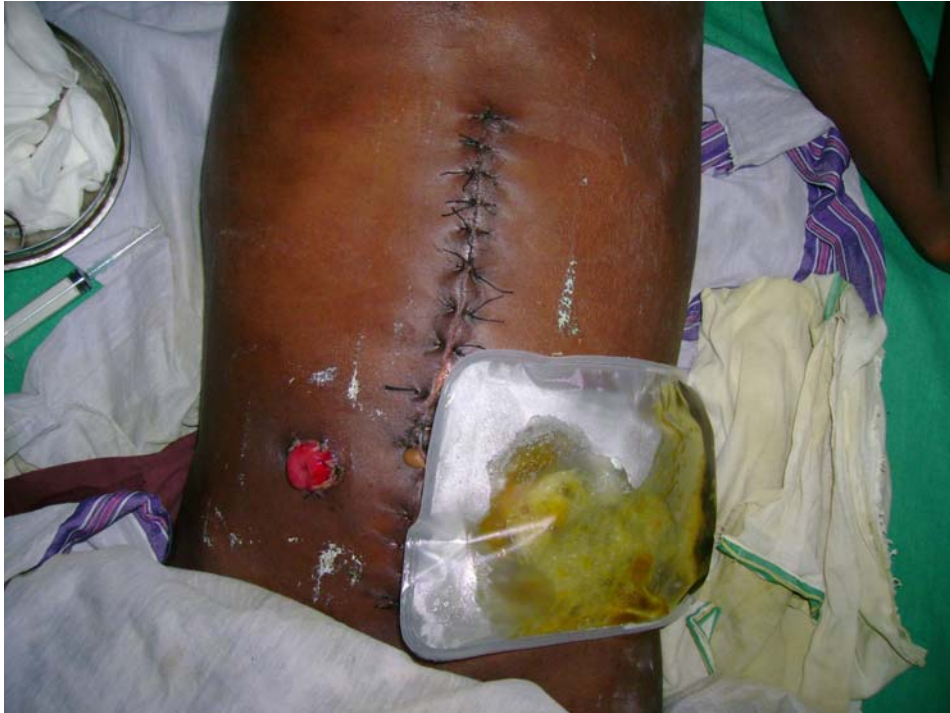## IEAL PERFORATION



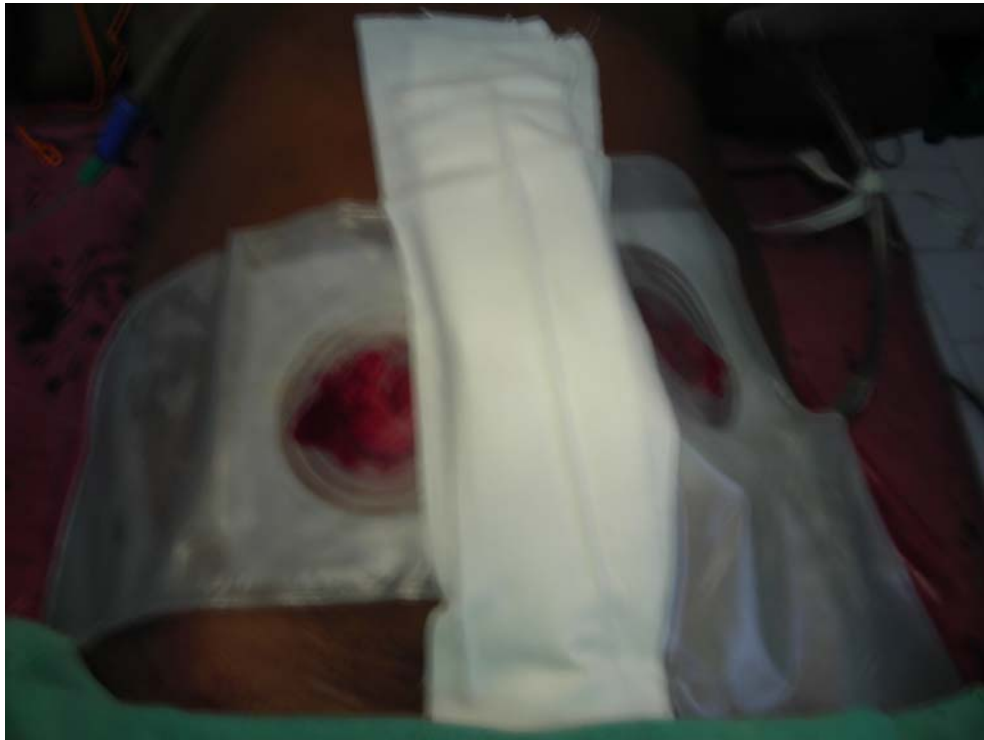## GANGRENE BOWEL



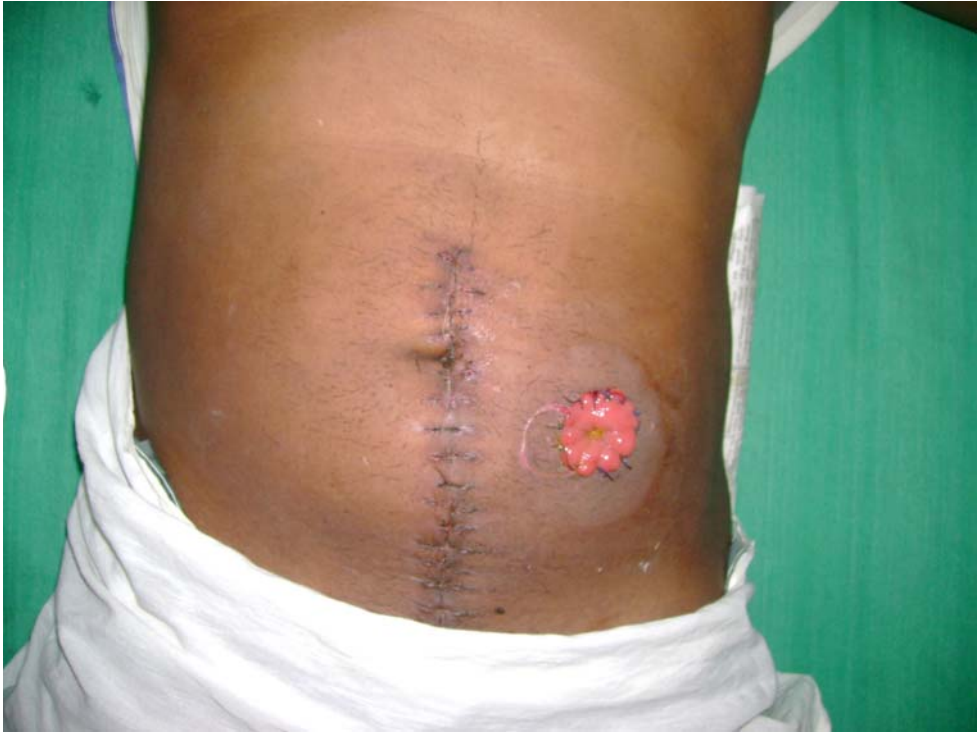**SPLIT ILEOSTOMY**



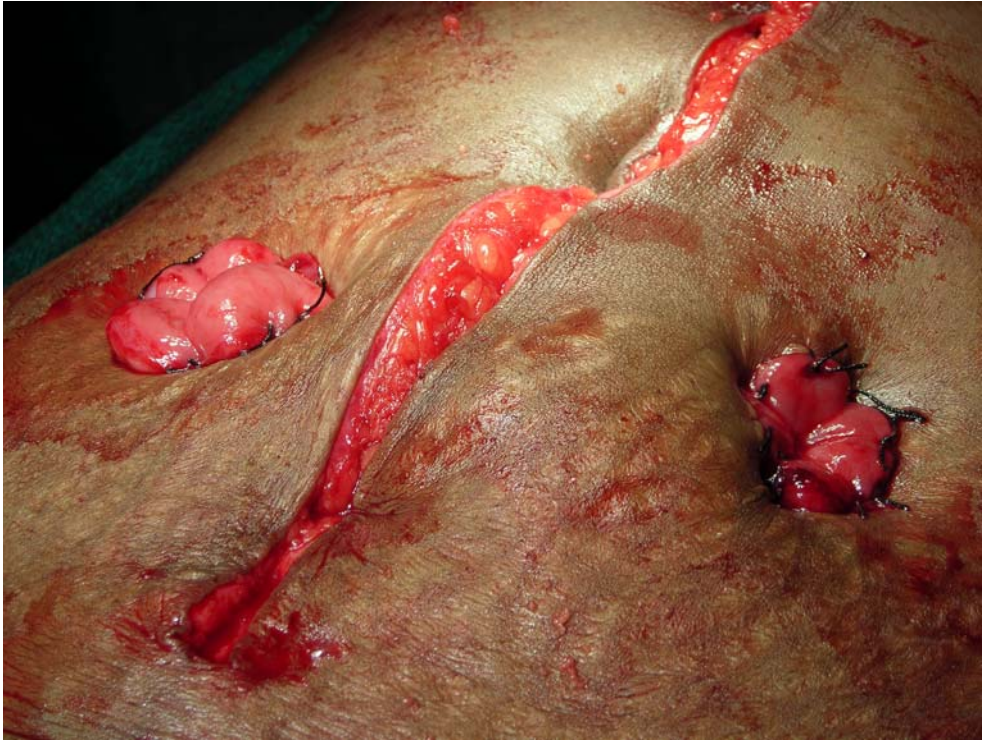
**SPLIT ILEOSTOMY WITH DRESSINGS**



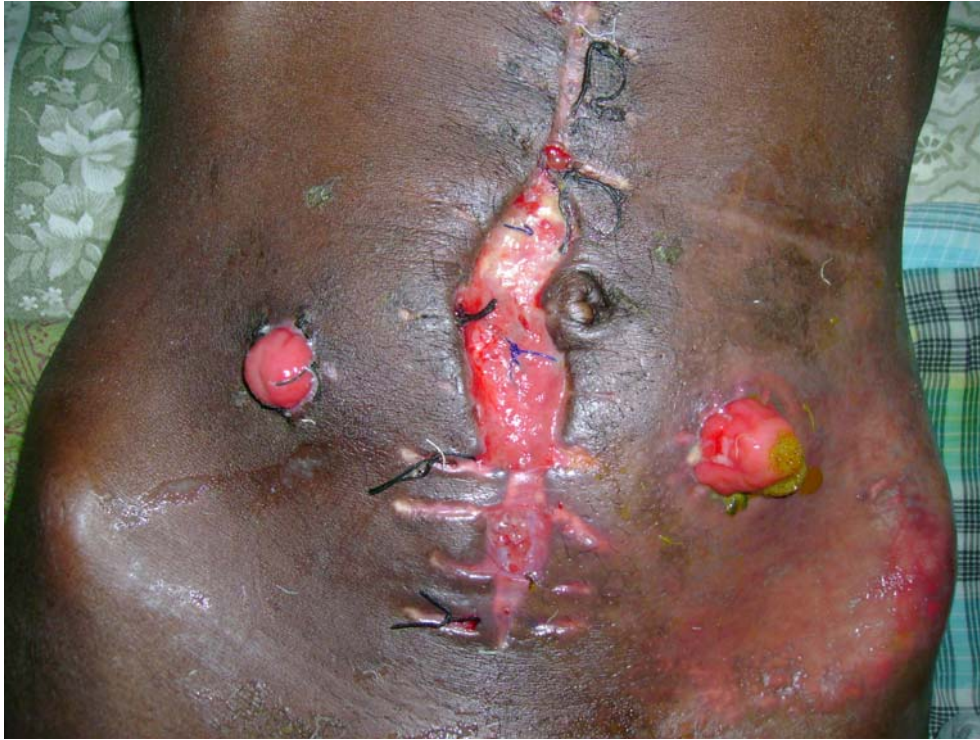**HARTMANN'S PROCEDURE**



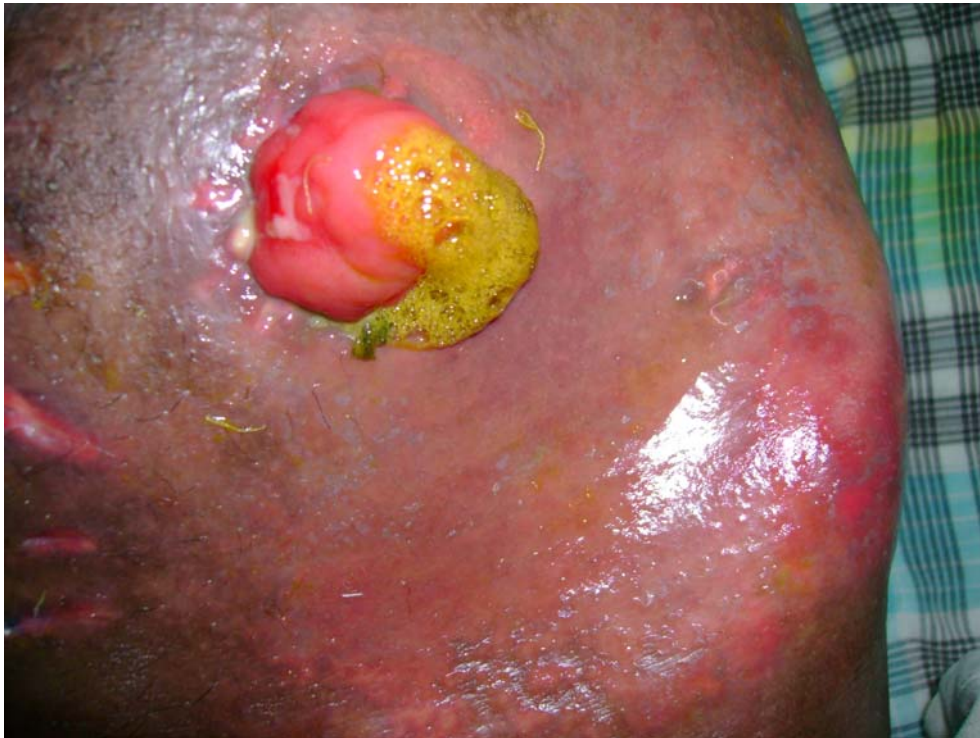**SIGMOID END COLOSTOMY WITH MUCOUS FISTULA**



**WOUND GAPING**

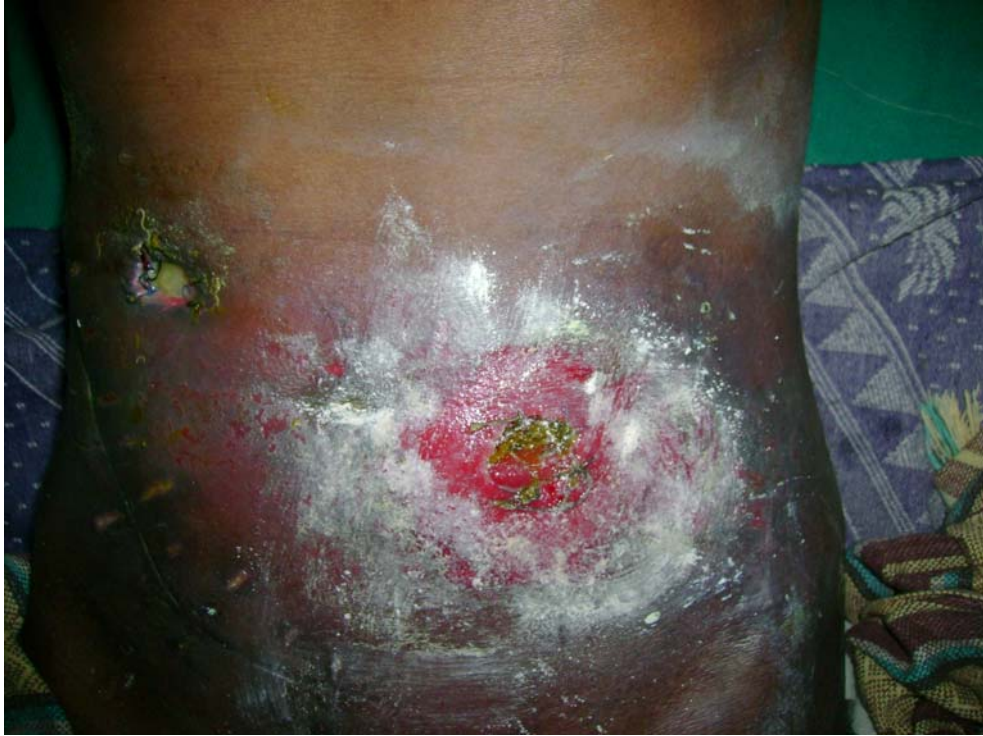

**SKIN EXCORIATION**

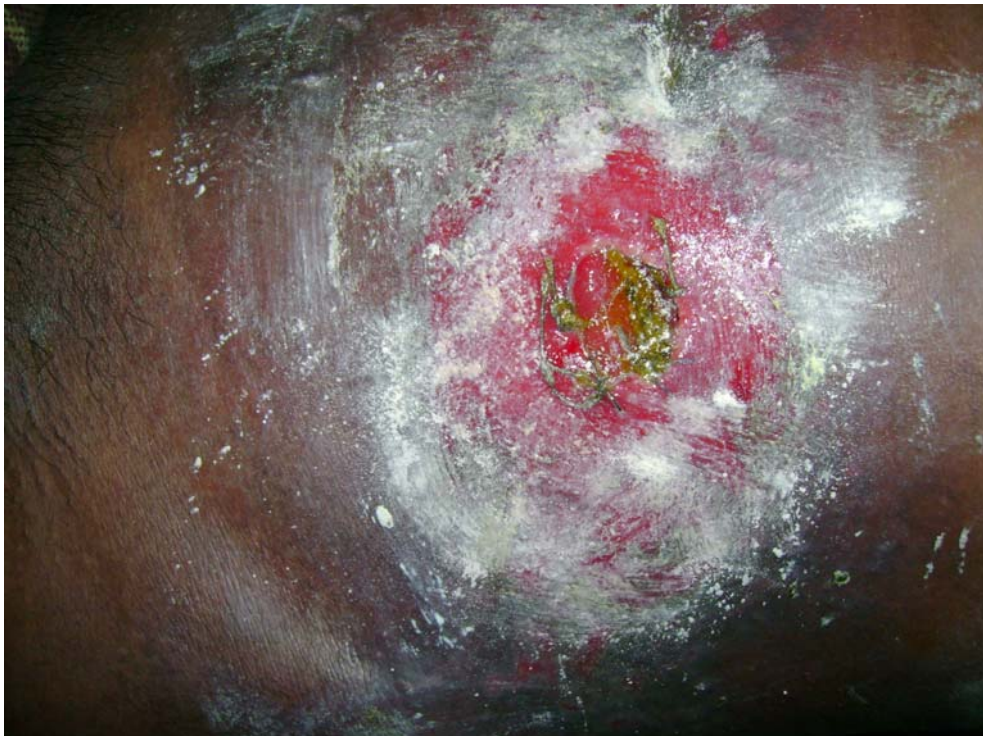



**RETRACTION OF ILEOSTOMY WITH SKIN EXCORIATION**



**ILEOSTOMY RETRACTION**



# DISCUSSION

## DISCUSSION

In the total of 42 patients studied, majority of cases were male predominant, with male to female ratio 2.5:1, comparable with **Ambreen Muneer et al study**, where the ratio was 2:1.

Majority of cases requiring ostomy was due to severe sepsis presenting late in the course of illness, the majority being ileal perforation requiring split ileostomy.

Intestinal perforation resulting from a complication of typhoid fever has always been a concern because of its high morbidity and mortality rates. Ileostomy is a life saving procedure, particularly in those cases where there is fulminant enteritis and peritonitis of long duration. Ileostomy remains a necessary procedure mainly on a temporary basis.

Gangrene bowel becomes the next most common indication for ostomy, for patients presenting with peritonitis.

For patients developing anastomotic leak either from primary closure of perforation or resection and anastomosis, ostomy conversion is a life saving procedure. In our study 7 patients (16.66%) had anastomotic leak, all were done split ileostomy and all the patients could be saved. The rate of occurrence of anastomotic leak is around 12% according to literature, **Nayen and Meier study** had a mortality rate of 62% in patients with anastomotic leak, but in our study, the mortality was nil.

Malignant intestinal obstruction cases presenting as emergencies, mostly results in performing an ostomy, which in acute situation becomes life saving for the patients. In our study we encountered 12 patients (28.57%) – which were treated either with defunctioning colostomy or Hartmann's procedure, and no mortality reported in the immediate post operative period. This is comparable with the **Danish study, kronberg and his colleagues**, where cumulative mortality is about 20% but the initial mortality was very low.

Unfortunately, the management of stoma remains difficult in developing countries, like us because of the shortage of suitable equipment.

In this respect, peristomal ulceration remains a major problem. In our study skin irritation with peristomal ulceration is around 66.66% in cases of ileostomy and 26.66% in patients with colostomy which is high when compared with **Leong et al study** where skin problem is 34% in patients with ileostomy and 15% in patients with colostomy in **Stothest et al study**.

Peristomal ulceration provokes some awful skin pain inducing the patients to self limitation of food intake, especially in patients with ileostomy. This can result in denutrition, cachexy and death. Two patients (9.09%) died from this complication in our study which is less than that of surgical experience of 64 cases study by **J. Kovame et al**.

The other complications encountered in patients with ileostomy include retraction, abscess, prolapse, stenosis, peristomal fistula and stomal necrosis. The patients with colostomy developed much less complication than ileostomy which include skin irritation, peristomal abscess, prolapse and retraction.

In emergency, though most of the stomas made were temporary, stoma care is also pivotal to prevent further morbidity and mortality.

**CONCLUSION**

## CONCLUSION

### TO CONCLUDE

- Patients presenting with peritonitis and severe contamination constitute the most common indication for ostomy, followed by patients with malignancy presenting as intestinal obstruction.
- Ileal perforation was found to be the most common cause for patients presenting with peritonitis who needed ostomy.
- Ileostomy, especially split ileostomy, the most common ostomy performed.
- Peristomal ulceration (skin irritation) – was found to be the most common complication of ostomy.
- Ostomy was found to be a life saving procedure especially so in moribund patients presenting late in the course of illness.

**PROFORMA**



## **PROFORMA**

NAME :

AGE :

SEX :

IP NO :

DATE OF ADMISSION :

DATE OF SURGERY :

DATE OF DISCHARGE :

COMPLAINTS :

H/O. PRESENT ILLNESS :

PAST H/O :

PERSONNEL H/O. :

FAMILY H/O. :

TREATMENT H/O. :

GENERAL EXAMINATION :

SYSTEMIC EXAMINATION : Abdomen

P/R :

### **INVESTIGATIONS**

- BLOOD BIOCHEMISTRY
- URINE ANALYSIS

- BLOOD TC, DC, Hb%
- WIDAL
- X-RAY CHEST PA VIEW
- X-RAY ABDOMEN – ERECT  
SUPINE
- ECG IN ALL LEADS

PROVISIONAL DIAGNOSIS

INTRA OPERATIVE DIAGNOSIS

TYPE OF OSTOMY MADE

POST OPERATIVE PERIOD – COMPLICATIONS

FOLLOW UP :

# BIBLIOGRAPHY

## **BIBLIOGRAPHY**

- Maingot's abdominal operation – 11<sup>th</sup> Edition – Michael J. Zinner and Stanley W. Ashley, 141 – 178.
- Essential surgical practice – Fourth Edition – Sir Alfred Cuschieri, Robert J.C. Steele, Abdool Rahim Moossa, 607-609
- Mastery of surgery – fifth edition – Jose E. Fisher 1439-1463, 1470-1473
- Sabiston text book of surgery – Eighteenth Edition 508, 509, 1379-1380.
- Schwartz's principles of surgery – Eight Edition 1071 – 1075
- World journal of medical sciences 1(2): 112-116, 2006  
Different surgical options and ileostomy in typhoid perforations  
Arshad M. Maliketal
- Keighley MRB and Norman S. Willams surgery of the anus, rectum and colon, 2<sup>nd</sup> edition volume 1, page 176 – 278.

- Abcarian H, Pearl R.K. Stomas, Surg. Clin North Am 68 : 1205
- Allen – Mersh TG, Thomas JPS, Surgical treatment of colostomy complications Br J Surg 1988, 45 : 416
- Browning GGP, Parks AG, A method and results loop colostomy Dis colon Rectum 1983;26:223.
- Corman ML, Veidenheimer MC, Collier JA, ileostomy complications prevention and treatment surg. 8:36
- Harries K, Owen C, Mills C et al. Acute stomal contact dermatitis or pemphigus. Br J Surg. 1977; 84;685.
- Leong APK, Londono – Schimmer EE, Phillips RKS, Life table analysis of stomal complications following ileostomy Br J Surg 1994; 81; 727.
- McLeod RS, Lavery IC, Leatherman JR, et al. Patient evaluation of the conventional ileostomy. Dis colon Rectum 28:152.
- Thomas JPS, Caecostomy and colostomy. Part I – Surgical procedures and complications. Clin Gastroenterology 11 : 285.

- Turnbull RB Jr. Management of ileostomy. Am J Surg 137:749.
- Winkler MJ, Volpe PA, Loop transverse colostomy, the case against, Dis colon rectum 1982; 25 : 321.

# MASTER CHART





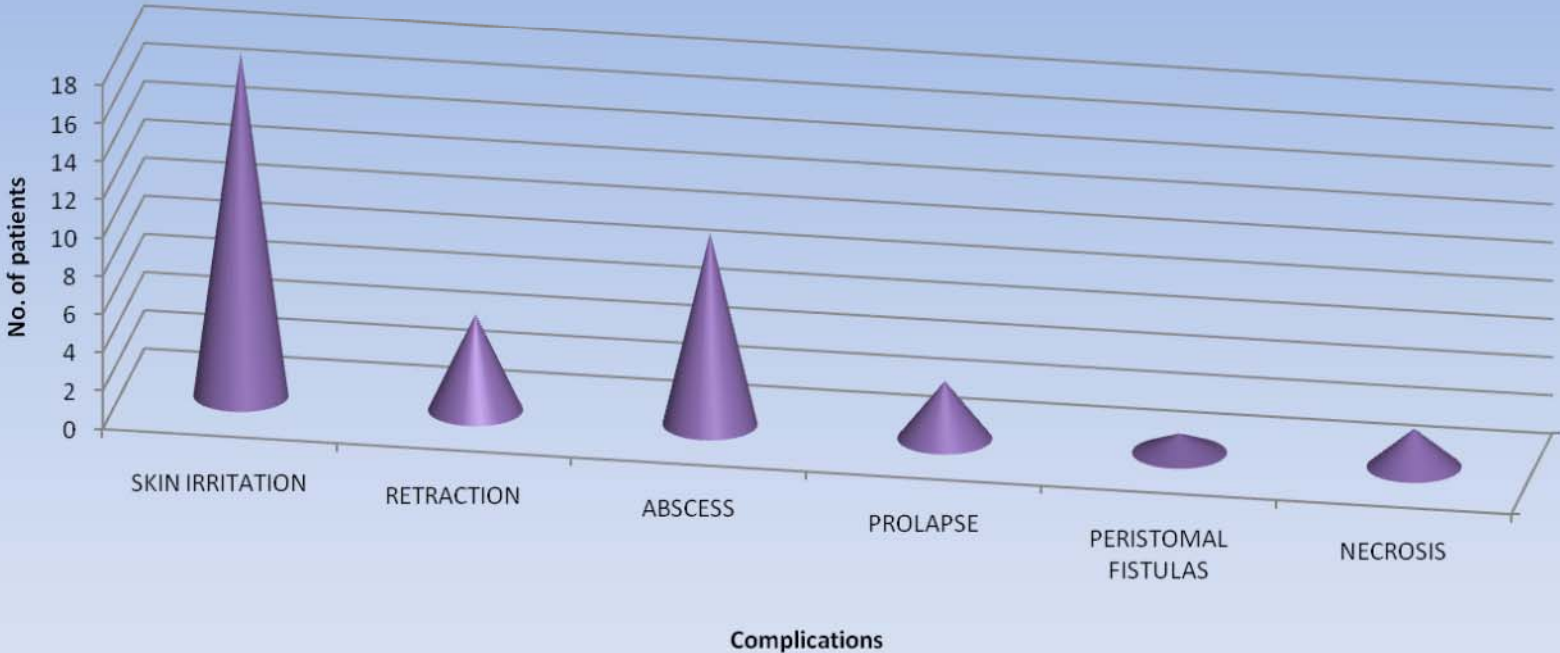
10	RAJENDRAN	48/M	921690	Intestinal obstruction	Sigmoid growth	(Lt.) Hemicolectomy Hartmann's procedure transverse end colostomy	Prolapse
11	VIGNESH	14/M	903849	RTA with Pelvic fracture	Rectal tear	(RT) Transverse loop colostomy	Retraction, abscess
12	SURESH	24/M	908321	Peritonitis	Ileal perforation	Split ileostomy	Skin irritation, abscess, retraction.
13	KUMAR	42/M	860985	Intestinal obstruction	Sigmoid growth	(Lt) Hemicolectomy resection and anastomosis Defunctioning transverse loop colostomy	Nil
14	SELVI	18/F	867086	Intestinal obstruction	Ileocaecal mass	Resection of mass ileostomy with mucous fistula	Skin irritation
15	SOKAMMAL	50/F	867717	Peritonitis	Gangrene bowel	Ileostomy with mucous fistula	Skin irritation
16	THULASI	40/F	870672	Peritonitis	Ileocaecal mass with perforation	Limited resection with ileotransverse anastomosis anastomotic leak, Ileostomy with mucous fistula	Skin irritation
17	MUNUSAMY	30/M	870179	Peritonitis	Post obstructed Hernia, Resection and Anastomosis , Anastomotic leak	Split ileostomy	Skin irritation, abscess

18	DANIEL	18/M	879291	Peritonitis	Ileal perforation	Anastomotic leak, split ileostomy	Skin irritation, Abscess
19	MURALI	44/M	880728	Peritonitis	Gangrene bowel	Split ileostomy	Skin irritation
20	INBARAJ	22/M	880133	Peritonitis	Ileal perforation	Resection and Anastomosis Anastomotic leak, Split ileostomy	Stomal Necrosis, Abscess, peristomal fistula
21	KASTHURI	53/F	840075	Intestinal obstruction	Sigmoid colon growth	Lt. Hemicolectomy end to end Anastomosis Defunctioning Transverse loop colostomy	Nil.
22	VENUGOPAL	50/M	839970	Intestinal obstruction	Carcinoma Rectum Inoperable	Transverse loop colostomy	Retraction
23	BABU	30/M	839941	Intestinal obstruction	Carcinoma Rectum Inoperable	Transverse loop colostomy	Prolapse
24	KALLEMULLAH	64/M	842675	Intestinal Obstruction	Sigmoid volvulus	Sigmoid end colostomy and mucous fistula	Retraction
25	IYAPPAN	20/M	846890	Peritonitis	Gangrene bowel	Jejunostomy with Mucous Fistula	Skin irritation, abscess
26	JAYARAJ	45/M	849345	Intestinal obstruction	Multiple ileal stricture with perforation	Split ileostomy	Skin irritation, abscess

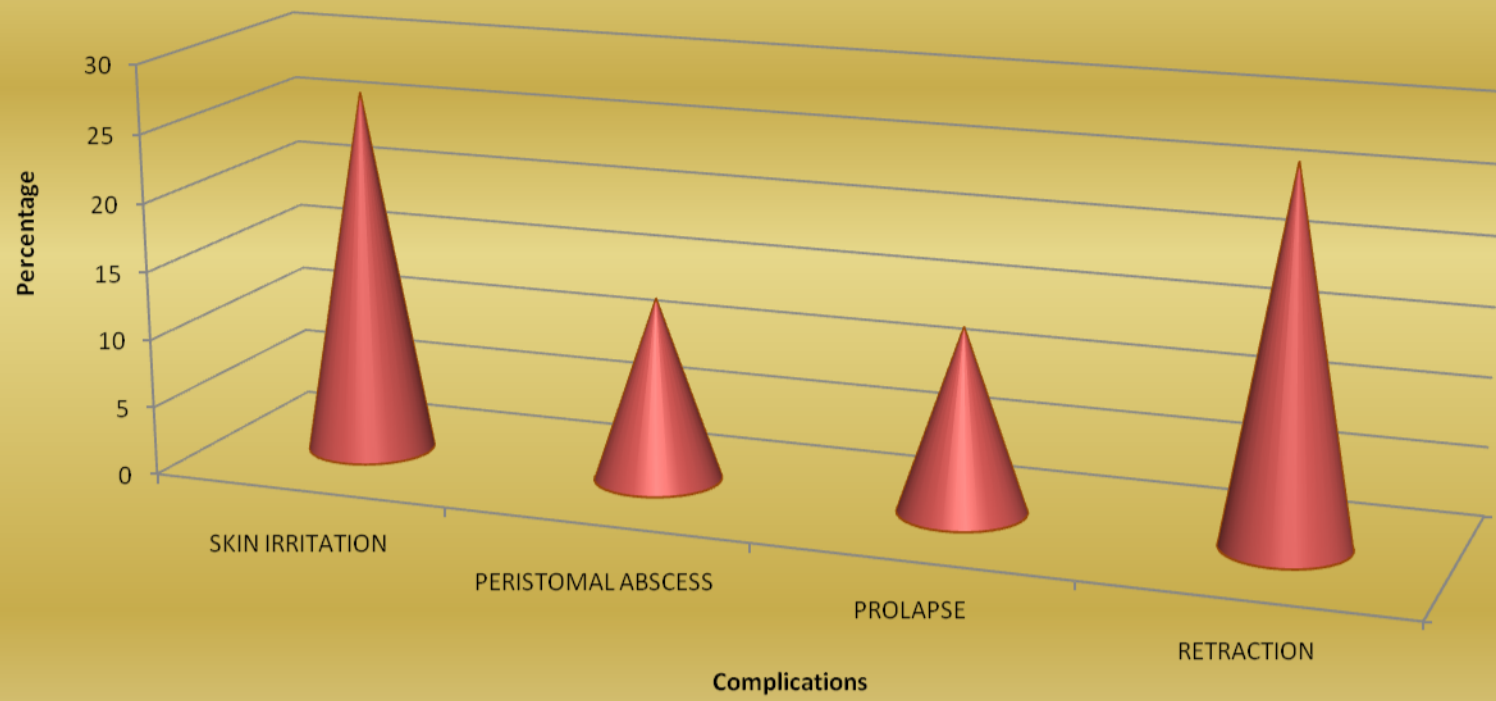
27	SRINIVASAN	25/M	852284	RTA with Pelvic fracture	Rectal tear	Diversion transverse loop colostomy	Skin irritation
28	PANDIYAN	54/M	853124	Intestinal obstruction	Carcinoma Rectum	Low anterior resection Defunctioning transverse loop colostomy	Nil
29	SUBBAMMAL	60/F	856258	Intestinal obstruction	Carcinoma Anal Canal	Diversion sigmoid loop Colostomy	Retraction
30	THILAGAVATHY	26/F	855920	Peritonitis	Ileocaecal mass with perforation	Limited resection and Anastomosis, Anastomotic Leak, Ileostomy with Mucous fistula	Skin irritation Abscess
31	MUTHU	57/M	859432	Peritonitis	Gangrene bowel	Jejunostomy with Mucous fistula of transverse colon	Skin irritation
32	KRISHNAMOORTHY	38/M	900150	Intestinal obstruction	Sigmoid volvulus	Transverse end colostomy with mucous fistula	Skin irritation
33	PENCILLAMA	52/F	892351	Peritonitis	Ileal perforation	Split ileostomy	Retraction
34	LAKSHMI	80/F	892099	Peritonitis	Ileal perforation	Split ileostomy	Nil
35	IYAPPAN	26/M	895064	Intestinal obstruction	Sigmoid growth	Transverse loop colostomy	Skin irritation
36	NANDAGOPAL	20/M	864513	Peritonitis	Ileal perforation	Split ileostomy	Nil

37	SUBRAMANI	65/M	865996	Peritonitis	Post strangulated Hernia, resection and anastomosis anastomotic leak	Split ileostomy	Skin irritation abscess retraction
38	SABIULLAH	45/M	876566	Peritonitis	Ileal perforation	Resection& Anastomosis Anastomotic leak, split ileostomy	Retraction
39	SARASWATHY	40/F	878462	Intestinal obstruction	Carcinoma Caecum,	Rt. Hemicolectomy Ileotransverse anastomosis Defunctioning loop ileostomy	Skin irritation, prolapse
40	SHANMUGAM	48/M	880282	Intestinal obstruction	Growth hepatic flexure	Rt. Extented hemicolectomy Ileotransverse anastomosis Defunctioning loop ileostomy	Prolapse
41	RAJAN	46/M	842853	Peritonitis	Ileal perforation	Split ileostomy	Skin irritation
42	MANIKANDAN	27/M	888418	Peritonitis	Ileal perforation	Resection with Anastomosis Anastomotic leak, split ileostomy	Skin irritation Abscess.

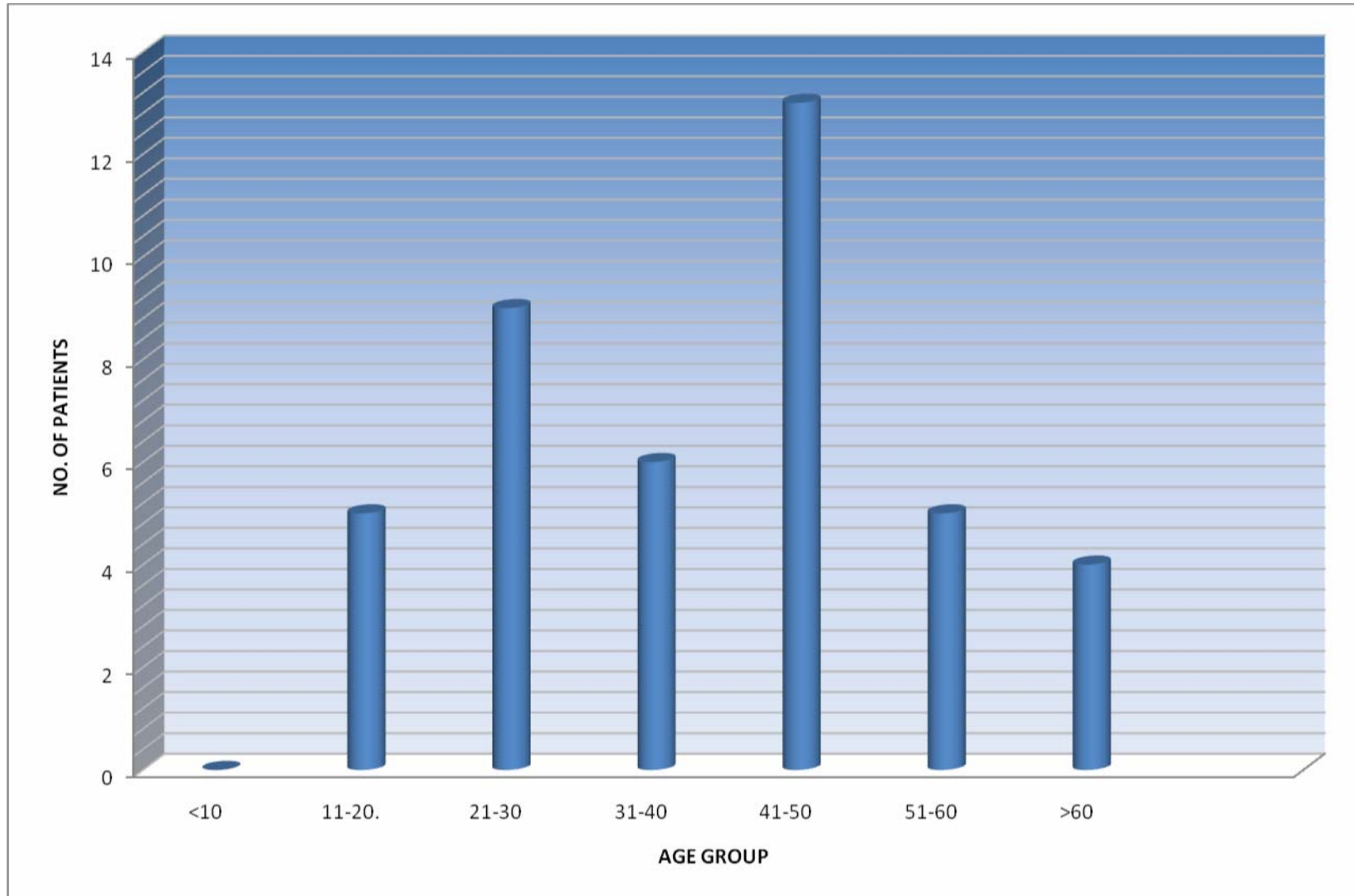
# ILEOSTOMY COMPLICATIONS



# COLOSTOMY COMPLICATIONS

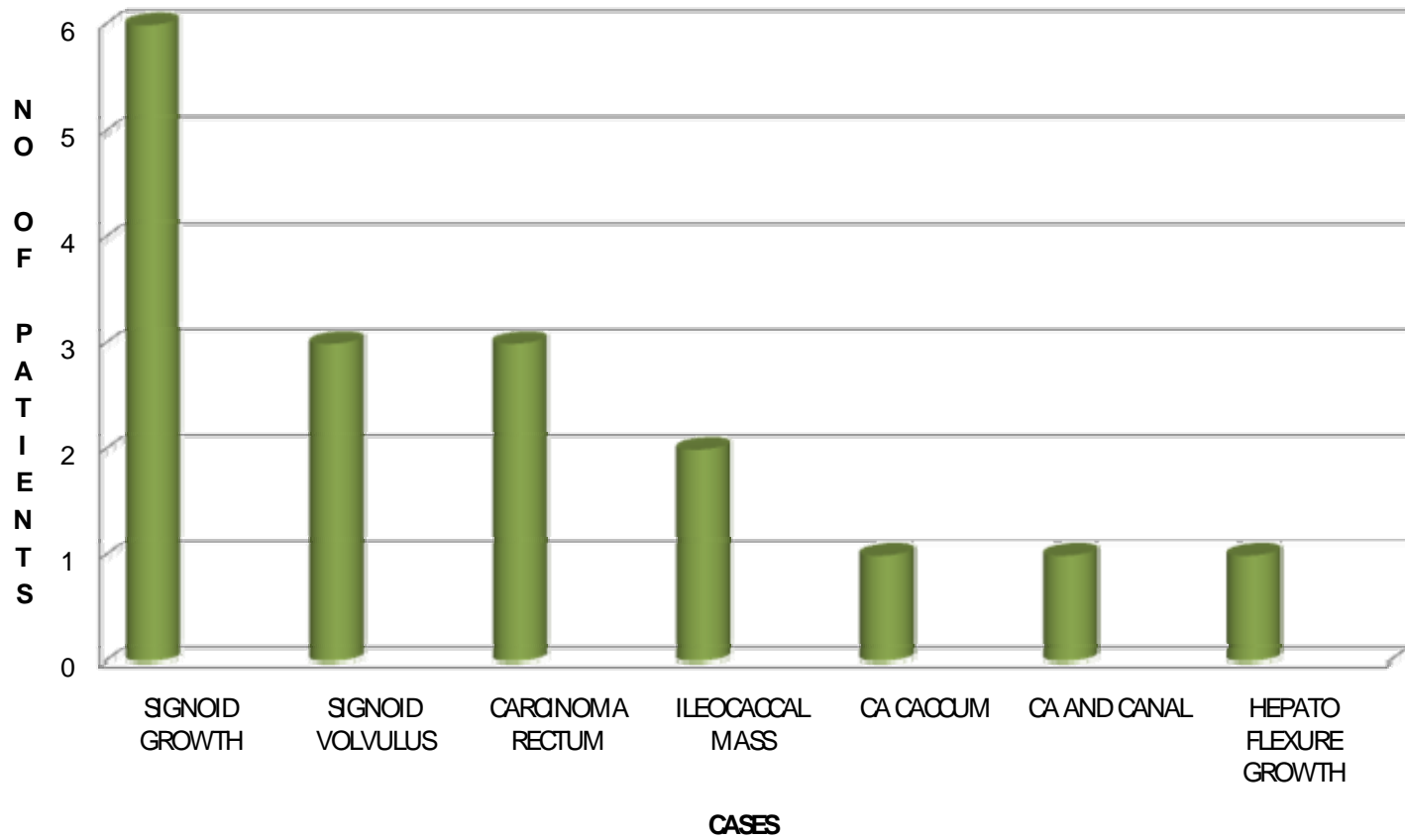


### AGE DISTRIBUTION

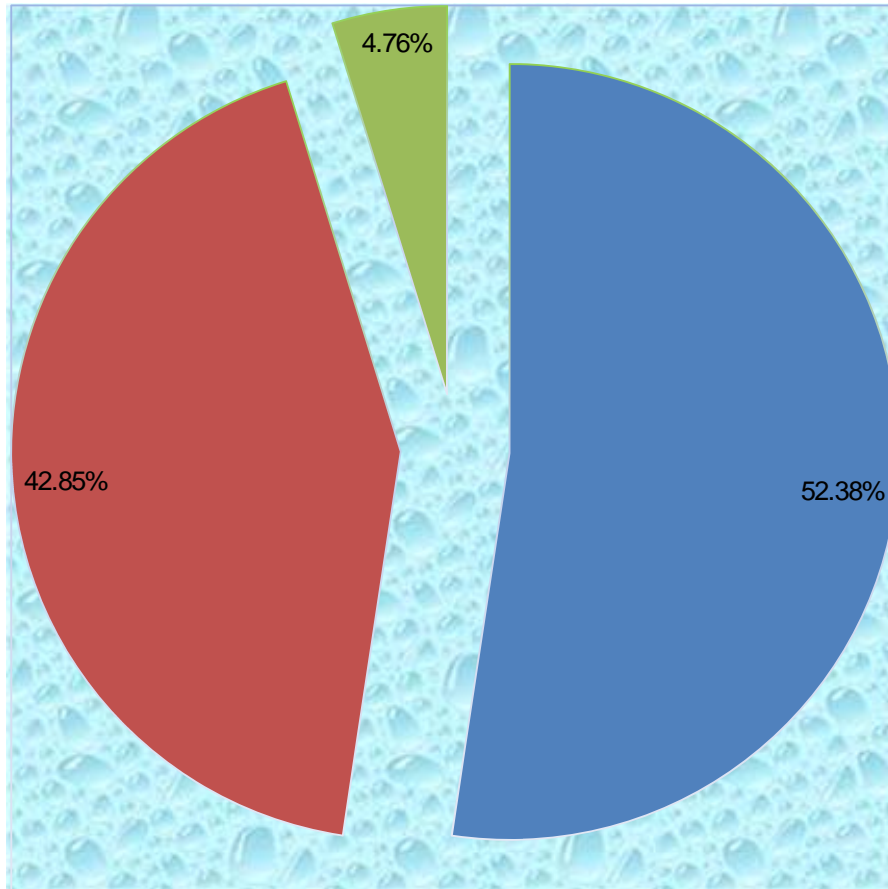




## CASES OF INTESTINAL OBSTRUCTION



## CASES PRESENTATION



■ PERITONITIS

■ INTESTINAL OBSTRUCTION

■ BLUNT INJURY ABDOMEN