

Dissertation

on

A COMPREHENSIVE STUDY ON CERVICAL LYMPHADENOPATHY

Dissertation Submitted to
the

**THE TAMILNADU Dr.M.G.R. MEDICAL UNIVERSITY
CHENNAI - 32**

*(partial fulfillment of the regulations
for the award of
the degree)*

**MS BRANCH - I
(GENERAL SURGERY)**



**KILPAUK MEDICAL COLLEGE
CHENNAI - TAMILNADU**

MARCH 2007

CERTIFICATE

This is to certify that this clinical work, A Dissertation on a Comprehensive Study on Cervical Lymphadenopathy is the original and bonafide work done by Dr. M. SIVAKAMI in the Department of Surgery, Govt. Kilpauk Medical College Hospital, Chennai, during the tenure of her course MS General Surgery from June 2004 to March 2007 under the regulation of The Tamilnadu Dr. M.G.R. Medical University, Chennai.

Prof. Mrs. ML.SHYAMALA
Chief Surgical Unit III
Kilpauk Medical College Hospital,
Chennai - 600 010.

Prof. K. KULOTHUNGAN,
Head of the
Department of surgery
KMCH, Chennai- 600 010

Prof. DR. THIAGAVALLI KIRUBAKARAN,
M.B.B.S., M.D.
Dean
Kilpauk Medical College
Chennai

ACKNOWLEDGEMENTS

I am thankful to The Dean, **Prof. DR. THIAGAVALLI KIRUBAKARAN**, M.B.B.S., M.D., Kilpauk Medical College, Chennai, for having permitted me to carry out the study at Govt. Kilpauk Medical College Hospital, Chennai.

I owe my sincere to **Prof. Dr. K. KULOTHUNGAN**, M.S., Professor of Surgery, Govt. Kilpauk Medical College Hospital, Chennai for having granted me permission, valuable advise and guidance to do this study.

My sincere and deep sense of gratitude for Prof. **Dr. M.L. SHYAMALA**, M.S., D.G.O., Chief Surgical Unit III, Govt. Kilpauk Medical College Hospital, Chennai for her guidance and supervision throughout this work.

It gives me great pleasure to express my deep sense of gratitude to my teachers and our unit Chief (Retd.) **Prof. A. NATARAJAN**, M.S., Kilpauk Medical College Hospital, for his help guidance and encouragement during the period of my study.

I wish to acknowledge **Prof. DR. EZHILVIZHI ALLAVANDAR**, M.D., Professor of Pathology, Kilpauk Medical College, for having allowed me access to all records and helped me to investigate the patient.

I wish to acknowledge my heartfelt gratitude to Assistant Professors **Dr. SRINIVASAN, M.S., Dr. DHAMODARAN, M.S., Dr. SELVAKUMAR, M.S., Dr. AFFEE ASMA, M.S., D.G.O.,** Surgical Unit III for their constant help, encouragement, and guidance to complete this study.

I am also thankful to all my post graduate colleagues and interns.

Last but not the least, I thank the patients without whom this study would not have been completed successfully.

CONTENTS

SI. NO.	TITLE	PAGE NO.
1.	INTRODUCTION	1
2.	AIM OF THE STUDY	4
3.	MATERIALS AND METHODS	5
4.	REVIEW OF LITERATURE	6
5.	OBSERVATION	50
6.	CASE DISCUSSION	53
7.	CONCLUSION	63
8.	BIBLIOGRAPHY	64
9.	ANNEXURE	

CERVICAL LYMPHADENOPATHY

INTRODUCTION

The cervical lymph node enlargement is the commonest swelling in the neck. Inflammation of cervical lymph nodes are exceedingly common and more so in the developing and underdeveloped countries and presents an enigmatic dilemma considering its varying import and in its management. Underlying its presentation though most of the cases are tuberculosis lymphadenitis or acute reactive hyperplasias, when it occurs in an elderly, one cannot be oblivious to the fact it can always be a secondary carcinomatous deposits.

In this country TB is still rampant and tuberculosis cervical lymphadenitis is still a common cause, occurring primarily in children. Absence of co-existing or primary pulmonary focus but the appearance of matted group of lymph nodes in the posterior triangle of a child or adult, who may or may not present with a constitutional

symptoms, though diagnostic but still demands a thorough investigation. Of all investigations FNAC has emerged as an important tool that is more confirmative and sensitive. It being simple and easier to perform needing meager experience in performing and consuming less time to perform can be done as an outpatient procedure without any morbid complications. It needs no preparation for sampling, but some cases may need more tissue for examination that may require a tru-cut biopsy or excision biopsy. FNAC remains the prime mode in differentiating benign from malignant cause of cervical lymphadenopathy.

In older ages malignant deposits warrants the search for primaries in upper aero digestive system, occult primaries in nasopharynx, oropharynx, Hypopharynx and thyroid etc.

Cervical lymphadenopathy may rarely be a part of generalized lymphadenopathy like Hodgkin's lymphoma or non-Hodgkin's lymphoma or sarcoidosis etc.

In a myriad of causes ranging from a simple benign enlargement to a disastorous malignant deposits, cervical lymphadenopathy cannot be considered as the condition to

be ignored. This study of cervical lymphadenopathy has been performed in an attempt to define the incidence of various etiological factors of presentations and to formulate the diagnostic approach and treatment mode in a given setup and facilities available.

AIM OF THE STUDY

- To study the incidence of cervical lymphadenopathy.
- To analyze the presenting symptoms of different causes of cervical lymphadenopathy.
- To study the appropriate diagnostic approach and treatment modality of cervical lymphadenopathy.
- To discuss the conservative and surgical management of cervical lymphadenopathy.
- To study the commonest secondary metastatic deposit and occult primary in cervical lymph node.

MATERIALS AND METHODS

All cases included in this study had presented to the surgical department either as outpatients or as inpatients. These patients were studied systematically and followed carefully based on protocol formatted and the relevant parameters were noted.

This study was prospective study period of three years between June 2004 to September 2006.

This patient symptoms, duration of illness, clinical findings were noted and baseline investigations and confirmatory diagnostic test were performed.

ENT, upper GI Endoscopy, Bronchoscopy, as conditions applied were done and treatment modalities adapted accordingly.

REVIEW OF LITERATURE

Cervical lymph nodes are composed of lymphoid tissue located along the lymphatic vessels in the Neck. There are 800 lymph nodes in the body and no fewer than 300 of them are in the neck embedded in the soft tissues of the Neck either partially or completely surrounded by fat.

Enlargement of cervical lymph nodes are more commonly due to infection than malignant diseases or deposits. A normal lymph node is 3 mm Size or size of pinhead and is clinically impalpable. Cervical lymph nodes are often the presenting feature of generalized lymphadenopathy.

ANATOMY

Waldeyer had earlier classified the nodes graphically into one vertical chain of nodes on either sides (deep cervical lymph nodes) and two horizontal circles namely the outer and the inner rings (of Waldeyer's). Inner rings comprises the tonsils (palatine or lingual), lymphoid tissues around the Eustachian tube and adenoids. The outer ring comprises the sublingual, sub-mental, sub

mandibular, jugulo-digastric (upper deep cervical), retro pharyngeal, parotid, facial, preauricular, retroauricular and the occipital group.

The main lymph node in the neck called deep cervical lymph node is all arranged vertically along the carotid sheath and IJV and they drain the afferent lymph nodes from various lymphatic zones. They are broadly divided into superior, middle and inferior deep cervical groups.

In order to establish a consistent & reproducible description of regional cervical lymph nodes now its customary to describe the cervical nodes by levels. This system divides the lymph nodes in lateral aspect of neck into VII levels.

Level-I submental group

The Nodal tissues between the anterior bellies of digastrics and cephalad to hyoid bone (Submental triangle). They drain the central part of lower lip, central part of floor of the mouth and some lymph from the tip of the tongue.

Level I Sub mandibular group

Nodal tissue in the triangular area bounded by the anterior and posterior belly of the digastric and the inferior border of body of the mandible. They are under deep fascia in contact with the sub mandibular salivary glands. One of these nodes lie in the “S” bend where the facial artery crosses the mandible. Small lymph node may actually be embedded in the sub mandibular gland substance and parotid salivary gland.

Sub mandibular nodes drain

- a. Side of nose
- b. Inner angle of eye
- c. The cheek
- d. Angle of the mouth
- e. Whole of upper lip
- f. Outer part of lower lip
- g. Gums
- h. Some afferents from sub mental group
- i. Some lymph from the side of the anterior 2/3rd of tongue
- J. Paranasal sinuses

Level II (Upper Jugular Group)

Upper deep cervical (Jugular) group lymph nodes around the upper third of the jugular vein and the adjacent spinal accessory nerve extending from the level of base of skull to the carotid bifurcation and includes the tonsillar node, that drains the posterior 1/3rd of the tongue, oro and nasopharynx, tonsils. Anterior border is lateral limit of sternohyoid muscle posterior border is sternocleidomastoid.

Level III (Mid Jugular Group)

Middle deep jugular group nodes around the middle third of the jugular vein extending from the level of the carotid bifurcation superiorly to the cricothyroid notch inferiorly or crossing of inferior belly of omohyoid drains the pyriform fossa, post-cricoid region, thyroid, larynx and includes Jugulo omohyoid nodes.

Level IV (Lower Jugular Nodes)

Lower deep jugular group lymph nodes located around the lower third of internal jugular vein extending from the cricothyroid notch to the clavicle.

Level V (Posterior Triangle Group)

Posterior triangle group nodes located along the lower half of the spinal accessory nerve or the transverse cervical artery, bounded by clavicle, posterior border Sternocleidomastoid, trapezius anterior border. The supra-clavicular (Virchow's) nodes is also located in this group.

Virchow's nodes are left supraclavicular nodes located in relation to the termination of the thoracic duct at the confluence of the internal jugular and sub clavian vein, in front of the scalene muscles, and is best palpated between the sternal and the clavicular heads of the sternocleidomastoid muscle against the back ground of scalene muscles either by standing behind or in front of the posterior triangle. Involvement of lymph node indicates advanced malignancy of abdominal / thoracic viscera (Trousier's sign), stomach being the commonest organ. Others are breast, lungs, esophagus and testis.

Level VI (Anterior Compartment or Visceral Group)

Anterior compartment group lymph nodes in relation to the midline structures of the neck extending from the

hyoid to the suprasternal notch between the two sternocleidomastoids draining the parathyroid, paratracheal, prelaryngeal, precricoid lymph node and the suprasternal space of Burns consists of superficial and deep sets of nodes.

Level VII

Tracheo-esophageal groove and superior mediastinum.

Superficial groups

Lies in relation to the IJV, draining the skin of the neck.

Deep groups

Consists of

- a. Infrahyoid lymph nodes – lie on the thyrohyoid membrane and drain the front of the larynx.
- b. Prelaryngeal nodes-these lie in the cricothyroid membrane and drain larynx and thyroid.

- c. Pretracheal nodes- these lie in relation to the inferior thyroid veins in front of the trachea and drain the thyroid and trachea.

Efferents of the Circular chain

The deep cervical nodes receive the lymph from the entire head and neck either directly or indirectly from the nodes of the circular chains. The lymph from the deep cervical chain i.e. all the lymph from the half of the head and neck is collected into one trunk, the jugular lymph trunk that leaves the inferior deep cervical nodes. On the right side the trunk enters the junction of Subclavian vein and IJV. On the left side the trunk enters the thoracic duct though it may join the IJV or the Subclavian.

The lymph node which are distributed in various regions of neck and are concerned with drainage of various tissues of head and neck are divided in to 2 groups.

- a. Regional lymph nodes which are concerned in drainage of superficial tissue of head and neck. They are arranged in circular manner from behind forwards as:

1. Occipital group.

2. Retro auricular or mastoid group.
3. Pre-auricular.
4. Parotid.
5. Buccal and facial.
6. Sub- mandibular.
7. Sub-mental,
8. Superficial and anterior cervical.

b. The regional lymph nodes which are concerned with drainage of the deeper tissues of the head and neck are

1. Retropharyngeal lymph node.
2. Para tracheal lymph node.
3. Lingual lymph node.
4. Infra-hyoid, pre laryngeal and pre tracheal lymph node.

Histology of the lymph node

Lymph node is encapsulated by fibrous tissue has cortical & medullary region, Cortex composed of densely packed lymphocytes forming spherical lymphoid follicles. Medulla consists of medullary cords, trabeculae, sinuses. Capsule inner surface of the capsule trabeculae forms frame work and shape of lymph nodes. Medullary trabeculae guide blood vessels and nerves to different regions of the lymph node. Medullary cords and sinuses composed of reticulum cells. Cords are parallel, long and irregular filled with lymph draining to the efferent lymphatic vessel. Paracortex area lymphocytes return to the lymphatics from blood. Main artery enters lymph node at the hilus branches into arterioles. Arterioles run along the trabeculae to the cortex supply the capillary bed of the medulla. Cortex arterioles gives capillaries to supply the lymphoid follicles has similar venous system. Venules converge to form small veins and the main vein in the medulla, leaves the lymph node at the hilus.

Functions of Lymph Nodes

Defence functions-filtration and phagocytosis. The structure of the sinus channels within the lymph nodes slows the lymph flow through them. This gives the reticuloendothelial cells that line the channels time to remove microorganisms and other injurious particles (soot) from the lymph and phagocytose them. Sometimes such large numbers of microorganisms enter the node that the phagocytes cannot destroy enough of them to prevent their injuring the node. An infection of the node, **adenitis**, then results. Because cancer cells often embolise from a malignant tumor and enter the lymphatics, they travel to the node, where they may set up new growths.

Hematopoiesis the lymphatic tissue of lymph nodes serve as the sites of the final stages of maturation for some types of lymphocytes and monocytes that have migrated from the bone marrow.

Significant lymph node enlargement

It is well known that soft, flat, non-tender cervical lymphadenopathy can exist without much clinical significance. A progressively enlarging tender and warm or hard node particularly with a primary disease in the drainage fields should be considered significant. Comparison with opposite side provides another important clue to their significance, hence lymph nodes on both sides should be examined even in unilateral disease.

Causes of cervical lymphadenopathy

I. Inflammatory

Reactive hyperplasia

II. Infective

Acute non-specific

Non-suppurative or pyogenic infections
(Streptococcus, Staphylococcus).

Acute specific

Tuberculosis, infectious mononucleosis, LGV

Chronic

Pyogenic, sarcoidosis

Specific

Bacterial : TB, Syphilis, brucellosis

Viral : LGV, Cat-scratch disease, HIV

Parasitological : Filarial, toxoplasmosis

Fungal : Histoplasmosis, coccidioidomycosis

III. Neoplastic

Primary eg., Lymphoma

Secondary eg., Squamous cell carcinoma, Adenocarcinoma and occult primary.

Acute lymphadenitis

Non-specific

This is the result of septic foci in drainage area and presents as painful, warm and tender lymph node enlargement and there may be associated general constitutional disturbances in the patients. The treatment

in first instance is directed to the primary focus of infection, example dental abscess is treated with antibiotics and NSAIDs. If despite antibiotic therapy pain continues or abscess formation occurs in the lymph node then surgical drainage may be required. The natural courses of the disease are:

- a. Resolution
- b. Suppuration
- c. Drift into chronicity

Acute Specific

This is seen in the conditions like filariasis, infectious mononucleosis, tuberculosis, lymphogranuloma venerium, and bubonic- plague. They are described under appropriate sections.

Chronic Non Specific lymphadenitis

Neck nodes are usually involved from smoldering sepsis in the teeth, tonsils or pediculosis capitus. Generally a painless or painful single anatomical group resolves with or without antibiotics. Common complication is abscess

formation causing difficulty in diagnosis with other types of chronic lymphadenopathy. Careful search warrants for a focus of sepsis in the scalp. ENT/dental examination should be routinely done and then two weeks course of broad-spectrum antibiotics is started. If abscess is suspected it is confirmed by needling or USG and drained by Hilton's method, collecting material for gram stain and culture and sensitivity. Total resolution can be expected with adequate local treatment and the focus of sepsis.

Chronic specific lymphadenitis

Tuberculosis

This is the commonest etiology among this group, affecting usually the young. The port of the entry for the organism-Mycobacterium tuberculosis, is the tonsils which then reaches the submandibular, sub mental, upper or middle deep cervical groups. The usual source of infection is either open primary tuberculosis or infected milk. Upper deep cervical are the most commonly affected in approximately 80% cases. The tuberculous process is limited to the clinically affected group of lymph node but primary focus in chest must be suspected and investigated.

Pathology

Bacilli reaching lymph node excites formation of tubercles in the cortex of the lymph nodes. Tubercles consists of central caseation necrosis surrounded by lymphocytes, epithelial cells and giant cells, further by round cells and finally fibrosis. The giant cells or Langerhan's cells with lots of nucleii eccentrically placed in both the poles are typical but not pathognomic of tuberculous process basically of foreign body type seen in other granulomatous disease.

The inflammation spreads to adjacent nodes causing periadenitis responsible for the classical matting of nodes. Caseation softens the nodes, pus coming out of them forms a cold abscess giving typically a variable consistency.

Other causes of cold abscess

- a. Actinomycosis with multiple abscesses
- b. Syphilitic gumma may present as lymphadenopathy rarely
- c. Hansen's disease in this condition the lymph nodes breakdown rarely.

This happens especially after an acute lepra reaction that may present as a cold abscess. Initially developing under the investing part of deep cervical fascia the pus tracks out through the point of entry of vessels and nerves to lie in the subcutaneous plane forming the dumbbell or the collar stud abscess. If left untreated the overlying skin gets indurated and ultimately breaks down to form a sinus discharging serous fluid. Hypertrophy of skin with scarring around the sinus is called as scrofula derma.

Stages of tuberculous lymphadenitis

Stage	I	Solitary lymph node enlargement without matting
Stage	II	Matted lymph nodes
Stage	III	cold abscess.
Stage	IV	Collar stud abscess

Clinical Features

Most patients usually give a long history of lumps in the neck and usually seek advice because the lumps have become painful, may also present with, 20% discharging

sinus, 10% cold abscess, 10% are adherent to skin. Patient usually have negative chest radiography. 90% are unilateral. 90% involve only one group, commonest being the upper deep cervical followed by the sub mandibular and the posterior triangle. Diagnosis is by the positive tuberculin test, demonstration of AFB in biopsy and growth of Mycobacterium tuberculosis from the biopsy. Lymphoma can also coexist with tuberculous lymphadenopathy classically seen in patients under 25yrs as enlarged painful or painless nodes may or may not be associated with constitutional symptoms. On examination enlarged matted nodes are seen with or without signs of local inflammation such as redness, warmth and tenderness. It may be associated with other groups of lymph nodes like the mediastinal or mesenteric or the axillary groups of lymph nodes.

Investigation

Routine including Total count, Differential count, ESR, Mantoux, chest X-ray, immunoglobulins (IgA, IgG, and IgM) and PCR for antigen. FNAC and Excision biopsy of the node.

Biopsy

The lymph node on section shows translucent grayish patch in the early stage. As disease advances these becomes opaque and yellowish which result in necrosis and caseation. Microscopically tubercles will be seen which consists of epitheloid cells and giant cells having peripherally arranged nuclei in early stage. After one week lymphocyte with darkly stained nuclei and scanty cytoplasm makes this appearance. By the end of second week caseation appears in the centre of the tubercle follicle. Hence tubercle consists of central caseation surrounded by giant cells and epitheloid cells around which remains a zone of chronic inflammatory cells, example lymphocytes and plasma cells, around which are fibroblasts.

Treatment

Anti-tuberculous chemotherapy 6-12 months with 4 drug regime for 2 months, followed by 2 drugs daily for 4 months. Modified regime - some advice drugs for only thrice a week under strict supervision for 6 months. Lymph node usually responds to ATT by period of 4 weeks when it

doesn't respond the possibility of a co-existing lymphoma or drug resistant tuberculosis has to be entertained and further investigations that may be necessary would be a biopsy of another node.

Dots Chemotherapy

Category of treatment	Drugs
I	2(HRZE) ₃ 4(HR) ₃
II	2(HRZES) ₃ 1(HRZE) ₃ 5(HRE) ₃
III	2(HRZ) ₃ 4(HR) ₃

Excision Biopsy

1. Lack of response to chemotherapy or uncertainty in diagnosis.
2. Co- existing malignancy suspected
3. Surgical removal of tuberculous lymph node must be followed by completion of chemotherapy course.

In cold abscess nondependent drainage or needle aspiration done.

Syphilitic lymphadenitis

The lymph node in primary stage is extra-genital chancres occurring in lips are painful and matted. In secondary stage generalised lymphadenopathy occurs with mucocutaneous lesions such as ulcers in the dorsum of the tongue, angular fissure condylomas of the mucocutaneous junction may be noticed.

In tertiary stage lymph nodes are seldom involved. Special investigations that confirm the diagnosis are:

1. W.R. and Kahn test- positive usually
2. Demonstration of *Treponema pallidum* in dark ground illumination in specimen obtained from primary tissue
3. Specific *Treponemal* antigen test
 - a) *Treponemal* heamagglutination test
 - b) *Treponema palladium* immobilisation test.

Treatment

Penicillin, Tetracycline and cefatoxime may be used as an alternative in patients with hyper sensitivity.

Cat scratch disease

This disease was always associated with cats but in spite of the name there is not necessarily an evidence of a cat scratch or bite. There is usually a initial skin lesion which is often significant. Enlargement of lymph node becomes the main feature of this condition and is caused by a chlamydial organism akin to LGV know as Borttenella hensale. It doesn't warrant any treatment and is a self-limiting disease.

Infectious Mononucleosis

Glandular fever is an acute febrile disease in which the common features are fever, enlargement of lymph node, splenomegaly, sore throat, and appearance in blood of lymphocytes of unusual type. The generalized enlargement of lymph node is due to intense hyperplasia without loss of architecture. The sinuses are filled with lymphoid cells and macrophages. In almost every case there is enlargement of

cervical lymph node and those in the posterior triangle are also affected. The nodes are often painful and tender. Suppuration never occurs unless there is secondary bacterial infection.

Investigation

Lymphocytosis is very characteristic feature of this disease. Paul - Bunnell test is quite diagnostic.

NEOPLASTIC DISEASE OF LYMPH NODE

There are virtually no benign tumors in relation to lymph node; the malignant disease may be primary (lymphoma / leukemia) or secondary, the latter being more common.

Definition of positive nodes

By palpation positive nodes are greater than 1cm in diameter hard in consistency and fixed with spherical configuration.

By CT scan an ill defined or irregular bordered mass non- enhancing mass in the nodal area

> 1.5cm for jugulo digastric & sub mandibular nodes

> 1.0cm for all other cervical nodes

> 0.8cm for retropharyngeal nodes.

Grouping of 3 or more nodes in 6-15 mm range a central necrosis evidence with decreased density, obliteration of fat-line around the carotid sheath in a preoperative & pre irradiated neck.

The use of CT or MRI can reduce the risk of occult disease to 12%.

Lymphomas

The earlier classification of lympho-proliferative disorders into Hodgkin's disease, lymphosarcoma, reticulum cell sarcoma and giant follicle lymphoma (Bill Symmer's disease) has been replaced by the Rappaport classification based on therapeutic and prognostic consideration which may be simplified as follows

1) Hodgkins lymphoma (HL)

a) Lymphocytic predominant (earlier known as paraganuloma, carries best prognosis).

- b) Nodular sclerosis
- c) Mixed cellularity
- d) Lymphocyte depletion (worst prognosis)

2) Non Hodgkin's lymphoma (NHL)

- a) Well differentiated which may be lymphocyte or histiocytes or mixed
- b) Moderately differentiated
- c) Poorly differentiated
- d) Undifferentiated, a variant of Burkitt's lymphoma.

3) Hodgkin's sarcoma

Hodgkin's Sarcoma, has mixed histological and clinical behavior.

Hodgkin's disease (syn; Hodgkin's lymphoma (HL))

Pathology

This is the commonest lymphoma macroscopically except in the lymphocyte depletion type, the nodes remain

discrete and rounded with rubbery consistency, a fish flesh appearance on section, fixity to each other, occurring late in disease. Pruritis may be present due to skin involvement. The periodic fever (Pel Ebstein) considered to be due to necrosis at regular interval observed in high grade is neither constant nor typical of Hodgkin's disease. Histologically cellular pleomorphism and **Reed-Sternberg** cells are the important features in diagnosis besides eosinophilic infiltration. Reed-Sternberg cells are not malignant cells but with diagnostic and prognostic significance; more the cell worse the prognosis.

Hodgkins lymphoma rye classification was updated as Real which incorporates immunologic and molecular data divides hodgkins into two groups. Nodular lymphocytes predominant and classic hodgkins. WHO classifications has incorporated REAL concepts.

Originates in lymph nodes, presents with Contiguous spread axial involvement, Splenomegaly and Thorax NS HL.

Lymphocyte predominant

Nodal architecture is replaced by normal appearing small lymphocytes with infrequent Reed-Sternberg giant cells.

Nodular Sclerosis

Frequent barrels and collagenous septae with eosinophils, Plasma cells and lymphocytes in between. Occasional Reed Sternberg cells are seen.

Mixed Cellularity

Same as proceeding without bands and septa more Reed-sternberg cells seen.

Lymphocyte depletion

Nodal architecture is totally affected with abundant Reed-Sternberg cells minimal lymphocytes and disorderly fibrosis are seen.

Clinical Staging (Ann Arbor, Peter's Classification)

- Stage - I** Involvement of single group of nodes.
- Stage - II** Involvement more than 2 groups on one side of diaphragm
- Stage - III** Involvement of groups on either side of diaphragm.
- Stage - IV** Disseminated foci or multiple extra lymphatic involvement or one extralymphatic site, Liver or spleen may not alter clinical stage.

Involvement of extra lymphatic site (E) is denoted by Liver (H), Spleen (S), Bone marrow (M) Bone (O) or pleura (P) are indicated with appropriate suffices to them like I-E, II-ES etc. Each stage is subdivided depending on absence (A) or presence (B) of constitutional features such as fever, weight loss (>10-%), anemia, Pruritis and bone pain, is further subdivided. The present Modified system is Cotswolds classification.

Clinical features

It occurs in II-III decades with bimodal and mild male predominance. Usually cervical group, followed by axillary, and mediastinal groups are affected. Centripetal distribution is seen, with typical painless progressive enlargement of lymphnodes, with or without constitutional symptoms mentioned above. Unexplained phenomenon, local pain, induced by consumption of alcohol is a peculiarity occurring in this disease. Minimal enlargement of liver and spleen commonly seen.

INVESTIGATIONS

Blood examination for anaemia and eosinophilia. Specific studies include node biopsy, immunohistochemistry, chest X-ray, USG Abdomen, CT and MRI Scan of chest and abdomen, lymph Node Biopsy is for grading, Bone marrow biopsy and Peripheral smear.

Gordon's Biological test

Production of encephalitis in rabbits by intracerebral injection of the extract of the lymphnode of Hodgkins disease, is not routinely done.

Markers of Worst prognosis are

- Stage III & IV
- Tumor bulk
- Histopathology grade
- Presence of constitutional symptoms (B stage)
- Low hematocrit at presentation (Bone marrow involvement).
- High LDH (liver involvement).

Staging Laparotomy

Once very popular, but not performed owing to the advent of non invasive imaging methods. It is recommended only for the patients with histologically aggressive disease and without obvious infradiaphragmatic disease, when findings may alter stage / therapy / prognosis. Laprotomy consists of thorough exploration of all abdominal viscera and lymphnode, liver biopsy, splenectomy, iliac bone biopsy and in women median fixation of ovaries to keep them away from the radiation field. Now a days it has been replaced by radiological

interventions like CT/MRI scan abdomen and minimal invasive diagnostic laparoscopy.

Treatment

a) Role of chemotherapy in stage I & II

This is given in all stages, realizing the systemic nature of the disease. Cyclical combination chemotherapy for 6-9 months.

MOPP (mechlorethamine, vincristine prednisolone and procarbazine) as 1 line and ABVD as II line- (Adriamycin, bleomycin, Vincristine and Dacarbazine)

b) Role of radiotherapy

As curative up to stage III A including cervical, axillary, mediastinal, abdominal and ilio inguinal groups (Mantle or inverted Y field) protecting the vital organs with lead shields. Only palliative form of radiotherapy for III-B and IV stage.

- c) Role of surgery
 - i) To establish diagnosis
 - ii) Strictly localized and easily removable nodes may be excised for debulking advantage upto Stage I & II.

It is a highly radiosensitive and chemosensitive disease, with > 80% cure rate if treated earlier. The cause of death in lymphoma is due to Immunosuppression leading to opportunistic infection. Rarely converts into acute leukemia under the influence of cytotoxic therapy. Other complications include anaemia/ thrombocytopenia, pulmonary fibrosis, infertility. The second line (ABVD regime is preferred to MOPP by many because of the high risk of developing myelodysplasia or acute myeloid leukemia with the latter.

Management of advanced / Recurrent disease

Aggressive chemo-radiation, made possible by autologous bone marrow transplantation may be attempted to achieve cure (rarely) or remission(often). Complications of aggressive therapy are hypothyroidism, infertility,

avascular necrosis of femoral head, secondary neoplasms and neurological complications due to radiation or vincristine.

Treatment

HL MOPP

- Mechlorethamine - 6 mg/m² IV on 1 & 8 days.
- Oncovin - 1.4 mg/m² IV on 1 & 8 days.
- Procarbazine - 100 mg/ m² oral on 1-14 days.
- Prednisolone - 40 mg/m² oral on 1-14 days.

Second line ABVD

- Adriamycin - 25 mg/m² IV on 1 & 15 days.
- Bleomycin - 10 mg/m² IV on 1 & 15 days.
- Vincristine - 6 mg/m² IV on 1 & 15 days.
- Dacarbazine - 375 mg/m² IV on 1 & 15 days.

Once in every four weeks.

Non Hodgkins lymphoma

This neoplasm occur in older age group, centrifugal distributed often involves soft tissue and viscera. Firm to

Hard nodes with early fixity and carries a poor prognosis compared to Hodgkins lymphoma. Presents with generalised lymphadenopathy, noncontiguous spread involves waldeyers ring, mediastinal nodes with SVC syndrome, extranodal involvement like meninges, brain and GIT. Those with Non-Hodgkins lymphoma of Testis, paranasal sinuses and bone marrow have special predilection for CNS involvement, hence CSF analysis / cytology should be done in such cases.

The working classification of NHL is largely based on pattern (follicular or diffuse), cell type (small or large, lymphocytes, immunoblastic or lymphoblastic) and nuclear cleaving (small or large).

Tumor with follicular pattern, small lymphocytic type with. small-cleaved nucleus carries favorable prognosis. Earlier working formulation and Rappaport classifications were used. Followed by Real classification. Revised European American Lymphoma (REAL) classification based on clinical morphological, genetic features and surface markers has been proposed. The updated REAL classification is WHO classification.

Classification of Non-Hodgkin's Lymphoma

Working Formulation	Rappaport
<p>Low grade</p> <p>Small lymphocytic</p> <p>Follicular predominantly small cleaved cell</p> <p>Follicular mixed small cleaved and large cell</p>	<p>Well-differentiated lymphocytic</p> <p>Nodular poorly differentiated lymphocytic</p> <p>Nodular mixed lymphocytic and histiocytic</p>
<p>Intermediate Grade</p> <p>Follicular predominantly large cell</p> <p>Diffuse small cleaved cell</p> <p>Diffuse mixed small and large cell</p> <p>Diffuse large cell</p>	<p>Nodular histiocytic</p> <p>Diffuse poorly differentiated lymphocytic</p> <p>Diffuse mixed lymphocytic and histiocytic</p> <p>Diffuse histiocytic</p>
<p>High Grade</p> <p>Large cell immunoblastic</p> <p>Lymphoblastic</p> <p>Small noncleaved cell (Burkitt's lymphoma)</p>	<p>Diffuse histiocytic</p> <p>Lymphoblastic</p> <p>Diffuse undifferentiated (Burkitt's non-Burkitt's lymphoma)</p>

WHO Classification

B-cell lymphoma

Small lymphocytic

Plasmacytoid

Mantle Cell

Follicular

Small noncleaved (including Burkitt)

Large cell

T-cell lymphoma

Lymphoblastic

Anaplastic large cell (Ki-1)

NHL Management

CHOP REGIME

Cyclophosphamide 750 mg/m² IV on day 1

Hydroxydoxorubicin 50mg/m²IV on day 1

Vincristine 1.4 mg/m² IV on day 1 & 8

Prednisolone 100mg oral 1-5 days continued every 21 days.

Followup- once in 3 months for 2 years and once in 6 months thereafter. Each visit - Physical examination
Routine blood counts LFT-, CXR are performed during each visit.

Secondaries Neck

As oral and pharyngeal cancers are among the commonest cancers in India, secondary malignant lymphadenopathy of neck is extremely common. In the first 4 decades of life thyroid and nasopharyngeal malignancies are responsible, but beyond 50 yrs oral, pharyngeal and laryngeal cancers are the common site for metastatic neck nodes. Secondary involvement of node may also occur.

Clinical Features

Patients usually over 50 years of age except in papillary carcinoma of thyroid and in whole secondary metastatic lymph node may be seen in children and young adults. More common in men than women.

Presents usually with

- i) Painless swelling later with pain due to involvement of nerves and surrounding structures.

ii) General symptoms Eg., Anorexia, weight loss, weakness, etc.

iii) Depending on the site patients may have other complaints such as ulcer in the tongue, hoarseness of voice, nasal block, Epistaxis. If the primary is in the chest, patient may have cough or hemoptysis, if in abdomen may complain of dyspepsia or abdominal pain.

The precise location of glands may give clue to the site of primary tumour

- 1) Upper deep cervical group - Head and face, interior of mouth.
- 2) Middle and lower deep cervical - larynx, thyroid and the draining nodes.
- 3) Supraclavicular-thoracic, abdominal disease and breast.

The nodes are usually hard, irregular, discrete and of varying size, mobile early may be fixed later on.

Clinical Staging of cervical metastasis nodes

- Nx - Lymph nodes cannot be assessed
- No - No metastasis
- N1 - Metastasis in single node < 3 cm
- N2 - Metastasis within > 3 cms < 6 cms
- 2a - Metastasis single 3-6 cms
- 2b - Multiple 3-6 cms ipsilateral
- 2c - Bilateral 3-6 cms
- N3 - Anynode > 6cm & fixed.

Investigation

1. Biopsy of the primary
2. Laryngoscopy - Indirect and Direct laryngoscopy for the vallecula, epiglottis, and vocal cords has to be done, but they have several blind “spots” such as pyriform sinuses, sub glottis, larynx etc. Flexible radio guided pharyngolaryngoscopy is currently most popular and fool - proof investigation to detect / biopsy occult malignancy.

3. Bronchoscope - Bronchogenic carcinoma
4. Endoscopy - upper GI tract
5. FNAC - This has 90% sensitivity, and specificity for a neck mass. The largest node without necrosis should have chosen and report if equivocal, it may be repeated by using a wide bore needle (Tru-cut). The ideal approach is to complement the FNAC of the secondary with a biopsy of primary, though when one is positive, other may be superfluous but tissue from primary is always preferable than from metastatic site. Open biopsy should not be done, since scaring and interference with tissue planes may compromise the subsequent lymph node dissection if needed and by breaking the fascial barriers that holds the cancer invasion and also by increasing the chances of local recurrences. The usual cause of death in them is hemorrhage from carotid invasion due to local recurrence.
6. Imprint cytology in lateral aberrant thyroid in papillary carcinoma.
7. USG neck to identify the lymph node enlargement (cystic or solid) and calcification.

8. CT/MRI - deep-seated primaries such as Nasopharynx.

9. FDG PET scan to identify the primary and secondary neoplasm.

Cervical nodes with occult primary

The occult primary occurring 20% indicates the secondary metastatic node arise from primary that is too small to be clinically made out, Above 50% are squamous cell carcinoma, 25% are adenocarcinoma and rest 25% are anaplastic tumors. The occult primary in order of frequency are nasopharynx, tonsil, and base of tongue, thyroid, larynx, pyriform fossa, broncho-oesophagus and stomach. If above investigation is non revealing blank - blind biopsies from naso pharynx, tonsils, tonsillarbeds, base of tongue and pyriform fossa are performed, with more than 10% yield of detecting primary. But such wild goose chasing is obviated by use of CT/MRI in recent times.

Treatment of neck Secondaries

No-There is considerable debate regarding prophylactic neck dissection. Factors in favour of prophylactic nodal surgery.

1. Incidence of microscopic spread in No is around 10-15%.
2. Block dissection carries negligible mortality
3. Neck disease is the commonest cause of death in head and neck cancers.

Factors against such aggressive approach are

- a) Vast majority (85-90%) of them require neck surgery later
- b) Filtering advantage of node is lost in case of local recurrence or development of a second primary.
- c) Prophylactic surgery does not totally eliminate the possibility of later nodal secondaries.
- d) There is no hard proof that it improves over all survival.

Various types of Neck dissection

1. Comprehensive Neck dissection - resection of the Cervical Lymph, nodes from level - I to level V
2. Classical Radical Neck dissection - resection of I to V lymph nodes with nonlymphatic structures like IJV, sternocleido mastoid muscle and accessory nerve.

3. Modified radical neck dissection

I - Preserves Accessory nerve.

II- Preserves Accessory nerve and sternocleido mastoid muscle

III - Preserves preservation of all the non-lymphatic structures

Selective Neck Dissection

Supraomohyoid dissection - resection of level I,II,III.

Jugular Neck Dissection (Anterolateral) - resection of level II,III,IV.

Central Compartment neck Dissection - resection of level VI and anterior superior mediastinum.

Posterolateral neck Dissection - resection of level II,III,IV.

Extended Radical Neck Dissection includes resection of Retropharyngeal, parapharyngeal, Mediastinal and axillary lymph nodes with non-lymphatic structures like cranial nerves, carotid, Artery, muscles and skin.

Unilateral Lymph node (N1)

Functional neck dissection, sparing the sternocleidomastoid, the spinal accessory nerve and the internal jugular vein.

Unilateral Single/ multiple (N₂ a/b) (3-6 cm)

The treatment is modified radical neck dissection followed by pre-operative or postoperative radiotherapy depending upon the resected specimen.

Bilateral neck nodes under 6cm size (N2C)

These occur in 5% of cancer and are of unfavourable prognosis. If mobile, bilateral neck dissection at the same setting is an acceptable approach.

Nodes above 6cms and fixed (N3)

Palliative radio/chemotherapy (CCRT) is the only option available. In locally advanced disease without distant spread, this may down stage the disease allowing subsequent salvage surgery.

OBSERVATIONS

- Incidence for TB lymphadenopathy is high in 21-30 age group.
- The average age of cervical lymphadenopathy at presentation is 33.83 years.
- Neck secondaries incidence is high in males.
- Most common presenting symptom is swelling with or without pain (almost 100%).
- Most common group of lymph node involved is Upper deep cervical lymph nodes.

As a whole the percentage of group of lymph nodes, including all pathology, involved are listed below:

Level I	9%	
Level II	57%	75%
Level III	6%	
Level IV	12%	
Level V	15%	
Level VI	1%	
Bilateral and	25%	

- Slight preponderance for males; F:M:: 62:38.
- Tuberculous lymph node presented mostly at Stage I. Average duration of symptoms is 24 months and the commonest duration is one month.

FNAC is the most sensitive diagnostic mode.

Tuberculosis is the most common cause, being causative for 59% of cervical lymphadenopathy followed by malignancy 21%, reactive lymphadenitis 10% and inflammatory lymphadenitis 4%.

The percentage of involvement are listed below:

Tuberculosis C.LA	59%
Malignant C-LA	21%
Reactive lymphadenitis	10%
Non-specific lymphadenitis	5%
Inflammatory	4%
Cold Abscess	2%
Toxoplasmosis	1%

The percentage of groups of lymphnodes involved in tuberculosis are tabled below:

Upper deep cervical	55.9%
Lower deep cervical	10.1%
Supraclavicular group	10.1%
Middle deep cervical	6.77%
Posterior cervical	6.77%
Submandibular	5%
Submental	1.69%
Pretracheal	1.69%
Multiple and Bilateral	27.11%

Average duration of treatment response for tuberculosis was 25 days and for inflammatory lesions was 7 days.

CASE DISCUSSION

In this study and Analysis of 100 cases of cervical lymphadenopathy between JUNE 2004 and SEPTEMBER 2006, causes of adenopathy in descending order of frequency are tuberculosis, malignancy includes secondaries and primaries, reactive hyperplasia, chronic non specific lymphadenopathy, and acute cervical lymphadenopathy.

In general most common group of lymph node involved is level II, includes jugulo digastric lymph nodes (33/59). Next in the descending order of frequency is lower deep cervical (6/59), supraclavicular (6/59), posterior cervical (4/59), middle cervical (4/59), submandibular (3/59), submental and pretracheal (1/59). There were 16/59 cases involved in bilateral and multiple group of lymph nodes.

Usually presenting as a solitary swelling, next is multiple. The consistency of swelling at presentation is most commonly firm while hard in malignancy. Other symptoms associated with the swelling are dysphagia, change in voice, cachexia, cough, dental caries, nasal bleed, HOH, breast lump.

The chronic condition associated with lymphadenopathy were NIDDM (1), Human immunodeficiency virus infection (1), old pulmonary tuberculosis (5) or generalized tuberculosis lymphadenopathy (1), chronic tonsillitis (3).

With baseline investigations the ESR done in all cases showed a consistent rise which was mild to moderate. Mantoux done in all cases, was found less specific and less sensitive as part of investigation concerning tuberculosis.

X-ray chest was done in all chronic case when symptoms exceeded a month, as screening procedure and as retrospective one when FNAC was found positive for tuberculosis, chest X-ray helped to study the mediastinal widening in lymphoma and help to pick up the primary tumor in the lung in a secondary node and mediastinal nodes in Bronchogenic carcinoma, old healed/active PT in tuberculosis lymphadenitis.

FNAC

Fine needle aspiration cytology, which remained the prime diagnostic mode. It remained diagnostic in 94% of cases, requiring only repeat FNAC in 6% of cases or biopsy

for diagnosis in 5% of cases. The sensitivity in diagnosing the cervical lymphadenopathy with FNAC was 95%.

The sensitivity and specificity remained high in diagnosing malignancy and biopsy for primary needed only for further information.

FNAC was diagnostic in 58 out of 59 cases of Tuberculous cervical lymphadenopathy, requiring only biopsy in 1 case. FNAC needed further biopsy in 10 cases of study was mostly of acute and chronic non-specific inflammatory lymphadenopathy and reactive hyperplasia, which only needed a week of antibiotic and followup for symptomatology. Out of 59 cases repeat FNAC was done in 6 cases because of unsatisfactory yield or poor fixation of smear.

ENT Examination

This includes clinical evaluation, direct and indirect laryngoscopy for complete research for primary focus of infection and mainly to identify the primary in secondary carcinomatous deposits in the throat especially in searching for occult primary in Nasopharynx, Oro- and Hypopharynx.

TRIPLE SCOPY

Triple scopy includes upper GI endoscopy, bronchoscopy and laryngoscopy mainly advocated in identifying an occult primary.

BIOPSY

Excision biopsy which is more confirmatory when the FNAC is inconclusive and was done only in 5% of cervical lymphadenopathy for diagnosis confirmation.

Tuberculous cervical lymphadenopathy

The average age incidence is 33.83 years. Tuberculosis forms the major etiology for cervical lymphadenopathy, accounting for about 59% of all cases. It presented mostly commonly as a swelling arising from the same group of nodes. Next common associated symptoms are pain followed by fever. The constitutional symptoms are rarely present in tuberculous cervical lymphadenitis. Contact of family history in cervical lymphadenopathy is insignificant and almost insignificant in influencing the etiology. History of similar complaints of pulmonary tuberculosis is reported only in 5 cases.

The most common group of lymph node involved in this entity is those in upper deep cervical 33 out of 59 cases followed by supraclavicular 6 out of 59, lower deep cervical 6 out of 59, middle cervical 4 out of 59, posterior cervical 4 out of 49, submandibular 3 out of 59, representing 55.9%, 10.1%, 10.1%, 6.77%, 6.77%, and 5% respectively. At presentation lump in decreasing order of frequency are upper deep cervical jugular, supraclavicular, lower deep cervical, middle cervical, posterior cervical, submandibular, submental, bilateral and multiple in 16 out of 59 cases (27.11%).

TB LN 43 out of 59 cases presented in 72.88% as solitary swelling and 16 out of 59 cases (27.11%) as multiple swellings. Of multiple lymph nodes 3 out of 16 were discrete that is 18.75 % and 13 out of 16 were matted (i.e. 81.25%).

The most common consistency of cervical lymphadenopathy at presentation was firm, being 62 out of 100 cases. 23 out of 100 cases were soft and 14 were hard. 1 variable (firm to hard). Of the firm 48/62 were tuberculous (i.e. 77.41%). 4/62 out of 10 were reactive hyperplastic and acute lymphadenitis 2/4 (50%). Cold abscesses 2 out of 59, were cold abscesses.

1 presented with variable firm to hard lymph node and was malignant lymph node.

Among the 59 cases with TB LN 1 was associated with HIV infection; five were old PT, one was associated with generalized LN, 2 recurrent/resistant TB LN. 1 presented with scrofuloderma (multiple sinuses), and one with NIDDM. The change in voice, cough with hemoptysis, hard of hearing, epistaxis were associated with carcinomatous deposits.

While investigating, ESR was raised in almost all tuberculous and carcinomatous lymphadenopathy. While it was insignificant in reactive hyperplasia and abscess.

Mantoux in tuberculous LN was positive only in 10 out of 59 and represents sensitivity of only 16.9% of cases.

Chest X-ray of TB LN with positive finding i.e associated with pulmonary TB in 4 cases, 1 was associated with HIV and with active PT and 3 with old PT. CXR in secondaries neck, did not showed positive findings hence was less specific in adding points to diagnosis.

FNAC was diagnostic in 58 out of 59 patients needing biopsy only in 1 cases hence was 98.3% specific as far as TB lymphadenitis is concerned. For malignant FNAC was diagnostic in 20 out of 21 carcinomatous deposits and one needing excision biopsy. One primary tumour needed biopsy for confirmation of diagnosis and the assess the grade. Primary malignancy was NHL 3 and HL 1 as a part of generalized lymphadenopathy. Hodgkins disease one case was on ATT for 6 months

NPC -3	Tongue CA- 1
Thyroid CA - 2	Vallecula CA - 1
PF CA - 2	Esophagus CA -1
Metastatic carcinoma unidentified - 3	Lung CA - 1
Breast CA - 1	Non Hodgkin's lymphoma 3
Pancreatic CA - 1	1 was Hodgkins lymphoma
Tonsil CA- 1	

Of 21 malignant cases of LN enlargement NP CA - 3, Thyroid CA - 2, PF CA - 2, Metastatic carcinoma unidentified - 3, breast CA - 1, pancreatic CA - 1, Tonsil CA- 1, Tongue CA- 1, Vallecula CA - 1, Esophagus CA -1, Lung CA - 1 were due to secondary deposits, 3 was Non

Hodgkin's lymphoma and 1 was Hodgkins lymphoma. Biopsy confirmed all inconclusive diagnoses, investigated by FNAC. ENT malignancy constitutes of 8 out of 21 cases 38% of involvement and 8% for 100 cases. Papillary carcinoma thyroid includes 2 out of 21 cases 9.52% of involvement and 2% per 100 cases.

All primary lesions were confirmed either by Bronchial brushing cytology or USG guided FNAC for lung carcinoma (SCC).

Three occult primary was thoroughly investigated with triplescopy and CT Scan abdomen for adeno carcinoma 2 cases, and scopy for Squamous cell carcinoma 1 case.

Treatment

Acute lymphadenitis - Antibiotic, analgesics and followup

Chronic NS lymphadenopathy - Reassurance, antibiotics and analgesics

Abscess-acute - Incision and drainage and antibiotics

Cold abscess - Nondependent needle aspiration followed by ATT for 6 months.

Tuberculous LN - ATT (revised regimen) 4 drugs/ weekly 3 days for 2 months and 2 drugs a/d 3 days for the next 4 months.

SECONDARIES NECK

Modified radical neck dissection with total thyroidectomy for papillary carcinoma with suppressive dose of eltroxin (0.2 to 0.3 mg/day) with calcium gluconate.

Breast carcinoma, Neoadjuvant chemoradiation followed by modified radical mastectomy and hormone therapy (Anastrozole).

In advanced Neck Secondaries

External palliative RT for secondary and primary

External palliation RT for occult primary

NPC - 6000-6500 rads including primary

Hypo pharynx and

oropharynx	-	6000-7400 rads
GIT	-	Pancreatic carcinoma Gemcitabine, chemoradiation
Lung	-	Palliative RT

NHL - Chemotherapy - CHOP regime

Cyclophosphamide 750 mg/ m² IV on day 1

Hydroxy doxorubicin 50 mg/m² IV on day 1

Vincristine 1.4 mg/ m² IV 1 & 8 day

Prednisolone 100 mg oral for 1 to 5 days for 21 days
cycle with 14 day rest period for 6-9 months.

Hodgkins Lymphoma

Adriamycin - 25 mg/m² IV on 1&15 days.

Bleomycin - 10 units/ m² IV on 1&15 days.

Vincristine - 6 mg/m² IV on 1& 15 days.

Dacarbazine - 375 mg/m² IV on 1 & 15 days.

Then follow up once in 3 months for 2 years and 6
monthly thereafter.

CONCLUSION

Most common cause of cervical lymphadenopathy is tuberculosis.

Most common group of lymph nodes involved is level II which correlates with the literature followed by level V/IV.

Cervical lymphadenopathy occurs with female preponderance including tuberculosis. FNAC is the simplest and most cost effective mode in diagnosing the etiology of cervical lymphadenopathy except lymphoma which required excision to assess the grade of the tumour.

Tuberculous patients were treated with ATT & Modified radical neck dissection for mobile occult primary and palliative RT for advanced neck secondaries.

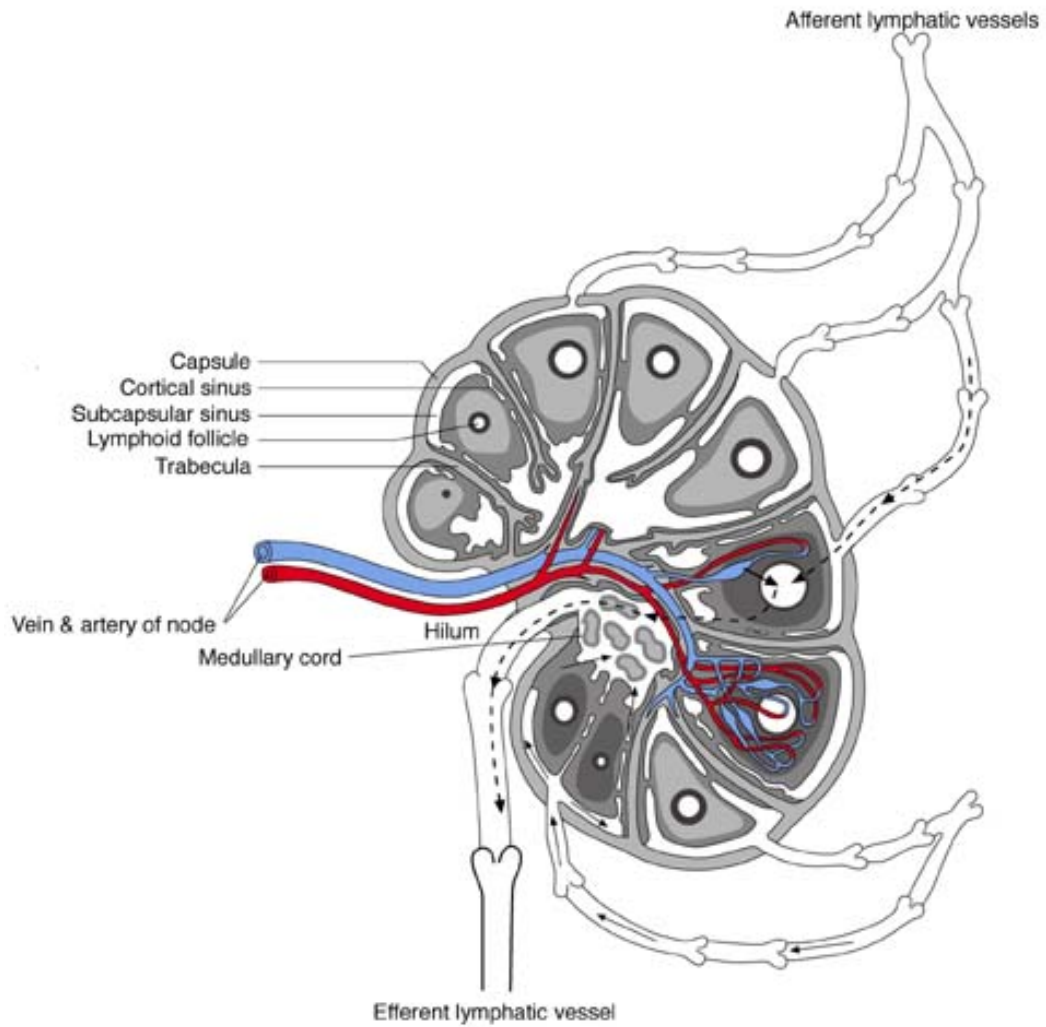
The most commonest cause for malignant cervical lymph node enlargement is due to naso, oro & hypopharyngeal carcinoma. Thyroid malignancy presented as lateral aberrant thyroid.

Inflammatory breast carcinoma presented with supraclavicular metastasis.

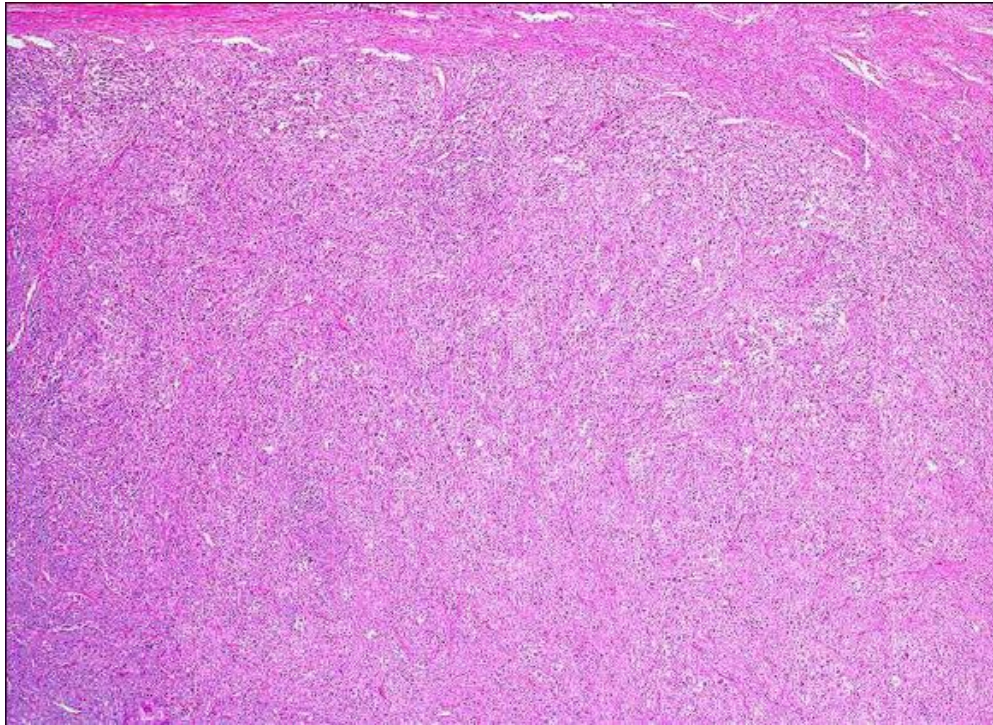
BIBLIOGRAPHY

1. Spiro R.H. Derox. G and strong E.W. (1983).
2. Stell and Marani Head and Neck surgery
3. Van Hasselt CA and Glbb, A.G. (1991)
Nasopharyngeal carcinoma.
4. Stell P.M. Dally J.E, Singh, S.D. et al (1984).
5. Cushieri. Aa dn Forbes (1992)
6. Donaldron S.S. and link.M.P. (1991)
7. Robins pathology basis of diseases - 5th colitis. Diness
of white cells, lymph nodes and spleen.
8. Lymph Node & Spleen - Principle and practice of
surgical pathology and cytopathology.
9. Aspiration and imprint cytology, preparation and
cytopathology, lymnh node - Atlas of differential
diagnosis in cytopathology, Atkinsis and sluerman.
10. Text book of surgery - by Sabiston. The lymptatic
system.

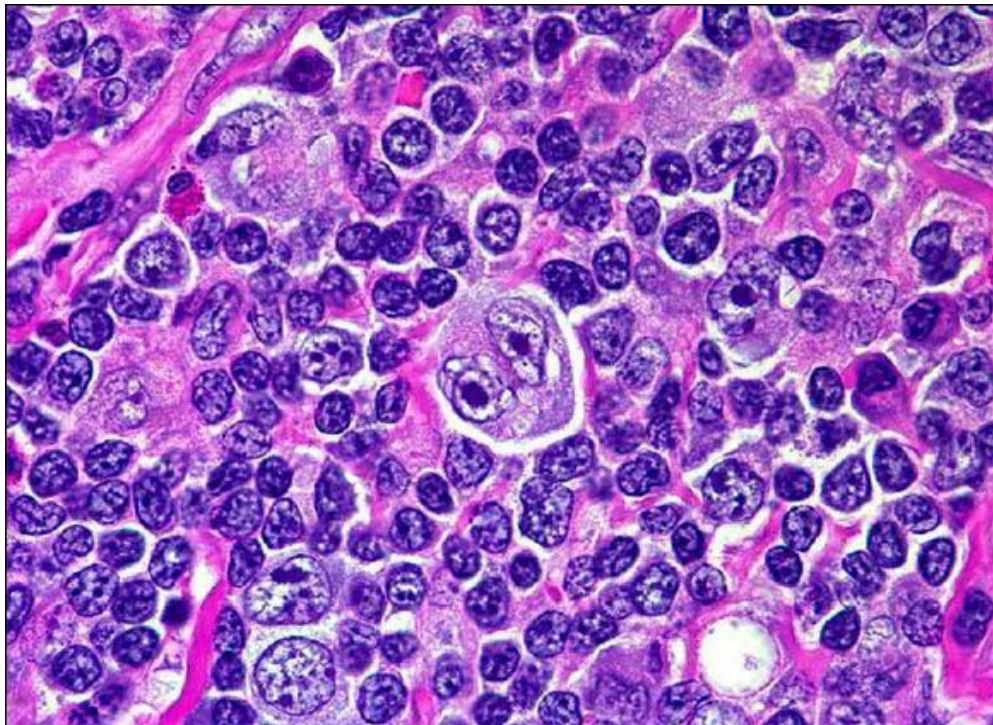
11. Surgical short cases - CM. Reddy and J.S. Rajkumar.
12. Oxford Text book of surgery -Morris and wood.
13. Hibbert, J. (1997)Scott Braun oto laryngology
14. American journal of Surgery, 146.
15. Bailey and love's short practice of surgery
16. Reede D, Som P. Lymph Nodes. Som and Bergeron Editions of Head and Neck Imaging: 2nd Edition, St.Louis, Mosby, 1991.
17. Lymph Nodes; Acker man's surgical pathology 2000, Vol.2.
18. A practical grade to pathology with cytological combination - spinger and verlof- 1991.



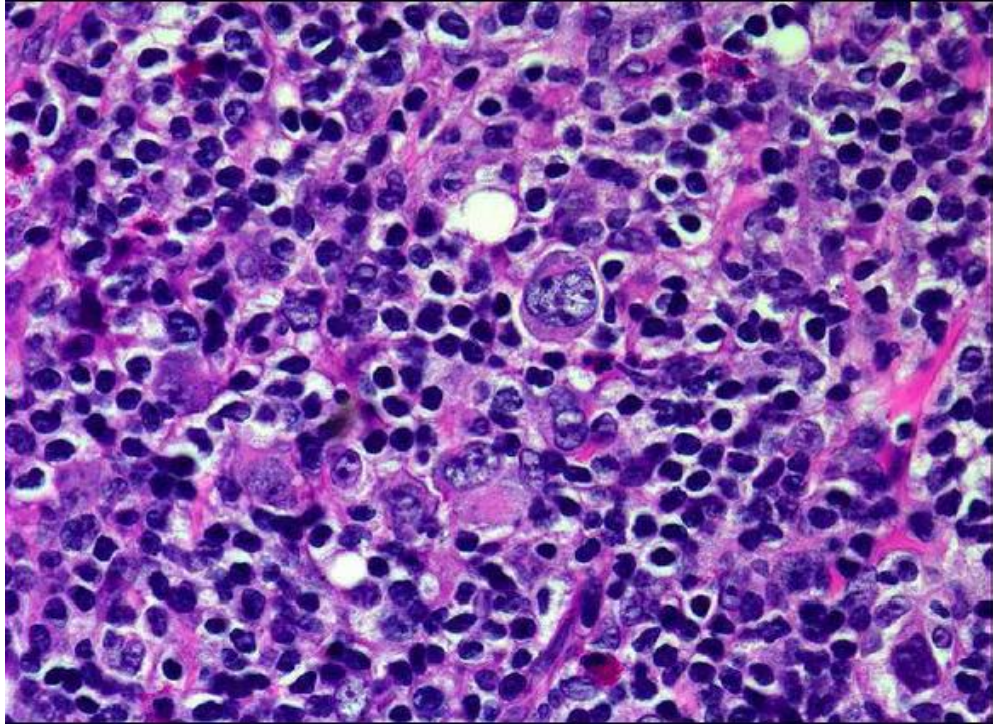
Lymph Node



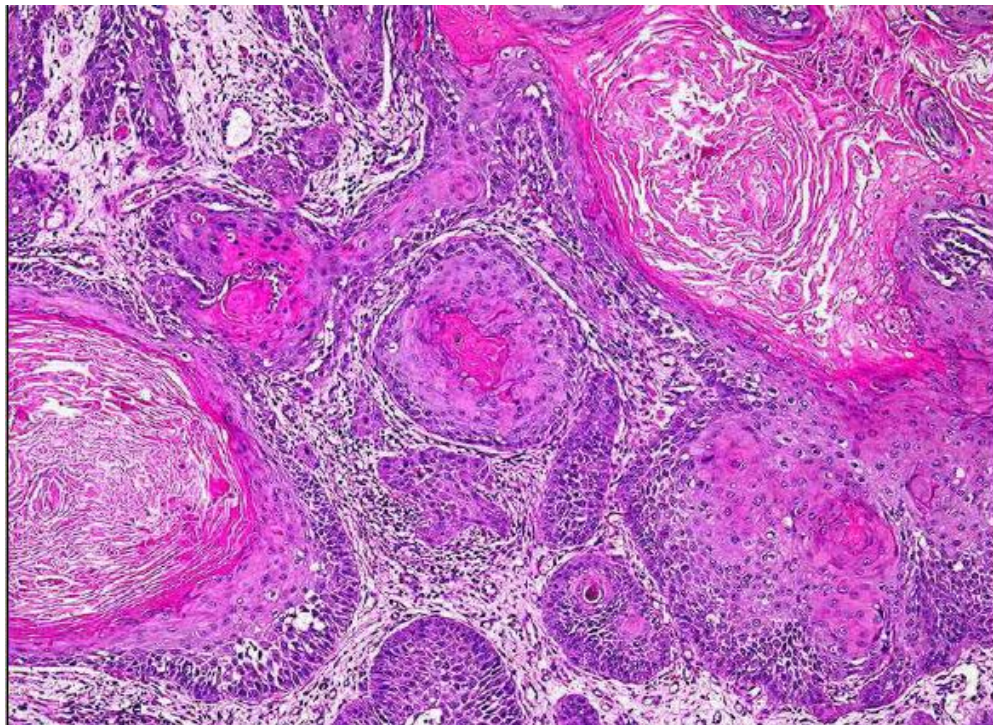
Hodgkins Lymphoma



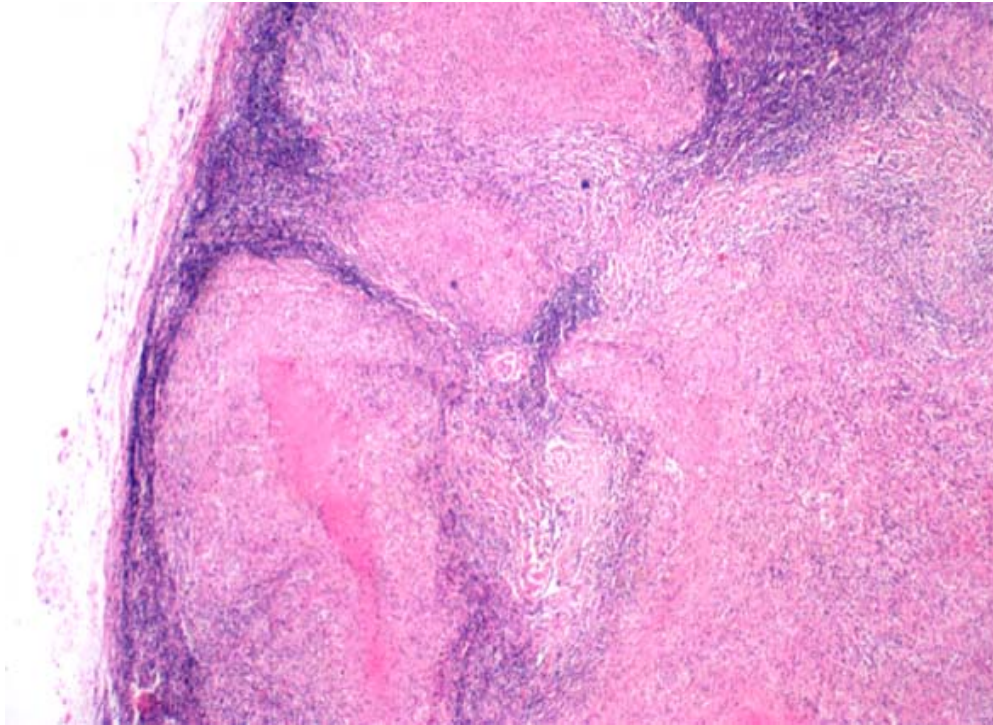
Hodgkins Lymphoma (NS) reed sternbergs cells



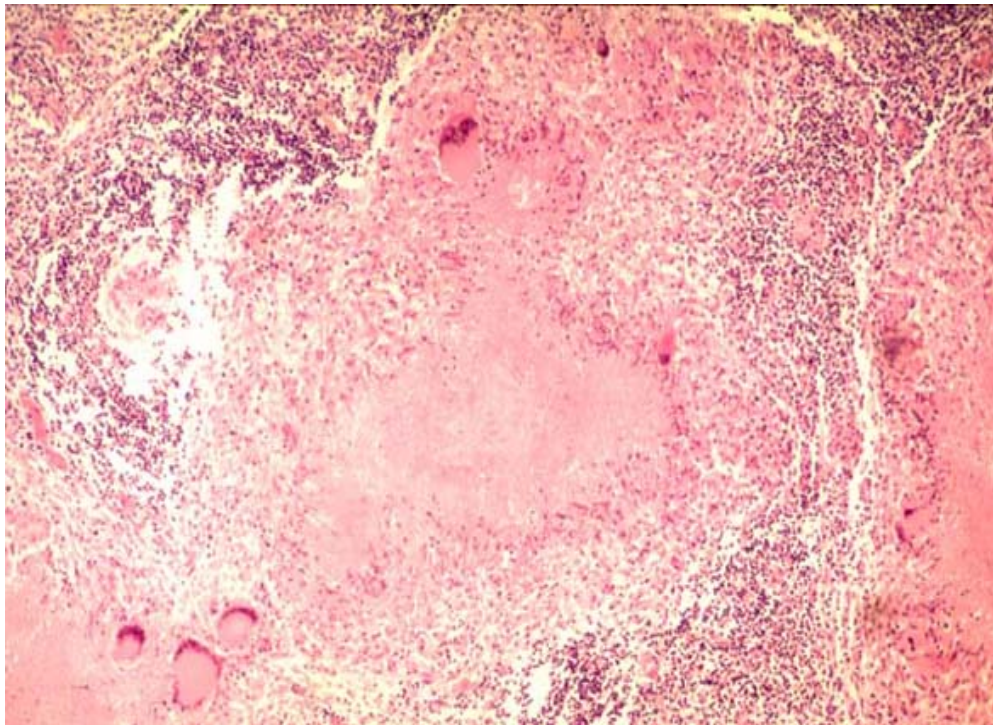
Hodgkins Lymphoma



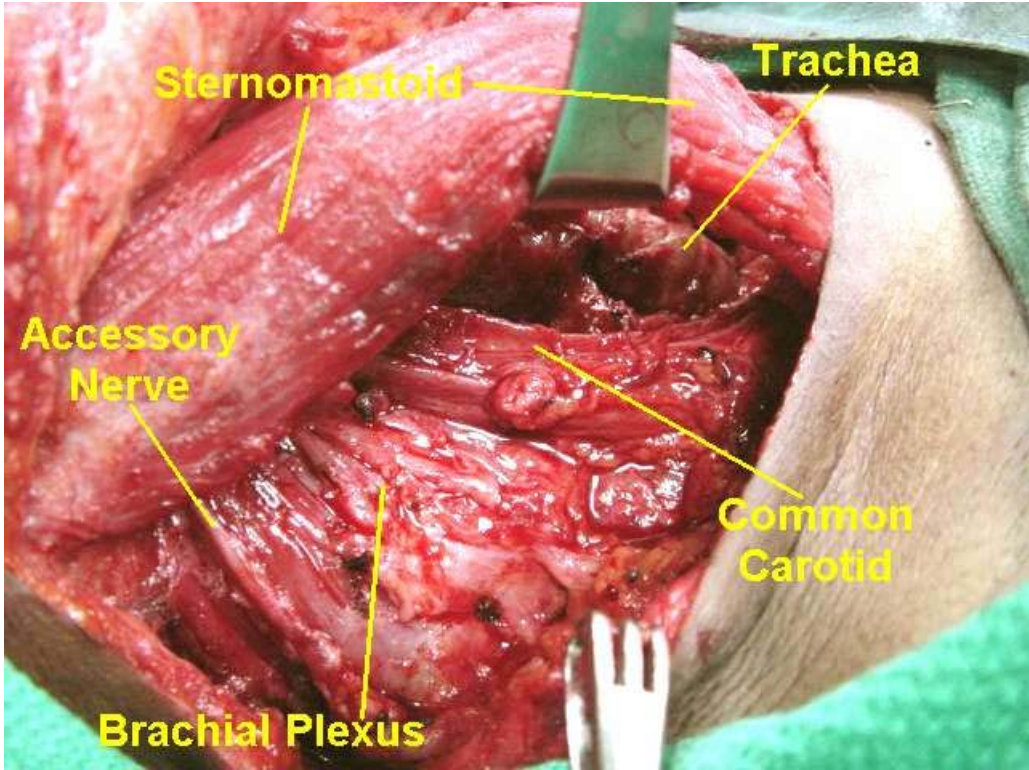
Squamous cell carcinoma with epithelial pearls



Caseating granuloma

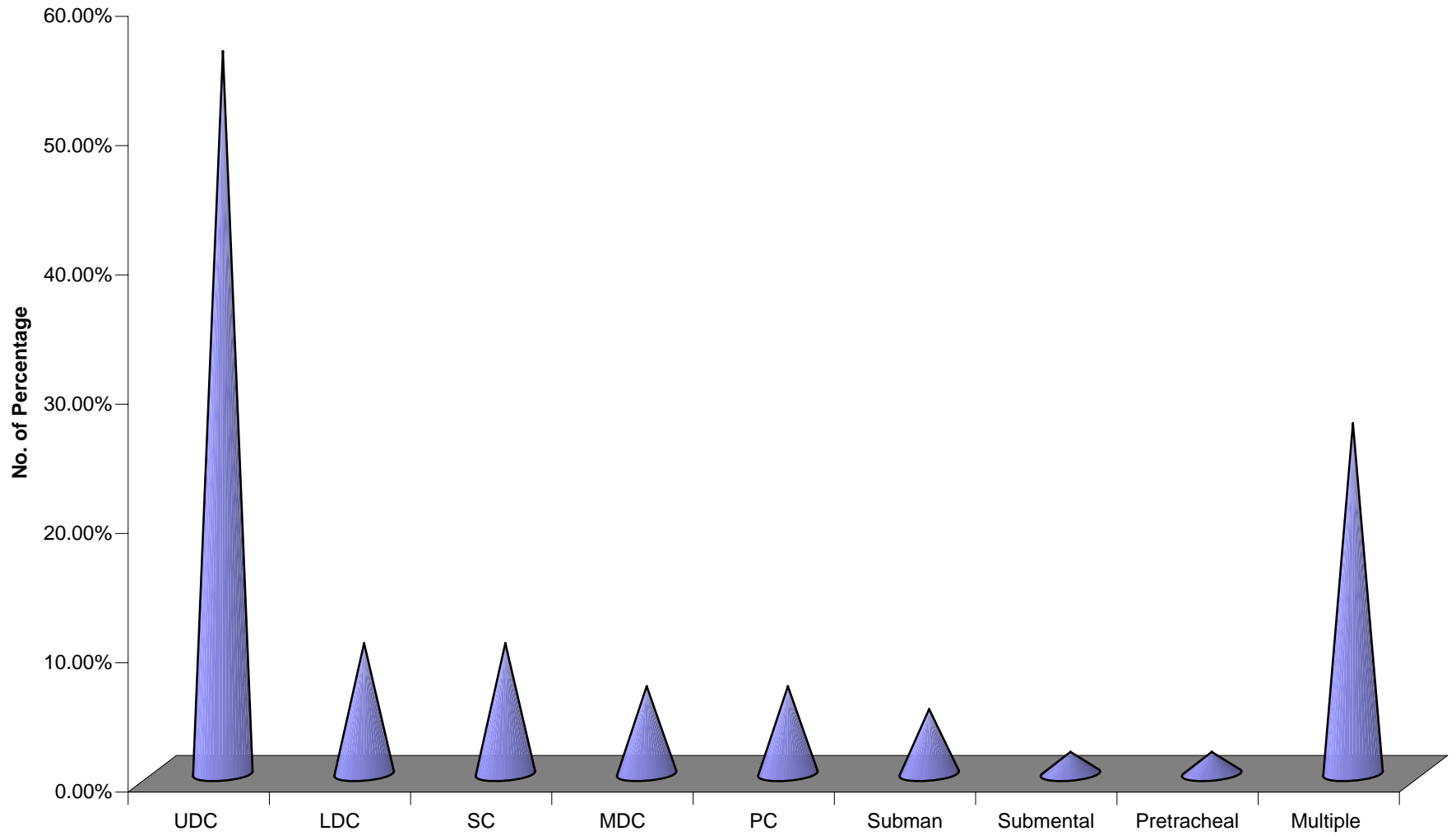


Histopathology tuberculous lymphnode



Modified Radical Neck Dissection

GROUPS INVOLVED IN TUBERCULOSIS



MASTER CHART

Name	Age	Sex	Swelling				FU	Group	Number	Size	Warmth	tenderness	consistency	discrete/m	Symptoms	Other disease	ESR	Mantoux	CXR	FNAC	ENT	Biopsy	Scopy	Treatment
			IP/NO	Duration	Fever	Pain																		
Kalaiarasi	28	F	3369	20 d	-	-	-	UDC @	Single	5*4	-	-	F	D	-	-	28/50	+	Normal	TB	-	-	ATT	
Geetha	19	F	18789	6 m	-	-	-	LDC @	Single	2*2	-	-	F	D	-	-	10/39	+	Normal	TB	-	-	ATT	
Revathy	22	F	7254	1 y	-	-	-	UDC @	Single	2*2	-	-	F	D	-	-	24/48	-	Normal	TB	-	-	ATT	
Be be John	48	F	2150	6 m	-	+	-	UDC @	Multiple	2.5*2/3*5	-	-	F	D	-	-	35/60	-	Normal	LPD	-	Excision Cas TB	ATT	
Elavarasi	13	F	40162	1 m	+	-	-	UDC @	Single	2*3	-	-	F	D	LOA	-	10/18	17 mm	Normal	TB	-	-	ATT	
Rajkumar	18	M	49528	1 w	+	+	-	UDC @	Single	2*3	+	+	F	D	-	DC	8/12	-	Normal	TB	-	-	ATT	
Pavithra	13	F	51190	6 m	+	+	-	UDC (L)	Single	1*1	-	-	F	D	Cough	-	8/16	+	Normal	TB	-	-	ATT	
Muthu	56	M	21860	1 Y	+	+	-	UDC @	Multiple	2*3 3*2	-	-	F	M	LOA	-	10/18	+	Normal	TB	-	Repeat F	ATT	
Kala	38	F	59582	1 m	+	+	-	UDC (L)	Single	2*1	-	-	F	M	-	-	10/18	-	Normal	TB	-	-	ATT	
Neelakandan	40	M	10072	2 w	+	+	-	LDC @	Single	3*2	-	-	F	D	-	DC	10/20	-	Normal	TB	-	-	ATT	
Selvi	36	F	13697	15 d	+	+	-	SUB Men	Multiple	1*0.5	-	-	F	D	-	DC	10/20	-	Normal	TB	-	-	ATT	
Kala	27	F	120418	1 m	-	-	-	UDC @	Multiple	1*1 1*1	-	-	F	M	-	-	15/25	-	Normal	TB	-	Repeat F	ATT	
Premalatha	24	F	129150	3 m	+	-	-	UDC (L)	Single	4*3	-	-	F	D	-	Danduff	18/25	-	Normal	TB	-	-	ATT	
Aparna	14	F	1015	1 w	-	-	-	UDC @	Single	2*1	-	-	S	D	-	DC	8/16	-	Normal	TB	-	-	ATT	
Vijayalakshmi	49	F	13260	10 d	-	-	-	LDC @	Single	3*4	-	-	F	D	-	-	8/20	-	Normal	TB	-	-	ATT	
Prasad	24	M	142308	2 w	-	-	-	UDC @	Single	3*3	-	-	F	D	-	-	7/16	-	Normal	TB	-	-	ATT	
Amudha	24	F	174216	3 m	-	-	-	UDC @	Single	3*2	-	-	F	D	-	-	18/22	-	Normal	TB	-	-	ATT	
Meenakshi	28	F	187940	1 m	+	-	-	UDC (L)	Single	1*1	-	+	S	D	Rhinitis	-	5/10	-	Normal	TB	-	-	ATT	
Amulu	17	F	18740	2 m	+	-	-	UDC (L)	Single	2*2	-	-	F	D	-	-	8/15	+	Normal	TB	-	-	ATT	
Dhanalakshmi	20	F	237293	3 y	-	-	-	PC @	Single	3*3	-	-	F	D	-	-	15/36	+	Normal	TB	-	-	ATT	
Prema	29	F	253903	4 m	+	+	-	UDC (L)	Multiple	1*1.5 1*5	-	-	F	M	-	Cough	15/22	18 mm	Normal	TB	-	-	ATT	
Nagappan	29	M	104395	2 m	+	+	-	MDC (L)	Single	2*1	-	-	F	D	-	-	5/10	-	Normal	TB	-	-	ATT	
Kanchana	24	F	159270	2 m	-	-	-	LDC (L)	Single	2*1	-	-	F	D	-	-	10/20	-	Normal	TB	-	Repeat F	ATT	
Revathy	35	F	174775	1 m	-	-	-	SUB Man @	Single	2*1	+	+	S	D	-	-	5/10	-	Normal	TB	-	-	ATT	
UMA	24	F	1253	10 d	+	-	-	UDC @	Multiple	1*2 1*5	-	-	S	M	Cough	-	18/28	-	Normal	TB	-	-	ATT	
Lakshmi	42	F	174834	15 d	+	-	-	SUB MAN @ & UDC @	Multiple	3*3	+	-	F	M	-	-	10/20	-	Normal	TB	-	-	ATT	
Manivannan	35	M	179364	15 d	+	+	-	UDC @	Single	6*6	-	-	F	D	-	Primary complex	21/42	17 mm	Normal	TB	-	-	ATT	
Elizabeth	50	F	182254	8 m	-	-	-	UDC (L)	Single	4*4	-	-	F	D	-	-	28/56	-	Normal	TB	-	-	ATT	
Sarasu	28	F	189091	8 m	-	+	-	UDC @	Single	8*8	-	-	F	D	-	-	18/36	-	Normal	TB	-	Repeat F	ATT	
Siddarthan	53	M	217429	1 m	-	+	-	UDC @	Single	3*3	-	-	F	D	Cold appsi-	-	32/56	+	Normal	TB	-	-	ATT	
Dhanalakshmi	21	F	21742	1 m	-	-	-	LDC @	Single	4*4	-	-	F	D	-	-	14/36	-	Normal	TB	-	-	ATT	
Rajalakshmi	18	F	227261	6 m	+	-	-	UDC @	Single	2*2	-	-	F	D	-	-	30/56	-	Normal	TB	-	-	ATT	
Siva kannu	28	M	28026	2 m	+	-	-	UDC @	Multiple	1*1 2*1	-	-	F	M	-	-	18/42	12mm	Normal	TB	-	-	ATT	
Kantha	25	F	229641	2 w	+	-	-	UDC @	Single	3*3	-	-	F	D	-	-	15/25	-	Normal	TB	-	-	ATT	
Perumal	28	M	1673	6 m	-	-	-	UDC (L)	Multiple	2*1 2*1	-	-	F	M	-	-	18/32	-	Normal	TB	-	-	ATT	
Punitha	21	F	247190	2 m	+	-	-	UDC (L)	Single	3*1	-	-	F	D	-	Old PT 6mths ATT	18/26	-	Normal	TB	-	-	ATT	
Dhanalakshmi	19	F	242632	3 m	-	-	-	SC @	Multiple	3*1 1*1	-	-	F	D	LOA	-	12/20	-	Normal	TB	-	-	ATT	
Mohammed	18	M	259487	3 m	-	+	-	UDC @	Single	2*1	-	-	F	D	-	-	5/10	-	Normal	TB	-	Repeat F	ATT	
Sasi Kala	19	F	142484	2 w	-	-	-	SC @	Single	4*3	-	-	F	D	-	-	5/10	-	Normal	TB	-	Repeat F	ATT	
Shenbagam	40	F	141078	2 w	-	-	-	PC @	Single	2*1	-	-	F	D	Cough	-	10/12	12 mm	Normal	TB	-	-	ATT	
Durga devi	10	F	145014	10 d	-	-	-	PC (L)	Multiple	3*2 5*.5	-	-	F	M	-	-	5/10	-	Normal	TB	-	-	ATT	
Vijayalakshmi	17	F	104762	1 m	-	-	-	SC (L)	Multiple	3*2	-	-	S	M	-	-	12/16	-	Normal	TB	-	-	ATT	
Babu	28	M	148699	1 m	-	-	-	PT	Single	2*1	-	-	S	D	-	-	10/16	-	Normal	TB	-	-	ATT	
Senthil	11	M	161631	3 m	-	-	+	UDC (L)	Single	4*3	-	-	S	D	-	-	3/7	-	Normal	TB	-	-	ATT	
Aktar Begum	18	F	153971	2 m	-	-	+	PC (L)	Multiple	1*1 1*.5	-	-	F	D	-	-	3/14	-	Normal	TB	-	-	ATT	
Raghu	30	M	1909	2 m	-	-	-	SC @	Multiple	2.5*2 2*.5	-	-	S	M	-	-	10/26	10 mm	Normal	TB	-	-	ATT	

Prema	29 F	253952 4 m	+	+	-	UDC @	Multiple	1*5 1*5	-	-	F	M	LOA, LOA/-	15/30	18 mm	Normal	TB	-	-	-	ATT
Ramalingam	42 M	31506 1 m	+	-	-	UDC (L)	Single	3*2	-	-	F	D	Cough	5/10	-	Normal	TB	-	-	-	ATT
Gauramma	50 F	220097 6 m	-	-	-	LDC @	Single	2*2	-	-	F	D	6 m ATT	13/19	-	Normal	TB	-	-	-	ATT
Gomathi	17 F	198945 2 w	+	+	-	UDC @	Single	2*2	-	-	F	D	-	32/61	18 mm	Normal	TB	-	-	-	ATT
Raniammal	45 F	194080 20 d	-	-	-	UDC (L)	Multiple	2*2	-	-	F	M	-	16/32	-	Normal	TB	-	-	-	ATT
Farook	28 M	6685 6 m	-	-	-	MDC (L)	Single	2*2	-	-	F	D	-	5/10	-	Normal	TB	-	-	-	ATT
Thiruva kannu	47 M	15547 3 d	+	-	-	MDC @	Single	2*1	+	+	F	D	-	8/16	-	Normal	TB	-	-	-	ATT
rAJASEKAR	72 M	23619 2 w	+	-	-	SC (L)	Single	5*5	+	+	S	D	-	1020	-	Normal	TB @	-	-	-	ATT
Rama Devi	50 F	163537 1 m	-	-	-	PC @	Single	1*1	-	-	F	D	-	-	-	Normal	MALIG	-	Pan adeno CA	-	CHEMO
Parthasarathy	50 M	152457 2 m	+	-	-	UDC (L)	Single	3*3	-	-	H	D	-	-	-	Normal	SCC/NPCC-	-	NPC	-	RT
Gauramma	50 F	220097 6 m	-	-	-	UDC @	Single	2*2	-	-	H	D	-	-	-	Normal	METS	-	Adeno CA	-	CHEMO
Uma Rani	56 F	987 2 m	-	-	-	SC (L)	Single	2*1	-	-	F	D	Left breast Inf CA Axila	-	-	Normal	CA Breast	-	-	-	CHEMO M- RT
Kamala	37 F	8361 3 m	-	-	-	LDC (L)	Multiple	3*2 1*5	-	-	F	D	-	10/15	-	Normal	PaP CA Th-	-	-	-	TT - MRND
Rajasekar	72 M	23619 2 w	-	-	-	SUB MAN @	Single	4*3	-	-	H	D	LOA, LOW	12/14	-	Normal	METS	Tonsil CA P 1/3	SCC	-	RT
Sankara pani	88 M	24247 3 m	-	-	-	MDC (L)	Single	5*4	-	-	H	D	-	-	-	Normal	SCC	Tongue	SCC	-	RT
Ananda narayanan	M	31506 1 m	-	-	-	UDC (S)	Single	3*2	-	-	H	D	Change in voice, dysphagia	12/16	-	Normal	METS	PF CA	SCC	-	RT
Raja	80 M	145926 10 d	-	-	-	UDC @	Multiple	8*7	-	+	H	M	Oral sepsis	14/20	-	Normal	METS	-	SCC	-	RT
Jyothi	42 M	158365 10 d	-	+	-	UDC @	Single	6*6	-	-	H	D	Voice chan-	8/16	-	Normal	SCC	-	SCC	-	NPC RT
Kanni ammam	53 F	96002 6 m	-	-	-	UDC @	Multiple	1.5*1 2*1	-	-	H	M	-	10/18	-	Normal	METS	-	Adeno CA	-	RT
Rangarajan	60 M	154799 1 1/2 m	-	-	-	UDC (L)	Single	2*1	-	-	H	D	Voice chan-	10/20	-	Normal	SCC	VALLE GR	SCC	DL	RT
Arumugam	66 M	7421 1 m	-	-	-	SC @	Single	1*1	-	-	H	D	Dysphagia	5/10	-	Normal	METS	CA Eso	-	O - scopy	CHEMO/RT
Devaraj	64 M	18188 3 m	-	-	-	UDC (L)	Single	5*5	-	-	H	D	-	10/22	-	Normal	SCC	NPC	SCC	-	RT
Ruthammal	70 F	3694 15 d	-	-	-	LDC (L)	Multiple	5*4	-	-	H	M	Dysphagia	10/18	-	Normal	SCC	PF CA	SCC	DL	RT
Rajamani	56 M	75758 6 m	-	-	-	UDC @	Single	6*4	-	-	H	D	Dysphagia Cough	10/26	-	Normal	SEC	Lung CA	-	B - scopy	RT
Mani	55 M	196 1 m	+	-	-	SUB MAN @	Single	3*3	-	-	F	D	NHL on coj-	30/60	-	Normal	IN	-	Excision	-	CHEMO
Stella	40 F	10967 2 m	+	-	-	LUDC, MDC	Multiple	8*6 2*4 1*2	-	-	F	D	-	22/42	-	Normal	NHL	-	Excision	-	CHEMO
Manoharan	45 M	461282 2 m	+	-	-	Right Multiple node	Multiple	8*6	-	-	F	M	Spleen +	18/32	-	Normal	NHL	-	Excision	-	CHEMO
Shankar	20 M	145783 1 y	-	-	+	Bilateral UDC	Multiple	4*4	-	-	V	D	ATT GL	18/36	-	Normal	HL	-	Excision	-	CHEMO
Rani	26 F	23841 6 m	-	-	-	LDC (L)	Single	2*1	-	-	H	D	-	18/40	-	Normal	PaP CA	-	-	-	TT - MRND
Suganya	17 F	200317 1 m	+	+	-	LDC (L)	Single	0.7	-	-	F	D	LOA	5/10	-	Normal	NSLA	-	-	-	Sym Trt
Nirmala	34 F	6971 3 m	-	-	-	SC @	Multiple	0.1	-	-	S	D	-	8/16	-	Normal	NSLA	-	-	-	Sym Trt
Sivaprakash	30 M	1251 1 m	+	+	-	SUB MAN (L)	Single	2*3	+	+	S	D	Odyo	6/12	Neg	Normal	NSLA	-	-	-	Sym Trt
Chitra	42 F	14642 15 d	+	+	-	UDC (L)	Single	2*1	+	+	S	D	DC	4/11	Neg	Normal	NSLA	-	-	-	Sym Trt
Shanthi	38 F	168752 2 m	+	-	-	UDC (L)	Single	3*2	+	+	F	D	DC	4/8	Neg	Normal	INF	Tonsil	-	-	Sym Trt A*B
Dhavamani	28 F	17886 10 d	+	+	-	UDC @ Scrofulderna	Single	3*2	-	+	F	D	-	-	Neg	Normal	INF	Tonsil	-	-	Sym Trt A*B
Priya	9 F	221298 1 wk	+	+	-	UDC @	Single	2*1	-	-	S	D	-	-	Neg	Normal	NSLA	-	-	-	Sym Trt
Poornima	29 F	29015 4 d	+	-	-	UDC @	Single	2*1	+	+	S	D	Odyo	-	Neg	Normal	INF	Tonsil	-	-	Sym Trt A*B
Diana	20 F	40549 1 w	+	+	-	UDC (L)	Single	3*2	+	+	F	D	LOA	10/15	Neg	Normal	Reac	-	-	-	Sym Trt
Zareena	37 F	4049 15 d	-	-	-	UDC @	Single	3*4	-	-	F	D	Cough	5/12	Neg	Normal	Reac	-	-	-	Sym Trt
Karthikeyan	18 M	66039 1 m	+	-	-	MDC (L)	Single	2*2	-	-	S	D	-	8/6	Neg	Normal	Reac	-	-	-	Sym Trt
Saumndeshwari	45 F	34694 3 m	+	-	-	UDC (L)	Single	2*3	-	-	S	D	-	10/20	Neg	Normal	Reac	-	-	-	Sym Trt
Apartha	10 F	1015 1 w	+	+	-	UDC @	Single	3*1	-	-	S	D	-	10/18	Neg	Normal	Reac	-	-	-	Sym Trt
Gayathri	2 1/2 F	185744 14 d	+	-	-	LDC (L)	Single	1*1	-	+	S	D	Rhinitis	5/10	Neg	Normal	Reac	-	-	-	Sym Trt
Chinni	36 F	205872 2 m	+	-	-	SUB MAN (L)	Single	3*2	+	+	S	D	-	10/18	Neg	Normal	Reac	-	-	-	Sym Trt
Deepakraj	18 M	16830 1 y	+	-	-	SUB MAN (L)	Single	2*2	-	-	S	D	DC	5/12	Neg	Normal	Reac	-	-	-	Sym Trt
Arunkumar	12 M	185648 10 y	+	-	+	PC @	Single	2*1	-	-	F	D	Dandruff	16/40	Neg	Normal	Reac	-	-	-	Sym Trt

Usha	23 F	2365 1 m	+	-	+	LDC (L)	Single	1*1	-	-	F	D	Cough	ATT 1yr	10/14	Neg	Normal	Reac	-	-	-	Sym Trt
Sathyamoorthy	62 M	156923 40 d	+	+	-	UDC (L)	Single Diff.	5*6	-	-	S	Di	-	Niddm	5/10	Neg	Normal	INF ABS	-	-	-	I&D
Sathish	18 M	15191 1 1/2 m	+	+	-	UDC @	Single	3*3	+	+	F	D	-	-	4/8	Neg	Normal	TOXO PLA-	-	-	-	Sym Trt

