

**A DESCRIPTIVE STUDY ABOUT ABDOMINAL
TUBERCULOSIS IN GOVERNMENT RAJAJI
HOSPITAL MADURAI**

Dissertation Submitted for

**MS DEGREE (BRANCH I) GENERAL SURGERY
APRIL 2012**



**The Tamilnadu Dr.M.G.R Medical University
Chennai – 600 032.
MADURAI MEDICAL COLLEGE, MADURAI.**

CERTIFICATE

This is to certify that this dissertation titled “**A DESCRIPTIVE STUDY ABOUT ABDOMINAL TUBERCULOSIS IN GOVERNMENT RAJAJI HOSPITAL**” submitted by **Dr. JAYAPRAKASH .N** to the faculty of General Surgery, The TamilNadu Dr. M.G.R. Medical University, Chennai in partial fulfillment of the requirement for the award of MS degree Branch I General Surgery, is a bonafide research work carried out by him under our direct supervision and guidance from June 2009 to May 2011.

Prof. Dr. M.Gobinath, M.S.,
Professor and Head of the Department,
Department of General Surgery,
Madurai Medical College,
Madurai.

Prof. Dr. Dr.G.V.Rajambigai M.S.,FACRSI.,
Professor & Unit Chief,
Department of General Surgery,
Madurai Medical College,
Madurai.

DECLARATION

I, **Dr. JAYAPRAKASH . N** solemnly declare that the dissertation titled “**A DESCRIPTIVE STUDY ABOUT ABDOMINAL TUBERCULOSIS IN GOVERNMENT RAJAJI HOSPITAL**” has been prepared by me. This is submitted to **The TamilNadu Dr. M.G.R. Medical University, Chennai**, in partial fulfillment of the regulations for the award of MS degree (Branch I) General Surgery.

Place: Madurai

Dr. JAYAPRAKASH . N

Date:

ACKNOWLEDGEMENT

At the outset, I wish to express my sincere gratitude to our unit chief **Prof. Dr.G.V.RAJAMBIGAI M.S, FACRSI.**, for her expert supervision and valuable suggestions. I wish to express my whole hearted thanks to our assistant Professors **Dr.P.Sundareswari M.S.,D.G.O., Dr. J.Ravishankar M.S., Dr.Celine Foustina Mary M.S, D.G.O**, for their constant encouragement and excellent guidance.

My sincere gratitude to my former unit chief Prof. **Dr.R.VIJAYAN M.S.**, for his valuable motivation and guidance to initiate this study.

I wish to thank **Prof.Dr. M.GOBINATH, M.S.**, Professor and Head of the Department of Surgery for his valuable guidance and advices. I am greatly indebted to **Prof.Dr. A.EDWIN JOE, M.D (FM), B.L.**, Dean, Madurai Medical College & Government Rajaji Hospital, Madurai for their kind permission to allow me to utilize the clinical material from the hospital.

I whole heartedly thank all the patients who willingly co-operated and rendered themselves for the study without which the study couldn't have been a reality.

CONTENTS

No.	TITLE	PAGE No.
1.	INTRODUCTION	1
2.	REVIEW OF LITERATURE	3
3.	AIMS & OBJECTIVES	34
4.	MATERIALS AND METHODS	35
5.	RESULTS	37
6.	TABLES AND FIGURES	40
7.	DISCUSSION	50
8.	CONCLUSION	59

ANNEXURES

- **BIBLIOGRAPHY**
- **PROFORMA**
- **MASTER CHART**
- **ETHICAL COMMITTEE CLEARANCE APPROVAL**

INTRODUCTION

Tuberculosis is a disease caused by the bacterium *Mycobacterium* species which is one of the commonest disease known to mankind. It is a well known fact that it has its reputation of being one of the greatest killer diseases. There has been a trend of increased incidence of tuberculosis in human race in the last three decades which can be partly attributed to increase in population, social deprivation and HIV infection.

The morbidity and mortality due to tuberculosis leads to a discovery of newer drugs and more emphasis on the disease. With improved socioeconomic conditions and disease diagnosis in the western countries, Tuberculosis in the western countries impose little clinical problem. But in most developing countries like India, it remains to be a major health hazard and major health related mortality, morbidity both physically and psychologically. As we know, Tuberculosis is one of the important gastroenterological problems in Tropics.

Gastrointestinal Tuberculosis is one of the earliest known diseases which still remain the disease with diagnostic enigma due to its perplexing protean clinical manifestations. Importance of the condition lies in the diversity of the presentations and its wide spread effects on the body. It may present as acute, subacute or chronic forms and may give rise to malabsorption, more so when associated with stricture formation.

The symptoms and signs often quite vague and laboratory investigations and radiological findings are sometimes non conclusive. There is no single feature which is diagnostic for abdominal Tuberculosis. In case of any localized involvement of the structures of the abdomen the presenting clinical picture will mimic the disease of the organ only. In various studies about abdominal tuberculosis worldwide, the results show wide range in its disparity in the nature course of disease, in its diagnosis and management. We planned a study on abdominal tuberculosis to understand the nature of disease process and to evaluate the various laboratory and radiological investigations and to study the management of the disease.

REVIEW OF LITERATURE

The diagnosis of abdominal tuberculosis is obscure. Joseph Walsh in 1909 remarked that “It is impossible to diagnose abdominal tuberculosis with any degree of certainty”²³. Unfortunately this remains even today in situations where it is relatively common. The signs and symptoms are often vague and laboratory investigation and radiological findings are non-specific. Many cases go unnoticed until a surgically removed specimen is examined histopathologically. A majority of stenotic lesions of the bowel are of tuberculous in nature and has been found on the operating table has one of the common findings in cases of acute intestinal obstruction.¹

The term abdominal tuberculosis refers to tuberculous infection of the gastrointestinal tract, mesenteric lymph nodes, peritoneum and omentum, and of solid organs related to the gastrointestinal tract such as the liver and spleen.¹ Various pathological forms of abdominal tuberculosis are

I. Peritoneal tuberculosis—acute or chronic

A. Tuberculosis of the peritoneum

- (i) Wet or ascitic type: Generalized, Localized (loculated)
- (ii) Dry or fibrous type: Adhesive type, Plastic type, Miliary nodular type

B. *Tuberculosis of peritoneal folds and contents viz.* Mesenteric adenitis, Mesenteric cysts, Mesenteric abscesses, Bowel adhesions and rolled-up omentum.

II. Gastrointestinal

1. Ulcerative
2. Hypertrophic or hyperplastic
3. Sclerotic or fibrotic

III. Tuberculosis of solid viscera (e.g. liver and spleen)

Epidemiology of abdominal tuberculosis

Starting from the mid-1980s a resurgence of tuberculosis occurred; due to a large extent to the epidemic of acquired immunodeficiency disease. Intestinal tuberculosis is seen more frequently in people of poor socioeconomic circumstances. Its incidence is higher in patients with caseo-pneumonic and advanced lung disease than in those with fibrotic lesions and early disease. The frequency of extrapulmonary tuberculosis has increased, largely an influence of human immunodeficiency virus (**HIV**) infection; over 50 per cent of individuals with HIV and tuberculosis develop extrapulmonary disease compared to 10 to 15 per cent in those without HIV². Finally, there is a marked increase in the emergence of multidrug-resistant *M. tuberculosis* organisms, a cause of much concern for the global control of tuberculosis.

Microbiology

Mycobacterium tuberculosis is responsible for nearly all cases of abdominal tuberculosis. Other pathogenic organisms such as *M. bovis* have been largely eliminated by public-health measures and are rarely encountered today. Several other atypical or anonymous mycobacteria whose pathogenicity is not yet established have been identified.^{3,4}

Routes of infection and pathogenesis

Mycobacterium tuberculosis spreads to the abdomen by several routes. Ingestion of contaminated food may cause primary intestinal tuberculosis. Secondary intestinal disease arises from swallowed sputum containing tuberculous bacilli; it is influenced by the virulence and quantity of the bacilli, and by host resistance to the infection. The peritoneum, mesenteric nodes, and the intestine may become infected during the bacteraemic phase that may follow primary pulmonary tuberculosis. Mycobacteria may also spread from diseased adjacent organs, such as the fallopian tubes. When the intestines become infected by lymphatic spread from the mesenteric lymph nodes, the nodal disease is considered as the primary site and intestinal involvement is secondary. This conclusion is supported by the observation that the earliest intestinal lesions are found in the submucosal layer, while the overlying mucosa is normal. In addition, more

advanced abnormalities such as caseation necrosis are found in the mesenteric nodes rather than in the intestine. The bacteria may also be disseminated in the bile, since they are sequestered and excreted from granulomas in the liver.

Sites of intestinal involvement

The terminal ileum and ileocaecal junction are involved most frequently⁵. The other regions affected in order of decreasing frequency are; colon, jejunum, rectum and anal canal, duodenum, stomach, and oesophagus. The site of predilection is dictated by factors such as the abundance of lymphoid tissue, the rate of absorption of the intestinal contents, prolonged stasis, which provides longer time of contact with the mucosa, and the digestive activity of the contents.

PATHOLOGY

Intestinal tuberculosis

Ulcerative lesions

Tuberculous intestinal ulcers are usually deep and are transversely placed in the direction of the lymphatics. Multiple ulcers may be seen, most often in the terminal ileum⁶. Disease progression is associated with the appearance of an inflammatory mass around the bowel. The diseased part of the gut becomes thickened and the serosal surface is studded with tubercles. There is often a marked increase in

mesenteric fat with fat wrapping around the bowel loops. The regional nodes become enlarged and may caseate leading to mesenteric abscess formation. Bowel perforation is rare, and is usually confined by the perilesional inflammatory mass.

Hyperplastic lesions

In the hyperplastic form of intestinal tuberculosis, a fibroblastic reaction occurs in the submucosa and subserosa resulting in marked thickening of the bowel wall; this, together with involvement of the adjacent mesentery, lymph nodes, and the omentum, results in the formation of a mass lesion⁷. Hyperplastic lesions are believed to be the result of reduced bacterial virulence and increased host resistance.

Sclerotic lesions

The sclerotic variety is associated with strictures of the intestine, typically described as 'napkin-ring strictures', which may be single or multiple. When multiple, the strictures may occur in a short segment of the bowel or over the entire length of the intestine. Enteroliths can form proximal to the stricture. In some patients a combination of the different pathological forms may be seen.

Peritoneal tuberculosis

Acute peritonitis

Acute tuberculous peritonitis is extremely rare and is encountered under the following circumstances: in the miliary phase of the disease, on perforation of intestinal disease, and with local dissemination from a ruptured, caseating mesenteric lymph node.

Chronic peritonitis

The chronic form of tuberculous peritonitis is much more common and typically presents as ascites. The fluid is usually clear and straw colored, but may be sanguineous. Peritoneal adhesions that range from thin and flimsy to dense and thick may occur. In the presence of adhesions the ascitic fluid may become loculated presenting as a localized cyst. The characteristic lesions are miliary nodules. When the nodules increase in size and coalesce, plastic adhesions develop, which may completely obliterate the peritoneal cavity, forming an abdominal cocoon that may encase the intestines. The omentum thickens to form a transversely placed mass, the so-called rolled-up omentum.

CLINICAL FEATURES

Abdominal tuberculosis is seen most frequently in patients between the ages of 30 and 50 years. Females outnumber males by 2:1⁸. The onset of illness is usually insidious, and the initial symptoms are often vague and non-specific; this is particularly true of peritoneal tuberculosis. As the disease progresses the individual may develop fever, which is present in two-thirds of the patients, night sweats, malaise, weakness, anorexia, and weight loss⁹. The appearance of specific symptoms depends upon the predominant site of involvement

Peritoneal tuberculosis: Tuberculous peritonitis usually presents with ascites. Less frequently, fluid collection is mild but the fibrotic component is more prominent, resulting in thickening of the peritoneum with adhesions, fluid loculation, and the classic doughy feel of the abdomen. Patients with peritoneal tuberculosis, especially women, often have coexisting tuberculosis of the pelvic organs, since the genital tract is frequently the portal of entry of the tubercle bacillus. This point is worth remembering, since a good pelvic examination and endometrial biopsy may provide the simplest method of confirming the diagnosis.

Gastrointestinal tuberculosis: The most common presentation in patients with disease of the gastro-intestinal tract is abdominal pain. The pain may be dull and vague, but when colicky it suggests intestinal obstruction. In such patients the

pain is often exacerbated by eating and relieved by vomiting, but only transiently as it soon recurs. Diarrhea is another common symptom in patients with intestinal involvement. The stools may be watery, small in amount and mixed with blood when the disease affects predominantly the colon. In primary small-bowel disease the stools are large in amount, foul smelling, and resemble those seen in patients with malabsorption. Other symptoms include flatulence, nausea, altered bowel habit, and borborygmi. Abdominal distension suggests the presence of ascites or persistent subacute intestinal obstruction.

Physical examination

Patients with chronic abdominal tuberculosis are often malnourished and anaemic. In some the abdomen may be completely normal on examination, but most demonstrate some abnormal findings. There may be visible peristalsis and the distended bowel loops can be palpated. The abdomen may show diffuse distension and tenderness, or the signs may be more localized, usually in the right lower quadrant. An ileocaecal mass may be felt in the right iliac fossa or higher up in the right lumbar region. A doughy' abdomen suggesting peritoneal disease has become less common in recent years. A rolled-up omentum, when present, is felt as a transversely placed mass in the epigastric region. Loculated ascites, mesenteric cysts, and mesenteric abscesses present as cystic masses.

Patients with ascites may have shifting dullness and a fluid thrill. In patients with large-bowel disease a diffusely thickened and tender colon may be felt. Other findings include hepatosplenomegaly, pelvic abnormalities mimicking gynaecological tumours, and features of gastric-outlet obstruction due to direct involvement of the stomach or extrinsic compression of the duodenum by enlarged mesenteric lymph nodes. Rectal examination may reveal anal fistulas, fissures, or stricture.

Complications:

Intestinal obstruction and malabsorption are the most frequent complications^{10,11}. Much less common are bowel perforation and massive gastrointestinal haemorrhage. Perforation is usually confined, owing to the presence of surrounding adhesions; as a result, signs of free perforation of the bowel are rarely seen. Acute bleeding from the rectum or haematemesis are rare, but can occasionally be severe and life threatening. Fistulas, both internal between adjacent bowel loops or with other hollow organs (uterus, vagina), and external to the skin, are described but are rare.

DIAGNOSIS

Since the discovery of the tubercle bacillus it has been possible to make a precise diagnosis of tuberculosis. However, in patients with abdominal tuberculosis the causative organism is often difficult to identify and the diagnosis is generally made by indirect methods.

Laboratory tests

The most common abnormality on routine blood tests is an elevated erythrocyte sedimentation rate, found in over 90 per cent of patients. Other abnormalities include varying degrees of anaemia and leucopenia with relative lymphocytosis. A positive tuberculin skin test (Mantoux test) is an excellent screening test in non-endemic countries, but is of little use in endemic countries because of high rates of positivity in healthy individuals and in those who have received the bacillus Calmette-Guerin (BCG) inoculation.

Analysis of ascitic fluid

The ascitic fluid has a high white blood-cell count, with a predominantly lymphocytic response. A total white-cell count of 500/mm³ or more has a sensitivity of 81 per cent, a specificity of 48 per cent, and a diagnostic accuracy of 46 per cent for tuberculosis. If a high count is associated with a predominantly non-polymorphonuclear response, the specificity and accuracy improve to 82 per

cent and 78 per cent, respectively. The diagnostic usefulness of the white-cell count is reduced in the presence of coexisting conditions such as cirrhosis and HIV infection, both of which are associated with an increased incidence of abdominal tuberculosis. In patients with cirrhosis and AIDS the response of white cells is poor and the total white blood-cell count is often within the normal range. Another characteristic of tuberculous ascites is high total protein, usually 2.5 g/dl or more, and the serum ascitic fluid albumin gradient (**SAAG**) is less than 1.1. However, high total protein is seen in several conditions, and the sensitivity, specificity, and diagnostic accuracy of this test for tuberculosis are only 65, 78, and 74 per cent, respectively. As with the white blood-cell count, the protein content of ascitic fluid in cirrhotic patients with peritoneal tuberculosis is significantly lower; the concentration is less than 2.5 g/dl in 30 to 50 per cent of patients, and the SAAG is highly variable. Other biochemical tests, such as lactate dehydrogenase (elevated to over 90 units/l), low pH, and an ascitic fluid:blood glucose ratio of less than 0.96, are usually positive in tuberculous ascites, but these tests are non-specific and of little diagnostic value¹².

Adenosine deaminase:

Lately, adenosine deaminase (**ADA**) in ascitic fluid has received much attention. ADA is an enzyme present in several cell types including macrophages,

lymphocytes, and erythrocytes. Its concentration in body fluids correlates with the number and degree of stimulation of lymphocytes, and is a marker of host immune response. Several studies have shown that ADA activity is an extremely useful diagnostic test for tuberculous ascites, with specificity and sensitivity of over 95 per cent. However, in the presence of cirrhosis, seen in more than 50 per cent of patients with peritoneal tuberculosis in the West, the sensitivity of ADA drops to 30 per cent; this is related to the abnormal T-lymphocyte activation and proliferation in those with cirrhosis. For similar reasons, ADA activity is likely to be less useful in HIV-positive patients, limiting the effectiveness of this test in subgroups of patients who are highly susceptible to tuberculosis. However, in those without these predisposing conditions, ADA is extremely useful and should be a first-line investigation, obviating the need for more invasive and expensive diagnostic tests^{13,14,15}. Another test that may prove useful is assay of interferon (produced by T-lymphocytes) in the ascitic fluid¹⁶.

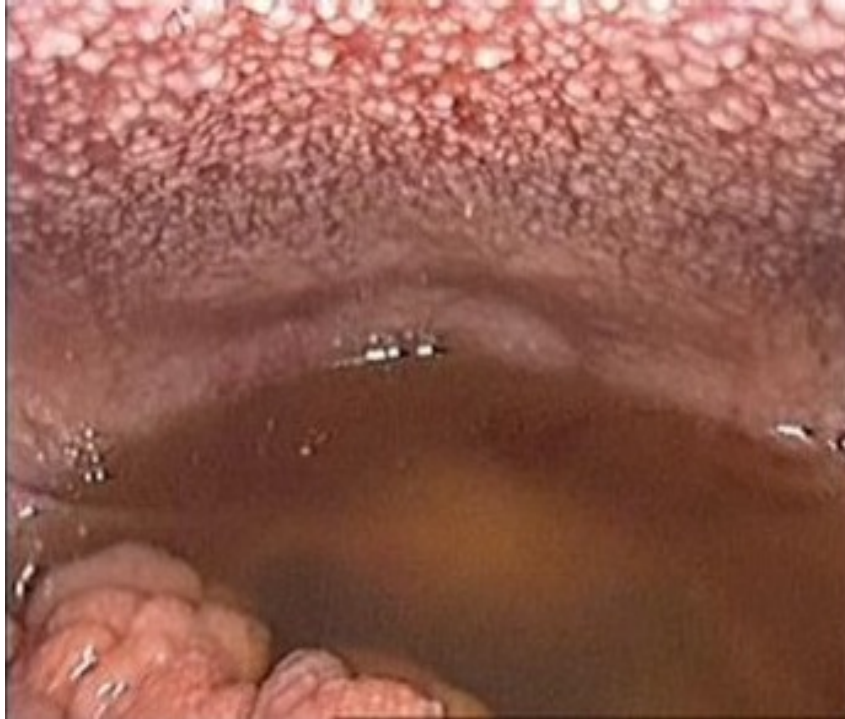Bacterial isolation and culture:

Positive identification of *M. tuberculosis* provides the definitive diagnosis of tuberculosis. Acid-fast smears prepared from ascitic fluid have an extremely low yield, with positive results in fewer than 5 per cent of patients. Culture of ascitic fluid for *M. tuberculosis* is more useful and is positive in 20 to 45 per cent of

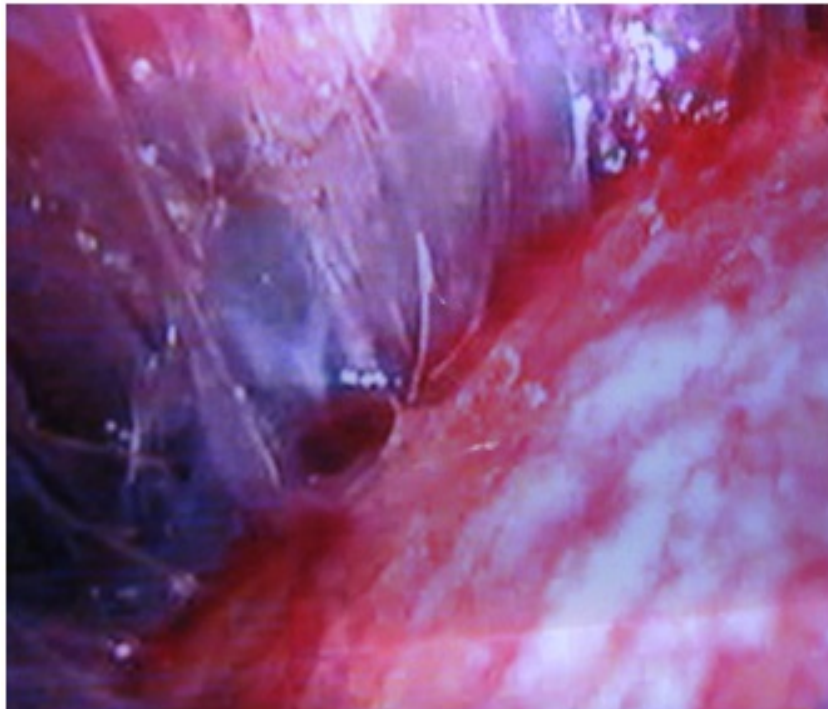
patients. An important disadvantage of culture is that the results take 4 to 6 weeks¹⁷, which severely limits the clinical usefulness of the test. While awaiting the results of culture, antituberculosis treatment should be started, which can be modified later based on drug-sensitivity findings.

Laparoscopy and peritoneal biopsy:

Blind needle biopsy of the peritoneum can be performed in the presence of ascites using special needles (Abrams' or Cope's). Most workers note a low complication rate, but fatality has been reported. The main risk of blind biopsy is bowel perforation, particularly in patients with adhesions between bowel loops and the anterior abdominal wall. Open biopsy of parietal peritoneum under local anaesthesia is much safer. A less traumatic and more useful approach is to obtain targeted biopsy specimens from diseased areas such as enlarged lymph nodes under ultrasonographic or computed tomographic (CT) guidance. The single most sensitive diagnostic test is laparoscopic examination of the peritoneum¹⁸. The peritoneal lining loses its smooth, glistening appearance and becomes rough, irregular and dull. The characteristic finding, as described above, is the presence of miliary tubercles. In addition, fibrous adhesions ranging from tiny filaments to thick bands may be seen. Ascitic fluid, if present, should be sent for biochemical analysis and culture. Targeted biopsy specimens should be obtained, preferably



LAPAROSCOPY – PERITONEAL TUBERCLES & ASCITES



LAPAROSCOPY – ADHESIVE TUBERCULOSIS

from the miliary tubercles. Peritoneal biopsy should be performed even if peritoneal nodules are not seen; histological examination shows caseating granulomas in nearly 90 per cent of patients. The combination of the distinctive visual and histological appearances accurately identifies nearly all patients. However, positive identification of *M. tuberculosis* histologically or by culture is made in only one-half of the patients. The complication rate of laparoscopy is low (less than 5 percent) but care should be taken in the presence of adhesions. This procedure is especially rewarding in patients with AIDS and cirrhosis, because of a much broader differential diagnosis of ascites and the poor sensitivity of the other tests.

Imaging studies

Plain radiographs:

Plain X-ray may show calcification of the mesenteric lymph nodes and calcified granulomas in the spleen, liver or pancreas, but these findings do not imply active disease. Patients in intestinal obstruction may show dilated bowel loops and air-fluid levels. An abnormal chest radiograph indicating pulmonary tuberculosis helps in the differential diagnosis but is seen in fewer than 50 percent of patients with gastrointestinal disease^{19,20}.

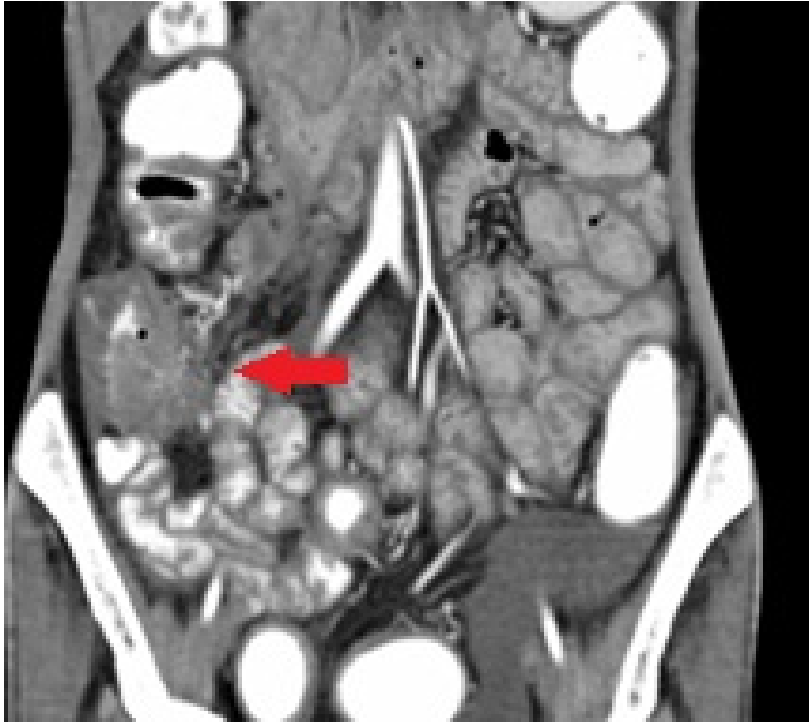Ultrasonography:

Several ultrasonographic findings have been described. The peritoneum

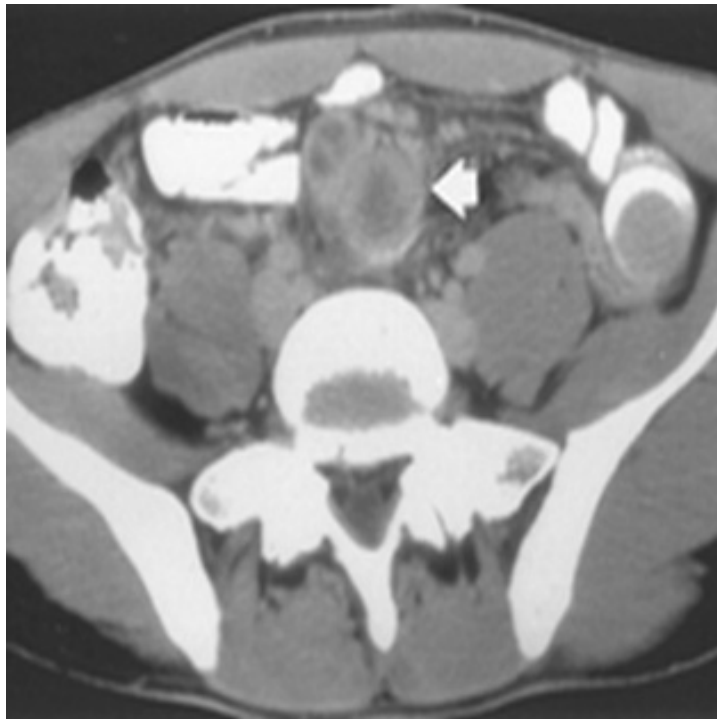
assumes a thickened, irregular, echo-poor, sheet-like or nodular appearance. Ultrasound is very sensitive in detecting small quantities of fluid. Because of their small size, peritoneal nodules are rarely detected, but are better visualized in the presence of ascites and appear as tiny, echo-poor deposits²¹. A characteristic finding is the presence of alternating echogenic and echo-free layers produced by the bowel wall, the serosa, and the adjacent bowel loop with interloop fluid collections; this is termed the 'club sandwich' appearance. In addition, isolated or matted enlarged lymph nodes, with hypoechoic or anechoic centres caused by caseation necrosis, may be seen.

Computed tomography:

Similar findings as noted on ultrasound, but with better definition and resolution, are seen with the CT scan¹⁷. The ascitic fluid has high-density appearances because of its elevated protein content. The thickening and nodularity of the peritoneum and mesentery can be more easily identified with CT than ultrasonography. In patients with intestinal disease there is thickening of the bowel wall and of the ileocaecal valve. The ultrasound and CT findings, although fairly characteristic, are not pathognomonic of abdominal tuberculosis. Similar appearances can be seen in other diseases such as lymphoma, metastatic carcinoma, peritoneal mesothelioma, and pseudomyxoma peritonei.



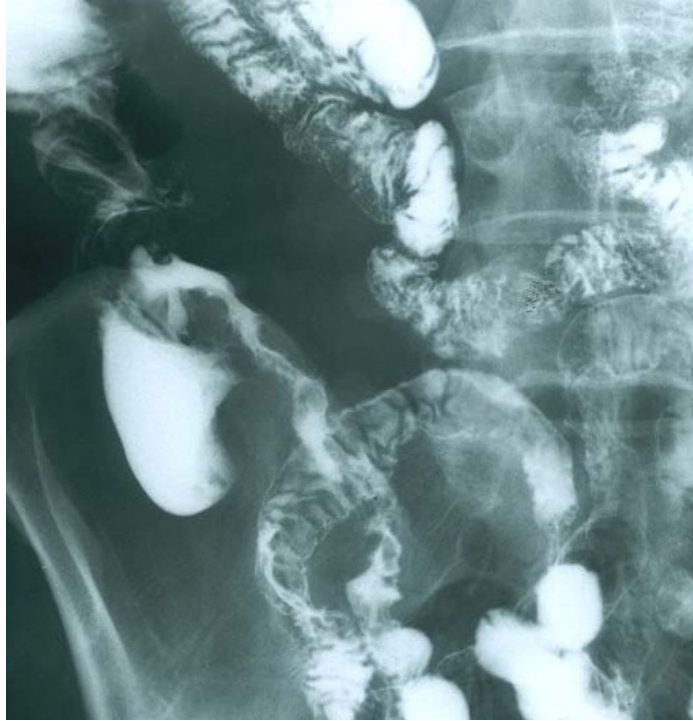CT ABDOMEN – ILEOCAECAL TUBERCULOSIS



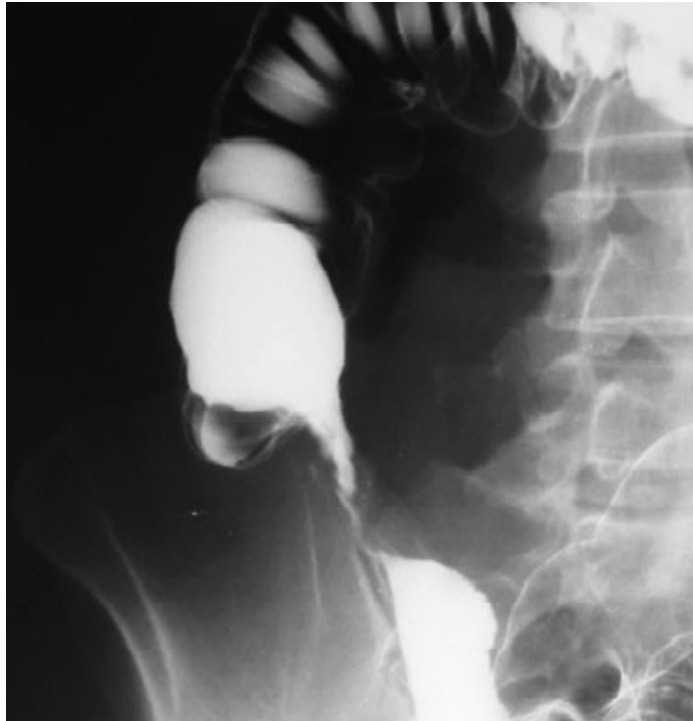CT ABDOMEN – MESENTRIC ADENITIS

Barium studies:

Barium studies provide useful information on the extent and severity of the intestinal disease. The earliest abnormalities include altered bowel motility, and irregularity and thickening of the mucosal folds. Barium swallow may show compression of the oesophagus by a mediastinal node, with or without mucosal ulceration. In patients with more advanced disease, mucosal ulcers, deformity of the bowel lumen, and stricture formation are noted. Rarely, sinus tracts and fistulas may be seen. Thickening of the ileocaecal valve, a wide-open valve accompanied by narrowing of the terminal ileum (Fleischner sign)¹⁹, and a fibrotic terminal ileum opening into a contracted caecum (Sterlin sign) are characteristic of intestinal tuberculosis. *Enteroclysis* (small-bowel enema) is generally considered the ideal method of assessing the small bowel. This technique involves passing a tube into the distal duodenum, which greatly reduces enthusiasm for the test, both by the radiologist and the patient. Most radiologists therefore prefer the use of small-bowel series. The regular 20 per cent wt/vol barium mixture has a high density, which often prevents proper examination of overlapping bowel loops. Low-density barium preparations (13 per cent wt/vol) containing methylcellulose have been introduced in the belief that they permit better dispersion of a barium that is less prone to flocculation and has greater transradiancy, allowing a 'see-through' effect with good



BARIUM MEAL STUDY - ILEAL STRICTURE



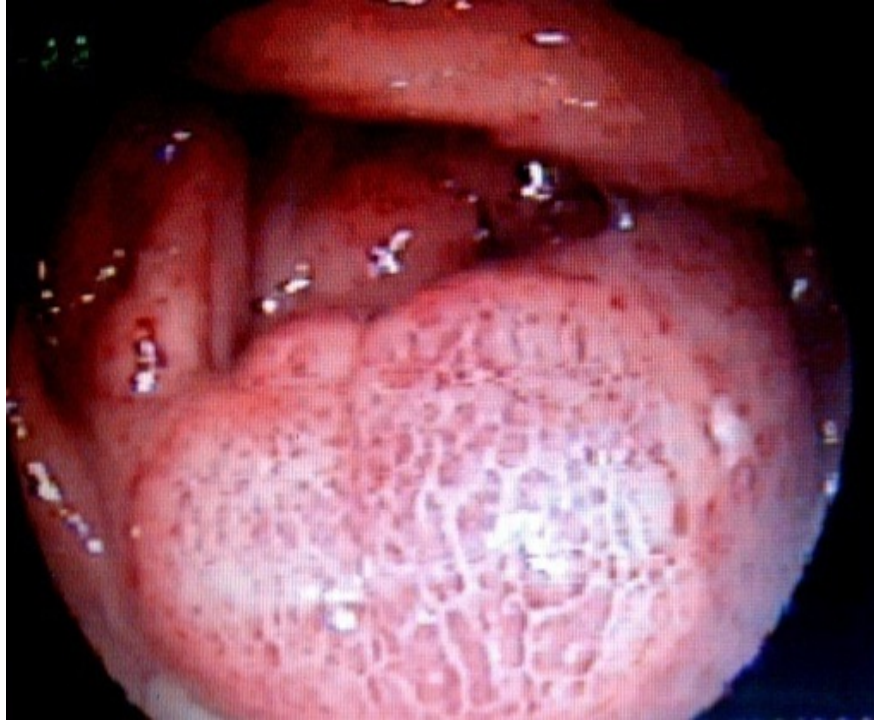BARIUM ENEMA - PULLED UP CAECUM

visualization of overlying loops. Whether these preparations are indeed better remains to be confirmed. For the large bowel the study of choice is air-contrast barium enema.

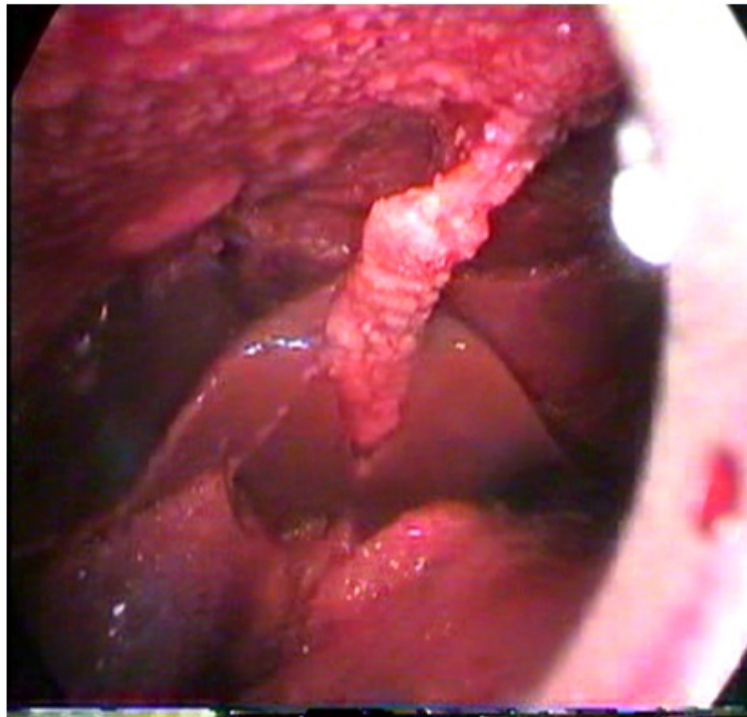
Overall, barium studies have a low sensitivity and are abnormal in only about 60 per cent of patients with endoscopically proven disease. A rapid transit and lack of barium retention may occur in inflamed segments of the small bowel, resulting in false-negative results. Moreover, the barium abnormalities are non-specific and can be mimicked by other conditions such as Crohn's disease and lymphoma.

Endoscopy with biopsy

Fibreoptic endoscopes have made it possible to visualize directly the gastrointestinal tract. The ileocaecal region can be accessed easily by colonoscopy, and the use of enteroscopes allows examination of the proximal small bowel. The usual endoscopic findings are mucosal ulcerations, nodularity, deformity, narrowing, and stricture of the bowel. Rarely, there is diffuse disease of the colon with hyperaemia and friability of the mucosa, mimicking ulcerative colitis. The endoscopic abnormalities in tuberculosis can be mistaken for Crohn's disease. Ulcers seen in tuberculosis are usually transversely located and have sharply defined margins with the surrounding mucosa showing erythema, while in



COLONOSCOPY – ULCERATIVE TUBERCULOSIS



LAPAROSCOPY – PERITONEAL TUBERCLES

Crohn's disease the ulcers are serpiginous, often longitudinal, with a relatively normal surrounding mucosa²²⁻²⁴.

Biopsy specimens obtained at endoscopy show granulomas and epithelioid cells in 40 to 74 per cent of patients with intestinal tuberculosis. However, confirmatory findings of caseation necrosis are present in only 8 to 21 per cent, acid-fast bacilli are observed infrequently, and positive cultures are obtained in only 6 to 40 per cent of patients. Although endoscopy provides a definitive diagnosis in only about one-third of the patients, it is very useful in excluding other conditions such as lymphoma, carcinoma, and caecal amoeboma.

Serological studies

Because of the difficulty in identifying *M. tuberculosis* in tissue material, a sensitive and specific serological test should be very helpful. Infection with *M. tuberculosis* stimulates a cell-mediated as well as a humoral immune response. The tuberculin skin test is a manifestation of the cell-mediated immune response. Serological tests based on the detection of specific antibodies to *M. tuberculosis* have been under investigation for several years. *Mycobacterium tuberculosis* has a complex structure and contains numerous antigens that cross-react with each other as well as with antigens of other mycobacterial species. Enzyme-linked

immunosorbent assays based on the use of one of several bacterial antigenic preparations are commercially available, but they provide sensitivity, specificity, and diagnostic accuracy of only 80 per cent, and moreover are unable to identify clearly²⁵ (a) active disease from dormant infection, (b) *M. tuberculosis* infection from other mycobacterial infections, and (c) individuals with previous BCG inoculation.

Polymerase chain reaction

The low positive identification rate for *M. tuberculosis* in intestinal tuberculosis is related to the presence of small numbers of organisms in the tissues. By amplifying tiny quantities of DNA and RNA, the polymerase chain reaction is thus ideally suited for this condition. The technique has been used in a variety of clinical specimens including sputum, cerebrospinal fluid, pleural and peritoneal fluids, and biopsy tissues, with sensitivity, specificity and positive predictivity of 85, 99, and 95 per cent, respectively. Based on studies with pulmonary secretions, the polymerase chain reaction can detect as few as 50 organisms per reaction, which is at least fivefold below the lower limit of detection by culture. The technique has also been successfully used on endoscopically obtained biopsy specimens but much more work is required before it can be recommended for routine use.^{26,27}

TREATMENT

Medical treatment

The treatment of abdominal tuberculosis is primarily medical. Since acid-fast bacilli and caseation necrosis are seen in a minority of patients, and culture results take several weeks, chemotherapy plays very important role in the treatment of abdominal tuberculosis.²⁸

Short-term therapy:

The current guidelines put forward by the World Health Organization and the United States Centers for Disease Control recommends a much shorter course of therapy. The initial treatment consists of a three-drug regimen of isoniazid (300 mg), rifampicin (450 mg), and pyrazinamide (1.5 g) in countries where the resistance rate to isoniazid is below 4 per cent. In countries with higher drug-resistance rates, a fourth drug is added, ethambutol (25 mg/kg) or streptomycin (1 g). All drugs are administered daily for 2 months, after which the patient is switched to two drugs; isoniazid 300mg/day and rifampicin 450 mg/day for 4 months. Facilities for directly observed therapy are available, initial treatment is the same as in short-term therapy, but after 2 months patients are started on a twice-a-week regimen consisting of isoniazid (600 mg/day) and rifampicin (600

mg/day) for 4 months. Thus, the total length of treatment for both short-term and directly observed therapies is 6 months.

Although these guidelines are based on studies in pulmonary tuberculosis, there is no evidence that patients with abdominal tuberculosis require longer therapy. Patients should be monitored every 4 to 6 weeks for drug-related side-effects. Isoniazid should be discontinued if the liver enzymes (alanine and aspartate amino-transferases) increase threefold over baseline. It is advisable to administer pyridoxine hydrochloride (5-10 mg/day) to all patients to prevent isoniazid-induced peripheral neuropathy. If a coexisting open pulmonary lesion is present, the patient should be isolated for 2 weeks. If not, the patient may be treated at home.

The clinical response to treatment is excellent. Systemic symptoms such as fever, malaise, and weight loss subside in a few weeks. Mucosal abnormalities take longer, but follow-up barium studies and endoscopy demonstrate regression of the lesions in most individuals. The majority of patients (70%) with symptoms of subacute bowel obstruction and evidence of intestinal stricture show complete resolution of the radiological abnormality.²⁸

Antituberculosis-drug resistance

Multidrug-resistant *M tuberculosis* received little attention until the early

1990s when several outbreaks were reported in patients with HIV. In 1994, the World Health Organization initiated global surveillance for antituberculosis-drug resistance in 35 countries and results of the first 4 years (1994-1997) of this project were recently published. Among patients with no prior treatment, a median of 9.9 per cent (range 2-41 per cent) were resistant to at least one drug and multidrug resistance was seen in 1.4 per cent (0-14.4 per cent). The resistance rates to individual drugs were: isoniazid 7.3 per cent, streptomycin 6.5 per cent, rifampicin 1.8 per cent, and ethambutol 1 per cent. Much higher rates of drug resistance were observed in patients with history of previous antituberculous treatment.

Drug resistance is a major threat to tuberculosis control programmes worldwide. Patients with resistant strains are less likely to be cured, and the treatment is more expensive and more toxic than in those with susceptible organisms. Multidrug resistance occurs more frequently in non-compliant patients, in the presence of HIV infection, and in malnourished individuals. The current emphasis is to create more facilities for directly observed therapy. Studies show that unsupervised treatment has a drug-completion rate of only 25 to 50 per cent, while directly observed therapy results in 85 to 90 per cent cure, with relapse rates of only 5 per cent.

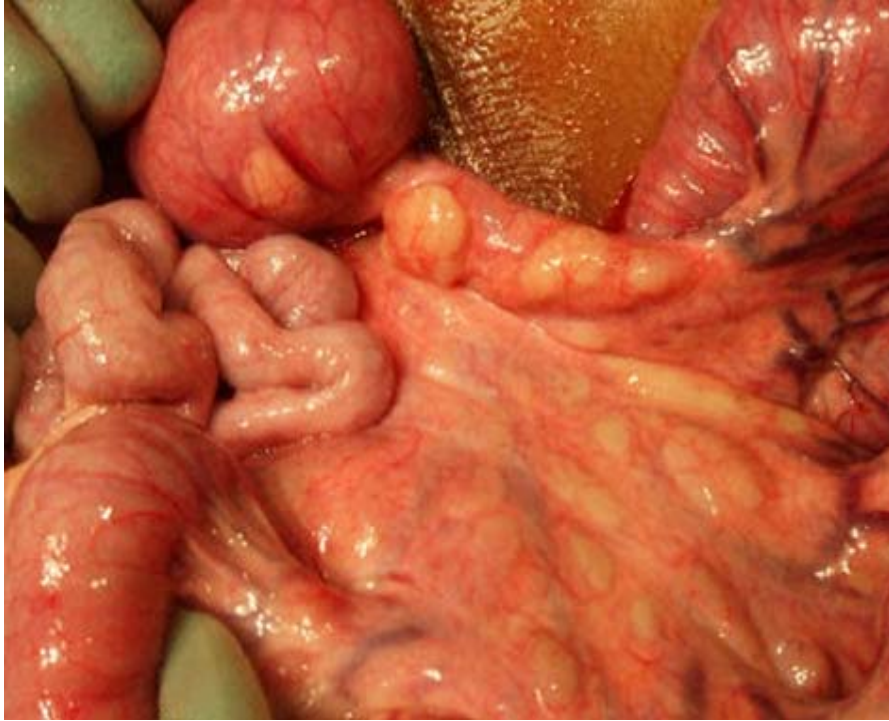
ROLE OF SURGERY

Indications:

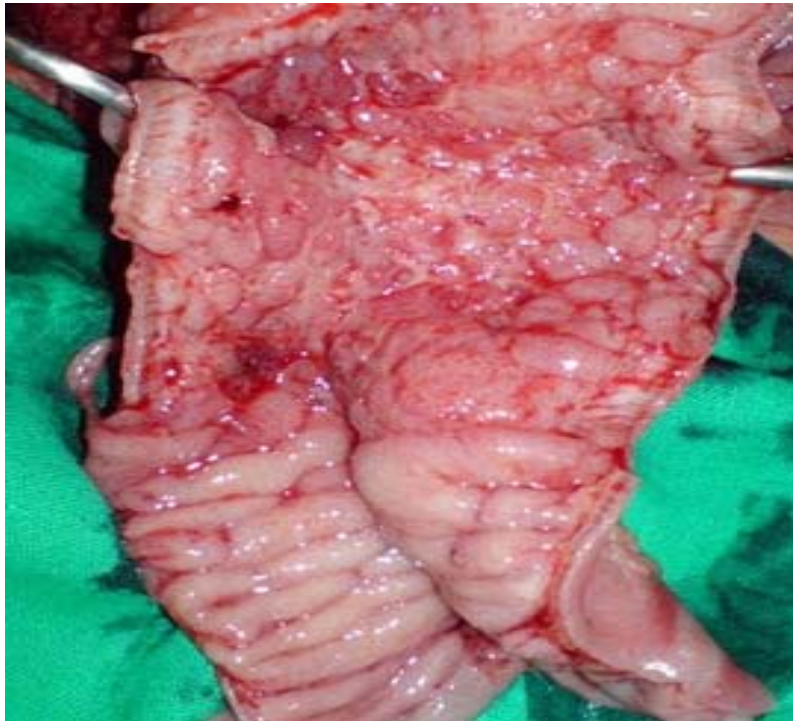
Surgery is reserved for mechanical complications of tuberculosis or when medical therapy fails. Emergency surgery is indicated in the presence of acute complications such as free perforation of the bowel and severe intestinal haemorrhage. The most common indication for surgery is intestinal obstruction secondary to stricture formation. In these patients, unless there is complete obstruction, conservative management is advocated. If symptoms persist, elective surgery is performed at a later stage, with significantly less morbidity. Predictors for surgical intervention are long strictures (12 cm or more in length) and multiple areas of involvement. Other indications for surgery are bowel adhesions, intra-abdominal abscess due to a confined perforation, mesenteric abscess, and internal or external fistulas. Surgery is also appropriate if the diagnosis is in doubt and when malignancy cannot be ruled out with reasonable accuracy.^{15, 29,30}

Surgical procedures:

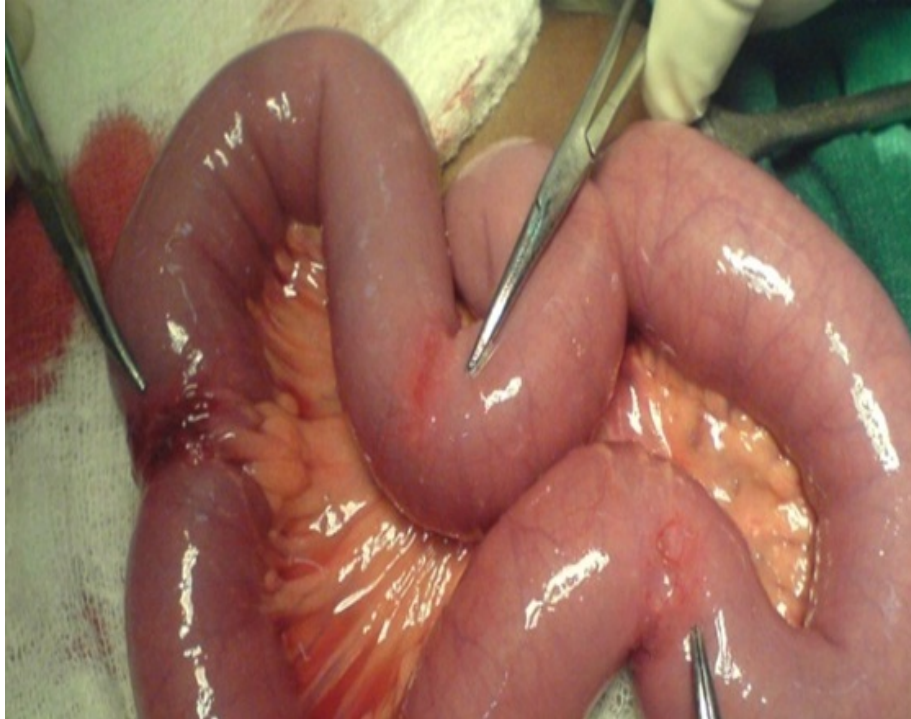Patients presenting with acute bowel perforation should be treated by resection of the involved segment and primary anastomosis. Simple closure of perforation is followed by a high incidence of reperforation and fistula formation. Drainage tubes are not recommended and, if used, should be removed early



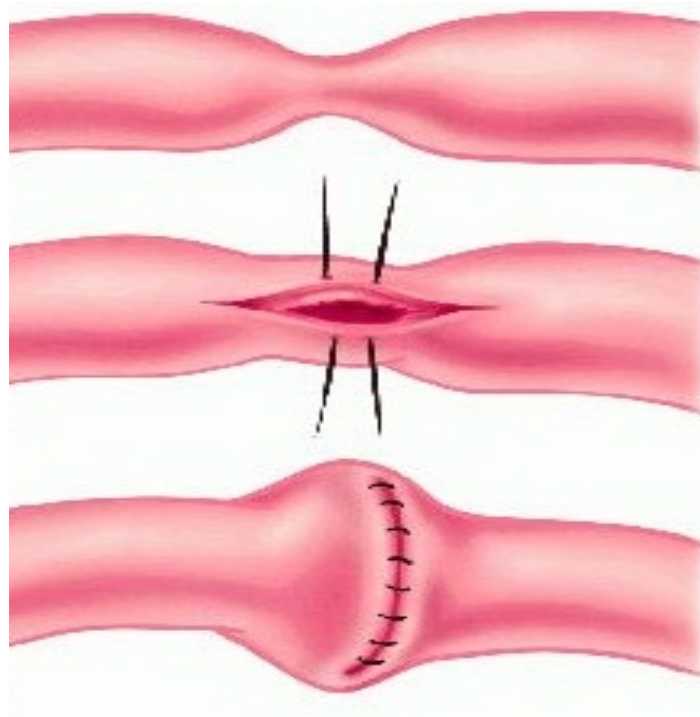
MESENTRIC ADENITIS



ULCERATIVE TUBERCULOSIS



TUBERCULOUS ILEAL STRICTURE



STRICTUROPLASTY

because of increased risk of abdominocutaneous fistulas if they are left in place for more than 7 days.

Surgical techniques for patients with bowel obstruction have evolved over time. At one time, bypass procedures such as ileotransverse colostomy and enteroenterostomy were practiced commonly, but have now been abandoned because of complications such as blind-loop syndrome, malabsorption, and perforation. Similarly, radical bowel resection and extensive dissection of mesenteric lymph nodes have fallen out of favour because of complications, including the development of short-bowel syndrome. The order of the day is minimal surgery. The procedure of choice for an ileocaecal mass is limited resection with 5-cm margins from visibly abnormal tissue in place of the standard right hemicolectomy. Segmental bowel resection has become rare and is only performed if multiple strictures are located in close proximity. Most surgeons prefer stricturoplasty for lesions involving the small bowel. Other procedures advocated are ileocaecoplasty and coloplasty for ileocaecal and colonic strictures, respectively.³¹⁻³³

Approach to intestinal adhesions:

Intestinal adhesions require a meticulous surgical approach. In addition to releasing the adhesions, enteric stenting has been found useful in preventing

adhesive bowel obstruction. Patients with florid sepsis may be treated by laparostomy, followed by secondary abdominal closure once the sepsis is controlled; this prevents recurrent adhesions and reduces postoperative morbidity and mortality. Patients with enterocutaneous fistulas are treated by resection of the fistulous tract, drainage of any intra-abdominal abscess, and intestinal anastomosis. A multicentre, prospective, randomized trial has shown that the interposition of a barrier film for a sufficient length of time between diseased areas of intestine contributes to adhesion-free healing. Seprafilm and Interceed are a few of the commercially available barrier films proved to be effective. Some of these patients may need stenting in addition to barrier-film placement.

SPECIFIC FORMS OF TUBERCULOSIS

Appendiceal:

Tuberculosis of the appendix is reported in 0.1 to 3 per cent of patients with tuberculosis. Isolated tuberculosis of the appendix is rare. Appendectomy followed by antituberculosis chemotherapy is the treatment of choice.

Anal canal:

Patients with tuberculosis of the anal canal may present with multiple fistulas,

fissures, or perianal abscesses. Treatment consists of drainage of the abscess combined with antituberculous chemotherapy.³⁴⁻³⁶

Gastric:

Involvement of the stomach is rare, occurring in 0.3 to 2.3 per cent of patients with pulmonary tuberculosis. The rarity of this location is related to several factors including the resistance of the gastric mucosa to infection, the lack of lymphoid tissue in the stomach, and the constant flow of contents through the stomach. Tuberculosis of the stomach presents as an ulcerative, granulomatous, or fibrosing lesion; the last two types may result in gastric-outlet obstruction. At endoscopy, the lesion may be mistaken for peptic ulcer disease, gastric carcinoma, or gastric sarcoidosis. Similar appearances are also seen in syphilis of the stomach. The diagnosis may be confirmed on endoscopic biopsy specimens.

Antituberculous chemotherapy should be initiated in all patients; this is curative in most, especially those with ulcerative lesions, which can be confirmed on repeat endoscopy and biopsy. Surgical intervention is required if gastric-outlet obstruction persists despite treatment. The usual surgical approach is a partial gastric resection such as a Billroth gastrectomy or a sleeve resection. Gastric cancer presents in a similar fashion, and both tuberculosis and cancer may coexist in the same patient. Therefore, if there is any doubt about the diagnosis, it is best

to proceed with frozen-section biopsy followed by surgical resection if indicated.³⁷⁻⁴³

Liver and spleen:

Hepatic tuberculosis has become exceedingly rare these days. The diagnosis is usually made accidentally during exploratory laparotomy or at autopsy in immunocompromised patients. The lesions typically are granulomas, with or without central caseating necrosis, calcified masses, and biliary strictures. Tuberculous periportal lymph nodes may cause obstructive jaundice by compressing the bile duct. Patients with hepatic tuberculosis usually have hepatomegaly, with or without jaundice. Symptoms related to abdominal tuberculosis often overshadow those due to liver disease. Liver enzymes, in particular serum alkaline phosphatase, are usually elevated. Tuberculosis should be differentiated from other conditions associated with hepatic granulomas such as leprosy, sarcoidosis, Hodgkin disease, brucellosis, infectious mononucleosis, inflammatory bowel disease, drug-induced liver damage, and syphilis. Chronic active hepatitis may also mimic tuberculosis of the liver. The treatment of hepatic tuberculosis is chemotherapy. It should be remembered that most antituberculous drugs (except ethambutol) are hepatotoxic, and may aggravate the liver damage and worsen the jaundice. These patients therefore should be kept under close

observation during antituberculous chemotherapy.

Splenic tuberculosis is also rare and may present as a splenic abscess or with hypersplenism. The presence of multiple hypoechoic lesions on ultrasonography of the spleen in a HIV-positive patient is highly suggestive of disseminated tuberculosis. The diagnosis is usually made following surgical resection of the diseased spleen.

'Silent' tuberculosis:

Subclinical or 'silent abdominal tuberculosis is seen mainly in patients belonging to upper socioeconomic groupings in the Third World countries. The onset of illness is often precipitated by stressful conditions. The patients present with atypical symptoms, resulting in frequent misdiagnosis. The response to short-term antituberculous drug therapy is excellent.

Abdominal Tuberculosis in childhood: Abdominal tuberculosis in children is seen most frequently in Immunosuppressed individuals and in those who have not been vaccinated with BCG. Clinically, weight loss and malaise occur in 95 per cent of these children, followed by abdominal distension (83 per cent), abdominal pain (79 per cent), and anaemia (76 per cent). Laboratory tests show leucocytosis and an altered albumin/globulin ratio; pulmonary tuberculosis is seen on the chest radiograph. Imaging studies, including plain radiographs, ultrasonography, CT,

and gastrointestinal contrast studies, are helpful in localizing the defect. The diagnosis is confirmed on tissue obtained by endoscopic biopsy or with echo- or CT-guided fine-needle aspiration; samples may be stained by the Ziehl-Nielsen method for acid-fast bacilli, subjected to microbiological culture and drug-sensitivity testing, and examined histopathologically. A short course of chemotherapy is an effective and economical treatment, and is associated with minimal side-effects in children.

HIV and tuberculosis:

Abdominal tuberculosis in HIV-infected patients is invariably a manifestation of disseminated disease and results in significant mortality. Extrapulmonary tuberculosis is seen in over 50 per cent of patients. Fever, weight loss, lymphadenopathy, and splenic abscesses are seen more commonly in HIV-infected patients than in those without HIV infection. The diagnostic techniques are the same as in uninfected individuals and include bacteriological testing of body fluids, abdominal ultrasound and CT scanning combined with guided-needle aspiration biopsies, barium examination, fiberoptic endoscopy, and laparoscopy. Serological tests such as enzyme-linked immunosorbent assay lack sensitivity due to a poor humoral immune response. Most patients respond well to conventional antituberculous drugs used in standard doses. Some experts recommend a longer

course of therapy (9 months). Despite treatment, a few patients experience a downhill course, which may be due to drug resistance or the presence of overwhelming infection.

PROGNOSIS

The prognosis of uncomplicated abdominal tuberculosis is good. Most patients respond well to medical therapy and the outcome of surgical management of complications is generally good. Bowel obstruction or perforation associated with plastic adhesions and the development of enterocutaneous fistulas with intra-abdominal abscesses are associated with increased morbidity and poor prognosis.

GENERAL RECOMMENDATIONS

The main advance in the diagnostic approach to patients with suspected abdominal tuberculosis is the use of endoscopy. Most patients with peritoneal tuberculosis can be diagnosed by laparoscopy, since the peritoneal appearances are fairly distinctive and the histological yield is high. If this facility is not available, adenosine deaminase in ascitic fluid should be assessed because of its high positive predictive value for tuberculosis, especially in patients without coexisting cirrhosis or HIV infection. In contrast to peritoneal tuberculosis, the diagnosis of gastrointestinal tuberculosis is more difficult. All endoscopically accessible lesions should be biopsied and the specimens used for histology, staining for acid-fast

bacilli, and culture. Even if a positive diagnosis of tuberculosis is not made, diseases such as carcinoma and lymphoma can be excluded. The next step in endemic countries is a therapeutic trial with antituberculous drugs. The majority of patients, even those with strictures, show a good response. In the West, where tuberculosis has made a major comeback, the main differential diagnosis is with Crohn's disease, and the clinical, radiological, and histological features of the two are often indistinguishable. Here, a specific diagnostic test for *M. tuberculosis* such as polymerase chain reaction, may prove extremely helpful.

AIMS & OBJECTIVES OF THE STUDY

1. To find out demographic profile of abdominal tuberculosis
2. To study the clinical presentations of abdominal tuberculosis.
3. To evaluate the diagnostic modalities of abdominal tuberculosis.
4. To discuss the medical and surgical modalities of treatment of abdominal tuberculosis

MATERIALS AND METHODS

STUDY AREA:

Department of general surgery in Madurai medical college, government Rajaji hospital , Madurai.

SAMPLE SIZE:

72 cases of abdominal tuberculosis

STUDY DESIGN:

Descriptive study

STUDY PERIOD:

June 2009 to May 2011

METHOD OF SAMPLING:

Convenient sampling

INCLUSION CRITERIA:

All patients who were diagnosed abdominal tuberculosis based on Radiological and/or Laparoscopic evidence with or without histopathological evidence.

EXCLUSION CRITERIA:

All patients who were in paediatric age group.

METHODOLOGY:

This descriptive study was done for a period of 2 years from June 2009 to May 2011 in Government Rajaji Hospital, Madurai, India. The proforma (Annexure) contains the following details demography , presentation, lab reports, radiological reports and management of these patients ,which were recorded after the consent of the patients. Collected datas were analysed.

RESULTS

The total number of cases who were diagnosed to be of abdominal tuberculosis in our study period was 72 patients. The male and females in our study group include 47 and 25 respectively. The sex ratio was 1.9:1 between males and females. (Table 1, Fig 1). There was a higher incidence of abdominal tuberculosis in the age group between 31-40 years of age in both the genders followed by the patients between 21-30 years of age. (Table 2, Fig 2). The clinical manifestations varying from Acute intestinal obstruction to non specific illness, with acute intestinal obstruction was a initial clinical presentation in one third of the patients, abdominal distension in 16 patients, features of peritonitis in one sixth of patients, mass in the abdomen in 10 patients, and non specific symptoms in 10 patients. (Table 3, Fig 3).

All the patients underwent routine laboratory investigations like total blood count and Erythrocyte sedimentation rate (ESR). Lymphocytosis was found in 59.71% of patients and raised ESR was found in 90.2 % of the patients in the study group. The ascitic fluid analysis which was done in 22 patients who presented with ascites showed the biochemical and microbiological parameters of tuberculosis in 10 patients. (Table 4, Fig 4). Three patients showed positive serology for HIV.

All patients underwent Roentgenogram of chest which showed features of active and healed pulmonary lesions, pleural effusion in one sixth of the patients with sensitivity of 16.6% for diagnosis of tuberculosis. X-ray of abdomen done in all patients who showed features of intestinal obstruction, perforative peritonitis, and calcified lymph nodes. Ultrasonographic evaluation of abdomen which was done in all patients revealed features suggestive of tuberculosis in 34 patients (47.2%). The computed tomography (CT) of abdomen was done in 7 patients suspected to be having features of abdominal tuberculosis clinically and ultrasonography did not provide a conclusive diagnosis. Also CT of abdomen was done in 38 other patients who underwent ultrasonographic examination which did not provide a conclusive diagnosis or other diagnosis for further diagnostic evaluation. CT done in total of 45 patients concluded to be of abdominal tuberculosis in 32 patients. Barium meal and Barium enema done in 9 and 6 patients respectively for small bowel and large bowel lesions when indicated showed a sensitivity of 66.6% and 40% respectively. (Table 5, Fig 5). Colonoscopic examination done in 8 patients when large bowel lesions were suspected revealed tuberculous lesions in 2 patients. Diagnostic laparoscopy was done in 28 patients of our study group which included the patients who did not have conclusive diagnosis after radiological diagnosis and also patients with radiological investigations supporting abdominal tuberculosis for further

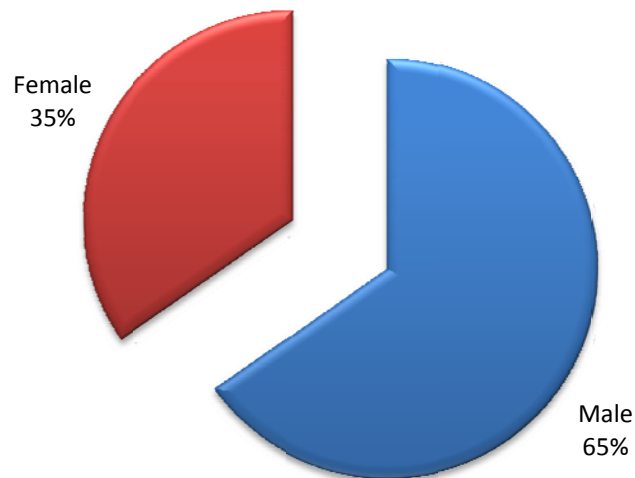
confirmatory evidence and tissue diagnosis. It showed a sensitivity of 92.8 % in our study group. (Table 6, Fig 6)

Of the 72 patients in the study group, only 35 patients needed surgical interventions whereas 37 patients were managed with chemotherapeutic drugs (Table 7, Fig 7). Emergency surgical management was done in total of 8 patients which include Right hemicolectomy in 2 patients, stricturoplasty in 2 patients, limited resection in 2 patients, and perforation closure and covering ileostomy in the other 2 patients. 27 patients had undergone management electively after complete investigatory evaluation, the surgical procedures include right hemicolectomy in 7 patients, adhesiolysis in 4 patients, stricturoplasty in 6 patients, limited resection in 3 patients, abscess drainage in 2 patients, adhesiolysis and abscess drainage through laparoscopy in 3 patients, sealed perforation closure which presented with interloop abscess in a case. (Table 8,9 and Fig 8,9). Of the 72 patients only 54 had histological evidence of abdominal tuberculosis.

TABLE 1: SEX DISTRIBUTION OF ABDOMINAL TUBERCULOSIS IN OUR STUDY GROUP

Male	Female	Total
47	25	72

Fig 1: Sex Distribution of abdominal tuberculosis in the study group



Male : female Ratio – 1.9:1

Table 2: Age Distribution Among The Genders In Our Study Group

	Male	Female	Total
<20 yrs	4	5	9
21-30	9	5	14
31-40	22	7	29
41-50	6	4	10
>50	6	4	10
Total	47	25	72

Fig 2: AGE DISTRIBUTION AMONG THE GENDERS IN OUR STUDY GROUP

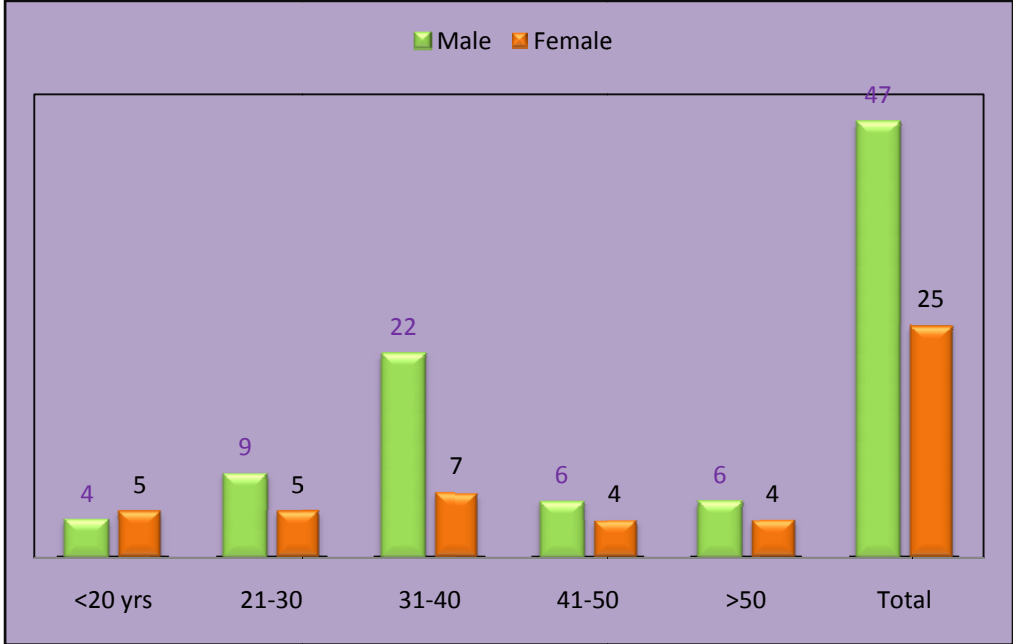


Table: 3 Clinical presentation of abdominal tuberculosis in our study

S. No	Clinical Presentation	No. of Patients
1	Intestinal obstruction	24
2	Peritonitis	12
3	Abdominal distention	16
4	Abdominal mass	10
5	Non specific symptoms	10

Fig 3: Clinical presentation of abdominal tuberculosis in our study

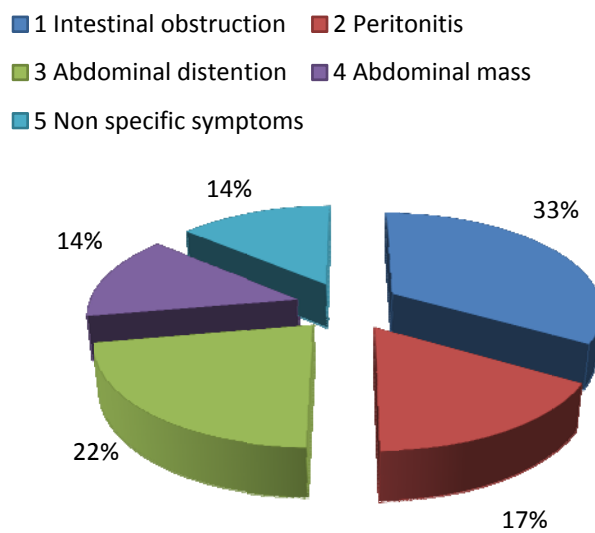


TABLE 4: LABORATORY INVESTIGATIONS DONE IN OUR PATIENTS AND ITS SENSITIVITY

S. No	Laboratory Investigations	No. of Patients investigated	Positive	Sensitivity
1	Lymphocytosis	72	43	59.71%
2	ESR	72	65	90.2%
3	Ascitic Fluid	22	10	45.4%

Fig 4: Sensitivity of Laboratory investigations.

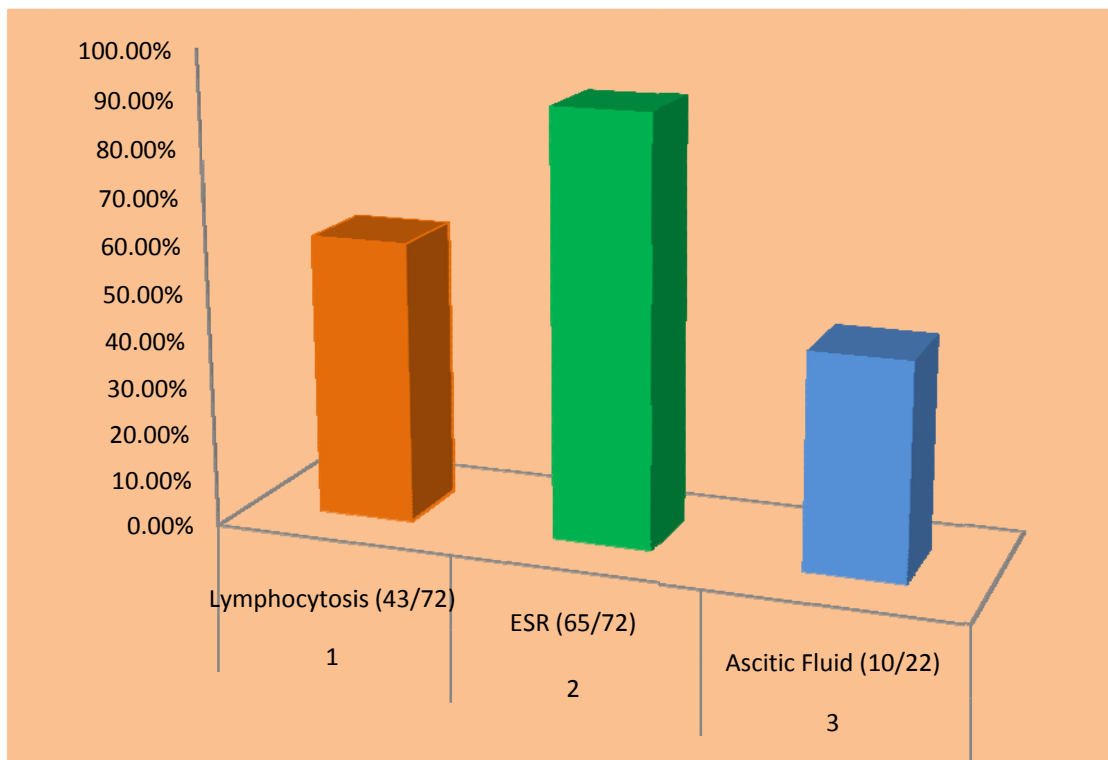


TABLE 5: RADIOLOGICAL INVESTIGATIONS DONE IN OUR PATIENTS.

S.No	Radiological Investigations	No .of Patients Performed	Positive	Sensitivity
1	X – ray Chest	72	12	16.6%
2	USG Scan	72	34	47.2%
3	CT Scan	45	32	71.1%
4	Barium meal	9	6	66.6%
5	Barium Enema	5	2	40%

Fig 5: Sensitivity of various radiological investigations in our study group.

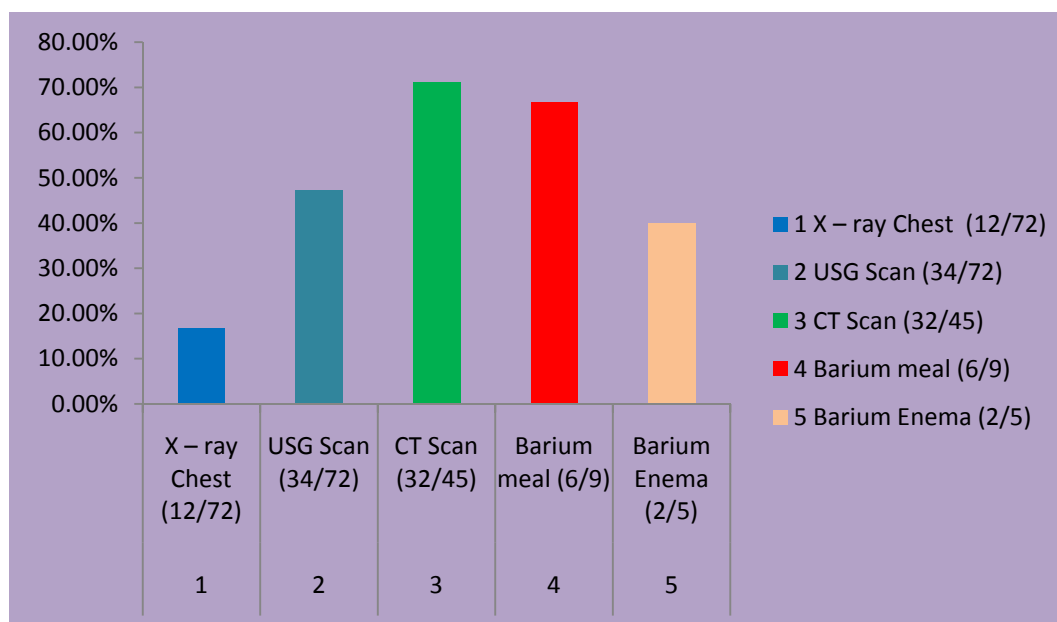


TABLE 6: Sensitivity of colonoscopy and diagnostic laparoscopy

S. No.	Investigations	Total No. of patients underwent	Positive	Sensitivity
1.	Colonoscopy	8	2	25%
2	Laparoscopy	28	26	92.8%

Fig 6: Sensitivity of colonoscopy and diagnostic laparoscopy

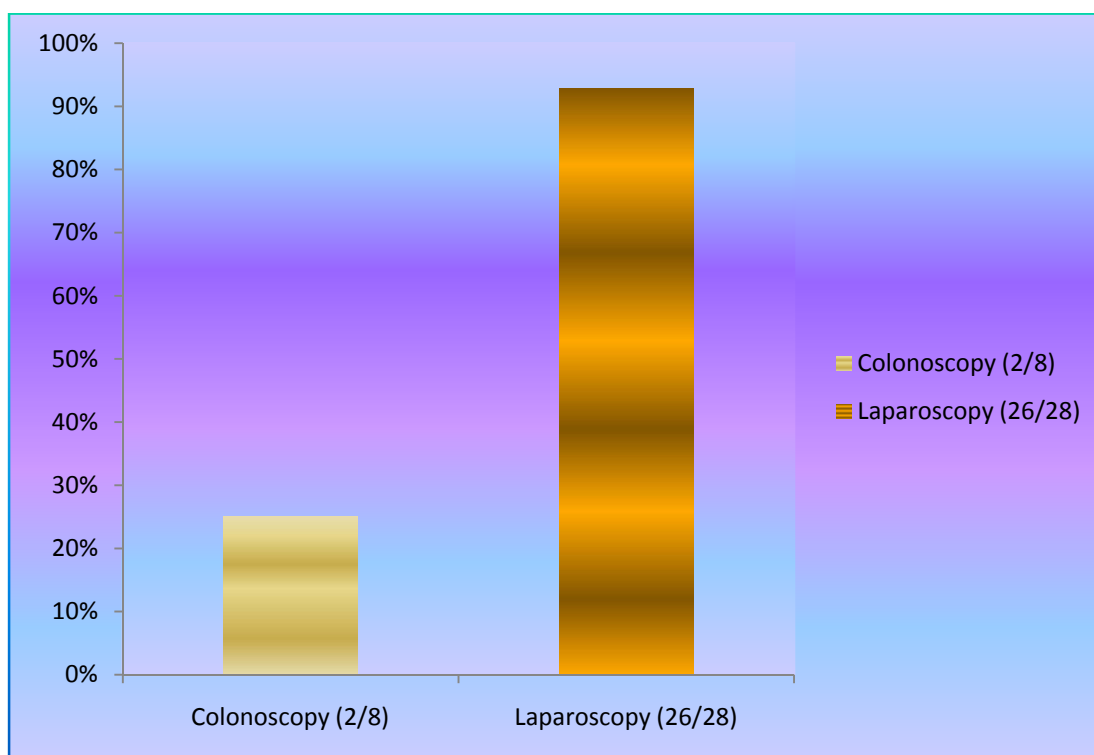


TABLE: 7 - MANAGEMENT OF ABDOMINAL TUBERCULOSIS IN OUR PATIENTS.

Surgical	Medical
35	37

Fig 7: Management of abdominal tuberculosis in our patients.

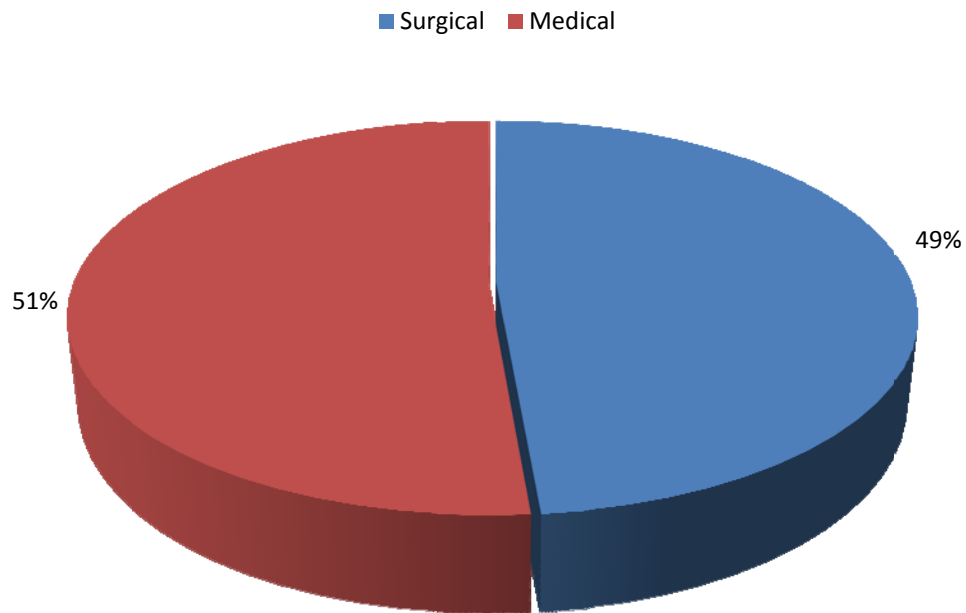


TABLE 8: Time Of Surgical Management

Elective	Emergency
27	8

Fig.8 Time of surgical management in our patients

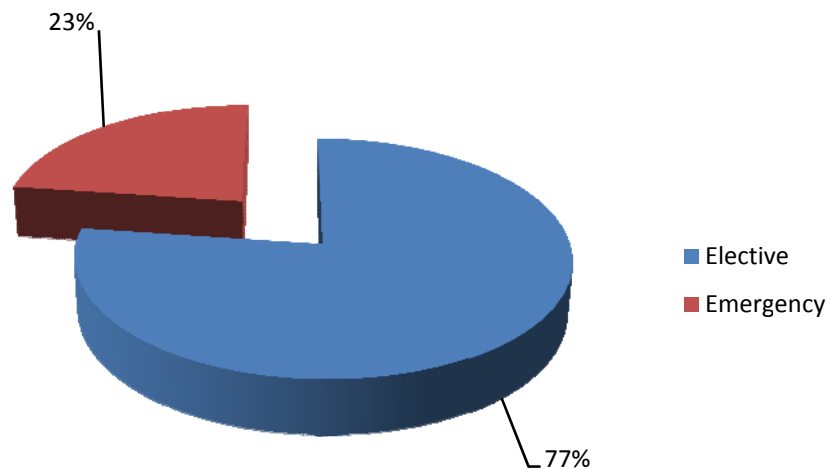
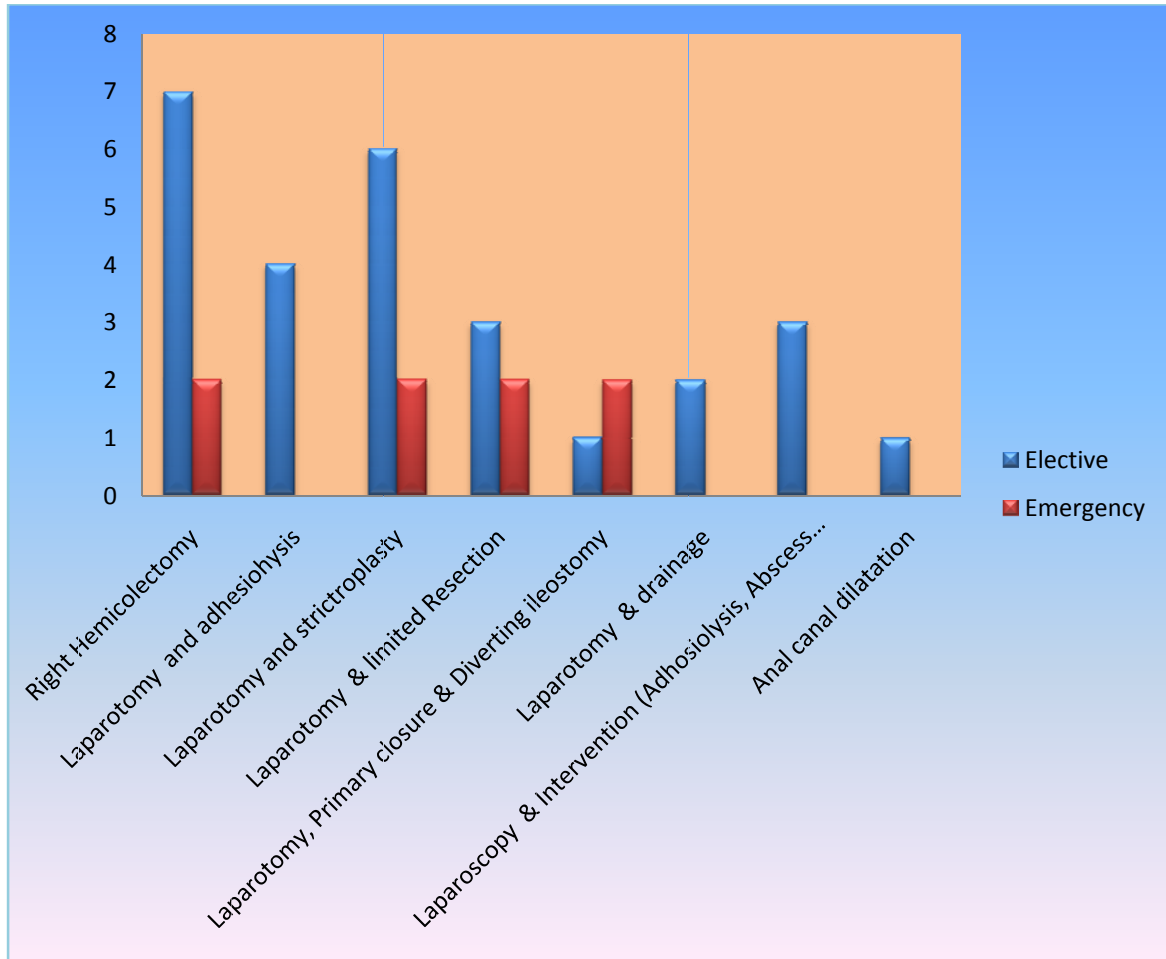


TABLE 9: DETAILS OF SURGICAL PROCEDURE DONE FOR ABDOMINAL TUBERCULOSIS IN OUR PATIENTS

S.No	Procedure	Elective	Emergency	Total
1	Right Hemicolectomy	7	2	9
2	Laparotomy and adhesiolysis	4	-	4
3	Laparotomy and stricturoplasty	6	2	8
4	Laparotomy & limited Resection	3	2	5
5	Laparotomy, Primary closure & Diverting ileostomy	1	2	3
6	Laparotomy & drainage	2	-	2
7	Laparoscopy & Intervention (Adhesiolysis, Abscess drainage)	3	-	3
8	Anal canal dilatation	1	-	1
	Total	27	8	35

Fig 9: Details of surgical procedures performed for abdominal tuberculosis in our patients.



DISCUSSION

In our study commonest age group affected was 2nd to 4th decade of life. Age incidence of present series is similar to reported by other workers [Adams and Miller,1946, Dutta Guptha1950,Sharma et al ,1972 B.K Bhansali,1968]. Pritam Das and Sukula .et.al 1978 , also reported same age group. The male and females in our study group include 47 and 25 respectively. The sex ratio was 1.9:1 between males and females Addison et al 1981 reported high incidence in males.

The clinical manifestations varying from Acute intestinal obstruction to non specific illness with acute intestinal obstruction was a initial clinical presentation in one third of the patients, abdominal distension in 16 patients, features of peritonitis in one sixth of patients, mass in the abdomen in 10 patients, and non specific symptoms in 10 patients. Badaoui E ,BerneyT , Kaiser L et al 2000,also reported similar presentation.

M P Sharma and Vikram Bhatia stated in their review article about the clinical presentation dominated by constitutional symptoms. 40-70% of patients present with fever, 80-95% with pain, 11-20% with diarrhea, 40 -90% with weight loss. N.Rangabashyam.et.al cited vague symptoms to be the predominant presenting symptoms. The abdominal pain accounts for in 77-94% of patients, followed by vomiting and abdominal distension.

Majority of patients in the present study had present with chronic symptoms. 8 out

of 72 patients had presented with an acute abdomen and underwent emergency surgery for the same. J.M.Findly 1981 found that acute presentation was present in 13.5% patients. Commonest symptom is vague abdominal pain .Other common symptoms were vomiting, fever, loss of appetite and loss of weight. Pritam Das and Sukula had reported abdominal pain in 94% of cases Bockus et al 1964 emphasised abdominal pain , anorexia ,loss of weight as common presenting symptoms. Shukula 1970 and L.E Hugas also reported these symptoms as common presentation

Any patient present with vague abdominal pain, vomiting , loss of appetite , loss of weight and not fitting with any other clinical diagnosis , diagnosis of abdominal tuberculosis should be considered.

Routine laboratory tests have limited value in the diagnosis of abdominal TB. Although the mantoux test is freely available, its value in the diagnosis active TB remains uncertain. Lymphocytosis was found in 59.71% of patients and raised ESR was found in 90.2 % of the patients in the study group.

Radiological studies

Chest X-ray:

Evidence of tuberculosis in a chest Roentgenogram supports the diagnosis of abdominal tuberculosis but a normal chest X-ray does not rule it out. Sharma *et al* studied 70 cases of abdominal tuberculosis and found evidence of active or healed

lesions on chest X-ray in 22 (46%). X-rays were more likely to be positive in patients with acute complications (80%). In Prakash's series of 300 patients, none had active pulmonary tuberculosis but 39 per cent had evidence of healed tuberculosis. Tandon *et al* found chest X-ray to be positive in only 25 per cent of their patients. Hence, about 75 per cent cases do not have evidence of concomitant pulmonary disease. Plain X-ray abdomen may show enteroliths, features of obstruction *i.e.*, dilated bowel loops with multiple air fluid levels, evidence of ascites, perforation or intussusception. In addition, there may be calcified lymph nodes, calcified granulomas and hepatosplenomegaly.

In our study group, out of all 72 patients, of chest x ray in 12 patients (16.67%) ,9 patients showed features of healed pulmonary tuberculosis whereas active pulmonary lesions found in 3 patients in contrast to the above literatures. 83.4% of patients in our study group did not have any evidence of concomitant pulmonary tuberculosis. Chest X- ray gives evidence of old or active pulmonary tuberculosis but rather they provide the indirect suspicion of abdominal tuberculosis.

30 patients in our study group out of 72, had evidence of features of intestinal obstruction, perforation, and ascites. None of the features in abdominal x

ray gave diagnostic evidence of abdominal tuberculosis but rather they provide the features of various presentations of abdominal tuberculosis. X ray abdomen though plays an important role in evaluation, but do not provide the diagnostic conclusion of abdominal tuberculosis.

Small bowel barium meal and large bowel barium enema: The features which may be seen: Accelerated intestinal transit; hyper segmentation of the barium column (“chicken intestine”), precipitation, flocculation and dilution of the barium; stiffened and thickened folds; luminal stenosis with smooth but stiff contours (“hour glass stenosis”), multiple strictures with segmental dilatation of bowel loops, may also be found; and fixity and matting of bowel loops. Barium meal was done in 9 of our patients which revealed the features of abdominal tuberculosis in 6 patients. Barium meal studies do have limitations in its diagnosis and application for the patients and cannot be used in all cases but has its significance in cases of strictures with proximal dilation. Barium enema with radiological diagnostic features as explained earlier was found in 2 of our patients but the features were nonspecific. Barium enema gives supportive evidence to the diagnosis. Barium studies though accurate for intrinsic bowel abnormalities, do not detect lesions in the peritoneum. Enteroclysis followed by a barium enema may be the best protocol for evaluation of intestinal tuberculosis and that is to be evaluated further.

Ultrasonography

Ultrasonography is a cheap and valuable investigation in the evaluation of abdominal tuberculosis when the clinical features have suspicion of abdominal tuberculosis. They are particularly useful in cases of abdominal mass (Coacoon), lymph nodes, ascites and dilated bowel loops. USG was found to be 47.2% of patients in our study group whereas other study groups from Uvqur et al showed sensitivity of 57% and Dobok G et al viewed a sensitivity of 54.2%. Ultrasonography is a non expensive diagnostic tool which can be used as initial radiological diagnostic modality.

Computed tomography:

CT of abdomen has high sensitivity than USG for diagnosis of cases with diffuse lymphadenopathy, low density lymph node with multilocular appearance following intravenous contrast, High density ascites, and mottled low density masses in the omentum thickening of the Bowel wall adjacent to mesentery and also with hepatic pseudo tumors. CT abdomen has a sensitivity of 71.1% in 45 patients in which CT was done which was marginally comparable to the observations of Dobak G et al who experienced a sensitivity of 69%.

Colonoscopy

Colonoscopy is an excellent tool to diagnose colonic and terminal ileal involvement but is still often underutilized in many of the institutions. Mucosal nodules of variable sizes (2 to 6 mm) were found in 2 of the 8 patients in which the colonoscopy was performed. Colonoscopy has its limitations in its indications and observer variant.

Immunological tests

Chawla *et al* reported a high sensitivity of ELISA for soluble antigen and Bhargava *et al* used competitive ELISA with monoclonal antibody against 38 Kd protein and found a sensitivity of 81 per cent, specificity of 88 per cent and diagnostic accuracy of 84 per cent. These above tests were not evaluated in our study. The values of immunological tests are not clearly understood in our clinical evaluation.

Ascitic fluid examination:

The ascitic fluid in tuberculosis is straw coloured with protein $>3\text{g/dl}$, and total cell count of $150\text{-}4000/\mu\text{l}$, consisting predominantly of lymphocytes ($>70\%$). The ascites to blood glucose ratio is less than 0.9650 and serum ascites albumin

gradient is less than 1.1 g/dl. In our study group laboratory and microbiological evidence done in 22 patients revealed features of tuberculosis in 10 patients. Ascitic fluid microbiological evidence needs 6-8 weeks of period for organism growth and it has its diagnostic limitation.

ADA levels were determined in the ascitic fluid of 49 patients by Dwivedi *et al.* The levels in tuberculous ascites were significantly higher than those in cirrhotic or malignant ascitis. In coinfection with HIV the ADA values can be normal or low. Falsely high values can occur in malignant ascitis. High interferon- γ level in tubercular ascites have been reported to be useful diagnostically. Combining both ADA and interferon estimations may further increase sensitivity and specificity.

Laparoscopic findings:

Bhargava *et al* studied 87 patients with high protein ascites, of which 38 were diagnosed as having tuberculosis. They found visual appearances to be more helpful (95% accurate) than histology, culture or guinea pig inoculation (82% and 37.5% sensitivity respectively). Caseating granulomas may be found in 85-90 per cent of the biopsies.

In our study group where 28 patients underwent diagnostic laparoscopy, 26 patients had features diagnosis of tuberculosis based on visual appearances. Tissue diagnosis taken for confirmation showed caseating granulomas in 23 patients.

Laparoscopy plays a very important role in the diagnosis of abdominal tuberculosis and it needs to be evaluated as initial diagnostic tool.

Management:

On discussing about the surgical management of abdominal tuberculosis, Surgery is reserved for mechanical complications of tuberculosis or when medical therapy fails. Emergency surgery is indicated in the presence of acute complications such as free perforation of the bowel and severe intestinal haemorrhage. The most common indication for surgery is intestinal obstruction secondary to stricture formation. Predictors for surgical intervention are long strictures (12 cm or more in length) and multiple areas of involvement Other indications for surgery are bowel adhesions, intra-abdominal abscess due to a confined perforation, mesenteric abscess, and internal or external fistulas. Surgery is also appropriate if the diagnosis is in doubt and when malignancy cannot be ruled out with reasonable accuracy.^{15, 29,30}

Surgical procedures:

In our study group, only 35 patients needed surgical interventions whereas 37 patients were managed with chemotherapeutic drugs . Most frequent interventions were right hemicolectomy (9patients), stricturoplasty (8patients), limited resection (5patients), adhesiolysis (4patients), laparoscopy intervention(3patients) and covering ileostomy(3patients). Similar observations

were made by Balasubramaniam *et al.*

Surgical techniques for patients with bowel obstruction have evolved over time. At one time, bypass procedures such as ileotransverse colostomy and enteroenterostomy were practiced commonly, but have now been abandoned because of complications such as blind-loop syndrome, malabsorption, and perforation. Similarly, radical bowel resection and extensive dissection of mesenteric lymph nodes have fallen out of favour because of complications, including the development of short-bowel syndrome. The procedure preferred for an ileocaecal mass is limited resection in place of the standard right hemicolectomy. Other procedures advocated are ileocaecoplasty and coloplasty for ileocaecal and colonic strictures. respectively.³¹⁻³³ Drainage tubes are not recommended and, if used, should be removed early because of increased risk of abdominocutaneous fistulas if they are left in place for more than 7 days. All patients who underwent surgery were given anti tuberculous drugs post operatively.

CONCLUSION

Abdominal Tuberculosis is a diagnostic enigma due to its vague clinical manifestations. The diagnosis can remain inconclusive even after laboratory and radiological evaluation. To diagnose tuberculosis a high degree of clinical suspicion is the prime needed.

Laparoscopy has a very significant role in establishing diagnosis in doubtful cases. Most patients with peritoneal tuberculosis can be diagnosed by laparoscopy, since the peritoneal appearances are fairly distinctive for tuberculosis.

The recommended surgical procedures today are conservative. Post operative conventional anti tubercular therapy for at least 6 months is recommended, but preoperative anti tubercular therapy is still controversial.

BIBLIOGRAPHY

1. Peda Veerraju E. Abdominal tuberculosis. In: Satya Sri S, editor. Textbook of pulmonary and extrapulmonary tuberculosis. 3rd ed. New Delhi: Interprint; 1998 p. 250-2.
2. Paustian FF. Tuberculosis of the intestine. In: Bockus HL, editor. Gastroenterology, vol.11, 2nd ed. Philadelphia :W.B. Saunders Co.; 1964 p. 311.
3. Wig KL, Chitkara NK, Gupta SP, Kishore K, Manchanda RL. Ileocecal tuberculosis with particular reference to isolation of Mycobacterium tuberculosis. *Am Rev Respir Dis* 1961; 84 : 169-78.
4. Vij JC, Malhotra V, Choudhary V, Jain NK, Prasaed G, Choudhary A, *et al.* Aclinicopathological study of abdominal tuberculosis. *Indian J Tuberc* 1992; 39 : 213-20.
5. Bhansali SK. Abdominal tuberculosis. Experiences with 300 cases. *Am J Gastroenterol* 1977; 67 : 324-37.
6. Tandon HD, Prakash A. Pathology of intestinal tuberculosis and its distinction from Crohn's disease. *Gut* 1972; 13 : 260-9.
7. Hoon JR, Dockerty MB, Pemberton J. Ileocaecal tuberculosis including a comparison of this disease with non-specific regional enterocolitis and noncaseous tuberculated enterocolitis. *Int Abstr Surg* 1950; 91 : 417- 40.

8. Kapoor VK. Abdominal tuberculosis. *Postgrad Med J* 1998; 74 : 459-6.
- 9 .Al Munnef M, Memish Z, Al Mahmoud SA ET al. Tuberculosis in the belly. A Review of forty-six cases involving the gastrointestinal tract and Peritoneum, *Scand J Gastroenterology* 2001 May; 36(5):528-32.
10. Bhansali SK, Sethna JR. Intestinal obstruction : a clinical analysis of 348 cases. *Indian J Surg* 1970; 32 : 57-70.
11. Gill , Eggleston FC. Acute intestinal obstruction. *Arch Surg* 1965; 91 : 589-91.
12. Wilkins EGL. Tuberculous peritonitis : diagnostic value of the ascitic / blood glucose ratio. *Tubercle* 1984; 65 : 47-52.
13. Dwivedi M, Misra SP, Misra V, Kumar R. Value of adenosine deaminase estimation in the diagnosis of tuberculous ascites. *Am J Gastroenterol* 1990; 85 : 1123-5.
14. Bhargava DK, Gupta M, Nijhawan S, Dasarathy S, Kushwaha AKS. Adenosine deaminase (ADA) in peritoneatuberculosis : diagnostic value in ascites fluid and serum. *Tubercle* 1990; 71 :1216.
15. Balasubramanian R, Ramachandran R, Joseph PE, Nagarajan M, Thiruvengadam KV, Tripathy SP, et al. Interim results of a clinical study of abdominal tuberculosis. *Indian J Tuberc* 1989; 36 : 117-21.
16. Sathar MA, Simjer AE, Coovadia YM, Soni PN, Moola SA, Insam B, et al. Ascitic fluid gamma interferon concentrations and adenosine deaminase activity in

tuberculous peritonitis. Gut 1995; 36 : 419-21.

17. Gulati MS, Sarma D, Paul SB. CT appearances in abdominal tuberculosis. A pictorial assay. Clin Imaging 1999; 23 : 51-9.

18. Bhargava DK, Shriniwas, Chopra P, Nijhawan S, DasarathyS, Kushwaha AK. Peritoneal tuberculosis: laparoscopic patterns and its diagnostic accuracy. Am J Gastroenterol 1992; 87 : 109-12.

19. Kapoor VK, Chattopadhyay TK, Sharma LK. Radiology of abdominal tuberculosis. Australas Radiol 1988; 32 : 365-7.

20. Tandon RK, Sarin SK, Bose SL, Berry M, Tandon BN. A clinico-radiological reappraisal of intestinal tuberculosis – changing profile? Gastroenterol Jpn 1986; 21 : 17-22.

21. Kedar RP, Shah PP, Shivde RS, Malde HM. Sonographic findings in gastrointestinal and peritoneal tuberculosis. Clin Radiol 1994; 49 : 24-9.

22. Bhargava DK, Tandon HD, Chawla TC, Shriniwas, Tandon BN, Kapur BM. Diagnosis of ileocecal and colonic tuberculosis by colonoscopy. Gastrointest Endosc 1985; 31 : 68-70.

23. Singh V, Kumar P, Kamal J, Prakash V, Vaiphei K, Singh Clinicocolonoscopy profile of colonic tuberculosis. Am J Gastroenterol 1996; 91 : 565-8.

24. Puri AS, Vij JC, Chaudhary A, Kumar N, Sachdev A, Malhotra V, et Diagnosis and outcome of isolated rectal tuberculosis. Dis Colon Rectum 1996; 39 : 1126-9.

25. Bhargava DK, Dasarathy S, Shriniwas MD, Kushwaha AKS, Duphare H, Kapoor BML. Evaluation of enzyme linked immunosorbent assay using mycobacterial saline extracted antigen for the serodiagnosis of abdominal tuberculosis. *Am J Gastroenterol* 1992; 87 : 105-8.
26. Gan HT, Chen YQ, Quyang Q et al. Differentiation between intestinal Tuberculosis and Cohn's disease in endoscopic biopsy specimens by Polymerase chain reaction. *Am J Gastroenterol* 2002;97:1446-1451.
27. Chan CM, Yuen KY, Chan KSW et al. Single tube nested PCR in the diagnosis of tuberculosis. *J Clin Pathol* 1996;49:290-294.
28. Balasubramanian R, Nagarajan M, Balambal R, Tripathy SP, Sundararaman R, Venkatesan P. Randomised controlled clinical trial of short course chemotherapy in abdominal tuberculosis: a five-year report. *Int J Tuberc Lung Dis* 1997; 1 : 44-51.
29. Anand BS, Nanda R, Sachdev GK. Response of tuberculous stricture to antituberculous treatment. *Gut* 1988; 29 : 62-9.
30. Pujari BD. Modified surgical procedures in intestinal tuberculosis. *Br J Surg* 1979; 66 : 180-1.
31. Sajjad mehmood khan Khalid mehmood khan, Abdus samad khan et al. Presentation of abdominal Tuberculosis in N.W.F.P. and its correlation with operative findings. *JPMI2005 vol.19 no.3 . 286-291.*

32. Akqun K. Intestinal and peritoneal tuberculosis: changing trends over ten years and Review of eighty cases. *Can J Surg.*:2005 Apr; 48(2):131-6.
33. Akinkuolie AA, A disa Ao, Aqba Kwurue A et al. Abdominal tuberculosis in Nigeria Teaching Hospital. *Afr. J. Med Sci.*2008 Sep; 37(3):225-9.
34. Dandapat MC, Mukherjee LM, Behra AN. Fistula in ano. *Indian J Surg* 1990; 52 : 265-8.
35. Shukla HS, Gupta SC, Singh C, Singh PA. Tubercular fistula in ano. *Br J Surg* 1988; 75 : 38-9.
36. Wadhwa N, Agarwal S, Mishra K. Reappraisal of abdominal tuberculosis. *J Indian Med Assoc* 2004; 102 : 31-2.
37. Ali W, Sikora SS, Banerjee D, Kapoor VK, Saraswat VA, Saxena R, et al. Gastroduodenal tuberculosis. *Aust NZ J Surg* 1993; 63 : 466-7.
38. Chowdhary GN, Dawar R, Misra MC. Coexisting carcinoma and tuberculosis of stomach. *Indian J Gastroenterol* 1999; 18 : 179-80.
39. Gupta SK, Jain AK, Gupta JP, Agrawal AK, Berry K. Duodenal tuberculosis. *Clin Radiol* 1988; 39 : 159-61.
40. Berney T, Badaoui E, Totsch M, Mentha G, Morel P. Duodenal tuberculosis presenting as acute ulcer perforation. *Am J Gastroenterol* 1998; 93 : 1989-91.
41. Nair KV, Pai CG, Rajagopal KP, Bhat VN, Thomas M. Unusual presentations of duodenal tuberculosis. *Am J Gastroenterol* 1991; 86 : 756-60.

42. Shah P, Ramakantan R, Deshmukh H. Obstructive jaundice - an unusual complication of duodenal tuberculosis : treatment with transhepatic balloon dilatation. Indian J Gastroenterol 1991; 10 : 62-3.

43. Vij JC, Ramesh GN, Choudhary V, Malhotra V. Endoscopic balloon dilation of tuberculous duodenal strictures. Gastrointest Endosc 1992; 38 : 510-1.

PROFORMA

Name :

Age

Sex :

IP No :

Presenting Complaints

- Abdominal pain
- Vomiting
- Abdominal distension
- Loss of appetite
- Loss of weight
- Low grade fever, night sweats
- Diarrhea / Constipation
- Bleeding per rectum

Past History: DM / HTN / TB/ Epileptic / Surgery

Personal History: Diet/ Alcoholic / smoker

General Physical examination

- Consciousness & Orientetation
- Built & Nourishment
- Pallor & icterus

- Hydration
- Generalised edema & lymphadenopathy
- Vitals

Abdominal Examination:

- Distension
- Soft / rigidity
- Visible intestinal peristalsis
- Tenderness – yes/no
- Abdominal mass - size/ site/ consistency/ mobility.
- Presence of free fluid
- Presence of gurgling
- Bowel sounds – present / absent.

Respiratory System :

- Chest – for any abnormality
- Breath sounds – normal /abnormal

Cardiovascular system for heart status

Central Nervous System:

- Higher mental functions
- Spinal tenderness.

- Any focal neurological deficit

Investigations.

- Haemoglobin
- total and differential white cell count
- ESR
- Blood sugar, Urea, Creatinine.
- Serum Electrolytes.
- Urine Routine analysis
- Blood Grouping
- X-ray Chest & Abdomen
- Mantoux test.
- Ultrasound abdomen
- CT Scan Abdomen
- Barium studies
- Colonoscopy

Provisional diagnosis:

Final diagnosis:

Management: Medical /Surgical

Post operative events:

MASTER CHART										
S No	Name	Age	Sex	I.P.N O	B M	B E	CT Abd	D/L	Diagnosis	Treatment
1	Falila	42	F	93457			d		Tuberculous ascites	MM
2	Manimuthu	35	M	77908			d		Tuberculous cocoon	MM
3	Murugan	48	M	94598			d		Enterocutaneous fistula	Laparotomy & Primary closure
4	Meenakchi	35	F	74663				d	Intestinal obstruction	Laparoscopy& Adesiolysis
5	Mahalaksmi	42	F	91522					Ileal stricture	Laparotomy& Adesiolysis & Strictureplasty
6	Senthilvel	18	M	91155			d		Intestinal obstruction	Laparotomy& Adesiolysis
7	Maheswari	29	F	99858	d		d		Ileal stricture	Laparotomy& Adesiolysis & Strictureplasty
8	Adaikalam	27	M	60830			d		TB abdomen & splenic abscess	Laparotomy& adesiolysis / drainage
9	Marimuthu	30	M	60073	d		d		Ileo caecal TB	Rt hemicolectomy
10	Lakshmi	45	F	84008			d		Interloop abcess	Laparotomy & drainage
11	Palani	55	M	35370	d		d		Ileal stricture	Laparotomy& Resection anastomosis
12	Ajith	33	M	82193				d	Mesentric lymphadenitis	MM
13	Raman	62	M	88600			d	d	TB Abdomen	MM
14	Sekar	55	M	79321				d	TB Abdomen	MM
15	Rajendran	40	M	77001			d		Ileal stricture	Laparotomy& Adesiolysis & Strictureplasty
16	Gomathi	35	F	86121			d		Intestinal obstruction	Laparotomy& Adesiolysis
17	Mayandi	35	M	88590		d	d		Ileo caecal TB	Rt hemicolectomy
18	Umasankari	19	F	80933				d	Intestinal obstruction	Laparoscopy&adesiolysis
19	Kaliyappan	55	M	58326	d		d		Ileo caecal TB	Rt hemicolectomy

20	Andisamy	40	M	5643 6			d		Ileo caecal TB	Rt hemicolectomy
21	Rajendran	37	M	8195 6				d	Mesentric lymphadenitis	MM
22	Nagasundari	60	F	8725 7			d		Mesentric lymphadenitis	MM
23	Meenakchl	65	F	6502 7				d	Mesentric lymphadenitis	MM
24	Sathyasivam	45	M	8541 7			d		Ileo caecal TB	Rt hemicolectomy
25	Ravikumar	39	M	8174 5				d	Mesentric lymphadenitis	MM
26	Balan	35	M	5384 0			d		Mesentric lymphadenitis	MM
27	Thangamani	36	M	7384 1				d	Mesentric lymphadenitis	MM
28	Ayanar	15	M	6506 3				d	Pelvic abcess	Laparoscopy & drainage
29	Lingeshwaran	22	M	6505 7				d	Mesentric lymphadenitis	MM
30	Gunasekaran	45	M	5259 4	d		d		Ileal stricture	Laparotomy& Resection anastomosis
31	Santhi	36	F	5838 6				d	Mesentric lymphadenitis	MM
32	Chinnathambi	55	M	6046 6					Ileal stricture	Laparotomy& Resection anastomosis
33	Mohammed	39	M	5539 8	d		d		Ileal stricture	Laparotomy& Adesiolysis & Strictureoplasty
34	Sathish	34	M	6068 4			d		Ileal stricture	Laparotomy& Resection anastomosis
35	Ananthi	37	F	6537 6			d	d	Mesentric lymphadenitis	MM
36	Aurumugam	35	M	7471 8		d	d		Ileo caecal TB	Rt hemicolectomy
37	Muthupillai	33	M	7889 9			d		Mesentric lymphadenitis	MM
38	Jothilakshmi	26	F	8587 1			d	d	Mesentric lymphadenitis	MM
39	Panchavaram	31	F	8373 4				d	Mesentric lymphadenitis	MM
40	Santhi	55	F	9488		d	d		Intestinal obstruction	Laparotomy& Resection anastomosis

				6						
41	Pandirajan	21	F	8716 5	d		d		Ileal stricture	Laparotomy& Adesiolysis & Strictureoplasty
42	Mumtaj	41	F	7156 1				d	Mesentric lymphadenitis	MM
43	Palpandi	31	M	9139 1			d	d	Mesentric lymphadenitis	MM
44	Sivaraja	39	M	7133 0					Ileal perforation	primary closure &covering ileostomy
45	Thavam	18	F	7343 3			d		Ileal stricture	Laparotomy& Adesiolysis & Strictureoplasty
46	Akbar	45	M	8586 2			d		Mesentric lymphadenitis	MM
47	Ramar	67	M	8138 1				d	Mesentric lymphadenitis	MM
48	Indirani	37	F	7511 2			d		Intestinal obstruction	Laparotomy&adhesiolysis
49	Palanikumar	38	M	8224 3		d	d		Ileo caecal TB	Rt hemicolectomy
50	Balakumar	18	M	7860 1			d		Tuberculus ascites	MM
51	Veerammal	20	F	8947 7					Tuberculus ascites	MM
52	Irulan	48	M	6335 9					Ileal perforation	primary closure &covering ileostomy
53	Murugan	40	M	7825 8			d	d	Mesentric lymphadenitis	MM
54	Selvakumar	20	M	8622 8			d	d	Mesentric lymphadenitis	MM
55	Priya	20	F	8853 2				d	Mesentric lymphadenitis	MM
56	Alagar	36	M	8851 0			d		Intestinal obstruction	Laparotomy&adhesiolysis
57	Latha	37	F	9539 7				d	Mesentric lymphadenitis	MM
58	Raja	27	M	2162 9	d		d		Ileo caecal TB	Rt hemicolectomy
59	sivaganga	18	F	3167 8			d	d	Mesentric lymphadenitis	MM
60	Selvam	38	M	3948 0		d	d		Ileo caecal TB	Rt hemicolectomy

61	Suresh	27	M	5064 2			d		Mesentric lymphadenitis	MM
62	Boominathan	41	M	4770 8					Anal stricture	Anal dilatation
63	Rajamohan	31	M	6551 4				d	TB Abdomen	MM
64	Vasanthalakshmi	25	F	2366 0			d		Ileal stricture	Laparotomy& Adesiolysis & Strictureoplasty
65	Kandhasamy	38	M	2473 8			d	d	TB Abdomen	MM
66	Oorkavalan	21	M	6872 3			d		Tuberculous ascites	MM
67	Gnanasundari	23	F	7150 4					Tuberculous ascites	MM
68	Pappammal	60	F	7507 2				d	TB Abdomen	MM
69	Balaji	26	M	9404 7	d		d		Ileal stricture	Laparotomy& Adesiolysis & Strictureoplasty
70	Nagajothi	22	M	8522 1				d	TB Abdomen	MM
71	sekar	32	M	7623 4					Tuberculous ascites	MM
72	Rajesh	30	M	8611 7			d	d	TB Abdomen	MM
BM - Barium Meal				CT Abd - CT Abdomen						d - Investigation done
BE - Barium Enema				D/L - Diagnostic Laparoscopy						MM - Medical Management

