

# **A CLINICAL STUDY OF PROFILE OF PATIENTS WITH LIVER ABSCESS**

**DISSERTATION SUBMITTED FOR  
M.S. (GENERAL SURGERY)**



**THE TAMILNADU DR.M.G.R. MEDICAL UNIVERSITY**

**CHENNAI – TAMILNADU**

**MARCH 2008**

**THE TAMILNADU Dr.M.G.R.MEDICAL UNIVERSITY,  
TAMILNADU, CHENNAI.**

**DECLARATION**

I here by declare that this dissertation/thesis entitled “A Clinical Study, Diagnosis And Management Of Liver Abscess At GRH-MMC, Madurai. Is a bonafide and genuine research work carried out by me under the guidance of Dr.M. GOBINATH. M.S., Professor, Department of General Surgery, MMC – Madurai.

Date:

Dr. N.K. Ganesh

Place:

Post Graduate Student

Department of General Surgery

Government Rajaji Hospital

Madurai Medical College

Madurai

**MADURAI MEDICAL COLLEGE, MADURAI**

**CERTIFICATE**

*This is to certify that the dissertation entitled “A Clinical Study, of Profile of Patients With Liver Abscess At GRH – MMC, Madurai” is a bonafide research work done by Dr.N.K.GANESH in partial fulfillment of the requirement for the degree of MS General Surgery.*

Dr.V.RAJI M.D.,

Dean

Madurai Medical College

Madurai

Dr. M. GOBINATH, M.S.,

Professor & HOD

Department of General Surgery

Government Rajaji Hospital

Madurai Medical College

Madurai

**Date**

**Place**

## **ACKNOWLEDGEMENT**

*It gives me immense pleasure to express my gratitude and thanks my respected and beloved teacher and guide, **Dr.M.GOBINATH, M.S.**, Professor, Department of General Surgery, GRH-MMC, Madurai for his priceless guidance, affection and constant encouragement in preparing this dissertation.*

*I express my humble thanks to my beloved teachers **Dr.M.NAZHEER AHAMEDSYEDM.S., Dr. T.A.THARA, M.S. D.G.O., Dr.R.GANESAN, M.S., Dr. D.MARUTHUPANDIAN, M.S., Dr. K. KARUNAKARAN, M.S.**, Assistant Professors, Department of Surgery, GRH – MMC, Madurai for their immense help and guidance on innumerable occasions with their suggestions.*

*I also express my sincere thanks to the rest of the **Teaching Faculty** of Surgery Department for their valuable suggestions and kind cooperation.*

*My heartfelt thanks to Professor and Head, Department of Radiology and their staff, Professor and Head, Department of Microbiology and their staff, whose help in completing this work has been immense.*

## TABLE OF CONTENTS

<b>Sl.No.</b>	<b>Particulars</b>	<b>Page No.</b>
1.	Introduction	1
2.	Aims and Objectives	2
3.	Review of literature	3
4.	Materials of Methods	70
5.	Results	72
6.	Discussion	84
7.	Conclusion	94
8.	Summary	96
9.	Bibliography	
10.	Annexures	
	a. Proforma	
	b. Key to master chart	
	c. Master chart.	

## **LIST OF TABLES**

<b>Sl.No.</b>	<b>Tables</b>	<b>Pages</b>
1	Etiology of liver abscess	18
2	Bacteriology of hepatic abscesses	22
3	The treatment of pyogenic liver abscess	32
4	Pyogenic liver abscess: factors predictive of mortality	38
5	Distinguishing features of virulent and non – virulent amebae	46
6	Age and sex incidence	72
7	Incidence of symptoms	73
8	Distribution of signs	74
9	Duration of symptoms	75
10	Alcoholism	75
11	Percentage of abnormal laboratory investigations.	76
12	Analysis of LFT	77
13	Chest X-ray	78
14	Ultrasound Examination	78
15	Solitary and multiple abscess.	79
16	Pus culture Analysis	80

17	Analysis of treatment	81
18	Complications	82
19	Mortality rate	82
20	Condition at the time of discharge	83
21	Analysis of repeat aspiration	83
22	Symptoms	85
23	USG Findings of liver Abscess	90
24	USG Findings of liver Abscess	91

## LIST OF FIGURES

<b>Sl.No.</b>	<b>Figures</b>	<b>Pages</b>
1	Liver abscess being aspirated	57
2	Typical 'Anchovy Sauce' Pus	57
3	Age and sex incidence	72
4	Incidence of symptoms	73
5	Distribution of signs	74
6	Alcoholism	76
7	Location of abscess	79
8	Distribution of abscess	80
9	Treatment of liver abscess	81



## **INTRODUCTION**

Liver abscess is a common condition in India. India has 2<sup>nd</sup> highest incidence of liver abscess in the world. Liver abscess are caused by bacterial parasitic or fungal infection. Pyogenic abscesses account for three quarters of hepatic abscess in developed countries. While amoebic liver abscess cause two third of liver abscess in developing countries.

Liver abscess continues to be disease with considerable mortality in our country. Locally made alcoholic drink like neera, arrack may be the router of faeco-oral transmission of amoebic cyst. Primary prevention by improving sanitation, health education, early diagnosis and prompt treatment may result in lowering mortality / morbidity associated with the disease. This study has tried to delineate clinical profile, diagnosis, and management strategies of liver abscesses.

## **AIMS AND OBJECTIVES**

1. To Study clinical presentation of liver abscesses i.e. Distribution with respect to age and sex, mode of presentations.
2. To Study risk factors associated
3. To Study effective of different modes of management.

## **REVIEW OF LITERATURE**

### **Historical aspects and review of literature**

The history of amoebiasis is a really fascinating one. Susruta (600 BC) has given vivid description of amoebic dysentery as Athisara, incriminating the germination of parasites in the intestines by drinking impure water and excessive liquor.

Liver abscess was probably recognized with more certainty in Hippocratic era, and master of medicine successfully practiced the draining of pus.

Annesley (1828) from Madras described the casual relationship between hepatic involvement and colonic lesion.

Lambi (1859) first discovered parasite. Koch demonstrated amoeba in pus from tissue adjoining the abscess. Osler (1890) found amoeba in pus from operated cases. Later Councilman and Lafleur (1891) in Baltimore proved the clinical and pathological evidence that amoeba was responsible for liver abscess.

Roger (1918) "The protozal organism reaches the liver by portal circulation and they entangle in the interlobular veins producing congestion of liver, he established that amoebae are constantly present in the walls of the abscess though not frequently in pus.

In 1927, Graig established specific complement fixation test in the diagnosis of amoebic liver abscess. In 1948, Conan demonstrated action of chloroquin on hepatic amoebiasis. In 1970, R.Subramaniam et al have worked and have described stages of hepatic amoebiasis.

### **Anatomy**

#### **Embryology**

When the embryo is about 3 weeks old and 2.5mm in length liver makes its appearance as a hollow out growth or diverticulum from the ventral wall of the duodenal portion of the primitive foregut called Hepatic Bud in common with the ventral pancreatic bud. This hepatic pancreatic bud is the rudiment of liver, the gall bladder, the bile duct. This hepatic bud grows into the ventral mesogastrium and passes through it into the septum transversum. It enlarges and soon shows division into a larger cranial part called the parshepatica, and a smaller caudal portion called pars cystica. The pars hepatica divides into right and left parts, each of which forms one lobe of the liver.

As the right and left divisions of pars hepatica enlarge and extend into the septum transversum, the cells arising from them are broken up into interlacing columns called hepatic trabeculae. In this process, the umbilical and vitelline veins which lie in the septum transversum, are broken up to form the sinusoids of liver. Sinusoids are also formed from the mesenchyme of septum transversum.

The endodermal cells of hepatic bud give rise to the parenchyma of the liver and bile capillaries. The mesoderm of septum transversum forms the capsule and fibrous tissue basis of the liver.

The fetal liver is an important center of blood formation (haemopoiesis) large aggregations of blood forming cells are present between hepatic cells and blood vessels.

### **Gross anatomy**

The liver is the largest gland in the body. It lies under cover of the lower ribs closely applied to the undersurface of the diaphragm and astride the venacava posteriorly. Most of the liver bulk lies to the right of the midline where the lower border coincides with the right costal margin but extends as a wedge to the left of the midline between the anterior surface of the stomach and the left dome of the diaphragm.

The upper surface is boldly convex, molded to the diaphragm, and the surface projection on the anterior body wall extends up to the fourth intercostal space on the right and the fifth space on left. The convexity of the upper surface slopes down to the posterior surface, which is triangular in outline. The liver is invested with peritoneum except on the posterior surface where the peritoneum reflects onto the diaphragm forming the right and left triangular ligaments.

The undersurface of liver is concave and tends down to the sharp anterior border. The posterior surface of the liver is triangular in outline with its base to

the right and here the liver lying between the upper and lower leaves of the triangular ligaments is bare and devoid of peritoneum.

The anterior border lies under cover of the right costal margin lateral to right rectus abdominis muscle, but slopes upwards to the left across the epigastrium. Anteriorly the convex surface of the liver lies comfortably against concavity of the diaphragm and is attached to it by the falciform ligament, left triangular ligament and the upper layer of right triangular ligament.

### **Lobes of liver**

Liver is divided into a large right lobe and a small left lobe by the attachment of the peritoneum of the falciform ligament. The right lobe is further divided into quadrate lobe and a caudate lobe by the presence of the gallbladder, the fissure of ligamentum teres, the inferior vena cava and the fissure for the ligamentum venosum. Experiments have shown that in fact, the quadrate and caudate lobes are a functional part of the lobe of the liver.

### **Porta hepatis / Hilus of liver:**

It is found on the postero-inferior surface and lies between the caudate and quadrate lobes. The upper part of the free edge of the lesser omentum is attached to its margins. In it lies the right and left hepatic ducts, the right and left branches of the hepatic artery, the portal vein, and sympathetic and

parasympathetic nerve fibres. A few hepatic lymph node lie here, they drain liver and gall bladder and send their efferent vessels to the celiac lymph nodes.

**Peritoneal relations:**

Most of the liver is covered by peritoneum. Bare areas of liver:

1. On posterior surface of right lobe of liver is limited by the coronary ligament and right triangular ligaments.
2. Groove for Inferior Vena Cava.
3. Gall bladder fossa on inferior surface of right lobe of liver
4. Porta hepatis
5. Along the lines of reflection of peritoneum.

**Peritoneal ligaments:**

Falciform ligament – Connecting anterosuperior surface of liver to the anterior abdominal wall and undersurface of diaphragm.

**Left triangular ligament-**

Connection superior surface of the left lobe of the liver to diaphragm.

**Right triangular ligament-**

Connection lateral part of the posterior surface of right lobe of liver to diaphragm.

**Coronary ligament-** with superior and inferior layers enclosing the bare area of liver.

Ligamentum Teres: Passes into a fissure on the visceral surface of the liver and joins the left branch of the portal vein in the porta hepatis.

**Ligamentum venosum:-** A fibrous band that is the remains of the ductus venosus, is attached to the left branch of the portal vein and ascends in a fissure on the visceral surface of the liver to be attached above to the inferior venacava.

**Lesser Omentum:-** Arises from the edges of the porta hepatis and the fissure for the ligamentum venosum, and passes down to the lesser curvature of stomach.

**Blood supply:** The blood vessels conveying blood to liver are hepatic artery (30%) and portal vein (70%). The hepatic artery brings oxygenated blood to the liver, while the portal vein brings venous blood rich in products of digestion, which have been absorbed from the gastrointestinal tract. The arterial and venous blood is conducted to the central vein of each liver lobule by the liver sinusoids. The central veins drain into the right and left hepatic veins, and these leave the posterior surface of the liver and open directly into the inferior venacava.

**Lymph vessels:**

The liver produces a large amount of lymph about one third – one half of all body lymph. The lymph vessels leave the liver and enter a number of lymph nodes in the porta hepatis. The efferent vessels pass to celiac nodes. A small



number of vessels pass from bare area of liver through the diaphragm to the posterior mediastinal lymph nodes.

**Nerve supply:**

The nerve supply of the liver is derived from the sympathetic and parasympathetic nerves by the way of celiac plexus. The anterior vagal trunk gives rise to a large hepatic branch, which passes directly to the liver.

**Microscopic Anatomy:-**

The liver is covered by thick capsule called Glisson's capsule. The capsule encases a sponge like mass of cells arranged in plates through which passes intricate system of capillaries called sinusoids. The sinusoids differ from ordinary capillaries in that their endothelial lining is made up of kupffer cells. The hepatic parenchyma appears to be distributed in poorly defined lobules. At the centers of each lobule lies central vein, tributary of hepatic venous outflow system that carries blood from the liver towards the heart. Central vein drains into progressively enlarging sublobular veins and intrahepatic veins until connections are made with major hepatic veins that enter the inferior venacava. At the periphery between lobules, is a collection of connective tissue called a portal tract or triad, which contain branches of the portal vein the hepatic artery and the bile duct. The branches of both the portal vein and the hepatic artery empty directly into the sinusoids after a series of divisions and ramifications. In addition, the branches of the hepatic artery nourish the structure in the portal

tracts. Bile duct system originates as fine bile canaliculi located between the hepatic cells and forming a part of the cell membrane. Bile is secreted by the hepatocytes into canaliculi which in turn drain into the intra lobular ductules and then into large bile ducts in the portal tracts.

### **Functional Anatomy of liver:-**

Hepatic segmentation is based on the distribution of the portal pedicles and the location of the hepatic veins. The three hepatic veins viz right, left and middle divide the liver into four sectors. These sectors are called as “portal sectors” because each of them is supplied by independent portal pedicles. Similarly the scissurae containing hepatic veins are called as portal scissurae those containing portal pedicles are called hepatic scissurae.

According to the functional anatomy, the liver appears to be hemiliver, the right and left liver, by the main portal scissura also called “cantlies line”. The right and left livers, individualized by the main portal scissura, are independent as regards the portal and arterial vascularization and the biliary drainage. The middle hepatic vein follows this main portal scissura. These right and left livers are themselves divided into two parts by the other portal scissurae. These four sub divisions are usually called as sectors.

The right portal scissura divides the right liver in two sectors anteromedial or anterior and posterior lateral or posterior. Along the right portal scissura runs the right hepatic vein. The right portal scissura is inclined  $45^{\circ}$  to

the right. With the liver in its normal place in the abdominal cavity, it is better to speak of anterior and posterior sectors. Left portal scissurae divides the left liver into two sectors, left hepatic vein lies in the left portal scissura and which intum is situated posterior to the ligamentum teres in the left lobe of liver. The two sectors are anterior and posterior.

**The sector consists of segments:-**

- 1) Right liver:
  - i) The anterior sectors consists of segment V inferiorly  
segment VIII superiorly
  - ii) The posterior sector consist of segment VI  
inferiorly and  
VII superiorly
- 2) Left liver:
  - i) anterior sector – it is divided by the umbilical  
fissure  
tissues into two segments segment IV medially the  
anterior part of which is the quadrate lobe and  
segment III  
lateral, which is anterior part of the left lobe.
  - iii) Posterior – sectors, contains only one segment,  
segment II  
which is the posterior part of the left lobe.

3) Spigel lobe (caudate lobe):- contains segment I. it is an autonomous segment because its vascularization is independent of the portal division and of three hepatic veins. It receives its vessels from left and right branches of portal vein and hepatic artery. Its hepatic veins drain directly into inferior venacava.

### **PHYSIOLOGY OF LIVER:**

#### **Functions of liver:**

- 1) Nutrition – receives, processes and stores nutrients absorbed from G.I.T. release metabolites on demand (amino acids, fats, carbohydrates, cholesterol and vitamins).
- 2) Synthetic functions: produces plasma proteins albumin, clotting factors, transporting proteins.
- 3) Immunologic functions – Involved in the transport of immunoglobulins. Antigens are cleared by kupffer cells.
- 4) Hematologic function: Synthesis and release of co-agulation factors and clears activated co-agulation factors.
- 5) Detoxification : Main site of metabolic conversion of endogenous and exogenous compound.
- 6) Excretory function: Bile acid metabolism synthesizes bile acid from cholesterol and secretes bile acids into duodenum thereby regulating bile flow and allowing for efficient emulsification and absorption of dietary fat.

- 7) Endocrine functions:- Server as a major site of catabolism of thyroid and steroid hormones and insuline metabolism.

### **Hepatic Hemodynamics:**

Liver receives about  $\frac{1}{4}$  of the cardiac output. Liver blood flow in normal subjects average 1500ml./min. the hepatic artery contributes about  $\frac{1}{4}$  of the blood and portal vein about  $\frac{3}{4}$  of the blood flowing to the liver. Pressure in the portal vein is 8-12 mm Hg and in hepatic artery is the same as systemic arterial pressure. In the hepatic sinusoids it is 2-6 mmHg in the hepatic veins it is 1-5 mmHg and in inferior venacava it is 0.5 mmHg. Oxygen content of portal vein blood is higher than systemic blood. Approximately 25-30% of the liver by volume consists of blood and half of this can be expelled rapidly into the circulation in response to activation of hepatic nerves or release of catecholamines. Thus liver plays on important role in maintaining circulatory haemostasis.

### **PYOGENIC LIVER ABSCESS:**

#### **Incidence:**

In 1938. Ochsner and associates reported that pyogenic hepatic abscesses occurred in 8 per 100,000 of admissions to the New Orleans charity Hospital. Their classic review documented appendicitis as the etiologic entity in more than one third of these cases. Since the introduction of antibiotics pyogenic hepatic abscess secondary to appendicitis – induced pyelophlebitis has become

rare. Patients with pyogenic liver abscess are now more likely to be older, (seventh and eight decade) to be female and to have a biliary cause or an underlying malignant disease.

Pitt and Zuidema, in 1973, documented an admission prevalence at the Johns Hopkins Hospital, Baltimore of 13 per 1,00,000. A more recent publication from that same institution comparing a pair of 21-year time periods suggests that the incidence of pyogenic hepatic abscesses has increased significantly to 20 per 1,00,000 admissions. In a series from Duke University Medical center, the incidence over period 1979 to 1986 was 22 cases per 1,00,000 hospital admissions. This compared with a figure of 11.5 cases per 1,00,000 admission during the period 1970 to 1978.

A further series from university of California San Francisco Hospital describes an incidence of 22 cases per 100000 hospital admissions. In each of these series, the peak incidence occurred early in sixth decade thereby suggesting a shift in age. This is thought to reflect improved diagnosis with the development of computed tomography (CT) and ultrasound (US) scanning together a more aggressive approach to the management of malignant biliary obstruction including the use of intraluminal biliary stents. However, in two of these series, the most common cause of hepatic abscess was found to be cryptogenic in that no obvious predisposing cause was identified. It has been suggested that this may reflect the earlier diagnosis and treatment of biliary

tract complications, with a reduction of pyelphlebitis related PLA would account for a proportional increase in the numbers of cryptogenic PLA. However, it remains possible that there has been a recent true increase in the incidence of primary cryptogenic PLA.

#### Etiology And Pathogenesis:

Most pyogenic liver abscesses are caused by infection in biliary or intestinal tracts. As a result, the causes of liver abscesses have been divided into six categories based on the route of extension of infection.

- 1) Biliary, from ascending cholangitis.
- 2) Portal vein, as in pylephlebitis resulting from appendicitis or diverticulitis.
- 3) Hepatic artery, from septicemia.
- 4) Direct extension, from contiguous disease process
- 5) Traumatic, from blunt or penetrating injuries
- 6) Cryptogenic, when no primary source of infection is found even after abdominal exploration of autopsy.

Before the introduction of antibiotics, appendicitis and other intra abdominal infections resulting in pylephlebitis were the leading causes of pyogenic hepatic abscess. In a collected series of 622 patients published by ochsner and associates in 1938, the route of infection was through the portal vein in 43% and through the biliary tree in only 14% of their patient. This

figure is in marked contrast to the 0 to 2% incidence of appendicitis as an etiologic factor in more recent large series. This change may be caused, at least in part, by the introduction of antibiotics.

In the 1975 report by Pitt and Zuidema from the Johns Hopkins Hospital, 51% of the patients had a hepatobiliary or pancreatic neoplasm (23%) or a benign biliary tract condition (28%). When this series was updated by Huang et al in 1996, 60% of patients had an associated hepatobiliary or pancreatic disease. However in the more recent series from Johns Hopkins, the underlying problem was a malignant disease in 42% of patients. Similar trends have been reported by Branum and Associates at Duke University in North Carolina.

Analysis of abscesses with a portal cause reveals that several other intra abdominal disease process have replaced appendicitis as the leading cause in this category. At present, the frequent sources of portal vein sepsis resulting in liver abscess include diverticulites, perforated ulcers, and perforated carcinomas. The relative incidence of pyogenic hepatic abscesses resulting from systemic bacteremia, direct extension, and trauma have remained relatively constant since 1950. In a more recent years, the incidence of liver abscesses after Hepatic artery embolization has increased.

Although a wide variation exists in individual reports, the incidence of cryptogenic abscesses in large collected series has remained relatively constant,



at approximately 15-20%. The pathogenesis of cryptogenic abscesses is still uncertain, although several theories have been proposed. In 1972, Lee and Block noted an increased incidence of anaerobic infections in their patients. They suggested that cryptogenic abscesses may develop from small areas of intrahepatic thromboembolism or infarction that become infected secondarily by anaerobic bacteria was present in 45% of all liver abscesses, the most commonly encountered organisms were anaerobic and microaerophilic streptococci, bacteroides fragilis and fusobacterium.

In a recent survey, trauma caused 5% of the liver abscess. According to Robertson et al 16% of all hepatic abscesses observed over a 25 year period originated from secondary infections of neoplastic lesions. Tromp et al have stated that of 1262 liver abscesses described in the literature since 1934, only 32 patients had a lesion associated with either primary or metastatic tumor. Jochimsen et al reported several cases of liver abscess that developed after the hepatic reported several cases of liver abscess that developed after the hepatic artery was ligated for the treatment of neoplasms (hepatic metastases).

Because of the liver's dual supply, hematogenous spread of infections to the liver can occur by portal vein or the hepatic artery. Although the portal system is the more common pathway. Hepatic abscesses that originate from the arterial circulation of the liver constitute 13 to 15% of all liver abscesses, a number, that has remained rather constant through the year. Around one third

of all hepatic abscesses are caused by cholangitis and operation or manipulations of biliary tract.

Patients with compromised host defenses have an increased risk of developing pyogenic liver abscesses. Diabetes mellitus was present in 15% of the patients of Altemeier et al , and liver abscesses have been found in children with leukemia, chronic granulomatous disease, AIDS and other immunodeficiency disorders.

Table : 1 : Etiology of liver abscess

<b>Etiology</b>	<b>Source of infection</b>	<b>Distribution</b>	<b>Primary Organism</b>
Biliary system	Cholangitis, biliary obstruction	Both lobes multiple	Single species, from (-ve) aerobes & anaerobes E.coli
Portal circulation	Intra abdominal infection	Rt. Lobe < Lt multiple or single	Polymicrobial, enteric aerobes, and anaerobes E. Faecalis, E.Coli, E fragilis.
	Liver metastasis	Area of metastasis	B. fragilis
Arterial circulation	Bacteremia systemic infection	Both lobes, multiple	Single species, gram (+) aerobes, S aureus, S pyoenes
Trauma	Direct exposure, necrosis	Adjacent area	Single species, gram (-) aerobes E. coli
Cryptogenic	Unknown	Rt. Lobe > left	Single species anaerobic, B. fragilis

## **Pathology**

The etiology of a liver abscess serves as best predictor of the size, number and location of abscesses affecting a given patient. Generally, portal, traumatic, and cryptogenic hepatic abscesses are solitary and large, while biliary and arterial abscesses are multiple and small. If the primary lesion is located within the portal circulation, the ‘abscesses are large, single or multiple and in most cases confined to the right lobe of liver, the left lobe is rarely affected. Kinney and ferrebee’ in a study based on experiments of serege in 1901<sup>18</sup>, showed that there is a separate flow of blood from superior mesenteric vein to the right lobe of the liver, and from splenic vein to the left lobe of the liver. This explains the preferential location of portal hepatic abscesses in the right lobe, which drains the intestines. Hepatic abscesses in both lobes will occur when the portal vein is filled with a septic thrombus.

In a review by Gyorff<sup>7</sup> and colleagues, 40% of the hepatic abscesses were found to be 1.5 to 5 cm in diameter, 40% were 5 to 8 cm, and 20% were 8 cm or larger. Pyogenic liver abscesses localize to the right hepatic lobe in 65% cases, with the majority of these being solitary. The left lobe is solely involved in 12% of cases, with 23% of patients having bilateral abscesses. Bilateral disease occurs in 90% of cases with a biliary or arterial source of infection distributing along the terminal branches of the portal triad. Fungal hepatic abscesses are most often multiple bilateral, and miliary in nature.

**Microbiology:**

Virtually every bacterium known to medical microbiology has been mentioned as a causative agent of hepatic abscess. On older literature, sterile culture were found in up to 60% of all cases. Even in more recent reviews, the number of sterile abscesses still exceeds 10%. Aside from 47 cases observed by Sabba et al Only 1 65 cases of anaerobic liver abscesses have been reported. This low number is probably the result of inadequate anaerobic culture techniques. In a systematic search, Sabbaj & Co-workers found that anaerobic bacteria were present in 45% of all liver abscesses, the most commonly encountered organisms were anaerobic and microaerophilic streptococci, *Bacteroides fragilis*, and *Fusobacterium*.

The observations of Onderdonk et al that the presence of anaerobic bacteria is necessary to produce intraperitoneal abscesses, it is likely that anaerobic bacteria are involved in a large percentage of hepatic abscesses. Unfortunately, there is little information about the relationship between the pathogenesis of liver abscess and its bacteriology. It seems, however, that anaerobic bacteria are prominent in abscesses, secondary to hepatic tumors, and that the bacteriology of abscesses originating from lesions within the Portal circulation closely resembles that of intraperitoneal infections, that is *E. Coli*, *Enterococcus* and *Bacteroides*. A summary of the bacteriology of liver abscesses in Table 2 excludes the data of Sahhaj et al. Rarely, bacteria that

normally elicit granulomatous reactions will cause hepatic abscess as a complication of systemic infection. Brucellosis is commonly complicated by hepatomegaly. Splenomegaly and microscopic hepatic granulomas. Although *Brucella abortus* is the common human pathogen, abscesses of the liver and spleen have been seen in *B. Suis* infections.

Most tuberculosis lesions of the liver are miliary granulomas. Abscess like masses (Tuberculomas) sometimes form and spread along the walls of the intrahepatic bile ducts (tuberculous cholangitis). Diagnosis may be difficult because both caseation and acid fast organisms can be absent. Tuberculomas are often, but not always, accompanied by an abdominal focus.

Miliary abscesses have been found in cases of disseminated granuloma inguinale. Hepatic clostridial infections cause gas abscesses, but most of the jaundice in disseminated infections is hemolytic.

**Table 2 : Bacteriology of hepatic abscesses**

Organisms	Number	%	Number	%
<b>Gram positive Aerobes</b>				
Staphylococci			34	18.5
S. Aureus	27	14.7		
S. Epidermidis	7	3.8		
Streptococci			16	8.7
Hemolytic streptococci	3	1.6		
Nonhemolytic streptococci	13	7.1		
Enterococci			20	10.9
Others			4	2.2
<b>Gram negative Aerobes</b>				
Escherichia coli			82	44.6
Klebsiella / enterobacter			61	33.2
Proteas			21	11.4
Pseudomonas			12	6.5
Others			16	8.7
<b>Anaerobes</b>				
Bacteroides			16	8.7
Peptostreptococcus			11	6.0
Clostridium			7	3.8
Others			5	2.7

## **Diagnosis**

### **Clinical Features**

Most patients with pyogenic hepatic abscesses present with symptoms of less than 2 wks duration. The most common presenting symptoms is fever, which is noted in approximately 90% of patients. Pain is the next common symptom, but in the Johns Hopkins series this symptom was present less often in recent years (PC 0.5) chills and weight loss occur in approximately one half of the patients, other symptoms like jaundice, diarrhoea, cough, anorexia can also be present.

The most common physical sign is an enlarged tender liver, which is found in 55% patients with pyogenic abscess. Jaundice is also found on physical examination in approximately one half of the patients. Chest symptoms and physical findings are found in approximately one fourth of the patients. Abdominal examination reveals a palpable mass or ascites in about 25% of patients where as splenomegaly is detected in only 10%.

Almost all patients with pyogenic liver abscess have abnormal hematological and liver function tests. Leucocytosis is noted in approximately 70 to 90% of patients. Many patients are also found to be anemic and this usually reflects the presence of chronic disease or a prolonged sub acute presentation. Erythrocyte sedimentation rate is also elevated. The most frequent liver function test abnormality observed in patients with hepatic abscess is an

elevated alkaline phosphates. This is seen in approximately 80 —90% of patients. Bilirubin is elevated in 40-60% of patients. Transaminases are also abnormal. Hypoalbuminemia is observed in approximately 70% of patients and mild elevation of prothrombin time are also frequently seen.

### **Diagnostic Imaging :**

Plain abdominal and chest radiographs are now used less frequently in the assessment of patients with hepatic abscess, though they may still be of diagnostic value. Chest radiographs are abnormal in approximately 50% of patients presenting with hepatic abscesses. Changes suggestive of sub-diaphragmatic pathology include an elevated right hemi diaphragm; a right pleural effusion and right lower lobe atelectasis. Similar findings are occasionally found in the left thoracic cavity if the abscess involves the left hepatic lobe.

Abdominal films may show evidence of hepatomegaly. If gas-forming organisms are present within the abscess and air fluid level may be seen. Air within an unoperated biliary tree may also be demonstrated, confirming the diagnosis of cholangitis. Rarely portal venous gas may be seen on an abdominal x-ray, confirming pyelophlebitis. Portal venous gas appears as branching linear lucencies along the peripheral portion of the liver. Air within the biliary tree tends to be seen more centrally. However, it is rarely possible to make this



distinction on the basis of plain film appearances alone and US or CT are usually required.

Contrast studies of the stomach, colon, or urinary tract occasionally demonstrate displacement of organs adjacent to the liver or give a clue to the source of infection. With the increased incidence of biliary causes of pyogenic liver abscess cholangiography has become more important in the diagnosis of many of these patients. Either ERC or FTC were helpful in defining biliary anatomy as well as in outlining the abscess cavities in approximately two third of the studies

Liver scans were reported to be 80 to 90% accurate in diagnosing liver abscesses. Satiani and Davidson however found liver scans to be positive in 90% of patients with a solitary abscess but in only 70% of patients with a multiple abscesses. The decreased accuracy of liver scanning in patients with multiple abscesses is explained by the finding that abscesses smaller than 2cm are not detected by this technique. A liver scan with technetium-99 sulfur colloid will show the defect in over 80% of all cases<sup>21,22</sup> Other radiologic methods, such as scanning with indium III labelled leucocytes and gallium <sup>67</sup><sup>22,23</sup> are used. Differentiation between abscess and tumor, however is frequently not possible with either technetium sulfur colloid (99m TC) or gallium citrate (<sup>67</sup>Ga) scans. The use of indium (<sup>111</sup> In) scans may be of some help in this regard. Liver scans have provided a means for early detection of

abscesses that was not previously available. They are also useful in defining location, size and number of abscesses, and they provide a mechanism for follow up. Further more, the role of liver scanning in patients with hepatic abscesses changed with the introduction of ultrasound and CT.

Reports by Balasegaram and by Verlenden and Frey found that ultrasound examination provided a correct diagnosis of pyogenic hepatic abscess in 37 of 38 patients studied 24.25 the one false-positive result in these two series was in a patient with a cavitated hepatocellular carcinoma that mimicked an abscess.

Barreda and Ros considered ultrasound to be modality of choice in studying the internal nature of hepatic abscesses 26

The disadvantages are:

1. Cannot always visualize the liver dome and may miss lesions in this area
2. Multiple microscopic abscesses such as those generally found with ascending cholangitis, may not be appreciated.
3. Fatty infiltration may produce a markedly echogenic liver, with resulting failure to detect a small abscess.

US and CT have replaced liver scans as the method of choice for radiologic proof of hepatic abscesses 27-29 Abscesses that are large enough to be suitable for diagnostic aspiration or therapeutic drainage can be equally well

diagnosed by either imaging technique 2 with ultrasonography the lesion can be echogenic as well as nonechogenic. In the case of nonechoic lesions variable amounts of internal echo can be seen. Nearly all abscesses show distal sonic enhancement as long as no gas is present 3 computed tomography may visualize hepatic collections as small as 0.5cm and CT may more easily identify multiple small abscesses. Most abscesses are inhomogeneous, but the density is generally Lower than in the surrounding tissue. Intravenous administration of contrast material enhances the case by which abscesses can be diagnosed, and in a few cases the abscess cannot be detected until the contrast material has been administered. However, rim enhancement is seen only rarely Levitt and associates, in their 1977 study of 166 patients in whom CT scanning of the liver was performed, pointed out that even this technique cannot always differentiate abscesses from other space occupying lesions MRI has recently been used for the detection of hepatic abscesses.

**Treatment:**

Once a diagnosis of hepatic abscess is suspected broad spectrum intravenous antibiotics should be started. Antibiotics therapy can be adjusted once the results of abscess cultures are available. Blood should also be sent for culture. Specimens should be cultured for acid —fast bacilli and fungi and this is particularly the case if there is a clinical suspicion of mycobacterium or fungal infections or if patients are immune suppressed. Empirical antibiotic

therapy should include effective cover against aerobic gram-negative bacteria. Appropriate antibiotic combination would include ampicillin and amino glycoside and metronidazole or a third generation cephalosporin such as cefotaxime together with ampicillin and metronidazole, alternatively a carbapenem antibiotic such as imipenem or meropenem may be used. Metronidazole will also be therapeutic for patients with amebic liver abscess. All patients at risk of amebic liver abscess should also undergo serological testing.

The duration of antibiotic treatment will vary according to the clinical setting. However antibiotic penetration into the abscess cavity is often poor and 2 weeks of intravenous antibiotics are usually recommended. Appropriate oral antibiotics are usually continued for a further 4 weeks.

In the pre-antibiotic era, untreated liver abscess was uniformly fatal. Following the publication of the review by Ochsner et al in 1938, surgical drainage was widely adopted and this resulted in dramatic reduction in mortality. Extra peritoneal drainage was recommended so as to avoid contamination of the peritoneal cavity. This was usually achieved via a posterior approach through the bed of the twelfth rib. However, with the availability of modern antibiotics, Transperitoneal drainage<sup>15,21,36</sup> may now be performed safely and this approach has the advantage of allowing full laparotomy and assessment of any underlying intra abdominal pathology. For

patients with a known source of infection within abdomen or biliary system, definitive surgery may be performed, followed by abscess drainage. Occasionally it may be difficult to identify the abscess site and intra-operative US may be of great help in this respect. Once identified the abscess should be aspirated and specimens sent for culture, the abscess may then be drained dependently, ensuring the cavity is completely break down. If etiology is uncertain, a biopsy of the abscess cavity may also be taken in order to exclude on underlying necrotic tumor. Multiple drains should then be sited and these may subsequently be used for irrigation or for sinograms to assess closure of cavity. Surgery continued to be recommended as the treatment of choice until as recently as 1984. Meidema and Dincen (1984) presented a series of 106 patients with pyogenic liver abscess of 65 patients treated surgically, the mortality was 26% of the remaining 41 patients treated non-surgically. Mortality was 95% within overall mortality of 53%.

Recently several reports have been published about treatment of hepatic abscesses with systemic antibiotics and closed- needle aspiration of the abscess cavity The initial results seem to he encouraging. A total of 62 cases with a mortality of 4% have been reported, although the aspiration often has to be repeated more than five times and adequate continuous drainage seems to be preferable . This can be achieved either percutaneously or surgically. As early as 1953, MC fadzean et a! reported a series of 14 patients from Hongkong all of

whom were successfully treated with diagnostic aspiration and antibiotics alone. By 1964, this series had grown to include 108 patients with only one death. However, these results were largely ignored and it was not until the 1980, when there was renewed interest in percutaneous methods of abscess drainage. In 1985, Gerzof et al 27 published a series of 18 hepatic abscesses, 16 of which were successfully managed by percutaneous catheter drainage. Only two patients required surgical drainage and no deaths were reported in this series. The following year Bertel et al 40 (1986) published a series 39 patients with pyogenic hepatic abscess; 23 patients were treated surgically, 16 patients underwent percutaneous drainage. Three of the percutaneously treated group required surgical drainage due to viscous abscess contents. However, the majority of patients were successfully treated. Mortality was 17% in the surgical group and 13% in percutaneoulsy-drained group. Wong (1990) ““ described 21 patients with pyogenic liver abscess treated by percutaneous drainage. This was successful in 85% of patients with mortality of less than 1 0%. Contraindications to catheter drainage include the presence of ascites, coagulopathy and proximity to vital structures. Unfortunately there are no randomized controlled trails comparing surgical and percutaneous drainage and raw comparison between these two groups will inevitably be subject to selection bias. However, many authors have since confirmed the safety and efficacy of percutaneous aspiration drainage and this is now considered the

treatment of choice for patients presenting with hepatic abscess 42 Surgery should now be reserved for patients with an identified intra abdominal source of sepsis in which a concomitant surgical procedure is planned or for patients who fail to respond to percutaneous treatment.

Recent series illustrate how the management of pyogenic abscess has changed over the last decades. Branum et al (1990) reported a series of 73 patients admitted between 1970 and 1986. During the period 1970 to 1978, 86% of patients (25 of 29) were initially treated by surgery. However, during the period 1971 to 1986, equal numbers of patients underwent surgery and percutaneous drainage as the first definitive therapy.

In 1996, Seeto and Rockey reported a series of 142 patients admitted between January 1979 and December 1994. During the first 3 years of this study 925 of patients (12 of 13) were initially treated by surgery. However, during the last 5 years of the study only 1 of 50 patients underwent surgery as the initial form of treatment. Percutaneous drainage was successful in 90% of these patients.

**Table – 3: The treatment of pyogenic liver abscess**

	Success			Mortality			Complications		
	Surgery	PNA (%)	PCD	Surgery	PNA (%)	PCD	Surgery	PNA (%)	PCD
<b>Seeto and Rockey 1979-1994 (1996)</b>	61 (n=23)	58 (n=17)	77 (n = 70)	13	6	6	-	-	-
<b>Branum et al 1989 – 1993 (1996)</b>	81 (n = 28)	-	83 (n = 18)	9.5	-	25	48	-	71
<b>Rintoul et al 1989- 1993 (1996)</b>	100 (n = 1)	-	60 (n = 15)	0	-	33	0	-	40
<b>Karatassas 1980 – 1987 (1990)</b>	69 (n = 14)	60 (n = 18)	-	43	-	0	-	-	-



There remains some controversy regarding the respective roles of percutaneous catheter drainage (PCD) and percutaneous needle aspiration (PNA) for the treatment of patients with liver abscess. It has recently been suggested that percutaneous aspiration may be preferable to catheter drainage. The main advantages of needle aspiration over catheter drainage are the fact that it is less invasive, less expensive and needle aspiration avoids the problems related to follow-up catheter care or loss of catheter position. The largest series of consecutive patients treated by percutaneous aspiration was reported by Giorgio et al (1995). In this series, 115 patients were treated over a 13-year period; PNA was successful in 113 patients (98.3%). Abscess cavities were gently lavaged with saline and antibiotics were administered into the cavity. A single aspiration was sufficient in 57 patients. Two patients underwent surgery when aspiration failed due to the high viscosity of abscess contents. The authors reported no mortality and no procedure related morbidity. In fact, many patients were treated on an outpatients basis. A further series of 64 consecutive patients treated by needle aspiration was recently reported with a success rate of 96.8%. However, in this study two patients died of septicemia related to uncontrolled sepsis secondary to liver abscess and one patient required laparotomy for hemoperitoneum due to a liver laceration. Again approximately half the patients required a second aspiration and of these, half required further aspiration. There has only been one randomized controlled trial comparing percutaneous needle

aspiration with catheter drainage, though this included patients with both amebic and pyogenic liver abscess. Percutaneous aspiration was successful in only 60% of patients whereas catheter drainage was successful in 100% of patients. All patients that failed percutaneous aspiration were subsequently successfully treated by catheter drainage. The relatively lower success rate was thought to be due to fact that repeat aspiration was only performed on one occasion. This is in contrast to the previous studies when multiple aspirations were performed as required. It is therefore likely that higher success rates would have been achieved if repeat aspirations had been performed. However, incomplete evacuation of the abscess cavity or rapid reaccumulation of abscess contents following percutaneous aspiration were considered indications for continuous catheter drainage. Percutaneous needle aspiration appeared to be less effective than PCD, though both procedures were shown to be safe with no major complications and no deaths.

Occasionally, patients with pyogenic liver abscess are treated by antibiotics alone. In general this is not recommended. It seems unreasonable to leave patients at risk of sepsis with an identified purulent collection given the availability of percutaneous drainage techniques. However, therapy with antibiotics alone may be appropriate in selected patients. For example, patients with malignant biliary obstruction and pyogenic liver abscess may be successfully managed with a combination of biliary decompression in these

patients is invariably fatal irrespective of whether abscess drainage is performed or not.

It was initially thought that only patients with single PLA should be managed by percutaneous drainage with operative drainage reserved for patients with multiple or complex abscess. However, a number of authors have found that percutaneous treatments are equally effective for patients with both single and multiple pyogenic abscesses. The largest series of patients with multiple abscesses comes from Taiwan. Of a total of 483 patients with PLA, 140 patients had multiple abscesses. This group found that treatment failure occurred more frequently for patients with multiple liver abscesses for both percutaneous aspiration and percutaneous catheter drainage. Overall mortality was significantly higher for patients with multiple liver abscesses. This reflected the fact that patients with multiple abscesses were more likely to have serious underlying diseases, whereas single abscesses were more likely to be cryptogenic in origin. The authors concluded that percutaneous aspiration and drainage were appropriate first line therapies for patients with multiple abscesses but, given the relatively high failure rates (42.4 and 38.7% respectively), surgical drainage should be considered early for patients with multiple abscesses who fail to respond to percutaneous treatment

Abscess communication with the intrahepatic biliary tree does not prevent abscess collections being successfully treated by percutaneous

drainage. Two studies have shown that, in the absence of biliary obstruction, abscesses with intrahepatic biliary communication are treated with equal efficacy by percutaneous drainage, though the period of abscess drainage may be prolonged. This is in contrast to patients with intrahepatic biliary communication when surgery and biliary diversion are usually required.

Liver resection is occasionally required for patients with pyogenic liver abscess. The indication for this is usually hepatolithiasis or intrahepatic biliary stricture. In other patients, hepatic destruction may be so severe that they are best served by liver resection. Clearly risks are involved as manipulation may produce a life-threatening bacteremia. It is therefore recommended that, following ligation of the vascular inflow, the involved hepatic vein should be ligated before parenchymal dissection is carried out.

Laparoscopic drainage is an attractive alternative for patients requiring open surgical drainage. The advantages of laparoscopic surgery in terms of reduced analgesia requirements, reduced morbidity, faster postoperative recovery and shorter hospital stay compared to laparotomy are well documented. Laparoscopic localization of liver abscess may be more difficult than at open surgery due to lack of tactile feedback. However, aspiration with a long endoscopic or spinal needle may aid localization. Laparoscopic US is also likely to be useful in this respect. Tay et al (1998) have reported a series of 20 patients treated by laparoscopic drainage of liver abscess. Of these, 15 patients

had previously undergone percutaneous drainage. initial therapy failed in three patients. One patient developed a further abscess at the same site due to blockage of the drainage catheter. This was changed and the abscess resolved. One patient developed a small abscess at another site and this was treated with antibiotics alone. A third patient required further laparoscopic drainage for what was the other half of a dumbbell shaped collection. Ultimately all patients were successfully treated.

**Table – 4 : Pyogenic liver abscess : factors predictive of mortality**

Lee et al (1991)	Mishinger et al (1994)	Chou et al (1994)	Chu et al (1996)	Huang et al (1996) (1973-1993)
Clinical jaundice	Bilirubin > 1.5 g/dl	Age > 60	Female gender	Multiple abscesses
Pleural effusion	Leukocytosis > 15.000/mm <sup>3</sup>	Gas forming abscess	Rupture of abscess	Malignancy
Bilobar abscess	Haemoglobin < 11 g/dl	Rupture of abscess	Emergency laparotomy	Jaundice
Albumin < 2.5 g/dl	APACHE II	Bilobar abscess	Malignancy	Hypoalbuminemia
Bilirubin >2mg/dl	Malignancy	Clinical sepsis	Hyperglycemia	Leukocytosis
AST > 100 IU/L		Bilirubin > 2mg/dl	Hyperbilirubinemia	Bactermia
Alkaline phosphatase > 150 IU/ L		Urea nitrogen > 20 mg/dl	Elevated prothrombin time	Septic shock
Leukocytosis > 20000/mm <sup>3</sup>		Creatinine >2 mg/dl	Elevated APTT	
		AST > 100 IU/L		
		Albumin <2.5g/dL		

**Outcome:**

The last 60 years have seen a continued improvement in the prognosis of patients with pyogenic liver abscess. In the preantibiotic era, prior to the introduction of surgical drainage, pyogenic hepatic abscess was almost always fatal. With the introduction of surgical drainage and systemic antibiotics mortality fell. Miedema and Dineen (1984) reported a mortality of approximately 50%, which remained relatively constant between 1945 and 1982. In the 1980s, the widespread availability of US and CT facilitated earlier diagnosis and the development of percutaneous methods of drainage. This has resulted in a further fall in mortality. In the Johns Hopkins series, the overall mortality in the period 1952 to 1972 was 65% compared to a mortality of 31% during the period 1972 to 1993. Branum et al (1990) have reported a mortality of 19% between 1970 and 1986 and most recently Seeto and Rockey (1996)<sup>6</sup> have reported a mortality of 11% for patients presenting between 1979 and 1994.

A number of studies have attempted to identify factors that are predictive of poor outcome. In a univariate analysis, Lee et al (1991)<sup>36</sup> identified clinical jaundice, pleural effusion and bilobar abscesses to be risk factors for mortality. Laboratory factors that were predictive of mortality were hypoalbuminemia, hyperbilirubinemia, elevated aspartate transferase and alkaline phosphatase and leukocytosis. Multivariate analysis revealed leukocytosis, hypoalbuminemia and pleural effusion to be independent risk

factors for mortality. A multivariate analysis of 46 patients from Austria found that a high bilirubin, low hemoglobin, and a high APACHE I score were predictors of a complicated clinical course or mortality. However, marked leukocytosis and the presence of malignancy

Were also closely related to the risk of death. Perforation of hepatic abscess was predictive of a complicated clinical course with a mortality of 3.07%. Chou et al (1994)<sup>48</sup> also found that rupture of pyogenic liver abscess was associated with a significantly higher mortality (43.5% compared to 15.5%). In a considerably larger series of 384 patients, Chou et al (1994)<sup>48</sup> identified age greater than 60, impaired renal function, hypoalbuminemia and elevated bilirubin to be independent risk factors of mortality. Variations between individual series are likely to reflect differences between patient populations with regard to etiology and the proportions of patients with malignancy.

In summary, the incidence of pyogenic liver abscess appears to be increasing. This is in part due to a more aggressive approach to the treatment of patients with hepatobiliary and pancreatic malignancy and the increasing use of cytotoxic drugs. Uncomplicated pyogenic liver abscess is now a disease with a good prognosis. This is illustrated by the fact that patients with cryptogenic liver abscess may have a mortality as low as 2%.<sup>66</sup> Factors such as delayed presentation and delayed diagnosis may both contribute to poor outcome.



However, the major factor now contributing to mortality in patients with pyogenic liver abscess is the severity of the underlying disease and in particular the presence of malignancy. It is the management of these patients that will continue to provide a clinical challenge in the future.

## **AMOEBIC LIVER ABSCESS**

### **History**

Dysentery and hepatic abscess were described by British physician in India in the early 19 century. Ballingall, in 1818, described a serendipitous cure of tropical liver abscess when during a duel in Madras between 2 British military officers one of them received a lucky shot, which punctured his liver abscess. The pus drained and he was cured of his malaise. Open drainage of liver abscesses with insertion of setons into the abscess cavity was advocated by Ballingall, but the technique fell into disrepute because of the high associated mortality due to sepsis.

Lusch in 1875, was the first author to give a detailed description of amebiasis in his report of Russian woodcutter who died of the disease. In the same decade, Koch and Gaffky and .Kartulis in Egypt reported original observations on amebic dysentery and liver abscess. The first recognized cases of amebic liver abscess in the United States were reported from Johns Hopkins Hospital in 1890 by Osler and Simon A classic monograph on amebiasis was published from the same institution the next year

Confusion existed in the early 20 century concerning nomenclature and pathogenicity of different species of amoebae. In the Philippines, experimental infections in prisoners made possible the distinction between *Entamoeba histolytica* (Pathogenic) and *Escherichia coli* (non- pathogenic), showed that cysts were the infective stage, and demonstrated that not all people infected with *E.histolytica* become ill.

Important milestones in the history of chemotherapy for amebiasis have been the introduction of emetine for amebic dysentery and liver abscess by Rogers in India in 1912: the demonstration of the efficacy of chloroquine in hepatic amebiasis in 1948<sup>59,60</sup> The introduction in 1959 of dehydroemetine, a synthetic compound closely related to but less toxic than emetine; and the demonstration by Powell and colleagues in 1966, of cure in all forms of invasive amebiasis using metronidazole.

## **EPIDEMIOLOGY**

Infection with *E. histolytica* affects one tenth of the world's population and is considered responsible for at least 40,000 deaths annually, most infections occurring in the developing countries of the tropics and subtropics<sup>61,62,63,64</sup>.

Infection prevalence varies greatly and in some regions exceeds 50%. One study from Gambia, West Africa documented infection rates approaching 100% annually<sup>64</sup>.

The association between amebiasis and warm climates results from the poor sanitation and lack of hygiene that accompany underprivileged living conditions. Infection occurs mainly by the fecal-oral route. With transmission resulting from contamination of food by flies, unhygienic handling of food and spread within the family. Raw sewage contamination water supplies occasionally causes infection, as may the use of human feces as fertilizer and of unclean water for freshening food. It is estimated that more than 10% of the world's population is infected by *E. dispar* and *E. histolytica*.

Transmission of amebiasis can also occur in the developed world. Although amoebic liver abscess was described some years ago in an unfortunate German worker 14 weeks after he fell into a sewage tank, infection is now rarely waterborne

“Person-to-person spread as may occur in institutions or in slum areas with large immigrant population accounts for most cases. An unusual mode of transmission in an outbreak of amebiasis was the paramedical practice of colonic irrigation. In occasional patients, no source of infection is evident.

In recent years, an increased incidence of amebiasis has been noted in urban male homosexual population. Recognition of the association between homosexuality and amebiasis is attributed to Most Although amoebic liver abscess has been documented in male homosexuals, no increase in frequency has been reported in acquired Immunodeficiency syndrome

**The organism:**

The protozoan *E. histolytica* belongs to the subphylum Sarcodina (whose motility depends on pseudopodia), the supercaiss Rhizopoda and the order Amoebida. The genus *Entamoeba* includes the species *E. histolytica*, *E. bartmanni* (a non-invasive 'small race' with cysts <10  $\mu$ m in diameter), *E. coli*, *E. polecki* (infects pigs) and *E. moshkovski* (a free-living non-pathogenic form found in sewage). Except for *E. histolytica*, the other species are regarded as non-pathogenic. With the discovery of *E. dispar*, the identification of *E. histolytica* on morphology has become unreliable. The presence of ingested erythrocytes is seen only with *E. histolytica*. The two species have now been characterized by the study of zymodemes (patterns of electrophoretic mobility of isoenzymes) and genetic differences using RNA and DNA probes, and the use of polymerase chain reaction amplification.

*E. Histolytica* has two forms : Trophozoite and cyst. The trophozoites are uninucleate, facultative anaerobes with a double-layered limiting membrane surrounded by a fuzzy, external 20-30 nm glycocalyx. With the emerging concepts of virulence, it appears that only certain strains of *E. histolytica* are capable of tissue invasion and contact lysis of cells.

Using the electrophoretic patterns of amebic enzymes such as glucose-phosphate isomerase, I -malate, NADP oxidoreductase, phosphoglucomutase and hexokinase, 18 zymodemes of *E. histolytica* have been described from

various areas of the world. Seven of these strains have been isolated from subjects with mucosal ulceration and hepatic abscess and are consequently labelled as pathogenic.

Cysts of *F. histolytica* are quadrinucleate. These cysts, measuring 8-20  $\mu\text{m}$ , are an important identifying feature, and constitute the infective form of the organism. They are responsible for fecal-oral transmission via food, water or direct person-to-person contact. After ingestion, the quadrinucleate cysts reach the intestinal tract, where they develop into a metacystic stage and undergo an additional nuclear division; thus, eight new uninucleate trophozoites emerge to complete the life cycle. Cysts survive up to 45 minutes in fecal material lodged under the finger nails and up to 1 month in soil at 10°C. They remain infective in fresh water, sea water and sewage but are rapidly destroyed by drying, 200 p.p.m. of iodine and heat above 68°C. They are not killed by chlorination used to purify ordinary drinking water.

**Table: 5 : Distinguishing features of virulent and non-virulent amebae**

	<b>Virulent strains</b>	<b>Non-virulent strains</b>
Size	20-60	7-30 $\mu\text{m}$
Negative surface charge	Less	More
Concanavalin A receptors	Present	Absent
Effect of PMNs and tissue culture cells	Lethal 3000 PMNs/Eh	Sysceptible to PMNs
Human serum complement	Resistant	Susceptible

### **Host factors**

The human host represents the major reservoir although cross-infection from animals-particularly monkeys and rodents-has been postulated. Interperson transmission occurs via files and handles, and by sewage contamination of water sources. Male homosexuals also transmit the disease, but usually harbour non- pathogenic E. dispar.

Again, for reasons not completely understood, menstruating women are protected against invasive infection. Breast-fed children also have a low incidence of invasion, and this has been postulated to be due both to the

presence of protective IgA in the immune mother's milk and to the low iron content of milk.

A high content of iron in the diet, often obtained from country liquor, predisposes to invasive amebiasis, as does a diet rich in carbohydrate. Young adult males of low socio-economic status are thus the most commonly affected group. Elderly individuals with underlying diseases, and patients with depressed immunity due to malnutrition or corticosteroid therapy, are also prone to invasion by amebae. The natural resistance of menstruating women is lost in pregnancy.

In Mexican Mestizo population the presence of HLA DR3 and complotype SCO in both adults and children constitutes a primary independent risk factor for the development of amebic liver abscess, irrespective of age or sex.

### **Pathology and Pathogenesis**

Pathology:- *Entamoeba histolytica* exerts a lytic effect on tissue, a characteristic for which the organism is named, Light and electron microscopic studies have been interpreted as showing lysis of mucosal cells on contact with amoeba or alternatively, a diffuse mucosal damage before amoebic invasion. An amorphous, granular, eosinophilic material surrounds trophozoites in tissue, whether in colon, liver, lung or brain. Consistent with the fact those

trophozoites have the capacity to destroy leukocytes, inflammatory cells are found only at the periphery of established amebic lesions.

Liver pathology in amebiasis consists of necrotic abscess or periportal fibrosis, The “abscess” contains a cellular, proteinaceous debris rather than white cells and is surrounded by a rim of amebic trophozoites invading tissue. Amebae establish hepatic infection by ascending the portal venous system rather than lymphatics Triangular areas of hepatic necrosis, possibly due to ischemia from amebic obstruction of portal vessels have been observed Amebic liver abscesses probably result from the coalescence of small microabscesses. Liver function abnormalities are frequently present with intestinal amebiasis and are associated with periportal fibrosis has been reported in such patients; whether this reflects past trophozoite invasion or host reaction to amebic antigens or toxins unclear.

The invitro adherence of *B. histolytica* trophozoites to Chinese hamster ovary (CHO) cells and human colonic mucus is exclusively mediated by the parasite's galactose inhibitable surface protein. The adherence lectin participates in the invitro adherence of *E. histolytica* trophozoites to human leukocytes, rat and human colonic mucosa and submucosa, human erythrocytes, Chang liver cells, opsonized bacteria or bacteria with galactose- containing lip polysaccharide, and rat colonic epithelial cells produced monoclonal antibodies that inhibited amebic adherence to CHO cells.



Petri et al isolated the *E. histolytica* galactose specific adhesion. The adhesin is a 260-KID surface protein that consists of 170KD and 35KD subunits. The heavy subunit may mediate attachment as it is recognized by adherence- inhibitory monoclonal antibodies. Direct galactose binding activity of recombinant heavy subunit produced by expression DCR methodology has been demonstrated. The heavy and light subunits are encoded by gene families. The heavy subunit has a short cytoplasmic domain, a transmembrane domain, and a large extra cellular portion with a distinct cysteine- rich area. The light subunit in contrast is attached to the membrane via a glycosyl-phosphatidylinositol anchor. Petri et al identified seven discrete epitopes in the heavy subunit using monoclonal Ig antibodies all of which are located in the cysteine-rich domain. Braga et al recently reported that monoclonal antibodies to the heavy subunit abrogated amebic resistance to the lytic effect of the human complement C5b9 membrane attack complex at the steps of C8 & C9 assembly. The adhesion also has sequence and antigenic similarities to the human CD59 inhibitor of C8 and C9.

*Entamoeba histolytica* contains numerous proteolytic enzymes, including a cathepsin and proteinase, an acidic proteinase, collagenase and a well characterized major neutral proteinase. In vivo models of amebic liver abscess and in vitro studies demonstrate that host polymorphonuclear leukocytes constitute the initial host response to *F. histolytica*. Neutrophils demonstrate

chemo taxis to amoebae, their lysis by *E.histolytica* enhances host tissue destruction.

Cell- mediated immune defense mechanisms probable have a role in limiting invasive disease and resisting a recurrence after pharmacologic cure. The cell- mediated response consist of antigen specific lymphocyte blastogenesis with production of lymphocytes (including interferon- $\gamma$ ) capable of activating monocyte derived macrophages to kill *E. histolytica* trophozoites.

**Clinical features:**

Amebic liver abscess is 3 to 10 times as common in man as women. Most patients are young adults, although all age groups can be affected. With care, a relevant epidemiologic history usually can be elicited. Most patients are emigrants from or residents of endemic areas and poor. In the more affluent, a history of international travel by the patient to his or her close contacts may be relevant. Specific questions about homosexual activity should be asked. A history of previous

dysentery is infrequent and generally unhelpful unless accompanied by dependable laboratory reports.

Symptoms of amebic liver abscess are slow in onset and usually are present for several days or weeks before medical attention is sought<sup>1,76</sup>. Initial complaints are vague and include malaise, fever, anorexia and abdominal discomfort. In established cases, pain is most often the dominant symptom and

is maximal in the right hypochondrium about three fourths of patients complain of fever, often with chills and sweats, particularly at night. Anorexia nausea and vomiting are common, and many patients lose weight. Chest symptoms are present in about one fourth of patients and include right-sided pleuritic pain and cough. Diaphragmatic irritation may result in right shoulder pain and hiccoughs occasionally patients recognize abdominal swelling. Concurrent intestinal disease, such as dysentery or diarrhea, is rare.

Infrequently the onset of disease is abrupt and the symptoms mimic those of an abdominal surgical emergency Sometimes patients complain of ill health for many months, with constitutional symptoms such as weight loss and anemia predominating. In a small minority, the only manifestation is fever.

On examination the most patients are ill, sallow and sweaty, and they may appear anemic and toxic. Fever and tenderness over the liver are almost invariable, with the tenderness sometimes being most impressive over the right lower intercostals area sometimes the liver is visibly enlarged or expands the lower rib cage to give the abdomen an asymmetry.

Most often the liver is palpable, and in rare cases, it is huge and extend down to the pelvis. The physical signs may be subtle when the abscess is in the left lobe of the liver. Epigastric and left hypochondrial tenderness and enlargement of the left lobe could raise the possibility.

Careful examination of the chest reveals abnormalities in up to half of patients. Movement of the right side may be limited by pain. Dullness to percussion over the right lower lung field is common and implies a raised right hemidiaphragm or pleural effusion. Occasionally there are fine creptations on auscultation or a pleural or pericardial friction rub.

Jaundice is rare and when present, usually of minor degree. It indicates severe illness. Deeper jaundice usually results from multiple or large amebic abscesses or from lesion situated near the inferior surface of the liver with compression of the larger intrahepatic ducts.

Wherever amebiasis occurs in adults, children may also be infected. Most reported cases of liver abscess in childhood have been in children under age 3, with some affected at only 1 month of life. The sex ratio of cases in children is almost equal. Fever and tender hepatomegaly are the usual physical signs, with the latter sometimes difficult to elicit in crying child. Associated intestinal amebiasis and multiple hepatic abscesses seem more frequent in children than adults, and malnutrition is an important accompaniment, amebic liver abscess often seems a severer disease in childhood.

Sometimes liver abscess occur in pregnancy and such cases frequently are misdiagnosed. A Nigerian autopsy study demonstrated a higher prevalence and mortality from amebiasis in pregnant compared with nonpregnant women. It has been suggested that the immunologic and hormonal alterations of

pregnancy predispose to invasive disease. Finally, there is a widespread clinical impression that amebic liver abscesses is rare in patients with chronic liver disease, although isolated cases have been documented.

## **DIAGNOSIS**

### **Conventional laboratory tests**

Anemia is common in amebic liver abscess, with about half the patients having hemoglobin values below 12gm/dL. Although usually normochromic and normocytic, a hypo chromic blood picture may occur despite adequate iron stores. A neutrophilic leucocytosis is usual and a high proportion of bands may be seen. Although the white blood cell count is between 10,000 and 20,000/ul isolated cases with leukemoid reactions are described. Eosinophilia is not a feature of amebiasis. The erythrocyte sedimentation rate is raised.

Results of liver tests often are abnormal and of value in focusing attention of the liver, although derangements may be minor and nonspecific. Slight elevation of alkaline phosphates levels and reduction of serum albumin levels are the most frequent abnormalities. Normal liver tests do not exclude the diagnosis of hepatic abscesses. Significant elevation of the bilirubin level in hepatic amebiasis is unusual.

### **Diagnostic imaging**

About half of patients show elevation of the right hemidiaphragm of the chest roentgenogram, the changes in contour being typically most marked

anteriorly and medially. Fluoroscopy may demonstrate reduced or absent diaphragmatic movement. Blunting of the right costophrenic angle from a sympathetic pleural effusion is common, as are minor right lower lobe parenchymal abnormalities from atelectasis. Abdominal films may show hepatomegaly but are not helpful. Barium studies and infusion tomography are now outdated techniques for diagnosing amebic abscess.

Technetium sulfur colloid scanning the first modality that allows direct assessment of space occupying liver lesions is sensitive but lacks specificity. Other hepatic masses, such its as tumors and cysts, may produce similar “Cold” Areas. Gallium scans often are used to complement sulphur colloid examinations. Unlike pyogenic abscesses and primary hepatocellular cancers, amebic abscesses concentrate gallium only at the periphery of the abscess. The disadvantages of these tests include their low specificity, tile time required for their completion, and the difficult of working with isotopes.

Ultrasound is quick, safe, economical, and easily repeatable. A disadvantages of ultrasonography is its dependence on the interest and skill of the investigator.

Ultrasonic signs quoted as typical of hepatic amebic abscess are 1) a round or oval shape 2) a lack of significant wall echoes, so that there is abrupt transition from normal liver to the lesion 3) a hypoechoic appearance compared with normal liver, with diffuse echoes throughout the abscess. 4) a peripheral

location, usually close to the liver capsule: and 5) a distal sonic enhancement. Atypical fractures that have been documented include an irregular shape and a hyperechoic appearance.

Computed tomographic scanning shows amebic abscesses well defined, round, low density lesions, which may have a non homogenous internal structure. CT scanning is particularly useful in precise localization and definition of extent of disease (eg, in cases complicated by rupture) Both CT scan and ultrasonography may be used for guidance in cases in which aspiration is indicated. Disadvantages of CT scanning are its cumbersome nature and expense and the ionizing radiation inherent to the investigation.

### **Parasitology and serodiagnosis**

Concurrent hepatic abscess and amebic dysentery are unusual, stool examination in large series of patients with amebic abscesses have been negative in three fourths of cases or more. Parasitologic examination of the stool specimen can neither prove nor exclude hepatic amebiasis, although it may be relevant for subsequent management. The quality of practical parasitology in hospital laboratories varies widely. Over diagnosis is especially common, with stools leucocytes frequently reported as trophozoites of *E. histolytica*.

Serodiagnostic tests used include complement fixation, immunodiffusion, indirect fluorescent antibody tests, indirect hemagglutination (IHA). Counterimmuno electrophoresis, and enzyme — linked immunosorbent

assay (ELISA). Commercially produced diagnostic kits for use at the bedside, such as those using latex agglutination are also available. Clinicians should familiarize themselves with local facilities and the accepted sensitivity and specificity of the tests in question.

Positive tests are expected in virtually all cases of extraintestinal amebiasis as well as in most cases of amebic dysentery. Serology can only prove that a patient has suffered invasive infection with *E. histolytica*, not that a particular illness is the result of that infection.

The IHA test is highly sensitive and widely available. A serologic titer of 1:512 is usual, although not invariable, in acute invasive disease. Titres may continue to rise after presentation, and on occasion, the test is negative when the patient is first seen but positive a few days later. The IHA test may remain positive for months or years after invasive infection. ELISA is a cheap and sensitive technique that has been widely applied to the serodiagnosis and seroepidemiologic study of many parasitic diseases. Its use for the diagnosis of amebiasis is likely to increase.

MRE is not significantly superior to CT in diagnosis of amebic liver abscess, it may be useful in follow up of treated cases, and in differentiating it from a hepatic neoplasm. Angiography is rarely required in the diagnosis of a straightforward amebic liver abscess, but may be necessary in a case where carcinoma is difficult to exclude.



**Role of aspiration:**

In the era before ultrasonography became widely available, aspiration of the typical ‘anchovy sauce’ pus from the liver was often considered vital to confirm the diagnosis of amebic liver abscess. Nowadays, ultrasound-guided aspiration is often justified on the basis that the diagnosis will then be ‘more certain’ or that the abscess can be ‘aspirate to dryness’ at the time of diagnostic aspiration. The controversy about routine aspiration of uncomplicated amebic liver abscess remains unresolved. Two recent studies have shown that aspiration does not accelerate healing, and may only confuse the diagnosis by revealing atypical pus or blood. However the belief that aspiration hastens clinical recovery and may not involve significant procedure related morbidity, is widespread in clinical practice. This approach is supported by a recent small prospective study. Clinical improvement invariably occurs with antiamebic therapy alone in an uncomplicated case. When the differential diagnoses in a given case include operable neoplasm or hydatid disease, aspiration is risky and may even be contraindicated.

Aspiration is therefore now regarded as generally superfluous in the management of amebic liver abscess, and should be reserved for situation when

I. Amebic serology is inconclusive, delayed, or unavailable and the main differential diagnosis is a pyogenic liver abscess.

2. A therapeutic trial with antiamebic drugs is deemed inappropriate (as in pregnancy).

3. There is suspicion of secondary infection of the liver abscess. This is estimated to occur in 15% of cases.

4. When fever and pain persist for more than 3 to 5 days after starting appropriate therapy, aspiration may provide symptomatic relief.

5. In extremely large abscesses where rupture is suspected to be imminent, especially when pericardial rupture from a left lobe abscess appears likely.

Single aspiration may be sufficient for diagnostic purposes, but when performed as part of therapy is likely to be inadequate. When more than one aspiration is required, the placement of a percutaneous drain is probably indicated to reduce the risk of recurrence.

### **Complications of amebic liver abscess:**

Communication or extension of amebic liver abscesses occur into neighboring cavities and organs — the peritoneum, viscera and large vessels on one side of the diaphragm and the pleura, bronchi, lungs and pericardium on the other.

### **Peritoneal and visceral involvement**

Peritonitis associated with amebiasis is due to a rupture of amebic liver abscess in 78% of cases and due to perforated or necrotizing amebic colitis in

the rest (22%). The two process can occur simultaneously in a small minority of cases, and this must be kept in mind while making therapeutic decisions for a given patient.

The incidence of spontaneous rupture of amebic liver abscess varies between 2.7 and 17% of cases. Between 18 and 70% of all amebic liver abscess ruptures are into the peritoneal cavity. Adherence of the liver abscess to the diaphragm, anterior abdominal wall, omentum and bowel tends to confine the area of contamination. Rupture into a hollow viscus such as the stomach or colon may occur in this situation with spontaneous drainage. A hepatogastric, hepatoduodenal or hepatocolonic fistula may result. Free rupture into the peritoneal cavity is uncommon and usually occurs in a nutritionally depleted and moribund patient. Patients present with abdominal pain, and either a mass or generalized distention. Sudden bloody diarrhea may occur in colonic rupture and hematemesis may occur in patients with hepatogastric fistula. Signs of peritonitis along with tender hepatomegaly, intercostals tenderness and right basal lung signs and clinical jaundice may lead to a suspicion of the diagnosis, which will be confirmed on ultrasonography. At times the diagnosis may be made only at laparotomy, at which time the excessive bleeding resulting from decreased prothrombin levels can be difficult to manage.

Ultrasonography and CT often shown perihepatic fluid collection in cases of amebic liver abscess. It is not possible by these imaging techniques to

tell if these collections are reactive or actual leaks from the abscess cavity, and the differentiation must be made clinically.

Various forms of management of an abscess which has extended into the peritoneal cavity have been advanced. The aggressive surgical approach of the 1970s and early 1980s were associated with increased mortality and have now given to many increasingly successful attempts at percutaneous drainage of the liver abscess and the extravasated pus.

Absolute indications for laparotomy include doubtful diagnosis, concomitant hollow viscus perforation with fistulization resulting in life-threatening hemorrhage or sepsis, or if conservative management fails. At laparotomy the liver abscess, which usually appears as a tan-colored bulge on the surface, must be handled gently. Septa running across the cavity are usually blood vessels and bile ducts traversing the abscess cavity. Hemorrhage can be difficult to control, especially if the clotting is disordered, and postoperative bile leaks may result. Irrigation of the abscess cavity with saline is usually sufficient and may be followed by the installation for 3-5 mm of a solution of 65 mg of emetine hydrochloride in 100 ml of normal saline. Tube drains are inserted and retained as necessary. Hollow viscus perforations must be dealt with on their own merits, with exteriorization, proximal diversion or serosal patch closure as indicated.

Postoperative antiamebic therapy in the form of intravenous metronidazole is combined with broad-spectrum antibiotics. Dehydroemetine is added if no cardiac contraindication exists.

The mortality of this complication ranges between 12% and 50%.<sup>80</sup>

### **Thoracic and pleuropulmonary involvement**

Thoracic complications associated with amebic liver abscess include a sympathetic straw colored right sided effusion, rupture of the abscess into the pleural cavity and rupture of abscess into the bronchial tree.

Transdiaphragmatic involvement in abscess located high on the right lobe are so common as to be part of the clinical syndrome of amebic liver abscess. Clinically, this manifests as dyspnea and a dry cough which exacerbates the right hypochondriac pain caused by the hepatic lesion. Right basal crepitations are a frequent accompaniment to the abdominal signs. A pleural rub may be found which decreases as signs of pleural effusion supervene. Chest radiography shows atelectasis and blunting of the costophrenic angle. Ultrasonography and CT often pick up the pleural effusion before it is clinically detectable. There are no ultrasound or CT features to differentiate between a sympathetic effusion and a transdiaphragmatic intrapleural rupture except that the former tender to be small and clinically insignificant. No treatment is required for this kind of pleural collection other than the treatment of the liver abscess on its own merits.

Rupture of an abscess into pleural cavity usually occurs suddenly, and extends rapidly to collapse the right lung and fill up the right pleural space. Clinically, it manifests as the sudden onset of severe dyspnea. Radiography reveals a homogenous opacification throughout the right hemithorax with displacement of the mediastinum to the opposite side. Ultrasonography will reveal the liver abscess.

Treatment consists of thoracocentesis. An important precaution to be observed both in chest aspiration and establishment of intercostal tube drainage is to go in high on the right lateral side of the chest near the axilla, as the right diaphragm is considerably elevated in these patients. The tube can easily be inserted across the diaphragm into the liver, where it will fail to evacuate the pleural collection and may keep the track from the liver abscess from closing. Ineffective early drainage of the amebic empyema is usually complicated by secondary infection requiring more aggressive surgical procedures like pulmonary decortication at a later date.

Rupture of the abscess into the bronchi is characterized by the sudden onset of coughing with expression of copious quantities of chocolate-colored sputum. Although a complication of amebic liver abscess, it almost always has a beneficial effect as the abscess drains itself. As the abscess is usually well walled off from both the pleural and peritoneal cavities, surgical intervention is not required and postural drainage, bronchodilators and antiamebic drugs

suffice. Lung abscess occurs rarely. In cases where adhesions are not well formed, the liver abscess can rupture into both the pleural space and bronchi simultaneously and postural drainage of bronchial secretions must be combined with thoracocentesis.

Metronidazole used as a single drug is effective in the treatment of thoracic complications of amebic liver abscess, but emetine produces a more rapid response and may be required in cases where metronidazole resistance occurs.

**Pericardial involvement:**

Abscesses of the left lobe of the liver are more prone to pericardial complications, which may range from asymptomatic pericardial effusions to cardiac tamponade from intrapericardial rupture of a left lobe abscess. Signs of pericardial effusion may be detected clinically or on chest radiography but amebic liver abscesses as the cause is often difficult to detect except on abdominal ultrasound. Although left lobe abscesses resolve equally well with antiamebic drugs as do right-sided abscesses, the detection of pericardial thickening or a pericardial effusion on CT scanning or ultrasound may constitute an indication for aspiration of a left-sided amebic liver abscess. Signs of pericardial effusion may be detected clinically or on chest radiography but amebic liver abscess as the cause is often difficult to detect except on abdominal ultrasound. Although left lobe abscesses resolve equally well with

antiamebic drugs as do right-sided abscesses, the detection of pericardial thickening or a pericardial effusion on CT scanning or ultrasound may constitute an indication for aspiration of a left-sided amebic liver abscess. In the presence of cardiac tamponade, aspiration of the pericardium must be performed along with drainage of the liver abscess followed by antiamebic drugs, of which metronidazole is the drug of choice. Dehydroemetine is used with caution because of its propensity for cardiotoxicity.

### **Chernotherapeutic agent**

Metronidazole is the treatment of choice for all forms of invasive amebiasis. It is a nitromidazole that is well absorbed after oral administration, and it is excreted mainly by way of kidneys. Reduction of the drug's nitro group by E.

*E. histolytica* produces toxic metabolites that interfere with nucleic acid synthesis. Adverse effects include nausea, anorexia, metallic taste, urethral and vaginal burning, dark urine and a disulfiram-like reaction with alcohol. Central nervous system effects such as vertigo, ataxia, and peripheral neuropathy have also been reported. A transient leukopenia occasionally is observed. Reports of possible carcinogenicity, mutagenicity, and the advantages of metronidazole for severe disease, including in pregnancy, outweigh its theoretic dangers. In practice, the gastrointestinal adverse effects cause the most trouble.



The usual dosage of metronidazole is 750 mgm three times daily for 5 to 10 days. In actual fact, a choice of regimens is available, and large single dose (2.4gm) given for shorter periods, such as 3 days, may be equally effective. The usual Paediatric dose is 35 to 50 mgm/kg/d in three divided doses. In very ill patients, some clinicians extend treatment 15 days or even beyond. Patients who cannot take oral metronidazole may be treated with the parenteral preparation Metronidazole is effective treatment for invasive intestinal disease but is not completely reliable as a luminal amebicide.

Occasional treatment failures have been reported in addition to cases of hepatic amebiasis developing after metronidazole therapy for intestinal disease. Other nitroimidazoles offer no advantage over metronidazole. The best known is tinidazole, which is perhaps associated with less nausea. The usual adult dosage is 2 g/day.

**Chloroquine:** The antimalarial drug chloroquine, a 4- aminoquinoline, acts by binding to parasite deoxyribonucleic acid. High concentrations in liver tissue are obtained after oral administration. It has half life upto 1 week and is excreted predominantly through the kidneys..

Adverse effects are nausea, abdominal discomfort, and pruritis. Retinopathy is only a potential problem in patients taking long term chloroquine, as for malaria prophylaxis or rheumatoid arthritis. The usual dose is 1 gm / day for 2 days followed by 500 mgm/day for 20 days. The only

controlled trial of chloroquine versus metronidazole for amebic liver abscess showed no difference in efficacy other than slightly quicker, response with metromidazole

### **Emetine and dehydroemetine**

Emetine is the oldest as well as the most potent amebicidal drug available. It is given by intramuscular or subcutaneous injection and slowly excreted through the kidneys. The drug acts by interfering with protein synthesis. The usual dosage is 1 mg/kg/d to a maximum of 60 mg/day for 10 days. Duration of the treatment should be kept to a minimum, preferably less than 6 days. Adverse effects have rendered this drug obsolete except in the severest of cases. Adverse effects include vomiting, diarrhoea, renal impairment, and pain or necrosis at the site of injection. The most serious adverse effect is cardiotoxicity, any sign of which is an indication for stopping the drug. Emetine has no luminal amebicidal activity.

Dehydroemetine is a synthetic preparation with a similar action to emetine but associated with less cardiotoxicity. It is equally effective therapeutically but excreted more rapidly. The daily dose of 1.25 mg/kg given by intra or subcutaneous injection to a maximum of 90 mg/d. It should be given in preference to emetine, if available. Cardiotoxicity may be more likely with concurrent administration of chloroquine.

**Therapeutic strategy:**

Metronidazole is administered as a single drug after diagnosis, with concomitant correction of hypoprothrombinemia, hypoproteinemia, and anemia. If dramatic improvement in 48 - 72 hours is noted no other therapy other than the complete course of metronidazole is required. A luminal agent such as Dilonaxide furoate (500 mgm p.o. tid x 10 days) or paromomycin (30 mgm/kg/day in 3 days x 10 days) must be administered following infection as a part of the complete treatment.

In patients who do not respond satisfactorily, emetine or dehydroemetine is added. Evidence of pulmonary, peritoneal or pericardial extension is all indication for aspiration of the liver abscess with an intercostal tube or catheter drainage into a closed-circuit collection system. Failure to adequately control the abscess by these means — increasing signs or peritonitis, uistulization into a hollow viscus or secondary infection with septicaemia constitutes an indications for laparotomy.

**Prevention**

Modern biologic techniques have helped to characterize amebic antigens which show great promise towards the development of a vaccine. These antigens include:

- a. Serine rich Entamoeba histolytica protein (SREHP)
- b. A 170 kD subunit of Gal / Gal Nac binding lectin and

c. A 29 kD cysteine rich protein

Recombinant vaccines based on these antigens have been successfully used in animal models of amebiasis. Attempts are now afoot to fuse these antigens with the relevant subunits of cholera toxin and salmonella species to develop an oral combination 'enteric pathogen' vaccine.

## **PROGNOSIS**

Meta-analysis of 3081 patients with amebic liver abscess showed that 114 (4%) died. In comparison, the mortality rate for pyogenic liver abscess was 46%. In patients treated with amebicidal drugs alone the mortality was 2% and the addition of needle aspiration did not improve this result. Independent risk factors for mortality include serum bilirubin more than 3.5 mg%, encephalopathy, hypoalbuminemia defined as less than 2.0 G% and multiple abscess cavities.

Patients treated with a strategy of early and aggressive surgery as advocated by Balasegaram (1981) and Eggleston et al (1982) did not show a remarkable improvement in mortality although in Balasegaram's series the hospital stay was probably reduced.

Ruptured amebic liver abscess occurs in 2-17% of patients, with a mortality between 6 and 50%. It is hoped that with increasing skill at percutaneous drainage of these abscesses the mortality in these patients, who usually constitute a major risk for surgery and anaesthesia, will be reduced.

## **MATERIAL AND METHODS**

A one year prospective time bond study from Nov. 2006 to Oct. 2007 was done on patients GRH, MMC, Madurai 20 patients were admitted diagnosed and treated as a cases of liver abscess.

A detailed history was taken from each of these patients and all of them were subjected to a through clinical examination. These patients were then subjected to investigations available within the hospital such as Hb, Tc, RBS, urea, creatinine, liver function tests (SGOT, SGPT, Serum bilirubin, ALP, serum albumin, total proteins, A:G ratio PT). Ultrasonography of abdomen was done in all cases. Serological tests for amebic liver abscess were not performed as the facilities were not available in our hospital. Chest X-ray was done in all cases. Pus was sent for gram's stain and culture and sensitivity. Anaerobic cultures were not done as the facility was not available in our hospital. Blood culture were not routinely performed in all cases. As the facility of computed tomography (CT) scans was not available in our hospital and most of the patients were poor, this investigation could not be carried out.

Following diagnosis of liver abscess, depending on volume of abscess, patients were treated by conservatively or percutaneous needle aspiration. Those abscess with <50 cc were treated conservatively, and with >50cc percutaneous needle aspiration was done with a 180 spinal needle using

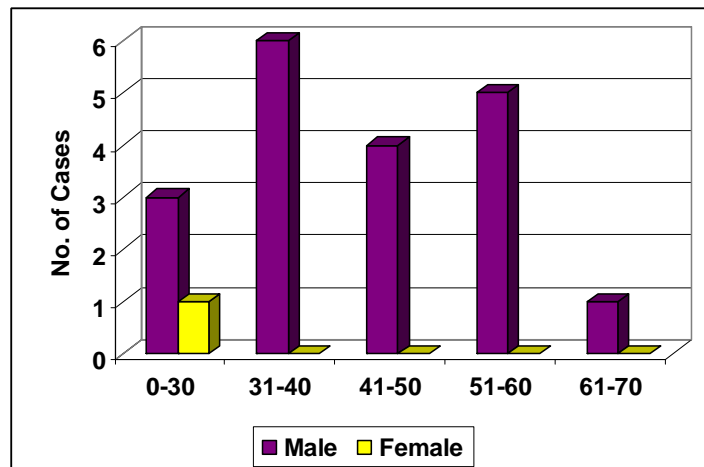
ultrasonography. Intravenous antibiotics were started and metronidazole at a dose of 40 mgm/kg/day in divided doses for 14 days. If pus revealed growth of organisms than appropriate antibioitics were given in full course follow-up was done as long as patient stayed in hospital and also during subsequent visits. Relapses were noted and repeat aspirations were performed when necessary, cure was defined as improvement clinically with subsidence of fever, and local signs, symptoms, decrease in WBC count and ultrasonography showed reduction in size < 3 cm in diameter.

## RESULTS

The following observations were made in this study

**Table 6 : Age and sex incidence**

Age Group	Male		Female		Total	
	No.	%	No.	%	No.	%
0-30	3	15	1	5	4	20
31-40	6	30	0	0	6	30
41-50	4	20	0	0	4	20
51-60	5	25	0	0	5	25
61-70	1	5	0	0	1	5
Total	19	95	1	5	20	100



**Fig 3: Age and sex incidence**

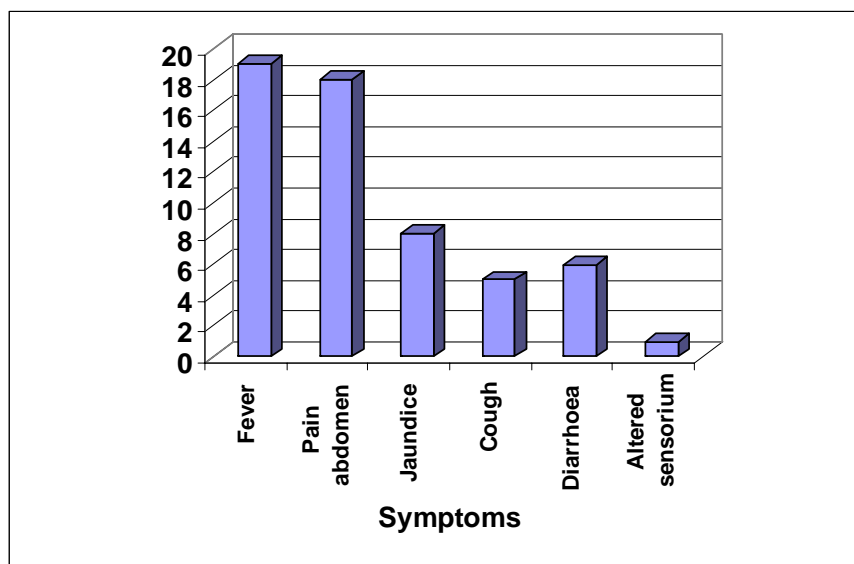


Liver abscess in this study was more common in males (95%) than females (5%). The commonest age group for liver abscess was 31-40 yrs (30%) followed by 51-60 yrs (25%). The youngest patient was 25 yrs and oldest was 62 yrs.

**Symptoms:**

**Table 7: Incidence of symptoms**

Symptoms	No. of patient	%
Fever	19	95
Pain abdomen	18	90
Jaundice	8	40
Cough	5	25
Diarrhoea	6	30
Altered sensorium	1	5

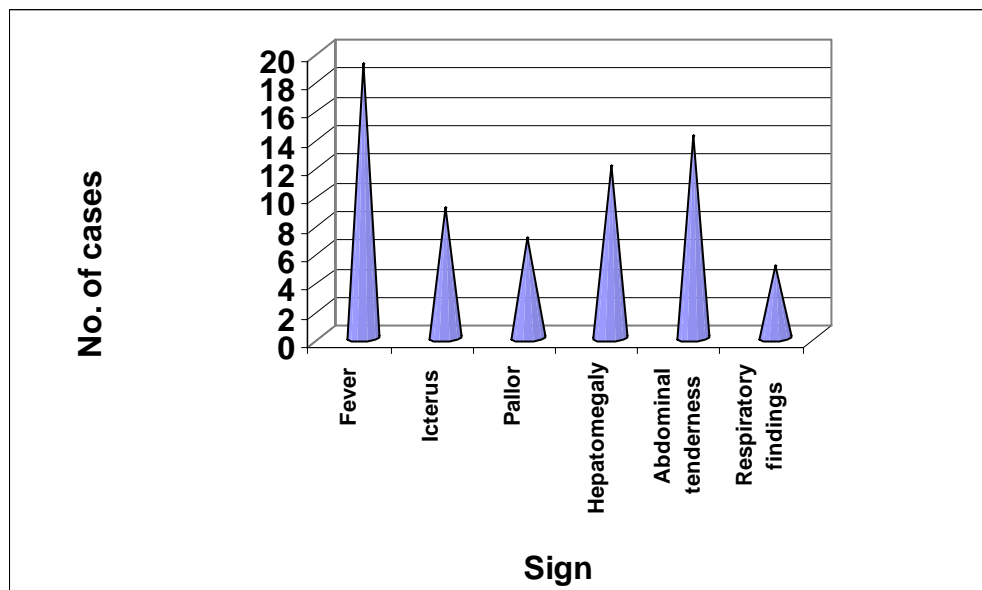


**Fig. 4 : Incidence of symptoms**

The commonest symptom was fever 95% followed by pain abdomen 90% jaundice was present in 40% (8/20), diarrhea occurring in 30% (6/20); cough in 25% (5/20, altered sensorium 5% (1/20).

**Table 8 : Distribution of signs**

Signs	No. of Patient	%
Fever	19	95
Icterus	9	45
Pallor	7	35
Hepatomegaly	12	60
Abdominal tenderness	14	70
Respiratory findings	5	25



**Fig. 5 : Distribution of signs**

The most common sign was fever which was present in 19 patients (95%) 14 patients had abdominal tenderness, at the time of diagnosis and 12 patients had hepatomegaly (60%), 9 patients had icterus (45%), pallor was present in 7 patients (35%) and respiratory findings in 5 patients (25%) included right pleural effusion, basal creptations.

**Table 9 : Duration of symptoms**

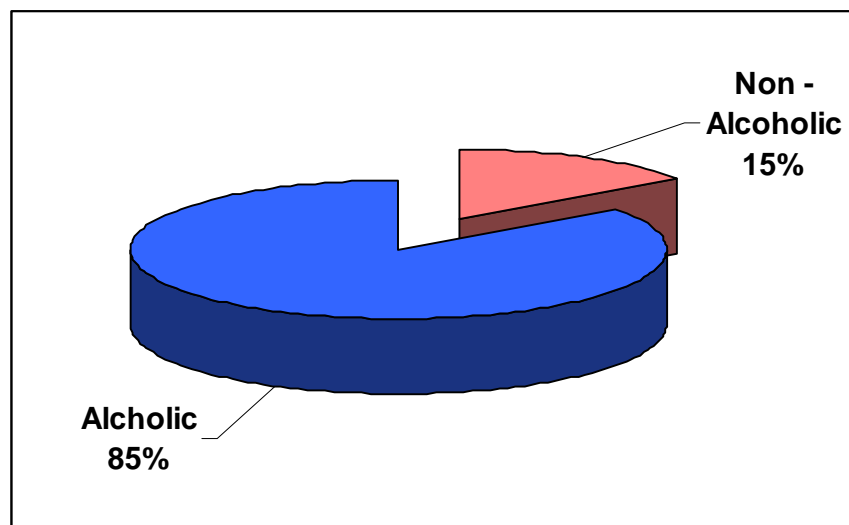
Onset	No. of patient	%
Acute < 7 days	6	30
Subacute > 7 days	13	65
Chronic > 2 month		

In this study patients presents presented acutely with onset of symptoms <7 days in 6/20 (30%) of cases. Subacute presentation between 7 days – 2 months was noted in 13/20 (65%) and those with chronic duration of onset > 2 months was seen 1/20 (5%) of cases.

**Table 10: Alcoholism**

Alcoholism	No. of patient	%
Neera / Toddy / Arrack	17	85
Amount > 500 ml/day	17	85
Duration > 1 yrs	17	85

Out of 19 males patients, 17 patients were alcoholics. All these patients had history of consuming neera/ toddy or locally made arrack. All these patients had history of consuming alcohol for more than 1 yr.



**Fig . 6 : Alcoholism**

**Table 11: Percentage of abnormal laboratory investigations.**

Investigation	No. of patient	%
Anaemia (Hb < 10 gm%)	6	30
Leucocytosis (> 12,000 c/cmm)	17	85
Diabetic (RBS > 200 mgm/ dl)	2	10
Raised urea ( > 60 mgm / dl)	3	15

Hemoglobin less than 10gm% was found in 6 cases (30%) and lowest hemoglobin noted in this series was 8.8 gm%. Leucocytosis of more than 12000

cells / cumm was present in 17 patients (85%). The highest count noted in this study was 16,000 cells / cumm, polymorphs were predominant 2/20 (10%) were found to be diabetic with RBS > 200mgm/dl raised urea (> 60mgm/dl) was found in 3/20 (15%).

**Table 12 : Analysis of LFT**

Serum Bilirubin	No.of patient	%
< 1	3	15
1.1 – 2	9	45
2.1 – 4	5	25
4.1 – 6	2	10
6.1 – 8	1	5

Clinically jaundice was detected in 8 cases (40%) and all of them had the Bilirubin >2mgm / dl (40%).

Investigation	No. of patient	%
ALP (Alkaline phosphatase)	14	70
Hypoalbumemia (< 3gm / dl)	2	10
Increased PT time (> 20 sec)	1	5
Increased SGOT (> 40 IU/I)	6	30
Increased SGPT (> 40 IU/L)	7	35

Alkaline phosphatase was found to be raised in 14/20 (70%) of cases. Hypoalbuminemia (< 3gm/dl) was observed in 2/20 (10%) cases. Increased Prothrombin time > 20 sec was seen in 1/20 (5%) of cases. Increased SGOT and SGPT was seen in 35% of the cases in this study.

**Table 13 : Chest X-ray**

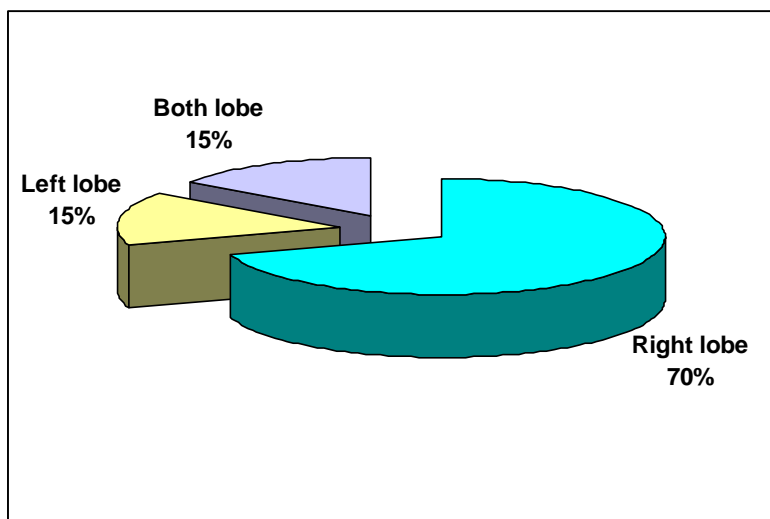
Chest X-ray	No.of patient	%
Elevated hemidiaphragm	11	55
Pleural effusion	5	25

Chest X-ray showed elevation of the right hemidiaphragm in 11 cases (55%) Obliteration of right costophrenic angle was seen in 5 cases (25%).

**Table 14: Ultrasound Examination**

Ultrasound examination was done in all cases. It showed evidence of abscess in liver in all the cases.

Location	No. of patient	%
Right lobe	14	70
Left lobe	3	15
Both lobe	3	15

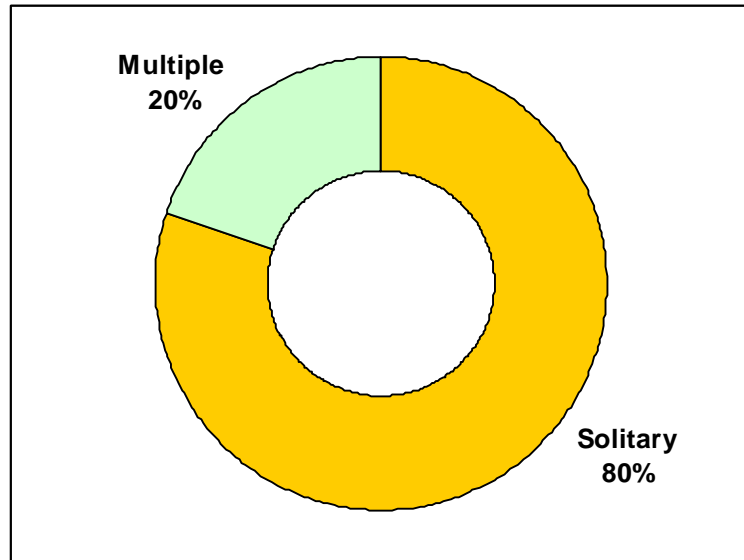


**Fig – 7 : Location of abscess**

Right lobe of the liver was more often involved than left lobe of liver. Right lobe involvement was present in 14 cases (70%) and both lobes in 3 cases (15%) and left lobe in 3 cases (15%).

**Table 15: Solitary and multiple abscess**

Number	No. of patient	%
Solitary	16	80
Multiple	4	20



**Fig . 8 : Distribution of abscess**

16 cases, (80%) of liver abscess showed solitary abscess in ultrasound examination and 4 cases showed multiple abscesses.

**Table 16: Pus culture Analysis**

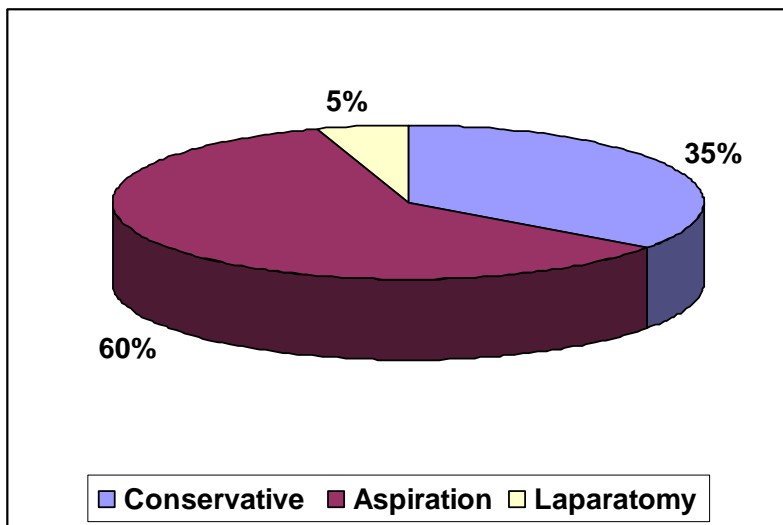
Organism	No.of patient	%
No growth / Anchovy sauce	11	84
Non- fermenting gram –ve	1	7.6
Staph aureus	1	7.6

In this study 13 cases were subjected to invasive treatment. Out of the 13 cases, 11(84%) had. “Anchovy sauce” appearance of the pus and revealed no growth. While growths were obtained in 2 (14.6%) of these cases. Non-fermenting gram –ve in 1 case (7.6%) and staph aureus in another case (7.6%).



**Table 17: Analysis of treatment**

Treatment	No. of patient	%
Conservative	7	35
Aspiration	12	60
Laparotomy	1	5



**Fig. 9 : Treatment of liver abscess**

Out of 20 cases, those whose volume is < 50 cc were treated conservatively and those whose volume > 50cc were treated by USG guided aspiration 7 cases (35%) were managed conservatively and 12 cases (60%) were treated by USG guided aspiration. For one case laparotomy was done.

One case which ruptured into peritoneal cavity, laparotomy was done. Pus was completely drained out and sent for microbiological examination, peritoneal toilet was given.

**Table 18: Complications**

<b>Complications</b>	<b>No.of patient</b>	<b>%</b>
Ruptured into peritoneal cavity	1	5
Pleural effusion	5	25
Septicemia	1	5

The type of complications in our study were ruptured into peritoneal cavity and pleural effusion and septicemia. In one case abscess ruptured into peritoneal cavity for which laparotomy was done. 5 cases had right pleural effusion. In one patient septicemia with multiorgan failure was seen.

**Table 19: Mortality rate**

Total patient with liver abscess	20
Surviving	19
Death due to liver abscess	1

Mortality rate of 5% was seen in the present study.

**Table 20: Condition at the time of discharge**

<b>Condition</b>	<b>No. of patient</b>	<b>%</b>
Relieved	19	95
Recurred	1	5

In current series 20 patients were cured of their symptom, in one patient reaspiration was done.

**Table 21: Analysis of repeat aspiration**

<b>Treatment</b>	<b>No.of patient</b>	<b>%</b>
Single aspiration	10	83.3
Two aspiration	2	16.2

In 10/12 (83.3%) required I aspirations were required and 2/12 (16.2%) required 3 aspirations.

## DISCUSSION

### Age and sex incidence

The age of the patients varied from 25-62. The mean age was 42 yrs. The lowest incidence was noted in the age group 61-70 yrs (5%). The highest incidence was noted in the age group 31-40 yrs (30%) followed by 51-60 (25%) yrs. Equal incidence was noted in each groups 41-50 yrs (20%) and 0-30 yrs (20%) 19/20 patient were males (95%) and 1/20 were females (5%) 50% of cases occurred between the age group 31-50 yrs.

in this study, liver abscesses seen to affect most in the age group 30-50 yrs, being rare above 60 yrs. Males were more commonly affected when compared to females,

- According to Bhagwan satiani, Eugene, D. Davidson the mean age was 49 y

- According to Walter D Gaisford James B.D, Mark, the age of the patients ranged from one and half to eight five year with the average age being forty six years (46 yrs). Liver abscess occurred in men more frequently than women.

**Table 22 : Symptoms**

Comparison of symptoms and signs in present study with other studies.

Symptoms	Present series		Greenstein – et al	Rubin et al
	No of cases	%	%	%
Fever	19	95	95	87
Pain abdomen	18	90	84	47
Jaundice	8	40	24	20
Cough	5	25	37	24
Signs				
Fever	19	95	95	87
Icterus	8	40	24	20
Abdominal Tenderness	14	70	42	47
Hepatomegaly	12	60	39	51
Respiratory finding	5	25	37	24

In this study, the commonest symptom was fever 95%, followed by pain abdomen 90%, jaundice 40% cough 25%, diarrhea 30%, cough 25%.

The commonest symptom at presentation in the study conducted by Greenstein et al and Rubin et al was fever (95%) and 87% followed by pain abdomen, jaundice cough.

Altered sensorium as a manifestation of shock was seen in 1/20 cases (5%).

According to Khee Siang, Chin ming, shock and altered sensorium occurred in 5% of cases of liver abscess in their study.

Diarrhoea was present in 6(20) (30%) cases, According to Shyam Mathur diarrhoea was seen in 7% of patients.

The commonest sign at presentation was fever 19(95%) followed by abdominal tenderness 14(70%), 12 patients had hepatomegaly (60%) 8 patients had icterus (45%), respiratory findings in 5 patients (25%).

The commonest sign at presentation in the study conducted by Greenstein et a and Rubin et al was fever (95% and 87%), followed by hepatomegaly (51%)

abdominal tenderness (47%), respiratory findings 24% icterus 20% in Rubin et al, and in Greenstein et al, second most common sign was Abdominal tenderness 42% hepatomegaly 39% respiratory findings 37%, icterus 24%.

### **Duration of symptoms**

The onset of the disease is subjected to great variations depending upon the type, location and quantity of liver abscess, It may be acute, insidious,

clinically undetectable or fulminant form. In this present study acute onset <7 days was seen in 30%, sub acute onset 7 days — 2 months was seen in 65% and chronic onset of > 2 months was noticed in 5%. Thus most patients (65%) presented with a duration of onset between 7 days to 2 months (subacute)

According to Bhagwan satiani, Eugene D,Davidson,duration of symptoms prior to admission varied considerably from one day to three months.

According to Maingot's abdominal operation most patients of liver abscess manifest symptoms for less than 2 weeks but a more indolent course occurs in 1/3<sup>rd</sup> of the patients.

### **Alcoholism in cases of liver abscess**

Alcoholism was found to be the most consistent etiological factor in this study of liver abscess, 17/20 (85%) of the cases of this study were found to be alcoholics. All patients consumed > 500 ml/day. All patients had history of consumption of alcohol for more than one year.

Thus it can be inferred from this study that alcoholism is the single consistent predisposing risk factor in patient with liver abscess. Further the locally made neera, Arrack, toddy may have a role in the causation of liver abscess. However it is possible that these locally made Arrack may have been contaminated by entamoeba histolytica through faeco-oral route and may contribute to high incidence of cases of liver abscesses in alcoholics.

According to Shyam Mattur, Ashok Gehlot, Alok Mehta, alcoholism was found in 70% of their cases.

### **Analysis of laboratory investigation**

6/20 (30%) were found to be anemic (Hb < 10gm /dl) in this study. The mean Hb of the patients in this study was 10.4 gm/dl with a range 8.8-13.6 gm%.

WBC count was found to be raised in 17/20 cases (85%). Mean WBC count in patient of this study was 12,400 cells/cumm with a range of 9200-16000.

The occurrence of diabetes in the present. Study was 2/20 (10%). Random blood sugars were done on all patients upon admission RBS > 200 mgm were considered diabetic. The mean RBS was 110mg and ranged from 50-213 mgm/dl in patients of this study.

Increased urea was present in 3 (15%) of cases.

- According to Bhagwan satiani and Eugene D. Davidson, anaemia was present in 39% of cases and leucocytosis in 86.5% of cases.

- According to A.J. Greenstein, D Lowenthal, BA, G.S. Hammer, F. Schaffner and A. H. Aufses, Diabetes was found in 10% of cases.

Analysis of liver function tests

Serum bilirubin >2 mgm Id! were seen in 8/20 cases (40%).



According to Bhagwan Satiani and Eugene D. Davidson, elevated serum bilirubin was seen in 36% of cases.

Alkaline phosphatase levels were raised in 4/20 (70%) of cases in this study. Hence ALP is the single most consistent liver function test to be elevated in cases of liver abscess.

- According to Bhagwan Satiani and Eugene D. Davidson increased levels of ALP was seen in 63% of cases.

- Hypoalbuminemia (S. alb <3.0 g/dl) was seen in 2/20 (10%) of cases. One patient who died due to liver abscess had hypo albuminemia.

- According to Chu KM, Fan ST hypoalbuminemia was an adverse prognostic factor in cases of liver abscess.

- Increased prothrombin time > 20 was seen in 5% increased SGOT in 30% increased SGPT in 35%.

### **PUS culture Analysis**

In this study 13 cases were subjected to invasive treatment. Out of the 13 cases, 11 (84%) had “Anchovy sauce” appearance of the pus and revealed no growth. While growths were obtained in 2(14.6%) of these cases. Non fermenting gram -ve in 1 cases (7.6%) and staph aureus in another case (7.6%)

According to Walter D. Gaisford, James B.D. Mark culture was positive in 19% of cases. The most common organism isolated was coliforms.

### **Chest X-ray finding:**

Chest X-ray was done for all patients in this study and the X-ray findings were studied. Chest X-ray showed elevation of the right hemidiaphragm in 11 cases (55%) obliteration of right costophrenic angle was seen in 5 cases (25%).

According to A.J. Greenstein, D. Lowenthal, G,S. Hammer, F. Schaffner and A. H. Aufses, elevation of right hemidiaphragm was seen in 40% of cases and right pleural effusion in 24% of cases.

**Table 23: USG Findings of liver Abscess**

	Present study		Bhagwan satiani et al
	No of cases	%	
Right lobe	14	70	79
Left lobe	3	15	5
Both lobe	3	15	16

Ultrasound abdomen was done to all patients in this study. In the present study right lobe was involved in 70% of cases. This is in accordance with the study concluded by Bhagwan Satiani et al who recorded 79% involvement in right lobe.

In present study left lobe and both lobes were involved with equal incidence I 5%.In the study conducted by Bhagwan Satiani et al, left lobe was involved in 5% and both lobes in 16% cases.

**Table 24 : USG Findings of liver Abscess**

	Present study		Chaturbhuj Lal Rajak et al
	No of cases	%	
Solitary	16	80	72
Multiple	4	20	18

In the present study solitary abscess and multiple abscesses were present in 16/20 (80%) and 4/20 (20%) cases respectively. This is in accordance with the study conducted by Chaturbhuj Lal Rajak et al who recorded 72% solitary and 18% multiple abscess.

#### **Analysis of treatment**

Surgical drainage of liver abscesses has been an accepted therapy for decades. The diagnosis and treatment of liver abscess has changed due to advances in imaging techniques.

In the present study of 20 cases patients who had multiple small abscess and solitary abscess with volume <50 ml were treated conservatively. The conservative management was done on 7/20 (35%) cases. All cases were started on metronidazole IV. at a dose of 40 mgm/kg/wt (2.0 —2.5gm/day in divided doses X 8-10 days). When patients did not show improvement in 24-48 hrs of metronidazole therapy, broad spectrum 3 generation cephalosporins were

started as well. Amoebic serology was not routinely performed as it was not available in our hospital and due to financial restraints.

According to Hiroshi Okano, Katsuya Shraki percutaneous aspiration is not required in all cases of liver abscess. A subset of cases with small liver abscess < 300 cc can be successfully managed conservatively.

In 12/20 patients who had abscess >50 cc were chosen for percutaneous aspiration. The site, depth and direction of aspiration was marked under USG guidance 18G spinal needle was usually used and under aseptic precautions the abscess cavity was entered. Local anaesthetic was used pus was aspirated and sent for culture and sensitivity no complications were noted due to this procedure apart from local pain which soon subsided after analgesics. Patient showed dramatic improvements in their symptoms and signs within 48-72 hrs of the aspiration. Percutaneous catheter Drainage was not done on any patient in this study. Laparotomy as the initial line of treatment was performed in 1/20 (5%) of cases of liver abscess. On laparotomy, thorough peritoneal lavage and drains were kept.

According to Arshed Zafar, Sajjad Ahnied<sup>o</sup> “needle aspiration is safe, rapid effective method of treating liver abscess. Routine aspiration is not indicated. It should be initial line of treatment in abscess > 300 cc, impending rupture or abscess that do not respond to chemotherapy.

According to Antonia, Giorgio, Lucien Turuntino percutaneous needle aspiration is an efficient effective and low cost technique that can even be performed on an out patient basis. It is safe, free from complication.

### **Analysis of Repeat Aspirations**

A Single aspiration was sufficient in 10/12 (83.3%) of cases while in 2/12 (16.2%) aspirations were required. Thick viscous pus was the main reason for repeat aspirations.

According to Chaturbhuj Lal et al, in their study on liver abscesses found that single aspiration was successful in 88% of cases while 10% required 2 aspirations.

### **Discussion of complication**

The type of complication in our study were ruptured into peritoneal cavity and pleural effusion. One case presented with peritonitis for which laparotomy was done and peritoneal lavage was given. Septicemia with multiorgan dysfunction was seen in 1 case.

According to Khee Siang Chan, chin Ming et al, mortality rate in their study was 6.5%.

## CONCLUSION

Liver abscess is a very common condition in India. India has 2 highest incidence of liver abscess in world. Hence the need for the present clinical study of liver abscess.

Liver abscesses occurred most commonly between 30-50 years. Males were affected more than females. Fever was the most consistently occurring symptom. Pain abdomen was the next most frequent symptom. Alcohol consumption was the single most important predisposing factor for causation of liver abscesses. Alkaline phosphatase is the most consistently elevated, abnormal liver function test in cases of liver abscesses. Liver abscess usually present as a solitary abscess most commonly in the right lobe of liver. Not all cases of liver abscesses need invasive management. Multiple small abscesses and solitary abscess <50cc can be managed successfully on conservative antimicrobial therapy alone.

Liver abscess is still a disease associated with considerable mortality and morbidity. Intraperitoneal rupture, septicemia, death are the complications that can occur. Mortality rate in this study was 5%.

**Discussion for risk factors:**

In this study, age > 60 yrs, alcohol consumption, jaundice, anaemia, cough, diabetes mellitus, pleural effusion, hypoalbuminemia were associated with protracted and longer durations of symptoms, longer time of resolution of symptoms and longer duration of stay. They were also associated with higher incidence of morbidity and mortality. Hence these factors are associated with worse prognosis.

## SUMMARY

The study was carried out at the Department of Surgery, Government Rajaji Hospital, Madurai. Nov. 2006 to Oct. 2007 during which 20 patients presented with symptoms suggestive of liver abscesses.

- In the present study, the highest incidence occurred in the age group 31-50 yrs (50%), males were more commonly affected than females.

- Subacute onset of symptoms (7 days — 2months) was the commonest presentation (65%). Fever was the most consistently occurring symptom occurring in 95% of cases. Pain abdomen was the next most common symptom (90%) Diarrhoea occurred only in 30% of cases. Hepatomegaly was present in 60% of cases. Jaundice was found in 30% of the cases. Respiratory findings in the form of pleural effusion were present in 25% of cases. This study found the single most consistent etiological factor in all patients of liver abscess included under present study, 85% of cases consumed alcohol. All these cases mostly consumed locally made arrack All these patients had history of alcohol consumption more than 1 year.

- Thus it may seem likely that alcoholism may predispose to formation of liver abscesses. Further although not investigated in this present study, it may be hypothesized that these locally made drinks may be contaminated with *entamoeba histolytica*.



- Laboratory investigations were analyzed. Leucocytosis was found in 85% of cases. Anaemia in 30% cases 10% of cases were found to be diabetic. Raised urea levels were seen in 15% of cases. Alkaline phosphatase was the single most consistent liver function test to be abnormal in cases of liver abscesses. It was raised in 70% of cases. Hypoalbuminemia was noted in 10% of cases.

- Chest X-ray was abnormal in 5 patient, right pleural effusion was noted i.e. 25% of cases. Ultrasonography revealed solitary abscesses in 80% of cases and multiple abscesses in 20%. Isolated right lobe abscess was seen in 70% and left lobe abscess in 15%. Both lobe involvement was seen in 15% of cases.

- Cases who had multiple small abscesses and solitary abscesses < 50 cc were managed conservatively. All patients responded well to conservative management 7/20 (35%) were managed conservatively. While 12/20 (60%) were subjected to percutaneous aspiration, 1/20 (5%) required laparotomy. 10/12 (83%) required single aspiration, while 2/12 (16.2%) required 2 aspiration.

- 1/20 (5%) of cases died due to liver abscesses in this study giving a mortality rate of 5%.

## LIST OF ABBREVIATIONS

A:G ratio	-	Albumin : Globulin ratio
ALA	-	Amebic liver abscess
ALP	-	Alkaline phosphatase
AST	-	Aspartate Amino Transferase
C/s	-	Culture and sensitivity
CXR	-	Chest X-ray
E.Histolytica	-	Entamaeba histolytica
HA	-	Haemeagglutinin
LFT	-	Liver function tests
No	-	Number
PA	-	Postero anterior
PCD	-	Percutaneous catheter drainage
PLA	-	Pyogenic liver abscess
PNA	-	Percutaneous needle aspiration
PT	-	Prothrombin time
USG	-	Ultrasonograpahy

## ***ABSTRACT***

**OBJECTIVES:** To analyse the clinical profile, diagnosis and management of liver abscesses.

**MATERIALS AND METHODS:** A prospective study of twenty patients (19 male; 1 female; Age range of : 25-62 years with a mean age of 42 years) with liver abscesses were studied for their clinical profiles diagnosis and management. The study was carried out for one years from Nov. 2006 to October 2007. 7/20 (35%) patients were managed conservatively. 12/20(60%) patients underwent percutaneous aspiration. Laparotomy was done on 1/20 (5%) cases.

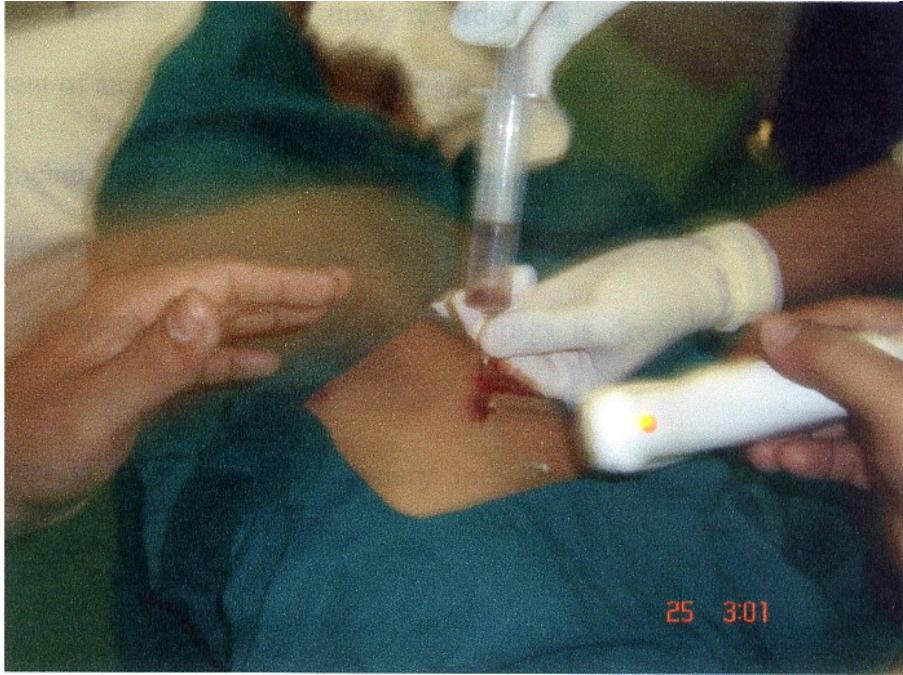**RESULTS:** Liver abscess most commonly occurs between 31-50 years. Males were affected more than females. Fever was the most consistently occurring symptom (95% of cases). Alcohol consumption was the single most important etiological factor for causation of liver abscess. Alkaline – phosphatase is the most consistently elevated, abnormal liver function test (70% of cases). Most liver abscess present on solitary lesions (80%) in right lobe (70%). Multiple small abscess and solitary abscess <50 cc were managed successfully on conservative line of management. Mortality rate was 5%.

**CONCLUSION:** Liver abscess is a common condition in India. It is still a disease associated with considerable mortality. Intraperitoneal rupture,

septicemia and death are the conditions that can occur. Alcoholism especially consumption of locally made Arrack is an important risk factor for causation of liver abscess.

Multiple small liver abscess and solitary liver abscess <50 cc can be successfully managed on conservative line of management with antimicrobials. Percutaneous needle aspiration is safe and highly effective method of managing liver abscesses Advanced age, local arrack consumption, jaundice, diabetes mellitus, hypoalbuminemia, are associated with poorer prognosis.

Keywords: Liver abscess ; alcoholism,



**FIG. 1 : LIVER ABSCESS BEING ASPIRATED**



**FIG . 2 : TYPICAL 'ANCHOVY SAUCE' PUS**

## BIBLIOGRAPHY

- 1) Ochsner, A. DeBakey M, and Murray S: Pyogenic abscess of the liver. AMJ Surg. 1938; 40: 292.
- 2) Pitt, F-l.A. and Zuidema, G.D. Factors influencing mortality in the treatment of hepatic abscess, Surg, Gynecol Obstet, 1975; 140: 228.
- 3) Huang C. J, Pitt. H. A. Lipsett, P. A. : Pyogenic hepatic abscess Ann. Surg. 1996; 223: 600.
- 4) Shaman JD, Robbins SL. Changing trends in Causation of hepatic abscess, American Journal of Medicine 1960; 28: 943-950.
- 5) Branum GD, Tyson GS, Hepatic abscess: Changes in etiology, diagnosis and management, Annals of surgery 1990; 212: 655-662.
- 6) Seeto RK, Rockey DC, Pyogenic liver abscess; Changes in etiology, management and outcome medicine, Journal of Medicine 1996; 75: 99-113.
- 7) Chen, C. Chen, P.J. Yang P.M. Clinical and microbiological features of liver abscess after transarterial embolization for hepatoccl lular carcinoma. Am. .1. Gastroenterol, 1997; 92: 2257.
- 8) Lee, .1. F. and Block, G. E. The changing clinical pattern of hepatic abscess. Arch. Surg. 1972; 104: 465.

- 9) Sabbj .1. Sutter YL, Finegold SM : Anaerobic liver abscess. Ann. Intern Med. 1972; 77: 629.
- 10)hO. Bordine WN, Schwartz SL, Pyogenic hepatic abscess. NY Staff .1. Med 1973; 73: 1657.
- 11) Robertson RD, Foster JH, Peterson CG. Pyogenic liver abscess studies by cliolangiography : Cases report and 25 yr. review. Am Surg 1966; 32: 521.
- 12)Trump DL, Fahnenstock J Clouteier CT, Dickman MD: Anaerobic abscess and intrahepatic metastases. A case report and review of literature, cancer 1978; 41: 682.
- 13) Jochimsen PR, Zinke WL, Shirazi SS, Pear NW; Jatrogenic liver abscess. Arch Surg. 1978; 113: 141.
- 14) Matthews TB, Gertsch P, Baer HV, Blumgart LH, Hepatic abscess after biliary tract procedure, Surg Gynecol, obstet, 1990; 170: 469.
- 15)Altemeier WA, Schowengerdt CG, 'Whitely DH : Abscesses of the liver: Surgical conisiderations, Arch Surg 1970; 101: 258.
- 16) Gunnarson G, Fredman LS, Liver abscess due to staphylococcus aureus in a patient with AIDS who underwent bowel biopsy, Clinical Infections Diseases 1994; 18: 802-804.
- 17) Kinney TD, Fei-rebee 1W; Hepatic abscess; Factors determining its localization. Arch Pathol 1948; 45: 41.

- 18) Serege H. Contribution a letude de La circulation dujang fort dans le foie localization lobaires hepatiche J. Med Bord 1901; 31: 208,217,291,312.
- 19) Gyorffy EJ, Frey CF. Pyogenic liver abscess. Ann Surg 1987; 206: 699.
- 20) Onderdonk A, Bartlett J, Louis T, Micrubial synergism in experimental intra abdominal abscess. Infect immune 1976; 13; 22.
- 21) Satiani, B. and Davidson ED Hepatic abscesses Improvement 1 mortality with early diagnosis and treatment. Am. J. Surg. 1978; 135: 647.
- 22) Thakur ML, Coleman RE, Welch MJ.: Indium —111 labeled Ieukocytes for the localization of abscesses; preparation, analysis, tissue distribution, and comparison with gallium — 67 Citrate in dogs, I. lab din med 1977; 89: 217.
- 23) Adatepe MH, Welch M, Evens RG, Potchen EI, Clinical Application of the broad. Spectmm scarming agent — indium I 3m Am I. Roentgenol RadiothrNucl Med 1971; 112: 701.
- 24) Balasegaram M. Management of hepatic abscesses. Cuff. Prob Surg 1981; 18; 282.
- 25) Verlenden, W.L., 3” and frey, CF. Management of liver abscess. Am. J. Surg. 1980; 140: 53.



- 26) Barreda R. and Ros P.R., Diagnostic imaging of liver abscess Crit, Rev Diagn imaging 1992; 33: 29.
- 27) Gerzof SG, Johnson WC, Robbins AH, Nabseth DC: Intrahepatic Pyogenic abscesses, treatment by percutaneous drainage. Am J. Surg 1985; 149: 487.
- 28) Mc Donald M Corey OR, Gallis HA, Duract DT: Single and multiple pyogenic liver abscesses. Medicine (Baltimore) 1984; 63: 291.
- 29) Neoptolems JP, Macpherson DS, I-loim J. Fossard DP: Pyogenic liver abscess, a study of forty four cases in two centers. Acta Chir scand 1982; 148: 415.
- 30) Mc Fadzean JS, Chang JCPS, Wong CC Solitary Pyogenic abscess of the liver treated by closed aspiration and antibiotics Br. J. Surg 1953; 41:141.
- 31). Kuligowska E, Connors SK, Shapiro JH : Liver abscess sonography in diagnosis and treatment AiR 1982; 138: 253.
- 32) Halvorsen NA, Korobkin M. Foster WL, The variable CT appearance of hepatic abscesses. AJR 1984; 142: 941.
- 33) Levitt, RU, Sagel 55, Stanley K Accuracy of computerized tomography of the liver and biliary tract. Radiology, 1977; 124: 123.
- 34) Hau T, Nishikawa R. Danziger LH: Antibiotics in surgery Surg Ann 1983; 15: 177.

- 35) Meidema EW, Dineen P. The diagnosis and treatment of pyogenic liver abscess. *Annals of surgery* 1984; 200: 328-335.
- 36) Lee KT, Sheen PC, Chen JS, Ker CU, Pyogenic liver abscess, Multivariate analysis of risk factors. *World J. Surgery* 1991.
- 37) Bergec LA, Osborne DR. Treatment of pyogenic liver abscesses by percutaneous needle aspiration. *Lancet*. 1982; 132.
- 38) Herbert DA, Rothinan 3, Simmons F, Pyogenic liver abscesses. Successful nonsurgical therapy *Lancet* 1982; 1: 134.
- 39) Donovan AJ, Yellin AE, ralls PW, hepatic abscess. *World J. Surg* 1991; 15: 162.
- 40) Bertel C. K. Van Hauden JA. Treatment of Pyogenic hepatic abscess, surgical Vs percutaneous drainage. *Archives of surgery* 1986; 121: 554-558.
- 41) Wong KP. Percutaneous drainage of pyogenic liver abscesses. *World Journal of surgery* 1990;14:492-497.
- 42) Karatasas A, William JA. Review of pyogenic liver abscesses at royal Adeliade Hospital. *Journal of Surgery* 1990, 60: 893-897.
- 43) Rintoul R, Lawensen, Changing management of pyogenic liver abscess, *British Journal of Surg* 1996;83: 1215-1218.
- 44) Stain SC, yellin A, Pyogenic liver abscess. *Archirves of surgery* 1991; 126: 991-995.

- 45) Chu KM, Fan ST, Hai EC. Pyogenic liver abscess, Audit of experience over past decade, Archives of surgery, 1996; 131(2) : 148-52.
- 46) Rajak CL, Gupta S. Jain S. Percutaneous treatment of liver abscess Needle aspiration versus catheter drainage. American Journal of Roentgenology 1998; 170: 1035-1039.
- 47) Tazawa J. Sakai, Mackawa, Solitary and Multiple liver abscesses. American Journal of Gastroenterology 1997; 92: 272-274.
- 48) Ghou. F. Sheen Chen, Tai DI, prognostic factors for pyogenic liver abscess 1994; 179: 727-732.
- 49) Do H, Lambiase RE, Deyoel, Cronan H, percutaneous drainage of hepatic abscess. American journal of Roentgenology 1991;157: 1209-1212.
- 50) Capucino H, Campunile F. laparoscopy guided drainage of hepatic abscess. Surgical laparoscopy and endoscopy 1994; 4: 234-237.
- 51) Mischinger JH, Jauser H. Pyogenic liver abscess, studies of therapy and risk factor world journal of surgery 1994; 18: 852-858.
- 52) Losch FA Massive development of amebas in the large intestine (Translated from the original) Am J trop med Hyg. 1975; 24-383.
- 53) Koch R, Gaffky G, Bericht uber die. Thatigkeit der zur Erforschung der cholera in jahre 1883 nach Egypten Und Indian Estandton Kommission. Arb Kaisere Ges 1887; 3:1.

- 54) Kartulis S. Zur Aetiologic der Dysenteric in aegypten. Arch Pathol Anat 1886; 105: 521.
- 55) Osler W. on the amoeba coli in dysentery and in dysenteric liver abscess Bull Johns Hopkins hosp 1890; 1: 53.
- 56) Simon CE, Abscess of liver : perforation into the lung Amoeba coli in sputum, Bull Johns Hopkins Hosp 1980; 1: 97.
- 57) Walker EL, Sellard, AW. Experimental entamoebic dysentery Philippine J Sci 1913; 8 : 253.
- 58) Rogers L. The rapid cure of amoebic dysentery and hepatitis by hypodermic injections of soluble salts of emetine, Br Med J. 9Clin Res) 1912; 1 : 14.
- 59) Conan NJ. The treatment of amobic hepatitis with choloroquine. Bull NY Acad Med 1984; 24: 545.
- 60) Conona NJ. Chloroqu ine in amebiasis, Am J. trop med 1948; 28: 107.
- 61) Ravdin JI, Guerrant RL. Role of adherence in cytopathogenic mechanisms of entamaoeba histolytica J. Clin Invest 1981; 68: 1305-13.
- 62) Petri W.A. Smith RD. Schlesinger DH, Isolation of the galactose binding lectin which mediates the in vitro adherence of E. histolytica J. Clin Inveser 1987; 80: 1238-41.

- 63) Young J E. Young TM, Lulp. Characterization of membrane port forming protein from entamoeba histolytica J. Exp. Med 1982; 156 : 1677-90.
- 64) Bray RS, harris WG. The epidemiology of infection with Entamoeba histolytica in the Gambia, West Africa, Trans R. Soc trop med hyg 1977; 71: 401.
- 65) Walsh JA, Prevalence of Entamoeba histolytica infection in Ravdin JI ed. Amebiasis, Human Infection by Entamoeba histolytica. New york, Churchill livingstone 1988 ; 93-105.
- 66) Krugstad DJ, Spencer HC, healy GR, Amebiasis epidemiologic studies in the United States 1971-1974. Ann intern med 1978; 88:89.
- 67) Kean BH, William DC, Luminais SK. Epidemic of amoebiasis and giardiasis in a biased population. Br. J. venet Dis 1979; 55: 375.
- 68) Pomerantz BM, Marr JS, Goldman WD, amoebiasis in New york city, 1958; identification of the male homosexual high risk population Bull Ny Acad Med – 1980; 56-232.
- 69) Mosh. H. Manhattan A Tropical isle. Am. J. Trop Med hyg 17: 333, 1968.
- 70) Allason – Jones E. Mindel A, Sargeant P, Katz D, Outcome of untreated infection with Entamoeba histolytica in homosexual men with and without HIV antibody : Br Med J 1988; 297: 654.

- 71) Gurrent RL, The Global Problem of Amebiasis, current status review of infection diseases, 1986; 8 : 218-227.
- 72) Salat R A. Immune mechanisms against entamoeba histolytica Review of infections disease 1986; 8: 261-272.
- 73) Aikat BK, Bhusmurmath SR, Pal AK, et al. The pathology and pathogenesis of fatal hepatic amoebiasis, A study based on 79. Autopsy cases, trans R Soc trop Med Hyg. 1979; 73: 188-92.
- 74) Gulati PD, Gupta DM, Chuttani HK, Amoebic Liver abscess and disturbances of portal circulation.
- 75) Braga LL, Ninomiya H, Mc Coy JJ, Inhibition of complement membrane attack complex by the galactose – specific adhesion of entamoeba histolytica, J clin invest 1992 ; 90: 1131-7.
- 76) Abuabara SF, Barrett JA, Haut, Jonasson O. Amebic liver abscess Arch surg. 1982; 117-239.
- 77) Krettek JE, Goldstein LI, Busuttil RW. The symptoms of an Amebic abscess of the liver simulating an acute surgical abdomen. Surg Gynecol obstet 1979; 148: 552.
- 78) McDermott VGM. Question and Answers : what is the role of percutaneous drainage for treatment of Amebic abscess of liver. American Journal of Roentgenology, 1995; 165: 1005-1006.

- 79) Monga NK, Sood S, Kaushik S, Amoebic peritonitis, American Journal of Gastroenterology 1976; 66 : 366-373
- 80) Saida AK, Bal S, Sharma AK. Influence of geographic factors in distribution of Entamoeba. Transactions of Royal society of tropical medicine and hygiene 1984; 78: 96-101.
- 81) Finegold SM Metronidazole. Ann. Intern med 1980; 93: 585.
- 82) Chowcat NL, Wyllie JH, Intravenous metronidazole in amoebic enterocolitis, Lancet 1976; 2 : 1143.
- 83) Gall Sa, Edmisten C, vermon RP, intravenous metronidazole in treatment of ruptured amebic liver abscess. South Med J. 1980 ; 73: 1274.
- 84) Kovaleski T, Malangoni MA, Wheat LJ. Treatment of an amebic liver abscess with intravenous metronidazole. Arch Intern med 1981; 141: 132.
- 85) Cohen HG, Reynolds TB, Comparison of metronidazole and chloroquine for the treatment of amebic liver abscess. Gastroenterology 1975; 69: 35.
- 86) Bhagwan Satiani, Eugene D, Davidson, American, Journal Sug. 1978; 135: 647-50.
- 87) Walter D Gaisford, James BD, Mark, American Journal Surgery 1969; 118: 317-326.

- 88) A.J. Greenstein D. Lowenthal B.A. G.S. Hammer, F. Schaffner and A.H. Aufses. Am. Journal gastroenterology 1984, 79: 217-226.
- 89) Rubin R. H. Swartz MM, Malt R. Hepatic Abscess. Changes in clinical bacterologic and therapeutic aspects. Am J med 1974; 57: 601-10.
- 90) Khee Sian, Chin Ming. Liver Abscess – A retrospective study of 107 patients during 3 years. 2005; 58: 366-368.
- 91) Shyam Mattur, Gehlot RS, Alok Mehta. Liver abscess. Journal of Indian Academy of clinical Medicine 2002; 3(4) : 78-79.
- 92) Chaturbhujlal Rajak, Sanjay Gupta, Yogesh Chowla. Percutaneous treatment of liver abscess. American Journal of Roentgenology 1998; 170: 1035-1039.
- 93) Hiroshi Okano, KatSuya, Shikari. Clinico pathological analysis of liver abscess in Japan. International Journal of Molecular Medicine 2002; 10: 627-630.
- 94) Sajjad Ahmed, Arshad Zafar. Liver abscess. Journal of Medical College, Ayub Medical College, Abbotabad 2002; 14 (1) : 10-12.
- 95) Antonio Giorgio, Luciano Torantrno, Nicola Maemiello. Pyogenic liver abscess: 13 years of experience in percutaneous needle aspiration with USG guidance. Journal of Radiology 1995; 122-124.



## ANNEXURE

### PROFORMA

Patient's Name : Address :  
Age : Hospital :  
Sex : Ward No :  
Occupation : Unit :  
Locality : Urban / Rural D.O.A :  
Religion : D.O.D :  
Duration of stay in hospital : Socio economic status:

#### **CHIEF COMPLAINTS :**

#### **HISTORY OF PRESENTING ILLNESS:**

##### **Symptoms**

##### **1. Abdominal Pain : Yes / No**

- Duration :
- Site :
- Character :
- Radiation :

##### **2. Fever : Yes / No**

- Duration :
- Type :
- Associated with chills and rigors :

**3. Diarrhoea / Dysentery :**

- Duration :
- Mucous diarrhea :
- Blood in stools :

**4. Vomiting :**

- Duration / Frequency :
- Color :

**5. Jaundice : Yes / No**

**6. Cough : Yes / No**

**7. Distension of abdomen: Yes / No**

**8. Altered Sensorium : Yes / No**

**9. Any Other :**

**PAST HISTORY**

Diarrhea : Yes / No

Jaundice : Yes / No

Diabetes : Yes / No

Tuberculosis : Yes / No

Surgery : Yes / No

Trauma : Yes / No

**FAMILY HISTORY :**

Similar illness :

Other :

**PERSONAL HISTORY :**

**ALCOHOL CONSUMPTION:**

Duration	
Type	TODDY / LOCAL ARRACK : Yes / No
Amount	

Smoking :

Appetite :

Sleep :

Bowel and Bladder :

**TREATMENT HISTORY :**

**GENERAL PHYSICAL EXAMINATION :**

Build :

Gynacomastia :

Nourishment :

Spider naevi / palmar erythema :

Pallor : Flapping tremors:

Cyanosis : Skin / Hair :

Jaundice : Nails :

Clubbing :

Lymphadenopathy :

Height : cms

Weight : kgs

Pulse : per minute

B.P. : mm of Hg

Respiration : per minute

Temperature : centigrade

### **LOCAL EXAMINATION :**

### **PER ABDOMEN:**

### **INSPECTION :**

1. Shape : Scaphoid / flat / distended / obese
2. Distended veins : Present / absent
3. Umbilicus :
4. Movements :

- Respiration
- Peristaltic
- Pulsatile

5. External hernial orifices :

6. Scrotum:

7. Left supraclavicular lymph node:

**PALPATION :**

1. Tenderness : Present / Absent

2. Rigidity : Present / Absent

3. Liver : Palpable / non palpable

Upper limit of percussion in rt MCL : LCS

Lower limit of percussion below costal margin: cms

Liver span : cms

Borders : sharp / rounded

Surface : Smooth / Nodular

4. Spleen : palpable / Non palpable

5. Scrotum / Testes :

6. Left supraclavicular lymph node:

**PERUSSION :**

1. Fluid thrill : Present / Absent
2. Shifting dullness :

**AUSCULTATION**

1. Bowel Sounds : Present / Absent
2. Bruit or rub over liver : Present / Absent

**RESPIRATORY SYSTEM :**

1. Shape and expansion of chest :
2. Air entry :
3. Breath sounds :
4. pleural effusion : Present / Absent

**CARDIOVASCULAR SYSTEM :**

**CENTRAL NERVOUS SYSTEM :**

**PER RECTAL EXAMINATION :**

**PROVISIONAL DIAGNOSIS :**

## **INVESTIGATIONS:**

### **1. Blood :**

Hb : gm%

T.C. : c/cmm

D.C. : N%, L%, E%, M%, B%

ESR : mm/hr

CT : min

BT : min

Prothrombin time : Sec

INR :

FBS : mg%

Blood urea : mg %

Serum creatinine : mg%

### **2. Urine :**

Albumin :

Sugar :

Microscopy :

### **3. Stool :**

Ova / cyst :

Occult blood :

## **SPECIAL INVESTIGATIONS:**

### **Liver Function Tests:**

1. Serum Bilirubin :           mg%
2. Direct :
3. Indirect :
4. Albumin :                gm%
5. Total proteins :    gm%
6. A:G ratio :
7. Alkaline phosphatase :   IU/L
8. S.G.O.T.                 IU/L
9. S.G.P.T.                 IU/L
10. PT :                     IU/L

Ascitic / pleural fluid analysis

## **RADIOLOGICAL INVESTIGATIONS:**

1. Plain X-ray Chest PA view :
2. Plain X-ray abdomen erect :

### **3. ULTRASONOGRAPHY ABDOMEN :**

**OTHER INVESTIGATIONS :**

**CLINICAL DIAGNOSIS :**

**TREATMENT :**



**MEDICAL TREATMENT:**

**SURGICAL TREATMENT**

**COMPLICATIONS :**

Early :

Late post operative :

**FOLLOW UP :**

**COMMENTS:**

## KEY TO MASTER CHART

-	-	Absent
+	-	Present
ALP	-	Alkaline Phosphatase
BT	-	Both lobes
CxR	-	Chest X-ray
DOA	-	Date of Admission
DR/DY	-	Diarrhoea / Dysentery
DUR	-	Duration
FVR	-	Fever
Hb	-	Hemoglobin
LT	-	Left lobe
Mul	-	Multiple abscess
NRA	-	No radiological abnormality
PA	-	Pain Abdomen
PT	-	Prothrombin time
RBS	-	Random blood sugar
REC	-	Recurrence
RPE	-	Right pleural effusion
RT	-	Right lobe
S. Alb	-	Serum Albumin
S. Bili	-	Serum bilirubin
Total Asp	-	Total No. of aspirations
WBC	-	White blood count

## MASTER CHART

Sl.No	Name	Age	Sex	IP.No	DOA	PA	FVR	DR/DY	Alcohol	Icterus	Liver span	PI/EH	Hb%	WBC	RBC	Urea	S.Bil	ALP	Alb	SGOT	SGPT	PT	CxR	USG Lobe	USG Volume	Treatment	Complication	DUR	REC	Total Asp	Culture & Sensitivity
1	Krishnan	51	M	29355	12/12/2006	+15	+	+	+	+	16	+	10.5	13700	115	19	3.2	204	3.2	30	30	14	RPE	RT	35	Conservative	-	8	-	-	-ve
2	Loganathan	55	M	30453	26/12/06	+2	+	-	+	+	10	-	9.8	12500	50	40	3.9	206	3.7	31	32	22	NRA	RT	45	Conservative	-	10	-	-	-ve
3	Raghunathan	62	M	1548	21/1/07	+20	+	+	+	-	16	-	11	13400	204	23	1.1	200	3	30	38	15	NRA	RT	270	Aspiration	-	14	-	1	-ve
4	Palpandi	60	M	4027	18/02/07	+60	+	-	+	+	10	-	13	12000	213	24	4.1	450	3.4	22	18	18	NRA	BT	mul	Conservative	-	18	-	-	-ve
5	Mohammed Rabi	45	M	27870	27/02/07	+8	+	-	-	+	16	-	11.4	12500	135	53	3	369	3.2	61	55	16	NRA	RT	320	Aspiration	-	10	-	1	-ve
6	Pothum Ponnuru	30	F	5204	4/3/2007	+10	+	-	-	+	11	-	9.2	9400	110	20	4.1	370	3.1	74	70	12	NRA	RT	350	Aspiration	-	14	-	1	-ve
7	Sanhuthavar	26	M	5591	12/3/2007	+6	+	-	+	-	11	+	10.2	14000	118	33	0.6	126	3.8	36	38	10	RPE	RT	mul	Surgical Drainage	Peritonitis	20	-	-	-ve
8	Muthuraman	54	M	6271	15/03/07	+3	+	-	-	+	18	-	10.2	12400	50	67	3.1	380	2.9	72	98	14	NRA	RT	420	Aspiration	-	12	-	1	-ve
9	Jeganathan	56	M	7566	30/03/07	+5	+	-	+	-	16	-	10.6	12500	116	25	1.7	520	3.2	25	20	10	NRA	RT	350	Aspiration	-	10	-	1	-ve
10	Manjunathan	35	M	7311	31/03/07	+7	+	+	+	-	18	-	9	9750	85	16	1.9	740	3.9	128	78	16	NRA	LT	600	Aspiration	-	20	-	1	-ve
11	Subramani	48	M	14491	19/06/07	+30	-	+	+	-	16	-	11.6	12000	104	23	1.2	490	7.1	71	78	15	NRA	RT	720	Aspiration	-	30	-	2	-ve
12	Laxmanan	30	M	13000	31/06/07	-	+	-	+	-	10	-	12.6	12200	114	23	1.4	143	7.3	22	19	16	NRA	RT	40	Conservative	-	7	-	-	-ve
13	Ramesh	40	M	23492	2/7/2007	+15	+	+	+	-	18	-	9.8	12700	172	70	3.1	570	2.7	25	19	10	NRA	RT	900	Aspiration	Septicemia	14	-	2	Non fer gram -ve
14	Raman	39	M	11760	16/07/07	+15	+	-	+	+	18	+	10.2	9200	57	66	7.2	580	5	93	98	12	RPE	BT	mul	Conservative	-	14	-	-	-
15	Somasundaram	40	M	14712	21/7/07	+4	+	-	+	+	11	+	12	17800	82	20	0.6	109	3.5	20	16	14	RPE	RT	450	Aspiration	-	10	-	1	-ve
16	Karuppan	34	M	24562	16/8/07	-	+	-	+	-	11	-	13.6	12300	80	32	1.1	476	3.8	32	36	18	NRA	LT	45	Conservative	-	8	-	-	-
17	Ravi	25	M	28174	29/8/07	+8	+	-	+	-	14	-	10.8	9200	84	31	1.2	162	3.6	39	43	12	NRA	RT	300	Aspiration	-	8	-	1	Staph aureus
18	Manickam	45	M	21970	5/10/2007	+7	+	-	+	-	10	-	12	15600	90	38	1.6	570	5	32	32	12	NRA	RT	350	Aspiration	-	5	+	1	-ve
19	Kathavarayan	46	M	24140	20/10/07	+4	+	-	+	-	11	-	9.2	12000	110	40	1.1	380	4.8	33	36	16	NRA	LT	250	Aspiration	-	10	-	1	-ve
20	Rajappan	35	M	27344	23/10/07	+7	+	-	+	-	16	+	8.8	16000	110	36	1.2	776	3.6	28	36	16	RPE	BT	mul	Conservative	-	10	-	-	-