

**A COMPARATIVE STUDY OF ONLAY MESH REPAIR
(LICHTENSTEIN'S) AND LAPAROSCOPIC
TOTALLY EXTRA PERITONEAL MESH REPAIR IN THE
TREATMENT OF INGUINAL HERNIA**

Dissertation submitted for

**M.S. BRANCH - I
GENERAL SURGERY**

SEPTEMBER 2006



**DEPARTMENT OF GENERAL SURGERY
MADRAS MEDICAL COLLEGE
THE TAMIL NADU DR. M.G.R. MEDICAL
UNIVERSITY**

CHENNAI

CERTIFICATE

This is to certify that Dr. T. Sakthivel prepared his dissertation entitled “**A COMPARATIVE STUDY OF ONLAY MESH REPAIR (LICHTENSTEIN’S) AND LAPAROSCOPIC TOTALLY EXTRA PERITONEAL MESH REPAIR IN THE TREATMENT OF INGUINAL HERNIA**” to be submitted to the Tamil Nadu Dr.M.G.R. Medical University in partial fulfillment of the requirement of the award of the Degree of Master of Surgery (General Surgery) September 2006 under my supervision and guidance. This dissertation is original and no part of this study has been submitted for the award of any other degree or diploma.

Prof. P.G. KOLANDAIVELU M.S.,
Professor & Head,
Department of General Surgery,
Surgery,
Madras Medical College
Chennai – 600 003

Prof. V. PARI M.S.,
Professor of Surgery,
Department of General
Surgery,
Madras Medical College
Chennai – 600 003

Dr. KALAVATHY PONNIRAIVAN B.Sc., M.D. (Bio)
DEAN,
Madras Medical College, Chennai – 600 003

ACKNOWLEDGEMENT

I would like to convey my sincere thanks to **Dr. KALAVATHY PONNIRAIVAN B.Sc., M.D (Bio)**, Dean, Madras Medical College, Chennai for permitting me to conduct the study at Government General Hospital, Chennai.

It is a proud privilege to express my heartfelt thanks and indebtedness to my enthusiastic and inspiring Chief **Prof. V. PARI M.S.**, without whom this study would not have been possible.

I have great pleasure in acknowledging the help rendered by **Prof. P.G. KOLANDAIVELU M.S.**, Head of the Department, Department of General Surgery, Madras Medical College, Chennai for allowing me to conduct the study.

I would like to offer my sincere thanks to my Assistant Professors **Dr. DEEPAK KABIR M.S, D.N.B., Dr.R.KARUNANITHI M.S, Dr. U. NIRMALA M.S., Dr. D. TAMIL SELVAN M.S.**, and colleagues of our unit for their help and co-operation rendered for conducting the study.

I also very grateful and indebted to my patients without whom this study would not have been possible.

INDEX

	<i>PAGE NO.</i>
1. INTRODUCTION	I
2. AIM OF THE STUDY	2
3. REVIEW OF LITERATURE	3
4. MATERIALS AND METHODS	36
5. OBSERVATION AND RESULTS	45
6. CONCLUSION	52
7. MASTER CHART	54
8. REFERENCES	58

INTRODUCTION

Inguinal hernia is one of the most common general surgical problems. It has an incidence of 10-15% in adults. The male/female ratio is 12:1. The incidence varies with age - in fullterm babies it is between 10-20/1000. In preterm infants it is much higher between 7-12%. Treatment for inguinal hernia has been constantly evolving starting from the earliest surgery through a scrotal incision to the present day laparoscopic preperitoneal mesh repair. Two of the procedures commonly used today are

1. Tension free mesh repair - onlay or
2. Laparoscopic Hernioplasty – TAPP (or) TEPP.

In this study a comparison has been done between the open and Laparoscopic mesh repair (TEP) techniques in patients with inguinal hernia who presented to the department of General Surgery at Government General Hospital, Chennai during the past two years. The literature regarding this is also reviewed and discussed.

AIM OF THE STUDY

To compare the results of Onlay (Lichtenstein's) and Laparoscopic totally extra peritoneal mesh repair in the treatment of inguinal hernia in terms of

1. Post operative pain
2. Analgesic requirements
3. Nerve entrapment & its sequelae
4. Cord oedema
5. Orchitis
6. Scrotal oedema
7. Recurrence

in patients who presented to the department of General Surgery at Government General Hospital, Chennai, in the past two years.

REVIEW OF LITERATURE

HISTORY

The earliest record of inguinal hernia dates back to approximately 1500 B.C. The term hernia is derived from the Greek word meaning an offshoot, bulging or bulge. The Latin word hernia means a rupture or tear. Trusses or bandages were generally used to control the herniation.

In the earlier part of the first century A.D. the operation in vogue was described by Celsus. Through an incision in the neck of the scrotum, the hernial sac was dissected off the spermatic cord and transected at the external inguinal ring. The testis was usually excised as well. The incision was generally left open.

Casper Stromary distinguished direct from indirect hernia in 1559 and advised that the testicle need not be removed during an operation for the former.

From the 18th century to the early 19th century the anatomy of the inguinal region was described and accurately defined. The dawn of modern surgery by the introduction of carbolic spray antiseptics by Joseph Lister in 1865 marked an important event in all surgeries including hernia surgery.

Marcy was the first to introduce antiseptic techniques in hernia repair. He was also the first to recognize the importance of the transversalis fascia and of closing the internal inguinal ring. Lucas - Championnere was the first to slit open the external oblique aponeurosis to reveal the canal, which allowed .dissection and ligation of the sac at the internal inguinal ring under direct vision. But all hernia repairs had a high mortality and recurrence rate of 30% - 40% at one year.

The greatest contribution to hernia surgery was that of an Italian surgeon, Edoardo Bassini. He had a clear insight into the anatomy and physiology of the inguinal region, which enabled him to dissect and reconstruct the inguinal canal preserving the functional anatomy. He laid the inguinal canal open widely by splitting the aponeurosis of the external oblique muscle. He next opened the transversalis fascia from the pubic tubercle to beyond the internal inguinal ring. Thus, he was able to dissect and ligate the sac high in the retoperitoneal space. Realising the importance of repairing the transervalis fascia, he sutured the internal oblique and transversus abddominis muscle as well as the upper leaf of the transversalis fascia in one layer to the lower leaf of the transversalis fascia and the inguinal ligament.

Bassini first performed the operation in 1884 reported in 1887. His cases had a very low recurrence rate and other complications. These phenomenal results earned him the title “Father of modern herniorraphy”.

During the next 100 years, most inguinal hernias were repaired by Bassini method or variations of it.

Important among them were

1. The multilayered repair of Shouldice in 1953.
2. In 1898, George Lotheissen first reported the technique of suturing the conjoint tendon to the Cooper's (pectineal) ligament.

A hernia repair done with undue tension is doomed to failure because of ischaemic necrosis of the tissues caused by pressure of sutures under tension. The Bassini repair or its modification is suitable only for cases where the musculoaponeurotic arch is close to the inguinal ligament to which it can be sutured without tension. When they are faraway, tension inevitably occurs with the Bassini method or its modification and leads to failure. The contribution of relaxing incision and slides in tension reduction were negligible.

To overcome this problem, darns were introduced. Earlier darning was done with natural materials like external oblique aponeurosis, fascial grafts from the thigh, strips of fascia lata, skin etc. They were largely disappointing.

Later silk was introduced, but failed for obvious reasons. It was not until Moloney introduced the nylon darn technique in 1948 that the results were satisfactory.

At about the same time patches were introduced in the form of sheets of natural tissues, biological material, metals or synthetic sheets or weaves to fill in the gaps of weakened posterior wall.

Between 1900 and 1909, Witzel, Goepel, Bartlett and McGavin used silver wire filigree sheets to fit the size and contours of the gaps in the tissue and sutured to the borders of the defect. However, the wire corroded, fragmented and was rejected through chronic sinuses.

Tantalum metal sheets were introduced by Burke in 1940; tantalum gauze by Throckmorton in 1948.

Then flaps of natural tissue-flaps of tissues of the thigh, external and internal oblique aponeurosis were used. Free grafts were also used.

No real progress was made until the development of modern synthetic polymer plastics in the form of sheets of woven or knitted mesh of polyamide and polypropylene. These were popularized by Usher in 1958. Later polyester, polytetrafluoroethylene (PTFE) were also introduced.

Today the use of these mesh sheets of Polypropylene or PTFE is widely practiced. Rolled up mesh plugs are also used extensively.

Preperitoneal approach was used since the days of ancient Hindus. The transabdominal but preperitoneal approach was introduced by Cheatle in 1920. The foremost proponent of this approach is Stoppa, who has developed the GPRVS (Giant Prosthesis for Reinforcement of the Visceral Sac) technique especially for problematic cases in which repeated repairs of multiple recurrent hernia has been done.

The latest in the armamentarium of the hernia surgeon is the Laparoscopic repair of the hernia, which affords a quick, relatively atraumatic technique in which bilateral repairs can be performed at the same operation and clinically unsuspected contralateral hernia identified and repaired.

ANATOMY OF THE INGUINAL CANAL

No disease of the human body belonging to the province of the surgeon requires in its treatment a greater combination of accurate anatomic knowledge, with surgical skill, than a hernia in all its varieties - Sir Astely Cooper.

The inguinal canal, about four centimeters in length, is an oblique canal located between the muscles, aponeuroses and fascia of the

anterior abdominal wall - created by the passage of the spermatic cord or round ligament, in males and females respectively.

Its internal end is the deep inguinal ring, which is a defect in the transversalis fascia, one centimeter above the midinguinal point and immediately lateral to the inferior epigastric artery. Its external end is the superficial inguinal ring, a triangular aperture in the aponeurosis of the external oblique muscle situated just above and lateral to the pubic tubercle. The base of the ring is formed by the inguinal ligament. Its margins are sewn together at the apex by the intercrural fibres.

BOUNDARIES

Floor

The shelf-like floor is formed by the inguinal ligament and its reflection onto the superior pubic ramus. It is the inturned part of the external oblique aponeurosis. It extends from the anterior superior iliac spine to the pubic tubercle. It continues onto the superior pubic ramus along the pectineal line to form the pectineal ligament.

Anterior wall

The anterior wall is formed in its whole length by the aponeurosis of the external oblique muscle and in the lateral third by the lowest fibres of the internal oblique arising from the inguinal ligament.

Roof

The inner two layers of the anterior abdominal wall muscles namely the internal oblique and transversus abdominis arch over the spermatic cord from their in into the iliac crest and lateral part of the inguinal ligament, forming the roof of the inguinal canal. Fibres of the internal oblique pass down to envelope the cord and thus constitute the cremaster muscle.

Posterior wall

The arching fibres of the internal oblique and transversus abdominis join together to form the conjoined tendon which forms the posterior wall in the medial third. Deep to the transversus abdominis is the endo-abdominal fascia. The part of this fascia that lies in contact with the transversus abdominis is called the transversalis fascia. It passes down to emerge from behind the free lower edge of the transversus abdominis muscle and forms the posterior wall of the inguinal canal in its whole length. It is inserted along the pectineal line.

The deep inguinal ring is a defect in the transversalis fascia through which the spermatic cord enters the inguinal canal. It is bounded medially and inferiorly by a condensation of the transversalis fascia and laterally by the aponeurotic lower edge of the transversus abdominis muscle.

CONTENTS

In the male, the contents of the inguinal canal are

1. The spermatic cord.
2. The vestigial remnants of the processus vaginalis - the fetal prolongation of peritoneum which accompanies the testes in its descent into the scrotum.
3. The ilioinguinal nerve - appears in the medial part of the inguinal canal and enters the superficial inguinal ring.
4. The iliohypogastric nerve, which is strictly not a content of the canal, but which is displayed when the canal is opened, lies in front of the internal oblique, a little above its lower border

In females, the round ligament is found instead of the spermatic cord. The spermatic cord consists of

1. The vas deferens
2. The artery to the vas
3. The testicular artery
4. The Pampiniform plexus of veins
5. Lymph vessels

6. Sympathetic nerves and
7. Genital branch of genitofemoral nerve

The cord has three coverings.

1. The internal spermatic fascia derived from the fascia transversalis at the deep ring.
2. Cremasteric muscle and fascia derived from the internal oblique muscle.
3. The external spermatic fascia derived from the external oblique aponeurosis at the superficial inguinal ring.

DIRECT AND INDIRECT INGUINAL HERNIA

The inferior epigastric artery, passes upwards, close to the medial edge of the deep ring. The part of the transversalis fascia, medial to the inferior epigastric artery, bounded by the artery, the rectus sheath and inguinal ligament is known as the Hasselbach's triangle. Indirect inguinal hernias pass through the internal ring lateral to the inferior epigastric artery and direct hernias bulge forward medial to the vessel through the Hasselbach's triangle, pushing the attenuated transversalis fascia ahead of them.

AETIOLOGY

The aetiology of inguinal hernia can be divided into

1. Congenital and
2. Acquired causes

A preformed sac is present in congenital hernia. The cause in acquired hernia may be

- a. repeated elevation of intra abdominal pressure.
- b. weakening of body musculature and tissues.

Congenital hernia

Preformed sac - a patent processus vaginalis is considered to be the cause of inguinal hernia in infants and children and probably in adults. Thus treatment for inguinal hernia in children is herniotomy. About 20% of adults have a patent processus vaginalis, yet most of them do not develop inguinal hernias.

Acquired hernia

- a. *Increased intra-abdominal pressure - enormously high intra abdominal pressures are generated when an individual coughs or strains, yet the abdominal wall usually maintains its*

integrity inspite of preformed weak areas, notably the transversalis fascia and internal inguinal ring. This is explained on the basis of the 'Shutter Mechanism'.

The Shutter Mechanism

The muscles of the abdominal wall must contract to raise the intra - abdominal pressure. As the external oblique muscle contracts, it becomes tense and presses on the weak posterior wall of the inguinal canal and so reinforces it and also tends to pull the inguinal ligament upward. At the same time, the muscular arch passing over the cord also sharply contracts, and as its fibres shorten the arch is straightened out and comes to lie on or close to the raised inguinal ligament and so protects the weak posterior wall of the canal. As this shutter comes down, it passes in front of the internal ring and so counteracts the pressure on the ring from the abdomen. The very act of contracting the abdominal muscles in coughing or straining which tends to blowout the internal ring and the transversalis fascia, automatically and at the exact same time, brings into play mechanisms that prevent the occurrence of this damage.

- b. Weakening of the muscles and fascia of the abdominal wall - weakening of the muscles and fascia of the abdominal wall occurs with advancing age, lack of physical exercise, obesity, multiple pregnancies, loss of weight and fitness after illness.*

Here, a basic defect in the structure of collagen such as reduction in polymerised collagen and a decreased concentration of hydroxyproline will lead to a loss of bonding between the collagen fibres. This mechanism is important in some cases especially in cases of repeated, recurrent hernia and perhaps in cases of a familial tendency to hernia.

Certain other factors like assumption of the erect posture in human beings and a low lying pubic tubercle etc. may be responsible for inguinal hernia-altering the functional anatomy of man, such as a reduction in the mechanical efficiency of the shutter mechanism.

The cause of inguinal hernia is probably multi factorial. In indirect hernia, a preformed sac of processus vaginalis is probably present, but bowel is prevented from entering the sac by the muscular action. When a sudden high intra-abdominal pressure occurs, the shutter mechanism is overcome. In cases with chronic cough, obesity, straining and advanced age the shutter mechanism gradually fails leading to bowel entering the sac. In direct hernia, there is no preformed sac, when the protective mechanisms fail due to the above factors, the weakened transversalis fascia is not able to hold up the repeated increases in the intra abdominal pressure and stretches, abdominal out in front of the advancing bowel.

CLASSIFICATION

Classification of hernia is important, because for any meaningful comparison of different methods of hernia repair, it is important that the same type, grade or stage of the hernia is discussed.

The commonly used methods include

1. Gilbert's classification
2. Nyhus classification
3. Bendavid classification
4. Stoppa classification

GILBERT CLASSIFICATION

It is an anatomic and functional classification for the diagnosis and treatment of inguinal hernias.

TYPE I

1. Snug internal ring
2. Posterior wall is intact
3. Sac does not reappear on coughing or straining after reduction.

TYPE II

1. Moderately enlarged internal ring - admits 1 finger but in smaller than two finger breadths.
2. Posterior wall is intact.
3. After reduction, sac will protrude when the patient coughs/ strains.

TYPE III

1. Large internal ring - two finger breadths or more.
2. The reduced indirect peritoneal sac will prolapse out immediately without any effort on the part of the patient.

TYPE IV

A direct hernia with a large or full blowout of the posterior wall of the canal. Internal ring is intact.

TYPE V

A direct hernia protruding through a punched out hole in the transversalis fascia.

The internal ring is intact.

Nyhus Classification

Type 1- Indirect hernia with normal internal ring and posterior wall.

Type 2- Indirect hernia with dilated internal ring but normal posterior wall.

Type 3- Direct hernia.
Indirect hernia with internal ring encroaching on the posterior wall.
Femoral hernia.

Type 4 - Recurrent hernia

TYPES OF REPAIR

The different types of repair of inguinal hernia can be classified into

1. Pure tissue repairs
2. Dam repairs
3. Mixed tissue - prosthetic repairs
4. Pure prosthetic repairs.
5. Laparoscopic repair.

PURE TISSUE REPAIRS INCLUDE

1. The Bassini operation
2. The Shouldice operation
3. The Cooper ligament repair
4. The iliopubic tract repair

DARN REPAIR

In DARN repair, the principle is to reinforce the weakened or torn posterior wall of the inguinal canal with the muscles of the musculoaponeurotic arch as well as with a simple lattice work of non-absorbable monofilament suture material without any tension on which is laid a buttress of fibrous tissue without the normal tissues being torn or necrosed.

MIXED PROSTHETIC TISSUE REPAIRS

Here sheets of synthetic mesh are laid either deep to the tissue repair as an underlay graft or in front of the repair as an overlay graft. Polypropelene mesh is usually used.

PURE PROSTHETIC REPAIRS

Here no attempt is made to close the defect. A sheet of polypropylene mesh of appropriate size is fashioned to reconstruct the entire posterior wall of inguinal canal without any attempt to close any defect by tissue repair.

THE IDEAL PROSTHESIS

The material should

1. not be physically modified by the tissue fluids.
2. be chemically inert
3. not excite an inflammatory or foreign body reaction
4. be non-carcinogenic
5. not produce allergy/hypersensitivity.
6. be capable of resisting mechanical strain.
7. be capable of being fabricated in the form required.
8. be capable of being sterilised.

It is unlikely that the ideal prosthesis for hernia repair will ever be developed; but the three meshes widely used today Prolene (Marlex), e-

PTFE (Gore-tex) and Polyester (Mersiline) satisfy the above needs to a greater extent.

MESHES COMMONLY USED

1. *Polyester mesh (Dacron, mersiline mesh)*

A polyester polymer from ethylene glycol and terephthalic acid. Extensive clinical experience has developed with plastic mesh repair of abdominal wall defects. Dacron mesh was the first popular nonmetallic mesh to stand the test of time and it remains in active clinical use today although its use has reduced as polypropylene mesh has become popular.

2. *Polypropylene mesh (Marlex Mesh)*

Introduced by Usher in 1958/59, polypropylene mesh has had an enormous impact on surgery over the past 4 decades and countless patients have benefitted from them. It is quite clearly and justifiably the most popular prosthetic mesh available today for surgical implantation.

Advantages

It has many obvious advantages

1. more pliable and readily inserted into any size defect without fragmentation.

2. more tolerant of bending and flex stress and can be used in the groin without discomfort to the patient.
3. less affected by infection and granulation tissue will grow through the mesh even in the presence of purulent infection without sloughing or sinus tract formation.

Expanded polytetrafluoroethylene (Gore-tex)

A fully fluorinated polymer with the chemical formula (-CF – CF) It is an effective biomaterial for a wide array of clinical problems. Its unique properties stand it apart from all previous mesh prostheses that are macroscopically composed of a coarse, weave or knit that is freely permeable to air and liquid. In contrast, the soft, smooth surface of the e-PTFE patch is non-abrasive, elicits minimal foreign-body reaction and is able to support a layer on the peritoneal surface of the patch, of neomesothelial cells, which results in a low incidence of postoperative visceral adhesion formation and reduction in long-term bowel complications.

Absorbable Mesh

1. Polyglycolic acid (Dexon)
2. Polyglyactin 910 (vicryl)

Presently available absorbable meshes should not be used as the sole prosthesis for the repair of abdominal hernias as they are absorbed in about 90 days. However they have a role in the closure of infected abdominal wall defects.

Complications of inguinal hernia repair

1. General complications
 - a. Pulmonary atelectasis
 - b. Pulmonary embolism
 - c. Pneumonia
 - d. Thrombo phlebitis
 - e. Urinary retention

LOCAL COMPLICATIONS

1. Ischaemic orchitis and testicular atrophy

Signs and symptoms:

- Painful, tender and swollen testicle and spermatic cord.
- Occasionally mild leucocytosis

- Temperature elevation to 38° or 39°C is not uncommon and typically precedes the testicular manifestations.

The testicular abnormality does not become apparent until 2-3 days after the operation. The intensity and duration of the signs and symptoms vary greatly and apparently have little bearing on the ultimate outcome.

Ischaemic orchitis may resolve completely or progress to testicular atrophy; only rarely does the testicular atrophy become gangrenous. Usually the fever disappears promptly, but the testicular pain and tenderness may persist for several weeks. The swelling of the testicle and spermatic cord lasts much longer, and four or five months may pass before the size and shape of the spermatic cord and testicle return to normal. Sometimes the inflammatory process foreshortens the spermatic cord, causing the testicle to retract in the scrotum. Such malpositions of the testicle are permanent. The return of the testicle to normal size, shape and consistency does not necessarily indicate that the inflammatory process has resolved. In fact, in about a third of the patients with ischaemic orchitis the testicle continues to shrink until it is frankly atrophic. In most cases, atrophy is apparent within a few months of the operation. However, in some patients, as long as 12 months may elapse before the atrophy is fully established. An atrophic testicle is painless and non tender.

Pathology

The cause of testicular atrophy in acute ischaemic orchitis is not known. It may be the result of arterial insufficiency, venous insufficiency or both.

Histologically, the Leydig cells which produce testosterone and the supporting Sertoli cells are present and appear normal. The seminiferous tubules are usually absent. Atrophy of the testis secondary to ischaemic orchitis is not associated with an increased incidence of testicular malignancy.

Aetiology

The aetiology of ischaemic orchitis is poorly understood. Apparently collateral circulation to the testis is very good as the spermatic cord can be divided without ischaemic orchitis necessarily resulting.

The causes could be

1. Interruption of the testicular blood supply by extensive dissection.
2. Injury to the cord by reconstruction of the deep and/or external inguinal rings too tightly.
3. Anomalous blood supply to the testis as suggested by Koontz.

The high frequency of ischaemic orchitis in patients undergoing hernia repair for scrotal hernias and recurrent inguinal hernias provide clue to the cause of this complication. The common trait in these patients is extensive dissection, often traumatic because of its extent, to free the sac from the cord or to free the previously dissected and scar encased spermatic cord. Such dissection may indeed injure the testicular artery, but is much more likely to traumatise the innumerable delicate little veins of the pampiniform plexus. The venous insufficiency caused by extensive thrombosis of the veins of the cord is as important as arterial insufficiency in initiating ischaemic orchitis. This contention is supported clinically by the slow onset of the orchitis; the tender, swollen and inflamed spermatic cord, the rarity of testicular gangrene requiring orchidectomy.

Prevention and treatment

There is no definite treatment for ischaemic orchitis though antibiotics and anti-inflammatory drugs are commonly used. Their usefulness is doubtful.

Therefore the best method of preventing testicular atrophy would be to minimise the complication of ischaemic orchitis.

This can be done by precise and nontraumatic dissection of the spermatic cord, meticulous reconstruction of the inguinal canal and whenever possible, avoidance of the dissection of the spermatic cord.

distal to the pubic tubercle in order to preserve collateral circulation. The testis should not be mobilised, nor should a spermatocele or hydrocele be excised concomitantly with an inguinal hernia repair.

One way to minimise trauma to the cord is to leave in place and untouched the distal portion of an indirect inguinal hernial sac in all but the smallest of the cases. Instead of excising the whole sac, one opens it near the internal ring, and circumferentially divides it. After the proximal sac is freed from the transversalis fascia and its attachment to the cord at the deep ring, the sac may or may not be closed and allowed to retract. The distal sac is left open.

It is impossible to eliminate this complication completely from primary inguinal hernia repair particularly in large, indirect sliding hernia. Here the sac must be entirely freed to reduce the large intestine that makes part of its wall. Dissection beyond the pubic tubercle is also necessary in patients with large direct hernias that descend into the scrotum.

A too tightly reconstructed inguinal ring produces immediate and obvious engorgement of the veins of the cord and necessitates redoing of the reconstruction.

Next there is the possibility that the testicular blood supply may be anomalous. This may be especially important if the external spermatic

artery and vein are divided, to perform a superior reconstruction of the posterior wall of the inguinal canal.

In recurrent hernias, reducing the frequency of testicular atrophy may be impossible. One way would be to repair the hernia preperitoneally. The hernia is approached and repaired posteriorly and an anterior dissection of a previously mobilised cord is thereby avoided altogether.

Informed consent

In all patients with large scrotal inguinal hernias and recurrent hernias the surgeon should explain and document in detail the nature of this complication.

2. *Haemorrhage, haematomas and ecchymosis*

Haemorrhage and haematomas are common to all operations and are not unique to inguinal hernia repair. The precautions to minimize them must be carefully followed.

The scrotum often becomes ecchymotic from blood gravitating into the scrotum from the inguinal canal. Scrotal ecchymosis is very common with the use of local anaesthesia, and when the local anaesthetic agent contains epinephrine. Ecchymosis does not interfere with wound healing and is not associated with serious sequelae. The ecchymosis subsides promptly.

3. *Numbness and Paraesthesia*

The ilioinguinal and iliohypogastric nerves are the sensory nerves to the groin. They innervate the pubis, the base of the penis, anterolateral aspect of the scrotum and upper medial aspect of the thigh.

Virtually all patients have numbness and paraesthesia in the groin after inguinal hernia repair. Most often these sensations are limited to a small triangular area just inferior and medial to the incision. Sometimes the area of numbness and paraesthesia may involve the entire cutaneous distribution of the ilioinguinal nerve. In most instances, these sensory changes are temporary and disappear with time. Occasionally some degree of hyperaesthesia, paraesthesia or even anaesthesia may present for long periods. Usually there is no correlation whatsoever between the patient's postoperative complaints of sensory changes and whether or not the nerve was traumatised.

If possible an effort to preserve the nerve from trauma, stretching, or interruption should be made. Often this is impossible and the surgeon should not hesitate to divide the branches of the ilioinguinal nerve, the iliohypogastric nerve or the ilioinguinal nerve itself, if their presence interferes with the performance of a good repair.

4. Paresis

The only motor nerve in the groin is the genital branch of genitofemoral nerve. This nerve innervates the cremasteric muscle and also may have a small sensory component to the lateral scrotum. Division of this nerve along with division of the cremasteric muscle abolishes the suspensory mechanism of the testicle and the cremasteric reflex. The patients may complain of the low position of the testicle in the scrotum and its inability to retract. The onset of the low position can be delayed and in some instances prevented by hitching up the testicle by incorporating the distal stump of the cremasteric muscle and fascia in the reconstruction of the external ring.

Paresis the extensor muscles of thigh will occur if the femoral nerve is injured. This may occur when the internal ring is made snug by blindly placing a suture 'lateral' to the spermatic cord at the deep inguinal ring. Placing a lateral suture at the deep ring destroys the shutter mechanism of the internal oblique muscle and also might injure the femoral nerve if inserted blindly and deeply. The deep ring should always be reconstructed from the medial side under direct vision by approximating the clearly defined aponeurotic arch and femoral sheath and/or inguinal ligament.

5. Groin pain

Groin pain is infrequent after inguinal hernia repair. Its causes include

1. Recurrence
2. Abdominal muscle strain
3. Nerve entrapment
4. Neuroma
5. Periostitis of the pubic tubercle
6. Adductor tendonitis

Most often postoperative groin pain is nonspecific and is due to abdominal muscle strain from overdoing exercises in a physical fitness program. Such pain stops if the offending exercise is stopped.

Most often injury, strain or inflammation is at the medial portion of the pectineal muscle at or near its origin from the pecten of the pubis. Pain is often mild and subsides spontaneously. Some cases may need local anaesthetic or steroid injection. Blocking the ilioinguinal or iliohypogastric nerves never abolish this pain as the pectineal muscle is innervated by the branches of the femoral nerve.

Physical examination with the patient supine and the adductor muscles fully stretched by circumduction of the knee and flexion of the hip and knee reveals sharply localised tenderness of the medial origin of the

pectineal muscle just lateral to the pubic tubercle and the taut tendon of adductor longus.

Pain in the groin may be caused by a nerve entrapped by a suture, scar or neuroma adherent to a muscle or aponeurotic structure. Both conditions produce similar symptoms. Typically the pain is burning or lancinating, aggravated by motion and radiates along the distribution of the involved nerve. The pain can be reproduced by pressure in the narrowly circumscribed spot to which the patient can point precisely. The ability to abolish the pain completely and repeatedly with local anaesthetic is considered pathognomonic of this condition. If the area triggering the pain is very sharply localised, operation might be avoided by permanently blocking the nerve with an injection of absolute alcohol/phenol. More often it is better to explore the wound and divide and ligate the involved nerve, thereby confirming possible neuroma formation within the neurovascular sheath.

6. *Transection of the vas deferens*

Transection of the vas deferens is very rare. If accidentally done, it should be repaired immediately after freshening the transected ends and by doing an end to end anastomosis with interrupted sutures of very fine polypropylene facilitated by an intraluminal splint.

7. *Visceral injury*

The intestine, urinary bladder and ureter may be injured during inguinal hernia repair.

The bladder or bladder diverticulum may make up a portion of the wall of a direct inguinal hernia. Bladder injuries can be avoided by inverting the direct inguinal hernia sac rather than excising it. Some large direct hernias may need opening and the bladder may be unintentionally entered. Bladder injury should be repaired in 2 layers with a fine chromic catgut and the bladder decompressed with a urethral catheter.

In indirect sliding hernias, the large intestine makes up a portion of the wall of the sac. The bowel may be injured either by entering it directly or devitalising it through interrupting its blood supply. Incised bowel should immediately be repaired. Devitalised bowel must be dealt with by exteriorisation or resection.

The ureter is occasionally encountered in both large indirect and direct sliding inguinal hernias. Traumatized ureter must be repaired by carefully anastomosing it, with fine interrupted sutures and splinting the anastomosis with a double J-splint.

8. Recurrence

The most common complication of inguinal hernia repair is recurrence. Patients with bilateral inguinal hernias have a much greater chance of recurrence than patients with unilateral hernia. Direct hernia recur more frequently than indirect hernias. Both direct and indirect hernias tend to recur as they occurred primarily ie a direct hernia tend to recur as a direct hernia and an indirect hernia recurs as an indirect hernia. Bilateral hernia that are operated on simultaneously recur more frequently than those operated separately.

Defective collagen may be a cause of recurrence for direct inguinal hernias. Tissue necrosis resulting from an interrupted suture tied too tightly or continuous sutures made excessively snug are very important aetiologic factors and must be carefully and strictly avoided.

There is a possibility that the recurrent hernia is infact an overlooked hernia. During primary inguinal hernia repair it is the femoral hernia that is frequently overlooked and during recurrent inguinal hernia repair small direct as well as femoral hernias are most easily missed.

Lastly, faulty evaluation of the integrity of tissues in the groin, especially tissues adjacent to the herniation is an important cause. The tendency for indirect hernias to recur as indirect hernias is probably due to incorrect evaluation of a weak lateral border of the deep ring and is not,

as is so frequently suggested to incomplete dissection of the indirect inguinal hernial sac from the deep ring or a loosely reconstructed deep ring.

9. *Hydrocele*

Very rare after hernia repair. Usually a preexisting hydrocele is aggravated due to lymphatic obstruction.

10. *Sexual dysfunction*

All forms of sexual dysfunction have been attributed to inguinal hernia repair, when in fact there is none. Most of these symptoms are functional and occur in patients with preexisting sexual problems. These patients need abundant reassurance and must be treated with understanding and circumspection.

MATERIALS AND METHODS

Fifty patients were included in the study - all of whom presented to the department of General Surgery at Government General Hospital, Chennai, in the past two years.

Patients were randomly allocated into either of the 2 groups - one group undergoing Onlay mesh repair and the other group undergoing Inlay mesh repair.

INCLUSION CRITERIA

Only elective cases were included in the study. Emergency cases were excluded from the study. Female patients were excluded from the study. Patients under 18 years of age were excluded from the study.

INVESTIGATIONS

Apart from the routine investigations, patients above 40 years of age and those complaining of symptoms of prostatism were investigated for evidence of prostatic hypertrophy by Digital rectal examination & Ultrasonogram of the Abdomen to determine the size of the prostate and assess for residual urine.

Those found to have benign prostatic hypertrophy were treated for BPH before they were subjected to hernia repair.

SURGICAL PROCEDURES

- Onlay (Lichtenstein's) mesh repair
- Laparoscopic (TEP)

SURGICAL TECHNIQUE

The two repairs compared are described in detail.

Lichtenstein's mesh repair

Incision

The skin incision is made along the line joining the anterior superior iliac spine and pubic tubercle in its medial two - thirds parallel to the inguinal ligament.

The subcutaneous tissue in its two layers - the fatty layer of Camper and the membranous layer of Scarpa are incised along the same line. Three named vessels are encountered - the superficial epigastric vein, the superficial external pudental vein and the superficial circumflex iliac vein. They are cut and ligated.

The external oblique aponeurosis is opened in the line of its fibres and the iliohypogastric and the ilioinguinal nerves are identified and preserved.

Dissection

Now the cord structures come into view. The cremaster is split open longitudinally and excised. The internal spermatic fascia is opened. The sac is dissected off its cord structures and an indirect sac is dissected well beyond the deep ring and ligated and excess sac excised. A direct sac is just invaginated by imbricating sutures. Now the repair begins.

ONLAY (LICHTENSTEIN'S) MESH REPAIR

Polypropylene mesh was used for the study. A sheet of mesh of size 11x6cm is trimmed suitably and is placed on the posterior wall over the transversalis fascia.

The mesh is sutured along its lower edge to the pubic tubercle, the lacunar ligament and the inguinal ligament using a continuous suture of 3-0 polypropylene. The medial edge is sutured to the rectus sheath. The superior edge is sutured to the conjoint tendon or muscle of the internal oblique with a few interrupted sutures. The lateral edge of the mesh is split up and the tails are passed around the cord at the internal ring and fixed.

LAPAROSCOPIC TOTALLY EXTRA PERITONEAL HERNIOPLASTY (TEP)

Position : Supine with 15° Trendelenburg's position.
Surgeon stands on the opposite side of the hernia monitor on the foot end of the table.

Ports : 10 mm – Subumbilical (camera)
5mm - one third distance from the umbilicus to pubic symphysis
5 mm - Midway between umbilicus & Anterior superior Iliac spine (on the side of the hernia)

PREPERITONEAL SPACE CREATION:

- An incision made on the lower half of the umbilicus in the midline.
- The tissues are separated with curved dissector & two curved retractors are used to expose the anterior rectus sheath on the same side of the hernia.
- The rectus sheath is incised transversely and the rectus muscle is identified & retracted laterally.

- A curved dissector is used to create a space between the rectus muscle & posterior rectus Sheath.
- A blunt nosed canula without obturator is introduced into the space
- A 0° scope is then inserted through the canula & space is formed by forward & backward with telescopic movement under continuous insufflation of CO₂ at 12mm Hg.
- For widening the space, 5mm trocar is introduced at one third distance from the umbilicus in the mid line.
- After widening the space, 2nd trocar is introduced midway between umbilicus and anterior superior Iliac spine

LATERAL DISSECTION:

- Using curved dissector & scissors laterally space is extended deep to the inferior epigastric vessels.
- Lateral & cranial dissection is performed till it reaches the line joining the umbilicus and anterior superior Iliac spine.
- 2nd trocar is introduced at the highest point of dissection.

TWO HAND DISSECTION:

- Cooper's ligament on the same side of the hernia should be exposed by using sharp and blunt dissection.
- Retropubic space can now be widened in the mid line and on the side of the hernia up to the level of obturator nerve & vessels.
- Lateral to the inferior epigastric vessel, keeping it up against rectus muscle areolar tissue is best dissected using a combination of blunt & sharp dissection gaining easy access to the space lateral to the internal ring.
- Dissection should be performed in avascular plane in the triangle of nerves and care should be taken not to damage the femoral branch of the genitor femoral nerve and lateral cutaneous nerve of thigh and a small branch of deep circumflex Iliac artery.
- With careful dissection indirect sac is dissected from the cord structures in case of congenital hernia where complete sac could not be separated, pretied endoloop is introduced through the lateral port, the grasper in the mid line port is introduced through the loop and the sac is held as distal as

possible endoloop pusher is pulled out, scissors are introduced through the same port & the sac is divided.

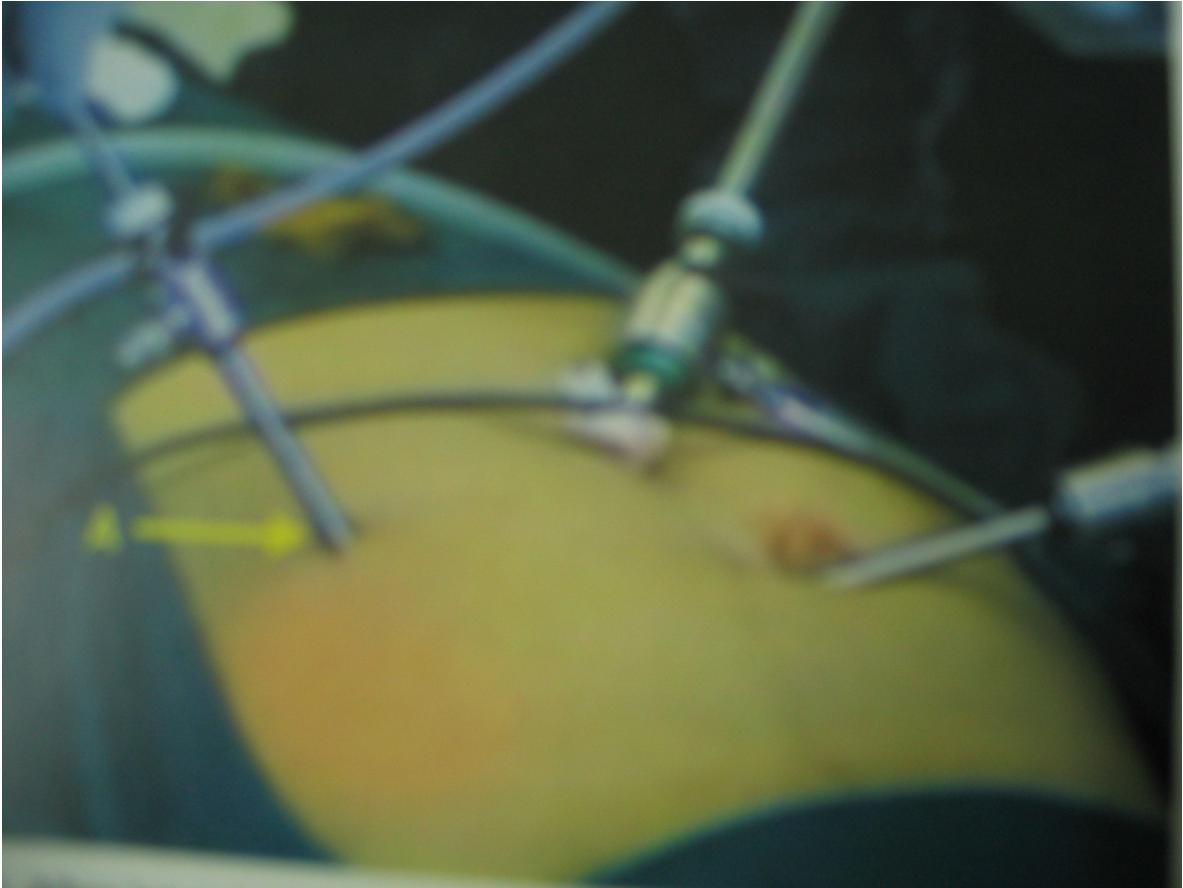
- In case of bilateral hernia once dissected on one side preferably on right side first, instrument turned to other side & similar dissection is performed.

MESH:

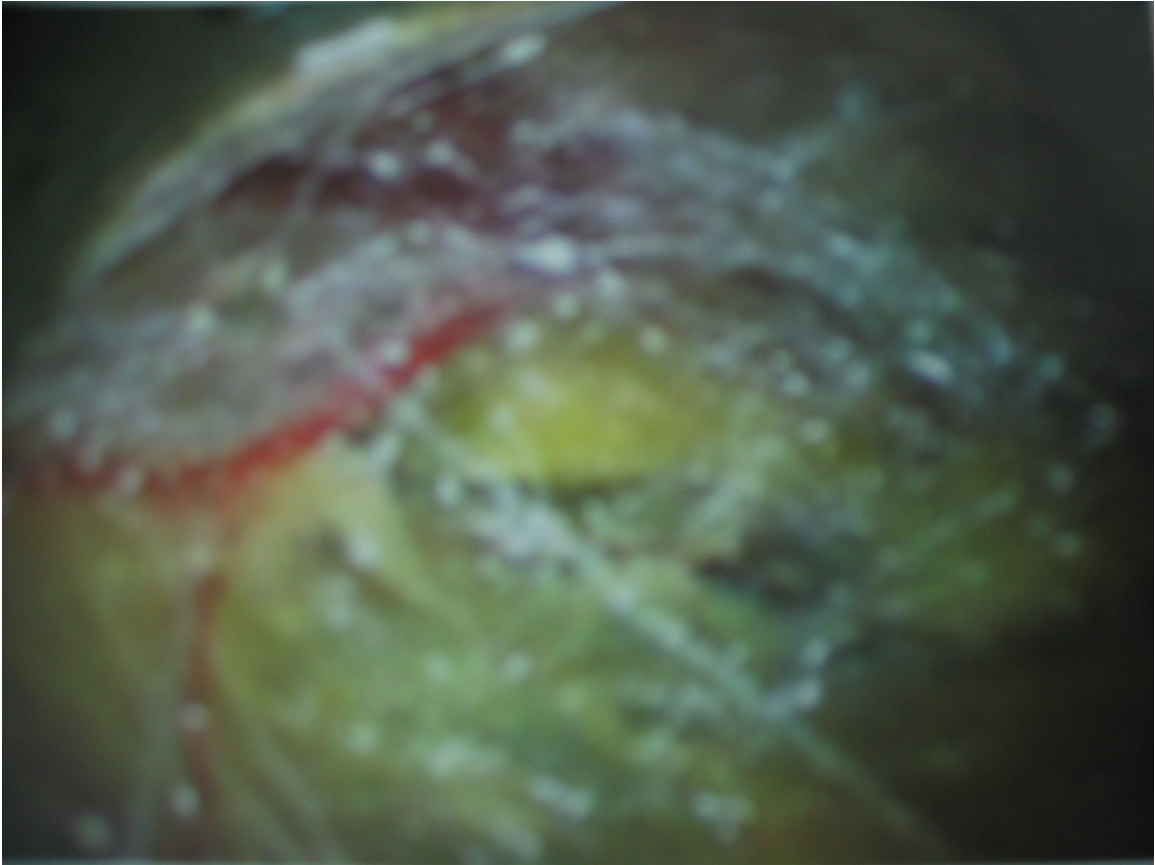
15 x 12 cm proline mesh is introduced into the space using the 10mm sleeve through the umbilical port blindly. The mesh adequately covers the dissected area of the musculo aponeurotic defect.

Mesh is fixed to the Cooper's ligament, rectus muscle & lateral to the inferior epigastric vessels with prolene suture.

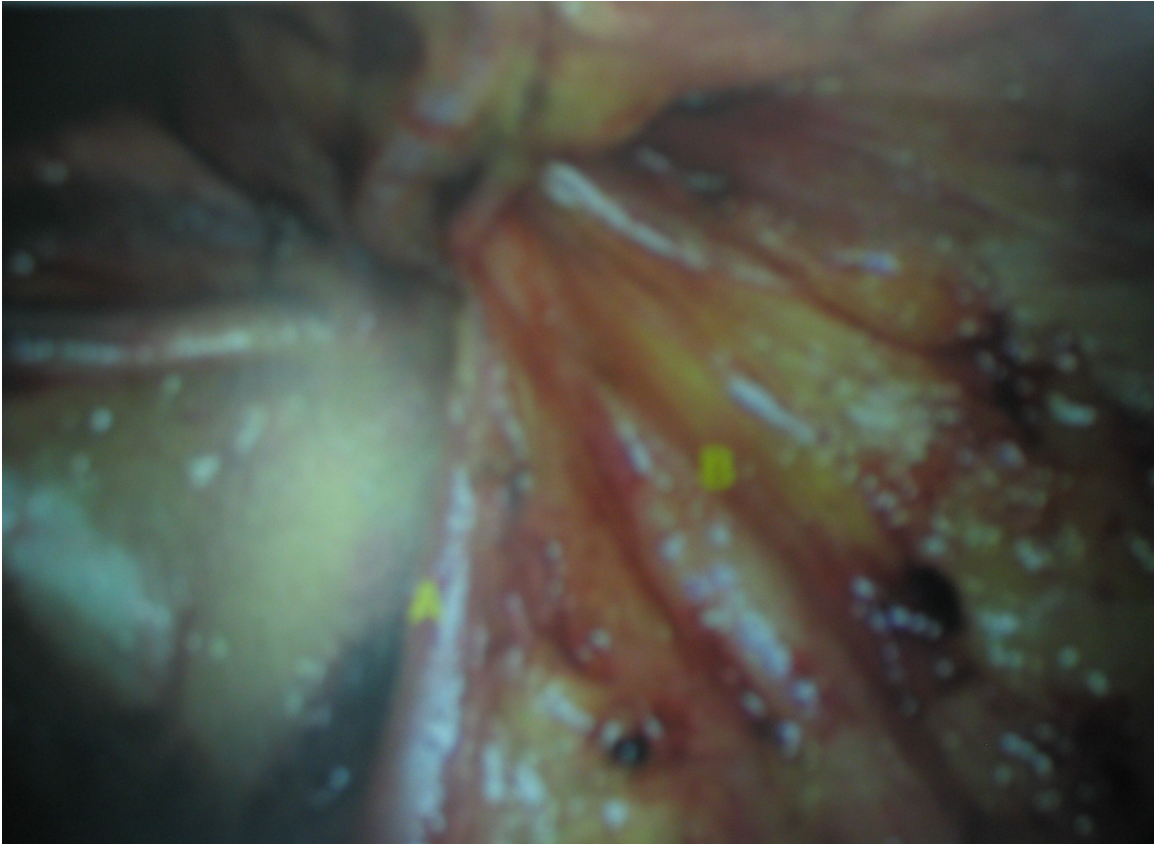
All the patients were given a preoperative antibiotic of injection Ampicillin one gram intramuscularly half an hour before surgery.



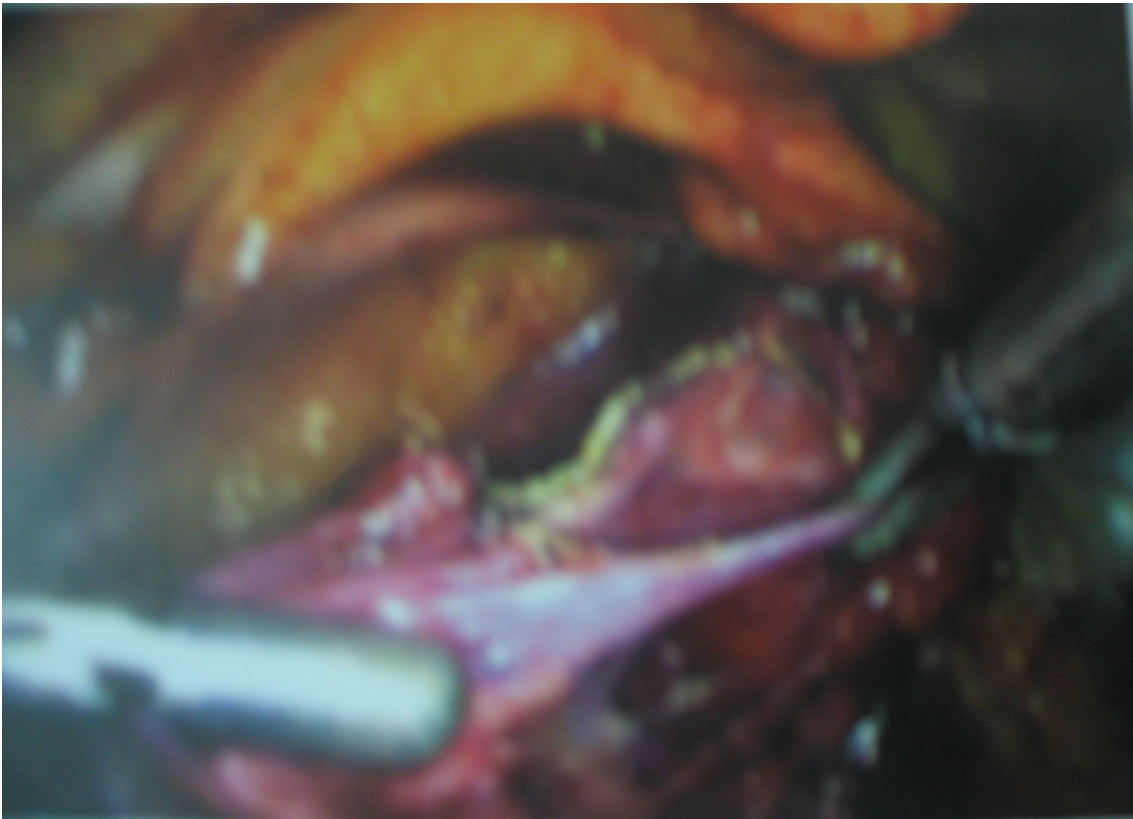
PORTS



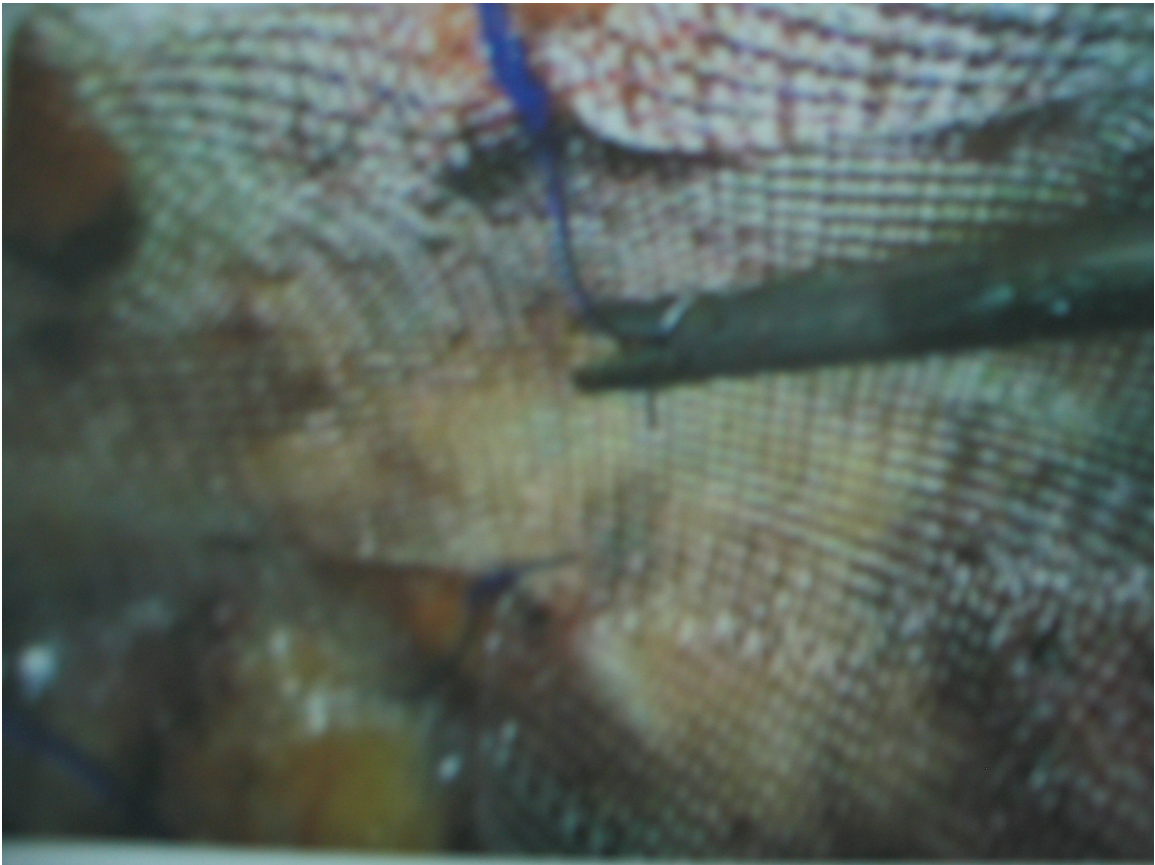
PRE PERITONEAL SPACE



TRIANGLE OF DOOM



DISSECTION OF SAC



MESH PLACEMENT

FOLLOW UP

Patients were discharged on the third postoperative day if there were no complications. Patients were reviewed on the eighth postoperative day and after three months, six months, one year and two years. Post operatively all patients received antibiotics - Injection Ciprofloxacin 200mg intravenously for three days.

Patients were followed up for

1. *Postoperative pain*

Postoperative pain is assessed on a subjective basis on each patient after six, twelve and twenty four hours.

2. *Analgesic requirements*

Patients were also studied for their analgesic requirements - calculated by the number of doses of analgesic injection (diclofenac sodium 75 mg i.m.) administered as demanded by the patient.

3. *Nerve entrapment and its sequelae*

Nerve entrapment within the fibrosing tissue layers over the mesh and its sequelae like pain, paresthesia over the inguinal region, medial

aspect of the scrotum are assessed from the third postoperative day to three months later.

4. *Cord Oedema*

Patients were assessed for oedema of the spermatic cord by the presence of pain, swelling of the spermatic cord between the first post operative day and for a period of about 6 weeks.

5. *Orchitis*

Patients were considered to have orchitis in the presence of pain and tenderness in the scrotum, usually arising after the second post operative day, and persisting for a variable period beyond one week.

6. *Scrotal Haematoma*

Scrotal haematoma was diagnosed if there was collection of blood in the scrotum in the immediate post operative period as confirmed by ultrasonogram.

7. *Recurrence*

Patients were also examined for recurrence during follow up.

OBSERVATION AND RESULTS

During the past two years, fifty patients presenting with inguinal hernia were studied - twenty five patients undergoing onlay mesh repair and twenty five patients undergoing Laparoscopic mesh repair (TEP) as stated above at the Department of General Surgery, Government General Hospital, Chennai.

Allotment of cases into the two groups was done randomly. Female patients and patients presenting as emergency were excluded from the study. Patients less than 18 years were excluded.

The following observations were made

1. TYPE OF HERNIA

a. *Direct inguinal hernia*

- i. In patients undergoing onlay mesh repair - 11/25 - 44%.
- ii. In patients undergoing laparoscopic mesh repair (TEP)- 8/25 - 32%.
- iii. Both groups together 19/50 - 38%.

b. *Indirect inguinal hernia*

- i. In patients undergoing onlay mesh repair - 13/25 - 52%.

ii. In patients undergoing laparoscopic mesh repair (TEP)- 15/25
- 60%.

iii. Both groups together 28/50 - 56%.

c. Pantaloon hernia

i. In patients undergoing onlay mesh repair - 1/25 - 4%

ii. In patients undergoing laparoscopic mesh repair, 2/25 - 8%.

iii. Both groups together - 3/50 - 6%.

In the study it was found that indirect hernias (56%) were more common than direct hernias (38%).

2. Side most commonly affected

i. In patients undergoing onlay mesh repair

a. Right side - 13/25 52%

b. Left side - 8/25 32%

c. Bilateral - 4/25 16%

ii. In patients undergoing Laparoscopic mesh repair (TEP)

a. Right side - 15/25 60%

b. Left side - 7/25 28%

c. Bilateral - 3/25 12%

- iii. Both groups together
 - a. Right side - 28/50 56%
 - b. Left side - 15/50 30%
 - c. Bilateral - 7/50 14%

In this study inguinal hernia was more common on the right side (56%) than on the left side (30%).

3. Age group

Patients were divided into two groups based on their age - those less than 40 years and those more than 40 years.

- a. Less than 40 years of age
 - i. Total number of patients - 19
 - ii. Incidence of direct hernia - 2.
 - iii. Incidence of indirect hernia - 20
- b. Greater than 40 years
 - i. Total Number of patients - 31
 - ii. Incidence of direct hernia - 16
 - iii. Incidence of indirect hernia - 13

In patients less than 40 years of age indirect hernia was much more common than direct hernia; whereas in patients above 40 years of age direct hernia was more common than indirect hernia.

4. *Analgesic requirements*

There was a significant difference in the analgesic requirement of the patients in both the groups. Patients in the onlay mesh repair group required on an average 4 doses of analgesic. Injection diclofenac sodium was the analgesic used. In the laparoscopic mesh repair it was 2.64.

5. *Orchitis*

- i. In patients undergoing onlay mesh repair - $6/25 = 24\%$
- ii. In patients undergoing laparoscopic mesh repair (TEP)- $0/25=0\%$

The incidence of orchitis was totally nil in the - mesh repair group compared to onlay mesh repair group in which it was 24%.

6. *CORD OEDEMA*

- i. In patients undergoing onlay mesh repair - $7/25 = 28\%$.
- ii. In patients undergoing laparoscopic mesh repair, - $3/25 = 12\%$.

7. RECURRENCE

1. In patients undergoing onlay mesh repair - $0/25 = 0\%$
2. In patients undergoing laparoscopic mesh repair $0/25 = 0\%$.

There was no recurrence at all in both the groups during this limited follow up period. A longer study period is therefore needed to identify recurrence within these groups to know the apparent advantage of mesh repairs.

COMPLICATIONS

<i>Sl.No</i>	<i>Complications</i>	<i>Onlay mesh repair %</i>	<i>Laparoscopic mesh repair %</i>
1.	Cord oedema	7	3
2.	Orchitis	6	-
3.	Testicular atrophy	-	-
4.	Recurrence	-	-
5.	Nerve Paresis	8	-

CONFIDENCE INTERVAL

<i>Sl. No.</i>	<i>Factors</i>	<i>Onlay mesh repair</i>	<i>Laparoscopic mesh repair (TEP)</i>
1.	Analgesic Requirement	3.8 to 4.2 (4.)	2.5-2.8 (2.64)
2.	Cordoedema	27.5-28.2 (28)	11.8-12.2 (12)
3.	Nerve Paresis	31.6- 32.1 (32)	--
4.	Orchitis	23.8-24.2 (24)	--

CONCLUSION

In our study during the past two years in the department of, General Surgery, Government General Hospital, Chennai about fifty patients were studied for comparing Onlay (Lichtenstein's) mesh repair and Laparoscopic mesh repair (TEP) in the treatment of inguinal hernia.

There was a significant difference in the overall complication rate between the two groups. Orchitis and Nerve paresis were virtually absent in the Laparoscopic mesh repair (TEP) group, which were present in a few number of patients in the onlay mesh repair group which is statistically significant ($p < 0.05$).

There was no recurrence at all in both the groups during this limited follow-up period. A longer period of study is therefore needed to identify recurrence within these groups to know the apparent advantage of mesh repairs.

C Analgesic requirement was significantly lower in the laparoscopic mesh repair (TEP) group when compared to the Onlay mesh repair group which is statistically significant. ($p < 0.05$)

Cord oedema is present in a statistically significant minimal number of patients in the Laparoscopic mesh repair (TEP) group when compared to the Onlay mesh repair group.

Based on the observation, results and analysis of this study, we recommend that

“Laparoscopic - repair, is superior than Onlay (Lichtenstein ‘s) mesh repair for treating Inguinal hernia” because of the following facts

1. Minimal post operative pain
2. Less analgesic requirements
3. Less cord oedema
4. Nil orchitis and nerve paresis

Apart from repairing the inguinal hernia, Laparoscopic mesh repair has got the additional advantages of

1. Identification of an occult femoral hernia and repairing it.
2. Identification of bilateral inguinal hernia.

Disadvantages:

Laparoscopic hernioplasty

1. Operative time is three times more than open Hernioplasty.
2. Learning curve for laparoscopic Hernioplasty is very long.
3. Laparoscopic Hernioplasty is costlier than open Hernioplasty.

Master chart

SL No	NAME	AGE	SEX	I.P.NO	HERINA TYPE	SIDE	REPAIR TYPE	POSTAL PAIN	ANALEGESIC REQUIRMENTS	CORD OEDEMA	NERVE ENTRAPMENT	ORCHITIS	RECURRENCE
1.	Sivabooshanam	43	M	532274	Indirect	Rt.	Lap	+	4	-	-	-	-
2.	Kamarudden	48	M	531674	Indirect	Rt.	Lap	-	2	-	-	-	-
3.	Dillibasha	19	M	532742	Indirect	Rt.	Lap	++	6	+	-	-	-
4.	Ponnuswamy	55	M	550905	Direct	Bil.	Lap	-	4	-	-	-	-
5.	Mari	55	M	537278	Indirect	Lt.	Lap	-	2	-	-	-	-
6.	Kuppiah	23	M	538834	Indirect	Lt.	Lap	-	2	-	-	-	-
7.	Seenu	35	M	535856	Indirect	Rt.	Lap	-	2	-	-	-	-
8.	Vinidh	39	M	556521	Indirect	Lt.	Lap	+	4	-	-	-	-
9.	Lakshmanan	60	M	546162	Direct	Rt.	Lap	-	2	-	-	-	-

10.	Ammasi	55	M	53229 4	Indirect	Rt.	Lap	-	2	-	-	-	-
11.	Khadhar	58	M	56548 0	Indirect	Lt.	Lap	-	2	-	-	-	-
12.	Dayalan	58	M	59542 3	Indirect	Rt.	Lap	-	2	-	-	-	-
13.	Murugan	65	M	57845 6	Direct	Rt.	Lap	+	4	-	-	-	-
14.	Ganapathy	31	M	53267 6	Indirect	Rt.	Lap	-	2	-	-	-	-
15.	Raja	44	M	52522 5	Indirect	Lt.	Lap	-	2	-	-	-	-
16.	Munuswamy	70	M	40845 0	Pantaloo n	Rt.	Lap	-	2	-	-	-	-
17.	Malliah	24	M	47691 7	Indirect	Rt.	Lap	-	2	-	-	-	-
18.	Thiruvathi	58	M	47835 4	Direct	Bl.	Lap	-	2	-	-	-	-
19.	Vaidevelu	30	M	47350	Indirect	Rt.	Lap	-	4	-	-	-	-
20.	Gopal	73	M	48743 1	Direct	Lt.	Lap	-	2	-	-	-	-
21.	Ranjith	29	M	45585	Indirect	Rt.	Lap	-	2	-	-	-	-

				8									
22.	Kumar	38	M	48954 2	Direct	Lt.	Lap	-	2	-	-	-	-
23.	Ramanujam	45	M	47050 6	Direct	Rt.	Lap	-	2	-	-	-	-
24.	Kandaswamy	59	M	40585 6	Direct	Bil	Lap	-	4	-	-	-	-
25.	Rajan	50	M	45694 2	Indirect	Rt.	Lap	-	2	-	-	-	-

Master chart

SL No	NAME	AGE	SEX	I.P.NO	HERINA TYPE	SIDE	REPAIR TYPE	POSTAL PAIN	ANALEGESIC REQUIRMENTS	CORD OEDEMA	NERVE ENTRAPMENT	ORCHITIS	RECURRENCE
1.	Muruganandam	65	M	325890	Direct	Rt.	Onlay	-	2	-	-	-	-
2.	Vijayakumar	43	M	372768	Indirect	Lt.	Onlay	+	4	+	-	-	-
3.	Ramasetu	85	M	317303	Direct	Bil.	Onlay	+	6	-	-	-	-
4.	Deivanathan	48	M	399656	Inirect	Lt.	Onlay	-	2	-	+	-	-
5.	Sankaran	65	M	401208	Direct	Lt.	Onlay	+	4	+	-	+	-
6.	Krishnan	42	M	412150	Indirect	Rt.	Onlay	-	2	-	-	-	-
7.	Kuty Raman	62	M	454594	Indirect	Rt.	Onlay	+	6	-	-	-	-
8.	Masthan	60	M	473514	Direct	Rt.	Onlay	-	2	-	+	-	-

9.	Marimuthu	35	M	47699 9	Direct	Lt.	Onlay	-	2	+	-	+	-
10.	Rajan	30	M	48580	Indirect	Rt.	Onlay	-	4	-	-	-	-
11.	Selvaraj	25	M	48871 6	Indirect	Lt.	Onlay	+	6	-	-	+	-
12.	Pollaiah	28	M	49943 0	Indirect	Rt.	Onlay	-	2	-	+	-	-
13.	Mani	38	M	49338 9	Indirect	Lt.	Onlay	-	2	+	+	+	-
14.	Viswakumar	29	M	50371 6	Indirect	Rt.	Onlay	+	2	-	-	-	-
15.	Rosaiah	58	M	51028 8	Direct	Bil	Onlay	-	2	-	+	-	-
16.	Sulthan	30	M	51161 9	Indirect	Bil	Onlay	++	6	+	+	+	-
17.	Farook	60	M	51495 0	Direct	Rt.	Onlay	-	2	-	-	-	-
18.	Parthasarathy	54	M	51497 4	Pantaloo n	Rt.	Onlay	+	4	-	-	-	-
19.	Srinivasan	28	M	51638 2	Indirect	Rt.	Onlay	+	4	-	+	-	-

20.	Kannan	41	M	51059 6	Indirect	Lt	Onlay	-	2	-	-	+	-
21.	Rajkumar	25	M	50450 9	Indirect	Rt.	Onlay	+	4	+	-	-	-
22.	Ramani	44	M	47978 6	Indirect	Rt.	Onlay	-	4	-	-	-	-
23.	Anandhan	56	M	46548 5	Direct	Lt.	Onlay	-	4	-	+	-	-
24.	Viswanathan	70	M	51121 6	Direct	Bil.	Onlay	+	6	-	-	-	-
25.	Narayanan	51	M	51094 8	Indirect	Rt.	Onlay	-	2	+	-	-	-

reference

1. Andrew N. Kingsnorth, FRCS, Christine S. Porter RN, David H. Bennett, FRCS, Alisdair J. Walker, FRCSEd, Micheal E.Hyland, Ph.D., CPsychol, and Samantha Sodergren, B.Sc., Plymouth, England. Lichtenstein patch of Perfix plug and patch in inguinal hernia:

A prospective double blind randomised controlled trial of short term outcome. p.276-285, Surgery, March 2000, Volume 127 Number 3.

2. Bhollo Singh Sidhu, Harsha Bhola, Deepak Gupta Tension-free hernioplasty under local anaesthesia - Gilberts' Repair, p.14, Indian Journal of Surgery Volume 61 No.5, October - November 1999.

3. E.Nilson.S, Daniec M.S., G. Gruber and S.Sandblom, Methods of repair and risk for reoperation in Swedish hernia surgery from 1992 - 1996. p. Dec.1998. British Journal of Surgery Vol.85 Number12.

4. Elias Athanasakis M.D., Zenia Saridaki, MD., Alexandros Kafetzakis, MD, Emmanuel Chrysos MD, Ph.D, George Prokopakis,MD,Nickolaos, Vrahasothakis, MD, Evangelos Xynos MD, Ph.D. Crete Greece. Surgical repair of inguinal hernia:

Tension free technique with prosthetic materials (Gore-tex mycro mesh- expanded polytetra fluoroethylene) p.728-731. The American Surgeon, August 2000, volume 66, No.8.

5. Groin hernia Surgery - The surgical Clinics of North America Vol.78 No.6 Dec.1998.
6. J.Zieren B. Horsch, F.A. Wenger, I.Opitz, J.M. Muller, Berlin Gennany, Inguinal hernia repair in the new millennium - plug and patch repair with local anaesthesia. p. 8-14 1. World Journal of Surgery Feb.2001. Volume 25 Number 2.
7. John L. Cameron M.D., FACS FRCSFRCSI. Current Surgical Therapy 6 Edition. p.557 - 567.
8. John.A.Chuback, MD, Robert S.Singh, MD, Charles Sills, MD, and Leon S. Dick, MD, Newark and Long Branch, New Jersey. Small bowel obstruction resulting from mesh plug migration after open inguinal hernia repair, p.475-476. SURGERY April 2000 Volume 127 Number4
9. Kelvin Burnand, Anthoy.E. Young, H.B.Devlin, A.N. Kingsnorth, The New Aird's Companion in Surgical studies. Second edition. p.670-683.
10. Lichtenstein, Tension Free Mesh Repair, The American Journal of Surgery Feb.1989.
11. Mattioli F, Puglisi M, Priora F, Millo F, Bottaro P. Treatment of inguinal hernia: a prospective study comparing Bassini's procedure,

the inguinal pre-peritoneal prosthesis and the Lichtenstein technique; Chir Ital 2002 May-Jun;54(3):3 17-21

12. M. Townsend Jr.MD., W.Steve Eubanks MD., Sabiston Text book of Surgery - The biological basis of modern surgical practice - 1 6 Edition.p.783-801.
13. Michael J.Zinner; MD Facs, Seymour I. Schwartz MD, Harold Ellis CBE, DM, MCH, FRCS, Jack Abrahamson, Maingots' Abdominal operation 10 edition. - Vol.1 P.479 -580.
14. Peter Damilsson, Sune Isacson and Michael V. Hansen. Randomised study of Lichtenstein compared with Shouldice Inguinal Hernia repair by surgeons in training. p.49 - 53. The European Journal of Surgery Vol.165 No.1 January 1999.
15. Seghal, Baichanran S. Bhatia, Paramjit S. Beth, Rajesh Mehta, The Role of low lying pubic tubercle in the development of inguinal hernia p.263-265. Indian Journal of Surgery. Volume 62 Number 4 August - September - 2000.
16. Text book of Laparoscopy - Dr.C.Palanivel
17. CIGES Atlas of Laparoscopy - Dr.C.Palanivel