

FUNCTIONING OF DEEP LOBE OF THE PAROTID GLAND AFTER SUPERFICIAL PAROTIDECTOMY

**A DISSERTATION SUBMITTED IN PARTIAL FULFILLMENT OF
THE M.S. BRANCH 1 (GENERAL SURGERY) EXAMINATION
OF THE
TAMILNADU DR.M.G.R UNIVERSITY, CHENNAI,
TO BE HELD IN MARCH 2008**

CERTIFICATE

This is to certify that the dissertation entitled

**“FUNCTIONING OF DEEP LOBE OF THE PAROTID GLAND AFTER
SUPERFICIAL PAROTIDECTOMY”**

is the bonafide original work of

Dr. T. Joseph Victor Gnanadurai

during his academic term in **Christian Medical College & Hospital, Vellore** in partial fulfillment of the **M.S Branch 1 (General Surgery)** examination of the **Tamilnadu Dr.M.G.R University, Chennai** to be held in **March 2008**.

Dr. John. C. Muthusami MS,
Professor & Head,
General Surgery Unit 1,
Christian Medical College,
Vellore, Tamilnadu.

Dr. Venkatramani Sitaram MS, FRCS(G),
Professor & Head,
Department of General Surgery,
Christian Medical College,
Vellore, Tamilnadu.

Acknowledgements:

Firstly, I thank God for giving me the opportunity and strength to complete this study. I would like to express my gratitude and thankfulness to Dr. John C. Muthusami and all my teachers for their constant support, encouragement and suggestions. I would like to specially thank Dr. Regi Ommen, Professor and Head, Department of Nuclear Medicine, Faculty and all the staff members of the department for their great help. I wish to thank my friends and family members for their encouragement and support.

Table of contents:

Page numbers

1. Introduction	2
2. Aims and objectives	4
3. Materials and methods	6
4. Review of literature	19
5. Observation and results	68
6. Discussion	90
7. Conclusions	93
8. Statement of limitations	94
9. Comments	95
10. Bibliography	97
11. Annexure	104

Introduction

1. Introduction:

Salivary fistula rarely occurs after superficial parotidectomy, an incidence of 0.02%. This is an unusually low incidence considering the surgical procedure of cutting across the gland. It is postulated that:

1. The innervation of the deep lobe is through the superficial lobe, branches from the auriculo-temporal nerve. While removing the superficial part these nerves are severed and the deep lobe loses its innervation. As a result of this there is no secretion of saliva and the deep part gradually atrophies.
2. The duct arises mainly from the deep lobe and the superficial lobe secretions drain into the main duct via small ductules that cross the facio-venous plane of Patey to enter the deep part. Hence there is preferential flow which remains intact.
3. Fistula formation is based on multiple branching pattern of the Stenson's duct.

There are no definite studies or trials on the above postulates. This study attempts to focus on the reduction in function of the deep part of the parotid gland following superficial parotidectomy, proving hypothesis number one.

Hypothesis:

The deep lobe of the parotid gland atrophies and ceases to function after the surgical procedure of superficial parotidectomy.

Aims and Objectives

2. Aims and objectives:

To assess the functioning of the remnant deep lobe of the parotid gland after superficial parotidectomy.

Materials and Methods

3. Materials and methods:

Based on this background knowledge, a prospective analytical study was designed to assess the function of the remnant deep lobe of the parotid gland after superficial parotidectomy in the Department of General Surgery , Christian Medical College and Hospital, Vellore. Lesions were confirmed clinically and all of them had Fine needle aspiration Cytology done prior to surgery. The same surgical technique of superficial was adapted in all the cases. During the period , May 2006 to July 2007, men and women undergoing superficial parotidectomy for all diseases of the parotid gland fulfilling the inclusion criteria were subjected to a prospective trial to assess the functioning of the remnant deep lobe of the parotid gland as compared to the opposite non-operated side deep lobe after superficial parotidectomy by Technetium - 99 scan on the tenth day and sixth week after surgery and on the on the same days, salivary secretion from the remnant gland was quantified by modified Saxon's test. All patients were included in the trial after obtaining written informed consent. Details were documented in the proforma made for the purpose.

Exclusion criteria:

- Recurrent disease
- Patients requiring post operative radiation
- Patients who had previous radiation in the head and neck region
- Deep lobe involvement
- Malignancy – intermediate and high grade
- Pregnancy
- Subtotal superficial parotidectomy
- Tuberculosis of the parotid gland

Sample size:

Based on the criteria set out, 20 patients were enrolled in the study after obtaining written informed consent.

Saxon's test:

This test involves chewing on a folded sterile sponge for 2 minutes. Saliva production is measured by weighing the sponge before and after chewing.

Normal control subjects produce greater than or equal to 2.75 gm of saliva in 2 minutes. This test was modified and used in this trial.

Procedure:

1. Clinical test (Modified Saxon's test):

On the days of the first and second scans, the salivary secretions from the glands on both sides were quantified. A Vacutainer[®] was used with a small cut gauze piece instead of the sponge originally described (Fig. 1). The weight of the container with the gauze was measured using a standard chemical balance (Fig. 2). At a time two such containers were used, one for each side. The oral cavity was mopped dry with cotton and then the floor of the mouth was packed with gauze to absorb the secretion from the sub-mandibular and sub-lingual salivary glands. The Vacutainers were then opened and the gauze was packed in the upper gingivo-buccal sulcus in the region of the parotid duct opening on both sides for a period of 2 minutes. Salivation was stimulated by placing 2-3 drops of concentrated lemon juice over the dorsum of the tongue. After 2 minutes, the gauze pieces from the two sites were placed back into the respective containers and now the post test weight was measured. The net saliva secretion was the difference between the pre and post test readings for each side.

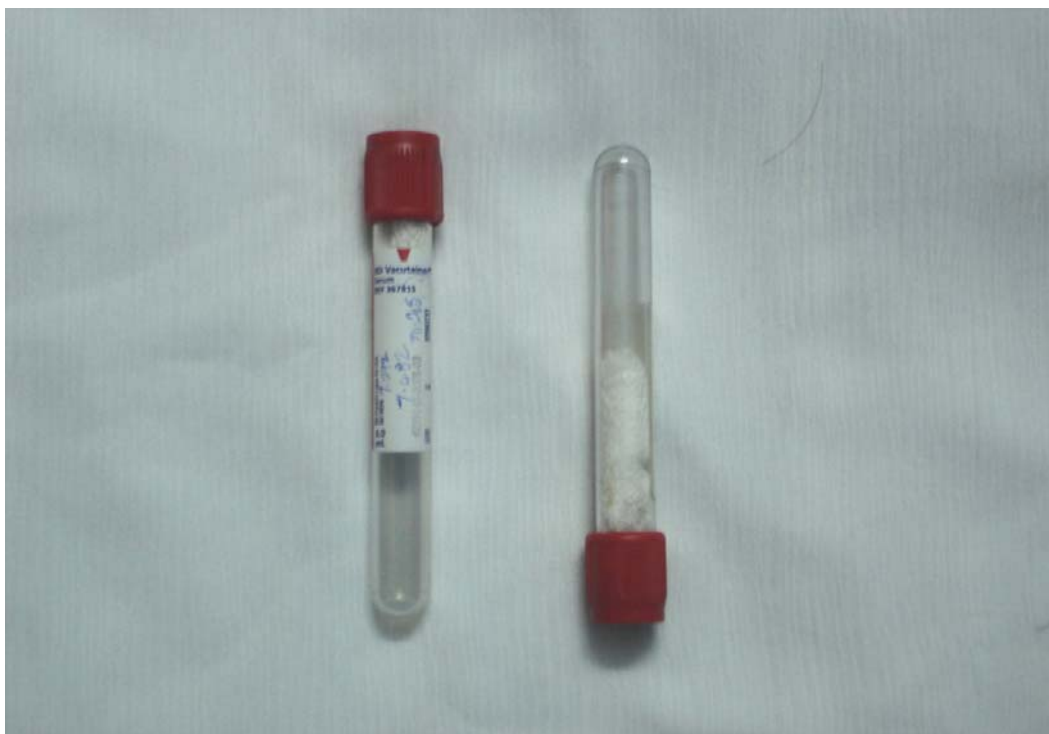

Figure 1. Vacutainers



Figure 2. Electronic chemical balance

2. Technetium 99 m pertechnetate scan:

The function of the parotid glands were also measured by parotid scintigraphy using radioactive Technetium 99m on the tenth day and at six weeks after the surgery. Technetium 99m is trapped and excreted by the salivary glands via the Na-K-Cl transport system in the basement membrane of the parotid acinar cells.

Parotid scintigraphy:

Following intravenous administration of 370 MBq of 99m Tc sodium pertechnetate, a scintigram (Fig. 5) was taken with a digital large field gamma camera and data analysis system using a low energy, high sensitivity, parallel hole collimator (Fig. 3 & 4). The images were digitally recorded in a 128 x 128 matrix. Duration of the scan was 30 to 45 minutes and the images of the salivary glands were acquired sequentially. Secretion from the salivary gland was stimulated with 2ml of concentrated lemon juice placed over the dorsum of the tongue for 2 minutes prior to the scan. Patients were also instructed not to swallow during imaging.

Semi-quantitative analysis was done by the same radiologist who was blinded to the patient's clinical information. Oval shaped regions of interest were drawn over the salivary glands (Fig. 6). Time activity curves were generated by background subtraction. For each salivary gland the maximum uptake was calculated.

The function of the gland was calculated using the following expression:

- **Function of the gland = (Maximum uptake – background)/background**
- **Percentage function of the affected gland = (Function on the affected side/function on the normal side) x 100%**

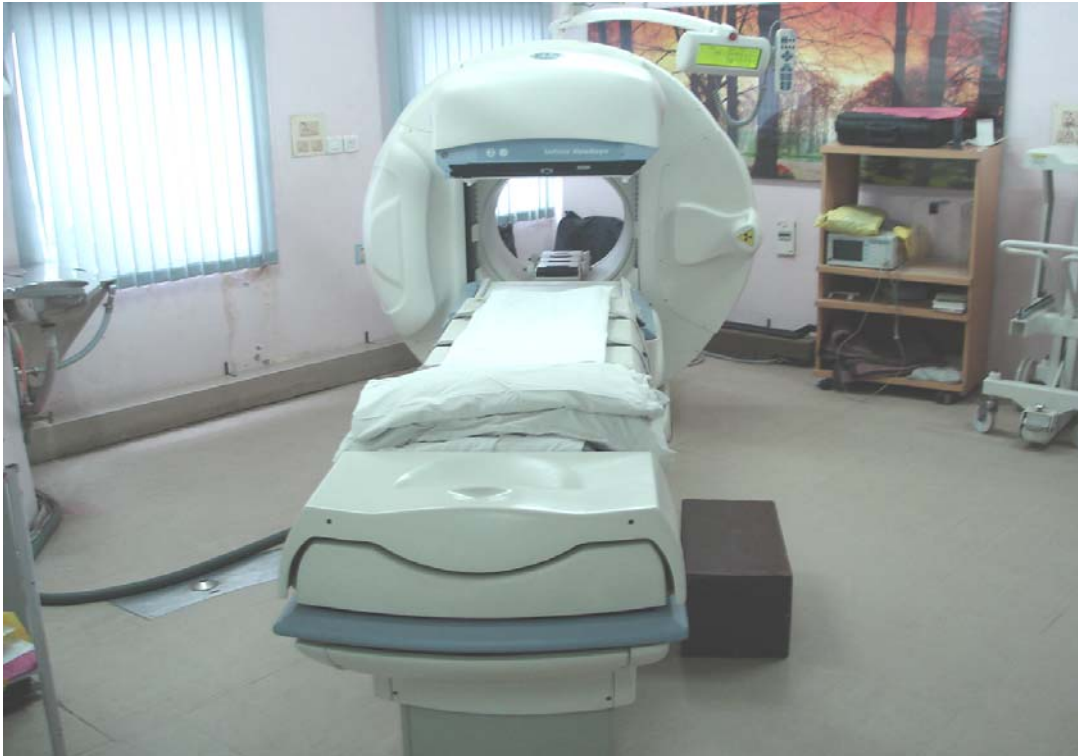

Figure 3: Gamma camera (Infinia-Hawkeye GE camera)

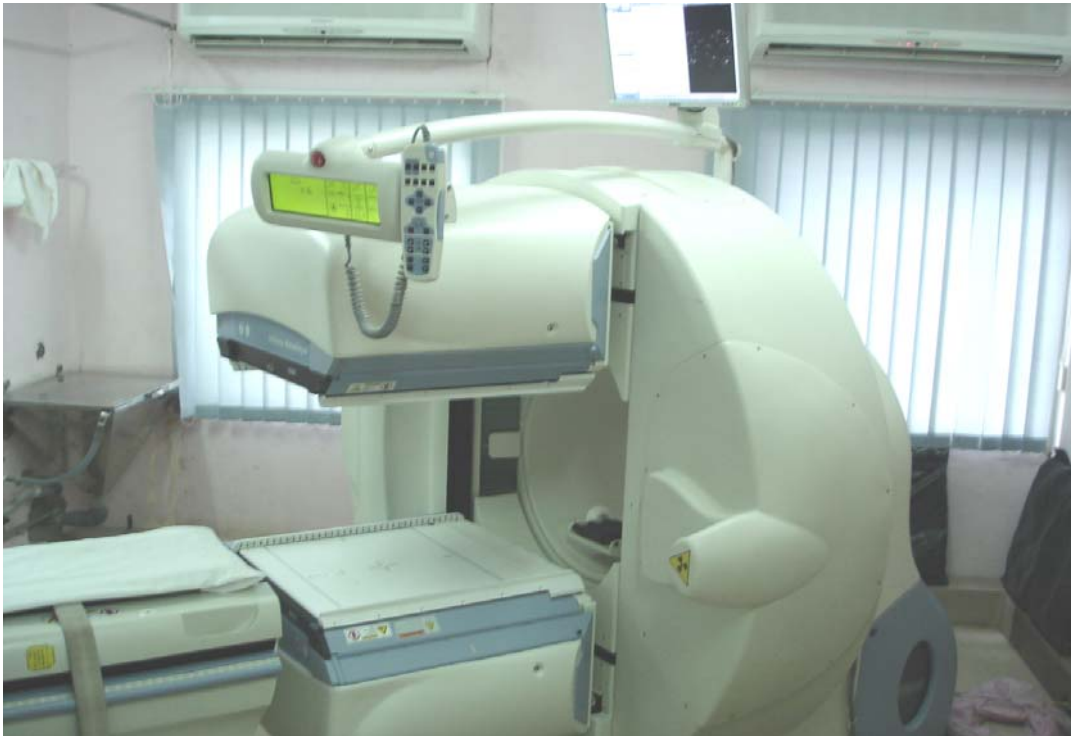

Figure 4: Gamma camera

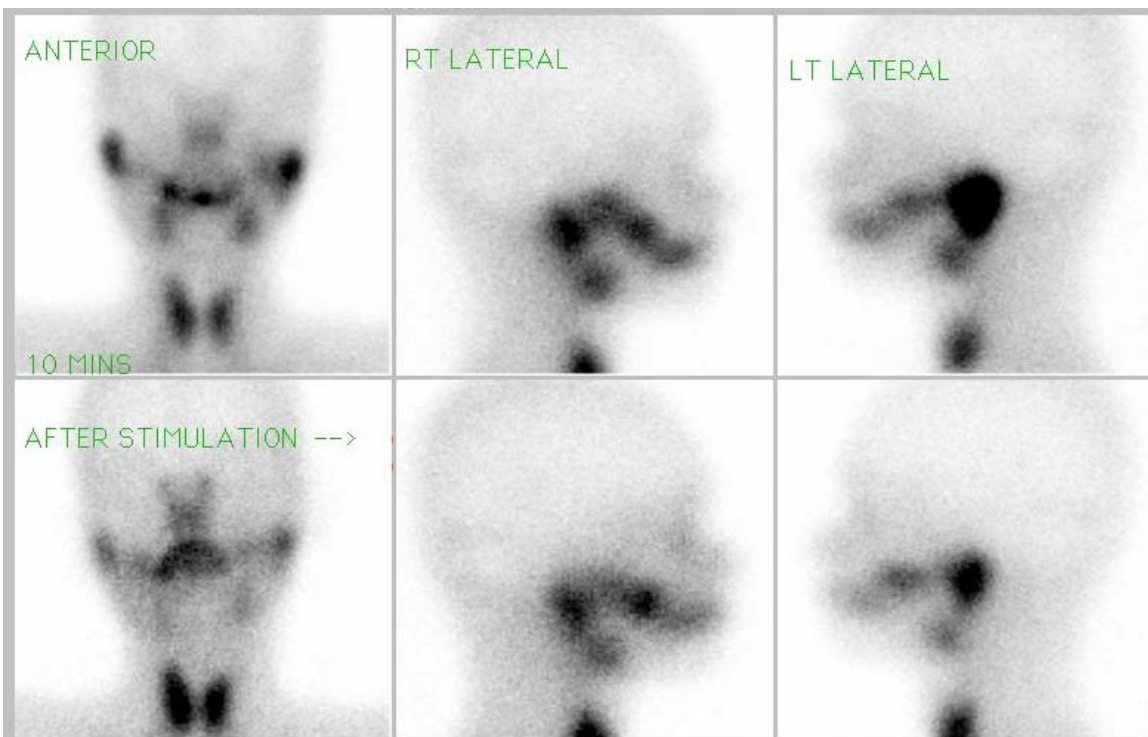


Figure 5: Parotid scan

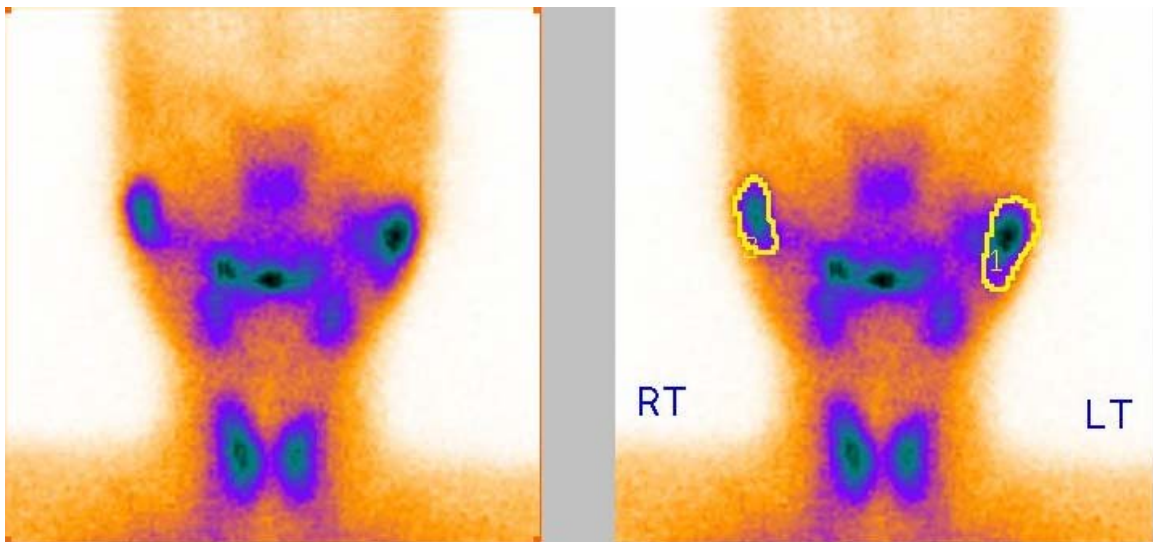


Figure 6: Measuring the uptake

Surgical technique:

Sistrunk's incision was made, raising a skin flap as required and leaving as much of the superficial musculo- aponeurotic system attached to the skin. The gland was separated from the cartilaginous external auditory canal and the anterior border of the sternocleidomastoid muscle. After identifying the facial nerve exiting at the stylo-mandibular foramen, the superficial lobe was lifted off by dissecting lateral to the branches. After achieving hemostasis, the skin flap was closed over a suction drain. Attempt was made to preserve the Stenson's duct.

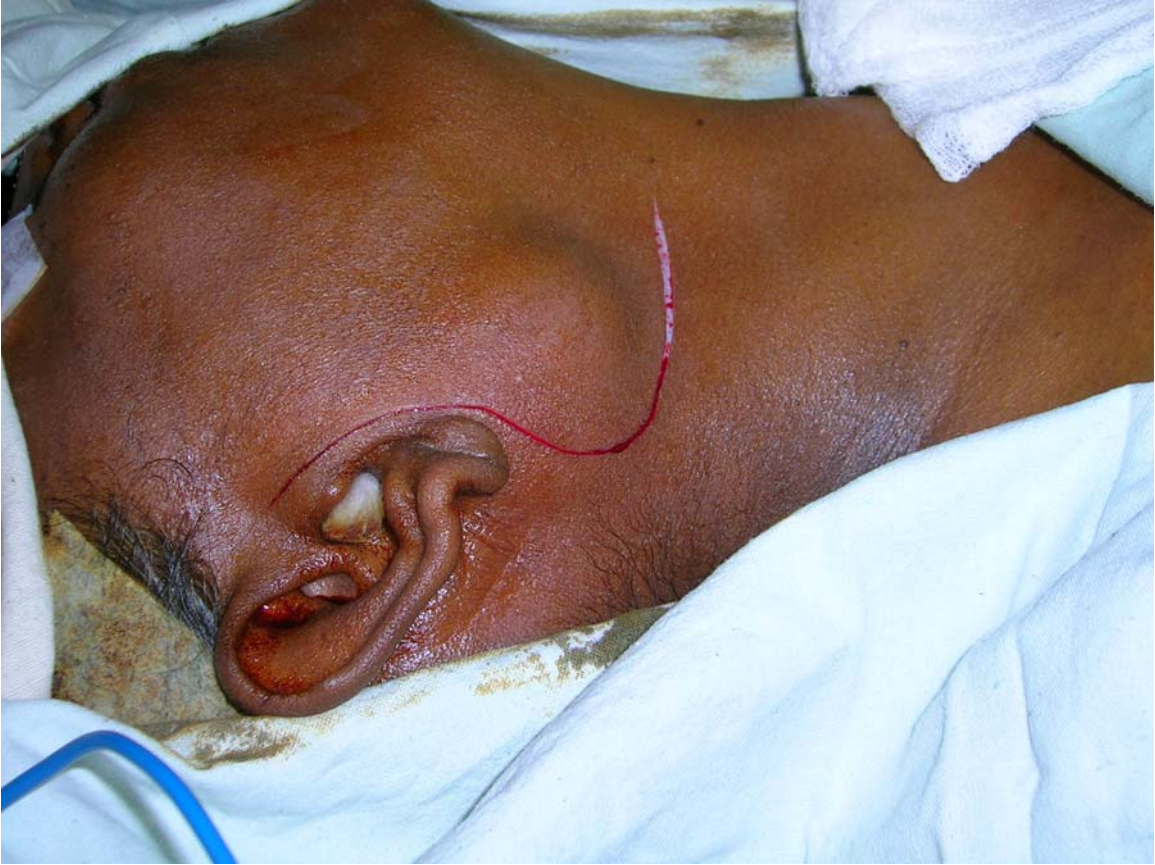

Figure 7: Superficial parotidectomy: - Sistrunk's incision

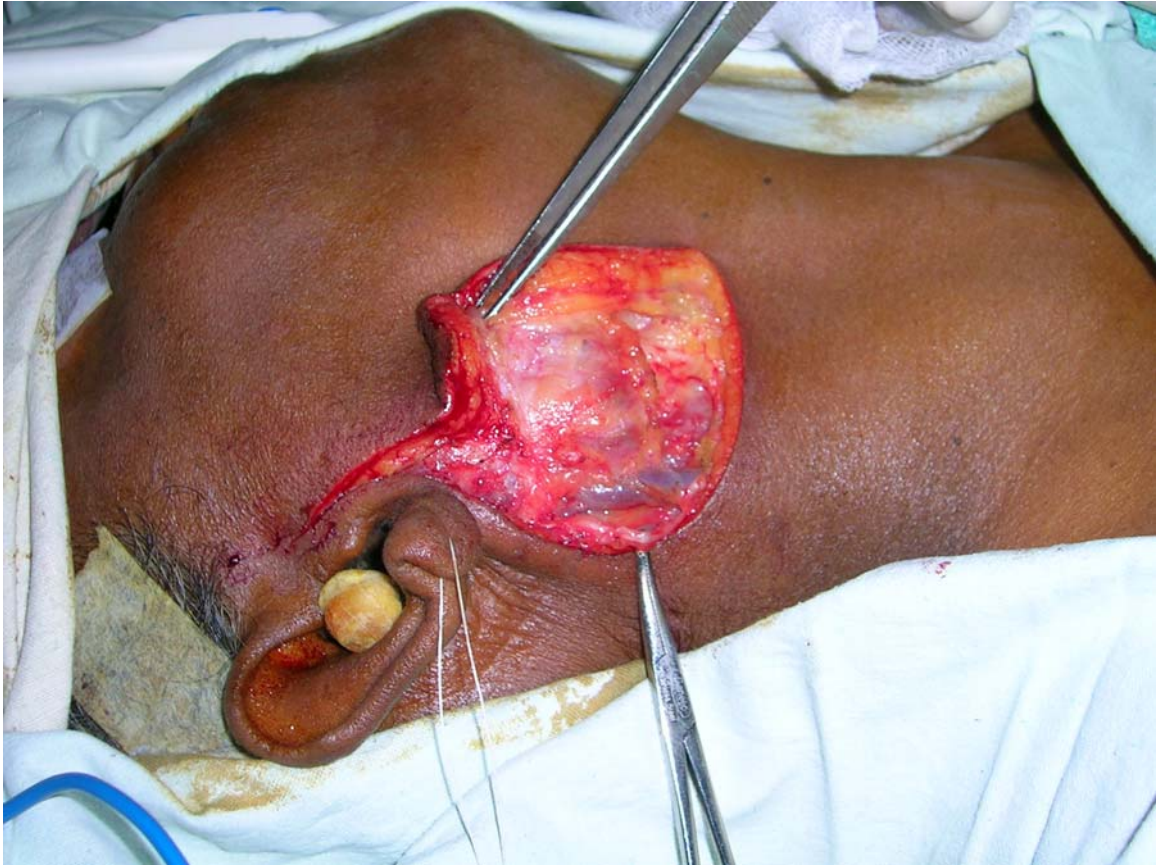

Figure 8: Superficial parotidectomy - Preservation of greater auricular nerve (lower clamp)

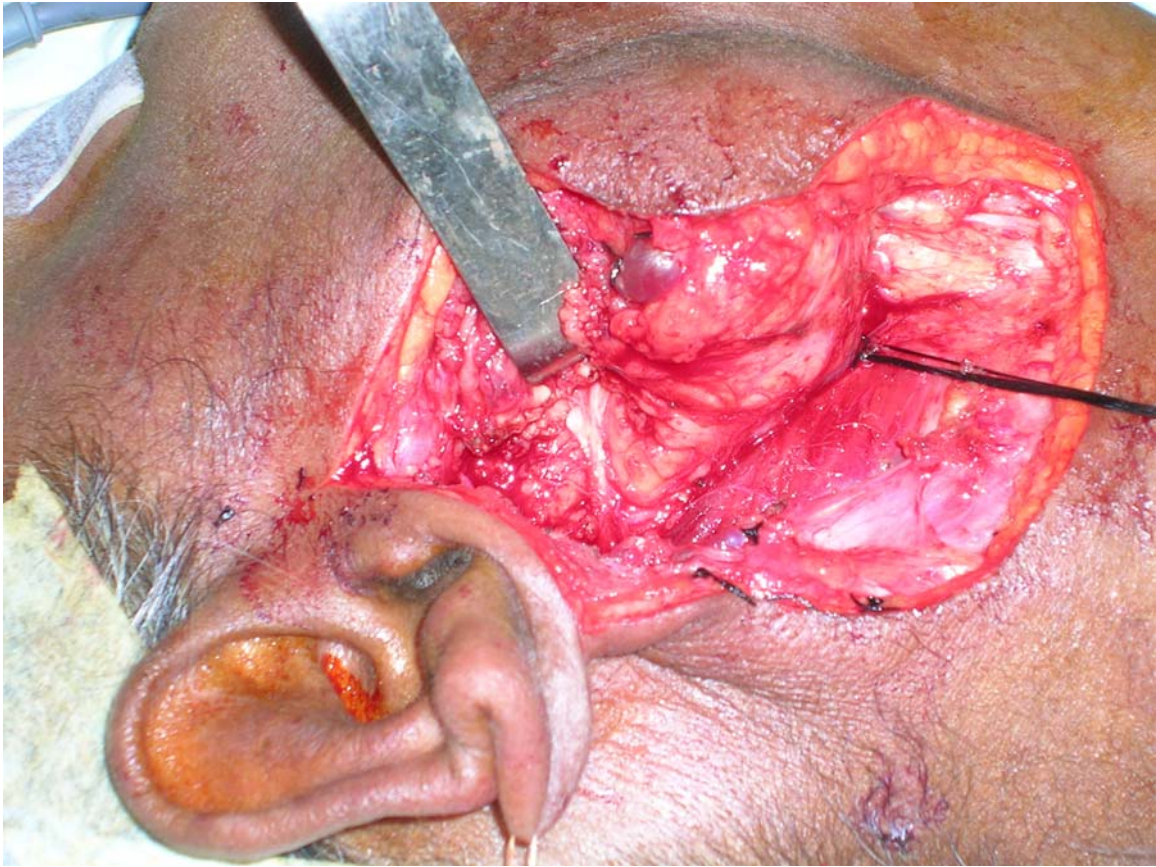


Figure 9: Superficial parotidectomy – Facial nerve identification

Post operative studies:

Patients were reviewed on the tenth day and six weeks later after surgery and each had modified Saxon's test and parotid scintigraphy at these times.

Statistical methods:

The data was described using summary statistics such as mean, median, range and standard deviation. Univariate and bivariate graphs were plotted. Mann – Whitney test was used for analyzing unpaired groups and Wilcoxon signed rank test was used for paired data analysis. A 'p' value of less than 0.05 at 95% confidence intervals was considered significant. The data analysis was performed using SPSS 11.0 for windows.

Ethical issues:

All the patients were explained about the safety of the radiation dose used for the scintigraphy. The dose was 370 mBq which was a safety dose.

Review of Literature

4. Review of literature:

Anatomy of the parotid gland:

Parotid glands are the largest salivary glands. Each has an average weight of 25 gm and is an irregular, lobulated, yellowish mass. It lies largely below the external auditory meatus between the mandible and sternomastoid muscle. The gland projects forwards on the surface of the masseter muscle where usually a detached part, the *pars accessoria or socia parotidis*, lies between the zygomatic arch above and parotid duct below. The parotid consists almost entirely of serous glandular tissue.

The capsule of the gland is derived from the deep cervical fascia; its superficial layer is dense, closely adherent and sends fibrous septa into the gland, it is attached to the zygomatic arch. Medial to the gland, it is attached to the styloid process, mandible and tympanic plate blending with the fibrous sheaths of the related muscles. The fascia extending from the styloid process to the mandibular angle forms the stylo-mandibular ligament which intervenes between the parotid and submandibular glands.

The parotid gland is like an inverted, flat, three-sided pyramid, presenting a small superior surface and superficial, antero-medial and postero-medial surfaces; it tapers inferiorly to a blunt apex. The superior, concave surface is related the cartilaginous part of the external auditory

meatus and posterior aspect of the temporo-mandibular joint; here the auriculo-temporal nerve curves round the neck of the mandible, embedded in the gland's capsule. The apex overlaps the posterior belly of the digastric muscle and carotid triangle to a variable extent.

The superficial surface is covered by skin and superficial fascia, the latter contains the facial branches of the great auricular nerve, superficial parotid lymph nodes and posterior border of platysma muscle. It extends upward to the zygomatic arch, backward to overlap the sternomastoid, downward to its apex postero-inferior to the mandibular angle and forward superficial to the masseter below the parotid duct.

The antero-medial surface is grooved by the posterior border of the ramus of the mandible. It covers the postero-inferior part of the masseter, the lateral aspect of the temporo-mandibular joint and the adjoining part of the mandibular ramus, passing forward medial to the ramus to reach the medial pterygoid muscle. Branches of the facial nerve emerge on the face from the anterior margin of this surface.

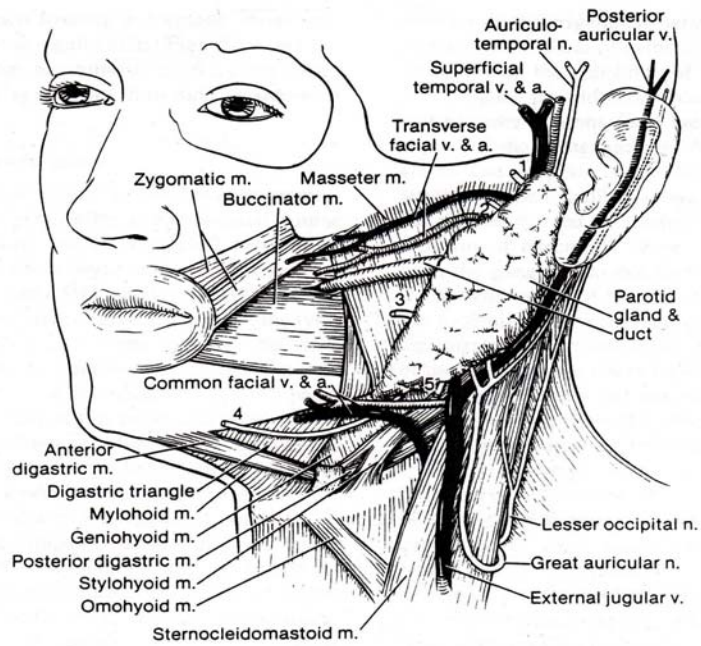
The postero-medial surface is moulded to the mastoid process, sternomastoid, posterior belly of the digastric and the styloid process and its muscles. The external carotid artery grooves this surface before entering the gland. The internal carotid artery and internal jugular vein are separated

from the gland by the styloid process and its muscles. The antero-medial and postero-medial surfaces meet at a medial margin, which may project so deeply as to be in contact with the lateral wall of the pharynx.

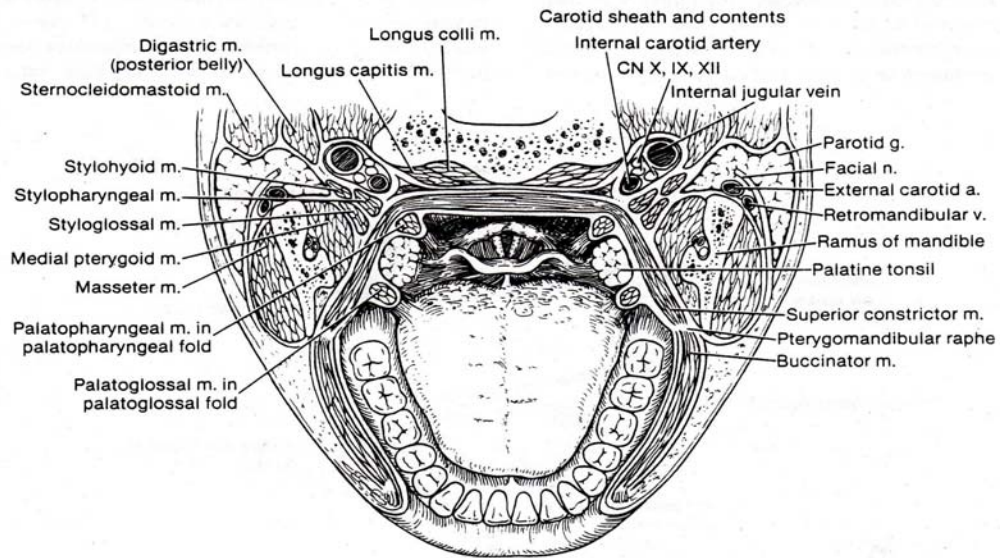
Several structures traverse the gland partly or wholly and even branch within it. The external carotid artery enters the postero-medial surface, dividing into the internal maxillary artery, which emerges from the antero-medial surface and the superficial temporal artery, which gives off its transverse facial branch in the gland and ascends to leave its upper limit. The posterior auricular artery may also branch from the external carotid within the gland, leaving by its postero-medial surface. The retro-mandibular vein, formed by the union of the maxillary and superficial temporal vein, is superficial to the external carotid artery; its posterior division emerges behind the gland's apex to join the posterior auricular vein, forming the external jugular and its anterior division emerges anterior to the apex to join the anterior facial vein, forming the common facial vein. Most superficial is the facial nerve, entering high on the postero-medial surface and passing forward and down behind the mandibular ramus in two main divisions, from which its terminal branches diverge to leave by the antero-medial surface, passing medial to its anterior margin.

The parotid gland develops as an outgrowth from the buccal cavity,

spreading back toward the ear and covering the facial nerve, prolongations of the gland penetrate medially between the branches of the nerve to form its deep part; the largest part being between the nerves main temporal and cervical divisions (Bailey 1947; McKenzie 1948)^{2, 3}. These processes finally engulf the nerve and its branches, which are sometimes considered to divide the gland into a superficial and a deep lobe.



Parotid gland and surrounding structures. Branches of the facial nerve: 1, Temporal; 2, zygomatic; 3, buccal; 4, mandibular (marginal); 5, cervical.



Medial relations of parotid gland.

Figure 10: Parotid gland

Parotid duct:

About 5 cm long, this begins by the confluence of two main tributaries within the anterior part of the gland, then crosses the masseter and at its anterior border turns medially at almost a right angle, traversing the buccal pad of fat and buccinator muscle. It then runs obliquely forward for a short distance between the buccinator and the oral mucosa to open upon a small papilla opposite the second upper molar crown. While crossing the masseter, it receives the accessory parotid duct and here it lies between the upper and lower buccal branches of the facial nerve; the accessory part of the gland and the transverse facial artery are above it. The buccal branch of the mandibular nerve, emerging from beneath the temporalis and buccinator, is just below the duct at the masseter's anterior border.

The parotid duct, as seen in lateral sialograms, is formed near the centre of the posterior border of the mandibular ramus by the union of two ducts, which respectively, ascend and descend at right angles to the main duct. The intraglandular part of the main duct receives an alternating series of descending and ascending tributaries, each formed from an arborization of fine ductules receiving acini. The acini usually do not show as dilatations in sialograms but are represented by the free endings of the smallest ducts. As it crosses the face, it also receives from above five or six ductules from the accessory parotid gland.

Blood supply:

The parotid arterial supply is from the external carotid and its branches within and near the gland. The veins drain into the external jugular, through local tributaries. The lymphatics end in the superficial and deep cervical lymph nodes, interrupted by two or three lymph nodes lying on and within the gland.

Innervation:

The efferent innervation is autonomic, which consists of the sympathetic fibres from the external carotid plexus while the parasympathetic fibres reach it via the tympanic branch of the glossopharyngeal nerve relaying in the otic ganglion and thence traveling along the auriculo-temporal nerve. The gland also receives secretomotor fibres through the chorda tympani nerve (Reichert and Poth 1933; Diamant and Wilberg 1965)^{4,5}. In dogs, secretomotor fibres pass to the parotid gland from the maxillary plexus and the facial and auriculo-temporal nerves, but this type of distribution of secreto-motor fibres is not confirmed in man (Holmberg 1972)⁶. The termination of these supplies is still controversial. In cats, both parasympathetic and sympathetic fibres end in relation to glandular cells (Genis-Galvez et al. 1966)⁷. Most salivary glands, except those secreting spontaneously, depend on autonomic nerves to evoke

secretion. The nerves involved are cholinergic (parasympathetic) and adrenergic (sympathetic) (Garrett 1976)⁸. Cholinergic nerves often accompany the ducts and arborize freely around thesecretory end pieces, but adrenergic nerves usually enter the gland along thearteries and ramify with them. Although there are separate sympathetic axons for secretion and vasoconstriction (Emmelin and Engstrom 1960)⁹, the cholinergic nerves may also induce myoepitheliocyte contraction. Infact, a single parasympathetic axon may induce vasodilatation, secretion and myoepitheliocyte contraction (Emmelin,1972)¹⁰. Secretory end pieces usually have the most innervation, cholinergic and adrenergic, individual cells often having both. Cholinergic axons have long been accepted as the secretomotor innervation; however, in the parotid gland of the rat, at least, sympathetic nerves are also secretomotor (Harrop and Garrett 1974; Hodgson and Spiers 1974)^{11, 12}. The innervation of myoepitheliocyte is sympathetic and parasympathetic (Kagayama and Nishiyama 1972; Garrett 1975)^{13, 14}. Salivary arterioles are supplied by both adrenergic (vasoconstriction) and cholinergic (vasodilatation) axons (Young and van Lennep 1978)¹⁵.

In parotid surgery, the facial nerve is reliably found between the mastoid process and the bony part of the external auditory meatus, where it lies 4 mm deep to the junction of the bony and the cartilaginous segments of

the meatus above the upper border of the posterior belly of the digastric muscle. It can then be traced forward following all its branches (Shaheen 1984)¹⁶.

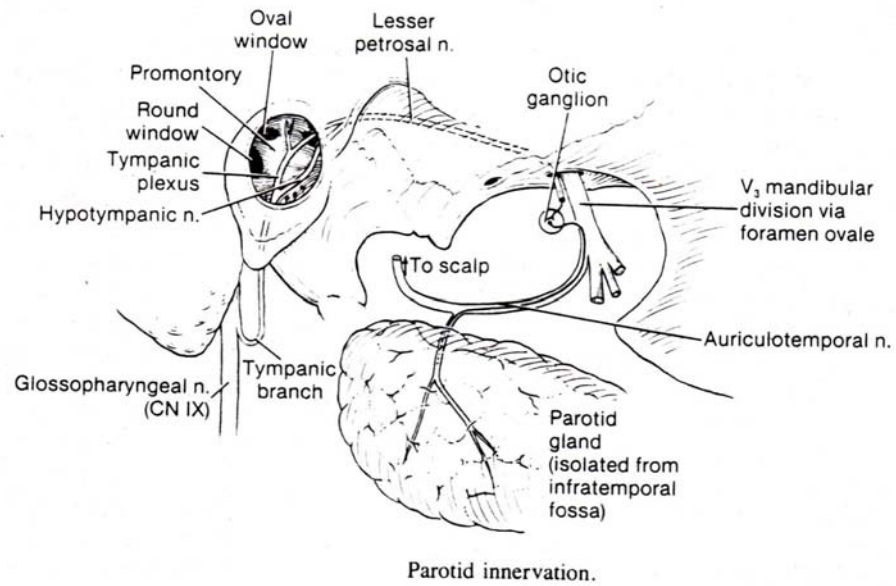


Figure 11: Innervation of the parotid gland

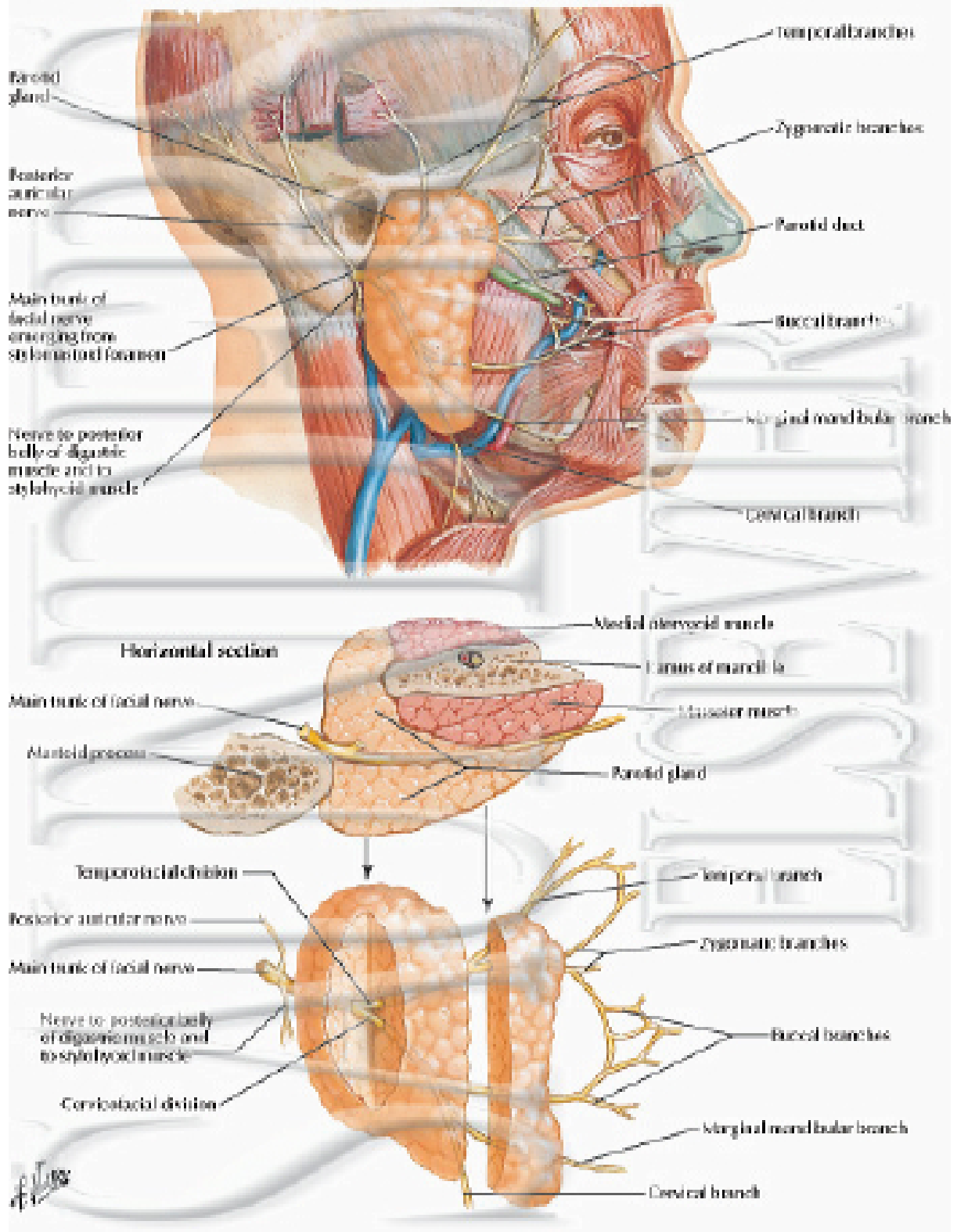


Figure 12: Parotid gland and its relations

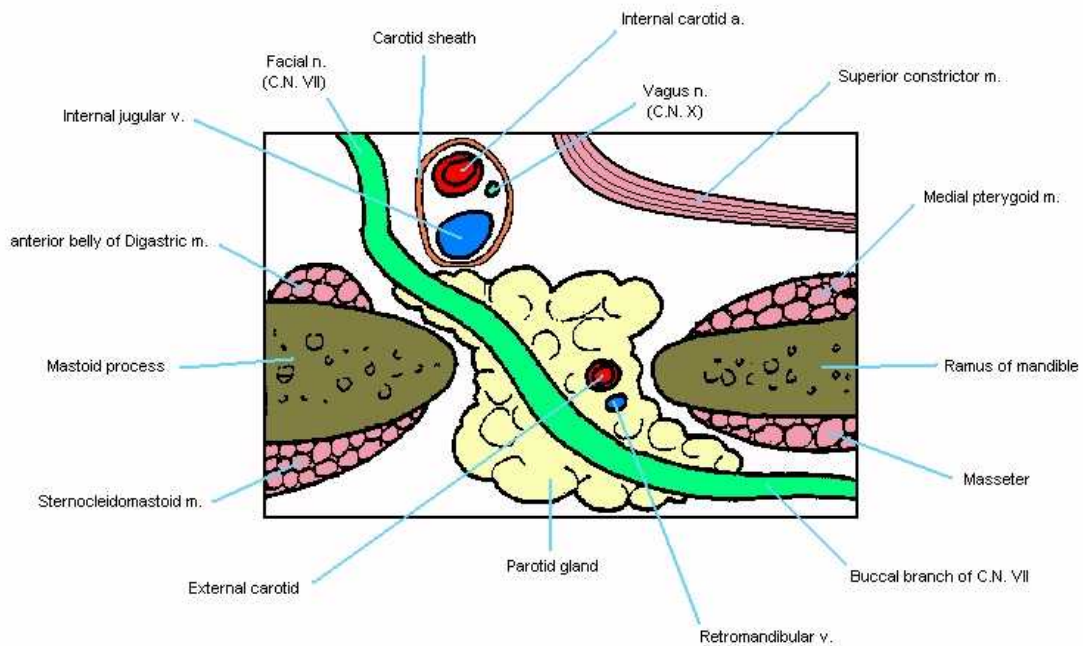


Figure 13: Cross-section of the parotid gland

Coverings:

The gland is invested by an inner true and outer false capsule. True capsule is formed by condensation of the fibrous stroma of the gland. False capsule or parotid sheath is formed by the splitting of the investing layer of the deep cervical fascia. The superficial lamella of the sheath is strong, attached to the lower border of the zygomatic arch and blends with the epimysium of the masseter muscle to form a thick parotido-masseteric fascia.

Presenting parts:

The gland presents an apex or lower end, base or upper surface, three surfaces, superficial, antero-medial and postero-medial, and three margins, anterior, posterior and medial. Apex is directed below, overlaps the posterior belly of the digastric muscle and extends to the carotid triangle. Structures emerging at the apex are cervical branch of the facial nerve, anterior division of the retro-mandibular vein, posterior division of the retro-mandibular vein. Base is concave and is related to the external auditory meatus and back of the temporo-mandibular joint. Structures emerging at the base are temporal branch of the facial nerve, superficial temporal vessels, and auriculo-temporal nerve.

Superficial (lateral) surface is covered by the skin, superficial fascia, posterior fibres of platysma and superficial lamella of the parotid sheath. The superficial fascia contains the superficial group of parotid lymph nodes and branches of great auricular nerve, which supply the skin over angle of the mandible.

Antero-medial surface of the gland is grooved by ramus of the mandible and presents the following relations. Postero-inferior part of the masseter, posterior border of the mandibular ramus, capsule of the temporo-mandibular joint, medial pterygoid muscle, outer lip of the groove

transmitting branches of the facial nerve, inner lip of the groove transmitting maxillary artery medial to neck of the mandible.

Postero-medial surface of the gland is extensive and is related to mastoid process, sternomastoid, posterior belly of the digastric, styloid process, styloid group of muscles, facial nerve entering the gland at the upper part of the surface, external carotid artery lodged on this surface before it enters the gland at this surface.

Anterior border of the gland is thin, rests on the masseter and separates the superficial from antero-medial surface. Structures radiating deep to this border are zygomatic branch of the facial nerve, transverse facial vessels, upper buccal branch of the facial nerve, parotid duct, lower buccal branch of the facial nerve, and marginal mandibular branch of the facial nerve.

Posterior border of the gland rests on the sternomastoid and separates the superficial from the postero-medial surface. Structures passing upward and backward deep to this surface are posterior auricular branch of the facial nerve and posterior auricular vessels.

Processes of the gland:

Facial process is a triangular projection extending forward superficial to the masseter along the parotid duct.

Pterygoid process is a triangular process sometimes extending forward from the deep part between the mandibular ramus and medial pterygoid muscle.

Glenoid process extends upward between the external auditory meatus and capsule of the temporo-mandibular joint.

Pre-styloid process is the gland in front of the groove for styloid process and is related to the internal carotid artery.

Post-styloid process is behind the groove for styloid process and may be related to the internal jugular vein.

Embryology of the parotid gland:

Understanding of the development of the parotid gland revealed that the primordium from which the main duct develops is always medial to the facial nerve rami. Also the auriculo-temporal branches are also closely related to the facial nerve plane. There is some evidence to suggest this, According to Raymond F Gasser in the article, **“The Early Development of the Parotid Gland around the Facial Nerve and Its Branches in Man”**, the development of the parotid gland centers and the related facial nerve branches were studied with the aid of reconstructions in 15 human embryos and fetuses 18 to 80 mm, crown-rump length, 7 + to 13.5 weeks (w), gestational age ¹⁷. Peripheral branches of the nerve terminate in the cervico-mandibular region at 18 mm (7 + w), when the unbranched- parotid bud is farther rostral. By 22 mm (8w), a small nerve branch approaches the buccal region superficial to the bud that extends toward the pre-auricular region. At 26 mm (8.5w), several nerve branches course superficial to the parotid primordium which has first order ductules and is adjacent to the masseter muscle. Second order ductules form quickly (27 mm. 8.5w) as the primordium approaches the superficial aspect of the lower buccal, marginal mandibular and cervical nerve branches. The primordium enters the parotid space by 32 mm (9w) as third order ductules develop. At 37 mm (10w), it

has fourth order ductules and the buccal branches are superficial to the main duct. Nerve branches of the temporo-facial ramus (temporal, zygomatic and upper buccal) occupy a superficial position in the primordium whereas branches of the cervicofacial ramus (lower buccal, marginal mandibular and cervical) are deeper. A similar arrangement is evident at 56-80 mm (11.5-13.5w) when the complex primordium has connections with its superficial and deep portions between many nerve branches. Tumors that occur in the human parotid gland often require removal by partial or total parotidectomy. Such an operation is hazardous because of the intimate relationship the gland has with the facial nerve that supplies the muscles of expression. In order to define this relationship, many authors have reported studies on dissected adult and infant specimens. (e.g., Gregoire,¹⁸; McWhorter,¹⁹; Mc-Cormack Cauldwell and Anson,²⁰; Mc-Kenzie,²¹; Davis et al.,²⁶; Patey and Ranger,²⁷; Youssef, Talaat and El-Malt²⁸). However, these studies summarize the results by the time the gland –nerve relationship has already become intricate and very complex. There is consistent lack of uniformity in the conclusions drawn with regard to whether the gland is uni or bilobed, whether or not a cleavage plane exists in the gland where the nerve passes through and where and how many areas of communication (isthmi) exists between the superficial and deep portions of the gland. Gregoire,

McWhorter, McKenzie, and Sammarco, Ryan and Longenecker here tried to clarify the relationship with reports on newborns and late fetuses, but even in these specimens, the relationship is too complex^{18, 19, 21, 29}.

A better understanding of the relationship is gained with information on the early development of the gland around the nerve. The relationship is easier to define at this time because the morphology of the gland is simple. Such information however, at best is incomplete and, in some instances, questionable. Bujard briefly mentioned a relationship in one 35 mm fetus²⁴. The earliest fetus examined by Gregoire was 80 mm when the arrangement is already quite complicated¹⁸. Shulte did not discuss the nerve in his detailed account of early salivary gland development³³. The first significant contribution on the early relationship was made by Rouviere and Cordier, who studied two specimens (31 and 31 mm)³⁰. Additional specimens were examined by Winsten and Ward and Brunner but they reported no pattern in the formation of the relationship and incompletely defined the relationship between the gland and the peripheral branches of the facial nerve^{31, 23}. The investigations of Cody and Samengo, insufficiently covered the early arrangement and some of their statements together with some of Winsten's and Ward's are disputed^{25, 32, 31}.

The authors of this paper describe the early morphogenesis of the

parotid gland around the extra cranial branches of the facial nerve and the related blood vessels in man. The manner in which the gland-nerve relationship develops with the pattern that it follows is given. It is hoped that such basic information will prove helpful to those who treat conditions involving the pre-auricular and buccal regions. A better understanding of the early arrangement should also help explain variations that are sometimes encountered at the operating and dissecting tables.

The sequence of development of the parotid gland around the facial nerve and its branches, the related parts of the retro-mandibular vein, and the external carotid artery is divided into four stages based on the location of the parotid gland primordium as it grows into the parotid space and on the degree of branching it exhibits.

Stage 1: The unbalanced parotid bud (18 to 22 mm, 7 + to 8 weeks)

The primordium of the parotid gland at 18mm is a simple, solid, short but broad, epithelial bud that extends into moderately dense mesenchyme (Fig. 14). It arises from the lateral most part of the oral epithelium, cranial to the angle of the mouth and grows dorsally and slightly laterally toward the first visceral groove. By 21-22 mm the bud is longer but narrower, remains unbranched and extends farther dorsally toward the pre-auricular region. The proximal part of the bud is narrower than its bulbous growing end.

Farther dorsally at 18 mm, the facial nerve terminates in the cervico-mandibular region, deep to the mandibular (pre muscle) lamina after coursing ventrally in the vanishing second visceral arch. Four fascicles are discernable in the distal part of the nerve. Definitive peripheral branches do not begin to form until 21-22 mm when the temporo-facial and cervicofacial rami are evident. The parotid bud is separated from the facial nerve terminals at 18 mm by the following structures from rostral to dorsal; the buccal nerve, inferior alveolar nerve, Meckel's cartilage and myelo-hyoid nerve. Both the bud and the facial nerve approach one another on a plane that is lateral to these structures. At 21-22 mm an upper buccal branch from the temporo-facial ramus lies lateral to the bud.

Caudal end

Cranial end

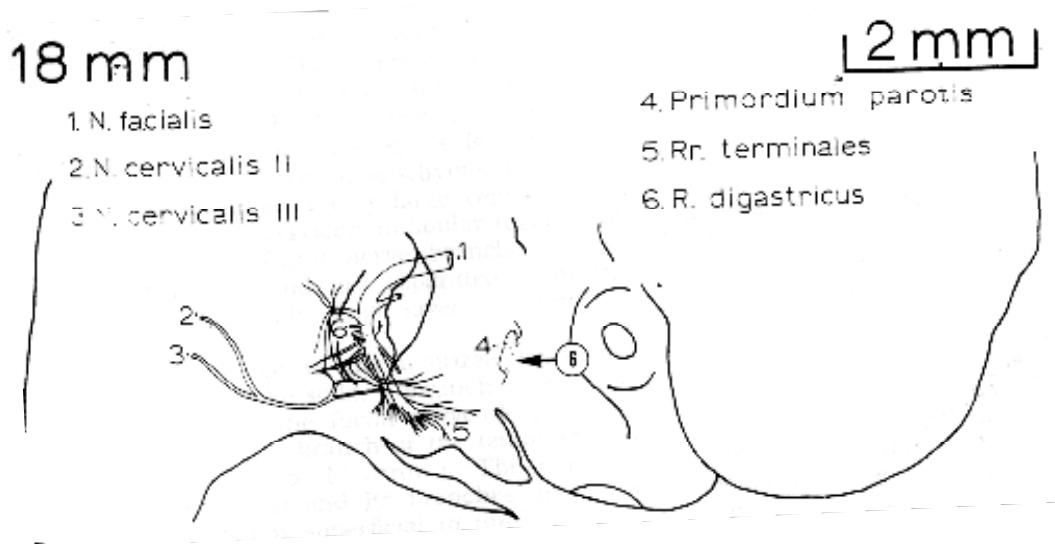


Fig.14. The arrangement of the facial nerve and parotid primordium at 18 mm, 7 + weeks.

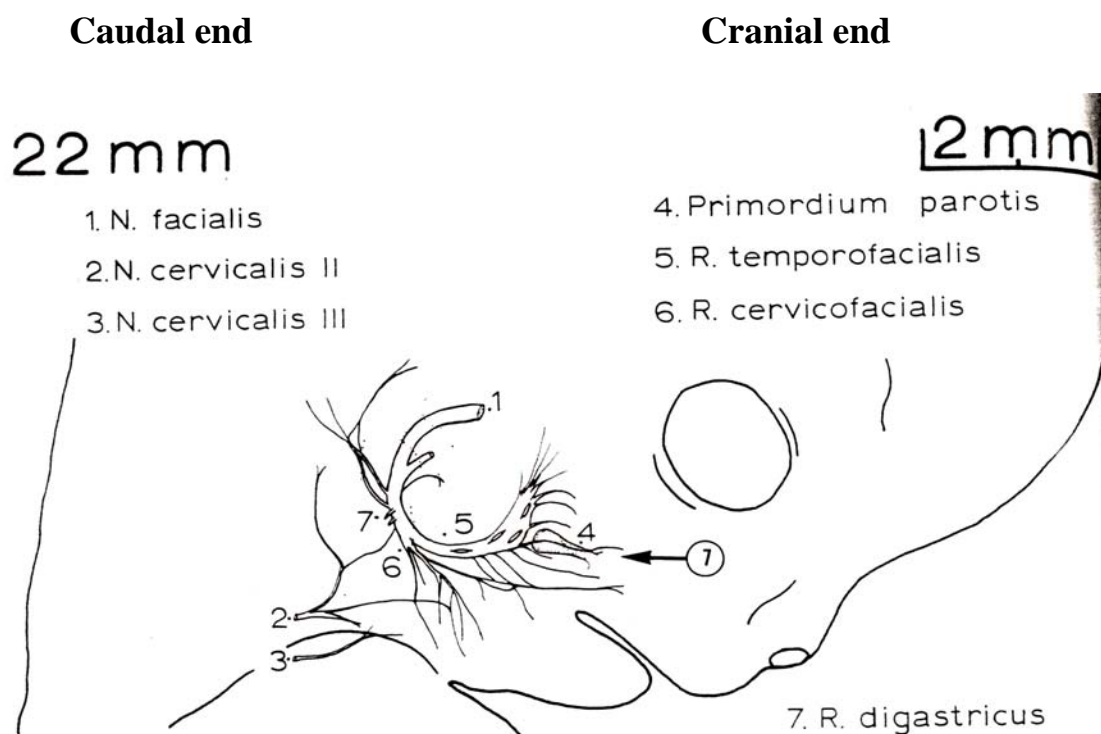


Fig.15. The arrangement of the facial nerve and parotid primordium at 22 mm. The outline of the auricle is indicated by a stippled line.

This stage is characterized by dorsal growth of the solid, unbranched bud that approaches the facial nerve deep to the upper buccal branch of the temporo-facial ramus (Fig.18,1⁰ arrow). The temporo-facial ramus and its branches are on a plane that is superficial to the bud while the cervicofacial ramus and its branches are on a plane that is slightly deep to the bud.

Stage II: First and second order branching of the parotid primordium

(26 to 27 mm, 8.5 weeks)

By 26 mm, the primordium can be sub divided into a long, narrow, proximal segment that is continuous with the oral epithelium and a large, bulbous, irregular shaped, distal segment that lies opposite the middle one-third of the masseter muscle (Fig. 16). The proximal segment will become the main parotid duct; lumen is developing in its middle part. The distal segment is a solid, epithelial mass that has knob-like projections extending from it that represent the first branch or ductules of the primordium. It undergoes secondary branching very quickly. Ducts that extend dorsally and laterally are not prominent. Moderately dense mesenchyme surrounds the primordium and separate it medially from the masseter muscle. Accessory parotid tissue is sometimes present as one or more isolated buds arise from the main duct near the mid of the masseter muscle.

Caudal end

Cranial end

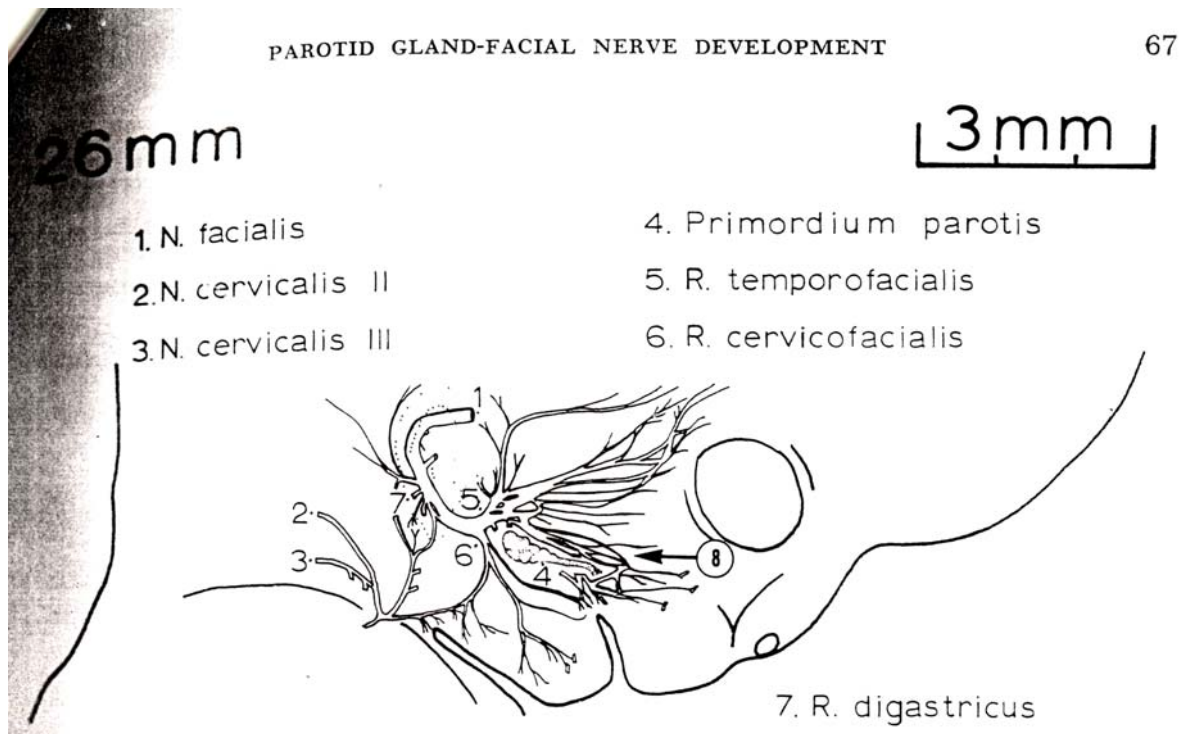


Fig.16. The arrangement of the facial nerve and parotid primordium at 26 mm, 8.5 weeks.

Definitive relationships are established during this stage between the peripheral branches of the nerve and the larger drainage ductules of the gland. Buccal branches are closely related to the primordium. Buccal branches were never observed medial to the proximal segment of the primordium that forms the main duct.

At 26 mm, a large venous plexus is in the superficial part of the cervico-mandibular region near the dorsolateral aspect of the masseter muscle. By 27 mm, the retro-mandibular vein is in its definitive location

medial to the facial nerve and lateral to the external carotid artery.

In this stage, those branches that arise from the temporo-facial ramus (temporal, zygomatic and upper buccal) are usually on a plane that is superficial to the primordium (Fig. 18, 2^o arrows). Those branches that arise from the cervicofacial ramus (lower buccal, marginal mandibular and cervical) are usually on a plane that is deep to the primordium. Dorsolateral growth of the primordium superficial to the facial nerve and its branches begins in this stage.

Stage III: Third and fourth order branching of the parotid primordium as it enters the parotid space (32 to 44 mm, 9 to 10.5 weeks)

The primordium undergoes third order branching and begins to enter the parotid space by 32 mm. Most of the branching is dorsal to the masseter muscle. Fourth order ductules are present at 37 mm, when the primordium is mostly within the parotid space (Fig.17). Dorsolateral growth increases considerably and extends cranially and caudally. Moderately dense mesenchymal tissue continues to surround the expanding primordium. A distinct lumen is present in the main duct and many of its tributaries.

A comparatively small portion of the primordium lies deep to the nerve at the stage. At 32 mm, small ductules in the caudal part of the primordium pass medially between the cervicofacial ramus and its lower

buccal branch. However, even at 41 mm, the only part of the primordium that is actually deep to the nerve is opposite the temporo-facial ramus and its upper buccal branch. This portion of the primordium attains its position by growing cranially from the main duct.

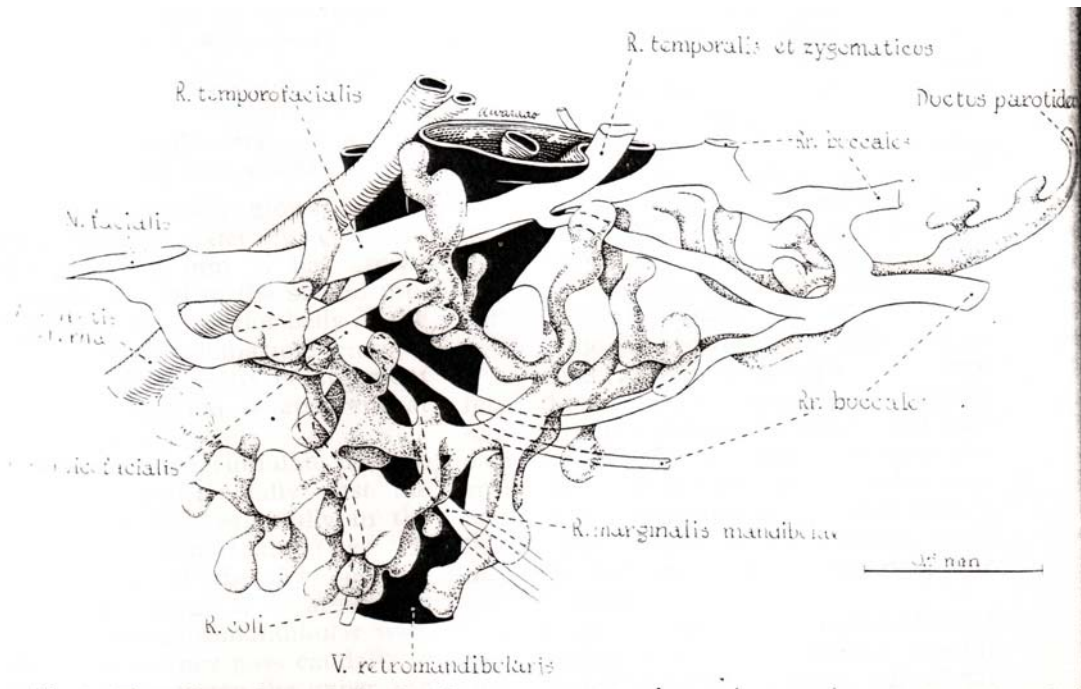


Fig.17. The relationships of the facial nerve, parotid primordium, retromandibular vein and external carotid artery at 37 mm, ten weeks. Notice the deeper position of the cervicofacial branches compared to the temporofacial branches.

The main feature in this stage is dorso-lateral growth of the primordium with extensions cranially and caudally, superficial to the facial

nerve and its branches (Fig.18, 3⁰ arrows). The deep portion is primarily opposite the temporo-facial ramus and proximal part of its buccal branches. Ductules of the superficial portion begin to grow medially, dorsal to the cervicofacial ramus and between this ramus and its lower buccal branch to contribute to the deep portion (Fig. 17, 4⁰ arrows).

Stage IV: Multiple branching of the parotid primordium superficial and deep to the facial nerve (49 to 80 mm, 11 to 13.5 weeks)

The superficial portion grows rapidly and extends dorsally, laterally, cranially and caudally. Progressive enlargement of the superficial portion is apparent at 80 mm.

Additional ductules accumulate deep to the nerve and grow medially past the ramus of the mandible especially in the cranial part of the primordium. That segment of the deep portion that began during stage II enlarges and grows medial to the retro-mandibular vein. Its ductules unite as they pass caudally to join the main duct between the upper and lower buccal branches (Fig.18). Contributions to the deep portion are also made by the medial growth of ductules in the superficial portion. Such growth is especially evident dorsal to the temporo-facial and cervico-facial rami, but it also occurs between other branches of the facial nerve. Very few ductules in the deep portion grow laterally to contribute to the superficial portion.

The facial nerve and its branches in the parotid space are almost completely surrounded by the primordium. Superficial ductules grow cranially and caudally by 49 mm covering the lateral aspect of the proximal portion of the upper buccal branch (Fig.18). A lesser quantity of the primordium is apparent deep to the cervicofacial ramus and its branches. Ductules appear on the medial aspect of the undivided part of the facial nerve by 62 mm. The communication between the temporal branch of the facial nerve and the auriculo-temporal nerve occurs within the primordium.

Ductules surround the retro-mandibular vein earlier than the external carotid artery since the vein is more superficial. The ductules attain this medial position by growing rostral and dorsal to the vein. This stage is characterized by medial growth of ductules in the superficial portion between and around branches of the facial nerve especially dorsal to the temporo-facial and cervicofacial rami (Fig.18, 4⁰ arrows).

Many conflicting reports exist on early relationship of the parotid gland and the facial nerve. Winsten and Ward observed the bulk of the gland primordium within the crotch of the main rami of the facial nerve at 27 mm³¹. Cody noticed the primordium completely separate from the nerve at 30 mm²⁵. According to Rouviere and Cordier the nerve is entirely deep at 31 mm³⁰. Bujard shows the nerve on a plane superficial to the primordium

at 35 mm²⁴. Brunner found the nerve mainly deep to the primordium at 40 mm²³. The study by Gasser however, shows that the temporo-facial branches on a plane which is superficial to the primordium at 22 mm (fig. 15). The upper buccal branches are entirely superficial the primordium at 26-32 mm, but the cervico-facial ramus and its branches are either deep to the primordium or on a plane that is deep (Fig. 16). Between 32 and 44 mm, most of the primordium expands superficial to the facial nerve branches with only a small parotid that is opposite the temporo-facial rami proximal part of the upper buccal branches (Fig. 17).

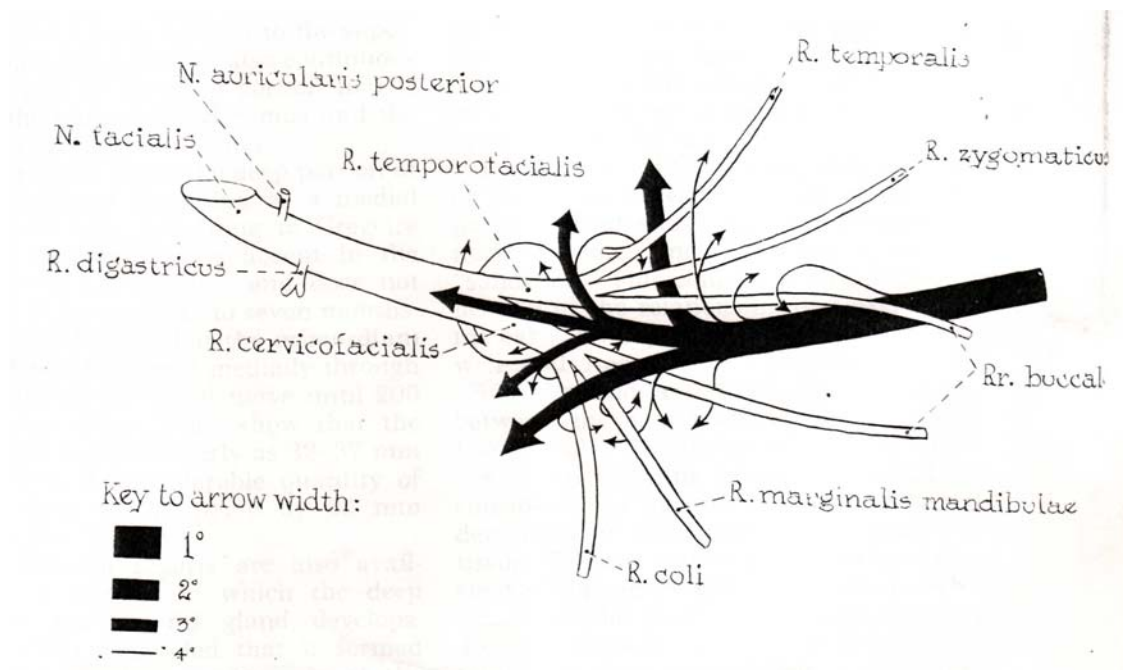


Fig.18. General pattern of development. Arrows indicate the direction of growth of the primordium around the facial nerve and its branches. The width of the arrows shows the sequence of development.

The present thought is that, in most instances, the growth of the parotid gland primordium around the facial nerve and its branches follows a pattern (Fig. 18). The findings of Winsten and Ward during early development of the oblique alignment of the nerve branches with the more medial position of the marginal mandibular and cervical branches are confirmed in the study by Gasser³¹. The latter author, disagrees with Winsten and Ward in that the continued growth of the gland does not always take place entirely lateral to the cervical branch. A considerable quantity of the primordium is medial or deep to this branch at 56 mm. Bailey's conclusion that apparently the main ductules connect only with the superficial portion is not supported by present findings²². Most of the main ductules during early development do connect to the superficial portion, but some are also continuous with that part of the deep portion that is opposite the temporo-facial ramus and the proximal part of its branches.

Brunner found the deep portion of the parotid gland beginning as a medial sprout at 40 mm²³. According to Gregoire the deep portion is absent in the 80 mm fetus (3 months) and does not begin to develop until six to seven months¹⁸. Cody indicated that the primordium does not begin to extend medially through the branches of the facial nerve until 200 mm²⁵. This is contrary to the observations made by Gasser, that the deep portion

begins as early as 32-37 mm (Figs. 17). A considerable quantity of gland is deep to the nerve by 80 mm.

Many different reports are also available of the manner in which the deep portion of the parotid gland develops. Gregoire concluded that it formed by migration of the superior pole of the gland cranial to the facial nerve¹⁸. Rouviere and Cordier observed at 51 mm projections which passed from the superficial portion over the nerve cranially as well as some which passed between the two main rami³⁰. McWhorter and many others observed the location of a prominent area of communication between the two main rami¹⁹. Winsten and Ward found the largest area of communication in the region of the lower branches of the nerve around the cervicofacial trunk³¹.

Samengo, studying 80 and 100 mm fetuses and adults, believed the two portions of the gland meet at their dorsal border³². Sammarco, Ryan and Longenecker observed several connections between the two portions in third trimester fetuses and stillborn infants²⁹. Winsten and Ward stated that as the gland grew all the interstices of the branches of the nerve are filled with proliferating buds³¹. In the study by Gasser, connections between the superficial and deep portions are present at 56 mm dorsal to and between the temporofacial and cervicofacial rami and between some of their branches. Communications between the two portions of the gland probably can occur

through any gap in the plexus. Because of the manner in which the primordium forms around the facial nerve branches, a more prominent communication necessarily exists between the two major rami of the nerve (Fig. 18).

Bailey believed that no part of the facial nerve is actually within the parotid gland substance and likened the nerve to the “meat” within a parotid “sandwich”²². This concept is an oversimplification of the relationship that exists during early development. McCormack, Cauldwell and Anson and Davis et al. reported a natural cleavage plane between the two portions of the gland^{20, 26}. Davis et al. indicated that the cleavage plane contains tissue that could be considered as an inward directed septal derivative of the surrounding connective tissue²⁶. Winsten and Ward stated that cleavage planes in which the nerve radicles transverse the gland do not exist³¹. Between 49 and 80 mm, Gasser found the area immediately surrounding the facial nerve and its branches to be devoid occasionally of parotid gland ductules, but this arrangement cannot be described as a cleavage plane. A complete cleavage plane through the gland primordium with a single mass of communicating ductules (isthmus) was never observed. Many ductules that are superficial to the facial nerve contribute to the deep portion by growing medially above and below the nerve and between many of its branches. It is

rare that ductules in the deep portion of the gland grow laterally and contribute to the superficial portion.

McCormack, Cauldwell and Anson, Davis et al. and many other believed that the parotid gland is bilobed^{20, 26}. Winsten and Ward and Patey and Ranger showed the gland to be unilobar^{31, 27}. Traditionally, lobes are demarked by fissures, sulci, connective tissue or shape.³⁴ None of these demarcations are clear during early development but only the position of the primordium with reference to the position of the nerve. In light of this, the terms, superficial and deep portions of the parotid gland, which were suggested by McKenzie and later adopted by *Nomina Anatomica*, are more appropriate than the terms, superficial and deep lobes^{21, 35}.

Auriculo-temporal nerve:

The trigeminal nerve is the first branchial arch nerve. It develops in the intra-uterine weeks 5 and 6. The auriculo-temporal nerve breaks up into branches in front of the external auditory pit at 7 weeks. In the 26 mm length stage of fetal development, it is connected to the facial nerve. Interruption or external effects within this period of development may lead to deviations from normal development. It originates from the posterior trunk of the mandibular nerve primarily in two branches and the middle meningeal artery

passes between them. This nerve runs through the deep lateral pterygoid muscle and supplies fibres to the parotid gland. It contains somatosensory and secretomotor fibres of third division of the fifth cranial nerve and the ninth cranial nerve. The auriculo-temporal nerve crosses medial to the neck of the mandible and changes its direction upward in the parotid gland between the temporo-mandibular joint and external auditory meatus. The auriculo-temporal nerve has communicating branches to the facial nerve and inferior alveolar nerve at the posterior border of the mandibular ramus in its course.

There are also variations in the anatomy of the nerve. Nadir Gulekon et al. concluded that, on 32 dissections in majority of the cases the auriculo-temporal nerve with two roots, the upper root was lateral to the middle meningeal artery and the lower root was medial. In the cases with one root, the number of those with roots lateral to the artery was almost equal to those with roots medial to the artery ³⁶. The variations are in the number of roots by which the nerve arises and the nerve was always medial to the facial nerve.

In the article, “The surgical anatomy of the parotid duct with emphasis on the major tributaries forming the duct and relationship of the facial nerve to the duct” by Richard’s et al dissection was made in cadaver heads ³⁷. In this study parotid duct had the same pattern in 78.6% on the

right and left sides. Parotid duct in 31% of the head hemi sections presented as a single discernible duct from the parotid papilla to within the gland. In 62.1% of the head hemi sections, the ducts were formed by a branching pattern within the gland. In the ducts with a branching pattern, 48.3% displayed a bifurcated pattern, 6.9% were trifurcated, and 6.9% had multiple branches. In 6.9%, of the head hemisections, the parotid ducts bifurcated distal to the parotid gland. In all cases, the deep lobe of the gland enveloped the parotid duct; only small tributaries connected the superficial lobe with the duct. The facial nerve and its branches were always observed lateral to the parotid duct. Because one dissects lateral to the facial nerve during a superficial parotidectomy, generally, the parotid duct remains intact and potential complications such as sialoceles and fistulizations are, thereby, minimized.

Physiology of the parotid gland:

For their size the salivary glands produce a large volume of saliva; the maximal rate in humans is about 1 ml/min/g of glandular tissue. The rate of metabolism of salivary glands is also high, accompanied by a high blood flow-both proportional to the rate of saliva formation. The flow of blood to maximally secreting salivary glands is approximately 10 times that of an equal mass of actively contracting skeletal muscle.

Receptors:

The receptors are moieties that interact with ligands involving recognition and transfer of information (Lefkowitz et al., 1984a)³⁸. The interaction initiates a biologic response or sequence of responses. The quality of the biologic response resides in the receptor-effector and not in the ligand. The binding of a ligand to a specific receptor is the first step in the regulation of cell function by extra-cellular factors. The majority of regulatory receptors are found in the plasma membrane (proteins or glycoproteins); a few (hormonal) are present within the cell. Once occupied by its specific regulatory molecule, the receptor complex activates an effector process to bring about the cellular response. Activation is either direct or by a second messenger. A receptor may be a single or composite membrane protein and may contain subunits with special functions.

Little is known of the molecular characteristics of salivary gland receptors. Probably, however, adrenergic, muscarinic-cholinergic, and other receptors are similar to those found on other cells. Receptors for

polypeptide hormones and neurotransmitters are on the plasma membrane, and for exocrine glands they are on the basal or lateral membranes (Stump, 1984) ³⁹. For some cells, receptor occupancy and biologic effects follow saturation kinetics; for other cells, regulation does not require full occupancy (Lefkowitz et al., 1984a) ³⁸.

Salivary function and regulatory molecules*

Salivary gland	Regulator	Second messenger	Effect
Parotid	Acetylcholine (ACh), x-adrenergic, substance P	Ca ⁺⁺	Production of saliva, limited enzyme secretion, increased cell metabolism
	B-adrenergic, vipadrenergic intestinal peptide (VIP)	AMP	Secretion of enzymes, increased cell metabolism

*Data from Williams JA: Ann Rev Physiol 46:361, 1984. ⁴⁰

Two major classes are alpha-adrenergic and beta-adrenergic receptors. Lefkowitz et al, (1984b) have defined two subtypes of each receptor, termed alpha 1, and alpha 2 and beta 1 and beta 2 ³⁸. Three of the four subtypes of adrenergic receptors are linked to the same biochemical effect on the adenylate cyclase system, which generates the second messenger, adenosine 3':5'-cyclic phosphate (cAMP). The beta1 and 2 receptors stimulate the enzyme, whereas the alpha 2 receptors inhibit it. Rather than being coupled to adenylate cyclase, alpha1 receptors appear to be coupled to processes that regulate cellular calcium-ion fluxes (Lefkowitz et al., 1984b) ³⁸.

Secretion:

Saliva consists of two components; macromolecules and fluid. The fluid component is derived from perfusing blood vessels; the macromolecules are primarily derived from secretory granules of the acinar cells. The fluid is produced at the secretory end-pieces and is currently thought to occur via an osmotic coupling (solute-solvent coupling) of transepithelial fluxes of sodium chloride and water (Izutsu, 1989)⁴⁵. It is likely that the water and electrolyte fluxes occurs transcellularly through acinar cells. Movement of sodium and chloride through the cell and into the acinar lumen provides an osmotic gradient to establish an accompanying water flow across the cell. The currently favored hypothesis to explain how sodium and chloride cross the basal cell membrane is that a co-transport of the two ions occurs with the movement of sodium down its electrochemical gradient driving the accumulation of chloride against its electrochemical gradient (Izutsu, 1989)⁴⁵.

For the salivary glands the precise method by which secretion is brought about is still largely unknown. Cyclic AMP-and calcium – activated phosphorylation of cellular substances are currently believed to be the major effects leading to macromolecular secretion (Williams, 1984)⁴⁰. In the case of electrolyte secretion, attention is directed primarily to ion channels and carriers by which ions enter the cells or to the energy-dependent $\text{Na}^+ - \text{K}^+$ pump, which carries out ion extrusion. Petersen (1980) and Williams (1984) have postulated a calcium effector system and/or a channel linking extracellular and intracellular compartments permeable to calcium and capable of different conformations corresponding to different calcium permeabilities^{41, 40}. Voltage-sensitive channels permeable to sodium,

potassium, or calcium ions open after a depolarization of the plasma membrane (Findlay, 1984; Petersen, 1980)^{47, 41}. The sodium pump exists in all cells, and since more sodium ions are actively pumped out than potassium is taken up, it contributes directly to the membrane potential. The pump is primarily activated by an increase in sodium. Calcium-sensitive ion channels, permeable to sodium, potassium, or chloride ions, open when calcium increases (Petersen, 1980)⁴¹. This is in addition to a calcium-activated channel. Possibly, cyclic nucleotides (AMP, GMP) activate ion channels or pumps.

Despite the many gaps in the knowledge of the electro-physiology of salivary acinar cells, the action of the major secretagogues can be summarized as follows. In mammalian salivary glands, acetylcholine and epinephrine and/or nor-epinephrine acting on alpha-receptors cause an increase in potassium and sodium ion permeability of the plasma membrane. This results in a pronounced reduction of the surface membrane resistance and a loss of potassium from the cells, balanced by an uptake of sodium. An active electrogenic extrusion of sodium and accumulation of potassium follow. An increase in calcium permeability probably mediates the permeability of sodium and potassium. Epinephrine and/or norepinephrine, acting on receptors, produce only small potential and resistance changes. The most important effect of beta-adrenergic activation is an increase in intracellular c-AMP, stimulating enzyme secretion, Cholinergic or alpha-adrenergic stimulation causes a marked fluid and some calcium-dependent enzyme secretion.

There is a dissociation of cellular secretory mechanisms underlying protein secretion and fluid/electrolyte secretion in the salivary glands. Of the three major cationic electrolytes-sodium, potassium, and chloride-

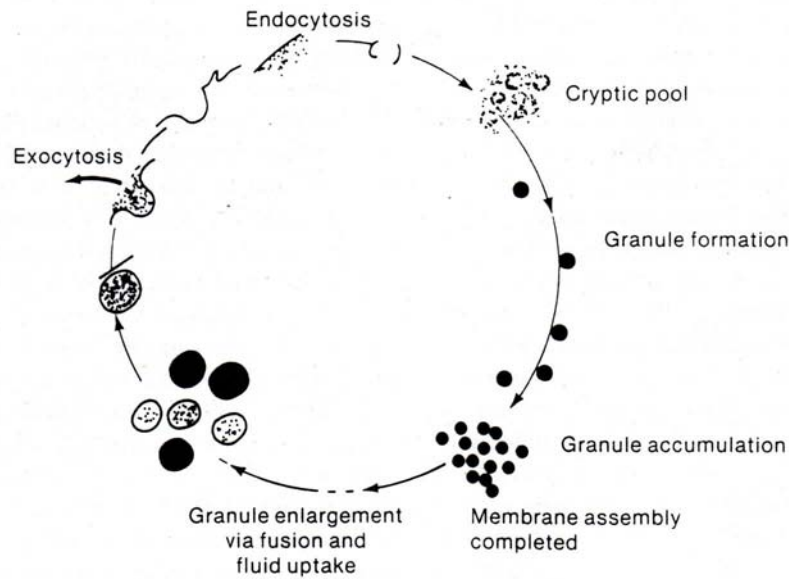
sodium is the only one with a pattern of very low concentrations at lowest flow rates to high concentrations at the highest rates of flow. Sodium is also the primary contributor to the increasing osmolality of the fluid as the level of secretion increases (Shannon et al., 1974)⁴². In human parotid saliva, sodium is the key in the secretion of fluid because local osmotic effects across the secretory luminal membrane influence the generation of the fluid (Shannon et al., 1974)⁴².

Acinar secretion:

Secretory cells such as the acinar cells of the parotid gland discharge their products by a process of exocytosis, wherein fusion of secretory granules with a delimited portion of the plasma lemma at the apex of the acinar cell occurs. The membrane fusion is the last of a series required for the transfer of export proteins from their synthesis in the rough endoplasmic reticulum (RER) to the extracellular environment. Using the model of Palade (1975), the secretory process can be divided into six successive steps: (1) synthesis, (2) Segregation, (3) intracellular transport, (4) concentration, (5) intracellular storage, and (6) discharge.

Saliva:

The variability of the composition of saliva can be accounted for by the fact that the several classes of salivary glands contribute different constituents and also because the final product depends on the stimuli evoking the secretion.



Endo-exocytotic process and granule formation in acinar cells of salivary tissues. (Modified from Williams MA, Cope GH: Anat Rec 199:389, 1981.)

Figure 19: Saliva secretion process:

Table 1: Contribution to saliva and relative viscosities of saliva by salivary gland*

Gland	Percent of total saliva (24 hours)	Relative viscosity
Submandibular	71	3.4
Parotid	25	1.5
Sublingual	3 to 4	13.4
Minor (oral, labial)	Trace amounts	--

Data from Mandel ID: Crit Rev Clin Lab Sci 12:321, 1980⁴⁴

Table 2: Saliva composition in normal adults:

Mean values	Parotid gland	Submandibular gland
Flow rate (ml/min/gland: stimulated)	0.7	0.6
Inorganic analytes (mEq/L)		
K ⁺	20	17
Na ⁺	23	21
Cl ⁻	23	20
HCO ₃ ⁻	20	18
Ca ⁺⁺	2	3.6
Mg ⁺⁺	0.2	0.3
HPO ₄ ⁻¹	6	4.5
Organic analytes (mg/dl)		
Urea	15	7
Ammonia	0.3	0.2
Uric acid	3	2
Glucose	<1	<1
Cholesterol	<1	?
Fatty acids	1	?
Total lipids	2 to 6	2 to 6
Amino acids	1.5	?
Proteins	250	150

Whole or mixed saliva is composed of approximately 99.5% water and has a specific gravity between 1.002 and 1.012. In humans the amount of saliva secreted in 24 hours is between 1000 and 1500 ml (Arglebe, 1981; Mandel, 1980)^{46, 44}. The secretory rate is highest during meals; during sleep or in the absence of stimulation the secretory rate is low or nearly absent. In human mixed saliva the pH varied from 5.75 to 7.05 (Arglebe, 1981)⁴⁶.

If data on flow and composition are to be meaningful, the saliva must be collected under standardized conditions (Arglebe, 1981; Mandel, 1980)^{46, 44}. Resting and stimulated secretions should be evaluated, and because many constituents of saliva are circadian, the times of collection should be uniform.

The flow rate in nonstimulated parotid glands is about 0.04 ml/min/gland; submandibular saliva has a somewhat higher resting flow rate, 0.05 ml/min/gland (Mandel, 1980)⁴⁴. This decreases markedly during sleep; the sleeping flow rate from the parotid gland is nearly nil.

Flow rates after stimulation vary with the stimulus. With usual gustatory stimulation a 0.6 ml/min/gland flow rate is obtained. A range of 0.4 to 1.0 is not uncommon. Discomfort from dryness is usually not a complaint until the rate of flow is below 0.2 ml/min/gland, (Mandel, 1980)

Neoplasms of the parotid gland:

Salivary gland neoplasms are rare, constituting 3% to 4% of head and neck neoplasms. The majority of the neoplasms arise in the parotid gland (70%), whereas tumours of the submandibular gland (22%), and sublingual gland and minor salivary glands (8%), are less common. The ratio of malignant to benign tumours varies by site as well: parotid gland 80% benign, 20% malignant; submandibular gland and sublingual gland 50% benign, 50% malignant; minor salivary glands 25% benign, 75% malignant.

The incidence of the various tumours in the parotid gland is as follows, Pleomorphic adenoma - 50%, Warthins tumour - 5-10%, Oncocytoma - 1%, other adenomas (Basal adenoma, Canalicular adenoma) - 5-10%, Mucoepidermoid carcinoma - 15%, Adenocarcinoma - 10%, Acinic cell carcinoma - 5%, Adenoid cystic carcinoma - 5%, Malignant mixed tumour - 3-5%, Squamous cell carcinoma - 1%, other carcinomas - 2%.

Animal studies:

There are a few trials that have assessed the function of the remaining part of the gland after various described surgeries of the parotid like functional superficial parotidectomy and deep lobe parotidectomy.

Zhao K *et al.*, designed a study in rats to clinically test a new type of parotid surgery termed '**functional superficial parotidectomy (FSP)**' to preserve the function of the residual gland ⁴⁸.

The results showed that 91.4% of the main parotid ducts were deep to facial nerve. Physical examination, sialography and scintigraphy showed that function of the residual gland was well preserved by FSP.

Zheng G *et al.*, had done a stereological study of the remaining parotid gland of rat after duct-preserved partial parotidectomy. The remaining parotid glands of rats after duct-preserved partial parotidectomy were sectioned and examined randomly by stereological methods, which determine the acinar area and proportional volume (PV) of the component tissues ⁴⁹. The volumes of the remaining glands were measured at the same time.

- 1) There was no difference of the above quota 1 – 3 days after the operation ($p > 0.05$).
- 2) 1 -2 weeks after the operation, the gland volume decreased ($p < 0.05$) with

the PV of acini decreasing ($p < 0.05$).

3) 4 – 7 weeks after the operation, the acinar area increased ($p < 0.05$), the PV of acini and gland volume regained ($p < 0.05$). All the results indicated that with the duct preserved, the remaining parotid glands, after partial parotidectomy, do have the regenerating ability and significant function.

The conclusion drawn here was, the acinar cells have regenerating capabilities with function which are statistically significant. The study mentioned below deals with the proliferative capacity of the acinar cells.

Burford Mason *et al.*, developed an animal model of regeneration to study the proliferative capacity of salivary glands⁵⁰. A clamp, which induced atrophy in parotid gland by obstructing the main excretory duct but allowed restoration of duct patency following removal, was implanted in a series of rats. When it was removed (Day 7), the weight of the glands was reduced by 50% and acinar cells had decreased from 93.8% to 8.2% of total cell population. Regeneration occurred rapidly following removal of the clamp. The number and location of cycling intercalated, striated, and excretory duct cells and acinar cells were monitored using an antibody to proliferating cell nuclear antigen (PCNA). All cell types were induced to cycle but the predominant cell to cycle was the acinar cell. During regeneration the number of PCNA+ acinar cells increased 38.7-fold from steady-state values. Results demonstrate that acinar cells have a significant potential for cycling, contrary to current histogenetic theories of salivary gland tumourogenesis which exclude acinar cells as

potential progenitor cells on the grounds of their putative limited cycling capacity.

In the article **“Experimental study on salivary gland scintigraph”** by **Funds Masayuki *et al.***, serial salivary scintigraphy was done after ligating the parotid ducts in rabbits ⁵³. There was progressive significant decrease in the uptake function from third day to 4 weeks after ligation.

There are no human studies demonstrating regeneration of the acinar cells.

Clinical trials:

In a trial by **Giuseppe Colella *et al.***, in the article “**Parotid function after selective deep lobe parotidectomy**”, selective deep lobe parotidectomy was done on fourteen patients who had a mass involving the deep lobe of the parotid seen between January 2001 and March 2004⁵¹. Evaluation of postoperative function of the superficial lobe of the parotid after selective resection of the deep lobe was done. At 6 months follow-up all patients had scintigraphy of both parotid glands.

After scintigraphy the maximum uptake value and function of the gland were evaluated with the concentration index (CI) and the CI percentage ratio. The concentration function of the gland in the resected side of the study group had a mean (S.D.) CI index of 5.5 (3.6) and a CI percentage ratio of 84%. They concluded that selective deep lobe parotidectomy has the following advantages: it minimizes the impact of treatment on the facial contour, it does not increase postoperative morbidity and it preserves the function of the gland.

Tumors in the parotid gland may affect salivary flow. The effects of tumor on glandular function and postoperative changes in both resected gland and contra-lateral gland were not formerly reported. In this trial named, **Salivary flow dynamics after parotid surgery**, **Gavriel Chaushu DMD *et al.***, studied the effects of tumours on salivary

flow rate and composition dynamics before and after parotidectomy were studied⁵². The Stenson's duct was routinely ligated in total parotidectomy only. In this study, the group prospectively evaluated salivary flow rates and composition in patients undergoing parotidectomy preoperatively and postoperatively. Stimulated parotid saliva from patients undergoing parotidectomy was collected bilaterally preoperatively and postoperatively by using a parotid cup. Subjective complaints were recorded. Salivary flow rates, sodium, potassium, and amylase levels were evaluated.

The pre-operative flow rates of the non-involved glands were significantly higher. No post-operative changes in flow rate were noticed in the un-involved glands, whereas involved glands presented with statistically significant post operative reduction. Analysis of the individual results revealed three patterns of pre operative and post operative response. They were as follows,

Group 1: Post operative compensatory group.

The mean results of this group are similar pre-operatively and close to mean (0.7 ml/minute). The mean post-operative compensatory increase in the uninvolved gland was 34% of the baseline value which is nearly half of the decline in the involved gland (75%). The total mean parotid salivary flow rate of both glands was 1.1 ml/minute, approximately

80% of the normal mean value. The mean flow rate is 0.04 ml/min/gland in un-stimulated state and 0.6ml/min/gland in the stimulated state.

Group 2: Pre operative compensatory group.

The mean pre operative value was much higher in the non - involved glands (0.92 ml/minute Vs 0.23 ml/minute, $p=0.001$). The pre-operative compensatory increase was about half (31%) of the decline in the involved gland (67%). The total mean parotid salivary flow rate of both glands was 1.15 ml/minute, approximately 80% of the normal mean value.

Group 3: Non responders.

The mean pre operative and post operative results in this group were lower compared with groups 1 and 2 ($p=0.014$) and no saliva was secreted from the involved glands post operatively.

Pre operative salivary secretion was detected in all the patients undergoing superficial parotidectomy. The mean pre-operative flow rate of the involved gland was 0.46 ± 0.3 ml/minute. The mean post operative flow rate was 0.05 ± 0.05 ml/minute which shows a reduction of 89% ($p=0.041$).

None of the patients complained of “dry mouth” before or after surgery.

Analysis of the individual results revealed 3 patterns of preoperative and postoperative response, compatible with either a preoperative or

postoperative compensatory mechanism in the contra-lateral gland. The postoperative decrease in flow rate corresponds with the amount of gland removed. Salivary electrolyte composition was unchanged. This study is the first to demonstrate the effects of parotid tumors and their surgery on salivary flow and a compensatory response and its different patterns in human parotid glands after their excision.

In the article **“Scintigraphic assessment of early and late parotid gland function after radiotherapy for head-and-neck cancer”** by **Judith M. Roesink M.D *et al.***, parotid scintigraphy was performed before radiation therapy and 6 weeks and 1 year after radiation therapy⁵⁴. The uptake, excretion fraction of the saliva from the parotid gland to the oral cavity (SEF), and the ratios of uptake and SEF after and before treatment were calculated. The SEF decreased to 18.7% at 6 weeks, but recovered to a SEF of 32.4% at 1 year after radiation therapy.

Observations and Results

Serial no.	Sex	Age	Operated side	Duct status	Technetium scan 1 – Right side uptake (%)	Technetium scan 1 – Left side uptake (%)	Technetium scan 2 – Right side uptake (%)	Technetium scan 2– Left side uptake (%)
1	Male	22	R	Preserved	35	65	34	66
2	Female	38	L	Preserved	84	16	76	24
3	Female	84	L	Ligated	75	25	88	12
4	Male	49	L	Ligated	80	20	95	5
5	Male	15	L	Preserved	72	28	63	37
6	Male	18	R	Preserved	25	75	24	76
7	Male	36	R	Preserved	51	49	26	74
8	Male	45	R	Preserved	11	89	0	100
9	Female	40	L	Preserved	63	37	90	10
10	Male	51	R	Preserved	27	73	20	80
11	Male	39	R	Not Known	49	51	46	54
12	Female	38	L	Preserved	75	25	75	25
13	Female	27	R	Not Known	42	58	39	61
14	Male	58	L	Preserved	61	39	73	27
15	Female	43	L	Preserved	91	9	98	2
16	Female	24	L	Preserved	68	32	71	29
17	Male	60	L	Preserved	79	21	89	11
18	Female	41	R	Preserved	25	75	38	62
19	Male	35	R	Preserved	52	48	42	58
20	Male	28	L	Preserved	47	53	70	30

Table 3. Parotid uptake functions

Table 3 shows the uptake function of the glands of 20 cases. The operated side uptake is written in green. In 16 patients there was decrease in the function by 10.68% in the second scan compared to the first one. In one case (no. 12) there was no change in the function. In 3 cases (no. 2, 5, 18) there was increase by 10% in the uptake function. In 2 cases (no. 19, 20) the uptake function in the operated gland was more than the normal gland in the first scan with subsequent reversal in the second scan. In one case (no. 8) the second scan function was 0%. In the cases (no. 2, 3) where duct was ligated there was more decrease in the uptake function than the others.

Serial no.	Sex	Age	Side	Duct status	Saxon's 1 - Right side(mg)	Saxon's 1 – Left side(mg)	Saxon's 2 – Right side(mg)	Saxon's 2 – Left side(mg)
1	Male	22	R	Preserved	15	110	5	41
2	Female	38	L	Preserved	200	152	Not done	Not done
3	Female	84	L	Ligated	156	946	22	11
4	Male	49	L	Ligated	71	2	109	27
5	Male	15	L	Preserved	132	85	194	157
6	Male	18	R	Preserved	26	51	29	59
7	Male	36	R	Preserved	19	255	28	61
8	Male	45	R	Preserved	15	78	35	94
9	Female	40	L	Preserved	155	32	184	114
10	Male	51	R	Preserved	44	48	22	32
11	Male	39	R	Not Known	12	59	18	32
12	Female	38	L	Preserved	67	28	52	16
13	Female	27	R	Not Known	210	114	90	102
14	Male	58	L	Preserved	194	117	114	28
15	Female	43	L	Preserved	28	18	48	33
16	Female	24	L	Preserved	88	18	356	296
17	Male	60	L	Preserved	14	16	36	21
18	Female	41	R	Preserved	22	28	34	202
19	Male	35	R	Preserved	12	20	12	22
20	Male	28	L	Preserved	28	25	45	16

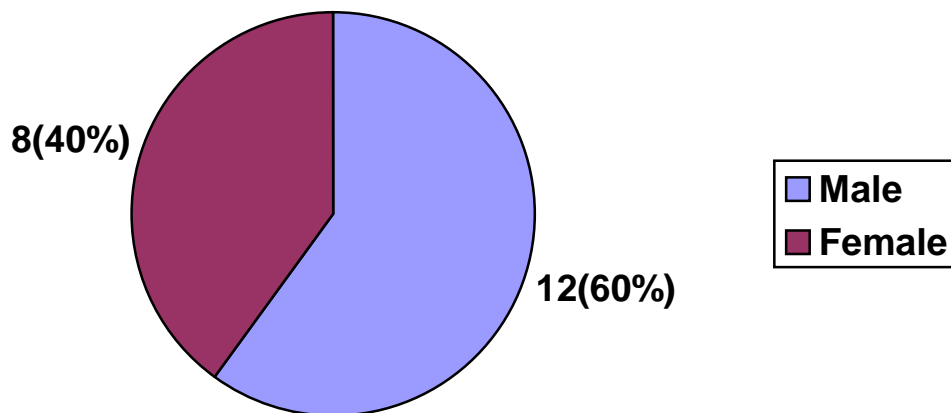
Table 4. Saliva secretion

In table 4, modified Saxon's test was done on the first scan day in all the 20 patients. In one case the second modified Saxon's test was not done as the scan was done in the native place. In case (no.3), the saliva weight was erroneously high due to practical difficulty, as she had no tooth leading to saliva contamination from the floor of the mouth. In 11 cases, there was actually increase in the saliva weight on the second measurement. In 5 cases (10, 12, 13, 14, 20), there was decrease in the saliva secreted. In on case (no. 19) there was no change in the weight.

From the above data percentage function and percentage saliva secretion was calculated for the operated gland compared to the non-operated gland. Only in 7 cases (35%) both scan and Saxon's test correlated with the same finding (either increase or decrease).

Sex distribution: (Fig. 20)

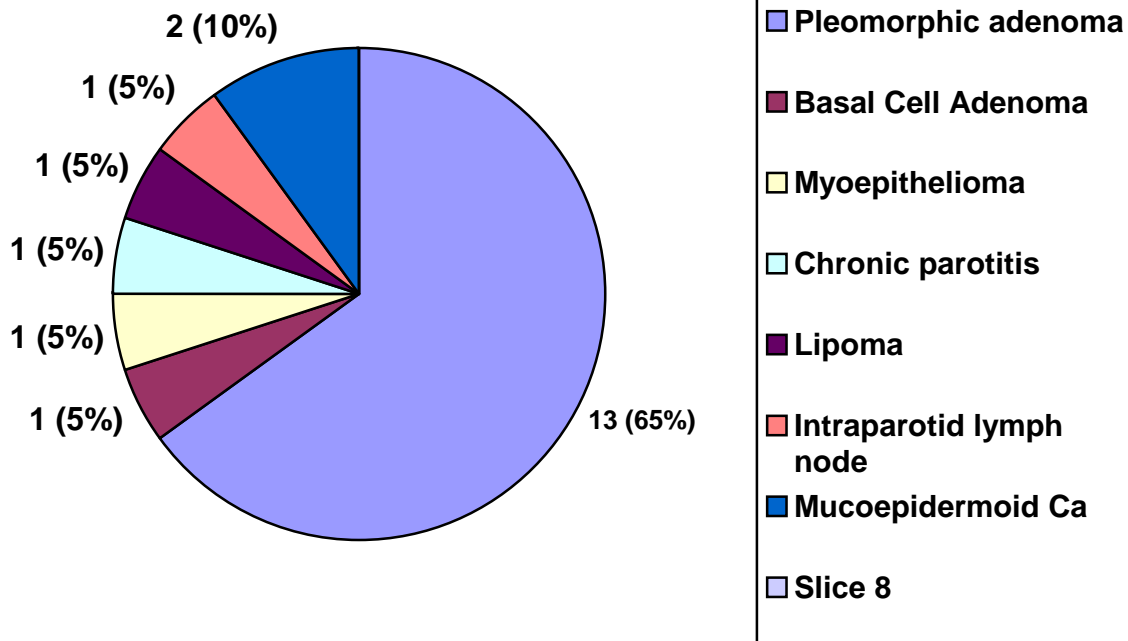
n=20



The male to female ratio in the present study of 20 patients was 2:3 with 8 males and 12 females (40 % and 60 % respectively). The age of the 20 patients enrolled in the present study ranged from 18 to 84 years with mean age of 40 years. The mean age for the males was 38 years while it was 42 years for females.

Pathology in the affected glands: (Fig. 21)

n = 20



The pathology of the involved glands were as follows: the commonest being pleomorphic adenoma in 13 cases (65%), low grade muco-epidermoid carcinoma in 2 cases (10%), basal cell adenoma, lipoma, chronic parotitis, intra-parotid lymphadenopathy and myoepithelioma in one case each, i.e. (5%) each.

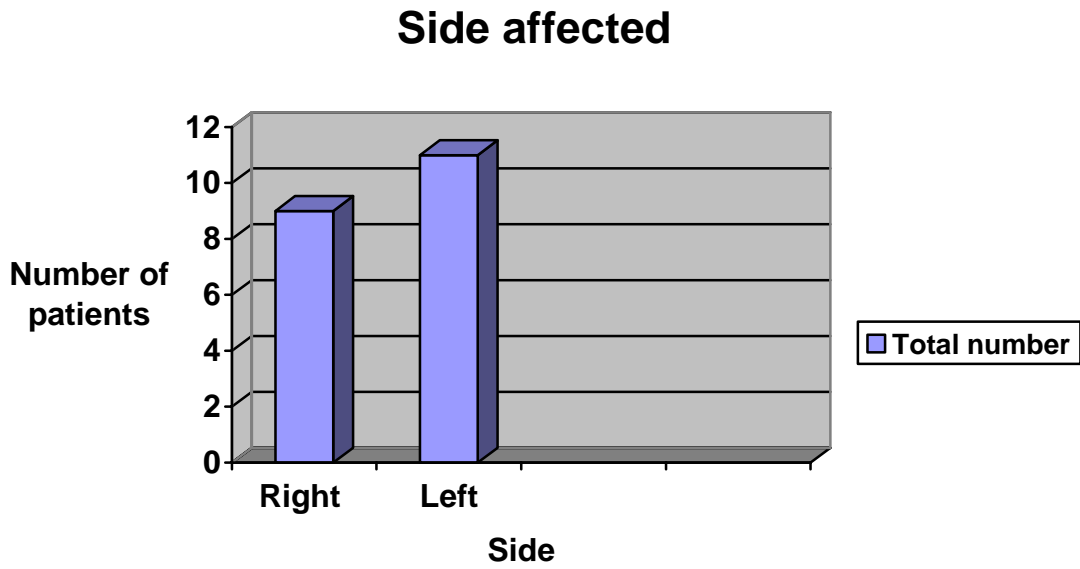


Figure 22: n = 20

Out of the 20 cases, 9 (45%) had affected glands on the right side and 11 (55%) had on the left side.

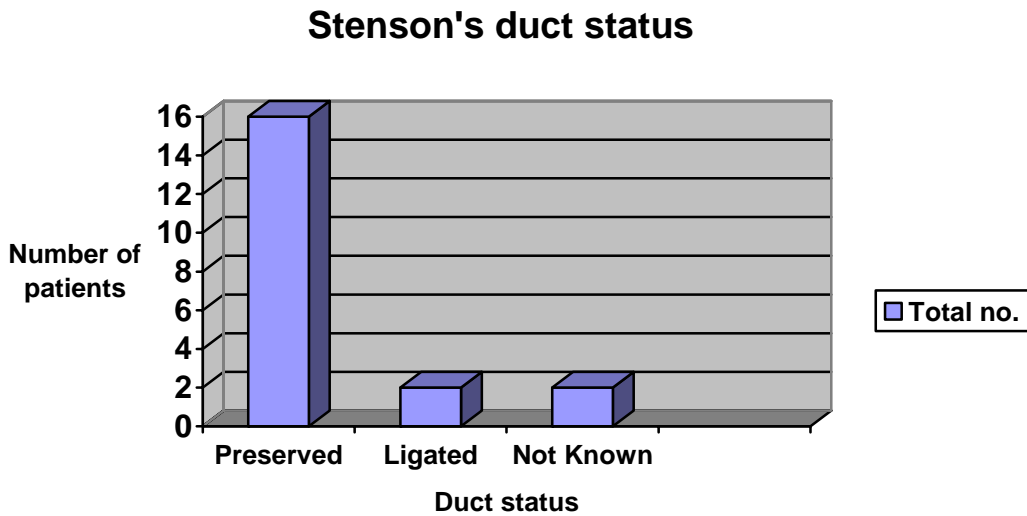


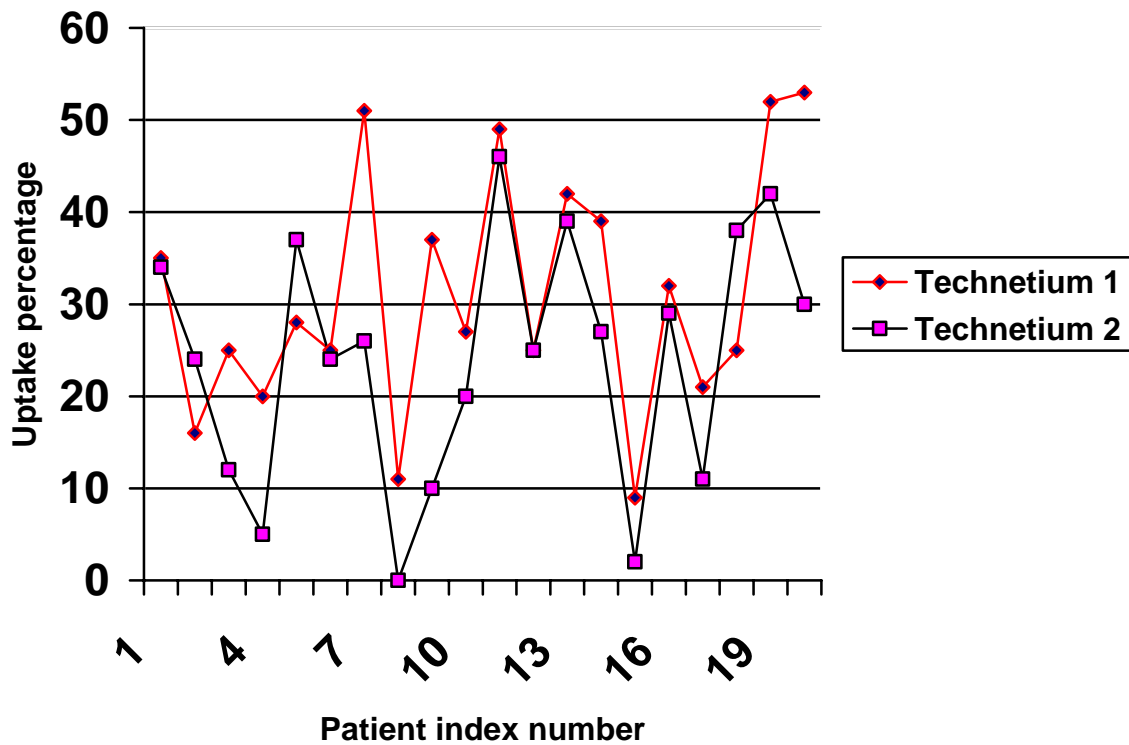
Figure 23: n = 20

The parotid duct was identified and preserved in 16 cases (80%), ligated in 2 cases (10%) and the duct status was not known in 2 cases (10%).

Fig.24.

n = 20

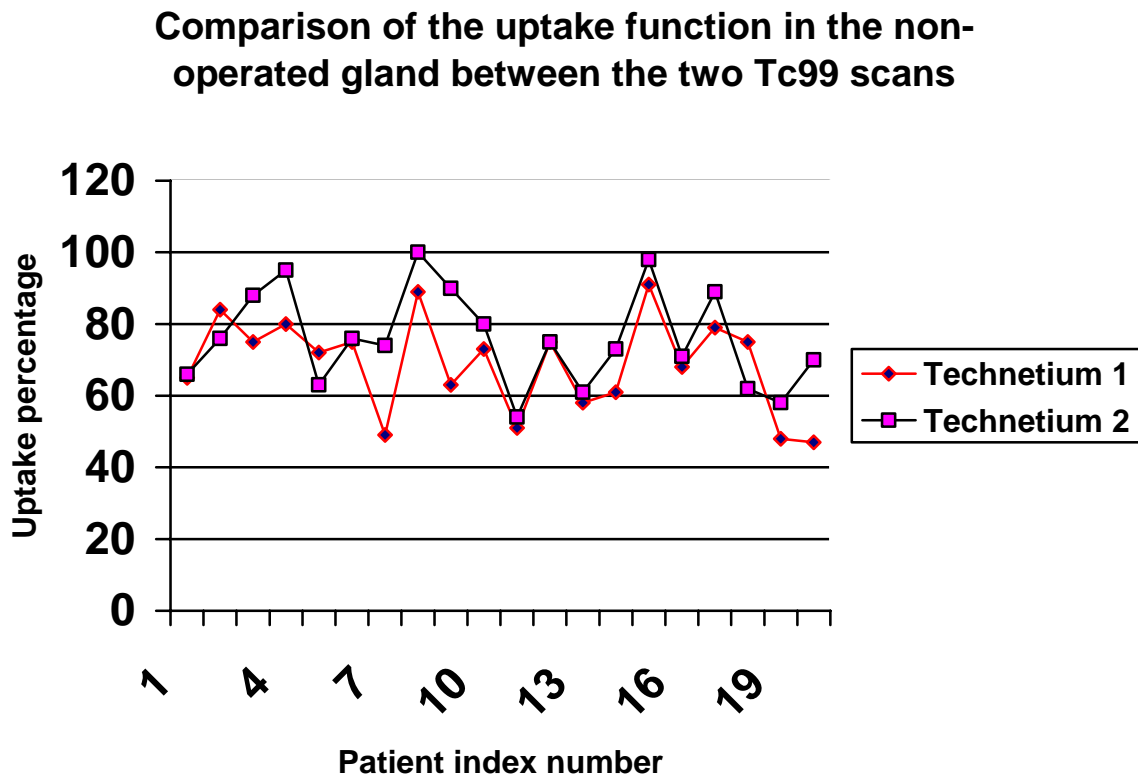
Comparison of uptake function between first and second Tc99 scans in the operated gland



In the above chart, comparison of uptake function of the operated gland was done between the two scans. This showed that there was a decrease in the function except for 3 cases where there was increase and one case where there was no change in function. The lowest function was 9% and the highest was 54% in the first scan. The lowest function was 0% and the highest was 46% in the second scan.

Fig. 25.

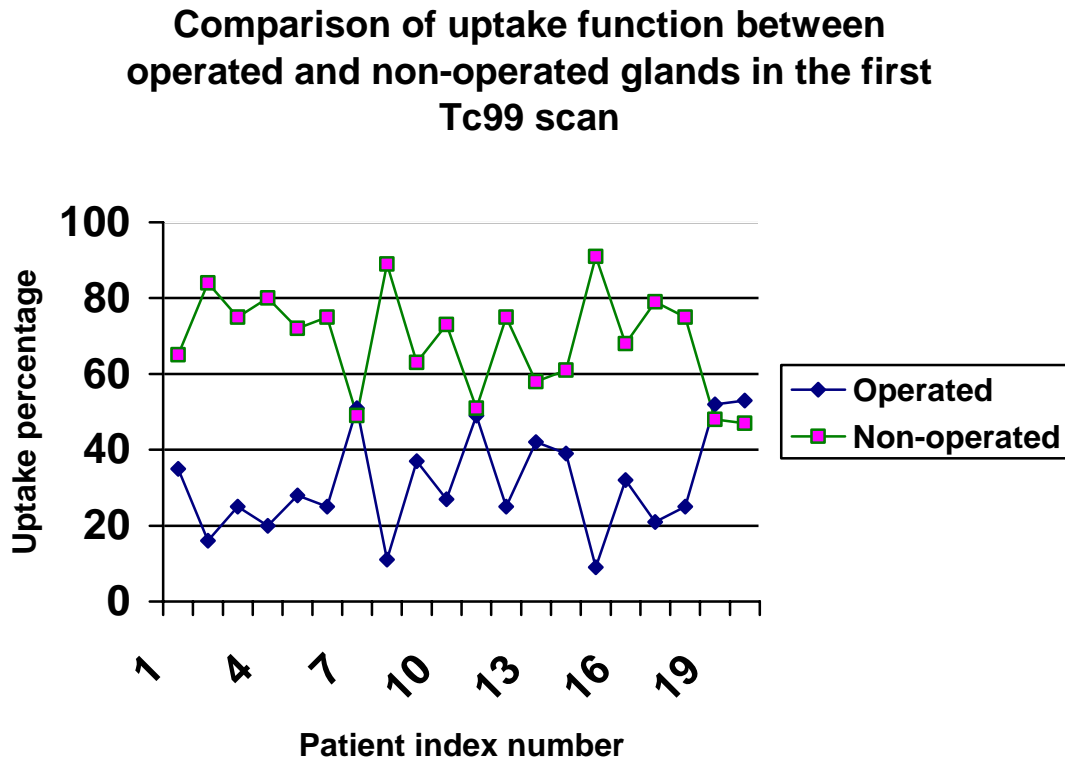
n = 20



In the above chart, comparison of uptake function of the non-operated gland was done between the two scans. This showed that there was an increase in the function except for 3 cases where there was decrease and one case where there was no change. The lowest function was 47% and the highest was 91% in the first scan. The lowest function was 54% and the highest was 100% in the second scan.

Fig. 26.

n = 20

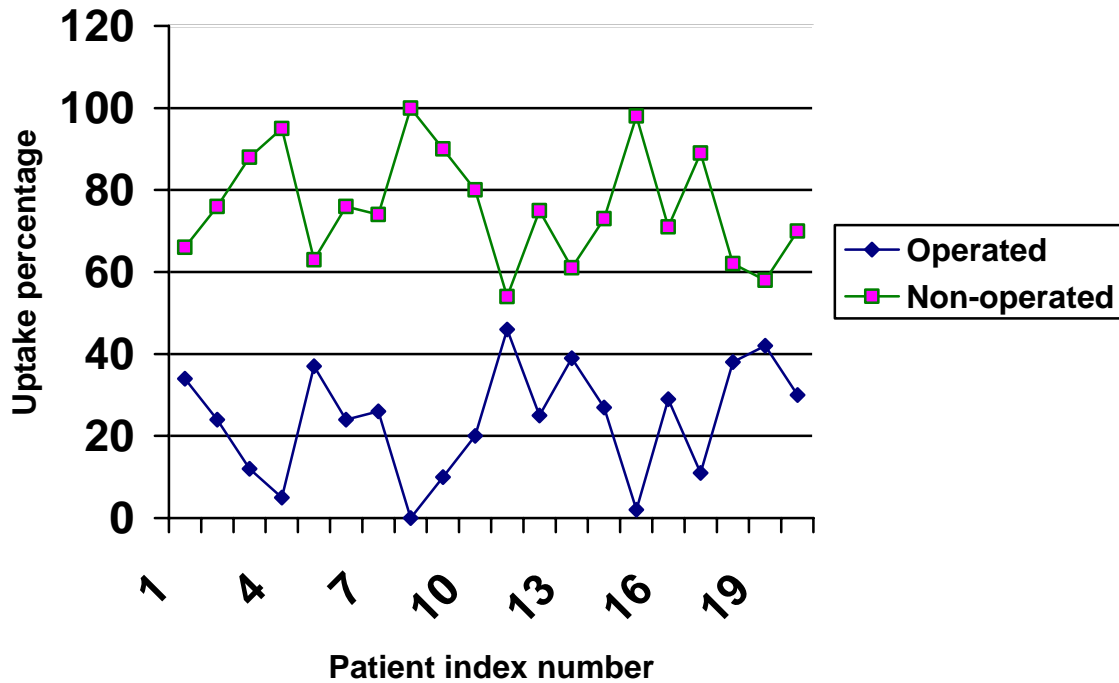


In the above chart, comparison of uptake function of the operated and non-operated gland was done in the first scan. This showed that there was a significant difference in the uptake between the two glands, the maximum uptake being 54% in the operated side and the lowest uptake being 47% in the non-operated side.

Fig. 27.

n = 20

Comparison of uptake function between operated and non-operated glands in the second Tc99 scan

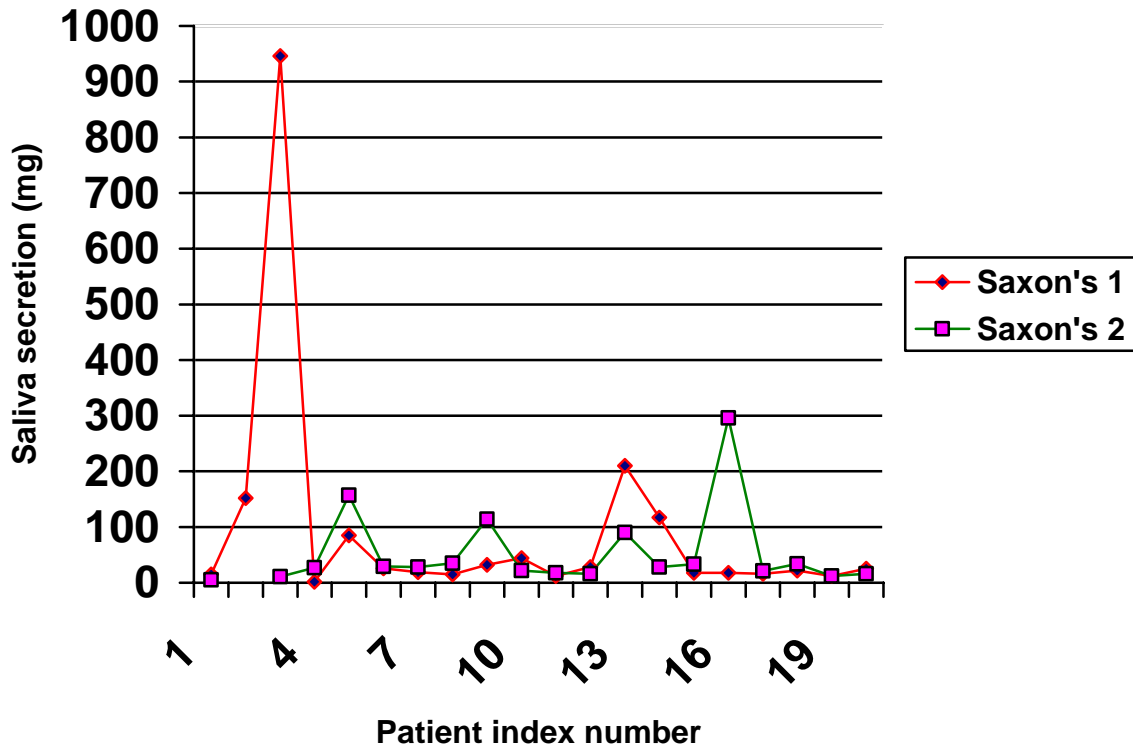


In the above chart, comparison of uptake function of the operated and non-operated gland was done in the second scan. This showed that there was a significant difference in the uptake between the two glands, the maximum uptake being 46% in the operated side and the lowest uptake being 54% in the non-operated side.

Fig.28.

n = 20, 19

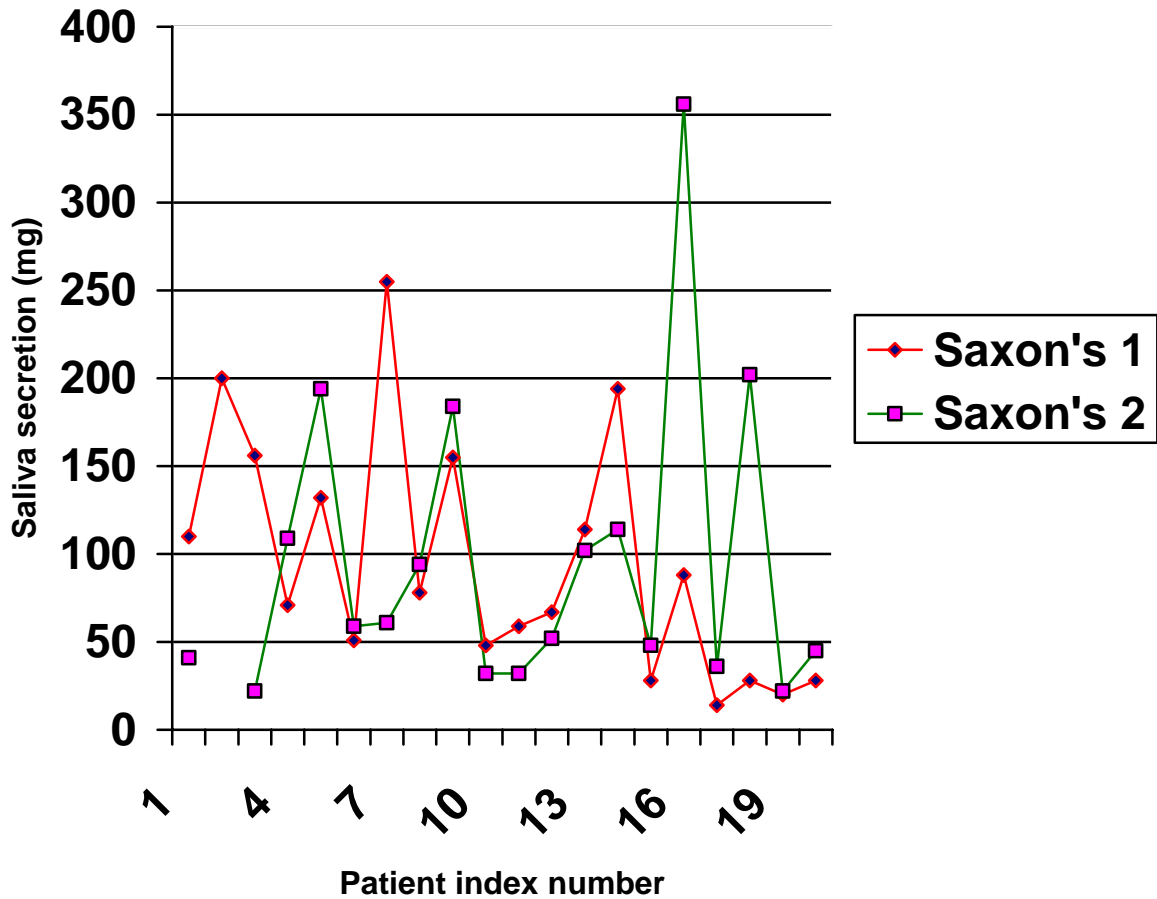
Comparison of saliva secretion between first and second scan days on the operated side



In the above chart, comparison of saliva secretion from the operated gland was done between the two scan days. The highest value was 210 mg in the first test and 296 mg in the second test. One value of 946 mg was erroneous. The lowest value was 2 mg on the first test and 5 mg on the second test.

Fig.29. n =20, 19

Comparison of saliva secretion from the non-operated gland between the two scan days



In the above chart, comparison of saliva secretion from the non - operated gland was done between the two scan days. The highest value was 255 mg in the first test and 356 mg on the second test. The lowest value was 14 mg on the first test and 22 mg on the second test. There seemed to be a compensatory increase in the normal gland uptake.

Fig.30. n=20

Comparison of saliva secretion between operated and non-operated glands on the first scan day

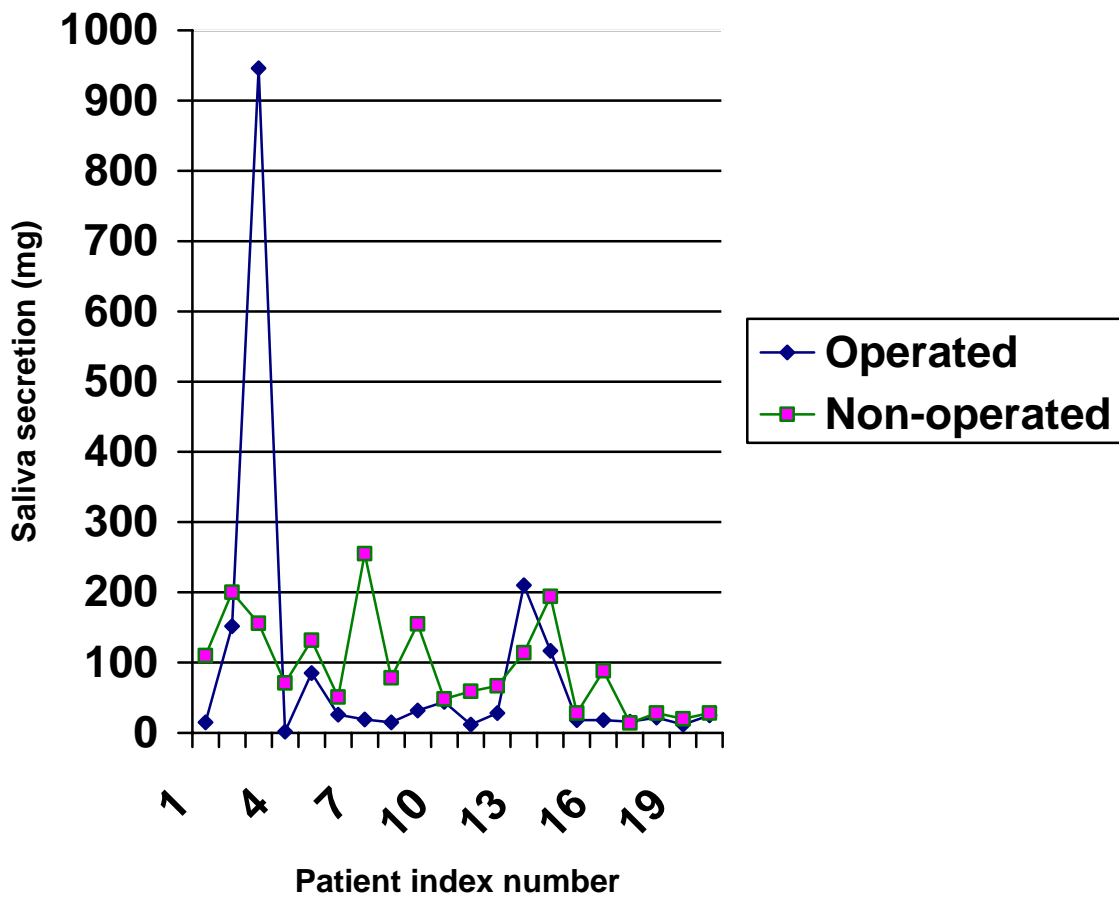
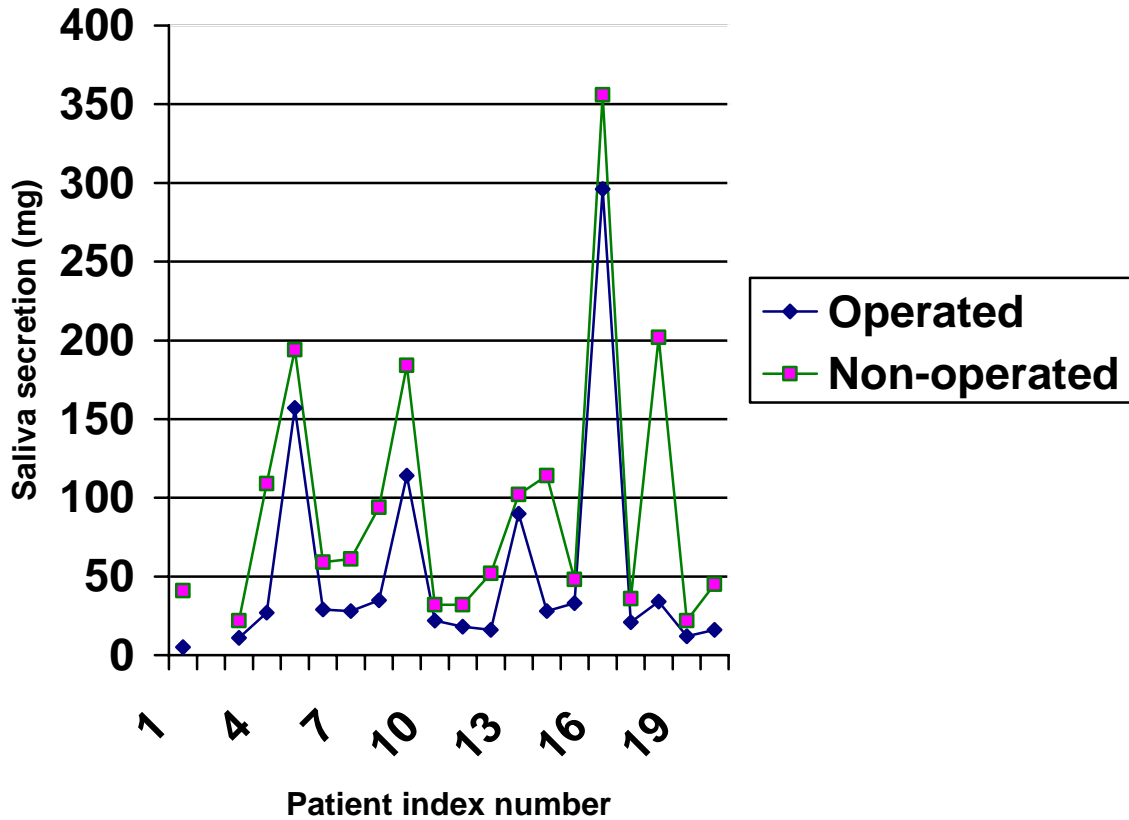


Fig.31.

n=19

Comparison of saliva secretion between operated and non-operated glands on the second scan day



From the above figures 25 and 26, there was no statistically significant difference in the salivary secretion between the two days, but the baseline secretion in the glands had increased in both the operated and non-operated glands.

Analysis of data:

Frequency: Table 5

Statistics

		PERTC_1	PERTC_2	PERSAX_1	PERSAX_2	number of days form surgery to scan 2	number of days from surgery to scan 1
N	Valid	20	20	20	19	20	20
	Missing	0	0	0	1	0	0
Mean		50.9665	35.7397	120.3231	92.4037	64.8500	11.1000
Median		37.9376	34.2342	62.2975	54.5455	48.5000	9.0000
Std. Deviation		32.22363	24.31478	193.69411	177.38402	50.20094	8.74131
Range		102.88	85.19	730.52	803.17	231.00	40.00
Percentiles	25	28.2700	12.6788	20.5022	35.5556	45.0000	8.2500
	50	37.9376	34.2342	62.2975	54.5455	48.5000	9.0000
	75	70.2940	56.9264	91.0714	68.7500	62.7500	10.0000

The expansions of the terms used in the tabular columns are as follows,

Perc_1 – Uptake percentage in the operated gland in first scan.

Perc_2 - Uptake percentage in the operated gland in second scan.

Persax_1 – Percentage saliva secretion in the operated gland on the day of first scan.

Persax_2 - Percentage saliva secretion in the operated gland on the day of second scan.

The mean time when the first scan was done was about 11 days. The mean time when the second scan was done was about 65 days.

From the scintigraphy, the percentage function of the deep lobe on the affected side was calculated with respect to the gland on the opposite

side assuming that it was normal, as it was normal clinically. Then the percentage functions were compared between the first and second scans. Analysis showed that the mean percentage function in the first scan was 50.97% (Median – 37.94, Range – 9.89 to 112.77) and in the second scan was 35.74% (Median – 34.23, Range – 0 to 85.19). This shows that there is a statistically significant reduction in the percentage function between the first and second scans, but still functioning. ($p = 0.020$), calculated using Wilcoxon Signed Ranks test. This was showed in the following table 6,

Wilcoxon Signed Ranks Test (Table 6)

Test Statistics^b

	PERTC_2 - PERTC_1
Z	-2.334 ^a
Asymp. Sig. (2-tailed)	.020

a. Based on positive ranks.

b. Wilcoxon Signed Ranks Test

Comparison between the saliva secretion on the days of first and second scans were also made. The mean secreted saliva weight was 120.32 mg (Median – 62.29, Range – 2.82 to 733.33), on the day of first scan. The mean secreted saliva weight was 92.4 mg (Median – 54.84, Range – 16.83 to 88.24), on the day of second scan. This decrease in the saliva secretion between the first and second tests, was not statistically significant, ($p = 0.717$).

Frequency: (Table 7)

Statistics

Duct Status			PERTC_1	PERTC_2	PERSAX_1	PERSAX_2	
Preserved	N	Valid	16	16	16	15	
		Missing	0	0	0	1	
	Mean		49.5316	34.1735	99.5428	102.4277	
	Median		37.9376	34.2342	62.2975	54.5455	
	Std. Deviation		32.87925	20.87509	171.61095	199.49358	
	Range		102.88	72.41	725.88	803.17	
	Percentiles	25		28.2700	15.5197	25.9316	35.5556
		50		37.9376	34.2342	62.2975	54.5455
		75		62.6334	49.3506	86.6071	68.7500
	Ligated	N	Valid	2	2	2	2
Missing			0	0	0	0	
Mean			29.1667	9.4498	304.6136	37.3853	
Median			29.1667	9.4498	304.6136	37.3853	
Std. Deviation			5.89256	5.92075	426.80495	17.83985	
Range			8.33	8.37	603.59	25.23	
Percentiles		25		25.0000	5.2632	2.8169	24.7706
		50		29.1667	9.4498	304.6136	37.3853
		75		33.3333	13.6364	606.4103	50.0000
9		N	Valid	2	2	2	2
	Missing		0	0	0	0	
	Mean		84.2461	74.5598	102.2748	72.2426	
	Median		84.2461	74.5598	102.2748	72.2426	
	Std. Deviation		16.73343	15.02656	115.87468	22.61702	
	Range		23.66	21.25	163.87	31.99	
	Percentiles	25		72.4138	63.9344	20.3390	56.2500
		50		84.2461	74.5598	102.2748	72.2426
		75		96.0784	85.1852	184.2105	88.2353

In table 5, comparison was also made in the percentage uptake function and percentage saliva secretion between the groups with the ducts preserved, ligated and status not known.

Duct preserved group:

There were 16 glands with ducts preserved. The mean percentage function in the first test was 49.5% (Median – 37.93, Range – 102.88) and in the second test was 34.17% (Median – 34.23, Range – 72.41). The mean secreted saliva weight was 99.54 mg (Median – 62.29, Range – 725.88), on the day of first scan. The mean secreted saliva weight was 102.42 mg (Median – 54.54, Range – 803.17), on the day of second scan.

Duct ligated group:

There were 2 glands with ducts ligated. The mean percentage function in the first test was 29.16% (Range – 8.33) and in the second test was 9.44% (Range – 8.37). The mean secreted saliva weight was 304.61 mg (Range – 603.5), on the day of first scan. The mean secreted saliva weight was 37.38 mg (Range – 25.23), on the day of second scan. Here the difference in the decrease appeared more when compared to the previous group.

Duct status unknown:

There were 2 glands with ducts status unknown. The mean percentage function in the first test was 84.24% (Range – 23.66) and in the second test was 74.55% (Range – 21.25). The mean secreted saliva weight was 102.27 mg (Range – 163.87), on the day of first scan. The mean secreted saliva weight was 72.24 mg (Range – 31.99), on the day of second

scan. Here also there was a decreasing trend.

The significance of the difference in the variables between the above mentioned three groups was calculated by the Mann-Whitney Test which was as follows,

Mann-Whitney Test (Table 8)

Test Statistics^b

	PERTC_1	PERTC_2	PERSAX_1	PERSAX_2
Mann-Whitney U	8.500	6.000	15.000	9.000
Wilcoxon W	11.500	9.000	18.000	12.000
Z	-1.059	-1.406	-.140	-.895
Asymp. Sig. (2-tailed)	.290	.160	.888	.371
Exact Sig. [2*(1-tailed Sig.)]	.327 ^a	.209 ^a	.941 ^a	.441 ^a

a. Not corrected for ties.

b. Grouping Variable: Duct Status

This showed that there was no statistical significance among the groups with the duct preserved, ligated and status not known in both uptake function as well as saliva secretion.

	Tc99 scan 1 (%)	Tc99 scan 2 (%)	Saxon's test 1 (mg)	Saxon's test 2 (mg)
Mean	68.9	75.95	90.05	93.1
Median	72.5	74.5	69	59
SD	13.34	13.6	70.4	87.24
Range	44	46	241	351
Minimum	47	54	14	5
Maximum	91	100	255	356

Table 9. Uptake function and saliva secretion in the non-operated gland

Table 7. Shows the uptake function and the saliva secretion in the non-operated gland. There is increase in the uptake function from 68.9% to 75.95%. The significance of the increase in the uptake function was calculated by Wilcoxon Signed Rank test, which showed a 'p' value of 0.01. Thus there is significant compensatory increase in the non – operated glands.

The increase in the saliva secretion was from 90.05 mg to 93.1 mg. Wilcoxon Signed Rank test (table 8) showed, $p = 0.507$ which is not statistically significant.

	Tc99 scan	Saxon's test
p	0.01	0.507

Table 10: Wilcoxon Signed Rank Test for uptake function and saliva secretion in the non-operated gland at ten days and six weeks post op.

6. Discussion:

Parotid tumours usually occur in adults with a slight female predominance. The benign tumours occur in fifth to seventh decades of life. In our study also the male: female ratio was 2:3 and the mean age was 40 Years ⁵⁵.

The incidence of pleomorphic adenoma is 50%, which in this study is 65%. The incidence of muco-epidermoid carcinoma is 15%, in our study is 10%. The incidence of basal cell adenoma is 5 – 10%, in our study is 5% ⁵⁵.

The embryology and anatomy describes the duct to be medial to the facial nerve in majority of the cases ^{16, 1, 20, 21, 22, 25}. In the article by Zhao k et al, 91.6% of the ducts were medial to the facial nerve ⁴⁸. But the location of the remaining 8.6% of the ducts was not known. Similarly in this study also 90% of the ducts were identified medial to the facial nerve, but the duct status in 2 cases (10%) was not known. The duct might be lateral to the facial nerve or there may be multiple branching pattern of the duct which needs to be studied further.

In the study done in rats by Zheng G et al, there was initial decrease and then there was increase in the gland function after 6 weeks ($p < 0.05$) ⁴⁹. In this study also there was a decrease in the gland function after 6 weeks by 15% ($p = 0.02$), this was statistically significant.

In the trial by Funds Masayuki et al, there was atrophy of the gland after duct ligation in 4 weeks time ⁵³. In the article by Burford Mason et al, there was initial decrease with ligation of the duct and then

regeneration and regaining of function on removing the ligature⁵⁰. The weight of the gland reduced by 50% at 7 days and the acinar cells decreased from 93.8% to 8.2%. Once the clamp was released there was 38.7 fold regeneration. In our study also there was profound decrease in function from 29% to 9% of the glands with their ducts ligated as compared to the others with preserved ducts which showed decrease from 49% to 34% demonstrating the same. In our study the duct was permanently ligated, hence no further imaging could be done with removal of ligature to assess the regenerating potential. This shows that the gland continues to function if the duct is preserved. In one of our cases the duct was preserved and the function was still low. This could be that the main duct might be arising by more than one branch duct pattern (2 branch patterns) and therefore the duct from the deep lobe might have been ligated and the others preserved³⁶.

In the article by Gavriel et.al., there was compensatory increase in the function of the non-operated glands observed in 6 patients, nearly half (34%) of the decline in the operated gland (75%)⁵². In 7 patients there was no affect. In our study the compensatory increase was seen in 16 non-operated glands by 7.05%. There was compensatory increase in 3 operated glands by 10%. There was no compensatory increase or decrease in both operated and non-operated glands in 1 patient.

In the clinical trial by Judith et al, there was recovery of function of the glands in scintigraphy after 1 year, which was a human trial⁵⁴. In our study the second scans were done around 6 weeks post op. There may be

increase suggestive of regeneration in our study also if another assessment is done at one year. One of the patients had the second scan after 269 days which still showed decrease in the function. The biopsy of that case was chronic parotitis.

7. Conclusions:

1. The deep lobe of the parotid gland has significant decrease in function at six weeks following superficial parotidectomy but there is no atrophy, disproving the hypothesis.

2. There is significant decrease in the function if duct is ligated.

3. Long term assessment may be required to show whether there is regeneration of the remnant gland or if it remains the same.

4. The auriculo-temporal nerve is in same plane of the facial nerve or medial to it or communicating with it, hence the fibres are not likely to be severed during superficial parotidectomy.

5. There was no salivary fistula in any of these cases.

8. Statement of limitations:

The following limitations were encountered,

In the clinical test:

1. In the elderly the measurement was technically difficult as there was loss of tooth,

there was saliva mixing from the floor of mouth.

2. The composition of the saliva secreted was not studied which could also affect the flow rates.

In the scan:

1. Pre – operative function is not assessed, since tumours will interfere with the Tc99m radioisotope uptake.

2. Volume of the glands on the subsequent scans could not be assessed due to technical reasons.

3. There was compensatory increase in the uptake function of the opposite gland which may indicate hyper functioning, thus taking up the radioisotope more than the affected side.

4. The range of the uptake function was wide.

5. A few scans were not done on the exact dates as the patients were from distant places.

6. The duct pattern was not assessed.

9. Comments:

1. Salivary fistula does not routinely occur is still not answered, sialogram may have been useful.
2. In the surgical procedure of superficial parotidectomy the stenson's duct is ligated. It is evident from our study that the deep lobe continues to function. Hence ligating the duct may not be needed.

Bibliography

10. Bibliography:

- 1. Bannister LH.** Alimentary System. In: Gray's Anatomy. *Williams PL (Ed), 38th ed. Churchill Livingstone: Edinburgh. 1995, pp. 1691-1692.*
- 2. Bailey H.** Parotidectomy: Indications and results. *Br Med J. 1947; 1:404-407.*
- 3. McKenzie J.** The parotid gland in relation to the facial nerve. *J Anat. 1948; 82:183-186.*
- 4. Reichert FL, Poth EJ.** Pathways for the secretory fibres of the salivary glands in man. *Proc Soc Exp Biol Med. 1933; 30:973-977.*
- 5. Diamant H, Wiberg A.** Do the chorda tympani in man contain secretory fibres for the parotid gland? *Acta Oto laryngol. 1965; 60:255-264.*
- 6. Holmberg J.** On the nerves of the parotid gland. *In: Oral Physiology. Emmelin N, Zotterman Y (eds) . Pergamon: Oxford. 1972, pp. 17-19.*
- 7. Genis-Galvez JM, Santos Gutierrez L, Martin Lopez M.** On the double innervation of the parotid gland. An experimental study. *Acta Anat .1966; 63:398-403.*
- 8. Garrett JR .** Structure and innervation of salivary glands. *In: Scientific Foundations of Dentistry. Cohen B, Kramar IRH (eds). Heinemann: London. 1976, pp. 499-516.*
- 9. Emmelin N, Engstrom J.** On the existence of specific secretory sympathetic fibres for the cat's submaxillary gland. *J Physiol. 1960; 153:1-8.*
- 10. Emmelin N.** Control of salivary glands. *In: Oral Physiology. Emmelin N, Zotterman Y (eds) . Pergamon: Oxford. 1972, pp. 1-16.*

11. Harrop TJ, Garrett JR. Effects of preganglionic sympathectomy on secretory changes in parotid acinar cells of rats on eating. *Cell Tissue Res.* 1974; 154:135-150.
12. Hodgson C, Spiers RL. The effect of preganglionic cervical sympathectomy, on the amylase content of parotid glands in fasted and fed rats. *J Physiol.* 1974; 237:56-57P.
13. Kagayama M, Nishiyama A. Comparative aspect on the innervation of submandibular glands in cat and rabbit; an electron microscopic study. *Tohoku J Exp Med.* 1972; 108: 179-193.
14. Garrett JR . Recent advances in physiology of salivary glands. *Br Med Bull.* 1975; 31:152-155.
15. Young JA, van Lennep EE. The morphology of Salivary Glands. *Academic Press: London, New York.* 1978.
16. Shaheen O H. Problems in head and neck surgery. 1984, 181 pp, *Illius, Bailliere Tindall: London. Published in: Head and neck surgery. vol 7(3): 262-263.*
17. Raymond F Gasser. The Early Development of the Parotid Gland around the Facial Nerve and Its Branches in Man. *Anat Rec.* 1970, May; 167(1): 63-67.
18. [Gregoire R. Le nerf facial et la parotid. *J del' Anat et de la Phvsiol.* 1945; 48: 422-447.]
19. McWhorter G L. The relations of the superficial and deep lobes of the parotid gland to the ducts and to the facial nerve. *Anat Rec.* 1917; 12: 149-154.
20. McCormack L J, E W Cauldwell and B Anson. The surgical anatomy of the facial nerve. *Surg Gynec Obstet.* 1948; 80: 620-630.

21. **McKenzie J.** The parotid gland in relation to the facial nerve. *J Anat.* 1917; 82: 183-186.
22. **Bailey H.** The treatment of tumours of the parotid gland with special reference to total parotidectomy. *Brit J Surg.* 1941; 28: 337-346.
23. [Brunner H. Die embryonale Entwicklung zur zweischichtigen Form der Glandula Parotis. *Anat Anz.* 1962; 111: 153-164.]
24. [Bujard E. Reconstructions plastiques glandes salivaires d'un foetus humain de semaines environ. *Anat Anz.* 1911; 38: 115-137.]
25. **Cody C C.** Surgical anatomy of the facial nerve outside the skull. *Arch otolaryng.* 1954; 60:291-301.
26. **Davis R A, B J Anson, J M Budinger and E Kurth.** Surgical anatomy of the facial nerve and parotid gland based on study of 350 cervicofacial halves. *Surg Gynec Obs.* 1956; 102: 385 – 412.
27. **Patey D H, and I Ranger.** Some points in the surgical anatomy of the parotid gland. *Brit J Surg.* 1957; 45: 250 – 258.
28. **Youssef E H, H F Talaat and A M EL Malt.** Surgical anatomy of the facial nerve and the parotid gland in infants. *J Egypt Med assoc.* 1965; 48(10): 694 – 701.
29. **Sammarco G J, R F Ryan and C G Longnecker .** Anatomy of the facial nerve and fetuses and stillborn infants. *Plast. Reconstruct. Surg.* 1966; 37: 566 – 574.
30. [Rouviere H, et G Cordier. Sur le developpement de la glande parotide et les conexions qui existent entre les deux lobes glande. *Ann. Anat. Path.* 1934; 11: 622 – 624.]
31. **Winsten J and G E Ward.** The parotid gland: an anatomic study. *Surgery.* 1956; 40: 583 – 606.

32. **Samengo L A.** Consideraciones embriologicas anatomoquirurgicas de la parotid. *Rev Asoc Med Argent.* 1964; 78: 513 – 516.
33. **Shulte H Von W.** The development of the salivary glands in man. Contributions the anatomy and development of the salivary glands in the mammalian. 1913, Vol. 4, Part 2, *Columbia University press, New York, 25 – 72.*
34. **Dorland's Illustrated Medical Dictionary.** 24th ed. 1965, *W.B. Saunders Co., Philadelphia.*
35. **Nomina Anatomica.** 1966 3rd ed., *Excerpt Medica Foundation, Amsterdam. 46.*
36. **Nadir Gulekon, Afitap Anil, Aylar Poyraz, Tuncay Peker, Hasan Basri Turgut and Mustafa Karakose.** Variations in the Anatomy of the auriculo-temporal nerve. *Clinical Anatomy.* 2005; 18:15-22.
37. **Richards AT et. al.** Surgical anatomy of the parotid duct with emphasis on the major tributaries forming the duct and relationship of the facial nerve to the duct. *Clinical Anatomy.* 2004, sep; 17(6): 463-467.
38. **Lefkowitz RJ.** Clinical physiology of adrenergic receptor regulation. *Am J Physiol.* 1984; 243: 43.
39. **Stumpf.** Histochemical characteristics and significance of cell receptors in biology and pathology. *Acta Histochem.* 1984; 29: 23.
40. **Williams JA.** Regulatory mechanisms in pancreas and salivary acini. *Ann Rev Physiol.* 1984; 16: 361.
41. **Peterson OH.** Mechanism of action of hormonal and neuronal peptides on exocrine gland cells. *Br Med Bull.* 1980; 38: 297.
42. **Shannon et. al.** Saliva : Composition and secretion. *Monographs in oral sciences.* 1974; Jun; 2: 1-103.

- 43. Palade G.** Intracellular aspects of process of protein synthesis. *Science*. 1975; 189: 347.
- 44. Mandel ID, Bauermash I.** Sialochemistry in Sjogren's syndrome. *Oral Surg*. 1976; 41: 182.
- 45. Izutsu KT.** Salivary electrolytes and fluid production in health and disease. In Sreebny LM. editor: *The salivary system, Boca Raton, Fla, CRC Press, 1989, pp 95 – 122.*
- 46. Arglebe (1981).** Biochemistry of human saliva. *Adv Otorhinolaryngol*. 1981; 26: 97.
- 47. Findlay I.** A patch – clamp study of potassium channels and white cell currents in acinar cells of the mouse lacrimal gland. *J Physiol*. 1984; 350: 179.
- 48. Zhao K, Qi DT, Wang LM.** Functional superficial parotidectomy. *J Oral Maxillofac Surg*. 1994; 52:1038-1041.
- 49. Zheng G, Li Y, Lu Y.** A stereological study of the remaining parotid gland of rat after duct-preserved partial parotidectomy. *Hua Xi Kou Quang Yi Xue Za Zhi*. 1998; 16:17-19.
- 50. Burford – Mason, Cummind MM, Brown DH, Mackay AJ, Darick .** Immuno- histochemical analysis of the proliferative capacity of duct and acinar cells during ligation-induced atrophy and subsequent regeneration of rat parotid gland. *Journal of Oral Pathological Medicine*. 1993, Nov; 22(10): 440-6.
- 51. Giuseppe Colella et al.** Parotid function after selective deep lobe parotidectomy. *British Journal of Oral and Maxillofacial surgery*. 2007, March; 45 (2):108-11.

52. Gavriel Chaushu DMD, MSc, Shay Dori DMD, Ben-Ami Sela PhD, Shlomo Taicher DMD, Jona Kronenberg MD and Yoav P. Talmi MD, FACS. Salivary flow dynamics after parotid surgery.

Otolaryngology Head Neck Surgery. 2001; 124:270-3.

53. Funds Masayuki, Takano Hideaki, Sato Child, Hiroshi Takashi, Wajima Hiroki, Taoka Ken, Ikeda Hiroshi. Experimental study on salivary gland scintigraph. *Higashi Nippon Dental Journal. vol 1, no.1(19821231), pp 99-107.*

54. Judith M. Roesink M. D, Marinus A. Moerland, Anne Hoekstm, Peter P. Van Rijk and Chris H.J Terhaard. Scintigraphic assessment of early and late parotid gland function after radiotherapy for head and neck cancers. *International J of Radiation oncology* Biology* Physics. 2004, Apr; volume 58, issue 5: 1451 – 1460.*

55. Robins and Cotran: Pathologic basis of diseases, 7th edition, pages 790 – 795.

Annexure

11. Annexure:

Proforma

Name :

Hospital no:

Age :

Sex :

Address:

A.Details of the disease.

1. Disease condition :

Biopsy –

2. Side affected :

-Right/Left

3. Date of surgery:

4. Parotid duct status:

Parotid duct ligated:

Yes/No

5. Dates of Tec99m scan and Saxon's test:

Tenth day post - op –

Six weeks post-op -

6. Remnant gland function:

1. By Saxon's test:

Post op days	Pre test weight(mg)	Post test weight(mg)	Net saliva secretion(mg)
Tenth day			
Sixth week			

2. By Technetium scan

- Tenth day

Yes/No

- Sixth day

Yes/No

7. Function of the remnant and normal glands by tec-99 in percentage:

1. Tenth day -

2. Sixth week -

CONSENT FORM

**I , Mr/Mrs. -----
-----**

am willing to join this study on determining the function of the remnant gland after superficial parotidectomy. The details of the study have been explained to me. I have also been explained about the need for additional investigations and follow up.

Witness – Name:

- Signature:

Date:

Patient's signature

List of pictures:	Page no.
1. Vacutainers	9
2. Electronic chemical balance	9
3. Gamma Camera (1)	11
4. Gamma camera (2)	12
5. Parotid scan	12
6. Measuring the uptake	13
7. Superficial Parotidectomy – Sistrunk’s operation	14
8. Superficial Parotidectomy – Preservation of greater auricular nerve	15
9. Superficial Parotidectomy – Facial nerve identification	16
10. Parotid gland	23
11. Innervation of the parotid gland	27
12. Parotid gland and its relations	28
13. Cross-section of the Parotid gland	29
14. The arrangement of the facial nerve and parotid primordium at 18 mm	37
15. The arrangement of the facial nerve and parotid primordium at 22 mm	38

16. The arrangement of the facial nerve and parotid primordium at 26 mm	40
17. The relationships of the facial nerve, parotid primordium, retromandibular vein and external carotid artery at 37 mm	42
18. General pattern of development	45
19. Saliva secretion process	57
20. Sex distribution	73
21. Pathology in the affected glands	74
22. Side affected	75
23. Stenson's duct status	75
24. Comparison of uptake function between first and second Tc99 scans in the operated gland	76
25. Comparison of uptake function between first and second Tc99 scans in the operated gland	77
26. Comparison of uptake function between operated and non-operated glands in the first Tc99 scan	78
27. Comparison of uptake function between operated and non-operated glands in the second Tc99 scan	79
28. Comparison of saliva secretion between first and second scan days on the operated gland	80

29. Comparison of saliva secretion between first and second scan days on the non- operated gland	81
29. Comparison of saliva secretion between operated and non-operated glands on the first scan day	82
30. Comparison of saliva secretion between operated and non-operated glands on the second scan day	83

Index Number	Name	Hospital number	Sex	Age (years)	Pathology	Operated Side	Duct status	UF-1st scan- R side(%)	UF-1st scan L side(%)	UF-2nd scan R side(%)	UF-2nd scan L side(%)	Saxon's 1- R side(mg)	Saxon's 1- L side(mg)	Saxon's 2 - R side(mg)	Saxon's 2 - L side(mg)	Date of surgery	Date of first scan	Date of second scan
1	Chandan Mallik	753747C	M	22	2	R	Preserved	35	65	34	66	15	110	5	41	06./21/06	6/30/2006	8/5/2006
2	Arunima Hore	843428C	F	38	1	L	Preserved	84	16	76	24	200	152			6/28/2006	7/7/2006	8/19/2006
3	Lakshmiammal	700425A	F	84	2	L	Ligated	75	25	88	12	156	946	22	11	6/28/2006	7/7/2006	9/5/2006
4	Muniappa	813298C	M	49	1	L	Ligated	80	20	95	5	71	2	109	27	7/5/2006	7/14/2006	8/17/2006
5	Aswin Agarwal	840822C	M	15	6	L	Preserved	72	28	63	37	132	85	194	157	7/5/2006	7/14/2006	8/21/2006
6	Prince Abraham	813580C	M	18	1	R	Preserved	25	75	24	76	26	51	29	59	7/12/2006	7/21/2006	8/26/2006
7	Ram Narayan Dhar	830403C	M	36	1	R	Preserved	51	49	26	74	19	255	28	61	8/16/2006	8/24/2006	10/11/2006
8	Arul Paul	879183C	M	45	4	R	Preserved	11	89	0	100	15	78	35	94	8/23/2006	8/31/2006	10/7/2006
9	Latha Murali	581906B	F	40	5	L	Preserved	63	37	90	10	155	32	184	114	8/23/2006	9/2/2006	5/19/2007
10	Ramawathar Prasad	894586C	M	51	1	R	Preserved	27	73	20	80	44	48	22	32	11/22/2006	12/1/2006	1/10/2007
11	Saik Sarabodhin	965324C	M	39	1	R	Not Known	49	51	46	54	12	59	18	32	2/14/2007	2/22/2007	4/19/2007
12	Mousami Ghosh	989339C	F	38	1	L	Preserved	75	25	75	25	67	28	52	16	4/10/2007	4/19/2007	5/24/2007
13	Stella	002470D	F	27	1	R	Not Known	42	58	39	61	210	114	90	102	5/9/2007	5/19/2007	6/16/2007
14	Madhusuhan Dutta	925585C	M	58	1	L	Preserved	61	39	73	27	194	117	114	28	2/23/2007	4/12/2007	5/31/2007
15	Swapna Dey	944144C	F	43	1	L	Preserved	91	9	98	2	28	18	48	33	2/21/2007	3/5/2007	5/15/2007
16	Reena kwasar	941655C	F	24	1	L	Preserved	68	32	71	29	88	18	356	296	2/27/2007	3/9/2007	4/16/2007
17	Prabodh Chandra Dey	970873C	M	60	3	L	Preserved	79	21	89	11	14	16	36	21	4/20/2007	4/28/2007	6/11/2007
18	Debola Bera	971517C	F	41	1	R	Preserved	25	75	38	62	22	28	34	202	4/4/2007	4/14/2007	5/21/2007
19	Himangshu Sekhar	221210C	M	35	7	R	Preserved	52	48	42	58	12	20	12	22	5/23/2007	5/31/2007	7/21/2007
20	Swapan Kumar	997825C	M	28	1	L	Preserved	47	53	70	30	28	25	45	16	6/15/2007	6/25/2007	7/30/2007

Legend: Sex: M = Male, F = Female Side: R = Right, L = Left UF - Uptake function
Pathology: 1 - Pleomorphic adenoma, 2 - Mucoepidermoid carcinoma, 3 - Basal cell adenoma, 4 - Myoepithelioma,
5 - Chronic parotitis, 6 - Intraparotid lymphadenopathy, 7 - Lipoma