

# **A STUDY ON ACUTE SCROTUM**

*Dissertation*

*Submitted in partial fulfilment of the regulation of*

**M.S. DEGREE EXAMINATION**

**BRANCH I GENERAL SURGERY**

**Department of General Surgery**

**GOVT. STANLEY MEDICAL COLLEGE AND HOSPITAL**

**CHENNAI – 600001**



**THE TAMILNADU DR.M.G.R. MEDICAL UNIVERSITY**

**CHENNAI**

**APRIL – 2013**

# **CERTIFICATE**

This is to certify that this dissertation titled  
**“A STUDY ON ACUTE SCROTUM”**

is the bonafide work done by **Dr. RAJESWARI B.,** Post Graduate Student (2010 – 2013) in the Department of General Surgery, Stanley Medical College and Hospital, Chennai under the direct guidance and supervision and in partial fulfilment of the regulations laid down by The Tamil Nadu Dr. M.G.R. Medical University, Chennai for M.S. Branch I, General Surgery Degree Examination to held in April 2013.

**Prof. K.KAMARAJ, M.S.,**  
Professor of surgery,  
Department of General Surgery,  
Stanley Medical College and Hospital,  
Chennai – 600001

**Prof. P. DARWIN, M.S.**  
Professor and HOD,  
Department of General Surgery,  
Stanley Medical College and Hospital,  
Chennai – 600001

**Dr.S.GEETHALAKSHMI M.D., Ph.D.,**

Dean

Stanley Medical College

Chennai – 600001

## **DECLARATION**

I, **Dr. RAJESWARI B.**, solemnly declare that the dissertation titled

**“A STUDY ON ACUTE SCROTUM”**

is a bonafide work done by me at Govt. Stanley Medical College and  
Hospital from May 2010 to Oct 2012 under the guidance and supervision  
of my unit chief,

**Dr. K. KAMARAJ, M.S.,**

**Professor of Surgery**

This dissertation is submitted to The Tamilnadu Dr.M.G.R. Medical  
University towards the partial fulfilment of the requirements of  
M.S. Branch I, General Surgery degree examination.

PLACE: CHENNAI.

**Dr. RAJESWARI B.**

DATE:

## **ACKNOWLEDGEMENT**

My sincere thanks to **Dr. S. GEETHALAKSHMI, M.D., Ph.D.**, the Dean, Govt. Stanley Medical College, **Prof. P. DARWIN, M.S.**, Professor and HOD, Department of General Surgery, Govt. Stanley Medical College and Hospital for permitting me to undertake and successfully complete this study in Govt. Stanley Medical College and Hospital, Chennai.

I am extremely grateful to our unit Chief, **Prof. K. KAMARAJ, M.S.**, for his valuable guidance and encouragement throughout this study.

I thank my former Prof of Surgery, **Prof. K. S. RAVISHANKAR, M.S., FICS.**, for his guidance throughout the study.

I would like to thank my Assistant Professors **Dr. M. ANTO, M.S., Dr. THIRUMURUGANAND, M.S., Dr. KUMARESAN, M.S., Dr. ABRAHAM, M.S.**, for their valuable suggestions and help in completing this dissertation.

I thank the Professor of Radiology, Professor of Urology Govt. Stanley Hospital for their valuable guidance and support.

I am particularly thankful to **Dr. GANESH BABU, Dr. ARAVIND**, my fellow postgraduate colleagues for their valuable support in the time of need throughout this study.

Last but not the least I would like to thank my patients with gratitude for their cooperation in during the study.

## **TABLE OF CONTENTS**

<b>Sl.No</b>	<b>Topic</b>	<b>Page No</b>
1.	INTRODUCTION	1
2.	AIM OF THE STUDY	2
3.	REVIEW OF LITERATURE	3
4.	METHODS AND MATERIALS	42
5.	RESULTS	44
6.	DISCUSSION	71
7.	CONCLUSION AND SUMMARY	74
8.	BIBLIOGRAPHY	
9.	ANNEXURES <ul style="list-style-type: none"><li>• Institutional ethical committee clearance</li><li>• Proforma</li><li>• Patient consent form</li><li>• Master chart</li></ul>	

## **LIST OF ABBREVIATIONS**

USG	Ultrasonography
MIS	Mullerian Inhibiting Substance
BPH	Benign Prostatic Hypertrophy
UTI	Urinary Tract Infection
STD	Sexually Transmitted Disease

## **LIST OF FIGURES**

<b>SL NO</b>	<b>FIGURE</b>	<b>PAGE NO</b>
1	ANATOMY OF SCROTUM AND TESTIS	7
2	FOURNIER'S GANGRENE	54
3	TORSION OF APPENDIX OF TESTIS	59
4	USG DOPPLER SCROTUM	62
5	TORSION OF TESTIS	63
6	TWISTED CORD WITH GANGRENOUS TESTIS	64
7	TORSION IN AN UNDESCENDED TESTIS	65
8	GANGRENOUS TESTIS WITH TWISTED CORD IN INGUINAL CANAL	66

## LIST OF TABLES

<b>SL NO</b>	<b>TABLE</b>	<b>PAGE NO</b>
1	INCIDENCE OF VARIOUS CAUSES OF ACUTE SCROTUM	44
2	AGE DISTRIBUTION	46
3	DURATION OF SYMPTOMS	47
4	PREDISPOSING FACTORS	48
5	PRESENTING SYMPTOMS	49
6	DISTRIBUTION OF SYMPTOMS	50
7	TREATMENT GIVEN	51
8	DURATION OF SYMPTOMS IN TORSION TESTIS	67
9	TYPE OF TORSION OF TESTIS	68
10	SURGERY DONE IN TORSION OF TESTIS	69
11	OVERVIEW OF CASES OF TORSION TESTIS	70



## LIST OF GRAPHS

<b>SL NO</b>	<b>GRAPH</b>	<b>PAGE NO</b>
1	INCIDENCE OF VARIOUS CAUSES OF ACUTE SCROTUM	45
2	AGE DISTRIBUTION	46
3	DURATION OF SYMPTOMS	47
4	PREDISPOSING FACTORS	48
5	PRESENTING SYMPTOMS	49
6	DISTRIBUTION OF SYMPTOMS	50
7	TREATMENT GIVEN	51
8	DURATION OF SYMPTOMS IN TORSION OF TESTIS	67
9	TYPE OF TORSION OF TESTIS	68
10	SURGERY DONE OF TORSION OF TESTIS	69

Originality

GradeMark

PeerMark

## A STUDY ON ACUTE SCROTUM

BY RAJESWARI Z2101002 M.S. GENERAL SURGERY

turnitin

11%

SIMILAR

--

OUT OF 0

**INTRODUCTION**

Acute scrotum<sup>1</sup> is defined as "the acute onset of pain and swelling of the scrotum that requires either emergency surgical intervention or specific medical therapy."

Acute scrotum is an emergency situation requiring prompt evaluation and urgent surgical intervention if required.

There are many causes of acute scrotum, important being torsion of testis, torsion of appendix of testis/epididymis, acute epididymoorchitis, hematocele, pyocele and fourmier's gangrene of scrotum.

Though torsion of testis is more common in pubertal age group, it must be considered as the first differential diagnosis and in case of doubt, a prompt surgical intervention is carried out to prevent further complications.

Doppler USG of scrotum is an important diagnostic tool in acute scrotum.

No Service Currently Active

## **INTRODUCTION**

Acute scrotum<sup>1</sup> is defined as "the acute onset of pain and swelling of the scrotum that requires either emergency surgical intervention or specific medical therapy."

Acute scrotum is an emergency situation requiring prompt evaluation and urgent surgical intervention if required.

There are many causes of acute scrotum, important being torsion of testis, torsion of appendix of testis/epididymis, acute epididymoorchitis, acute hematocele, pyocele and Fournier's gangrene of scrotum.

Though torsion of testis is more common in pubertal age group, it must be considered as the first differential diagnosis and in case of doubt, a prompt surgical intervention is carried out to prevent further complications.

Doppler USG of scrotum is an important diagnostic tool in acute scrotum.

## **AIM OF THE STUDY:**

The main aim of this study is to note the prevalence and epidemiology of acute scrotum and their presentation, there by facilitating a systematic approach in identifying those patients who need early intervention to decrease associated morbidity and mortality.

# **REVIEW OF LITERATURE**

## **ANATOMY OF SCROTUM**

### **EMBRYOLOGY<sup>2</sup>:**

Germ cells from the yolk sac migrate to form the genital ridge by 3<sup>rd</sup> week of gestation. Germ cells develop into primordial testis between 4<sup>th</sup> to 8<sup>th</sup> week of gestation. Leydig cells in the primordial testis begin to secrete testosterone under the influence of the hormone human chorionic gonadotropin.

The two genital swellings fuse to form scrotum by 9<sup>th</sup> week of gestation. Under the influence of testosterone Wolffian Ducts develop into epididymis, vas deferens and seminal vesicles. Testis descends across the pelvis during this stage of development to lie near the deep inguinal ring.

By 13 weeks of development there develops an out pouching from the parietal peritoneum which forms into processus vaginalis. This out pouching herniates through the anterior abdominal wall muscles to enter the developing scrotum. The testis lies in the internal inguinal ring for about 2–3 months during development. This out pouching of processus vaginalis is dependent on the intra-abdominal pressure.

During 8<sup>th</sup> to 9<sup>th</sup> month of gestation testis enters into the scrotum along the processus vaginalis. At term the neck of processus vaginalis closes thus obliterating the communication between abdominal cavity and scrotum. As Wolffian duct develops into the epididymis, vas deferens and seminal vesicles, some remnants of it may persist at the head of epididymis which is called as appendix of epididymis. Sertoli cells in the developing testis secrete Mullerian Inhibiting Substance (MIS), thus causing regression of Mullerian duct, the remnant of which might remain as Appendix of Testis.

## **SURGICAL ANATOMY OF SCROTUM<sup>3,4</sup>**

Scrotum is a two cavity out pouching of the anterior abdominal wall containing the testis, epididymis and initial portion of the spermatic cords.

A median septum divides the scrotal cavity into right and left halves. It is homologous to labia majora in females.

### **Structure of scrotum:**

Following are the layers of the scrotum:

- **Skin:**

Skin of the scrotum is pigmented, very thin and has numerous folds called rugae. There is a midline raphe separating the right and left halves which is due to the fusion of two genital swellings.

- **Superficial fascia:**

It is the continuation of fatty and membranous layer of superficial fascia of the anterior abdominal wall. The superficial fatty layer is replaced by a subcutaneous muscle, dartos which is supplied by sympathetic fibres. Contraction of this muscles leads to increased wrinkling of the scrotal skin. The membranous layer of superficial fascia of anterior abdominal wall (Scarpa's fascia) continues as the

membranous layer of scrotal superficial fascia where it is called as Colle's fascia.

- **Spermatic fasciae:**

They are deep to the superficial fascia and are made up of three layers.

- **External spermatic fascia:**

It is an extension of external oblique aponeurosis.

- **Cremasteric fascia:**

This is derived from the internal oblique muscle which contains both cremasteric muscle and fascia.

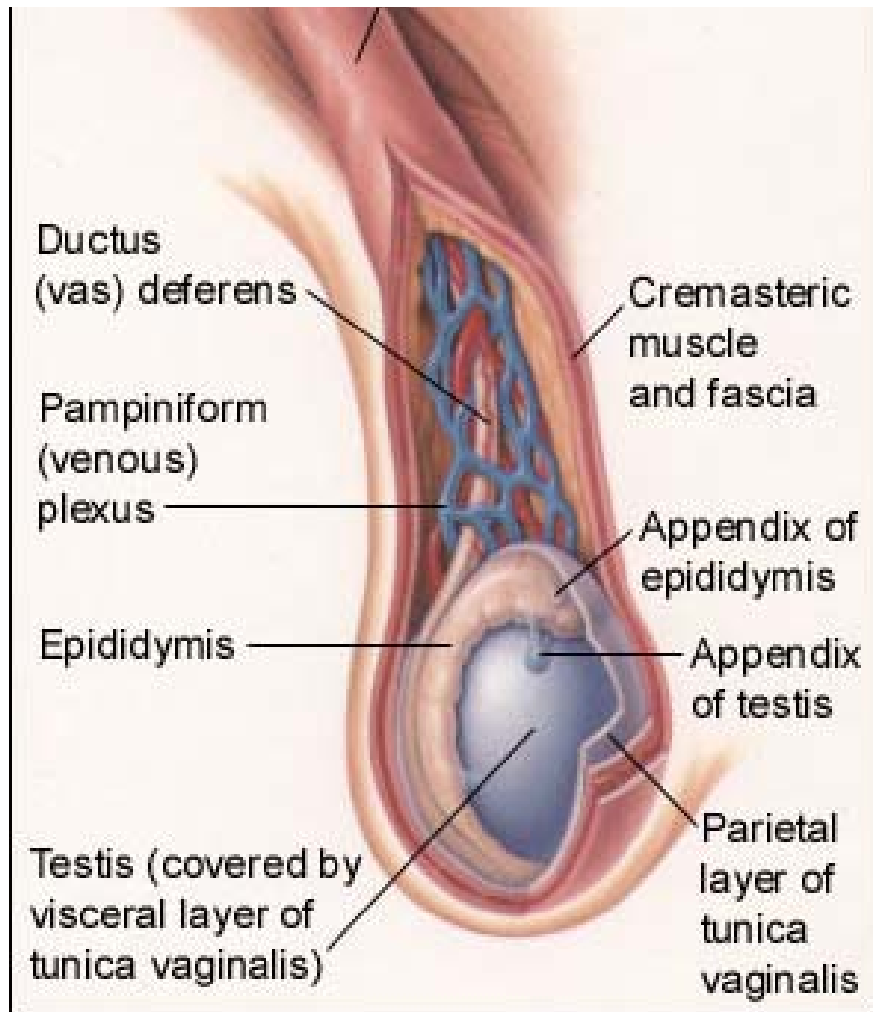
- **Internal spermatic fascia:**

It is an extension of transversalis fascia.

- **Tunica vaginalis:**

It is nothing but the persistent portion of processus vaginalis which covers the anterior, medial and lateral surfaces of the testes. It is made of two layers, parietal and visceral, forming a closed sac and the testes invaginate this sac from behind.





**FIGURE 1: ANATOMY OF SCROTUM AND TESTIS**

The picture shows the various layers of the scrotum, coverings of the testis and the spermatic cord.

## **Blood supply of scrotum:**

### **Arterial supply:**

1. Anterior scrotal artery (a branch of the deep external pudendal artery)
2. Posterior scrotal artery (a branch of the internal pudendal artery).

### **Venous drainage:**

Inferior vena cava via the testicular veins

### **Nerve supply to scrotum:**

Scrotum is supplied by following nerves:

- Scrotal nerves – anterior and posterior branches
- Cremastic muscle is supplied by Genital branch of Genitofemoral nerve
- Posterior femoral cutaneous nerve (Perineal branches)

### **Lymphatic drainage of scrotum:**

Skin, subcutaneous tissue and tunica vaginalis drain into superficial group of inguinal lymph nodes.

Testis and epididymis drain into the para-aortic lymph nodes via the lymphatics along the testicular vessels.

**Functions of scrotum:**

Spermatogenesis requires temperature lower than the normal body temperature. This is accomplished by the scrotum which lies outside the abdominal cavity, thus the temperature being less than the core body temperature.

Cremaster muscle, during contraction shrinks the scrotum, thus bringing the testes closer to the abdominal wall and increase in the temperature when exposed to cold temperatures.

Scrotum also forms a protective covering for the testis, epididymis and lower ends of the spermatic cord.

## **TESTIS:**

The word testis is derived from the Greek word *orchis*<sup>6</sup>. The testis is a paired reproductive organ situated in the scrotum, separated from each other by a median septum. The testis has a length of about 3.5-5 cm, width of 2.5-3 cm and an anteroposterior diameter of 3 - 3.5cm.

It is placed obliquely in the scrotum, with its superior pole directed slightly anterior and lateral. Inferiorly, the testis is attached to the scrotum at its lower pole by the remnant of gubernaculum which forms the scrotal ligament.

The remnant of processus vaginalis, the tunica vaginalis envelopes the testis all around except at its posterolateral surface which is occupied by epididymis and spermatic cord. The tunica vaginalis has two layers, parietal and visceral layers. There is a slit like recess between posterolateral surface of testis and epididymis called as Sinus of epididymis which is due to the firm adherence of visceral layer of tunica vaginalis to the testis.

Tunica albuginea is a tough, fibrous layer present deep to the tunica vaginalis layer and is firmly attached to the testis. It forms an incomplete posterior septum called as mediastinum testis.

Deep to the tunica albuginea is a vascular coat of testis called as tunica vasculosa.

**Structure of testis:**

The glandular part of testis consists of 200 – 300 lobules. Each lobule contains 2 – 3 seminiferous tubules.

The seminiferous tubules join together to form 20 – 30 straight tubules which enter the mediastinum testis and anastomose together to form rete testis.

Rete testes in turn give rise to 12 – 20 efferent ductules which enter the epididymis.

**Epididymis:**

It is made up of highly coiled tubes which act as reservoirs of spermatozoa.

It has an upper end called as head or Globus major or caput, body or corpora and a tail or Globus minor or cauda.

The head is made up of highly coiled efferent ductules while the body and tail are made up of a single duct, the duct of epididymis, which is highly coiled on itself. At the lower end of the tail this duct becomes continuous with the ductus deferens.

**Arterial supply:**

The testis is supplied by testicular artery, which is a lateral branch of aorta which arises at the level of L2 vertebra.

It descends along the posterior abdominal wall and enters the spermatic cord via the deep inguinal ring.

**Venous drainage:**

The veins emerging from the testis form the pampiniform plexus of veins. The plexus condenses into four veins at the superficial inguinal ring, into two at the deep inguinal ring and ultimately one vein is formed which drains into inferior vena cava on the right side and left renal vein on the left side.

**Lymphatic drainage:**

The lymphatics from the testis ascend along the testicular vessels and drain into the para-aortic nodes at the level of L2 vertebra.

**Nerve supply:**

Testis is supplied by sympathetic nerves arising from T10 segment of spinal cord which pass through renal and aortic plexuses. They are both afferent (for testicular sensation) and efferent (vasomotor).

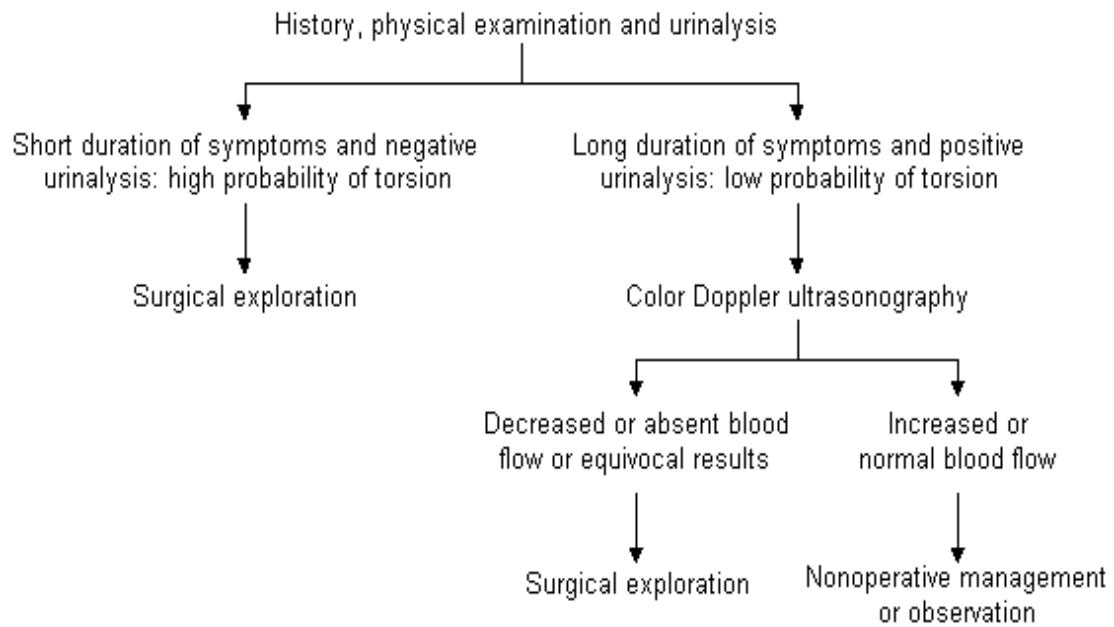
## ACUTE SCROTUM

Acute scrotum is defined as,"the acute onset of pain and swelling of the scrotum that requires either emergency surgical intervention or specific medical therapy." Several acute scrotal conditions can present in similar way, testicular torsion is by far the most significant. Testicular torsion is a true surgical emergency because the testis cannot be salvaged if the patient presents late after the onset of symptoms.

Differential diagnosis for acute scrotum:

1. Torsion of testis
2. Acute Epididymitis
3. Acute Epididymo-orchitis
4. Torsion of appendix of testis
5. Torsion of appendix of epididymis.
6. Infection of scrotum - Abscess of scrotal wall / scrotal erysipelas
7. Gangrene of scrotum - Fournier's gangrene
8. Trauma to scrotum.
9. Miscellaneous –
  - i. Idiopathic scrotal oedema
  - ii. Scrotal fat necrosis
  - iii. Henoch-Schonleinpurpura
  - iv. Hurricaine Testicular tumour
  - v. Ischemic orchitis





**ALGORITHM FOR MANAGEMENT OF ACUTE  
SCROTUM**

## **TESTICULAR TORSION<sup>7, 8, 9, 27</sup>**

**Definition:** It is a condition in which testicle rotates and strangulates its blood supply at the level of spermatic cord

### **Pathophysiology:**

Torsion of testis is uncommon because a fully descended normal testis is well anchored and cannot rotate. There must be presence of one or more anatomical abnormalities for torsion to take place.

### **Predisposing factors:**

1. Inversion of testis: it is the most common predisposing cause. Testis is rotated so that it lies upside down or transversely.
2. High investment of tunica vaginalis: it is also referred to as Bell Clapper Deformity in which testis hangs within the tunica like a clapper in a bell.
3. There is presence of a small pedicle which connects epididymis to testis. If this undergoes twisting, it leads to torsion of testis alone wherein epididymis is normal.

**Precipitating factors:**

- The spiral attachment of the cremaster favours the torsion of testis around a vertical axis, provided there is presence of any above said anatomical abnormalities.
- Straining at stools, lifting heavy weight and coitus are all precipitating factors.
- Trauma
- Occasionally torsion may develop spontaneously during sleep.

**Epidemiology:**

About 1 in 4000 males less than 25yrs age develop testicular torsion. It most commonly involves the left side.

There are more chances of salvaging the testis (chances reaching up to 100%) if the patient presents within 6hrs of symptom onset. The chances of salvage keep on decreasing as the duration increases with 20% chance by 12hrs and virtually nil by 24hrs.

**Clinical presentation:**

Patients usually present with sudden onset of severe scrotal pain. Pain might be preceded by trauma, straining or no activity. Nausea and vomiting might be complained by some patients. Torsion of testis must be the first differential diagnosis in all patients presenting with sudden onset severe scrotal pain irrespective of the age of the patients.

**Physical findings:**

Examination of scrotum shows tense and tender testis which may be placed high up in the scrotum with a transverse lie. Most often, patient will not allow anyone to touch the scrotum for the fear of severe pain it induces. Careful palpation might reveal twisted cord at the upper pole of testis. As the duration increases, progressive edema of the skin and the scrotal tissues occurs and by 18 – 24hrs the findings might be almost similar to epididymo-orchitis.

In general all signs of infection and inflammation like fever, local rise of temperature are absent in case of torsion of testis.

**Additional signs:**

***DEMING SIGN***

Affected testis is positioned high because of twisting of cord and spasm of cremaster muscle

***ANGELL'S SIGN***

Opposite testis lies horizontally because of the presence of mesorchium

***PREHN'S SIGN***

Elevation of scrotum relieves pain of epididymo-orchitis but aggravates in case of torsion

***CREMASTERIC REFLEX***

Absent on the affected side

**Management:**

USG of the scrotum with Doppler study is a must for all cases presenting with acute scrotal pain. USG of the scrotum helps to differentiate between torsion of testis from other causes of acute scrotum. In case of torsion, USG with Doppler shows absence of blood flow in the testis and sometimes twisted cord structures might be demonstrated by the USG whereas epididymo-orchitis shows increased flow to the epididymis.

If USG with Doppler is not available, urgent surgical exploration of scrotum is mandated as testicular torsion is a true surgical emergency and any delay might result in loss of viability of testis which has a lifelong morbidity of infertility. On exploration the involved cord must be untwisted, a warm pad must be put over the testis and contralateral side orchidopexy must be done. Then the ipsilateral testis must be inspected for viability and if found viable, tunica albuginea layer must be anchored to the dartos layer of the scrotum. If the testis is found to be not viable orchidectomy should be done.

A negative exploration is better than conservative management in case of doubtful diagnosis, since scrotal exploration has least long term morbidities.

“Intermittent” testicular torsion is a condition in which patient presents with classical history of torsion but clinical examination and USG scrotum are normal. In this type of patients an option of elective bilateral orchidopexy must be offered before the patient develops full blown torsion of testis.



## **TORSION OF TESTICULAR OR EPIDIDYMAL**

### **APPENDAGES<sup>10, 11, 25</sup>**

This is a condition mimicking testicular torsion and is more common in pediatric age group. Patients usually present with unilateral scrotal pain but examination reveals normal testis. Occasionally a small mass can be palpable at the upper pole of the testis. In fair skinned individual and if the appendage is ecchymotic, it can be seen through the scrotal skin, the sign called as “Blue Dot sign”.

USG Doppler of the scrotum demonstrates a normal testicular flow with a small hypervascular mass in the upper pole of the testis in some cases.

The condition is self-limiting without requirement of any surgery. If scrotum is opened and torsion of an appendage is identified a simple excision of the appendage is sufficient without requirement of any orchidopexy.

## **EPIDIDYMITIS AND EPIDIDYMOORCHITIS<sup>12, 24</sup>**

It is the inflammation of the epididymis and testis.

### **Classification of Epididymitis**

<b>Acute bacterial epididymitis</b>
Secondary to UTI
Secondary to STD
<b>Nonbacterial infectious epididymitis</b>
Viral
Fungal
Parasitic
<b>Noninfectious epididymitis</b>
Idiopathic
Traumatic
Autoimmune
Amiodarone-induced
Associated with a known syndrome (e.g., Behçet's disease)
<b>Chronic epididymitis</b>
<b>Chronic epididymyalgia</b>

**Pathophysiology:**

It usually results from ascending infection from the urinary bladder or urethra, or prostate via the ejaculatory ducts and vas deferens into the epididymis.

In pediatric patients, it is often related to a UTI and/or an underlying genitourinary congenital anomaly.

BPH and associated stasis, UTI, and urinary catheterization are the most common cause of epididymitis in elderly men.

In sexually active men younger than 35 years of age, epididymitis is commonly the result of an STD

**Pathogens:**

In pediatric and elderly populations it is most often caused by coliform organisms

*N. gonorrhoeae* and *C. trachomatis* in men < 35yrs of age

*E. coli* and *Haemophilus influenza* in homosexual men

Viral, fungal, and parasitic microorganisms have also been implicated in epididymitis

**Clinical features:**

Patients usually present with unilateral pain in the scrotum radiating to the groin or flank.

Patients often give history of fever and urinary symptoms like dysuria.

On examination the scrotum may be erythematous on the side of involvement with tenderness at the site of epididymitis.

USG Doppler scrotum helps to differentiate from the other causes of acute scrotum which shows increased blood flow to the epididymis. A reactive hydrocele might be present in few cases.

Urine routine examination might show presence of pus cells and culture might show the presence of the causative bacteria.

**Treatment:**

Oral antibiotic treatment is directed against specific causative organisms.

In addition, bed rest, scrotal elevation and the use of nonsteroidal anti-inflammatory agents are helpful in reducing the duration of the symptoms.

In patients with epididymitis caused by sexually transmitted organisms, treatment of their sexual partners is recommended to prevent reinfection.

For patients with sepsis or severe infection, hospitalization and parenteral antibiotic therapy may be needed.

Open drainage is indicated in cases in which an abscess develops.

Occasionally, patients with chronic, relapsing epididymitis and scrotal pain may require epididymectomy for relief of their symptoms.

## **FOURNIER'S GANGRENE<sup>13, 14, 15, 24</sup>**

Fournier gangrene is a condition characterised by necrotizing fasciitis of the perineal, perianal, or genital areas.

It was first described by French venereologist **Jean Alfred Fournier** in 1883, when he described a study in which 5 healthy young men suffered from a rapidly progressive gangrene of the penis and scrotum without any predisposing factor or any cause.

### **Pathophysiology**

Infection most commonly arises from the skin, urethra, or rectal regions.

The infection leads to obliterative endarteritis followed by the gangrene of the skin and subcutaneous tissue which further helps in bacterial proliferation.

Infection from the perineal region may spread to the surrounding regions like the scrotum, the penis and the anterior abdominal wall along the fascial planes. Involvement of testis is rare as it has a different blood supply and also due to the presence of tough tunica vaginalis layer.

Infection is caused due to an imbalance between the host immunity and the virulence of the organism.

The predisposing factors allow the organism to cause the infection while the reduced host immunity helps in the spread of the disease.

The virulence of the organism not only depends on the proliferation in the number of the organisms and triggering infection but also to the enzymes and toxins produced in large amounts by these organisms which cause local tissue destruction. This mechanism is classically seen in Streptococcal species but might be seen in other organisms also.

Initially Fournier's gangrene was thought to be monobacterial in origin, caused mainly by Streptococci, but present studies show that it is polymicrobial in nature.

The following are common causative microorganisms:

- Streptococcus
- Staphylococcus
- Enterobacteriaceae
- Anaerobic bacteria
- Fungi

The polymicrobial infection acts in a synergistic fashion. Few bacteria produce enzymes and toxins causing thrombosis of the blood vessels. This reduces the oxygen tension which helps in proliferation of anaerobes. Anaerobic bacteria produce variety of enzymes which are responsible for tissue destruction which helps in destruction of fascial planes thus aiding in rapid extension of the disease.

Fascial plane destruction and tissue necrosis are the hallmarks of this disease.

The tissue destruction can be so severe that the disease might spread from the perineum to the anterior abdominal wall and cause destruction of the whole anterior abdominal wall.



## **Etiology:**

Though it was described as idiopathic gangrene of scrotal skin, cause is identifiable in about 75% cases.

Anorectal causes:

- Perianal abscesses;
- Fissure in ano
- Perforations of colon.
- Appendicitis
- Diverticulosis of colon

Urogenital tract causes:

- Infection spreading from Bulbourethral glands,
- Injury to urethra,
- Injury during urethral stricture dilatation,
- Epididymo-orchitis, or catheter related lower urinary tract infections.

## Dermatologic causes

- Hidradenitissuppurativa,
- Pressure sore over the scrotum,
- Traumatic.
- Poor perineal hygiene, for instance in paraplegic patients.

Presence of foreign body might also be a cause.

## **Precipitating factors:**

- Blunt injury to thorax
- soft-tissue injuries
- Genital piercings
- Urethral instrumentation
- penile implants
- Intramuscular injections

In children, the following have led to the disease:

- Circumcision
- Strangulated inguinal hernia
- Omphalitis
- Trauma
- Urethral catheterisation
- Perianal abscesses

**Pathogens:**

It is a polymicrobial infection with *E. coli* being the predominant aerobe and *Bacteroides* being the predominant anaerobe.

Other common isolates are:

- *Proteus species*
- *Staphylococcal species*
- *Enterococcal species*
- *Aerobic and anaerobic Streptococci*
- *Pseudomonas species*
- *Klebsiella species*
- *Clostridium species*

**Predisposing disease:**

- Diabetes mellitus (present in as many as 60% of cases)
- Obesity
- Alcoholism
- Cirrhosis of liver
- Any Extremes of age
- Haematological Malignancy (eg, acute promyelocyticleukemia, acute nonlymphoidleukemia, acute myeloblasticleukemia)
- Autoimmune disorder like Systemic lupus erythematosus
- AIDS
- Malnutrition
- Immunosuppressive drugs

**Clinical presentation:**

Pain and tenderness are the hallmark of the disease.

Disease progresses through the following stages:

1. Prodromal stage: characterised by fever and lethargy, lasts for 2 – 7 days
2. Stage of intense pain: severe genital pain often associated with edema of the overlying skin; itching may also be present
3. In the third stage the pain increases in intensity with development of progressive erythema of skin
4. Skin changes in appearance to a rather dusky look with presence of subcutaneous crepitus.
5. Pus discharge from the wound with overt gangrene of skin of genitalia develops.

**Extent of spread:**

- The disease can spread along the fascial planes of the anterior abdominal wall up to the clavicle.
- All the branches which supply the scrotal skin will get thrombosed subsequently during the disease progression leading to gangrene of the whole scrotum.
- The urethra, testis, corpora cavernosa are spared.

## TREATMENT

### Medical therapy:

If the patient presents in late stages, aggressive resuscitation of the fluid balance with electrolyte abnormality correction must be the initial goal. Patient must be started on broad spectrum antibiotics covering both gram positive and gram negative and anaerobic organisms.

### Surgical Therapy:

**1) Incision and drainage:** this is the most basic surgery required for the disease. Opening of the scrotum in the median raphe followed by drainage of all the pus forms the first step in the surgical treatment

**2) Excision of necrotic tissue:** Aggressive excision of all the necrotic tissue with a rim of normal tissue is required.

**3) Fecal diversion:** In cases of extensive perineal involvement with potential fecal contamination of the wounds, a fecal diversion procedure must be done.

**4) Urinary diversion:**Bladder catheterisation is sufficient in most of the cases while only few patients require supra pubic cystotomy.



**5) Orchidectomy:** Orchidectomy is not required in most of the cases as the testicles are usually spared in this disease. If testis is found to be involved, orchidectomy must be done.

**6) Scrotal reconstruction:** Once the disease is controlled and there is sufficient granulation tissue formed, scrotal reconstruction can be done by any of the following methods.

- Primary skin suturing
- Local advancement flaps
- Split skin grafting

**Complications:** Spreading infection and sepsis are the most important complications of Fournier's gangrene.

**Outcome and prognosis:** Prognosis mainly depends on the age of the patient and the extent of the sepsis.

## **SCROTAL WALL INFECTIONS** <sup>26</sup>

Superficial infections of the skin of the scrotum are included in this group. They might be classified as cellulitis, abscess and fasciitis. These conditions can be differentiated from the deep infections of the scrotum by the fact that testis can be palpable separately in these conditions and it will be non-tender.

Scrotal wall abscess can be due to infection of sebaceous cyst, folliculitis or a cellulitis with secondary abscess formation. Incision and drainage followed by daily debridement and wound dressing with appropriate antibiotic cover is the treatment required.

## **TRAUMA<sup>16, 17</sup>**

Trauma to the testis might be either penetrating or blunt injury. Most often it is blunt injury, a blow forcing the testis against the pubic bone. Penetrating injuries occur as a consequence of gunshot and knife wounds and from bomb blasts.

Patients usually present with severe pain in the scrotum with variable swelling of the scrotum. Patients might also have nausea and vomiting.

Testis might not be palpable separately if there is presence of hematocele. If the testis is palpable, it will be extremely tender. The resulting scrotal haematoma can be very large and the bruising and swelling so caused may spread into the inguinal region and lower abdomen.

USG of the scrotum helps to identify the possible injuries produced. Exploration of testis is required in cases of hematocele and in case of intraparenchymal injury to the testis.

In cases with severe destruction of testicular parenchyma, orchidectomy might be needed.

## **MATERIALS AND METHODS**

### **AIMS AND OBJECTIVES:**

1. To study various causes of acute scrotum
2. To know the mode of presentation, investigations required and the treatment outcome of various causes of acute scrotum with special reference to torsion of testis.

The study was conducted by a retrospective and a prospective analysis of the patients who were admitted with acute scrotum, in all the surgical units of the Department of General Surgery, Government Stanley Medical College and Hospital, Chennai between May 2010 and October 2012.

### **INCLUSION CRITERIA:**

1. All cases of acute scrotum admitted in our hospital

### **EXCLUSION CRITERIA:**

1. Patients not willing for getting investigated.
2. Patients absconding before full clinical evaluation and treatment.

## **METHODOLOGY:**

A total of 60 patients who presented with acute scrotum were included in the study.

The study design is as follows.

1. All patients were subjected to detailed history taking and physical examination.
2. Patients underwent basic investigations like complete blood counts, bleeding time, clotting time and renal function tests, cardiac evaluation by ECG and echocardiography, if warranted and a Chest X ray.
3. Then the patients were subjected to USG scrotum with Doppler studies, if required.
4. Based on the clinical diagnosis and the USG scrotum reports, patients were subjected to appropriate surgery, if warranted. Cases of acute epididymoorchitis were managed conservatively.
5. Patients closely monitored in the post-operative period for any complications.
6. The findings are tabulated according to the pre-designed proforma.

## RESULTS

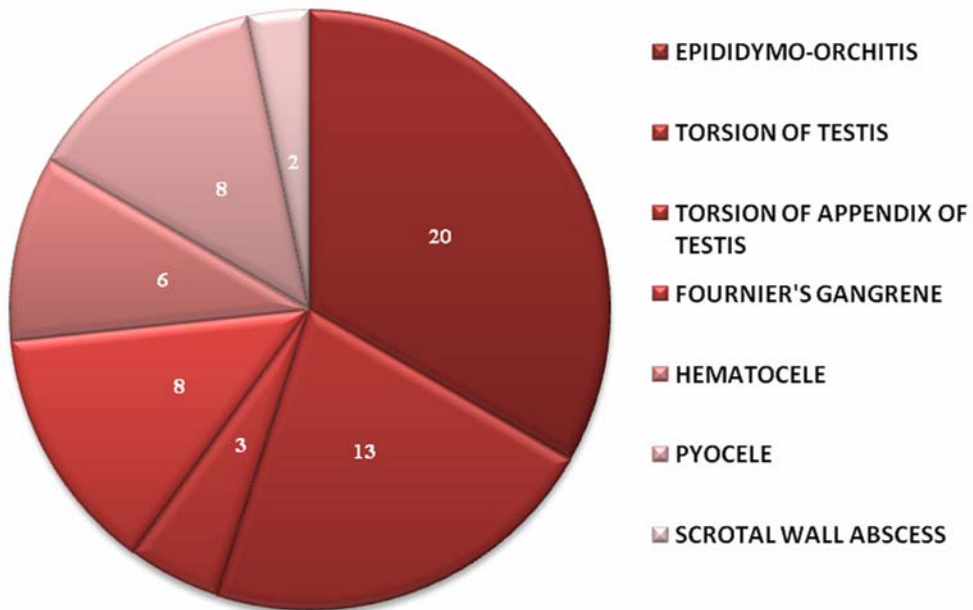
A total of 60 cases were included in the study group.

### INCIDENCE OF VARIOUS CAUSES OF ACUTE SCROTUM:

SL. NO.	DIAGNOSIS	NO. OF CASES	PERCENTAGE
1	EPIDIDYMO-ORCHITIS	20	33.3%
2	TORSION OF TESTIS	13	21.7%
3	TORSION OF APPENDIX OF TESTIS	3	5%
4	FOURNIER'S GANGRENE	8	13.3%
5	HEMATOCELE	6	10%
6	PYOCELE	8	13.3%
7	SCROTAL WALL ABSCESS	2	3.4%

**TABLE 1: INCIDENCE OF VARIOUS CAUSES OF ACUTE SCROTUM**

## INCIDENCE OF VARIOUS CAUSES OF ACUTE SCROTUM

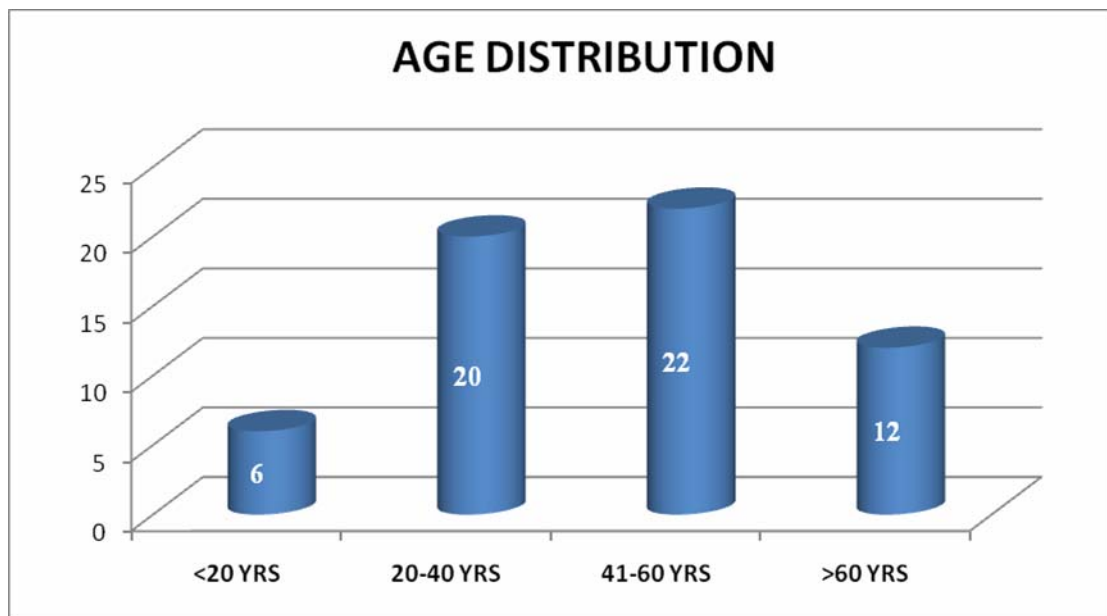


**GRAPH 1: INCIDENCE OF VARIOUS CAUSES OF ACUTE SCROTUM**

## AGE DISTRIBUTION:

AGE	NO OF CASES	PERCENTAGE
<20	6	10
20 – 40	20	33.3
41 – 60	22	36.7
>60	12	20

**TABLE 2: AGE DISTRIBUTION**



**GRAPH 2: AGE DISTRIBUTION**

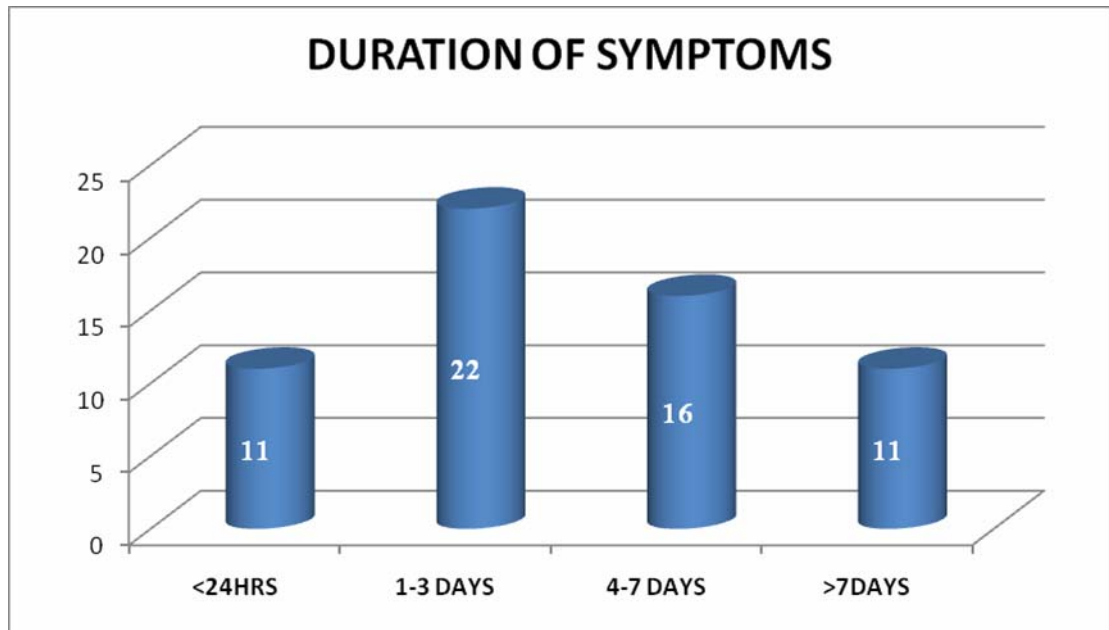
Majority of the cases were in the age group of 41 – 60yrs (36.7%), followed by 20 – 40yrs (33.3%).



### DURATION OF SYMPTOMS:

DURATION	NO. OF CASES	PERCENTAGE
0 – 24 HRS	11	18.3
1 – 3 DAYS	22	36.7
4 – 7 DAYS	16	26.7
>7 DAYS	11	18.3

**TABLE 3: DURATION OF SYMPTOMS**



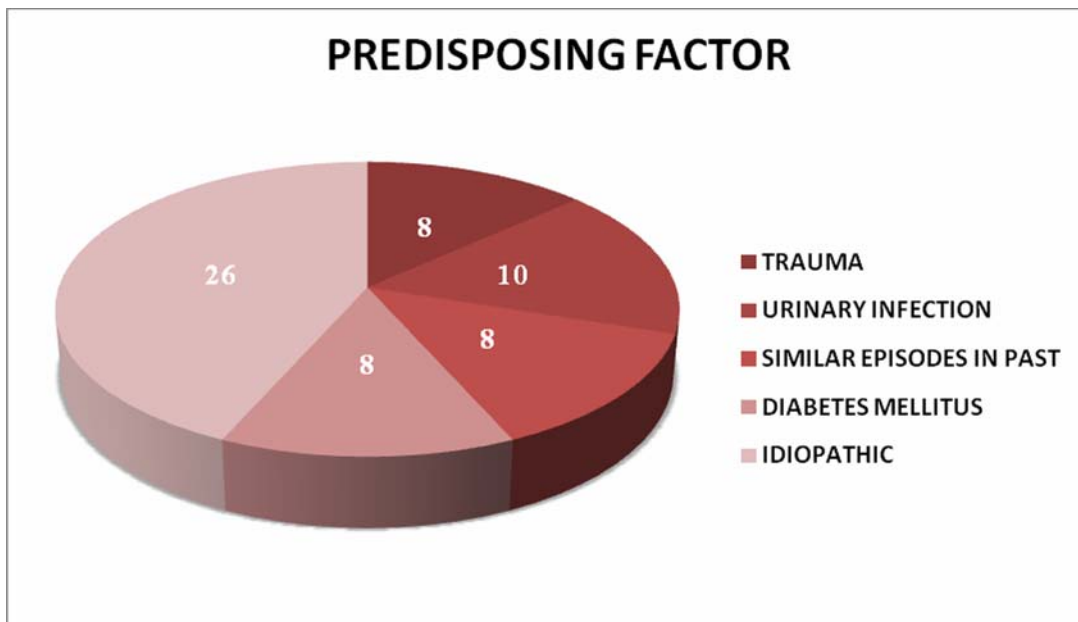
**GRAPH 3: DURATION OF SYMPTOMS**

Majority of the patients (36.7%) had a mean duration of symptoms of 1 – 3 days.

**PREDISPOSING FACTORS:**

<b>FACTOR</b>	<b>NO OF CASES</b>	<b>PERCENTAGE</b>
TRAUMA	8	13.3%
URINARY INFECTION	10	16.7%
SIMILAR EPISODES IN PAST	8	13.3%
DIABETES MELLITUS	8	13.3%
IDIOPATHIC	26	43.4%

**TABLE 4: PREDISPOSING FACTORS**



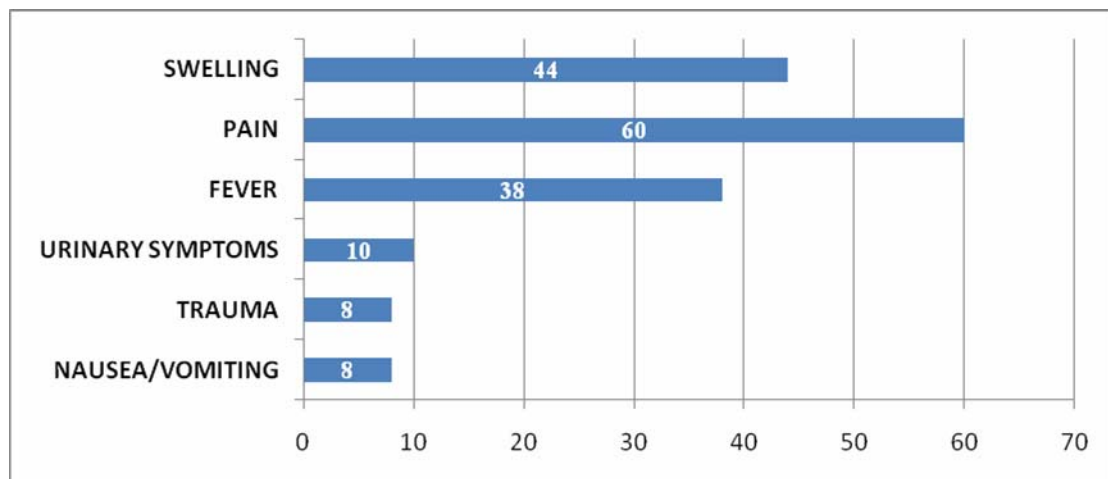
**GRAPH 4: PREDISPOSING FACTORS**

Predisposing factors were absent in most of the patients (43.4%).

## PRESENTING SYMPTOMS:

SYMPTOM	NO OF CASES	PERCENTAGE
SWELLING	44	73.3%
PAIN	60	100%
FEVER	38	63.3%
URINARY SYMPTOMS	10	16.6%
TRAUMA	8	13.3%
NAUSEA/ VOMITING	8	13.3%

**TABLE 5: PRESENTING SYMPTOMS**



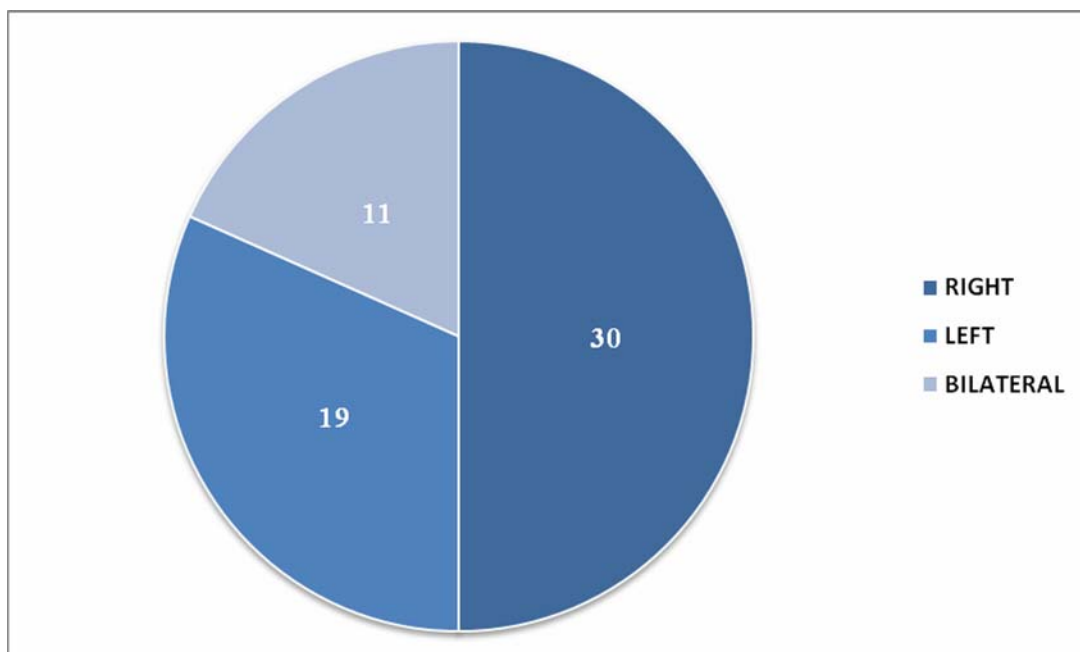
**GRAPH 5: PRESENTING SYMPTOMS**

All the patients presented with pain in the scrotum while majority of them (73.3%) also presented with swelling of the scrotum.

### DISTRIBUTION OF SYMPTOMS:

SIDE	NO OF CASES	PERCENTAGE
RIGHT	30	50%
LEFT	19	31.7
BILATERAL	11	18.3

**TABLE 6: DISTRIBUTION OF SYMPTOMS**



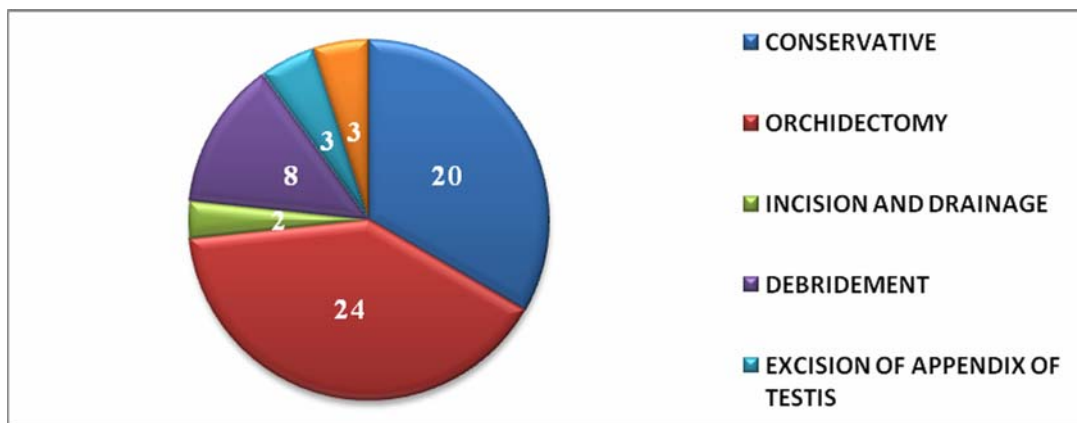
**GRAPH 6: DISTRIBUTION OF SYMPTOMS**

50% of the patients had righted sided disease while 31.7 % had a left sided disease. Bilateral involvement was seen in 18.3% patients

### TREATMENT GIVEN:

TREATMENT GIVEN	NO OF CASES	PERCENTAGE
CONSERVATIVE	20	33.3%
SURGICAL	40	66.7%
INCISION & DRAINAGE	2	3.3%
DEBRIDEMENT	8	13.4%
EXCISION OF APPENDIX OF TESTIS	3	5%
B/L ORCHIDOPEXY	3	5%
ORCHIDECTOMY	24	40%

**TABLE 7: TREATMENT GIVEN**



**GRAPH 7: TREATMENT GIVEN**

Conservative treatment was followed in 33.3% patients while 66.7% patients needed surgical management.

## **DESCRIPTION OF INDIVIDUAL CASES**

### **EPIDIDYMOORCHITIS:**

We encountered 20 cases of epididymoorchitis in our study period which accounted for 33% of cases. Mean age of presentation was 51yrs (Range: 24 – 72yrs). Majority of the cases (65%) had epididymoorchitis on right side, while 35 % was on left side. Mean duration of symptoms was 3.6 days.

All the patients presented with unilateral pain in the scrotum associated with fever. Urinary symptoms were present in 10 cases (50%), diabetes mellitus in 2 cases (10%) while history of previous episodes of epididymo-orchitis was present in 6 cases (30%).

Urine examination was done in all the cases, which showed traces of albumin in 2cases while there was presence of significant number of pus cells in 6 cases.

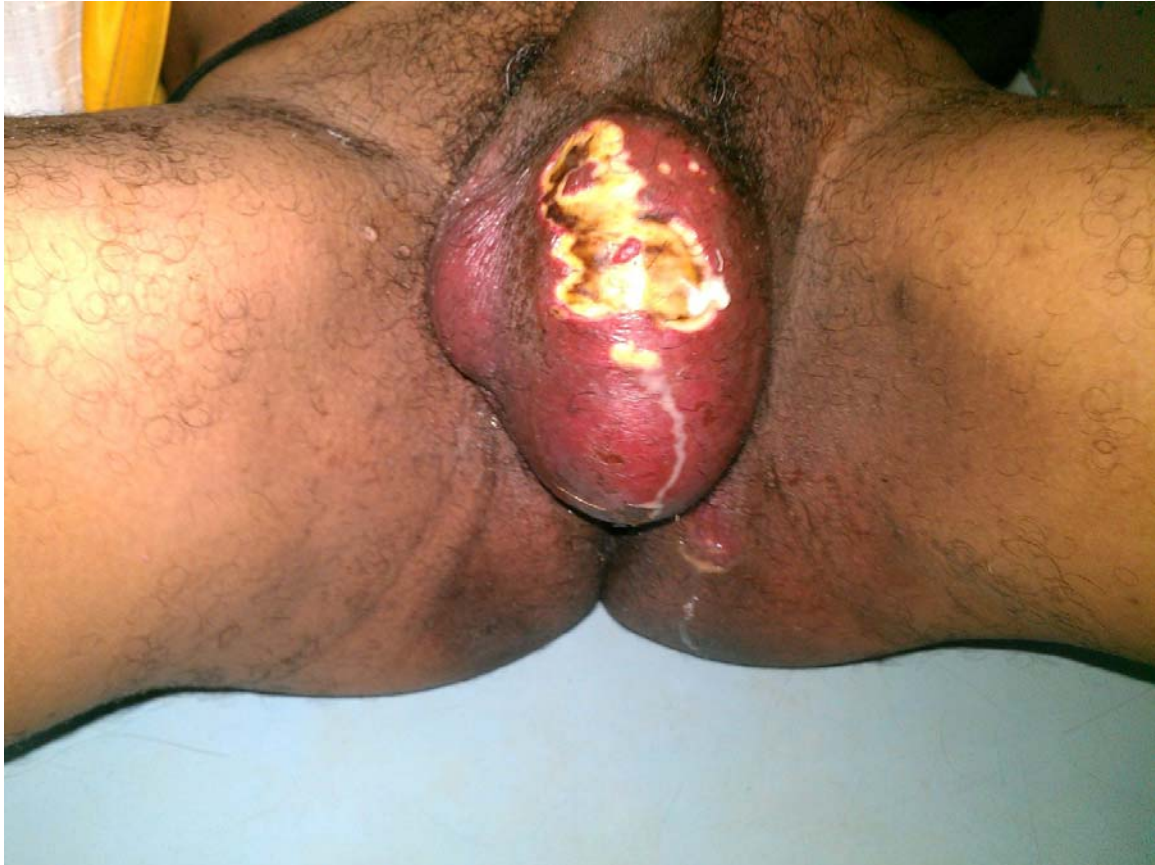USG scrotum was done all the patients which showed features of epididymo-orchitis i.e., hypoechoic, diffusely enlarged testis with hyperechoic and swollen epididymis with increased blood flow.

All the patients responded well for the conservative management.

### **FOURNIER'S GANGRENE:**

Fournier's gangrene accounted for a total of 8 cases (13.3%) in the present study. Mean age of presentation was 60.5yrs (Range: 45 – 75yrs). Mean duration of symptoms was 9.25 days (Range: 5 – 11 days). History of diabetes mellitus was present in 3 cases (37.5%).

All the patients were subjected to debridement initially followed by daily saline dressings. Based on the size of final defect, patients were treated conservatively or secondary suturing or split skin grafting. In our study 3 patients (37.5%) were treated with debridement alone, 3 patients (37.5%) underwent secondary suturing and 2 patients (25%) were subjected to split skin grafting.



**FIGURE 2: FOURNIER'S GANGRENE**

Above picture shows clinical appearance of Fournier's gangrene with gangrene of the scrotal skin and surrounding inflammation which has spread up to the upper part of left thigh.



## **HEMATOCELE:**

Total number of cases of hematocele encountered was 6 cases (10%). Mean age of presentation was 35.67yrs (Range: 21 – 48yrs). Duration of symptoms was shorter in hematocele, with mean duration being 2.5 days. History of trauma was done in all cases. USG scrotum showed features suggestive of hematocele. Orchidectomy was done in all cases.

**PYOCELE:**

Pyocele accounted for 8 cases (13.3%) with one case associated with Fournier's gangrene. Mean age of presentation was 54.12yrs with mean duration of symptoms being 7.12days. History of diabetes mellitus was present in 2 cases (25%). All the patients were subjected for USG scrotum followed by orchidectomy.

## **SCROTAL WALL ABSCESS:**

We encountered two cases of scrotal wall abscess (3.3%). Mean age of presentation was 47yrs with mean duration of presentation of 10days. History of diabetes was present in one patient. Incision with drainage of abscess was present in both the cases and the patients improved well following the treatment.

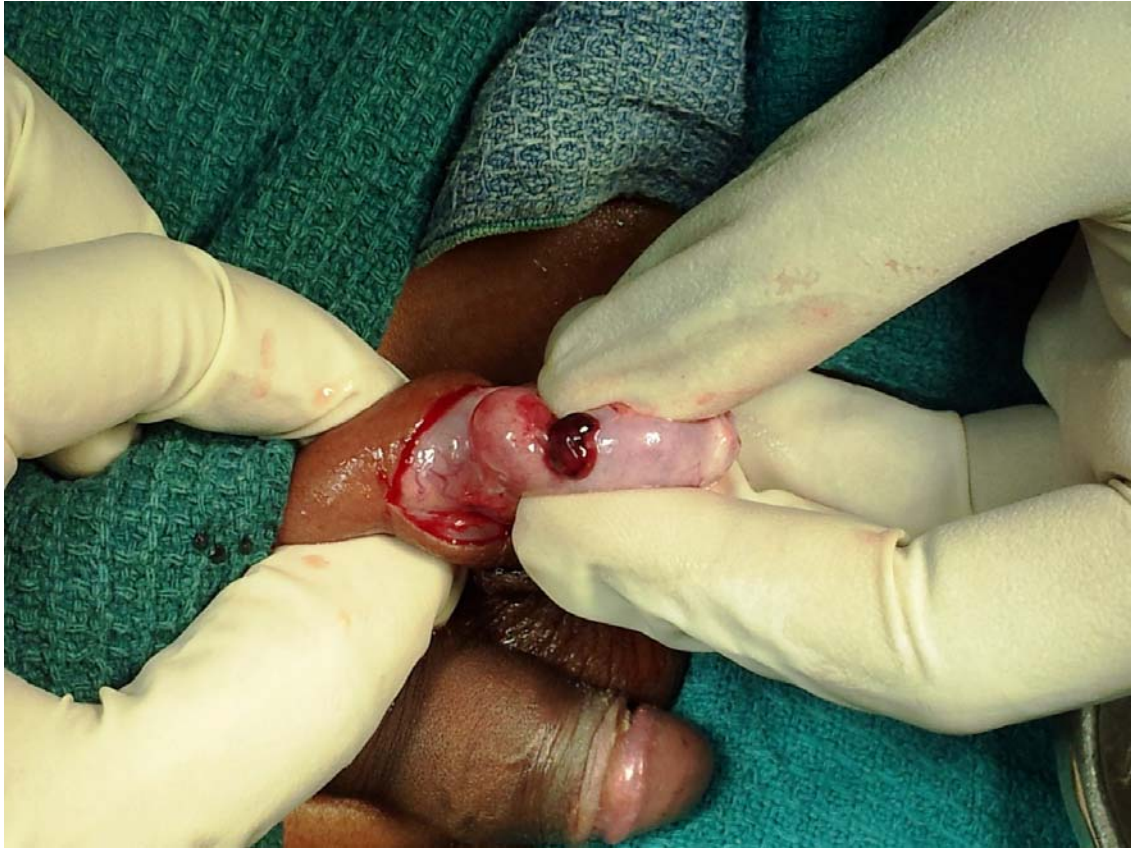## **TORSION OF APPENDIX OF TESTIS:**

Torsion of appendix of testis is one of the important causes of acute scrotal pain in adolescent age group. We encountered three cases of torsion of appendix of testis accounting for 5 % of total cases. The patients presenting with torsion of appendix of testis were in the age group of 9 – 14yrs.

The duration of presentation was 6 hrs – 2 days. One patient presented with pain in the scrotum along with constitutional symptoms like lower abdominal pain and vomiting.

USG scrotum was done in all the three patients who showed normal testis with adequate blood flow. All the patients were subjected to scrotal exploration which showed, small gangrenous appendix of testis which was excised.

Patients did not have complaints in the post-operative period.



**FIGURE 3: TORSION OF APPENDIX OF TESTIS**

Above picture shows a small lump present in the upper pole of the testis which is gangrenous and was excised.

## **TORSION OF TESTIS:**

Torsion of testis accounted for 21.67% of the cases in the present study as we encountered 13 cases with variable presentations. Patients had right sided testicular torsion in 6 cases(46.2%) and left sided torsion in 7 cases(53.8%).

On par with previous studies, most of the patients who presented with torsion testis were of young age group with a mean age of presentation of 23.9yrs (Range: 13 – 31yrs). The duration of presentation was anywhere from 3hrs to 3 days.

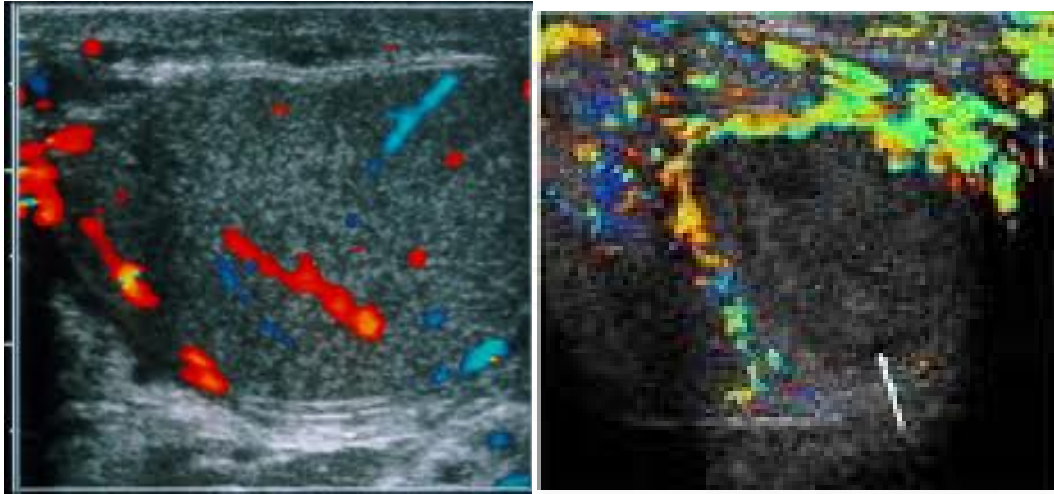
There was history of trauma to the scrotum in 2 cases (15.4%) and there was history of similar episodes in the past in two patients (15.4%). Constitutional symptoms like nausea, vomiting was present in 7 out of 13 patients (53.8%).

Out of the 13 patients, one patient torsion testis with undescended testis on the opposite side while one patient presented with acute pain in the inguinal region with history of absence of testis in the ipsilateral scrotum since birth. On examination he was found to be having torsion of an undescended testis.

USG Doppler study of scrotum was done in all the patients. Most of the patients were found to have testis without any vascular flow with twisting of the spermatic cord. One patient with undescended testis showed features of epididymo-orchitis on USG Doppler, who was put on conservative management. Since the pain did not respond to conservative management, he was subjected to repeat USG scrotum which showed features of torsion of testis. Patient was subjected to emergency scrotal exploration which showed gangrenous testis with torsion at the upper pole.

Scrotal exploration was done in all cases, with orchidectomy followed by contralateral testis fixation was done in 13 cases (76.9%). Exploration, manual detorsion with bilateral fixation of testis was done in 3 cases (23.1%).

All the patients in whom the testis was conserved presented to us within 6 hours of the symptom onset, thus exploration was done when the testis was still viable.



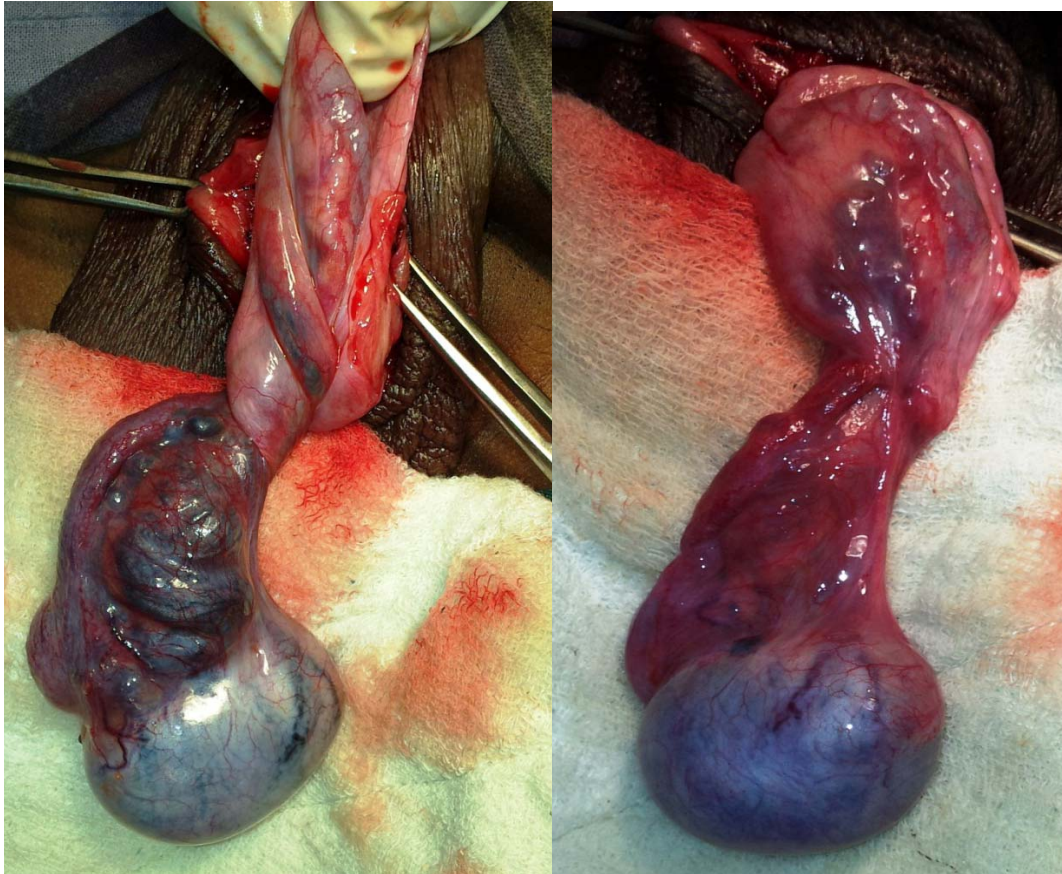
**NORMAL FLOW**

**ACUTE INFARCTION**

**FIGURE 4: USG DOPPLER SCROTUM**

USG Doppler scrotum is an important tool to differentiate torsion of testis from other causes of acute scrotum. There is absence of blood flow to the testis in case of torsion of testis while there is hypervascularity with edema of epididymis in case of epididymo-orchitis.



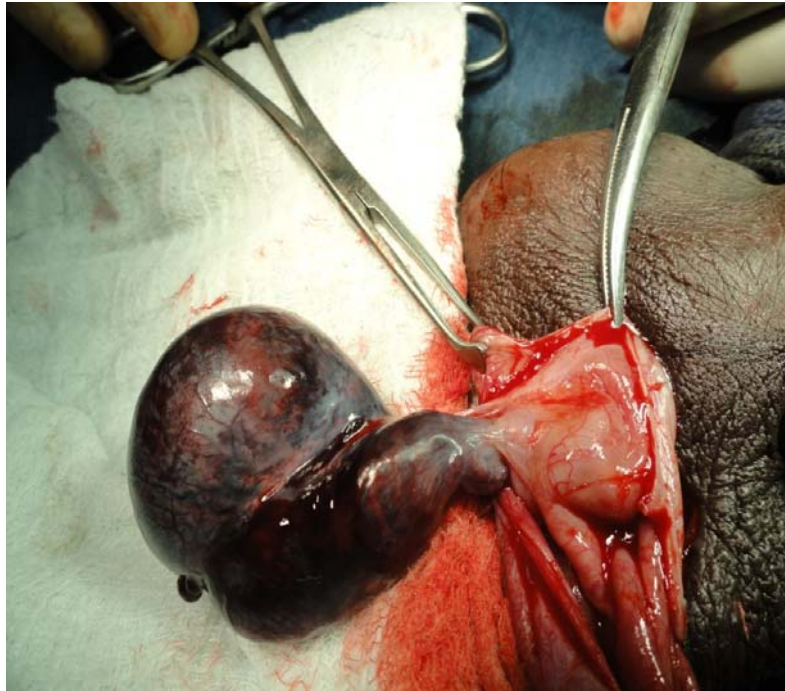


**TWISTED CORD WITH CONGESTED TESTIS**

**AFTER DETORSION**

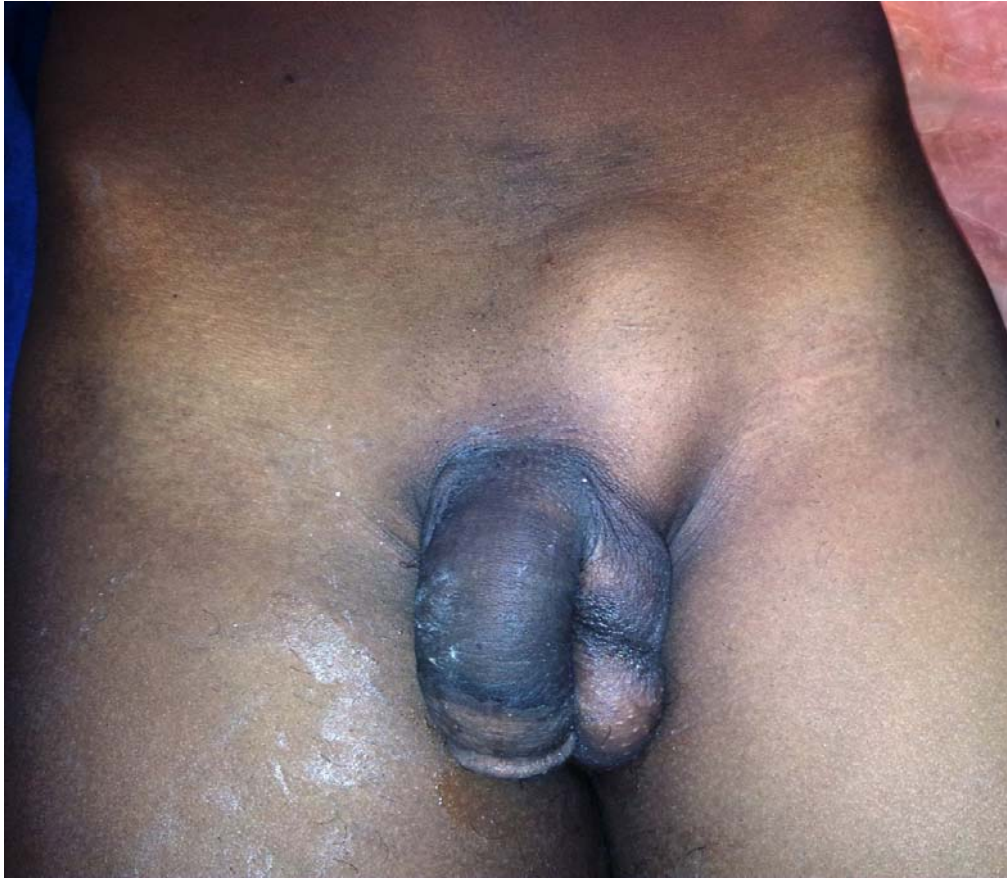### **FIGURE 5: TORSION OF TESTIS**

The above pictures are the intraoperative findings of a patient who presented with acute scrotal pain for 3 hours duration. On scrotal exploration torsion of the testis was noted. After detorsion, the vascularity was improved and testis was salvaged.



**FIGURE 6: TWISTED CORD WITH GANGRENOUS TESTIS**

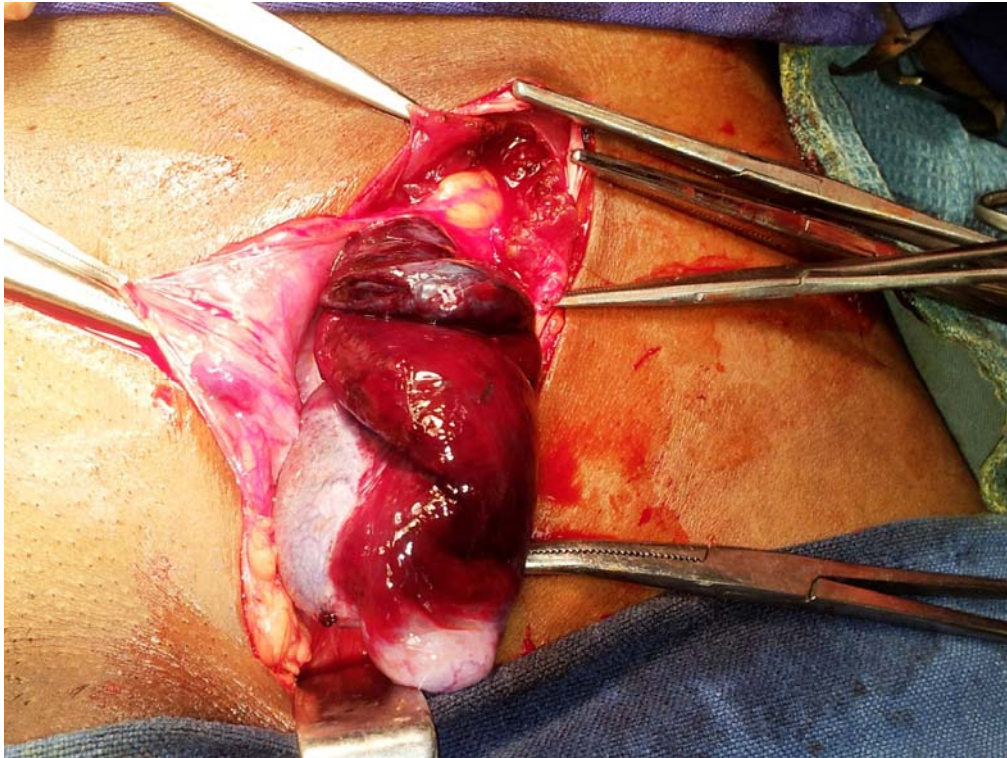
The above picture shows twisted gangrenous testis which is beyond salvage. Also note the high investment of tunica vaginalis, which is an important predisposing factor for torsion of testis.



**FIGURE 7: PREOPERATIVE PICTURE OF A PATIENT WITH TORSION OF UNDESCENDED TESTIS**

A 21yr old gentleman presented to us with a history of painful swelling in the left inguinal region since 2 days. He also gave history of undescended testis on the same side. On examination, the left hemiscrotum was empty with a tense, tender mass in the left inguinal region suggestive of torsion of the undescended testis.

The patient subjected for emergency inguinal exploration which showed twisted gangrenous left testis present in the left inguinal canal. Left orchidectomy was done.

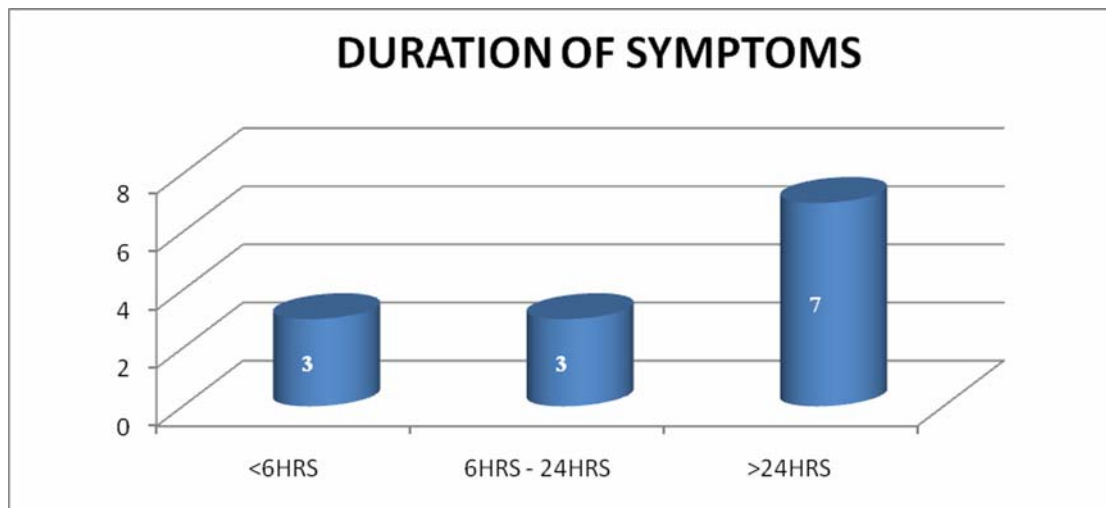


**FIGURE 8: INTRAOPERATIVE PICTURE SHOWING TWISTED CORD WITH GANGRENOUS TESTIS IN THE INGUINAL CANAL**

**DURATION OF SYMPTOMS:**

<b>DURATION OF SYMPTOMS</b>	<b>NO OF CASES</b>	<b>PERCENTAGE</b>
<6HRS	3	23.1
6HRS – 24HRS	3	23.1
> 24HRS	7	53.8

**TABLE 8: DURATION OF SYMPTOMS IN TORSION OF TESTIS**



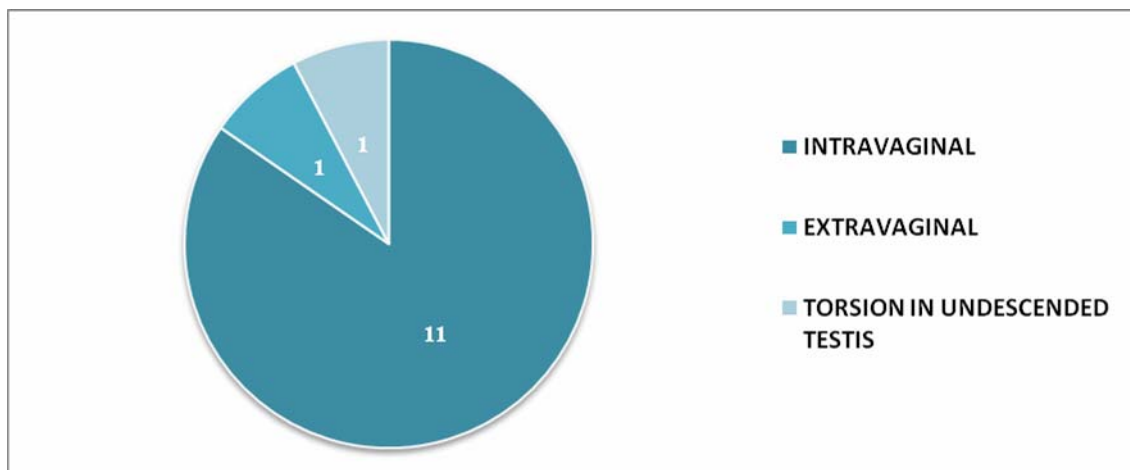
**GRAPH 8: DURATION OF SYMPTOMS IN TORSION OF TESTIS**

Majority of the patients (53.8) presented with the history of scrotal pain for more than 24 hours.

### TYPE OF TORSION:

TYPE OF TORSION	NO OF CASES	PERCENTAGE
INTRAVAGINAL	11	84.6
EXTRAVAGINAL	1	7.7
TORSION IN UNDESCENDED TESTIS	1	7.7

**TABLE 9: TYPE OF TORSION OF TESTIS**



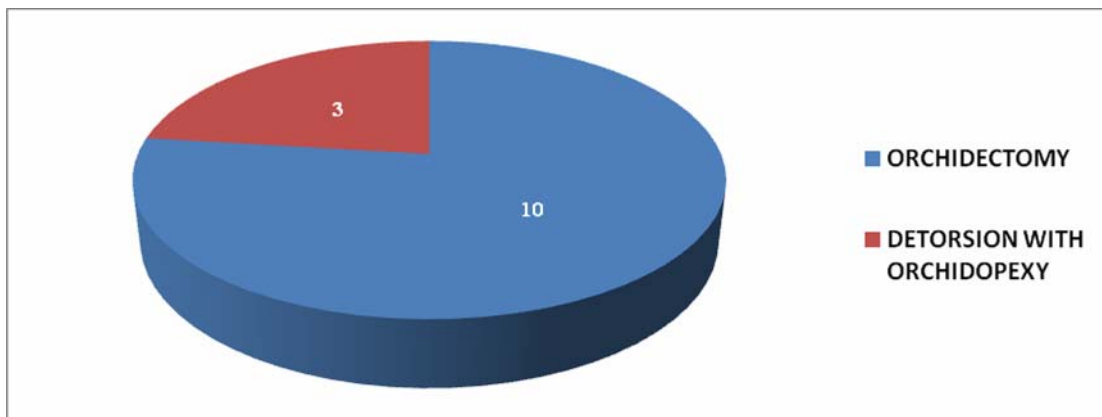
**TABLE 9: TYPE TORSION OF TESTIS**

Most of the patients had intravaginal type of torsion (84.6%).

**SURGERY DONE:**

<b>SURGERY</b>	<b>NO OF CASES</b>	<b>PERCENTAGE</b>
ORCHIDECTOMY	10	76.9
DETORSION WITH ORCHIDOPEXY	3	23.1

**TABLE 10: SURGERY DONE**



**TABLE 10: SURGERY DONE**

Testis could be salvaged in only 3 cases (23.1%), rest of the patients (73.9%) had to undergo orchidectomy.

## OVERVIEW OF CASES:

SL NO	AGE IN YEARS	DURATION OF SYMPTOMS	SIDE	TYPE OF TORSION	TREATMENT DONE
1	22	12 HRS	LEFT	INTRAVAGINAL	LEFT ORCHIDECTOMY
2	13	4 HRS	RIGHT	INTRAVAGINAL	B/L ORCHIDOPEXY
3	25	1 DAY	RIGHT	INTRAVAGINAL	RIGHT ORCHIDECTOMY
4	31	2 DAYS	LEFT	EXTRAVAGINAL	LEFT ORCHIDECTOMY
5	27	1 DAY	LEFT	INTRAVAGINAL	LEFT ORCHIDECTOMY
6	18	3 HRS	LEFT	INTRAVAGINAL	B/L ORCHIDOPEXY
7	17	6 HRS	LEFT	INTRAVAGINAL	B/L ORCHIDOPEXY
8	28	1 DAY	RIGHT	INTRAVAGINAL	RIGHT ORCHIDECTOMY
9	23	3 DAYS	RIGHT	EXTRAVAGINAL	RIGHT ORCHIDECTOMY
10	30	12HRS	RIGHT	INTRAVAGINAL	RIGHT ORCHIDECTOMY
11	28	18HRS	LEFT	INTRAVAGINAL	LEFT ORCHIDECTOMY
12	28	1 DAY	RIGHT	INTRAVAGINAL	RIGHT ORCHIDECTOMY
13	21	2 DAYS	LEFT	TORSION IN UNDESCENDED TESTIS	LEFT ORCHIDECTOMY

TABLE 11: OVERVIEW OF CASES



## DISCUSSION

The present study consisted of analysis of 60 patients who got admitted to Govt Stanley Hospital during the period of May 2010 to October 2012.

In our study, Acute epididymo-orchitis was to be the commonest cause for acute scrotum accounting for 33.3% of total cases, followed by torsion of testis which accounted for 21.7%, Fournier's gangrene (13.3%), pyocele (13.3%), hematocele (10%), torsion of appendix of testis (5%), scrotal wall abscess (3.4%).

In a case study by **Cass et al.**,<sup>18</sup> showed the incidence of epididymitis of about 72.5% when compared to torsion of testis which was about 20.67%.

Another study conducted by **N. H. Moharib et al.**,<sup>19</sup> showed that testicular torsion (33.92%) was the most common cause for acute scrotal pathology followed by epididymitis which accounted for 8.92%.

The study by **N. A. Watkin et al.**,<sup>20</sup> showed that torsion of the testis was the most frequent cause (39.5%) followed by torsion of appendages of testis/epididymis which was found to be 29% of the cases

and 15% of the patients had epididymo-orchitis. The rest of the cases were hematocele, pyocele which was about 16%.

**Barker & Paper**<sup>21</sup>, in their study noted that none of their patients were below 14yrs. But in our study we had 4 patients who were under the age of 14yrs with majority of the cases between 41 – 60yrs (36.7%), followed by 20 – 40yrs (33.3%).

In a study conducted by **A S Cass & B P Cass**<sup>18</sup>, the maximum incidence of epididymoorchitis was 62% in contrast to our study with 33.3% incidence.

The mean age of occurrence of epididymoorchitis in the present study was 51yrs where as it was 21.3yrs according to the study done by **N A Watkin**<sup>20</sup>.

In the present study, duration of symptoms varied from few hours to more than a week. The shortest duration of symptoms was 3hrs and the longest duration was 12days. In the study conducted by **Thorsteinn**<sup>22</sup>, the shortest duration of symptoms was 3hrs and the longest was 21days. The average duration of pain from onset till presentation in case of epididymo-orchitis was 3.54 days, whereas it was 4 days in the study conducted by **Ricardo et al**<sup>23</sup>.

In the present study, all the patients underwent ultrasonography except for the cases of Fournier's gangrene and Scrotal wall abscess. In this study of 60 cases, 20 cases (33.3%) were managed conservatively, who were diagnosed to have epididymo-orchitis. All other cases (66.7%) needed surgical treatment.

Patients who were treated conservatively responded well with complete recovery. All our patients who were treated surgically had uneventful postoperative period. All patients were followed up for a period of 1month to 6 months. None of the patients had any complications.

## **CONCLUSIONS AND SUMMARY**

Acute scrotum is a common case seen in the outpatient department with considerable morbidity which requires prompt evaluation.

- This is an observational study comprising of 60 cases of acute scrotum admitted at Govt. Stanley Medical College and Hospital, during the period of May 2010 to October 2012.
- Acute epididymo-orchitis was the commonest cause followed by torsion of testis.
- Most common age group involved was 41-60yrs followed by 21-40yrs.
- Majority of the patients presented with complaints for about 1-3 days.
- Pain in the scrotum was the commonest presenting symptom followed by swelling of scrotum.
- Majority of the patients had right sided involvement.
- Conservative management was followed in 33.3% patients while the rest required surgical exploration.

- Torsion of testis is an important differential diagnosis in case of an acute scrotum which requires emergency scrotal exploration.
- Any young patient presenting with acute scrotum, torsion of testis must be considered and evaluated.
- All the cases of acute scrotum must be subjected for USG Doppler of the scrotum
- In patients with torsion testis, presenting within 6hours of onset of symptoms, testis can be salvaged.

## BIBLIOGRAPHY

1. Willam C S. Acute scrotal pathology. *SurgCl N America* 1982; 62 (6) : 955-970
2. Singh Inderbir. Urogenital System. In: Singh I, editor. *Human Embryology*. 5th edition. New Delhi: Macmillan India Limited; 1991.p.305-309.
3. Chaurasia B D. Male external genital organs. In : Singh I., editor. *Human Anatomy Volume 2*. 3rd edition. New Dehli : CBC Publishers & Distributors; 2003 p.181-188.
4. Bannister L H, Dyson M. Reproductive System. In : Bannister L H, editor. *Gray's Anatomy*. 38th edition. London: Churchill Livingstone ; 2000 p.1848-56.
5. Francis X S, Bellinger M F. Abnormalities of the testis and scrotum and their surgical management. In: Patrick C. W, editor. *Campbell's Urology*. 8th edition. Philadelphia: Saunders; 2002 p. 2379-84.
6. Gray, Henry. XI. Splanchnology. 3c. The Male Genital. In: *Anatomy of the Human Body*. 20<sup>th</sup> ed. Philadelphia, New York: Lea &Febiger, 1918; Bartleby 2000; 2000

7. Karmazyn B, Steinberg R, Kornreich L et al. (March 2005).  
"Clinical and sonographic criteria of acute scrotum in children: a retrospective study of 172 boys". *PediatrRadiol* 35 (3): 302–10.
8. Kavoussi, Parviz K.; Costabile, Raymond A. (2011). "Disorders of scrotal contents: orchitis, epididymitis, testicular torsion, torsion of the appendages, and Fournier's gangrene". In Chapple, Christopher R.; Steers, William D.. *Practical urology: essential principles and practice*. London: Springer-Verlag
9. Kavoussi, Parviz K.; Costabile, Raymond A. (2011). "Disorders of scrotal contents: orchitis, epididymitis, testicular torsion, torsion of the appendages, and Fournier's gangrene". In Chapple, Christopher R.; Steers, William D.. *Practical urology: essential principles and practice*. London: Springer-Verlag.
10. Rakha E, Puls F, Saidul I, Furness P. Torsion of the testicular appendix: importance of associated acute inflammation. *J ClinPathol*. Aug 2006;59(8):831-4.
11. Barloon TJ, Weissman AM, Kahn D. Diagnostic imaging of patients with acute scrotal pain. *Am Fam Physician*. Apr 1996;53(5):1734-50.
12. Tracy CR, Steers WD, Costabile R. Diagnosis and management of epididymitis. *UrolClin North Am*. Feb 2008;35(1):101-8

13. Thwaini A, Khan A, Malik A, Cherian J, Barua J, Shergill I, Mammen K (2006). "Fournier's gangrene and its emergency management". *Postgrad Med J* 82 (970): 516–9.
14. Yanar H, Taviloglu K, Ertekin C, Guloglu R, Zorba U, Cabioglu N, Baspinar I (2006). "Fournier's gangrene: risk factors and strategies for management". *World J Surg* 30 (9): 1750–4.
15. Eke N. (2000). "Fournier's gangrene: a review of 1726 cases". *British Journal of Surgery* 87(6): 718–728.
16. Atwell J D, Ellis H. Rupture of the testis. *Br J Surg* 1967; 64 : 345-346.
17. Albert N E. Testicular Ultrasound for Trauma. *J Urol* 1980 ; 124 : 558-559.
18. Cass A S, Cass B P, Veeraraghavan K. Immediate exploration of the unilateral acute scrotum in young male subjects. *J Urol* ; 1980 ; 124 : 829-832.
19. Moharib N H, Krahn H P. Acute scrotum in children with emphasis on torsion of spermatic cord. *J Urol* ; 1970 ; 104 : 601-603.
20. Watkin N A, Reiger N A, Moisey C U. Is the conservative management of the acute scrotum justified on clinical grounds? *Br J Urol* 1996; 78 : 623-627.



21. Ricordo G, Del Villar, Ireland G W, Cass A S. Early Exploration in acute testicular conditions. *J Urol* 1972 ; 108 : 887-888.
22. Thorsteinn Gislason, Reynold F X, Noronha, Gregory J G. Acute epididymitis in boys: a 5-yr retrospective study. *J Urol* 1980 ; 124:53-34.
23. Ricordo G, Del Villar, Ireland G W, Cass A S. Early Exploration in acute testicular conditions. *J Urol* 1972 ; 108 : 887-888.
24. Reynard, John; Brewster, Simon; Biers, Suzanne. Oxford Handbook of Urology. 1st Edition. Infections and inflammatory conditions. 162-166
25. Van Glabeke E, et al. Acute scrotal pain in children: results of 543 surgical explorations. *PedSurgInt* 1999;15:353-357.
26. Jordan GH, Gilbert DA. Male genital trauma. *ClinPlastSurg* 1988;15:431.
27. Ringdahl E, Teague L; Testicular torsion. *Am Fam Physician*. 2006 Nov 15;74(10):1739-43.
28. Schneck FX, Bellinger ME. Abnormalities of the testis and scrotum and their surgical management. In: Wein AJ, Kavoussi LR, Novick AC, Partin AW, Peters CA, eds. *Campbell- Walsh Urology*. 9<sup>th</sup> ed. Philadelphia, Pa: WB Saunders; 2007:Chapter 127.

29. Cattolica EV, Karol JB, Rankin KN, Klein RS. High testicular salvage rate in torsion of the spermatic cord. *J Urol*. Jul 1982;128(1):66-8.
30. Johnston BI, Wiener JS. Intermittent testicular torsion. *BJU Int*. May 2005;95(7):933-4.
31. Tracy CR, Steers WD, Costabile R. Diagnosis and management of epididymitis. *Urol Clin North Am*. Feb 2008;35(1):101-8; vii
32. Swartz, MH. Male Genitalia and Hernias. In: *Textbook of Physical Diagnosis: History and Examination*. 5<sup>th</sup> ed. Philadelphia: Saunders Elsevier; 2006:520-526.
33. Sahni D, Jit I, Joshi K, Sanjeev. Incidence and structure of the appendices of the testis and epididymis. *J Anat*. Oct 1996;189 ( Pt 2):341-8.
34. Suzuki K, Inaba S, Takeuchi H. Clinical study on acute scrotum. 1991 Oct;37(10):1287-91.
35. Kim SH et al.: Significant predictors for determination of testicular rupture on sonography: a prospective study. *J Ultrasound Med*.(2007)26:1649-1655.

## PROFORMA

- **NAME :** **SL. NO:**
- **AGE /SEX:**
- **ADDRESS WITH CONTACT NUMBER:**
- **IP NO:**
- **DATE OF ADMISSION:**
- **DATE OF SURGERY:**
- **DATE OF DISCHARGE:**

### **HISTORY OF PRESENTING ILLNESS:**

- Swelling in the scrotum
  - Onset-
  - Duration-
  - Progress-
  - Persistent or intermittent-
  - Aggravating or relieving factors-
- PAIN:
  - Site-
  - Duration-
  - Nature-
  - Aggravating/relieving factors-
- H/O Fever, IF ANY:
- H/O burning micturition or urinary symptoms
- H/O Vomiting/ Nausea

- H/O ulcer over scrotum, if any

**PAST HISTORY:**

WHETHER A KNOWN CASE OF  
DM/HYPERTENSION/ASTHMA/TB/EPILEPSY/CARDIAC ILLNESS

H/O SIMILAR EPISODES IN THE PAST, IF ANY:

H/O SURGERIES IN THE PAST, IF ANY:

H/O TRAUMA IN THE PAST, IF ANY

H/O MAJOR ILLNESS/ HOSPITAL ADMISSIONS, IF ANY

**PERSONAL HISTORY:**

Whether a smoker or an alcoholic,

H/O Sexual contact

**FAMILY HISTORY:**

**TREATMENT HISTORY:**

**CLINICAL EXAMINATION:**

**GENERAL EXAMINATION:**

**SYSTEMIC EXAMINATION:**

CVS

RS

PER ABDOMEN

CNS

## **LOCAL EXAMINATION:**

- **SWELLING:**

Side

Size

Shape

Surface

Tenderness

Warmth

Consistency

Fluctuation

Transillumination

- LIE OF TESTIS
- CORD STRUCTURES
- OPPOSITE SIDE OF SCROTUM
- ULCER
  - Size
  - Extent
  - Floor
  - Base
  - Discharge, if any

## **REGIONAL LYMPH NODE EXAMINATION**

**CLINICAL DIAGNOSIS:**

**INVESTIGATIONS:**

- ROUTINE INVESTIGATIONS(CBC,RFT,CXR,ECG)
- USG SCROTUM
- URINE ROUTINE
- DOPPLER USG OF SCROTUM
- OTHER INVESTIGATIONS(IF ANY):

**FINAL DIAGNOSIS:**

**TREATMENT GIVEN: SURGICAL/ NON SURGICAL**

**SURGERY DONE:**

**PER OPERATIVE FINDINGS**

**POST OPERATIVE COMPLICATIONS, IF ANY:**

**POST OPERATIVE BIOPSY (HPE) REPORT, IF APPLICABLE:**

**FOLLOW UP:**

**Pkø©- õÚ Á¼²hß Ti- ÂøµÃUP® ÷{õ´  
HØ£kÁuØPõÚPõµn[PÐ® AuØPõÚ ]Qaø\ -øÓPÐ®  
\®£øu´£mh £¶÷\õuøÚUPõÚ J´iuÀ £iÁ®**

Bµõ´a] |ø»´® : Am\_ ihõß¼ ©,zxÁ©øÚ  
ö\ßøÚ& 600 001.

£[S ö£Ö® ÷{õ´ õí°ß ö£´° : Á´x:

£[S ö£Ö® ÷{õ´ õí°ßGs: £ð¼Ú®: Bs

÷{õ´ õí°ßÁ»ö\® :

÷{õ´ õíCuøÚ (v) SÕUPÄ®.

÷©÷» SÔ´mh´£mkÒí ©,zxÁB´Âß ÂÁµ[PÒ GÚUS ÁÍUP´£mhx. GßÝøh´  
\ø÷uP[Pøí ÷PmPÄ®.AuØPõÚuSøuÁÍUP[Pøíö£ÓÁ® Áõ´´£ÍUP´£mhx.

{ößGßøÚCÆÁõ´ÁÀußÚaø\´ õPuõß £[÷PØP AY©vUQ÷Óß.  
GøuPõµnzvÚõ÷»õ Gøu Pmhzv¾® Gøu \mh ]UP¾US®   
Em£hõ©ÀGßøÚCÆÁõ´ÁÀ C,øx Á»UQöPõÒí»õ® GßÖ® AÔøxöPõs÷hß.

Cøu B´Ä \®£øu©øP÷Áõ, Cøu \õøøu ÷©¾® B´Ä ÷©øøPõÒÐ® ÷£øx®  
Cøu B´ÄÀ £[Sö£Ö® ©,zxÁ° GßÝøh´ ©,zxÁAÔUøPPøí £õ´´£uØSGßAY©v  
÷uøÁ´Àø» GÚ AÔøxöPõÒQ÷Óß. GßøÚ B´ÄÀ C,øx Á»QU öPõshõ¾®  
Cxö£õ,øx® GÚ AÔQ÷Óß.

CøuB´Äß -»® QøhUS® uPÁÀPøí²®, £¶÷\õuøÚ -iÄPøí²® ©øÖ® ]Qaø\  
öuøh°£õÚ uPÁÀPøí²® ©,zxÁ° ÷©øøPõÒÐ® B´ÄÀ £´ß£kzvUöPõÒíÁ® Aøu  
µµ\_¶UPÄ® Gß -É ©Úxhß \®©vUQ÷Óß.

Cøu B´ÄÀ GßøÚDk£kzu -É©Úxhß J´iu öPõÒQ÷Óß.Cøu ©´UP  
©,øxPÒ ©øÖ® ©´UP -øÓ´ÚõÀHØ£hUTi´ µß ÁøíÄPÒ ©øÖ®  
Gv°£õøµøuÁøíÄPøí´ £ØÔ GÚUS ÁÍUP©øPøu¶ÁUP´£mhx.

Cøu B´ÄÀ Pkø©- õÚ Á¼²hß Ti- ÂøµÃUP® ÷{õ´USAÖøÁ ]Qaø\  
÷©øøPõÒ£Á°PÐUS EÓí B£zuõÚPõµoPÒCµzu £¶÷\õuøÚPÒ ©øÖ® hõ´´»°  
ì÷Pß(Doppler Scan) ©øÖ® AÀµµõ Våsmi÷Pß -»® PshÔ´´£kQÓx. GßÝøh´  
÷{õUP©õÚxCøuÁøµUöPõmøh Á¼UPõÚ AøÚzxPõµn[PøíPskæi´£x®  
AuØSGÆÁõõÚ ]Ó´i ]Qaø\ -øÓPøí ÷©øøPõÒÁx® BS®.

÷{õ´ õí°ßøPõ´ õ´£®..... Ch® .....  
÷uv.....

PmøhÁÀ ÷µøP (Cøu £iÁ® £izxPõmh´£mk !¶øx øP÷µøPAÍUQß÷Óß)

B´Áøí¶ßøPõ´ õ´£® .....Ch® .....

÷uv..... B´Áøí¶ß ö£´° .....

INSTITUTIONAL ETHICAL COMMITTEE,  
STANLEY MEDICAL COLLEGE, CHENNAI-1


Title of the Work : A study on acute scrotum  
Principal Investigator : Dr.B. Rajeswari  
Designation : PG in M.S (GS)  
Department : Department of General Surgery  
Government Stanley Medical College,  
Chennai-1

The request for an approval from the Institutional Ethical Committee (IEC) was considered on the IEC meeting held on 06.03.2012 at the Council Hall, Stanley Medical College, Chennai-1 at 2PM

The members of the Committee, the secretary and the Chairman are pleased to approve the proposed work mentioned above, submitted by the principal investigator.

The Principal investigator and their team are directed to adhere to the guidelines given below:

1. You should inform the IEC in case of changes in study procedure, site investigator investigation or guide or any other changes.
2. You should not deviate from the area of the work for which you applied for ethical clearance.
3. You should inform the IEC immediately, in case of any adverse events or serious adverse reaction.
4. You should abide to the rules and regulation of the institution(s).
5. You should complete the work within the specified period and if any extension of time is required, you should apply for permission again and do the work.
6. You should submit the summary of the work to the ethical committee on completion of the work.

 25/10/12  
MEMBER SECRETARY,  
IEC, SMC, CHENNAI