

# CLINICAL PROFILE OF NEUROLOGICAL MANIFESTATIONS IN WILSON DISEASE

*Dissertation submitted for*

**MD Degree (Branch I) General Medicine  
March 2007**



**The Tamilnadu Dr.M.G.R. Medical University  
Chennai, Tamilnadu.**

## **CERTIFICATE**

This is to certify that this dissertation titled “**CLINICAL PROFILE OF NEUROLOGICAL MANIFESTATIONS IN WILSON DISEASE**” submitted by **Dr. S. GOKULNATH** to the faculty of General Medicine, The Tamilnadu Dr. M.G.R. Medical University, Chennai in partial fulfillment of the requirement for the award of MD degree Branch I (General Medicine) is a bonafide research work carried out by him under our direct supervision and guidance.

**Dr.M.Muthiah M.D.,**  
**Additional Professor,**  
**Department of Medicine,**  
**Madurai Medical College,**  
**Madurai.**

**Dr. Nalini Ganesh M.D.,**  
**Professor and Head,**  
**Department of Medicine,**  
**Madurai Medical College,**  
**Madurai.**

**Place: Madurai**

**Date:**

## **DECLARATION**

I, **Dr. S. GOKULNATH**, solemnly declare that the dissertation titled  
**“CLINICAL PROFILE OF NEUROLOGICAL MANIFESTATIONS IN  
WILSON DISEASE”** has been prepared by me.

This is submitted to the Tamil Nadu Dr. M.G.R. Medical University,  
Chennai, in partial fulfillment of the regulations for the award of MD Degree  
Branch I (General Medicine).

It was not submitted to the award of any degree/ diploma to any University  
either in part or in full form previously.

Place : Madurai

Date :

Dr S. GOKULNATH

## ACKNOWLEDGEMENT

At the outset, I wish to thank our Dean in-charge **Dr.S.M.Sivakumar M.S.**, for permitting me to use the facilities of Madurai Medical College and Government Rajaji Hospital to conduct this study.

I express my sincere thanks to my former unit chief and former Head of the Department of Medicine, **Prof. Dr. P. Thirumalaikolundu Subramanian M.D.**, for his valuable advice and guidance throughout the course of the study. He had given me moral support and encouragement during most part of my study and my post graduate course. I owe my sincere thanks to him.

My beloved unit chief **Dr. M. Muthiah M.D.**, was instrumental in guiding me during the final phase of my study and helping me complete my work. He has in his short period as my unit chief has guided me both by example and by his valuable advice and encouragement. I owe my sincere thanks to him.

I express my sincere thanks to the former Head of the Department of Neurology **Prof. M. RajaGuru** for giving me permission to collect patients' details and guiding me in the making of this study.

I sincerely thank my beloved teachers, **Dr. Nalini Ganesh M.D. (Professor and Head of the Department of Medicine)**, **Dr.A.Ayyappan M.D.**, **Dr. P.Selvaraj M.D.**, **Dr. M. Kamaraj M.D.**, **Dr. Moses K. Daniel M.D.** and **Dr. D.D.Venkatraman M.D.** for their valuable advice and guidance throughout my post graduate course.

I offer my heartfelt thanks to my Assistant Professors **Dr. David Pradeepkumar M.D., Dr. C. Dharmaraj M.D., D.C.H., Dr. K. Senthil M.D., Dr. M. Ranisolai M.D., Dr. R. Balajinathan M.D.** and **Dr. A. Senthamarai M.D.** for their constant encouragement, timely help and critical suggestions throughout the study and also for making my stay in the unit both informative and pleasurable.

My family and friends have stood by me during my times of need. Their help and support have been invaluable to this study.

My patients, who formed the most integral part of the work, were always kind and cooperative. I cannot but pray for their speedy recovery and place this study as a tribute to them and to the numerous others likely affected.

Above all I thank the Lord Almighty for his kindness and benevolence.

## **ABBREVIATIONS AND ACRONYMS**

ATP	–	Adenosine Triphosphate
ATPase	–	Adenosine Triphosphatase
DNA	–	Deoxyribonucleic acid
RTA	–	Renal tubular acidosis
CT	–	Computerized tomography
MRI	–	Magnetic resonance imaging
ECG	–	Electrocardiogram
FLAIR	–	Fluid-attenuated inversion recovery

# CONTENTS

	Page
	No.
1. TITLE PAGE	i
2. CERTIFICATE	ii
3. DECLARATION	iii
4. ACKNOWLEDGEMENT	iv
5. ABBREVIATIONS AND ACRONYMS	vi
6. INTRODUCTION	1
7. AIMS OF THE STUDY	4
8. REVIEW OF LITERATURE	5
9. MATERIALS AND METHODS	37
10. RESULTS	42
11. DISCUSSION	60
12. CONCLUSION	66
13. SUMMARY	69
BIBLIOGRAPHY	
APPENDIX I - APPROVAL FROM ETHICAL COMMITTEE	
APPENDIX II – PRO FORMA	
APPENDIX III- MASTER CHART	

## INTRODUCTION

The nervous system is more frequently affected by a genetic abnormality than any other organ system, probably because of large number of genes implicated in its development (an estimated one-third genes in the human genome). Approximately one-third of all inherited diseases are neurologic to some extent; if one adds the inherited diseases affecting the musculature, skeleton, eye and ear, the number rises to 80 to 90 percent.

Among the list of inherited diseases affecting the nervous system which are often not curable one potentially treatable inherited disease affecting the nervous system is Wilson disease.

Wilson disease is transmitted as an autosomal recessive trait, and the abnormal gene resides on chromosome 13, in the region of 13q14. One of the curious aspects of the disease is the multitude of mutations affecting ATP7B gene. The genetic defect gives rise to two fundamental disturbances of copper metabolism – a reduced rate of incorporation of copper into ceruloplasmin and a reduction in biliary excretion of copper into ceruloplasmin. The deposition of copper in tissues is the cause of virtually all the manifestations of the disease – cirrhosis, hemolytic anaemia, renal tubular changes, Kayser-Fleischer rings and, in all likelihood, the cerebral damage.

Neurological manifestations are second most common form of presentation and are the predominant pattern seen in adults. The onset of neurologic symptoms is usually in the second and less often in the third decade. The first neurological



manifestations are most often extrapyramidal with a proclivity to affect the oropharyngeal musculature. The typical presentations are tremor of a limb or of the head and generalized slowness of movement or slowness of movements of the tongue, lips, pharynx, larynx, and jaws, resulting in dysarthria, dysphagia and hoarseness. As the disease progresses, the classic syndrome with features of parkinsonism develops.

The disease in advanced stages poses a considerable degree of neurological impairment and disability. As the disease affects the young and productive age group of the population it poses a huge burden both for the family and the community as a whole both on social and economic aspects.

Newer advances in medicine has brought a considerable degree of relief such that the disease can be diagnosed at an early stage and potential treatment options are available to prevent and reduce the morbidity caused by the neurological disease. But still the disease remains undiagnosed most often in a population like ours where early hepatic manifestation of Wilson are underrecognised and often left undiagnosed to present later with neurological manifestations which are all not completely reversible.

Therefore considerable improvements have to be made to study the epidemiology of the disease in our community, develop cost effective methods to diagnose and provide treatment. Research has to be initiated to know the genetics of the Indian Wilson which present at an earlier age group when compared with the western world.

In view of the early occurrence and the multiple modes of presentation, with special preference to nervous system an attempt has been made to pick up Wilson disease through nervous system.

## **AIMS OF THE STUDY**

- 1) To find out the prevalence of Wilson disease among those attending neurology clinic
- 2) To analyze their socio demographic aspects
- 3) To study the pattern of presentation, analyze the symptomatology and elicit the familial nature of the disease.
- 4) To interpret and compare the laboratory investigation with the clinical picture of the patients.
- 5) To assess the clinical response to treatment and to study the complications (if any) out of the treatment in the short term.
- 6) To elicit selected social aspects of the disease.

## REVIEW OF LITERATURE

### WILSON DISEASE

#### INTRODUCTION

Wilson disease (hepatolenticular degeneration) is an autosomal recessive disorder characterized by degenerative changes in the brain, liver disease, and Kayser-Fleischer ring in the cornea leading on to varying patterns of hepatic, neurological and psychiatric symptoms. Because effective treatment is available early diagnosis has to be made.

#### HISTORY

Wilson disease was first described in 1912 by Kinnear Wilson as ‘progressive lenticular degeneration’, a familial, lethal neurologic disease accompanied by chronic liver disease leading to cirrhosis.<sup>1</sup> The association of corneal copper deposits with this disorder was later made by Kayser and Fleischer.<sup>2</sup> Over the next several decades the role of copper in the pathogenesis of Wilson disease was established, and the pattern of inheritance was determined to be autosomal recessive.<sup>3</sup>

In 1993 the abnormal gene in Wilson disease was identified.<sup>4-7</sup> The gene, *ATP7B*, sometimes also referred to as “*WND*”, encodes a metal transporting P-type ATPase, which is expressed mainly in hepatocytes and functions in the

transmembrane transport of copper. Absent or reduced function of ATP7B protein leads to decreased hepatocellular excretion of copper into bile. This results in hepatic copper accumulation and injury. Eventually copper is released into the bloodstream and deposited in various other organs, notably the brain, kidneys and cornea.

Wilson disease was one of the first liver diseases for which effective pharmacologic treatment was identified. The first chelating agent introduced in 1951 for the treatment of Wilson disease was British anti-lewisite (BAL or dimercaptopropanol) .<sup>8-9</sup> The identification and testing of an orally administered chelator, D-penicillamine, by John Walsh in 1956 revolutionized treatment of this disorder.<sup>10</sup>

Other treatment modalities have since been identified, including use of zinc salts (Schouwink in 1961 introduced zinc as an alternative to penicillamine) to block enteral copper absorption and orthotopic liver transplantation, which may be lifesaving and curative for this disorder. Over the years diagnostic advances have enabled more systematic screening of individuals suspected to have Wilson disease prior to their development of neurologic symptoms. More recently, molecular diagnostic studies have made it feasible to define patterns of haplotypes or polymorphisms of DNA surrounding *ATP7B*, which are useful for identification of first-degree relatives of newly diagnosed patients. In some patients disease-specific mutations on both alleles of chromosome 13 can be determined.

## EPIDEMIOLOGY OF THE DISEASE

The worldwide incidence rate is 10-30 million cases, with increased rates in areas of consanguinity. The heterozygote carrier rate is 1 case per 100 persons, corresponding to a gene frequency varying between 0.3-0.7 percent. The frequency ranges worldwide from 1 case per 30,000 populations in Japan, to 1 case per 100,000 populations in Australia. It occurs in all races and is comparatively more common in Jews of east European origin, Arabs, Italians, Japanese, Chinese and Indians.

## GENETICS

The abnormal gene for Wilson disease is on chromosome 13; linkage studies have assigned the Wilson disease locus to chromosome 13 at q14.3-q21.1. Wilson disease gene, like the Menkes disease gene encodes a 1411-amino-acid copper-binding cation transporting P-type ATPase with 14 domains—6 copper binding, 4 transmembrane, 1 phosphatase, 1 transduction, 1 phosphorylation and 1 ATP binding. The Menkes and Wilson genes have 55% amino acid identity. The Menkes and Wilson ATPases utilize common biochemical mechanisms, but the tissue-specific expression differs. The Wilson disease gene is found predominantly in liver, kidney and placenta, and to a lesser extent, in heart, brain, lung, muscle and pancreas. All copper-transporting ATPases have a histidine residue in the large cytoplasmic loop, adjacent to the

ATP binding domain. The histidine residue is essential for function and is the most common mutation in Wilson disease.

The most common gene mutations are single base pair changes or frame-shift mutations due to small deletions. Occasionally, splicing errors are seen. Mutations that completely destroy gene function are associated with an onset of disease symptoms as early as 2-3 yr of age, when Wilson disease may not typically be considered in the differential diagnosis. Milder mutations can be associated with neurologic symptoms or liver disease as late as 50 yr of age. Genetic testing may be helpful in diagnosing a patient's asymptomatic relatives but has not replaced the traditional laboratory studies because of the large number of mutations that have been identified (approximately 200).

## PATHOPHYSIOLOGY

The estimated total body copper content is 50-100 mg, with an average daily intake of 1-2 mg. Copper is an important component of several metabolic enzymes, including lysyl oxidase, cytochrome c oxidase, superoxide dismutase and dopamine beta-hydroxylase. Intestinal copper absorption and transport into hepatocytes is intact in Wilson disease. After copper reaches the hepatocyte, it is incorporated into copper-containing enzymes, including ceruloplasmin ( $\alpha_2$  globulin). Excess copper may be rendered nontoxic by forming complexes with apo-metallothionein to produce copper-metallothionein, or it may be excreted into bile.

The ATPase affected by Wilson disease is predominantly in the liver and transports copper within the hepatocyte, thereby allowing the incorporation of copper into ceruloplasmin and subsequent excretion into the bile. This is the only significant pathway for copper removal. In Wilson disease, the processes of incorporation of copper into ceruloplasmin and excretion of excess copper into bile are impaired. Excess hepatic copper is initially bound to metallothionein, but as this storage capacity is exceeded, liver damage begins as early as 3 years of age. Copper accumulation in the cytoplasm of hepatocytes results in cellular necrosis. The underlying mechanism of liver damage in Wilson disease is presumably oxidant injury to the hepatocyte mitochondria, which is the target organelle in copper-induced toxicity. Lipid peroxidation of the mitochondria resulting from copper overload leads to functional alterations.

Defective copper incorporation into apoceruloplasmin leads to excess catabolism and low blood levels of ceruloplasmin. Serum copper levels are usually lower than normal because of low blood ceruloplasmin, which normally binds >90% of serum copper. As the disease progresses, non-ceruloplasmin serum copper ("free" copper) levels increase. The excess copper then collects in extrahepatic tissues, including the basal ganglia, kidney and the descemet's membrane of the cornea, to which it is toxic, primarily as a potent inhibitor of enzymatic processes. Ionic copper inhibits pyruvate oxidase in brain and ATPase in membranes, leading to decreased ATP-phosphocreatine and potassium content



of tissue. The glycolytic pathway and microsomal membrane ATPases are inhibited.

Staging: The natural history of the disease may be considered in 4 stages, as follows:

- Stage I - The initial period of accumulation of copper by hepatic binding sites
- Stage II - The acute redistribution of copper within the liver and its release into the circulation
- Stage III - The chronic accumulation of copper in the brain and other extrahepatic tissue, with progressive and eventually fatal disease
- Stage IV - The achievement of copper balance with chronic chelation therapy.

## CLINICAL PRESENTATION

There are protean manifestations of the disease which may appear as early as 4 years of age or may be delayed until the fifth decade. Wilson disease manifests as liver disease in children and adolescents, peaking at ages 10-13 years, and as neuropsychiatric illness in young adults aged 19-20 years. In India and

countries in the Far East, the hepatic presentation may occur much earlier, often in children only five or six years of age.

### Hepatic presentation

The type of the liver disease can be highly variable, ranging from asymptomatic with only biochemical abnormalities to fulminant hepatic failure. Children may be entirely asymptomatic, with hepatic enlargement or abnormal serum aminotransferases found only incidentally. Some patients have a brief clinical illness resembling an acute viral hepatitis, and others may present as clinically indistinguishable from autoimmune hepatitis. Some present with only biochemical abnormalities or histologic findings of steatosis on liver biopsy. Many patients present with signs of chronic liver disease and evidence of cirrhosis, either compensated or decompensated. Patients may present with isolated splenomegaly due to clinically inapparent cirrhosis with portal hypertension. Wilson disease may also present as fulminant hepatic failure with an associated Coombs-negative hemolytic anemia and acute renal failure. Fulminant presentation of Wilson disease is more common in females than males (4:1). Some patients have transient episodes of jaundice, due to hemolysis. Low-grade hemolysis may be associated with Wilson disease when liver disease is not clinically evident.

In one series hemolysis was a presenting feature in 25 out of 220 cases (12%); in these patients hemolysis occurred as a single acute episode, recurrently, or was low-grade and chronic.<sup>11</sup> In a series of 283 Japanese cases of Wilson

disease, only 3 presented with acute hemolysis alone, but one quarter of the patients who presented with jaundice also had hemolysis.<sup>12</sup> Patients diagnosed with Wilson disease who have a history of jaundice may have previously experienced an episode of hemolysis. Patients with apparent autoimmune hepatitis presenting in childhood, or in adults with a suspicion of autoimmune hepatitis that does not readily respond to therapy should be assessed carefully for Wilson disease because elevated serum immunoglobulins and detectable nonspecific autoantibodies may be found in both conditions.<sup>13-15</sup>

Hepatic Wilson disease should be considered in the differential diagnosis of any unexplained chronic liver disease, especially in individuals younger than 40 years.

#### Neuropsychiatric presentation

Neurologic manifestations of Wilson disease typically present later than the liver disease, most often in the second decade of life, but they can present in childhood. Earlier subtle findings may appear in pediatric patients, including changes in behavior, deterioration in schoolwork or inability to perform activities requiring good hand-eye coordination. Handwriting may deteriorate, and cramped small handwriting, as in Parkinson disease (micrographia), may develop.

Most patients who present with neuropsychiatric manifestations have cirrhosis, frequently asymptomatic. The most common presenting neurologic feature is asymmetric tremor, occurring in approximately half of individuals with

Wilson disease. The character of the tremor is variable and may be predominantly resting, postural or kinetic.

Frequent early symptoms include difficulty in speaking, excessive salivation, ataxia, mask like facies, clumsiness with the hands and personality changes.

Late manifestations (now rare because of earlier diagnosis and treatment) include dystonia, spasticity, grand mal seizures, rigidity and flexion contractures.

Autonomic disturbances may include orthostatic hypotension and sweating abnormalities as well as bowel, bladder and sexual dysfunction. Memory loss, migraine-type headaches and seizures may occur. Patients have difficulties focusing on tasks, but cognition is not usually grossly impaired. Sensory abnormalities and muscular weakness are not features of the disease. Because of pseudobulbar palsy, transfer dysphagia may also occur, with a risk of aspiration, if severe.

Walshe described 4 distinct diagnostic categories based on patients' major neurologic findings and it was published two decades ago. The details are given below

- 1) The parkinsonian patients (45%) were distinguished by paucity of expression and movement.

2) The pseudosclerotic patients (24%) had tremor resembling multiple sclerosis.

3) The patients in the dystonic group (15%) were characterized by hypertonicity associated with abnormal limb movements.

4) The patients in the choreic group (11%) were predominantly characterized by choreoathetoid abnormal movements associated with dystonia.

The psychiatric manifestations of Wilson disease have been frequently noted. In his original monograph Wilson described “psychical” symptoms in 8 out of his 12 cases; since then, many studies and case reports have described psychiatric symptoms or disorders in patients with Wilson disease. Scheinberg and Sternlieb went so far as to state that “almost every patient with clinically manifest Wilson disease suffers at some time during the course of his disease” with psychiatric problems.

Psychiatric features include emotional lability, impulsiveness, disinhibition and self-injurious behavior. The reported percentage of patients with psychiatric symptoms as the presenting clinical feature is 10-20%. The range of psychiatric abnormalities associated with Wilson disease has been divided into 4 basic categories, as follows:

1) Behavioral

2) Affective

3) Schizophrenic like

4) Cognitive

#### Ophthalmological manifestations

Kayser-Fleischer rings are formed by the deposition of copper in Descemet membrane in the limbus of the cornea. The color may range from greenish gold to brown; when well developed, rings may be readily visible to the naked eye or with an ophthalmoscope set at +40. When not visible to the unaided eye, the rings may be identified using slit-lamp examination or gonioscopy.

Kayser-Fleischer rings consist of electron-dense granules rich in copper and sulfur. The rings form bilaterally, initially appearing at the superior pole of the cornea, then the inferior pole, and, ultimately, circumferentially.

Large series of patients with Wilson disease show that Kayser-Fleischer rings are present in only 50% to 62% of patients with mainly hepatic disease at the time of diagnosis.<sup>16-20</sup> In children presenting with liver disease Kayser-Fleischer rings are usually absent.<sup>21-23</sup> Kayser-Fleischer rings are almost invariably present in patients with a neurologic presentation, but even in these patients they may not be found in 5%.<sup>24</sup> Other ophthalmologic changes may be found. Sunflower

cataracts, also found by slit-lamp examination, represent deposits of copper in the lens.<sup>25</sup> These typically do not obstruct vision. Both Kayser-Fleischer rings and sunflower cataracts will gradually disappear with effective medical treatment or following liver transplantation, although the rate of disappearance does not correlate with resolution of clinical symptoms.<sup>26-27</sup> The reappearance of either of these ophthalmologic findings in a medically treated patient in whom these had previously disappeared suggests noncompliance with therapy.

Although Kayser-Fleischer rings are a useful diagnostic sign, they are no longer considered pathognomonic of Wilson disease unless accompanied by neurologic manifestations. They may also be observed in patients with chronic cholestatic disorders such as partial biliary atresia, primary biliary cirrhosis, primary sclerosing cholangitis, and cryptogenic cirrhosis. These diseases can usually be distinguished from Wilson disease on clinical grounds.

#### Renal manifestations

The Wilson disease gene is expressed in kidney tissue; therefore, any renal manifestations may be primary or secondary to release of copper from the liver. Clinically, patients may resemble those with Fanconi's syndrome, demonstrating defective renal acidification and excess renal loss of amino acids, glucose, fructose, galactose, pentose, uric acid, phosphate and calcium. The frequency of renal manifestations is variable.

Urolithiasis, found in up to 16% of patients with Wilson disease, may be the result of hypercalciuria or poor acidification.

Hematuria and nephrocalcinosis are reported, and proteinuria and peptiduria can occur both before treatment as part of the disease process and after therapy as adverse effects of D-penicillamine.

#### Musculoskeletal manifestations

Skeletal involvement is a common feature of Wilson disease, with more than half of patients exhibiting osteopenia on conventional radiologic examination.

The arthropathy of Wilson disease is a degenerative process that resembles premature osteoarthritis. Symptomatic joint disease, which occurs in 20-50% of patients, usually arises late in the course of the disease, frequently after age 20 years. The arthropathy generally involves the spine and large appendicular joints such as knees, wrists and hips. Osteochondritis dissecans, chondromalacia patellae and chondrocalcinosis have also been described.

#### Other manifestations

Some female patients have repeated spontaneous abortions, and most become amenorrheic prior to diagnosis.



Electrocardiographic and other cardiac abnormalities have been reported but are not common. Endocrinological abnormalities in the form of hypoparathyroidism can occur.

Rare case reports of Wilson disease presenting with olfactory dysfunction<sup>28</sup>, severe generalized myoclonus, encephalopathy like manifestations, hypokalaemic periodic paralysis due to RTA,<sup>29</sup> mixed polyneuropathy,<sup>30</sup> etc have been described.

## **DIAGNOSIS**<sup>31-38</sup>

The presence of Kayser-Fleischer rings and ceruloplasmin levels of less than 20 mg/dL in a patient with neurologic signs or symptoms suggest the diagnosis of Wilson disease. If a patient is asymptomatic/ exhibits isolated liver disease, and lacks corneal rings, the coexistence of a hepatic copper concentration of more than 250 µg/g of dry weight and a low serum ceruloplasmin level is sufficient to establish a diagnosis.

### **Serum ceruloplasmin**

- Serum ceruloplasmin levels are low in newborns and gradually rise within the first 2 years of life. Approximately 90% of all patients with Wilson disease have ceruloplasmin levels of less than 20 mg/dL (reference range, 20-40 mg/dL).

- Ceruloplasmin is an acute phase reactant and may be increased in response to hepatic inflammation, pregnancy, estrogen use or infection.
- Falsely low ceruloplasmin levels may be observed in any protein deficiency state, including nephrotic syndrome, malabsorption, protein-losing enteropathy and malnutrition. Ceruloplasmin levels may also be decreased in 10-20% of *WD* gene heterozygotes, who do not develop Wilson disease and do not require treatment.
- The method used by the laboratory (the oxidative assay or nephelometric assay) may also affect the results of ceruloplasmin measurement.

### **Urinary copper excretion**

- The urinary copper excretion rate is greater than 100 mg/d (reference range, <40 mg/d) in most patients with symptomatic Wilson disease. The rate may also be elevated in other cholestatic liver diseases.
- Both the sensitivity and specificity of this test are suboptimal for use as a screening test; however, it may be useful to confirm the diagnosis and to evaluate the response to chelation therapy.

### **Hepatic copper concentration**

- This test is regarded as the criterion standard for diagnosis of Wilson disease.

- A liver biopsy with sufficient tissue reveals levels of more than 250  $\mu\text{g/g}$  of dry weight even in asymptomatic patients. Special collection vials are available to help avoid contamination.
- A normal hepatic copper concentration (reference range, 15-55  $\mu\text{g/g}$ ) effectively excludes the diagnosis of untreated Wilson disease. An elevated hepatic copper concentration may be found in other chronic hepatic (mostly cholestatic) disorders.

### **Radiolabeled copper**

- Radiolabeled copper testing directly assays hepatic copper metabolism. Blood is collected at 1, 2, 4, 24, and 48 hours after oral ingestion of radiolabeled copper ( $^{64}\text{Cu}$  or  $^{67}\text{Cu}$ ) for radioactivity in serum. In all individuals, radioactivity promptly appears after absorption, followed by hepatic clearance. In healthy people, reappearance of the radioactivity in serum occurs as the labeled copper is incorporated into newly synthesized ceruloplasmin and released into the circulation.
- Heterozygotes exhibit a slow lower-level reappearance of radioactivity rather than the continued fall in radioactivity in those with Wilson disease, but there may be considerable overlap between the two. Patients with Wilson disease, even those with normal ceruloplasmin levels, do not exhibit the secondary rise in radioactivity.

## **Genetic diagnosis**

Linkage analysis has been used in family studies for presymptomatic testing; however, the multiplicity of mutations (>200 mutations) of *ATP7B* have been identified that require screening in individuals without affected family members is large, making such analysis impractical. Therefore, the use of molecular testing is currently limited to screening of family members for an identified mutation detected in the index patient.

## **Imaging Studies:**

- Cranial CT scan
  - The cranial lesions observed on CT scan are typically bilateral and are classified into 2 general categories, i.e., (1) well-defined, slit like, low-attenuation foci involving the basal ganglia, particularly the putamen and (2) larger regions of low attenuation in the basal ganglia, thalamus or dentate nucleus.
  - Widening of the frontal horns of the lateral ventricles and diffuse cerebral and cerebellar atrophy, which correlate histologically with widespread neuronal loss, have also been described.

- Brain MRI
  - MRI of the brain appears to be more sensitive than CT scanning in detecting early lesions of Wilson disease.
  - MRI studies have identified focal abnormalities in the white matter, pons and deep cerebellar nuclei. These lesions, measuring 3-15 mm in diameter, are typically bilateral, appearing with low signal intensity on T1-weighted images and with high signal intensity on T2-weighted images, representing cell loss and gliosis. Other studies describe decreased signal intensity in the putamen and other parts of the basal ganglia, which may represent either copper or iron ferritin deposition.
  - A characteristic "face of the giant panda" sign has been described, formed by high signal intensity in the tegmentum (except for the red nucleus), preserved signal intensity of the lateral portion of the pars reticulata of the substantia nigra, and hypointensity of the superior colliculus.
- Positron emission tomography scan
  - Positron emission tomography (PET) scan reveals a significantly reduced regional cerebral metabolic rate of glucose consumption in

the cerebellum, striatum, and, to a lesser extent, in the cortex and thalamus.

- PET analyses of patients with Wilson's disease have also demonstrated a marked reduction in the activity of dopa-decarboxylase, indicative of impaired function of the nigrostriatal dopaminergic pathway.
- These abnormalities improve with chelation therapy, indicating a reversible component of striatal neuron injury.

Abdominal imaging: CT scan, MRI, ultrasound, and nuclear medicine studies of the liver have been uninformative, with findings neither specific nor sensitive for Wilson's disease.

- Electron microscopy
  - Electron microscopic studies on ultra thin sections reveal numerous electron-dense lysosomes and residual bodies.
  - The elemental analysis in transmission electron microscopy with electron energy loss spectroscopy, and in scanning electron microscopy with energy dispersive x-ray analysis, shows copper-specific signals of electron-dense accumulations inside these dark lysosomes and residual bodies.

- The electron microscopic detection of copper-containing hepatocytic lysosomes is helpful for the diagnosis of early stages of Wilson disease in addition to the quantification of hepatic copper by atomic absorption spectrophotometry.

### **Other Tests:**

- Resting ECG abnormalities include left ventricular or biventricular hypertrophy, early repolarization, ST segment depression, T-wave inversion and various arrhythmias.

### **Procedures:**

In the absence of Kayser-Fleischer rings or neurologic abnormalities, a liver biopsy for quantitative copper determination is essential to establish the diagnosis of Wilson's disease

### **Histological Findings:**

#### **Hepatic**

- The earliest changes detectable with light microscopy include glycogen deposition in the nuclei of periportal hepatocytes and moderate fatty infiltration. The lipid droplets, which are composed of triglycerides, progressively increase in number and size, sometimes resembling the

steatosis induced by ethanol. Hepatocyte mitochondria typically exhibit heterogeneity in size and shape, with increased matrix density, separation of the normally apposed inner and outer mitochondrial membranes, widened intercrystal spaces, and an array of vacuolated and crystalline inclusions within the matrix. With progression of disease, copper protein is sequestered in lysosomes and is visible as electron-dense pericanalicular granules.

- Despite consistently elevated hepatic copper levels in patients with Wilson disease, histochemical staining of liver biopsy specimens for copper is of little diagnostic value. Early in the disease, copper distribution is primarily cytoplasmic and is not readily apparent with rhodamine or rubeanic acid staining.
- The rate of progression of the liver histology from fatty infiltration to cirrhosis is variable, although it tends to occur by one of two general processes, either with or without hepatic inflammation. The histologic picture may be histologically indistinguishable from that of chronic active hepatitis. Pathologic features include mononuclear cell infiltrates, which consist mainly of lymphocytes and plasma cells, piecemeal necrosis extending beyond the limiting plate, parenchymal collapse, bridging hepatic necrosis, and fibrosis. The histologic pattern is one of a macronodular or mixed micro-macronodular cirrhosis, with fibrous septa (containing predominantly types I and III collagen), bile ductule proliferation, and



variable septal round cell infiltration. Hepatocytes at the periphery of the nodules frequently contain Mallory hyaline.

- One proposed mechanism implicates copper as the inducer of fibrogenesis. Interestingly, hepatocellular carcinoma is exceedingly rare in patients with Wilson's disease compared to patients with hemochromatosis. This may be attributable to the significantly shortened life expectancy in untreated patients, which does not allow time for carcinoma to develop. An increasing number of case reports suggest that the incidence will likely increase with improved survival. It has been proposed that the diminished cancer risk is due to the relatively low inflammatory component in the pathogenesis of Wilson's disease.

### Neurologic

- Observed gross anatomic changes include degeneration and cavitation, primarily involving the putamen, globus pallidus, caudate nucleus and thalamus.
- Little correlation has been observed between the degree of neurologic impairment and the neuropathologic findings. The affected areas of the brain do not possess higher copper concentrations than the unaffected portions.

In 2001 at the 8th international conference on Wilson disease and Menkes disease a scoring system for the diagnosis of Wilson disease was discussed<sup>39</sup>. The aim was to provide objective criteria with high sensitivity and specificity for the diagnosis of Wilson disease. A combination of clinical and biochemical tests with a score ranging from 0 to 4 for each test were developed.

The patients with a total score of at least 4 were diagnosed with Wilson disease. The patients with a total score of two to three were considered as "likely to have Wilson's disease, yet more investigations had to be performed". The diagnosis of Wilson's disease was judged to be improbable for scores between zero and one. With respect to molecular analysis, it should be noted that more than 200 different mutations have been identified. It has been difficult to devise a simple genetic screening test for the disease.

In order to test this scoring system, 143 children with chronic liver disease, aged at least 5 years, were reviewed. All patients had urinary copper assessments and a liver biopsy as part of the diagnostic work up.

Fifty patients with Wilson disease had a score  $\geq 4$  (true positives). A total of 85 true negatives with a score of either 2-3 (40 children) or  $< 1$  (45 children) were observed. Only 3 patients with Wilson disease had a score of 2 to 3 (false negatives), while 5 non Wilson disease patients had a score of at least 4 (false positives). Both sensitivity and specificity of this scoring system was higher than

94%. In addition, positive predictive value and negative predictive values were higher than 90% (90.9% and 96.59% respectively).

Table 1: Scoring system for the diagnosis of Wilson disease

<b>Liver copper</b> (in absence of cholestasis)		<b>Serum Caeruloplasmin</b>	
Normal (<50 µg/g)	-1	Normal(>0.2g/l)	0
<5xULN (50-250 µg/g)	1	0.1-0.2g/l	1
>5xULN (>250 µg/g)	2	<0.1g/l	2
<b>Rhodanine Stain</b>			
Absent	0		
Present	1		
<b>Mutation Analysis</b>		<b>Clinical symptoms and signs</b>	
2 chromosome mutations	4	KF rings	
1 chromosome mutation	1	Present	2
No mutations detected	0	Absent	0
<b>Urinary copper</b> (in absence of acute hepatitis)			
Normal	0	Severe	2
1-2x ULN	1	Mild	1
>2x ULN	2	Absent	0
Normal but >5xULN after penicillamine	2	Coombs' negative haemolytic anemia	
		Present	1
		Absent	0

Table 2 : Scoring system for the diagnosis of Wilson disease

	Score			
	$\geq 4$	2-3	$\leq 1$	Total
Wilson's disease Patients	50	3	0	53
Other diagnosis	5	40	45	90
	True +	False -	False+	True -
Wilson's disease Patients	50	3		
Other diagnosis			5	85
	Sensitivity	Specificity	+ predictive value	Predictive value
	94%	94%	91%	97%

## TREATMENT<sup>40</sup>

Penicillamine was previously the primary anticopper treatment but now plays a minor role because of its toxicity and because it worsens existing neurologic disease if used as initial therapy. If penicillamine is given, it should always be accompanied by 25 mg/d of pyridoxine. Trientine is a less toxic chelator and has largely supplanted penicillamine.

For patients with hepatitis or cirrhosis, without evidence of hepatic decompensation other than a mildly elevated bilirubin level and without neurologic or psychiatric symptoms from Wilson's disease, zinc is the therapy of choice, although some advocate therapy with trientine. Zinc has proven efficacy in Wilson disease and is essentially nontoxic. It produces a negative copper balance by blocking intestinal absorption of copper, and it induces hepatic metallothionein synthesis, which sequesters additional toxic copper. All presymptomatic patients should be treated prophylactically, since the disease is close to 100% penetrant.

The first step in evaluating patients presenting with hepatic decompensation is to establish disease severity, which can be estimated using the Nazer prognostic index. Patients with scores = 6 can usually be managed with medical therapy. Patients with scores = 10 should be considered immediately for liver transplantation, and those with scores between 7 and 9 require clinical judgment as to whether to recommend transplantation or medical therapy. A combination of trientine and zinc has been used to treat patients with Nazer scores as high as 9, but such patients should be watched carefully for indications of hepatic deterioration, which mandates transplantation.

For initial medical therapy of patients with hepatic decompensation, a chelator (trientine is preferred) plus zinc is recommended. Zinc should not, however, be ingested simultaneously with trientine, as it will chelate zinc and form therapeutically ineffective complexes; the two drugs should be separated by at least 1 hr. Hepatic transplantation is necessary for patients with severe hepatic decompensation.

For initial neurologic therapy, tetrathiomolybdate is emerging as the drug of choice because of its rapid action, preservation of neurologic function, and low toxicity. However, until tetrathiomolybdate is commercially available, trientine and zinc are recommended for 8 weeks, at which time the trientine can be stopped, and zinc continued for maintenance therapy. Although hepatic transplantation may improve neurologic symptoms, it does so only by removing copper, which can be done more safely and inexpensively with anticopper drugs.

Table 3: Profile of drugs used in the treatment of Wilson disease

<i><b>DRUG</b></i>	<i><b>MODE OF ACTION</b></i>	<i><b>NEUROLOGICAL DETORINATION?</b></i>	<i><b>SIDE EFFECTS</b></i>	<i><b>COMMENTS</b></i>
<b>D-penicillamine</b>	General chelator; induces cupriuria	10% to 50% during initial phase of treatment	Fever, rash, proteinuria, aplastic anaemia, leucopenia, thrombocytopenia, nephritic syndrome, degenerative changes in skin, elastosis perforans serpiginosa, serous retinitis, hepatotoxicity,	Reduced dose for surgery to promote wound healing & during pregnancy
<b>Trientine</b>	General chelator; induces cupriuria	Occasionally during initial phase of treatment	Gastritis, aplastic anaemia rare, sideroblastic anaemia,	Reduced dose during surgery to promote wound healing and during pregnancy
<b>Zinc</b>	Metallothionein inducer; blocks intestinal absorption of copper	During initial phase of treatment	Gastritis; biochemical pancreatitis, zinc accumulation, possible changes in immune function	No dose reduction for surgery or pregnancy
<b>Tetrathio-molybdate</b>	General chelator; blocks copper absorption, induces intestinal and urinary copper loss	Reports of only rare neurologic deterioration during initial treatment	Anaemia; neutropenia	Experimental in the united states and Canada

Anticopper therapy must be life long. With treatment, liver function usually recovers after about a year, although residual liver damage is usually present. Neurologic and psychiatric symptoms usually improve between 6 and 24 months of treatment.

Table 4: Drugs used in the treatment of Wilson disease

<b>DISEASE STATUS</b>	<b>FIRST CHOICE</b>	<b>SECOND CHOICE</b>
<b>Initial hepatic</b>  Hepatitis or cirrhosis without decompensation	Zinc	Trientine
<b>Hepatic decompensation</b>  Mild  Moderate  Severe	Trientine and Zinc  Trientine and Zinc  Hepatic transplantation	Penicillamine and Zinc  Hepatic transplantation  Trientine and Zinc
<b>Initial psychiatric/ neurologic</b>	Tetrathiomolybdate and  Zinc	Trientine and Zinc
<b>Maintenance</b>	Zinc	Trientine
<b>Presymptomatic</b>	Zinc	Trientine
<b>Pediatric</b>	Zinc	Trientine
<b>Pregnant</b>	Zinc	Trientine

## **Diet**

Patients should generally avoid eating foods with a high copper content such as liver, chocolate, nuts, mushrooms, legumes and shellfish (especially lobster). Drinking water from atypical sources (e.g., well water) should be analyzed for copper content and replaced with purified water if the copper content is greater than 0.2 parts per million.

## **Monitoring Anticopper Therapy**

When first using trientine or penicillamine, it is necessary to monitor for drug toxicity, particularly bone marrow suppression and proteinuria. Complete blood counts, standard biochemical profiles, and a urinalysis should be performed at weekly intervals for a month, then at 2-weekly intervals for 2 to 3 months, then at monthly intervals for 3 or 4 months, and at 4- to 6-monthly intervals thereafter.

The anticopper effects of trientine and penicillamine can be monitored by following 24-h "free" serum copper. Changes in urine copper are more difficult to interpret because excretion reflects the effect of the drug, as well as body loading with copper. Free serum copper is calculated by subtracting the ceruloplasmin copper from the total serum copper. Each 10 mg/dL of ceruloplasmin contributes 0.5  $\mu\text{mol/L}$  (3.0  $\mu\text{g/dL}$ ) of serum copper. The normal free copper value is 1.6 to 2.4  $\mu\text{mol/L}$  (10 to 15  $\mu\text{g/dL}$ ), and it often is as high as 7.9  $\mu\text{mol/L}$  (50  $\mu\text{g/dL}$ ) in untreated Wilson disease. With treatment, free copper should be  $<3.9 \mu\text{mol/L}$  ( $<25 \mu\text{g/dL}$ ).



Zinc treatment does not require blood or urine monitoring for toxicity. Its only significant side effect is gastric burning or nausea in about 10% of patients, usually with the first morning dose. This can be mitigated by taking the first dose an hour after breakfast or taking the zinc with a small amount of protein. Because zinc mainly affects stool copper, 24-h urine copper can be used to reflect body loading. The typical value in untreated symptomatic patients is  $>3.1 \mu\text{mol}$  ( $>200 \mu\text{g}$ ) per 24 h. This level should decrease during the first 1 to 2 years of therapy to  $<2.0 \mu\text{mol}$  ( $<125 \mu\text{g}$ ) per 24 h. A normal value [ $0.3$  to  $0.8 \mu\text{mol}$  ( $20$  to  $50 \mu\text{g}$ )] is rarely reached during the first decade of therapy and should raise concern about over treatment (copper deficiency), the first sign of which is anemia and/or leukopenia.

### **Surgical Care:**

- The use of surgical decompression or transjugular intrahepatic shunting (TIPS) in the treatment of portal hypertension is reserved for individuals with recurrent or uncontrolled variceal bleeding that is unresponsive to standard conservative measures.
- Orthotopic liver transplantation is a potentially curative treatment of Wilson's disease.

- Transplantation is primarily reserved for treatment of patients with fulminant liver failure or end-stage liver disease, which progresses despite chelation therapy.
- The selection of patients for transplantation may be facilitated by determination of a prognostic index, which is based on the degree of abnormality of serum aspartate aminotransferase, bilirubin, and prothrombin time and appears to accurately predict a fatal or nonfatal outcome.
- In the absence of severe hepatic disease, liver transplantation is generally not recommended for treatment of refractory extrahepatic manifestations.

**Prognosis:**

Table 5: Prognostic Index of NAZER in Fulminant Wilsonian Hepatitis

Laboratory measurement	Normal value	Score (in points)				
		0	1	2	3	4
Serum bilirubin	0.2 – 1.2 mg/dl	<5.8	5.8-8.8	8.8-11.7	11.7-17.5	>17.5
Serum aspartate transaminase	10-35 IU/L	<100	100-150	151-200	201-300	>300
Prolongation of prothrombin time (seconds)	-	<4	4-8	9-12	13-20	>20

- Patients with a prognostic index (i.e., score) of 10 or greater should be considered immediately for liver transplantation. All patients who exceeded this score died within 2 months of diagnosis despite the institution of appropriate medical therapy.
- Prognosis after liver transplantation is relatively good. In a study involving 55 patients with Wilson disease who underwent hepatic transplantation, the 1-year survival rate was 79% and the overall survival rate was 72% at 3 months to 20 years.
- In view of the social and economic implications and the occurrence of Wilson disease among family members, it is essential to look/ search for Wilson disease as early as possible and provide them appropriate treatment to delay the progression.

## Materials and Methods

Study Design	:	Prospective observational study
Setting	:	Govt. Rajaji Hospital, Madurai
Collaborating Departments	:	Department of Neurology & Department of Medicine
Period of study	:	August 2004 to August 2006
Ethical clearance	:	Ethical committee approved the methodology of the study and the copy was enclosed in annexure I
Consent	:	Consent was obtained from all the patients considered for the current study.
Financial support	:	This project did not receive funds from any national National organization/ charitable agencies.
Conflict of interest	:	Nil

### **Inclusion criteria**

- 1) Patients belonging to the age group of 5-50 yrs with one or other neurological manifestations in the form of
  - Extra pyramidal features like tremors, choreoathetosis, dystonia and akinetic rigid syndromes
  - Cerebellar manifestations in the form of intention tremors, ataxia, dysarthria, etc.
  - Neuropsychiatric manifestations

Patients with the above mentioned manifestations who had

1. Kayser Fleischer rings and
2. decreased serum ceruloplasmin (<20 mg/dl)

were taken up for the study.

### **Exclusion criteria**

The exclusion criteria included

- 1) Patients with the above neurological manifestations but who did not satisfy the criteria for the diagnosis of Wilson disease.
- 2) Patient not willing to cooperate for the evaluation.

## **METHODS**

Socio-demographic and clinical data were elicited from the patients. Laboratory results were obtained and recorded in a pro forma (enclosed in annexure II).

### **I. Socio demographic data:**

- a) Age
- b) Sex
- c) Locality
- d) Occupation
- e) Family history and symptoms among family members

### **II. Clinical data**

- a) Height
- b) Weight
- c) Pulse rate
- d) Blood pressure
- e) Clinical history and examination
- f) Slit lamp examination

### **III. Laboratory data**

- a) Complete hemogram
- b) Blood sugar & serum electrolytes
- c) Urine examination & renal function tests
- d) Liver function tests

- e) Serum ceruloplasmin
- f) Electrocardiogram

#### **IV. Imaging studies**

- a) Chest x-ray PA view
- b) X-ray of joints in selected cases
- c) Ultrasound examination of abdomen
- d) CT &/ MRI imaging of the brain in selected cases

Hemoglobin was measured using Sahli's hemoglobinometer.

Total count was carried out using hemocytometer, differential count carried out using Leishman's stain and platelet count was counted manually by using cresyl violet staining.

Urine analysis was completed by adopting standard bedside procedure.

Blood sugar, blood urea, serum creatinine and serum electrolytes were estimated using ERBA XL 300 automated analyzer.

ECG: 12 lead ECG was taken in all the patients

X-ray Chest: PA view was taken in a radiation dosage of 0.02mSv.

Serum ceruloplasmin was determined using the oxidation method and values < 20 mg/dl were taken as abnormal.

Ultrasound examination of abdomen was done in all patients.

Computerized tomography of brain and magnetic resonance imaging of brain were done in selected patients.

### **Limitations of the study**

- 1) Due to technical reasons all patients could not be investigated with free copper and urinary copper levels.
- 2) Considering the invasive nature, ethical committee clearance did not permit to perform liver biopsy to assess the copper levels in liver tissue.
- 3) Family members could not be screened as most of the patients' relatives did not turn up for the screening of the disease due to socio cultural implications of the progressive nature of the disease and the probable familial occurrence.
- 4) Due to socio-economic constraints most of the patients could not be followed up.
- 5) Genetic studies could not be done.
- 6) Specialized statistical analysis could not be applied in view of the small number of cases reported to the tertiary care centre over a period of 24 months.

### **BIAS :**

- 1) Selection bias – the selection of cases of Wilson disease was limited to those with neurological manifestation only.
- 2) Recall bias – symptomatology at onset of the disease was considered as reported by the patient or their family members of relatives.



## RESULTS

A total of 64 patients who had one or other forms of extrapyramidal manifestations with/without cerebellar, with/without neuropsychiatric manifestations were screened for the Wilson disease. The diagnosis was ascertained in 19 patients. Thus the prevalence of Wilson disease among those with extrapyramidal manifestations/cerebellar was 29.5% during the study period. These patients have been analyzed in detail.

### DISTRIBUTION OF CASES ACCORDING TO AGE AND GENDER

Among the 19 patients, there were 8 males and 11 females.

Table 6: Comparison of age group and gender

AGE GROUP (in years)	PATIENTS					
	MALE		FEMALE		TOTAL	
0-10	0	-	1	9.1%	1	5.3
11-20	5	62.5%	8	72.7%	13	68.4
21-30	2	25%	1	9.1%	3	15.8
31-40	1	12.5%	0	-	1	5.3
>40	0	-	1	9.1%	1	5.3
TOTAL	8	100	11	100	19	100
MEAN	20.13		18.27		19.05	
SD	9.37		9.69		9.34	
'p'	0.8038					

The youngest one to present was a 8 year old girl and the older one was a 45 year old male, both had neurological symptoms lasting months before the hospitalization. The mean age and SD of the study group among males and females was  $20.3\pm 9.4$  and  $18.3\pm 9.7$  years respectively.

The age of presentation was not significant with reference to gender.

Overall the average age of presentation has been determined to be 19.05 years with majority of patients falling in the 2<sup>nd</sup> decade group.

#### POSITIVE FAMILY HISTORY & CONSANGUINITY IN STUDY SUBJECTS

Out of 19 subjects 12 were born out of consanguineous marriage.

History of family members with the disease was obtained in 9 out of 19 subjects only.

Family members could not be screened as they were unwilling for screening.

#### DISTRIBUTION OF CASES ACCORDING TO DURATION OF SYMPTOMS

Duration of symptoms before the 1<sup>st</sup> presentation of all patients were obtained either from the patient or parents or relatives and it varied from 1 month to 5 years. The period of symptoms are displayed below in Table 7.

Mean duration of symptoms was 20.5 months.

Table 7: Age group in relation to duration of symptoms

AGE GROUP	MEAN (in months)	SD
0-10	6.1	-
11-20	15.1	15.16
21-30	30.42	18.25
31-40	36.5	-
>40	60.83	-
TOTAL	20.58	18.54
'p'	0.1573	

The younger the patient the duration was less.

The gender variation in the duration of symptomatology had been analyzed. Average duration of symptoms in male patients was 18.47 months and it was 22.09 months among females. However, it was not significant statistically ( $p=0.8352$ ). The details are provided in Table 8.

Table 8: Duration of symptoms in relation to gender

GENDER	DURATION OF SYMPTOMS (in months)	
	MEAN	SD
MALE	18.48	12.01
FEMALE	22.01	22.62
'p'	0.8352	

## DISTRIBUTION OF CASES ACCORDING TO THE SYMPTOMATOLOGY

The pattern of presentation was analyzed and categorized into four distinct types based upon the predominant symptoms. The patterns of presentation were compared with the age group, gender and the duration of symptoms. Although the study subjects were categorized into 4 groups based on the neurological findings there was considerable overlap of clinical features in all the patients.

The results are presented in the Table 9.

Table 9: Age group and pattern of neurological manifestation

PATTERN OF PRESENTATION*	AGE (in years)	
	MEAN	SD
PARKINSONIAN(6)	19.2	13.2
PSEUDOSCLEROTIC(8)	22.6	7.7
DYSTONIC(3)	12.3	1.2
CHOREIC(2)	14.5	2.1
'p'	0.0345	

\*Welshe (1984)

The majority of the patients presented with tremors which characteristically worsened on action and cerebellar symptoms were observed among these patients.

Choreic movements were noticed only in 2 cases and that too in upper limbs. There was significant correlation ( $p=0.03$ ) between the age and the pattern of presentation.

Duration of symptoms varied from 1.9 months to 26.6 months in various patterns of neurological manifestation which are given in Table 10.

Table 10: Duration of symptoms and pattern of neurological manifestation

PATTERN OF PRESENTATION	DURATION OF SYMPTOMS (in months)	
	MEAN	SD
PARKINSONIAN	18.5	21.26
PSEUDOSCLEROTIC	26.62	17.5
DYSTONIC	1.94	1.78
CHOREIC	15.2	12.9

However, there was no correlation could be made between the pattern of presentation and duration of symptoms.

Pattern of neurological manifestation in relation to gender is provided in Table 11 below.

Table 11: Pattern of presentation in relation to gender

PATTERN OF PRESENTATION	GENDER			
	MALE		FEMALE	
	No.	%	No.	%
PARKINSONIAN	3	50	3	50
PSEUDOSCLEROTIC	3	37.5	5	62.5
DYSTONIC	-	-	3	100
CHOREIC	2	100	-	-

## HEPATIC MANIFESTATIONS

The hepatic manifestations of the disease was considered when all or any one of the following were present

1) A positive history of jaundice in the past or at the time or presentation

or

2) Symptoms suggestive of chronic liver disease in the past or at the time or presentation

or

3) Clinical findings suggestive of liver disease

or

4) Investigations supporting hepatic involvement.

The results of the analysis were compared with other parameters of the patients.

Table 12: Hepatic disease in relation to gender

HEPATIC MANIFESTATION	GENDER			
	MALE		FEMALE	
	No.	%	No.	%
PRESENT(8)	5	62.5	3	37.5
NOT PRESENT(11)	3	27.3	8	72.7
'p'	0.1438			

Out of the total 8 patients who had hepatic involvement 6 patients were proved to be cirrhotic with clinical examination and/ investigations, 2 patients had previous history of jaundice which could be attributed to the disease process manifesting as jaundice during childhood but went undiagnosed.

Table 13: Duration of neurological symptoms and hepatic disease

HEPATIC MANIFESTATION	DURATION OF SYMPTOMS (in months)	
	MEAN	SD
PRESENT	15.94	14.29
NOT PRESENT	24.28	21.12
'p'	0.5057	

The average duration of symptoms with hepatic disease was 15.94 months and without hepatic disease was 23.28 months.

Table 14: Age and hepatic disease

HEPATIC MANIFESTATION	AGE (in years)	
	MEAN	SD
PRESENT	18.3	9.3
NOT PRESENT	19.6	9.8
'p'	0.5076	

There was no significant correlation noted between the age and incidence of the hepatic disease in these patients. There was no correlation noted between sex and the incidence of hepatic disease, similarly with duration of neurological symptoms and the incidence of hepatic disease.

All the patients who did not have hepatic manifestations with the above criteria were considered to have hepatic disease in a sub clinical form and as liver biopsy could not be done for these patients it is wise to consider them to be having liver disease until proved otherwise.

#### NEUROLOGICAL PATTERN AND HEPATIC MANIFESTATION

The correlation of the neurological pattern with the hepatic manifestation of the disease were analyzed.

Table 15: Pattern of neurological disease and hepatic disease in study subjects

PATTERN OF PRESENTATION	HEPATIC MANIFESTATION			
	PRESENT		ABSENT	
	No.	%	No.	%
PARKINSONIAN	3	50	3	50
PSEUDOSCLEROTIC	2	25	6	75
DYSTONIC	1	33.3	2	66.7
CHOREIC	2	100	0	-



There was no significant difference in the groups compared except with the majority of pseudosclerotic patients not having hepatic manifestations.

- Stigmata of chronic liver disease were observed in 3 patients (1-pseudosclerotic, 2-choreic group) however one had evidence of hepatic decompensation at the time of presentation.
- Splenomegaly of mild to moderate degree was observed in 4 patients.
- Hepatomegaly of mild degree was observed in only one patient.
- Liver span was reduced in 3 patients.

#### PSYCHIATRIC MANIFESTATIONS OF THE DISEASE

The number of patients with psychiatric manifestations either preceding or coexisting with the neurological symptoms were analyzed which was noticed in 9 patients only.

Baseline data of both group of patients were analyzed and compared.

Table 16: Comparison of psychiatric manifestation with age, sex and duration of neurological disease

VARIABLE	PSYCHIATRIC MANIFESTATION				'p'
	PRESENT		ABSENT		
	No.	%	No.	%	
1) SEX					
MALE	4	50	4	50	0.605
FEMALE	5	45.5	6	54.5	
2) AGE (in years)					
MEAN	19		19.1		0.8059
SD	10		9.3		
3) DURATION OF SYMPTOMS (in months)					
MEAN	19.24		21.78		0.7421
SD	19.60		18.51		

Both the groups had similar features except for the female predominance in those without psychiatric symptoms but there was no statistical significance in the variables (age, duration of neurological symptoms and sex) and the psychiatric manifestation when compared.

Three out of nine patients had psychiatric symptoms preceding the neurological manifestation by a few years.

Majority of the patients exhibited one or other symptoms which were in the form of

- 1) personality changes – irritability, emotional lability, extreme anger, decreased threshold and decreased ability to control it and occasional aggression.
- 2) Psychosis
- 3) Cognitive changes – intellectual decline, deteriorating school performance
- 4) Depression

The results are provided here in the Table 16 below

Table 17: Pattern of psychiatric manifestation

Pattern of psychiatric manifestation	Number of patients
Personality changes	4
Psychosis	3
Cognitive changes	3
Depression	1

To study whether the pattern of neurological symptoms had any correlation with the psychiatric manifestation, both the groups were compared and analyzed and the details are provided in Table 17 below.

Table 18: Psychiatric manifestation and the pattern of neurological manifestation

PATTERN OF PRESENTATION	PSYCHIATRIC MANIFESTATION			
	PRESENT		ABSENT	
	No.	%	No.	%
PARKINSONIAN	5	83.3	1	16.7
PSEUDOSCLEROTIC	2	25	6	75
DYSTONIC	0	-	3	100
CHOREIC	2	100	0	-

Psychiatric manifestation in the form of personality changes were observed in the majority of parkinsonian patients for whom cognitive assessment was difficult. Psychiatric manifestations were absent in the majority of pseudosclerotic patients and nil in the dystonic group.

#### OTHER MANIFESTATIONS OF THE PATIENTS

##### Autonomic symptoms

Out of 19 only one patient had autonomic symptoms in the form of profuse sweating involving all over the body which preceded the neurological manifestation (parkinsonian group).

- One episode of seizure of generalized tonic clonic nature was described by one patient (female aged 17 years) when the patient was 2 years of age and did not have further episodes.
- One patient had clinical presentation as of an acute encephalopathy when she was ten years old.
- Anosmia was complained by one patient and was confirmed on clinical examination.

### Bleeding manifestations

Bleeding manifestation in the form of epistaxis and gum bleeding were observed apart from the gastrointestinal bleed due to varices which was observed in only one patient. Number of patients who had epistaxis/bleeding gums were 5 eventhough all the patients had a normal platelet count, bleeding time and clotting time. Interestingly four out of five patients had evidence of liver disease.

### Musculoskeletal symptoms

Patients were observed for any musculoskeletal manifestations in the form of joint pains, joint deformities, osteoarthritic changes in the joints, etc.

Six patients had symptoms of joint pain(4 in the parkinsonian group & 2 in the pseudosclerotic group) which necessitated analgesics for pain management. The knee joint was the most common joint involved joint.

One patient (17 years of age) had osteoarthritic changes involving the major joints of both lower limb and also the small joints of both upper limb in a

symmetrical manner. She also had features of secondary fanconi's syndrome due to copper deposition in the proximal tubular epithelium of kidney.

#### Menstrual disturbances

Out of 11 female patients 7 attained menarche, out of which 3 had delayed menarche ( average = 16 yrs).

Five patients had regular menstrual cycles and 2 had irregular cycles.

Only one patient got married but did not have any child.

#### Other symptoms

- Night blindness was complained in 2 patients both had hepatic disease.

#### GENERAL EXAMINATION FINDINGS IN STUDY SUBJECTS

- All the study subjects had bilateral Kayser Fleischer ring visible without the aid of Slit lamp.
- Two patients had extensive tinea versicolor over the neck & trunk.
- Blue nails was observed in two patients.
- Vital data finding among the study subjects were normal.
- Features of osteoarthritic changes in small joints of both hands were observed in one patient with fanconi's syndrome.

#### OPHTHALMOLOGICAL FINDINGS IN STUDY SUBJECTS

- All patients were confirmed to have corneal rings by Slit lamp examination.

- Other ophthalmological findings include,
  - Sunflower cataract was observed in only one patient.
  - Subcapsular punctate cataract was observed in two patients.

#### SERUM CERULOPLASMIN IN STUDY SUBJECTS

All patients were investigated for serum ceruloplasmin and ranged from 10 mg/dl to 26 mg/dl,

The average serum ceruloplasmin of the patients was 15.04 mg/dl with values as low as <10 mg/dl observed.

There was no gender variation in the serum ceruloplasmin levels.

The values of the study subjects are provided in the tables given below.

Table 19: Serum ceruloplasmin levels in different age groups

AGE GROUP	SERUM CERULOPLASMIN(mg/dl)	
	MEAN	SD
0-10	10.0	-
11-20	14.02	4.71
21-30	16.7	0.96
31-40	26	-
>40	17.4	-
'p'	0.1531	
MALE	14.15	5.97
FEMALE	15.69	4.25
'p'	0.455	

There was no significant correlation when statistically analyzing the age and the serum ceruloplasmin levels.

The higher serum ceruloplasmin level observed in one patient had evidence of hepatic decompensation at the time of presentation which might have falsely elevated the ceruloplasmin level.

Table 20: Comparison of serum ceruloplasmin and pattern of neurological illness

PATTERN OF PRESENTATION	SERUM CERULOPLASMIN (mg/dl)	
	MEAN	SD
PARKINSONIAN	12.3	2.89
PSEUDOSCLEROTIC	18.48	4.66
DYSTONIC	14.8	3.97
CHOREIC	9.9	4.8
'p'	0.03	

There was significant correlation ( $p=0.03$ ) and the pattern of neurological manifestation with low values noted in the choreic and Parkinson group and higher ceruloplasmin values obtained in the pseudosclerotic group.

- Urine examination for all subjects was nil contributory but for 2 subjects who had abnormal urine examination out of which one had features of fanconi's syndrome and the other had only glycosuria, mild albuminuria and screening for aminoaciduria was negative.



- Hemoglobin, total count and differential count of the patients were within normal limits. There was no evidence of hemolysis in the patients during the study period, however they were not investigated with haptoglobin levels.
- Biochemical evidence of hepatic decompensation was present only in one patient, the rest had a normal Liver function profile except for a decreased serum albumin (<3.5g/dl) in 5 patients and elevated SGPT in 2 patients.
- Serum alkaline phosphatase was found elevated in 4 patients out of which one had evidence of secondary hyperparathyroidism as a part of fanconi's syndrome for others the cause was undetermined.
- Other biochemical parameters like blood sugar, blood urea and serum creatinine were within normal limits in all the study subjects.

#### IMAGING STUDIES IN THE STUDY SUBJECTS

- Ultrasound imaging of the liver showed altered echopattern of liver and decreased size of the liver in 6 patients.
- Chest X-ray of all the patients were within normal limits.
- X-ray of knee joint taken for those with symptomatic joint manifestations showed osteoarthritic changes 3 patients. Diffuse osteopenia was present in one patient who had fanconi's syndrome.
- CT was done only in 2 subjects who had bilateral hypodensities in basal ganglia.

- MR imaging was done in only one subject who had bilateral hypointense signal changes in T1W & hyperintense changes in T2 & FLAIR in thalamus, putamen, cerebral peduncles, midbrain & pons.

#### TREATMENT RESPONSE IN STUDY SUBJECTS

- Out of 19 patients only 6 patients turned up for follow up and so the clinical response of those 6 patients to treatment was assessed.
- Two of the pseudosclerotic group showed a good response to d-penicillamine therapy and were symptom free by about 8 months of therapy.
- Two other patients of the parkinsonian group did not show remarkable improvement in symptom control in the short term follow up for 6 months.
- Two other patients showed deterioration of clinical condition after d-penicillamine therapy and discontinued therapy. They were alternatively treated with zinc.

## DISCUSSION

Neurological manifestations is the second most common presentation of Wilson disease. Although hepatic manifestations is the most common presentation, adults with Wilson disease have predominantly neurological manifestations.

The onset of neurological symptoms is usually in the second and less often in the third decade, rarely beyond that time. Half of patients are symptomatic by age 15, but exceptionally patients present at an early or later age group.<sup>43</sup> In our study majority of patients (68.4%) present in the second decade with a mean age of 19 years. The youngest patient was a 8 year old girl who had neurological symptoms lasting for many months before 1<sup>st</sup> presentation. The oldest patient in our study was a 45 year old woman who had symptoms lasting few months before 1<sup>st</sup> presentation.

There is no gender variation in the neurological or any other form of manifestation in Wilson disease except for a slight increased frequency of fulminant hepatic failure in females. In our study, females outnumber males but still they do not show statistical significance when compared individually with the age group. Similarly there is no correlation between gender and the age of presentation understating the autosomal recessive nature of the disease.

The first neurological manifestations are most often extrapyramidal with a proclivity to affect the oropharyngeal musculature.<sup>43</sup> In our study most of the

patients had tremors either in the form of action/intention/resting tremors to start with later increasing in severity to affect the truncal and bulbar muscles. However, all patients exhibited some form of extrapyramidal manifestations in the form of dystonia, chorea, resting tremors, parkinsonian features, etc. predominating in atleast 60% of patients.

The duration of symptoms at first presentation has been compared with many variables. Two of our patients who had dystonia presented early (one month) when compared with the duration of symptoms of other patterns of the disease which averaged more than 21 months. There is no significant correlation in the duration of symptoms and the patterns of the presentation. The nature of the disability produced by the dystonia would have made the patients present with a short duration of symptoms. Similarly there was no gender influence of the symptomatology of the disease, but considering the social influence on female sex they may come to hospital late with the symptoms.

The age of the patient here showed a statistical significance ( $p=0.03$ ) when compared with the pattern of presentation with majority of pseudosclerotic patients presenting at a later age (mean age = 22.6). The average age for other patterns of the disease was around 15 years. This observation states the influence of age on the pattern of presentation and needs further large scale studies to prove such an association.

Although the liver is the first organ to suffer the toxicity of copper accumulation not all patients have manifestations out of liver disease. Subclinical

evidence of liver injury due to copper accumulation have been observed, so every other patient without clinical evidence of liver disease is said to have subclinical liver damage until proved otherwise. In our study 8 patients had evidence of liver disease (approx. 42%) which preceded the neurological manifestation most of the times.

The influence of the hepatic disease on the neurological manifestation of the disease has been studied and analyzed. The results show no such statistical correlation between the symptomatology and concomitant hepatic disease.

Neuropsychiatric manifestations are common which begins early or present subtly along with the neurological symptoms. Exceptionally, an abnormality of behavior or a gradual impairment of intellectual function precedes other neurologic signs by a year or more.<sup>43</sup> In our study 9 out of 19 patients had psychiatric symptoms amounting to approximately 50% of patients.

In our study 3 patients had psychiatric symptoms which preceded neurological manifestations by a year. Other patients had psychiatric manifestations observed along with neurological symptoms at the time of presentation. They were mostly in the form of personality changes and cognitive dysfunction.

The pattern of psychiatric symptoms were correlated with the neurological pattern and analysis revealed that personality changes were seen in most of the patients of parkinsonian group and were found to be decreased in frequency in pseudosclerotic group.

No other correlation of statistical significance was observed when comparing the psychiatric group with other variables.

Kayser-Fleischer rings are present invariably when there are neurological manifestations. A slit lamp examination may be necessary for their early detection particularly in brown-eyed patients, but in the majority of patients with neurological signs the rings can be visualized with the naked eye or with the aid of an indirect ophthalmoscope focused on the limbus.<sup>43</sup> Kayser-Fleischer ring was present in all patients in our study seen even with the naked eye confirmed by slit lamp examination. Three of our patients had cataract. One patient had sunflower cataract, the two others had posterior subcapsular cataracts.

Symptomatic joint disease, which occurs in 25-50% of patients,<sup>44,45</sup> usually presents late in course of the disease, frequently after 20 years of age; although occasionally osteoarthritis may be the initial manifestation.<sup>46,47,48</sup>

The general radiographic features of Wilson Disease consists of osteopenia and arthropathy. The arthropathy of Wilson disease observed on radiographic evaluation in 3/4th of all patients is a degenerative process that resembles premature osteoarthritis.<sup>44,45,49,50,51</sup> The arthropathy generally involve the spine, large appendicular joints such as wrist, elbow, shoulder, hip, knee, and metacarpophalangeal joints, associated with periarticular osteopenia. Radiologic studies reveal typical degenerative changes including osteophytes, sclerosis, subchondral pseudocysts, and bone fragmentation.

In our study musculoskeletal manifestations (40% ) were in the form of joint pain affecting knee joint in the majority of patients. One patient had arthralgia affecting multiple joints with radiological findings suggestive of osteoarthritic changes.

One patient presented with joint pain and deformities affecting the distal interphalangeal joints of both hands who had radiologically diffuse osteopenia and arthritic changes. The patient was found to have features of fanconi's syndrome with elevated alkaline phosphatase.

Other manifestations of Wilson include autonomic symptoms, which was present in one of our patient. Symptoms of bleeding in the form of epistaxis and gum bleeding was present in 26.3 % of patients, majority of them had liver disease which could explain the bleeding tendency.

Menstrual irregularities were noted in 2 of our patients out of 7 female patients who attained menarche. Three out of them had delayed onset of menarche. Menstrual irregularities has been attributed to endocrine disturbances secondary to disease process affecting the endocrine glands.

Hemolysis was not evidenced in any of our patients who had normal peripheral smear morphology and a normal hemoglobin values. However further investigations like serum haptoglobin and others had not been done to assess the hemolysis.

Serum ceruloplasmin was measured in all patients and the average was 15.04 mg/dl. There was no positive correlation between the serum ceruloplasmin and the other variables like age, sex and duration of symptoms.

However, there was a significant correlation between serum ceruloplasmin levels and the pattern of neurological manifestation ( $p=0.03$ ) with lesser values obtained in the parkinsonian and choreic group and higher values obtained in the pseudosclerotic group.

Treatment response was assessed only in 6 patients who had a regular follow up for upto 8 months. Two patients of the pseudosclerotic group showed remarkable symptom control and almost free of symptoms by 6-8 months. Two patients of the parkinsonian group did not show much of improvement even after prolonged therapy for 8 months. Two patients developed worsening of neurological symptoms after D-penicillamine therapy and was discontinued and started on zinc. But in majority of patients the reason for discontinuation was the high cost of drugs which they were not affordable and the slow improvement in symptomatology which makes them discontinue the medications.

Strength of the study:

- Rigid criteria to assess those with neurological presentation
- All of them who satisfied the rigid criteria were studied over a period of 24 months.



## CONCLUSION

1. The prevalence of Wilson disease with neurological manifestations at a neurology centre in tertiary care level was 0.4%
2. Among them those with extrapyramidal with or without cerebellar with or without neuropsychiatric manifestations in patients of the age group 5-50 years was around 29.5%
3. The most common age group of presentation is in the second decade.
4. Age of onset, duration of symptoms and the pattern of neurological manifestation was independent of gender.
5. Most common neurological manifestation were in the form of extrapyramidal symptoms.
6. Most common pattern of neurological manifestation were in the form of tremors (pseudosclerotic group), the second being parkinsonism.
7. Majority of pseudosclerotic patients presented later when compared to younger age of presentation in dystonic/choreic group.
8. The pattern of neurological manifestation were independent of the status of liver.
9. Psychiatric manifestation were observed in half of patients with personality disorders predominating in the parkinsonian group.
10. Serum ceruloplasmin had a significant correlation with the pattern of neurological manifestation with higher values obtained in

pseudosclerotic group and lesser values obtained in parkinsonian and dystonic group.

## **AREAS OF FURTHER WORK/RECOMMENDATION**

- To determine the incidence among population and disease burden proper documentation of all cases and through effective screening of all asymptomatic carriers of the abnormal gene.
- It is recommended to develop a disease registry at a higher tertiary care centre with proper hierarchical referral system.
- To correlate the phenotype of the patients with the genotypes.
- To study the pattern of the Wilson disease in Indian patients in a large scale prospective study and compare with the western world to elicit further differences in the presentation, severity of the disease, phenotype and genotype of the disease and the treatment response.
- To develop measures to decrease the incidence, develop less expensive methods for diagnosis, prevent morbidity by early identification and effective treatment and importance of genetic counseling.

## **SUMMARY**

Wilson disease is an autosomal recessive disorder characterized by degenerative changes in the brain, liver disease, and Kayser-Fleischer rings in the cornea. The disease has protean manifestations. It is fatal if untreated; requiring early diagnosis and effective treatment. Neurological manifestations arising out of Wilson disease is an important cause for the morbidity and mortality of the disease. Prompt identification of subtle neurological symptoms during early stages is important. As the disease advances, most of the symptoms do not completely resolve even with our effective treatment.

An attempt has been made here to study the Wilson disease through nervous system. The study was conducted over a period of 2 years screening for all the patients attending the neurology clinic with either one or the other neurological manifestations classical for Wilson disease. Nineteen patients selected for the study were divided into 4 major groups based on the predominant symptoms – parkinsonian, pseudosclerotic, dystonic and choreic. The patients were analyzed with respect to age, gender, duration of neurological symptoms, hepatic disease, psychiatric manifestations and serum ceruloplasmin level.

The study concluded that Wilson disease constituted approximately 30% of patients presenting with one or other symptoms in the form of extrapyramidal, cerebellar &/ psychiatric manifestations.

Extrapyramidal symptoms were the most common manifestation, with majority of patients presenting in the second decade. Most of the pseudosclerotic

patients present at a later age when compared with younger age of presentation seen with choreic/dystonic group. Family history was strong in 50% of patients with high rates of consanguinity observed. Hepatic manifestations of the disease were independent of the neurological manifestation. Almost half of patients exhibited psychiatric symptoms.

Serum ceruloplasmin levels were low in the dystonic and choreic group whereas higher levels were seen with the pseudosclerotic group which was statistically significant.

The study identified early manifestations in the form of tremors predominating in most of the patients. Such patients present early with deterioration in handwriting, slowness of activities and decline in school performance. It is not only the duty of the physician to appreciate such earlier symptoms but the duty of school teacher to identify them early and refer them timely to an appropriate health care system. Teachers and parents have to be educated for the same.

Apart from screening of family members using the newer molecular and genetic testing, genetic counseling is vital which helps to decrease the incidence of the disease in the community.

## **BIBLIOGRAPHY**

1. Wilson SAK. Progressive lenticular degeneration: a familial nervous disease associated with cirrhosis of the liver. *Brain* 1912;34:295-507
2. Fleischer B. Ueber einer der "Pseudosclerose" nahestehende bisher unbekannte Krankheit (gekennzeichnet durch Tremor, psychische Störungen, braeunliche Pigmentierung bestimmter Gewebe, insbesondere Such der Hornhauptperipherie, Lebercirrhose). *Deutsch Z Nerven Heilk* 1912;44:179-201.
3. Bearn AG. A genetical analysis of thirty families with Wilson's disease (hepatolenticular degeneration). *Ann Hum Genet* 1960;24:33-43.
4. Bull PC, Thomas GR, Rommens JM, Forbes JR, Cox DW. The Wilson disease gene is a putative copper transporting P-type ATPase similar to the Menkes gene. *Nat Genet* 1993;5:327-337.
5. Tanzi RE, Petrukhin K, Chernov I, Pellequer JL, Wasco W, Ross B, et al. The Wilson disease gene is a copper transporting ATPase with homology to the Menkes disease gene. *Nat Genet* 1993;5:344-350.
6. Petrukhin K, Fischer SG, Pirastu M, Tanzi RE, Chernov I, Devoto M, et al. Mapping, cloning and genetic characterization of the region containing the Wilson disease gene. *Nat Genet* 1993;5:338-343.
7. Yamaguchi Y, Heiny ME, Gitlin JD. Isolation and characterization of a human liver cDNA as a candidate gene for Wilson disease. *Biochem*

- Biophys Res Commun 1993;197:271-277.
8. Cumings JN. The effect of BAL in hepatolenticular degeneration. *Brain* 1951;74:10-22.
  9. Denny-Brown D, Porter H. The effect of BAL (2,3 dimercaptopropanol) on hepatolenticular degeneration (Wilson's disease). *N Engl J Med* 1951; 245:917-925.
  10. Walshe JM. Wilson's disease. New oral therapy. *Lancet* 1956;i:25-26.
  11. Walshe JM. The liver in Wilson's disease. In: Schiff L, Schiff ER, editors. *Diseases of the Liver*. 6th ed. Philadelphia: Lippincott, 1987:1037-1050.
  12. Saito T. Presenting symptoms and natural history of Wilson disease. *Eur J Pediatr* 1987;146:261-265.
  13. Scott J, Gollan JL, Samourian S, Sherlock S. Wilson's disease, presenting as chronic active hepatitis. *Gastroenterology* 1978;74:645-651.
  14. Schilsky ML, Scheinberg IH, Sternlieb I. Prognosis of Wilsonian chronic active hepatitis. *Gastroenterology* 1991;100:762-767.
  15. Milkiewicz P, Saksena S, Hubscher SG, Elias E. Wilson's disease with superimposed autoimmune features: report of two cases and review. *J Gastroenterol Hepatol* 2000;15:570-574.
  16. Steindl P, Ferenci P, Dienes HP, Grimm G, Pabinger I, Madl C, et al. Wilson's disease in patients presenting with liver disease: a diagnostic challenge. *Gastroenterology* 1997;113:212-218.
  17. Gow PJ, Smallwood RA, Angus PW, Smith AL, Wall AJ, Sewell RB.

Diagnosis of Wilson's disease: an experience over three decades. *Gut* 2000;46:415-419.

18. LaRusso NF, Summerskill WH, McCall JT. Abnormalities of chemical tests for copper metabolism in chronic active liver disease: differentiation from Wilson's disease. *Gastroenterology* 1976;70:653-655.
19. Stremmel W, Meyerrose KW, Niederau C, Hefter H, Kreuzpaintner G, Strohmeyer G. Wilson disease: clinical presentation, treatment, and survival. *Ann Intern Med* 1991;115:720-726.
20. Emre S, Atillasoy EO, Ozdemir S, Schilsky M, Rathna Varma CV, Thung SN, et al. Orthotopic liver transplantation for Wilson's disease: a single-center experience. *Transplantation* 2001;72:1232-1236.
21. Sanchez-Albisua I, Garde T, Hierro L, Camarena C, Frauca E, de la Vega A, et al. A high index of suspicion: the key to an early diagnosis of Wilson's disease in childhood. *J Pediatr Gastroenterol Nutr* 1999;28:186-190.
22. Martins da Costa C, Baldwin D, Portmann B, Lolin Y, Mowat AP, Mieli-Vergani G. Value of urinary copper excretion after penicillamine challenge in the diagnosis of Wilson's disease. *Hepatology* 1992;15:609-615.
23. Giacchino R, Marazzi MG, Barabino A, Fasce L, Ciravegna B, Famularo L, et al. Syndromic variability of Wilson's disease in children. Clinical study of 44 cases. *Ital J Gastroenterol Hepatol* 1997;29:155-161.



24. Demirkiran M, Jankovic J, Lewis RA, Cox DW. Neurologic presentation of Wilson disease without Kayser-Fleischer rings. *Neurology* 1996;46: 1040-1043
25. Cairns JE, Williams HP, Walshe JM. "Sunflower cataract" in Wilson's disease. *Br Med J* 1969;3:95-96.
26. Schilsky ML, Scheinberg IH, Sternlieb I. Liver transplantation for Wilson's disease: indications and outcome. *Hepatology* 1994;19:583-587.
27. Esmaeli B, Burnstine MA, Martonyi CL, Sugar A, Johnson V, Brewer GJ. Regression of Kayser-Fleischer rings during oral zinc therapy: correlation with systemic manifestations of Wilson's disease. *Cornea* 1996;15:582-588.
28. *vmov disord* 2006 Jun 8.
29. *nephron* 1996; 73(3) :477-9.
30. *arch neurol* 2005 Oct; 62(10) :1628-31.
31. Brewer GJ: Recognition, diagnosis, and management of Wilson's disease. *Proc Soc Exp Biol Med* 2000 Jan; 223(1): 39-46.
32. Cuthbert JA: Wilson's disease. Update of a systemic disorder with protean manifestations. *Gastroenterol Clin North Am* 1998 Sep; 27(3): 655-81, vi-vii.
33. Gitlin N: Wilson's disease: the scourge of copper. *J Hepatol* 1998 Apr; 28(4): 734-9.

34. Huster D, Kuhn HJ, Mossner J: Wilson disease. *Internist (Berl)* 2005 Jul; 46(7): 731-2, 734-6, 738-40.
35. Perri RE, Hahn SH, Ferber MJ: Wilson Disease keeping the bar for diagnosis raised. *Hepatology* 2005 Oct; 42(4): 974.
36. Pfeil SA, Lynn DJ: Wilson's disease: copper unfettered. *J Clin Gastroenterol* 1999 Jul; 29(1): 22-31.
37. Schilsky ML: Wilson disease: new insights into pathogenesis, diagnosis, and future therapy. *Curr Gastroenterol Rep* 2005 Feb; 7(1): 26-31.
38. Walshe JM: Copper: its role in the pathogenesis of liver disease. *Semin Liver Dis* 1984 Aug; 4(3): 252-63.
39. 8th International conference on Wilson's disease and Menkes Disease. Leipzig/ Germany, April 16-18, 2001
40. Harrison's principles of internal medicine 16<sup>th</sup> edition; vol II: 2313-2315.
41. Nelson textbook of pediatrics 16<sup>th</sup> edition: 1209-1210
42. API textbook of medicine 7<sup>th</sup> edition: 266-267
43. Adams and Victor's principles of neurology 8<sup>th</sup> edition: 831-832
44. Golding DN, Walshe JM. Arthropathy of Wilson's disease: a study of clinical and radiological features in 32 patients. *Atlanta R J Arthritis Foundation* 1988:215
45. Menerey K A, Eider W, Brewer G J, et al. The arthropathy of Wilson's disease: clinical and pathological features. *J Rheumatol* 1988; 15:331.

46. Saito T. Presenting symptoms and natural history of Wilson's disease. *Eur J Pediatr* 1987;146:261
47. Lugassy G, Michaeli J, Oren R. Wilson's disease presenting as isolated arthritis of the hip. (Letter). *Arthritis Rheum* 1988; 31:573
48. Walshe J M. Wilson's disease: the presenting symptoms. *Arch Dis Child* 1962;37:253
49. Feller ER, Schumacher HR. Osteoarticular changes in Wilson's disease. *Arthritis Rheum* 1972;15:259.
50. Fox IH, Menerey KA. The arthropathy of Wilson's disease. In: Schumacher RJ, ed. *Primer on Rheumatic Diseases*. Atlanta, R J Arthritis Foundation, 1988; 215.
51. Braunstein EM, Burnstein MI. The arthritis of metabolic disease. *Curr Prob Diagn Radiol* 1987;16:179.

## **APPENDIX II**

### **PROFORMA**

**Period of study :**

**Patient number :**

**Name :**

**In patient number :**

**Age at presentation :**

**Sex :**

**Contact address :**

**Marital status :**

**Occupation :**

**Income :**

**Referred from :**

**Chief complaints**

**History of presenting complaints**

**Past history**

**Family history**

**No. of siblings/children**

**Whether born out of consanguineous marriage:**

**Prenatal/natal/postnatal history:**

**Developmental history:**

**Immunization history:**

**Drug/trt. History:**

**Clinical examination findings**

General examination:

Built -

Nourishment -

Cyanosis - clubbing - jaundice - pallor - pedal edema -

Lymphadenopathy -

Signs of liver cell failure -

KF ring

Vital signs

Pulse - temperature –

BP- RR –

**System examination**

**Central nervous system**

**Abdomen**

**Cardiovascular system**

**Respiratory system**

**Clinical summary:**

**Investigations**

## **General**

Complete hemogram

Blood urea -

Blood sugar -

Serum creatinine-

Serum electrolytes -

Urine examination

Chest X- ray

ECG

## **Liver function tests**

Bilirubin

Total -

Direct -

Indirect-

SGOT -

SGPT -

ALP –

Serum proteins

Total -

Albumin -

Globulin -

Serum ceruloplasmin -

Ultrasound

UGI scopy

CT scan/ MRI

Serum copper – free

Total

Urinary copper (24 hour)

Liver biopsy

**Specialists opinion:**

MGE opinion:

Ophthalmologist opinion:

Psychiatrist opinion:



Neurologist opinion:

ENT opinion:

**Treatment**

Date of starting treatment

Clinical condition after starting treatment

Follow up

Medicine procured from

Compliance of drugs

Reason for discontinuation (if any)

Financial constraints

Prognosis :

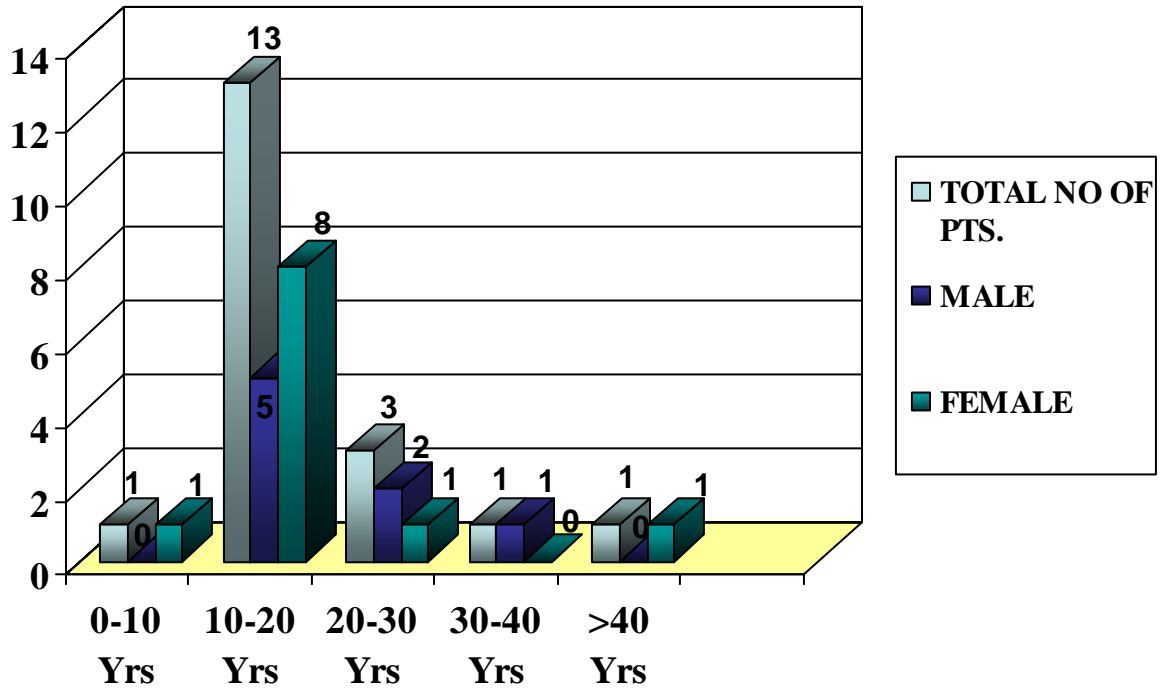
Alive/ dead :

Cause of death :

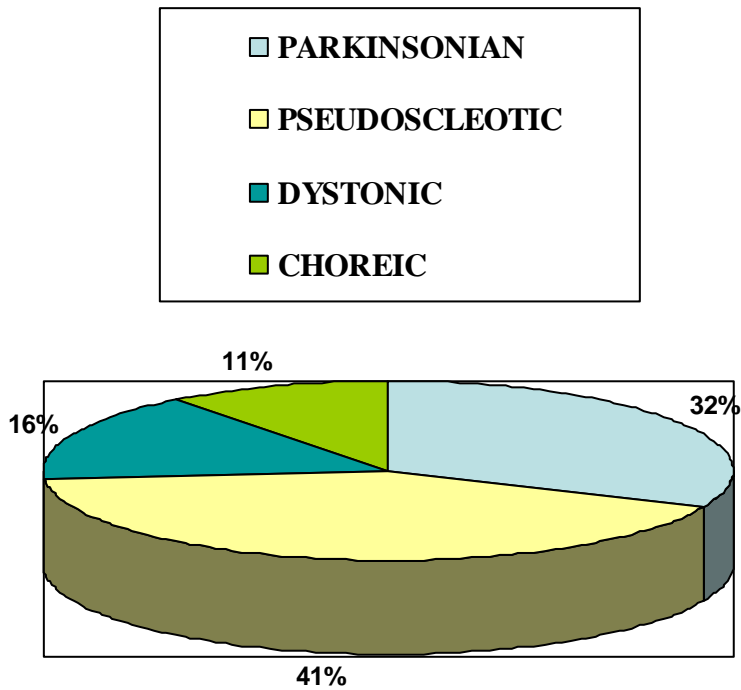
**APPENDIX I**

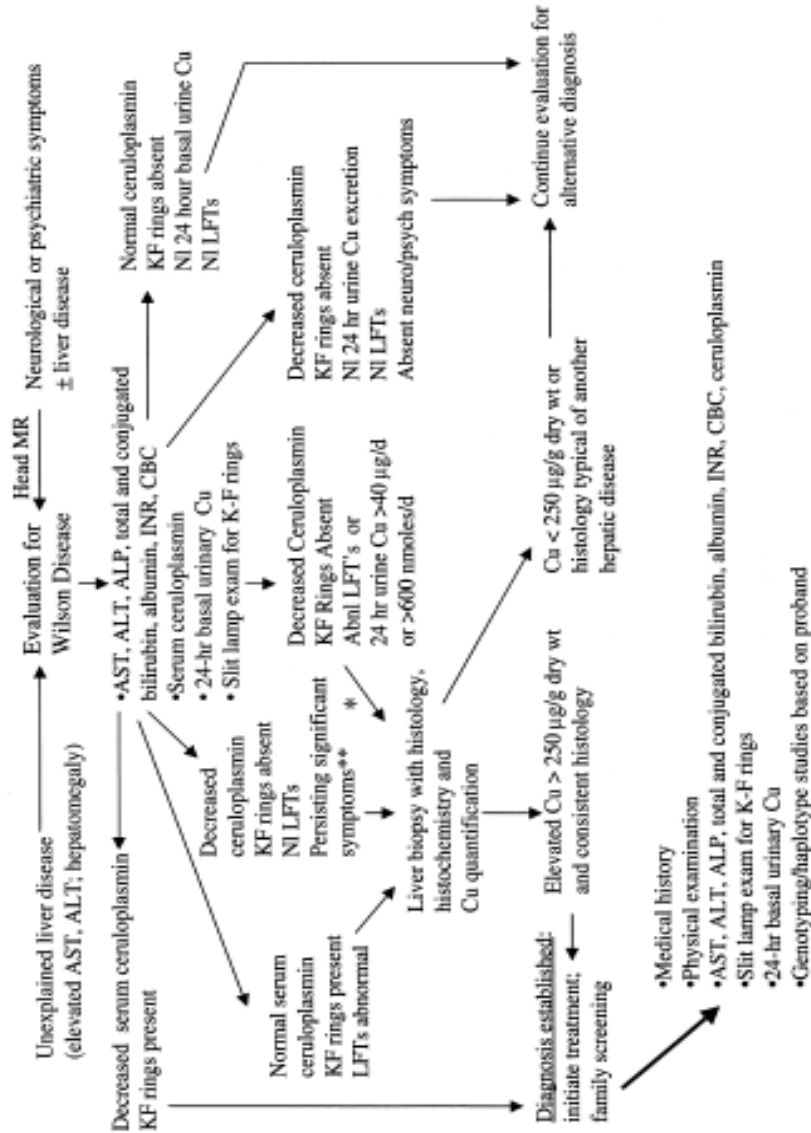
**ETHICAL COMMITTEE FORM**

### DISTRIBUTION OF PATIENTS ACCORDING TO AGE & GENDER

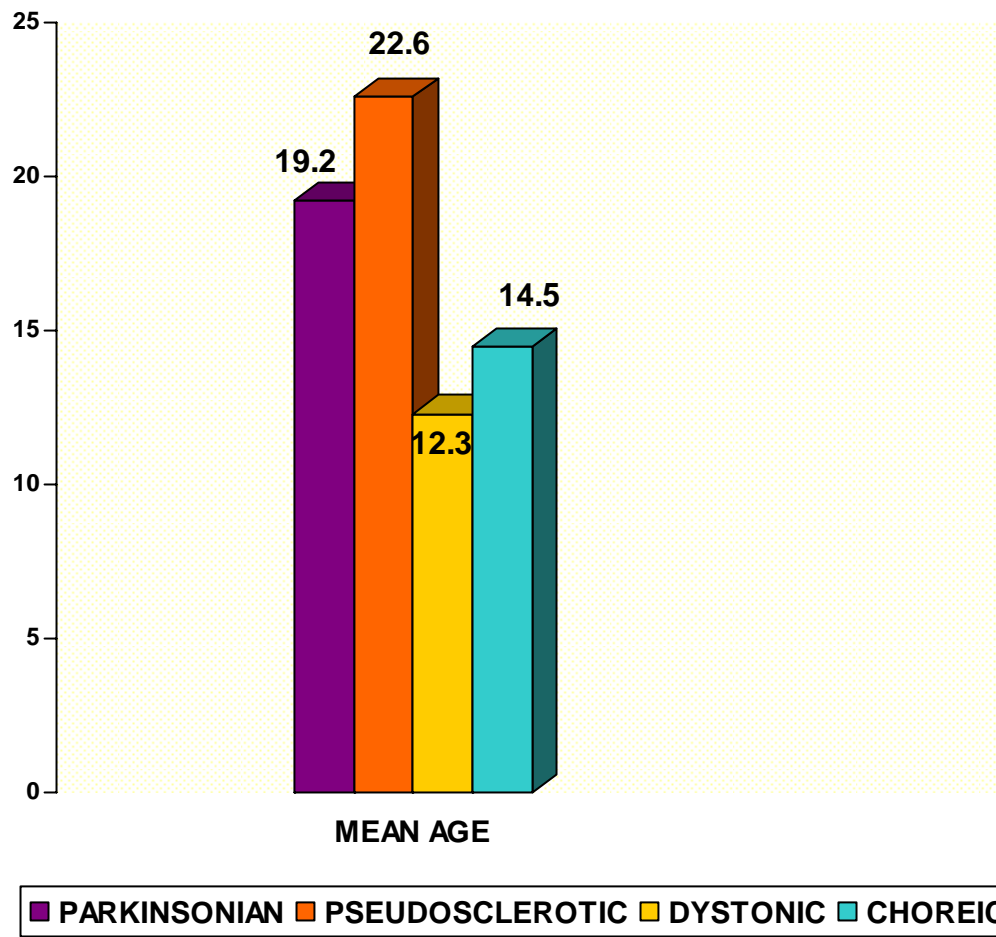


### PATTERNS OF NEUROLOGICAL MANIFESTATION

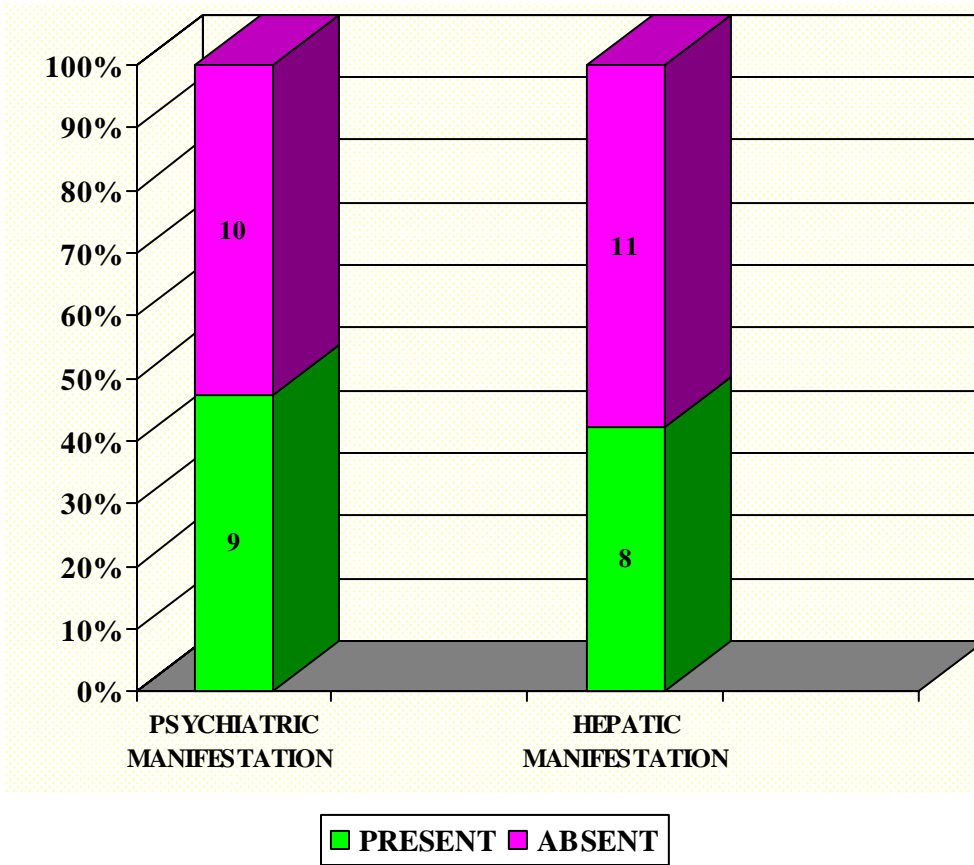




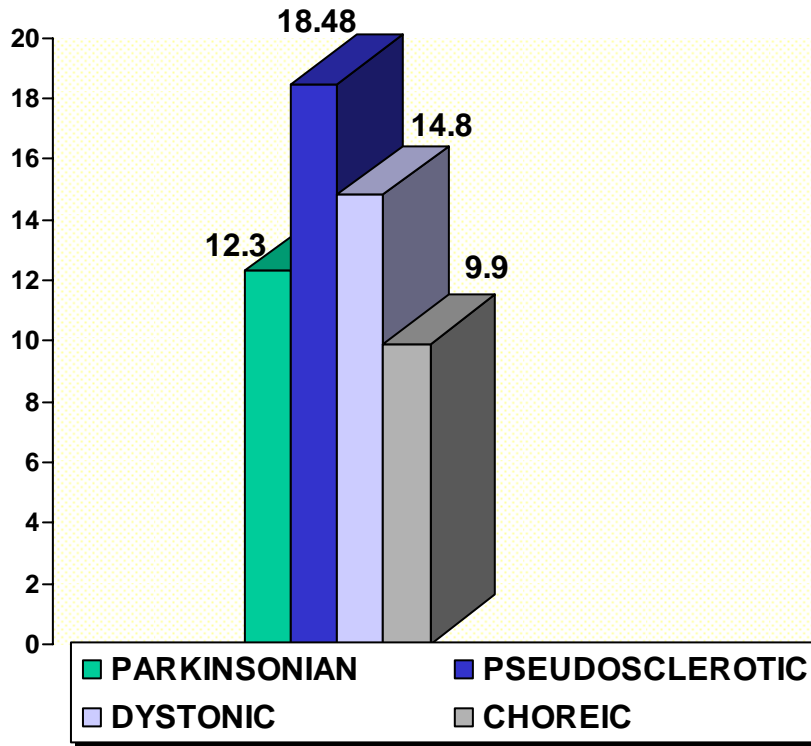
## PATTERN OF PRESENTATION AND AGE



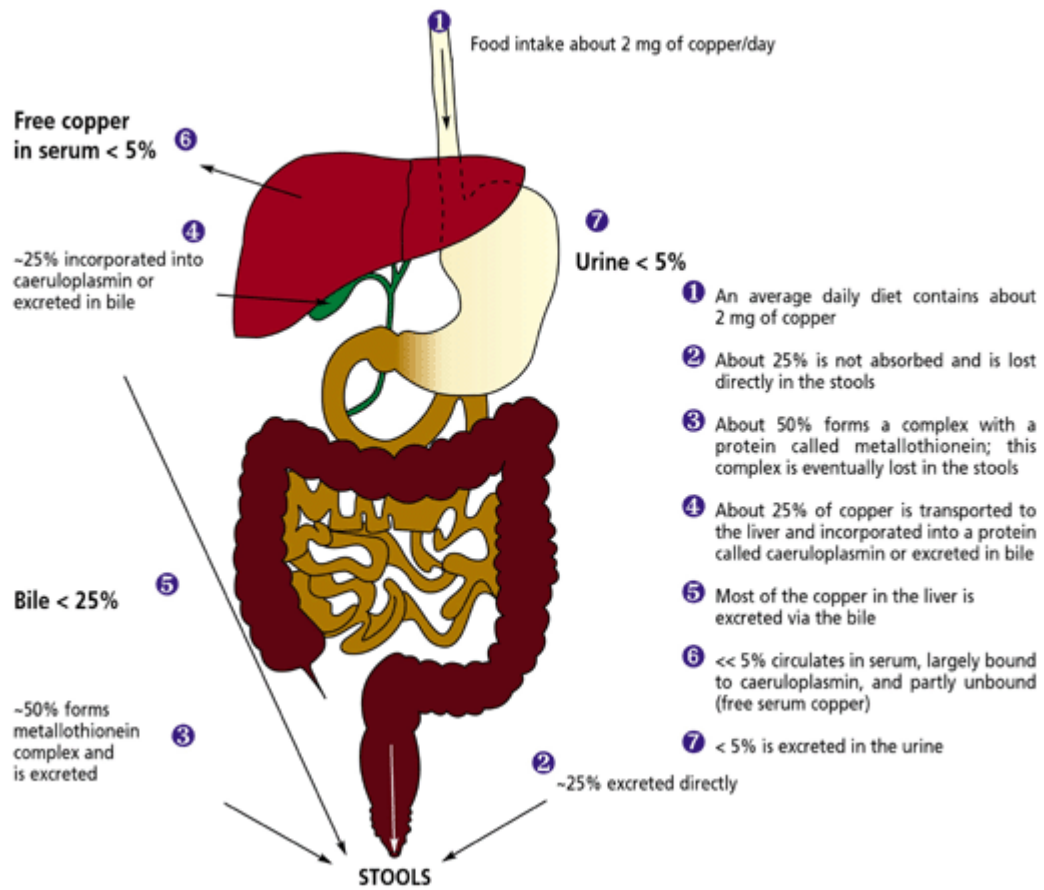
## PSYCHIATRIC & HEPATIC MANIFESTATION



## MEAN SERUM CERULOPLASMIN & PATTERN OF NEUROLOGICAL MANIFESTATION

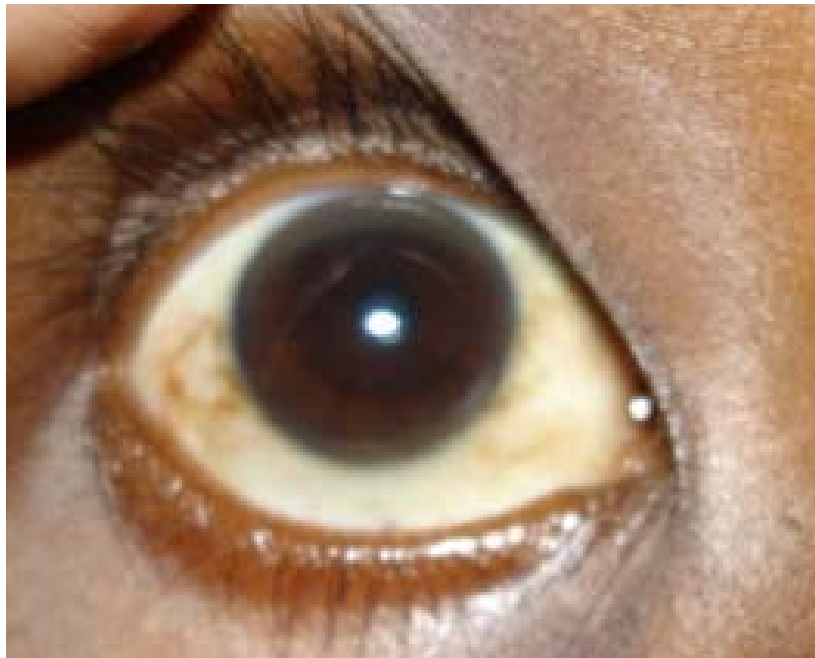

## NORMAL COPPER METABOLISM

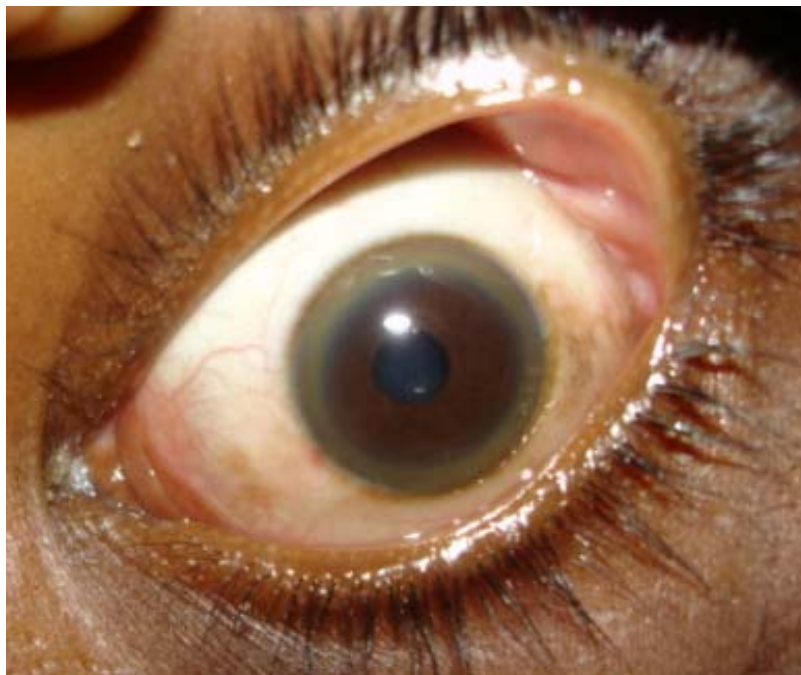




**EARLY KAYSER-FLEISCHER RING**



**COMPLETELY FORMED KF RING**



# CLINICAL MANIFESTATIONS IN WILSON DISEASE

