

**EVALUATION OF CARDIOVASCULAR CHANGES
IN CHRONIC OBSTRUCTIVE PULMONARY
DISEASE AND ITS CORRELATION WITH THE
DISEASE SEVERITY**

Dissertation Submitted to the

TamilNadu Dr.M.G.R. Medical University

In Partial Fulfillment

of the requirements for the degree of Director of Medicine

in

Tuberculosis and Respiratory Medicine

Branch – XVII

INSTITUTE OF THORACIC MEDICINE

Madras Medical College &

Rajiv Gandhi Government General Hospital



The Tamil Nadu Dr. M.G.R. Medical University

Chennai – 600032.

APRIL 2013

BONAFIDE CERTIFICATE


Certified that this dissertation is the bonafide work of
Dr.R.HARIPRASAD on “**EVALUATION OF
CARDIOVASCULAR CHANGES IN CHRONIC
OBSTRUCTIVE PULMONARY DISEASE AND ITS
CORRELATION WITH THE DISEASE SEVERITY**” during his
MD (TUBERCULOSIS AND RESPIRATORY MEDICINE)
course from April 2010 to April 2013 at the **INSTITUTE OF
THORACIC MEDICINE AND RAJIV GANDHI GOVERNMENT
GENERAL HOSPITAL-MADRAS MEDICAL COLLEGE,
CHENNAI.**

Prof.Dr.N.MEENAKSHI,M.D (TB&RD),D.T.C.D.,
Director and Head of the department,
Institute of thoracic medicine and
Rajiv Gandhi Government General Hospital,
Madras Medical College, Chennai

Prof.Dr.V KANAGASABAI, M.D.,
DEAN
Madras Medical College
Chennai-600 003

**MADRAS MEDICAL COLLEGE & RAJIV GANDHI
GOVERNMENT GENERAL HOSPITAL**

Chennai-600 003



DECLARATION BY THE SCHOLAR

I hereby declare that the dissertation entitled **“EVALUATION OF CARDIOVASCULAR CHANGES IN CHRONIC OBSTRUCTIVE PULMONARY DISEASE AND ITS CORRELATION WITH THE DISEASE SEVERITY”** submitted for the degree of Doctor of Medicine in M.D, degree examination Branch XVII TUBERCULOSIS & RESPITORY MEDICINE is my original work and the dissertation has not formed the basis for the award of any degree, diploma, associate ship, fellowship or similar other titles. It had not been submitted to any other university or institution for the award of any degree or diploma.

Place: Chennai

Signature of the scholar

Date:

Name: **Dr.R.Hariprasad**

ACKNOWLEDGEMENT

I would like to thank **Prof.Dr.V.Kanagasabai, M.D.**, Dean, Madras Medical College & Rajiv Gandhi Government General Hospital for giving me permission to conduct the study in this institution.

I am deeply indebted to my respected madam **Prof.Dr.N.Meenakshi,M.D (TB&RD),.D.T.C.D.**, Director and Head of the department, Institute of thoracic medicine and Rajiv Gandhi Government General Hospital, Madras Medical College, Chennai for her guidance and constant inspiration throughout my dissertation work. Words are sparse to express my gratitude to her for sparing her precious time and energy in trying to bring out the best in me.

I would like to express my sincere thanks and heartfelt gratitude to **Prof.Dr.D.Ranganathan M.D (TB&RD); D.T.C.D** Professor, Madras Medical College & Rajiv Gandhi Government General Hospital for the constant encouragement, valuable guidance and relentless support given by him throughout my post graduate course.

I would like to thank **Prof.Dr.A.Chitra kumar M.D (TB&RD); D.C.H.** Associate Professor, Madras Medical College & Rajiv Gandhi Government General Hospital, for his guidance

throughout the study and his immense support in bringing the study in good shape and knowledge.

I would like to specially thank **Dr.G.Gnanavel M.D;D.M,** Senior Assistant Professor, Department of cardiology, Madras Medical College & Rajiv Gandhi Government General Hospital, for his kind support in doing this study.

I would like to specially thank **Dr.D.NancyGlory,** Assistant professor, for enduring the pain of clearing my doubts in the thesis.

I am bound by ties of gratitude to Assistant professors **Dr.V.Sundar, Dr.Vijayusharaj, Dr.G.S.Vijayachandar, Dr.K.Veena, Dr.A.Sundararajaperumal, Dr.V.Vinodkumar, Dr.K.Thiruppathi, Dr.A.Maheshkumar, Dr.NancyGlory, Dr.T.Gunasekaran, Dr.C.Ammaiyapan palaniswamy, Dr.P.Rajeswari, Dr.V.Dheebha.**

I would be failing miserably in my duty if I don't place my sincere thanks to those who were the subjects of my study.

CONTENTS

| Sl. No. | Title | Page No. |
|----------------|-----------------------|-----------------|
| 1 | INTRODUCTION | 1 |
| 2 | AIM | 3 |
| 3 | REVIEW OF LITERATURE | 4 |
| 4 | MATERIALS AND METHODS | 45 |
| 5 | RESULTS | 58 |
| 6 | DISCUSSION | 71 |
| 7 | CONCLUSION | 75 |
| 8 | BIBLIOGRAPHY | |
| 9 | ANNEXURE | |

INTRODUCTION

Chronic Obstructive Pulmonary Disease (COPD) has considerable effects on cardiac function, including those of the right ventricle, left ventricle and pulmonary blood vessels.

Chronic Obstructive Pulmonary Disease (COPD), a common preventable and treatable disease is characterised by persistent air flow limitation that is usually progressive and associated with an enhanced chronic inflammatory response in the airways and lungs to noxious particles or gases. Exacerbations and comorbidities contribute to the overall severity in the individual patients.

COPD is one of the leading causes of morbidity and mortality worldwide and results in an economic and social burden. The global burden of disease study projected that COPD, which ranked sixth as a cause of death in 1990 will become the third leading cause of death worldwide by 2020. Many patients with COPD have comorbidities that have a major impact on quality of life and survival.

Airflow limitation and particularly hyperinflation affect cardiac function and gas exchange. Pulmonary hypertension may develop late in the course of COPD and is mainly due to hypoxic vasoconstriction

of small pulmonary arteries, eventually resulting in structural changes that include intimal hyperplasia and later smooth muscle hypertrophy/hyperplasia. The loss of pulmonary capillary bed in emphysema may also contribute to increased pressure in the pulmonary circulation. Progressive pulmonary hypertension may lead to right ventricular hypertrophy and eventually to right sided cardiac failure.

Progressive impairment of left ventricular diastolic function correlates with the severity of pulmonary Hypertension. It is likely that this results in large part from bulging of the inter ventricular septum from the hypertrophied and dilated right ventricle into the cavity of the left ventricle.

Most of the increased mortality associated with COPD is due to the cardiac involvement. Echocardiography provides a rapid, non-invasive, portable and accurate method to evaluate the cardiac changes. In South India, studies are not found easily related to cardiovascular abnormalities in mild to very severe COPD. This study is to find out the specific effects on the right ventricle, left ventricle and pulmonary blood vessels due to COPD and their relation to its severity.

AIM

1. To assess the cardiovascular changes secondary to COPD by echocardiography.
2. To find out the correlation between the cardiovascular changes and the severity of COPD

REVIEW OF LITERATURE

Definition of COPD as per Gold Report 2011:

“Chronic Obstructive Pulmonary Disease (COPD), a common preventable and treatable disease, is characterized by persistent air flow treatable disease, is characterized by persistent airflow limitation that is usually progressive and associated with an enhanced chronic inflammatory response in the airways and the lung to noxious particles and gases. Exacerbations and co-morbidities contribute to the overall severity in individual patients”.

Natural History

Factors contributing to the history of COPD include embryologic events such as intrauterine lung development, childhood and adolescent lung growth and adult lung exposures. Hence the natural history of COPD extends over the entire life span of an individual. A longitudinal study by Fletcher and colleagues for 8 years on natural history of COPD explains several key clinical issues. This study commonly called a “Fletcher-Peto curve,” plots FEV₁ versus age. But, this study was limited by the fact that it did not consider the non-smokers with COPD and the extra pulmonary effects of COPD.

Several ongoing longitudinal studies on COPD patients over time help to define the “Fletcher-Peto curve” by tracking other features of the COPD, effects outside the lung and for exposures other than cigarette smoking. (7)

Over a life time of 50 years a normal individual can lose 1 L of FEV₁, declining at an average of 20 mL/yr, but this decline accelerates with increasing age.

Cigarette Smoking

Cigarette Smoking impacts natural history of COPD in several ways. Smoking reduces maximally attained lung function, “plateau phase” is reduced in duration and may be absent and the rate at which lung function declines is probably increased. As a result an average smoker loses about 2 L of FEV₁ over a period of 50 years with an average decline of about 40 mL/yr. This decline in lung function may not be continuous. In some cases the decline may be stepwise where the individual’s lung function was acutely impacted by exacerbations.

In some individuals decline in lung function may be rapid. Individuals with a low FEV₁ will have a more rapid decline of FEV₁ and have more chance of developing COPD when compared to

individuals with a more normal FEV₁, a prediction known as the “horse-racing effect” (according to which, at any point in a race, the horse in the lead was the fastest, will continue to be the fastest, and is more likely to win). (8). Cessation of smoking habit during adult years can slow the rate of decline among patients with mild COPD.

Early Disease

Treatment goals in COPD mainly focus on alleviation of symptoms. Because patients with early disease are often asymptomatic, the importance of identifying individuals with early disease usually was not recognized. However, individuals with mild COPD have increased mortality, which is mainly due to **acute cardiac events**. This is true for both smokers and non smokers. The relationship between cardiac events and mild COPD may be due to systemic inflammation. Identifying a group of individuals with increased cardiac risk, and identifying that they may need treatment by exercise training program, has potential clinical benefit.

Advancing Disease

As FEV₁ declines, risk for mortality increases. Cardiac events still remain a major cause of death, even in severe COPD, as the

severity of lung function compromise increases, the relative incidence of death due to respiratory causes, increases. During exacerbations, individuals are at particular risk for death.

Mortality is also increased in those who have recovered from an exacerbation. In the SUPPORT (Study to Understand Prognoses and Preferences for Outcomes and Risks of Treatments) trial, the 2-year mortality rate for patients who are admitted for acute exacerbation of COPD with CO₂ retention was 49%. But, studies from several places have shown that some patients with more severe obstructive airway disease can survive for many years.

Thus, it is impossible to predict the course of an individual with certainty. Decisions relating giving care and end-of-life issues must be individualized and also must be based on all other factors in addition to lung function.

Pathophysiology of the Pulmonary Circulation

The normal pulmonary circulation, which is composed of good compliant pulmonary arteries and a rich capillary network with a large capability for recruitment, can accommodate high increases in blood flow (e.g., with left-to-right congenital intra cardiac shunts or during

exercise) without a significant rise in pulmonary arterial pressure. For example, this capillary reserve can be showed in a healthy person during cardiac catheterization by transient balloon occlusion of the right or left main pulmonary artery. Only a small rise or no rise in the resting pulmonary arterial pressure results, in spite of the fact that the entire cardiac output must go through the pulmonary circulation of only one lung. Thus, after recovering from pneumonectomy, patients usually have only slightly raised resting pulmonary arterial pressure.

Oxygen is the major mediator of pulmonary autoregulation, with vasoconstriction occurring in lung regions that are poorly oxygenated and pulmonary vasodilation occurring in regions where the partial pressure of oxygen is high and the blood flow is directed preferentially to the areas which are better oxygenated. Hypoxic pulmonary vasoconstriction is the major mechanism reasoned for the development of pulmonary hypertension in patients with lung disease; but, significant structural changes within the pulmonary vascular tree can also occur, which lead to the pulmonary capillary bed destruction and contribute to the development of pulmonary hypertension. Earlier in the natural history of lung diseases, the resting pressure in the pulmonary artery is normal usually, and because of the large capillary

reserve within the lung, it may not be readily detectable that significant capillary destruction occurs until almost half of the capillary bed is destroyed.

The pathophysiology of pulmonary hypertension associated with severe respiratory diseases is generally distinct from that of the pulmonary arterial hypertensive disorders, though they share some similar mechanistic pathways. The vascular remodelling process in pulmonary arterial hypertension and interstitial lung disease involve changes in all three portions of the vessel wall: the adventitia, media, and intima. But so, unlike the pulmonary arterial hypertensive disorders, in which marked intimal proliferation adventitial extracellular matrix and collagen deposition, and plexigenic lesions are seen, such severe findings are not usually present in patients with pulmonary hypertension associated with chronic restrictive or obstructive lung disorders.

Hypoxic Pulmonary Vasoconstriction

Many stimuli may result in pre capillary pulmonary vasoconstriction with resultant pulmonary hypertension. Out of these, the most important and the most potent, alveolar hypoxia may be

present under many circumstances. Pulmonary vasoconstriction may occur in perfectly healthy lungs. The pulmonary hypertension observed in persons living at high altitudes is caused by chronic hypoxemia although the presence of hyperventilation with resultant hypocapnia would be there. Like that, hypoventilation sufficient to produce alveolar hypoxia and hypercapnia, which can occur in morbidly obese patients, results in pulmonary hypertension that is secondary to pulmonary vasoconstriction.

Other causes of primary hypoventilation, whether it arises centrally or from respiratory muscle weakness, can also cause pulmonary hypertension secondary to inadequate alveolar ventilation. Hypercapnia, which is primarily mediated by an increase in hydrogen ion concentration, aggravates pulmonary vasoconstriction, enhancing the pressure increase expected from a reasonable degree of hypoxia alone.

The consequences of hypoxic pulmonary vasoconstriction in healthy residents who are residing at high altitude and in COPD patients with cor pulmonale residing at sea level may be compared. In the former case, a combination of alveolar hypoxia, hyperventilation, and hypocapnia is seen; in the latter case, hypoxia is usually

associated with hypoventilation and hypercapnia. Subjects residing at high altitudes would have a decreased plasma volume and increased hematocrit. Their stroke volume and cardiac output predisposed to be low. But in contrast, patients with COPD seem to have normal or increased blood volume, and their cardiac output is usually normal or even elevated. Healthy subjects, even who are residing at very high altitudes, usually do not develop right ventricular failure inspite of the presence of hypoxia and pulmonary artery hypertension, which suggests that acidemia and hypercapnia are vital contributing elements to impaired right ventricular function in COPD patients. Low alveolar pO₂ increases pulmonary arterial pressure in a hyperbolic dose-response curve, with which the pressure rises much more rapidly when the arterial PO₂ values fall below 75 mm Hg.

There is still a marked individual variability in the level of pulmonary arterial pressure at a given high altitude. Somewhat, this may be elucidated by differences in individual sensitivity to ventilatory drive which is produced by hypoxia, with some persons hyperventilating more than others. But, some of the variability depends on the difference in pulmonary vasoconstrictive response,

which apparently reflects an inherited difference in reactivity of pulmonary vasculature.

This viewpoint is sustained by observations of the high-altitude pulmonary hypertensive disease in cattle known as brisket disease. When cattle native to low altitudes are exposed to high altitudes for grazing, pulmonary arterial pressure climbs only moderately in some; but in others the pressure raises steeply. Cattle with either hyporesponsive or hyperresponsive pulmonary vascular reactivity transmits these phenotypes from parents to offspring as a genetic trait. Like as it has been suggested that genetic traits can play a role in the pulmonary pressor response to the hypoxia of high altitude, an explanation for the consideration that some patients with COPD develop pulmonary hypertension, but others do not, assigns this variability to inherited differences in pulmonary vascular reactivity or in the ventilatory sensitivity to hypoxia and carbon dioxide, or both (9).

Most of the patients who develop pulmonary hypertension at rest with COPD are both hypoxemic and hypercarbic. As assumed, the hypercarbic patients have a low ventilatory sensitivity to carbon dioxide, because, hypoxemic residents at high altitudes hyperventilate

and are hypocarbic. It is thus explained that some patients who have a normal ventilatory sensitivity to carbon dioxide and hypoxia have a raised ventilatory effort in response to obstructive lung disease and so, normal blood gases would be maintained. In contrast, a patient who responds with a low ventilatory sensitivity don't compensate and therefore develops an insufficient ventilatory drive to escape airway resistance, finally causing hypercapnia, hypoxemia, and pulmonary vasoconstriction.

Apparently all COPD patients, whether characterized by the now obsolete terms "pink puffers" and "blue bloaters," have more drive to breathe when observed by the mouth occlusion pressure (P0.1) test. The clinical differences between the groups are now accepted to result from differences in the breathing pattern and, may be, in intrapulmonary gas exchange. However, generally the more abnormal the PO₂ and PCO₂ values in COPD patients, the more severe the pulmonary hypertension and polycythemia and more chance of cor pulmonale.

Pulmonary Vascular Remodelling

The presence of chronic hypoxemia and ventilatory inadequacy in patients with chronic respiratory diseases usually lead to pulmonary vascular remodelling, which is characterized by distal smooth muscle proliferation with neomuscularization of normally unmuscularized small pulmonary vessels, prominent medial smooth muscle hypertrophy, and mild intimal changes. Hypoxic vasoconstriction raise the pulmonary vascular resistance and pressure, shear force, and wall stress, and so, these mechanical forces lead to a cascade of mediators and cellular changes which contribute to the remodelling process.

COPD is the most common and frequently studied lung disease associated with pulmonary hypertension and cor pulmonale. Well known structural changes occur in the pulmonary circulation in COPD patients. The presence of hypoxemia and chronic ventilatory inadequacy is associated with hypoxic pulmonary vasoconstriction and early changes of intimal proliferation with medial hypertrophy in the small branches of the pulmonary arteries. Vascular smooth muscle cells are laid down transversely within the intima, and hypertrophy of these cells and smooth muscle cells within the media are seen.

Localized thrombosis in situ may occur, obliterating parts of the pulmonary vascular tree.

Progressive destruction of capillaries which course along alveoli which are being destroyed or coalescing into bullae diminishes further, the cross-sectional area of the pulmonary vascular tree. (10).The structural changes together with the vasoconstrictive effects result in a noted increase in pulmonary vascular resistance. The result is pulmonary arterial hypertension, which in itself can cause further structural damage to the smaller branches of the pulmonary circulation and present as a stimulus for the development of medial hypertrophy and dilation of the larger branches of the pulmonary artery. If these changes are longstanding, prominent atherosclerotic changes can be seen in the main pulmonary artery and its main branches.

Role of Inflammation

COPD is defined as an inflammatory airways disease and in both asymptomatic smokers and patients with COPD, the inflammatory reaction has been well characterised in central and peripheral airways, as well as in the alveolar spaces and septae. In

non-hypoxemic patients with mild to moderate COPD, Peinado and his colleagues found that the number of inflammatory cells, mainly T lymphocytes (CD8+) was increased in Pulmonary artery of COPD in comparison with non-smokers and smokers who have normal lung function (11,12). The intensity of the inflammatory infiltrate corresponds to both the endothelium-dependent relaxation and the intimal thickening and was also abnormal even in smokers with normal lung function. Thus, smoking-induced inflammatory changes are important. Studies done in murine model suggest the role of the proinflammatory cytokine, IL-6 in the pulmonary vascular remodelling. In patients having COPD and PH, IL-6 levels were reported to be raised in those with genotype IL-6 GG and 5-HTT LL additionally more likely to have pulmonary hypertension.

The association of pulmonary hypertension with interstitial lung disease (ILD) is less well characterized when compared with that of COPD; recent studies have led to a better understanding of the pathophysiologic mechanisms involved in the development of pulmonary hypertension in these patients. The most common ILDs associated with pulmonary hypertension include connective tissue

disease-related ILD, idiopathic pulmonary fibrosis, sarcoidosis and histiocytosis X.

The degree of pulmonary hypertension seen in COPD patients and cystic fibrosis is generally, reported to be mild or moderate, often paralleling the degree of hypoxemia. In a cohort study of 500 patients with COPD and cor pulmonale, Stevens and colleagues observed that only 6 patients had severe elevations of pulmonary arterial pressure, defined as mean pulmonary arterial pressure greater than 50 mm Hg, and that the increase in the severity of pulmonary arterial pressure did not seem to be related to the severity of underlying lung disease.

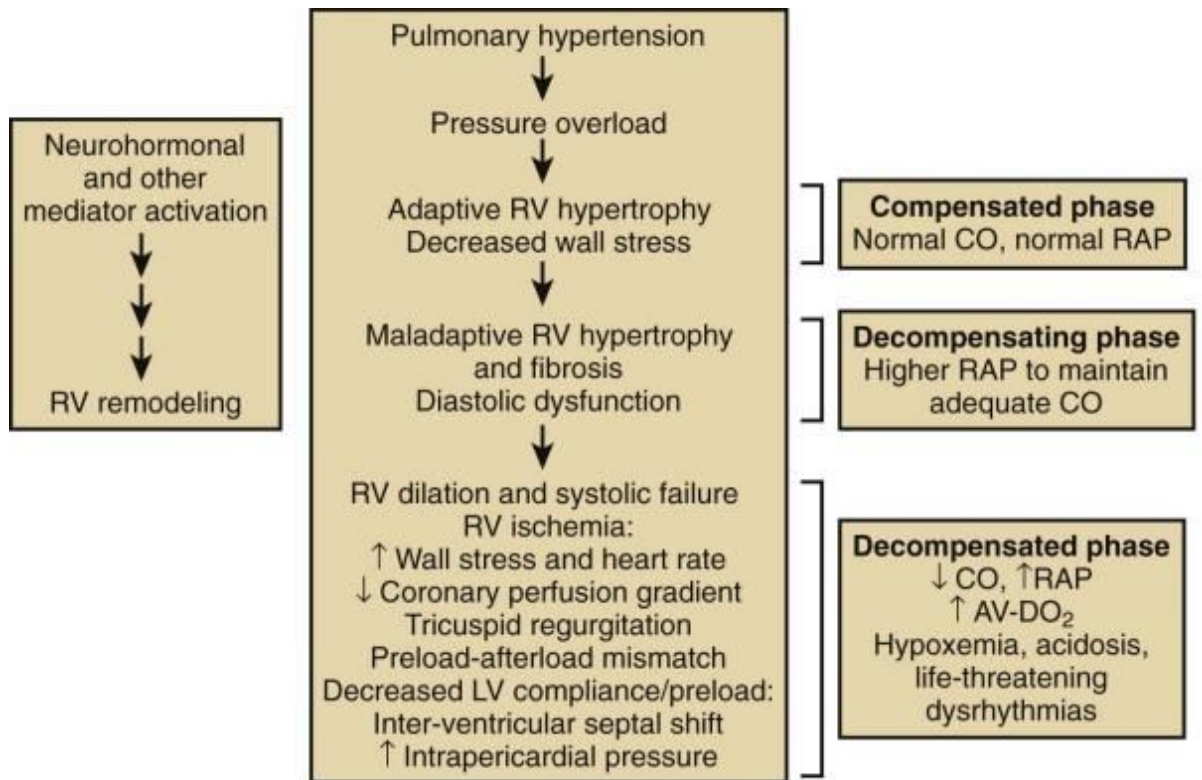
Henceforth, the direct correlation between arterial PO₂ and pulmonary arterial pressure is not good. In a study of 120 patients with severe emphysema assessed for entry into the National Emphysema Treatment Trial, multiple stepwise regression analysis showed that arterial PO₂ was not an independent predictor of mean pulmonary arterial pressure, and that the indices of emphysema severity and pulmonary arterial pressure did not correlate with each other.

Studies in patients with ILD revealed that the presence of pulmonary hypertension does not seem to correlate well with lung

volumes, whereas impairment of diffusion (reduced transfer factor for carbon monoxide) and the oxygen supplementation need were predictors of pulmonary hypertension.

Several studies recommend that vascular remodelling in patients with mild COPD without concomitant hypoxemia is a component of early-stage disease as witnessed by increased inflammatory cell density in the adventitia and increased intimal thickness of pulmonary arteries. Further, endothelial lesions have been observed to be present in cigarette smokers without chronic airflow obstruction.

A study investigated the development of pulmonary arterial hypertension in patients with moderate to severe airflow obstruction who neither had resting pulmonary arterial hypertension nor met criteria for long-term oxygen therapy ; 76 of 131 (58%) had exercise-induced pulmonary arterial hypertension at the initiation of the study. Five years later, 25% of the subjects had evolved resting pulmonary arterial hypertension, including 32% of subjects who had exercise-induced pulmonary arterial hypertension at baseline. These studies imply that factors other than hypoxemia alone are responsible for the development of pulmonary vasoconstriction and remodelling finally leading to pulmonary arterial hypertension.



AV-DO₂ = arteriovenous oxygen difference; CO = cardiac output; RAP = right atrial pressure; LV = left ventricular; RV = right ventricular

RIGHT VENTRICLE

The normal right ventricle is crescent shaped and the thickness of right ventricular wall is less than 0.6 cm. In men it weighs usually less than 65 g in, and in women it is less than 50 g.

The embryological development of right ventricle is from two components: the bulbus cordis and sinus venosus. Bulbus cordis forms the outflow tract, and the sinus venosus forms the inflow tract. Both

these are separated by a muscular ridge namely crista supraventricularis.

The right ventricle contracts sequentially from inflow to outflow in normal heart. This results in the effective emptying of its volume into the low-impedance pulmonary circulation. In accordance with venous return and Starling's law of the heart, the right ventricle plays an almost passive role in maintaining the cardiac output in absence of cardiac disease.

In congenital tricuspid atresia, Fontan procedure, an early surgical intervention involved right ventricular bypass through anastomosis between right atrium and the pulmonary artery. This resulted in the perfusion of pulmonary circulation from high central venous pressure. It is to be noted that a reduced survival rate is observed in those with right ventricular damage caused by elevated central venous pressures which was resulted from an inferior myocardial infarction.

It is difficult to measure accurately the right ventricular volume by radiographic or echocardiographic techniques due to its shape. In a series of 15 subjects without heart disease, right ventricular end-diastolic volume measured in supine position by a thermo dilution

technique, which should have overestimated volumes, averaged $103 \pm 24.4 \text{ ml/m}^2$. With passive assumption of an upright posture, right ventricular end-diastolic volume falls because of gravitational pooling of blood within the distensible venous tree. In a separate series of 8 subjects without heart disease, end-diastolic volume declined a mean of 16.3 ml/m^2 from a mean baseline of $98.1 \pm 23.3 \text{ ml/m}^2$.

The end-diastolic fibre stretch becomes less due to fall in right ventricular end-diastolic volume and this results in a decrease in stroke volume on upright position. Aortic baroreceptor stimulation at the same time reflexively raises heart rate by about 12 beats/min, and thus compensates for a stroke volume fall of about 13.3 ml/m^2 ; hence cardiac output is maintained at the same range as in a recumbent patient at rest.

A significant fall in stroke volume results due to acute increases in right ventricular afterload. Contrastly, the left ventricle accommodates an acute increase in after load with only little change in stroke volume. Uniform hypertrophy of the right ventricle results from chronic pulmonary hypertension along with increase in right ventricular work. Due to this, the right ventricular weight increases

as right ventricular wall myocytes thicken and the nuclei enlarges. Interstitial fibrosis occurs.

As the ventricular hypertrophy increases, the ability to expel the stroke output against high pulmonary vascular resistance increases and thus maintains the cardiac output. Pulmonary artery systolic pressure was observed to be significantly higher than the systemic pressure in patients having idiopathic pulmonary hypertension or severe mitral stenosis and pulmonary vascular disease.

The increase in right ventricular work along with pulmonary hypertension produces a significant increase in myocardial oxygen consumption of right ventricle. Right ventricular endocardial coronary perfusion is decreased due to wall thickening. End-diastolic pressure increases due to increasing right ventricular stiffness during diastole, and thus compromising endocardial coronary perfusion. These factors produce an imbalance between right ventricular myocardial oxygen demand and supply.

In studies based on end-diastolic pressure-volume relationship, in the presence of pulmonary hypertension, COPD patients had well-preserved right ventricular contractility. Presence of acidemia or infection precipitates right ventricular failure. The right ventricle is

unable to increase its work and the end-diastolic pressure increases in patients with alveolar hypoventilation in the presence of chronic hypercapnia with acidosis.

The myocardial contractility impairment in the presence of hypercapnia plays a vital role in causing decompensated pulmonary heart disease in case of acute increases in arterial PCO_2 during exacerbations of COPD and decreases in alveolar ventilation. Right ventricular and pulmonary artery systolic pressures show pulsus alternans which is similar to that of left ventricular failure.

The right ventricular volume overload along with ventricular dilation decreases the ejection fraction, because stroke volume is maintained close to the normal range in decompensated cor pulmonale. Right ventricular afterload increases on exercise in COPD patients, which increases right ventricular end-diastolic volume and ejection fraction decreases. This limits the normal exercising ability of such patients.

Right ventricular dilation and wall thinning increases right ventricular wall stress and that, along with increased heart rate, increases myocardial oxygen consumption. Increased myocardial oxygen consumption along with decreased myocardial perfusion

results in right ventricular ischemia and deterioration of right ventricular function.

As pulmonary pressure increases and the right ventricle dilates, severe tricuspid regurgitation occurs, thus limiting left ventricular filling. Further right ventricular dilation with intact pericardium compromises left ventricular filling. The interventricular septum shift towards the left ventricle and intrapericardial pressure raise reduces left ventricular distensibility and filling pressure, which represents the true preload.

Decreased left ventricular preload compromises the systemic cardiac output initially with exercise and eventually at rest. In patients with a patent foramen ovale, increasing right atrial pressures cause significant right-to-left atrial shunting and thus causes systemic oxygen desaturation and further worsens systemic oxygen delivery.

LEFT VENTRICLE

It was uncertain whether left ventricular failure occurs following right ventricular failure resulting from cor pulmonale. This was due to the fact that earlier studies of COPD patients with cor pulmonale included chiefly middle-aged or older

men with a smoking history and were likely to have associated coronary artery disease.

Left ventricular failure in some of these patients may have been resulted from coexisting coronary artery disease. Cardiac catheterization studies showed abnormal left ventricular end-diastolic pressure-volume relationships even with normal left ventricular performance. (13,14).

Echocardiographic studies revealed impairment of left ventricular diastolic function correlated with the severity of pulmonary hypertension. This results largely from the bulging of interventricular septum from the hypertrophied and dilated right ventricle into the left ventricular cavity, and ventricular interdependence exerted by pericardial constraint. (15).

Left ventricular diastolic geometry becomes distorted and there is alteration of filling characteristics such that a higher filling pressure is needed to produce the same end-diastolic fibre stretch that is needed for a given stroke work, according to Starling's law of the heart.

Pulmonary artery wedge pressure which is a reflection of left heart filling pressure gets distorted due to increased intra-alveolar

pressures, and large swings in intrathoracic pressure. This produces large fluctuations in wedge pressure tracings in COPD patients, and increases intrapericardial pressure. This is difficult when the patient receives positive end-expiratory pressure from a mechanical ventilator.

In severe right heart failure with increase in right atrial pressure, coronary sinus pressure increases. This results in an increase in left ventricular wall dimension and thus limiting distensibility of left ventricle. The mechanism causing reduced left ventricular preload acts independently of diastolic ventricular interaction caused by enlargement of right ventricle enlargement.

Recent studies have shown that left ventricular dysfunction is associated with increased arterial stiffness, independent of the mechanisms mentioned above. Left ventricular dysfunction alone has also been reported in some cases, might be because of these arterial stiffness measured by pulse wave velocity.

One study posted in Eur Respir Journal in the 2012 observed that cardiac changes are highly prevalent in patients with COPD during their first severe exacerbation. These patients did not have any

cardiac ailments before or any other risk factors for cardiovascular disease. (1)

SYMPTOMS AND SIGNS

Mild pulmonary hypertension reflected in small chronic elevations in right ventricular pressure usually causes minimal clinical, radiologic, or electrocardiographic findings. When moderate or severe pulmonary hypertension occurs (mean PPA > 40 mm Hg), symptoms are usually those associated with the underlying pulmonary disease.

Most common symptoms are dyspnea on exertion, chronic cough with mucoid productive sputum (mainly in the morning hours), inconstant degrees of wheezing, and occasional cyanosis; clubbing of the fingers can be present. Moderate or severe pulmonary hypertension by itself due to idiopathic reasons (e.g., in patients with idiopathic pulmonary arterial hypertension) can result in only minimal or nonspecific symptoms.

Along with exertional dyspnea and fatigue, some patients experience dizziness or even exertional syncope, which is due to the inability to increase cardiac output during exercise along with a

marked increase in pulmonary vascular resistance. Also, these patients can have chest pain because of right ventricular ischemia or main pulmonary artery stretching.

When resting PPA is sufficiently raised, patients may reach a point eventually at which the right ventricle won't meet the need for increased stroke work without a significant raise in right heart filling pressures. The resultant increase in central venous pressure is related with evolving symptoms of right-sided heart failure, such as, right upper quadrant discomfort, nocturia, peripheral edema and easy fatigability.

On examination, the patient is usually cyanotic and sitting upright with tachypnea, prominent accessory muscles of respiration, and arms extended holding the edges of the mattress. In COPD, pulsus paradoxus can be present. The chest would be hyperinflated. There can also be audible wheezing, mainly if the decompensation process has been relatively acute and combined with a superimposed respiratory infection.

Sinus tachycardia is usually present, atrial and ventricular arrhythmias are also present. Evidence of fluid retention can include

dependent edema and ascites. The liver is enlarged and tender to palpation, and would be pulsatile, reflecting the presence of severe tricuspid regurgitation. Likewise, the neck veins are distended and, when tricuspid insufficiency is present, would show a large *c-v* wave with rapid *y* descent; also, there would be a prominent *a* wave indicating the raised force of right atrial contraction.

On chest examination, there may be a left para sternal systolic lift, due to the over activity of the enlarged right ventricle, and a thud may be felt over the pulmonary area when the pulmonary valve closes.

The heart sounds are usually difficult to hear if the patient has underlying COPD. The pulmonic component of the second heart sound (S_2) would be accentuated and occurs earlier than usual, and so the normal splitting may be abolished and a single loud S_2 would be heard. Normally not heard at the apex, the pulmonic component of S_2 can now be clearly heard.

A high-pitched systolic ejection click can be heard in the second and third left intercostal spaces just next to the sternum. It is usually followed by a soft, localized systolic ejection murmur which is produced by ejection of the stroke volume into a dilated pulmonary

artery. An S_3 gallop arising from the right side of the heart can be heard in the fourth and fifth interspaces next to the left of the sternum or even next to the xiphoid process. A presystolic S_4 gallop can also be heard, reflecting the forcible contraction of the right atrium with expulsion of blood into the dilated and hypertrophied right ventricle.

Usually tricuspid regurgitation is present which results in a prominent blowing pansystolic murmur in the same location, which can increase somewhat with inspiration. When prominent pulmonary hypertension is present, a diastolic murmur of pulmonary incompetence can be heard; this murmur, which is known as Graham Steell's murmur, is a soft, blowing decrescendo diastolic murmur, mainly well localized to the second and third left intercostal spaces next to the sternum.

Chest Radiograph

The appearance of the chest radiograph depends mainly on the underlying cause for the presence of pulmonary hypertension. Usually, the main pulmonary artery segment is enlarged, together with large right and left descending pulmonary arteries. But, there is abrupt

tapering of the peripheral vessels, which results in disproportionately large central pulmonary arteries and attenuated distal vessels.

A right descending pulmonary artery with a diameter greater than 16 mm indicates pulmonary hypertension. Enlargement of the right ventricle, which can be observed on echocardiography, is usually not appreciated on the chest radiograph. If lung hyperinflation is present, the overall diameter of the cardiac silhouette would not be increased, although the heart may have a globular appearance. Usually some encroachment of the retrosternal space by an enlarged right ventricle can be seen in a lateral view.

Pleural effusions are not seen in patients presenting with pure cor pulmonale unless coexisting left ventricular dysfunction with failure are also present.. The visceral pleura plays little role in pleural fluid turnover in the normal lungs, but does help as an important escape route for excess interstitial fluid that accumulates in the lungs at the time of the evolution of cardiogenic pulmonary edema.

Pleural effusions may be expected in patients with chronic cor pulmonale and elevated right heart filling pressures, as they have increased systemic venous pressures, which must increase capillary

pressures within the parietal pleura. Increased transudation of fluid into the parietal pleural interstitium and then into the pleural space can be expected.

Failure to find pleural effusions under these circumstances reflects the capacity of the parietal lymphatics to significantly increase their fluid removal capacity, by almost 20-fold. These mechanisms would appear to be aided by the findings of a prospective study of 37 patients who were admitted for congestive heart failure in whom the presence of pleural effusions matched with the values of pulmonary artery wedge pressure but not with that of the right atrial pressure.

In another retrospective study of 18 patients with long-term pulmonary or right atrial hypertension or both, but with normal pulmonary artery wedge pressures, no pleural effusions were seen. But, patients have been observed with chronic cor pulmonale and acute exacerbation of cardiac decompensation which results from a superimposed respiratory infection who showed transient small pleural effusions during the acute episode.

Electrocardiogram

The electrocardiogram can be helpful in establishing the presence of chronic cor pulmonale. Characteristically, the P wave have a “p pulmonale” pattern with right-axis deviation which results in an increase in its amplitude in leads II, III, and aVF to more than 2.5 mm. The P wave can also be tall in the right precordial leads.

When the pulmonary arterial hypertension is moderate or severe, the more classic findings of right ventricular hypertrophy would dominate the electrocardiogram, which shows a prominent S wave in V₅ and V₆ with an R/S ratio of less than 1 and tall R waves in V₁ with an R/S ratio of more than 1. The electrocardiographic evidence of cor pulmonale in COPD patients is a poor prognostic sign.

Echocardiography

Echocardiography is the most widely used and accepted screening tool for diagnosing the presence of pulmonary hypertension and the right ventricular structure and function monitoring. An echocardiographic examination can help the clinician in ruling out various non pulmonary causes of secondary pulmonary hypertension,

like aortic or mitral valve disease, left ventricular failure from coronary disease or dilated congestive cardiomyopathy, and congenital heart disease with left-to-right shunt.

An estimation of the pulmonary artery systolic pressure can be evaluated in 36% to 86% of patients with pulmonary hypertension by the presence of tricuspid regurgitation and using continuous-wave Doppler to get the tricuspid regurgitant jet velocity.⁽¹⁶⁾

The pressure gradient across the tricuspid valve between the right atrium and ventricle is evaluated using the modified Bernoulli equation ($4v^2$), where v represents the tricuspid regurgitant jet velocity, and this value is then added to the right atrial pressure (estimated by the size and collapsibility of the inferior vena cava) to finally obtain an estimate of the right ventricular systolic pressure, which equals the pulmonary artery systolic pressure in the absence of pulmonary valve stenosis. Also, there is pulmonary valve insufficiency detectable by Doppler echocardiography in the presence of pulmonary hypertension, which allows an estimation of pulmonary artery diastolic pressure. The size of the right ventricle and the right atrium can be determined and the contractile state of the right ventricle can be assessed.

Flattening or leftward shift of the interventricular septum during systole indicates right ventricular pressure overload and interventricular septal flattening during diastole suggests right ventricular volume overload. If right heart filling pressure (which is equal to right atrial pressure) is increased, it is generally associated with the inferior vena cava dilatation, which won't collapse with respiratory manoeuvre such as sniffing.

Although right ventricular ejection fraction was the most commonly used index for assessing right ventricular function in the past, it is highly relied on loading conditions and cannot accurately reflect contractility. Echocardiography is less accurate than magnetic resonance imaging (MRI) and radionuclide angiography derived right ventricular ejection fraction methods.

In a study of 32 patients with advanced lung disease, Schenk and colleagues observed that, among the many echocardiographic parameters, right ventricular end-diastolic area and fractional area change from the apical four-chamber view matched best with MRI-derived right ventricular volume and ejection fraction, respectively.

Newer Doppler-derived indices of right ventricular function, right ventricular myocardial performance index (RVMPI) and the tricuspid annular plane excursion (TAPSE) have both been shown to have prognostic value in patients with idiopathic pulmonary arterial hypertension and other classes of pulmonary hypertension.

Three-dimensional echocardiography is a better technique that could lead to a more definite assessment of right ventricular volume and ejection fraction; but, difficulties in delineation of the anterior wall and infundibular plane still need to be overcome. The presence of lung hyperinflation impairs the transmission of ultrasound and may result in suboptimal transthoracic echocardiographic imaging.

The sensitivity and specificity of Doppler echocardiography to predict the presence of pulmonary hypertension would range from 0.79 to 1.0 and from 0.6 to 0.98, respectively, and the actual echo-Doppler-derived estimate of pulmonary artery systolic pressure can be imprecise when compared with right heart catheterization. (17).

If sufficient lung hyperinflation prevents adequate transthoracic examination, we can go for the transesophageal echocardiography (TEE) to rectify the problem. Usually patients in this stage are

intubated, and a transesophageal study probe may be slipped into the esophagus with ease.

It is of value to note that the estimation of pulmonary artery systolic pressure via echo-Doppler alone might not fully address pulmonary hypertension, and when therapies directed at the pulmonary vasculature are being planned, a diagnostic right heart catheterization must be considered.

Computed Tomography

Chest CT is usually used to visualize the pulmonary parenchyma in patients with respiratory disease. With this imaging modality, the size of the pulmonary artery would be measured, and in patients with moderate to severe pulmonary hypertension, an increased diameter of the pulmonary artery (>29 mm) may be measured.

But, in a study of 65 patients with advanced idiopathic pulmonary fibrosis, the measurement of main pulmonary artery diameter on high-resolution chest CT is unable to differentiate between those who did or did not have pulmonary hypertension as diagnosed with right heart catheterization. So, CT does not seem to be

a reliable modality to screen for pulmonary hypertension. But, dilated right heart chambers on contrast-enhanced CT imaging would suggest but not diagnostic of cor pulmonale in patients with severe parenchymal lung diseases.

Magnetic Resonance Imaging

MRI is the most accurate method for evaluating right ventricular volume and ejection fraction. Compared with the normal left ventricular volume, the right ventricular volume is larger and the ejection fraction is lower.

Phase-contrast MRI has the capability to accurately calculate flow characteristics, including valvular regurgitant fraction, cardiac output, and shunt fraction. Because of its capability to penetrate diseased lungs and its high temporal resolution, the image quality of MRI to view cardiac structures is superior to that of echocardiography, mainly in patients with advanced lung disease.

Although relatively long image acquisition time, high cost, and lack of widespread availability limit its use when compared with echocardiography, cardiac MRI is being used increasingly as a standard tool for the evaluation of right ventricular structure and

function in pulmonary arterial hypertension patients. Its application in patients with respiratory diseases and cor pulmonale has still to be evaluated. (18).

GENERAL ASPECTS OF DISEASE MANAGEMENT

The general measures to be considered in the patients with pulmonary hypertension and cor pulmonale are as follows. Treatment is also directed by the underlying diseases and the identification of any reversible causes on treatment.

Exercise and the Avoidance of Deconditioning

In variable of the cause, patients with pulmonary hypertension and cor pulmonale should maintain a active lifestyle. Regular, steady aerobic exercise should be advised and encouraged, and is usually best initiated under monitoring of a pulmonary or cardiac rehabilitation program.

Oxygen Therapy

Mainly in the management of patients with pulmonary hypertension, the avoidance of acute hypoxia is important, as hypoxic pulmonary vasoconstriction add up the burden on the right ventricle.

Measurements of arterial oxyhemoglobin saturation should be done at rest, during sleep, as well as during exertion. Levels of arterial oxygen saturation below 90 percent would require supplemental oxygen.

Maintaining the adequate oxygen saturation would be difficult in those patients with severe pulmonary hypertension and a patent foramen ovale allows right-to-left shunting. Supplemental oxygen has been shown to benefit patients with COPD.

Two separate trials, that of the National Heart, Lung and Blood Institute (Nocturnal Oxygen Therapy Trial) and of the Medical Research Council have shown that intellectual function and survival of the COPD patients are enhanced in chronically hypoxemic patients (arterial PO₂ under 55 mmHg) who are edematous, polycythemic (hematocrit greater than 55 percent), and show P pulmonale on the electrocardiogram. But, to be effective, oxygen must be delivered for at least 18 h per day—including at night, when arterial hypoxemia and respiratory acidosis intensify.

Oxygen corrects hypoxic pulmonary vasoconstriction, and so decreasing vascular resistance and improving the cardiac output,

decreases renal vasoconstriction improving the urinary sodium excretion, and corrects tissue hypoxia by improving oxygen delivery.

Supplemental oxygen should be administered to avoid arterial oxygen saturation below 90 percent. Supplemental oxygen is generally required for those with borderline levels of arterial oxygen saturation at sea level; increased oxygen flow rates are needed for those who use oxygen therapy for the activities of daily life.

Infection

Acute respiratory infection may induce right heart failure in patients with cor pulmonale. Acute exacerbations are a particular and usually recurrent problem for patients with pulmonary hypertension due to COPD. Worsened hypoxia and/or respiratory acidosis may aggravate pulmonary hypertension, and precipitate cardiac arrhythmias. Treatment for pulmonary infection must be given promptly and include oxygen and antibiotic therapies.

Airways obstruction can increase intrathoracic pressures and influence the venous return causing hepatic congestion and peripheral edema. Bronchodilators should be given to relieve airways obstruction and relieve hypoxia. Immunizations against influenza and

pneumococcal pneumonia are main preventive measures in all patients with pulmonary hypertension and cor pulmonale.

Fluid Management and Diuretics

To avoid fluid overload is main stay of the management of cor pulmonale of any cause. Patients must be trained regarding appropriate dietary habits and must restrict sodium intake in order to slow down fluid retention and the development of right heart failure.

Digitalis and Theophylline

The role of cardiac glycosides in treating right heart failure is unsettled. Nevertheless, digoxin is regularly used empirically, mainly when pulmonary hypertension is accompanied with atrial fibrillation.

Dysrhythmias

Dysrhythmias occur infrequently with cor pulmonale. Common precipitating mechanisms are anxiety and excessive use of bronchodilators. Sometimes, a bout of respiratory failure induces an episode of atrial tachycardia, a wandering pacemaker nodal rhythm, atrial flutter, or fibrillation. Stimuli that induce intense adrenergic

discharge raise the possibility of adverse effects from therapeutic agents, such as digitalis.

Arrhythmias in cor pulmonale are transient and disappear with discontinuation of the precipitant (e.g., an acute respiratory infection.). But, arrhythmias can be life threatening if they happen in the presence of arterial hypoxemia, disturbances in acid-base balance, and heightened sympathetic activity. The happening of such a life-threatening arrhythmia, usually ventricular fibrillation, is mainly during a bout of acute respiratory failure, with its accompanying disturbances in gas exchange and electrolyte imbalances.

Respiratory alkalosis, induced by mechanical hyperventilation and accompanied by hypokalemia, may also be a precipitating mechanism.

Pulmonary Vasodilators in non-PAH Forms of Pulmonary Hypertension

Many vasodilator drugs are under use in the attempt to decrease pulmonary vascular resistance and enhance right heart function in cor pulmonale. But, except for some patients with pulmonary arterial

hypertension, the use of vasodilators doesn't have been of benefit in corpulmonale.

Results in patients with corpulmonale due to COPD, for example, have been mixed and, successful only in the short term. For example, the use of calcium channel antagonists in COPD patients can worsen hypoxia and ventilation-perfusion mismatch. In addition, the depressant effects of these agents on cardiac inotropy can significantly worsen right heart function (19).

MATERIALS AND METHODS

STUDY CENTRE

Institute of thoracic medicine, Chetpet and Department of Thoracic Medicine, Rajiv Gandhi Government General Hospital, Chennai.

Department of Cardiology, Rajiv Gandhi Government General Hospital, Chennai.

STUDY DESIGN

Observational study.

STUDY PERIOD

From February 2012 to November 2012

INCLUSION CRITERIA

1. known case of COPD patients
2. newly diagnosed COPD patients
3. age group >30 years

EXCLUSION CRITERIA

1. PT Sequelae
2. known diabetics
3. known Hypertensives
4. h/o ischaemic cardiac disease and valvular heart disease.
5. known case of Bronchial asthma and Interstitial lung disease.

METHODOLOGY

About 51 COPD patients with unknown severity who have attended as out-patients in Institute of thoracic medicine, Chetpet and Department of thoracic medicine, Rajiv Gandhi Government general hospital, Chennai were subjected to following investigations. The study was done within a time period of ten months.

Written consent was obtained from the patients in their regional language, after explaining the details of the study. Complete history regarding the symptoms, past history, smoking history, occupational history and other associated illnesses were taken and noted in a proforma. Clinical examination of the patients had been done.

Smoking index were categorized in male patients as follows:

<150 - mild

150 - 300 - moderate

>300 - severe.


In the females, history regarding passive smoking and biomass fuel usage were obtained.

Patients were then subjected to routine blood investigations like complete blood count, renal function tests, liver function tests, routine blood sugar, blood pressure, ECG, Chest X ray PA and CT chest, wherever indicated.

The patients who met the inclusion and exclusion criteria are subjected to spirometry.

- Severity of COPD patients were assessed by SPIROMETRY as per GOLD guidelines

| Classification of Severity of Airflow Limitation in COPD (Based on Post-Bronchodilator FEV1) | | |
|---|-------------|----------------------------|
| In patients with FEV1/FVC < 0.70 | | |
| GOLD 1 | Mild | FEV1 ≥ 80% predicted |
| GOLD 2 | Moderate | 50% ≤ FEV1 < 80% predicted |
| GOLD 3 | Severe | 30% ≤ FEV1 < 50% predicted |
| GOLD 4 | Very Severe | FEV1 < 30 % predicted |



ECHOCARDIOGRAPHY:

Echocardiographic assessment of right ventricular and left ventricular function were done using

- Systolic pulmonary arterial pressure
- Tricuspid annular plane systolic excursion(TAPSE)
- LV Ejection fraction
- RV & LV diastolic function
- Tei index
- Respiratory variation (5,6)

The ECHOCARDIOGRAPHY was done to all the patients in the Department of Cardiology, Government General Hospital, Chennai and the reports were obtained in a regular format.

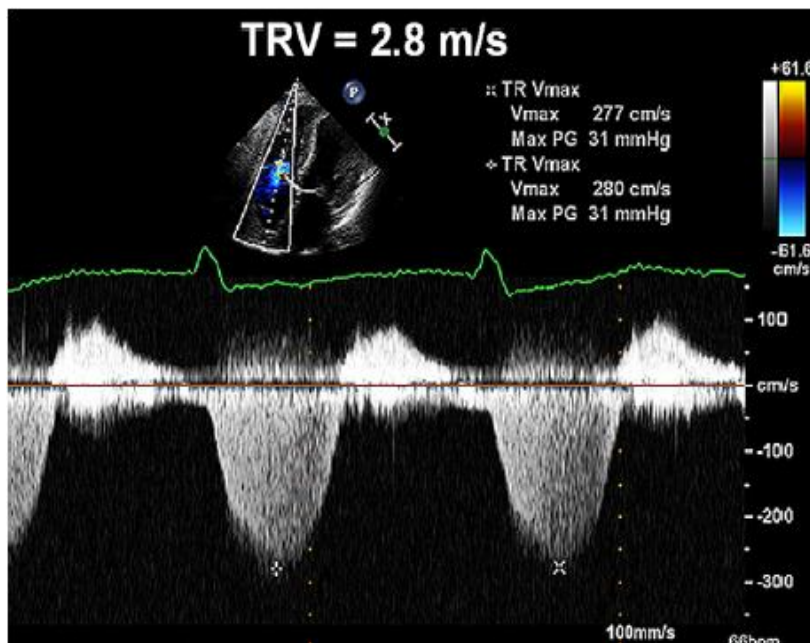
SYSTOLIC PULMONARY ARTERIAL PRESSURE (SPAP)

Pulmonary hypertension is defined as SPAP >30mmHg. It can be categorized as follows:

- Mild - 30 to 40mmHg
- Moderate - 40 to 60mmHg
- Severe - > 60mmHg

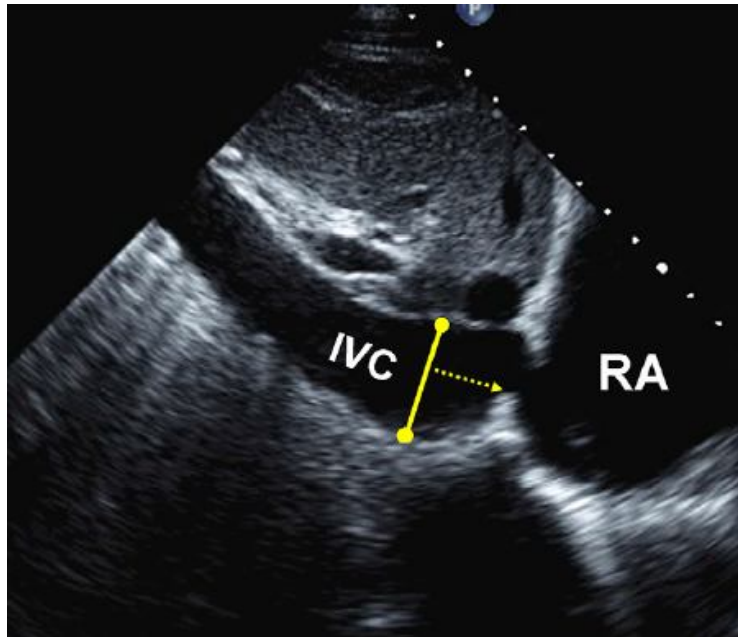
It is calculated by the formula,

$$\text{SPAP} = \text{TRPG} + \text{RA Pressure.}$$



DOPPLER ECHOCARDIOGRAPHIC determination of systolic pulmonary arterial pressure (SPAP). Spectral continuous –wave Doppler signal of tricuspid regurgitation signifying Right ventricular (RV)-Right atrial (RA) pressure gradient.

- **RA pressure:** RA pressure can be estimated by IVC diameter and the presence of inspiratory collapse. When RA pressure increases, it would be transmitted to IVC, which results in reduced collapse with inspiration and IVC dilation. Specific values of RA pressure should be used in the SPAP determination. IVC diameter of ≤ 2.1 cm which collapses $>50\%$ with a sniff indicates a normal RA pressure of 3 mm Hg (0-5 mmHg), but an IVC diameter >2.1 cm which collapses $<50\%$ with a sniff indicates a high RA pressure of 15 mm Hg (range of 10-20 mm Hg). In indeterminate cases, an intermediate value of 8 mmHg (range of 5-10 mmHg) can be used.



View of Inferior vena cava. The solid line which indicates the diameter measured perpendicular to the long axis of the IVC at end-expiration proximal to the ostium of the right atrium.

Table 3 Estimation of RA pressure on the basis of IVC diameter and collapse

| Variable | Normal (0-5 [3] mm Hg) | Intermediate (5-10 [8] mm Hg) | | High (15 mm Hg) |
|---|---|-------------------------------|---------|-----------------|
| IVC diameter | ≤2.1 cm | ≤2.1 cm | >2.1 cm | >2.1 cm |
| Collapse with sniff | >50% | <50% | >50% | <50% |
| Secondary indices of elevated RA pressure | <ul style="list-style-type: none"> • Restrictive filling • Tricuspid E/E' > 6 • Diastolic flow predominance in hepatic veins (systolic filling fraction < 55%) | | | |

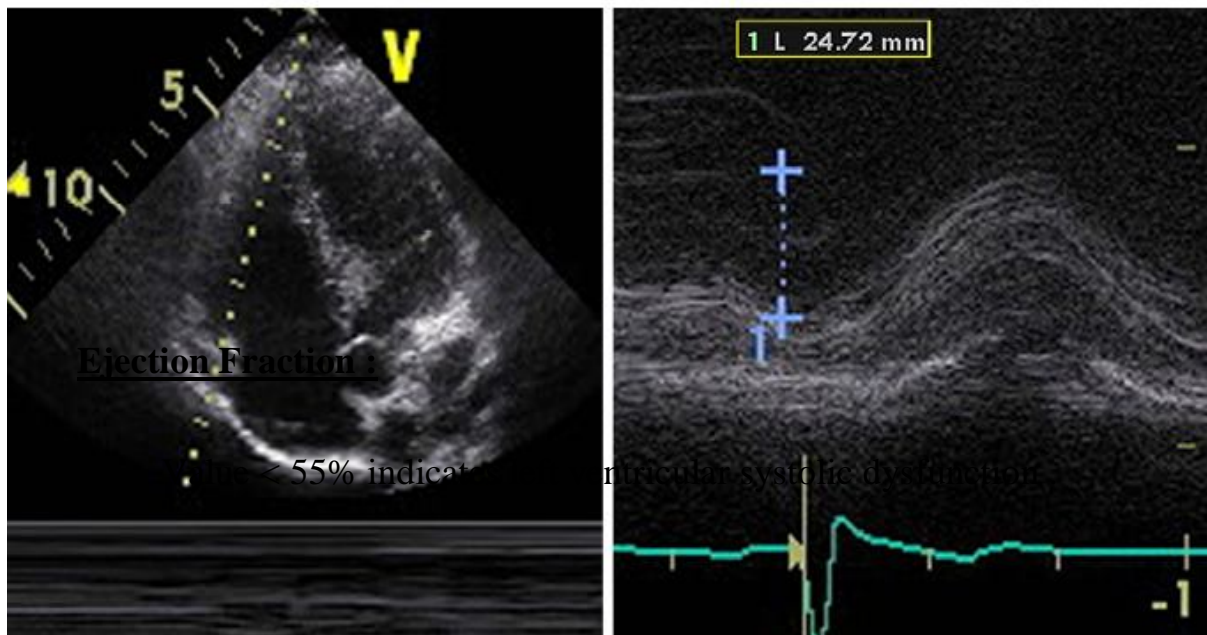
Ranges are provided for low and intermediate categories, but for simplicity, midrange values of 3 mm Hg for normal and 8 mm Hg for intermediate are suggested. Intermediate (8 mm Hg) RA pressures may be downgraded to normal (3 mm Hg) if no secondary indices of elevated RA pressure are present, upgraded to high if minimal collapse with sniff (<35%) and secondary indices of elevated RA pressure are present, or left at 8 mm Hg if uncertain.

IVC, Inferior vena cava; RA, right atrial.

TAPSE (TRICUSPID ANNULAR PLANE SYSTOLIC EXCURSION) :

TAPSE is a method which measures the distance of systolic excursion of the RV annular segment along its longitudinal plane, by a standard apical 4-chamber window. Its acquired by placing a M-mode cursor through the tricuspid annulus and then measuring the longitudinal motion of the annulus at the peak systole.

Value $< 1.6\text{cm}$ indicates Right ventricular Systolic dysfunction.



MEASUREMENT OF TRICUSPID ANNULAR PLANE SYSTOLIC EXCURSION (TAPSE)

RESPIRATORY VARIATION:

Respiratory variation is said to be significant when the difference in ventricular filling during inspiration and expiration is > 40% in right side and >25% in left side.

VENTRICULAR DIASTOLIC FUNCTION:

E/A Ratio:

Ratio of peak flow velocity across AV valve during early rapid filling wave (E) and during atrial contraction (A).

Normal value: Right - 0.8 - 2.1
 Left - age 41 to 60 → 0.78 - 1.78
 age > 60 → 0.6 - 1.32

E/E' Ratio :

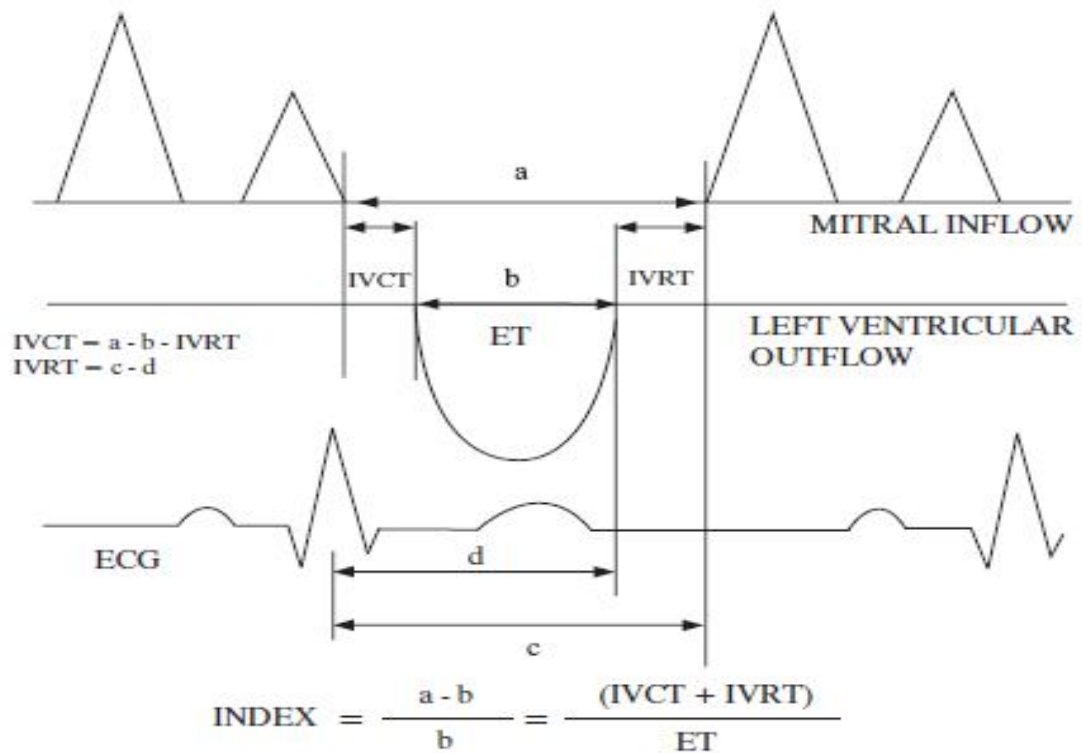
Normal value : Right - < 6
 Left - < 6.7

TEI INDEX :

Tei index is a global estimate of both systolic and diastolic functions of the ventricle.

The mean normal value of the Tei index is 0.28 for the right ventricle and 0.54 for the left ventricle.

CALCULATION OF TEI INDEX



The right sided MPI may be obtained by two methods: The tissue Doppler method and the pulsed Doppler method. In the pulsed Doppler method, all time intervals are evaluated from a single beat by pulsing the tricuspid annulus. In the pulsed Doppler method, ET is measured with pulsed Doppler of RV outflow (the time calculated from the onset to the cessation of flow) and the tricuspid closure-opening time is measured with either pulsed Doppler of the tricuspid inflow or continuous Doppler of the TR jet.

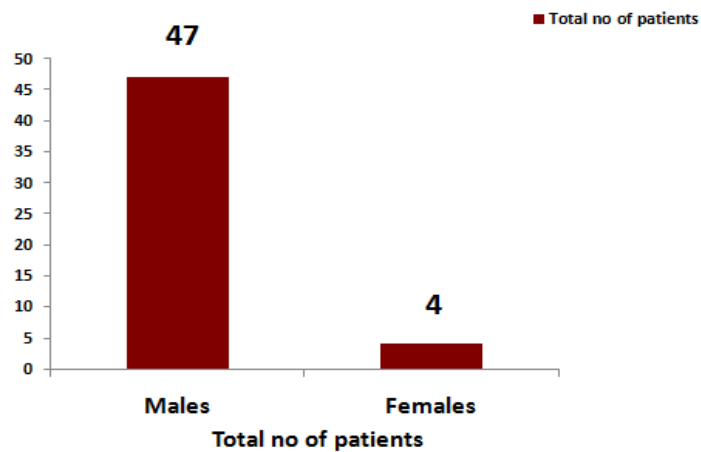
RESULTS

The results of the study are as follows:

Total No. of COPD patients enrolled in our study-51.

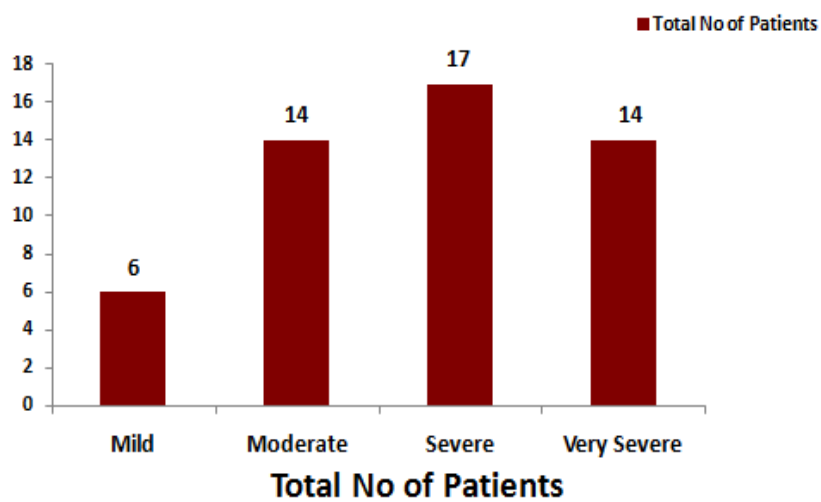
No. of Males and Females participated

| COPD Patients | Total no of patients |
|---------------|----------------------|
| Males | 47 |
| Females | 4 |



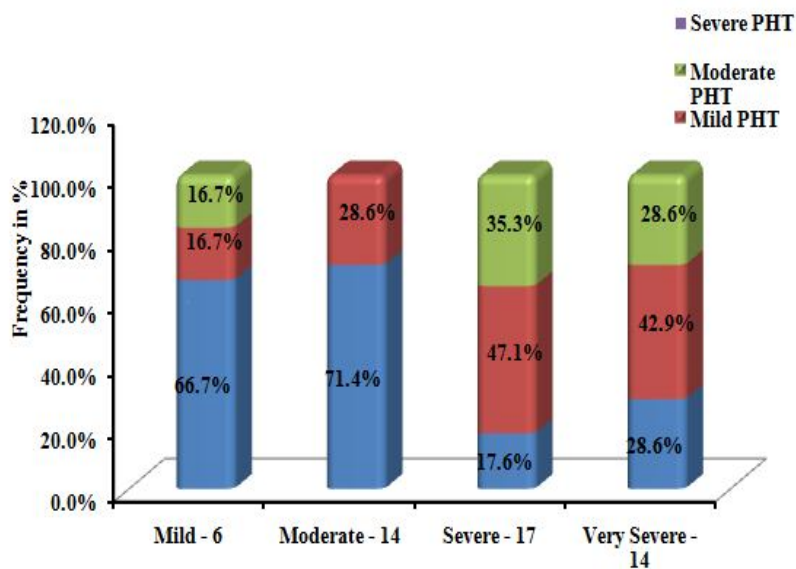
The patients are categorized according to the severity assessed by spirometry based on GOLD guidelines, as follows:

| COPD SEVERITY | Total No Of Patients |
|----------------------|-----------------------------|
| Mild | 6 |
| Moderate | 14 |
| Severe | 17 |
| Very severe | 14 |



MEASUREMENT OF PULMONARY HYPERTENSION BY CALCULATING SPAP AND ITS CORRELATION WITH COPD SEVERITY.

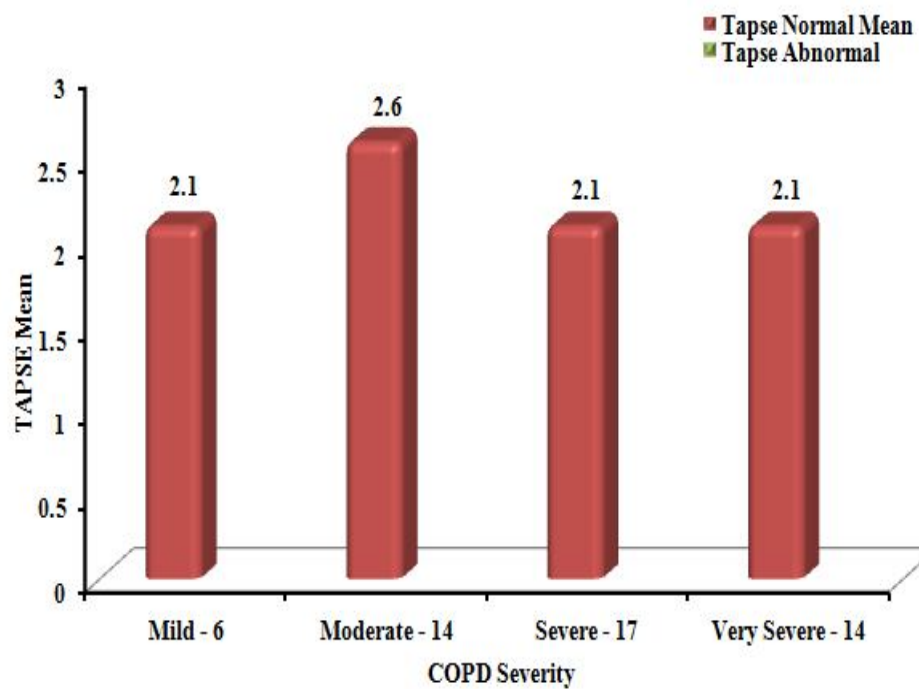
| COPD severity | PULMONARY HYPERTENSION | | | | Total |
|------------------|------------------------|------|----------|--------|-------|
| | Normal | Mild | Moderate | Severe | |
| Mild - 6 | 4 | 1 | 1 | | 6 |
| Moderate - 14 | 10 | 4 | | | 14 |
| Severe - 17 | 3 | 8 | 6 | | 17 |
| Very Severe - 14 | 4 | 6 | 4 | | 14 |
| Total | 21 | 19 | 11 | | 51 |



Pulmonary hypertension is present in 33.3% (2/6), 28.6% (4/14), 82.3% (14/17) and 71.4% (10/14) cases of mild, moderate, severe and very severe obstruction respectively.

RIGHT VENTRICULAR SYSTOLIC FUNCTION AS ASSESSED BY TAPSE.

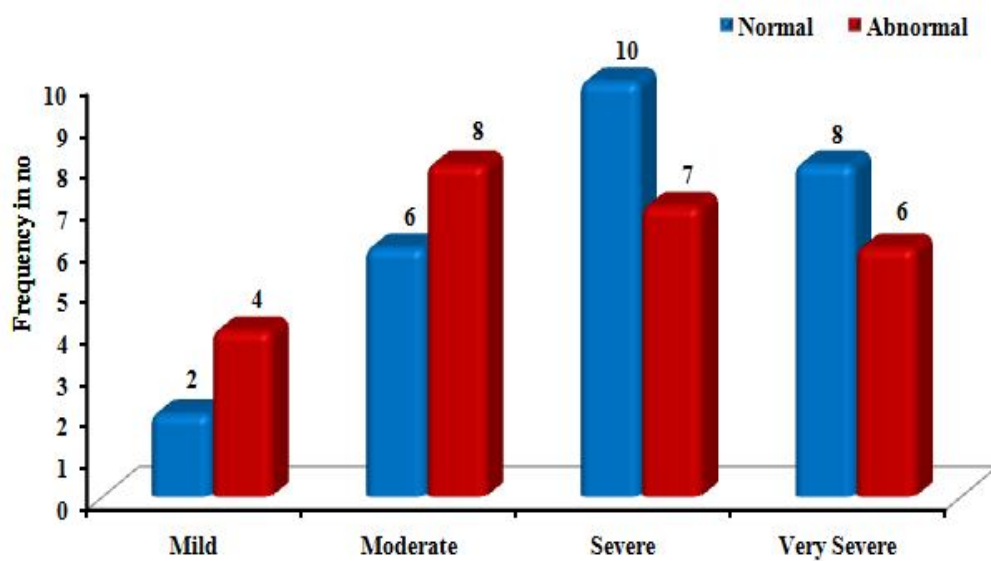
| COPD severity | TAPSE | | Total |
|------------------|-------------|----------|-------|
| | Normal Mean | Abnormal | |
| Mild - 6 | 2.1 | | 6 |
| Moderate - 14 | 2.6 | | 14 |
| Severe - 17 | 2.1 | | 17 |
| Very Severe - 14 | 2.1 | | 14 |



Normal TAPSE values are seen in all the patients invariable of the COPD severity.

**RIGHT VENTRICULAR DIASTOLIC FUNCTION AS
ASSESSED BY E/A AND E/E' RATIO AND ITS
CORRELATION WITH COPD SEVERITY**

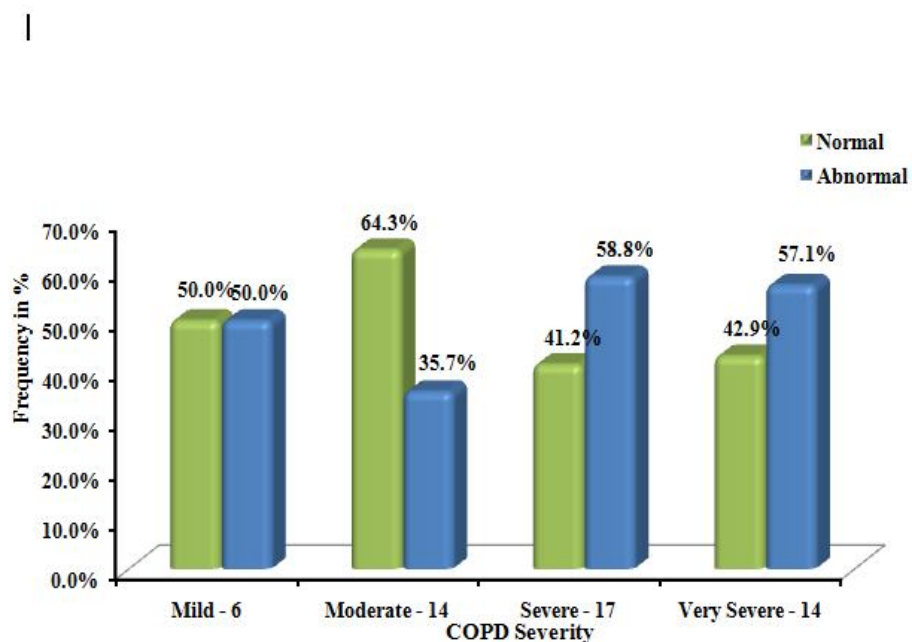
| COPD severity | Right Ventricular Diastolic Function | | Total |
|------------------|--------------------------------------|----------|-------|
| | Normal | Abnormal | |
| Mild - 6 | 2 | 4 | 6 |
| Moderate - 14 | 6 | 8 | 14 |
| Severe - 17 | 10 | 7 | 17 |
| Very Severe - 14 | 8 | 6 | 14 |



The right ventricular Diastolic dysfunction has no relation to the severity of COPD in this study.

THE RESPIRATORY VARIATION IN RIGHT VENTRICLE CORRELATED WITH COPD SEVERITY

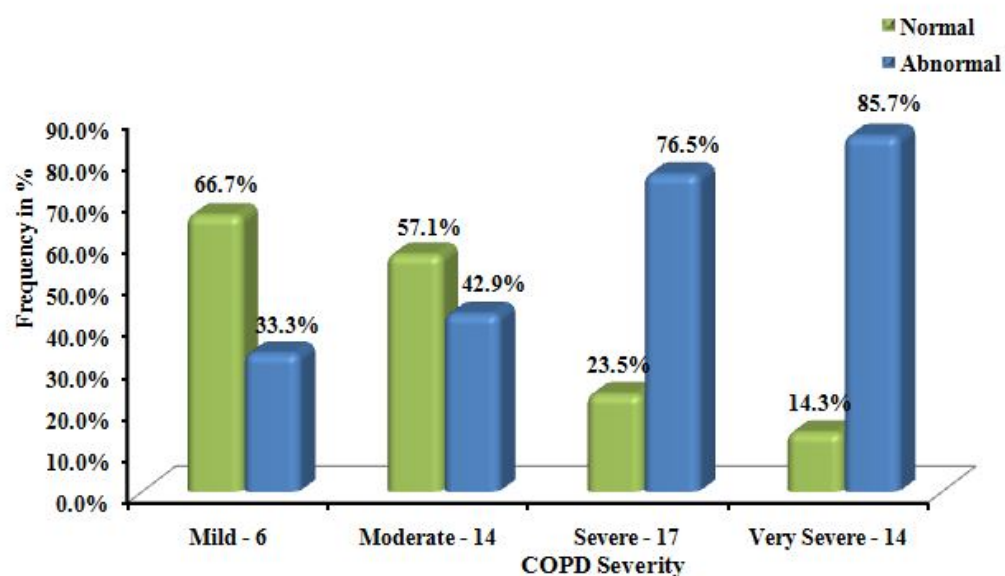
| COPD severity | Right Ventricular Respiratory variation | | Total |
|------------------|---|----------|-------|
| | Normal | Abnormal | |
| Mild - 6 | 3 | 3 | 6 |
| Moderate - 14 | 9 | 5 | 14 |
| Severe - 17 | 7 | 10 | 17 |
| Very Severe - 14 | 6 | 8 | 14 |



The abnormality in Right ventricular filling during respiratory variation increases, when the severity in COPD increases.

RIGHT VENTRICULAR GLOBAL FUNCTION MEASURED BY TEI INDEX COMPARED WITH COPD SEVERITY AS FOLLOWS:

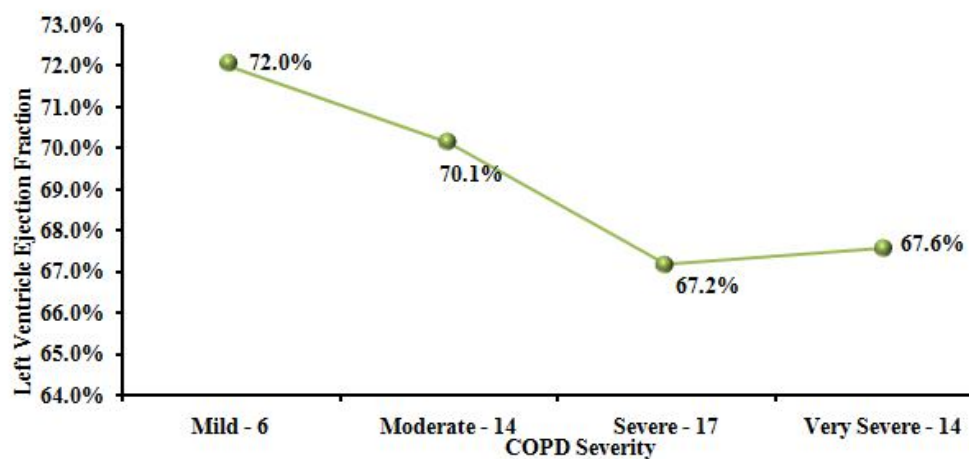
| COPD severity | Right Side TEI Index | | Total |
|------------------|----------------------|----------|-------|
| | Normal | Abnormal | |
| Mild - 6 | 4 | 2 | 6 |
| Moderate - 14 | 8 | 6 | 14 |
| Severe - 17 | 4 | 13 | 17 |
| Very Severe - 14 | 2 | 12 | 14 |



Right ventricular global dysfunction (using Tei index) are 33.3%,42.9%,76.5% and 85.7% in mild, moderate, severe and very severe obstruction respectively.

THE LEFT VENTRICULAR SYSTOLIC FUNCTION AS ASSESSED BY EJECTION FRACTION WHEN CORRELATED WITH COPD SEVERITY.

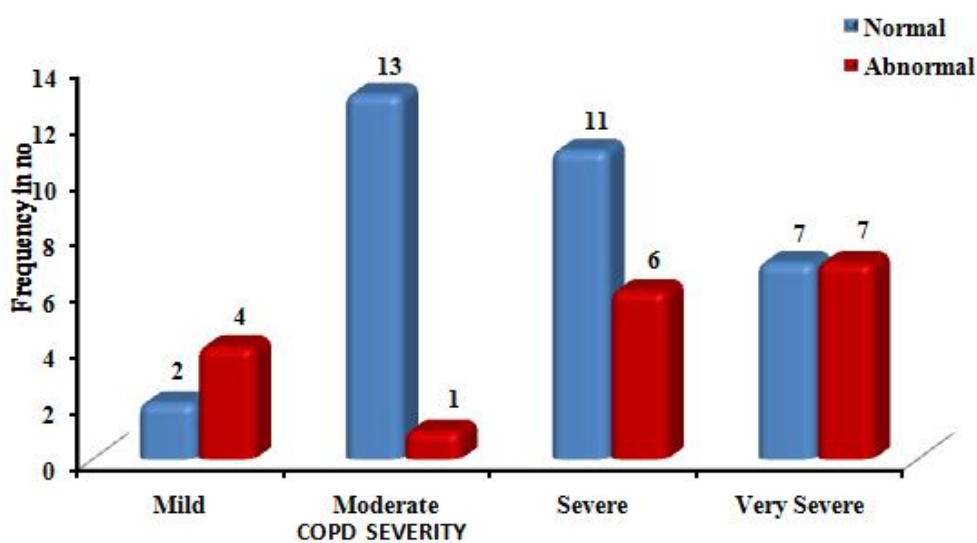
| COPD severity | Left systolic Ejection Fraction |
|------------------|---------------------------------|
| Mild - 6 | 72.0% |
| Moderate - 14 | 70.1% |
| Severe - 17 | 67.2% |
| Very Severe - 14 | 67.6% |



Although the mean value of the Ejection fraction decreases as the COPD severity increases from 72.0% to 67.6%, all the values comes within the normal range.

LEFT VENTRICULAR DIASTOLIC FUNCTION MEASURED BY E/A & E/E' RATIO WHEN COMPARED WITH COPD SEVERITY.

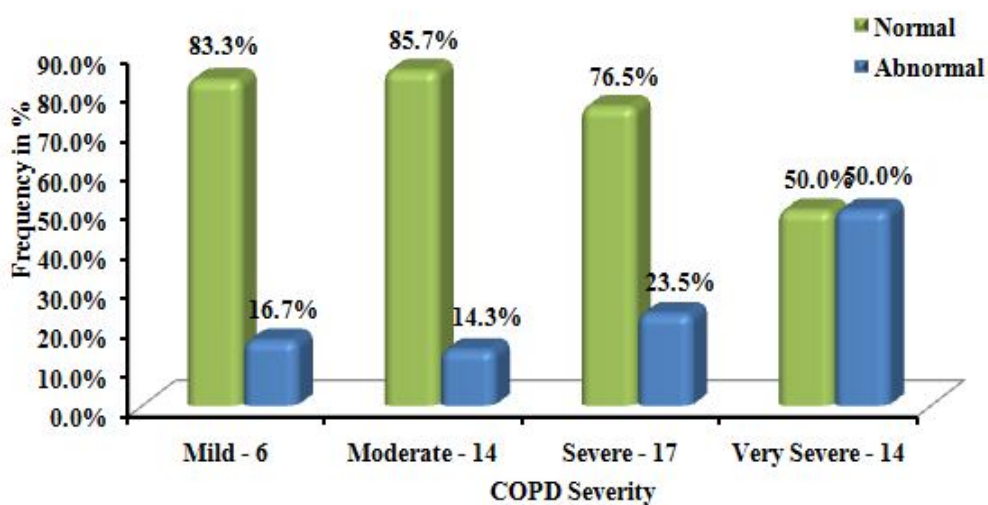
| COPD severity | Left Ventricular Diastolic Dysfunction | | Total |
|------------------|--|----------|-------|
| | Normal | Abnormal | |
| Mild - 6 | 2 | 4 | 6 |
| Moderate - 14 | 13 | 1 | 14 |
| Severe - 17 | 11 | 6 | 17 |
| Very Severe - 14 | 7 | 7 | 14 |



The left ventricular diastolic dysfunction have no correlation with the COPD disease severity.

THE CORRELATION OF LEFT VENTRICULAR FILLING ON RESPIRATORY VARIATION WITH COPD SEVERITY.

| COPD severity | Left Ventricular Respiratory variation | | Total |
|------------------|---|----------|-------|
| | | | |
| | Normal | Abnormal | |
| Mild - 6 | 5 | 1 | 6 |
| Moderate - 14 | 12 | 2 | 14 |
| Severe - 17 | 13 | 4 | 17 |
| Very Severe - 14 | 7 | 7 | 14 |

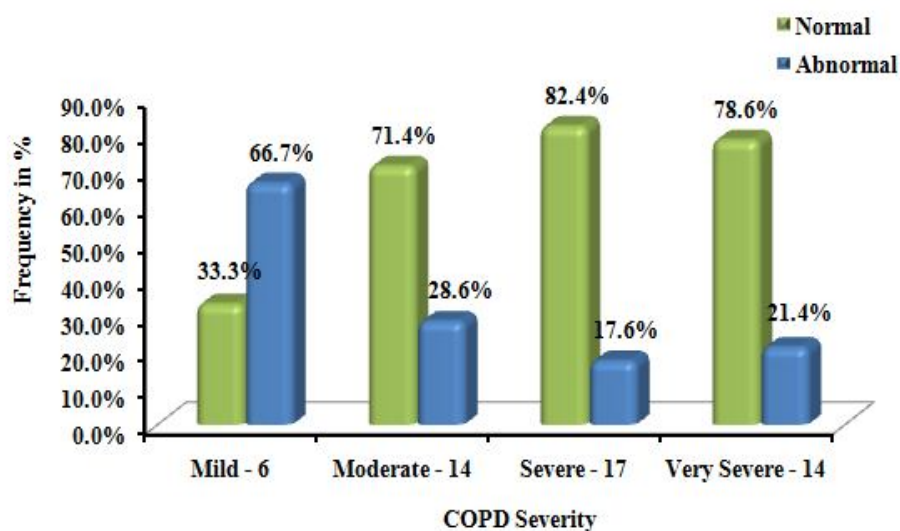


n

As the COPD severity increases, the abnormality in left ventricular filling on respiratory variation increases.

THE LEFT VENTRICULAR GLOBAL FUNCTION MEASURED BY TEI INDEX IN RELATION WITH THE COPD SEVERITY.

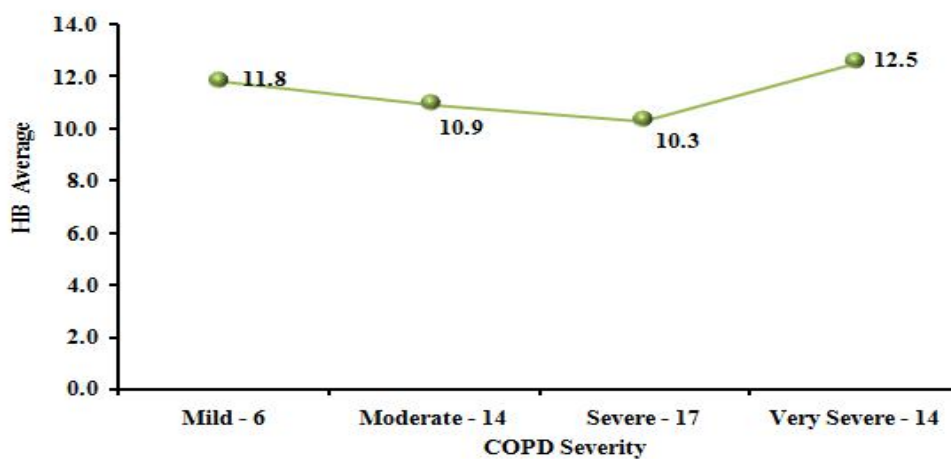
| COPD severity | Left Side TEI Index | |
|------------------|---------------------|----------|
| | Normal | Abnormal |
| Mild - 6 | 2 | 4 |
| Moderate - 14 | 10 | 4 |
| Severe - 17 | 14 | 3 |
| Very Severe - 14 | 11 | 3 |



The left ventricle global function does not correlate with COPD severity in this study.

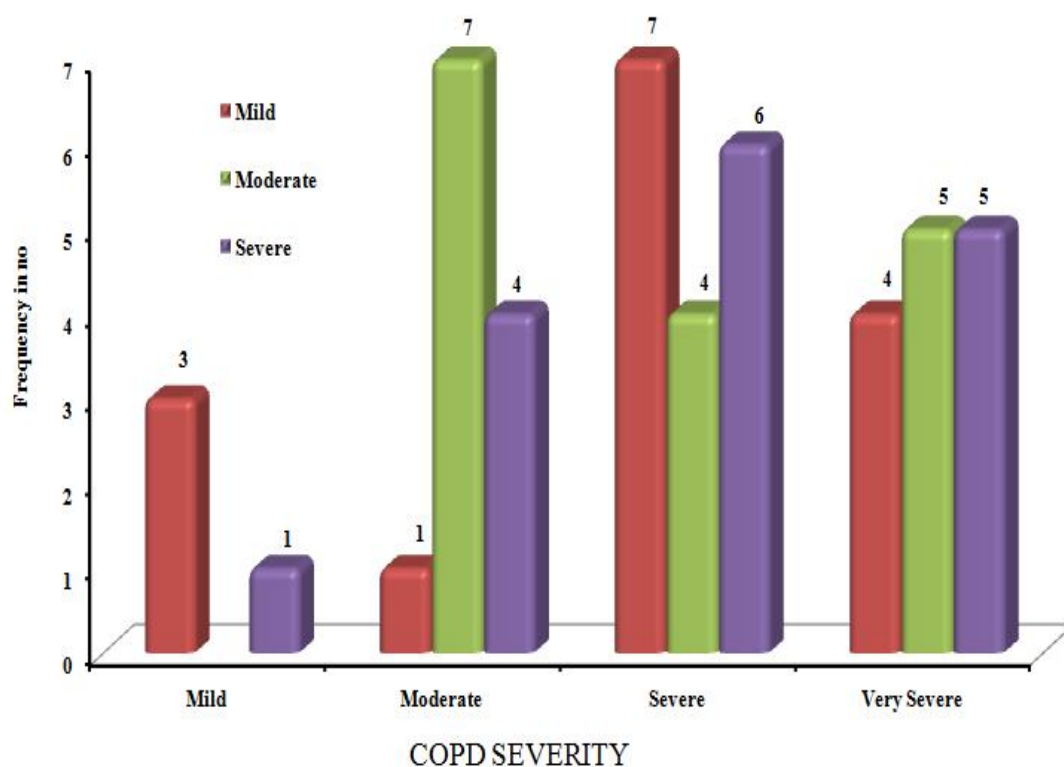
THE AVERAGE HAEMOGLOBIN VALUES PLOTTED ACCORDING TO THE COPD SEVERITY.

| COPD severity | HB Average |
|------------------|------------|
| Mild - 6 | 11.8 |
| Moderate - 14 | 10.9 |
| Severe - 17 | 10.3 |
| Very Severe - 14 | 12.5 |



The haemoglobin values in all the cases are in the low normal range and no value showed polycythemia.

**THE SMOKING INDEX OF THE STUDY POPULATION
WHEN PLOTTED AGAINST THE COPD SEVERITY.**



Of the 47 male cases, 15 mild, 16 moderate and 16 severe categories of smoking index are distributed unevenly among individuals. In the females, history of passive smoking and biomass fuel usage are seen.

DISCUSSION

Chronic Obstructive Pulmonary Disease have been proved to be a systemic disease rather than a pulmonary disease, as it was identified in the past.

Cardiovascular system is mainly affected among systems other than lung itself. Cardiac dysfunction has been well known to complicate COPD of any severity and also remain to be the main cause of mortality in these patients. Changes in cardiovascular system both in mild and moderate COPD has been demonstrated in many studies and also well documented in literature.

Right ventricle and the pulmonary blood vessels are the major parts affected in patients with COPD during its clinical course. The structure of pulmonary blood vessels would be affected, leading to intimal thickening and medial hypertrophy which further increases the pulmonary arterial pressure and so, pulmonary hypertension. The raise in pulmonary arterial pressure has been reported in 30-80% of COPD patients, using pulmonary arterial catheterisation.

Pulmonary hypertension , in turn augments the right ventricular afterload leading to the dilatation and hypertrophy of right ventricle.

In addition to these, left ventricle also have been known to be affected , either alone or along with right ventricle.

This study mainly focuses on the assessment of cardiovascular changes in COPD patients and its correlation with the disease severity. In south india, studies related to this are not found easily. The salient features of this study are,

- Based on GOLD guidelines, the no. of Mild, Moderate, Severe and Very severe COPD patients participated in the study are 6,14,17 and 14 respectively using spirometry.
- Pulmonary hypertension is present in 33.3% (2/6), 28.6% (4/14), 82.3% (14/17) and 71.4% (10/14) cases of mild, moderate, severe and very severe obstruction respectively. This reveals that pulmonary hypertension is present more commonly in the severe cases than in the milder cases.
- Although normal values of TAPSE and ejection fraction are observed indicating normal ventricular systolic function, the ejection fraction diminishes with the disease severity.
- Right ventricular global dysfunction (using Tei index) are 33.3%,42.9%,76.5% and 85.7% in mild, moderate, severe, and

very severe obstruction respectively, which shows that right ventricular dysfunction increases with COPD disease severity.

- The left ventricular global dysfunction does not correlate with the disease severity.

In contradiction to these results, A study published in the Respir Med in the year 2010 revealed that COPD patients have right ventricular dysfunction related to airways obstruction and sub-clinical left ventricular dysfunction related to arterial stiffness. This study also explains that cardiovascular changes are seen in COPD even during mild airways obstruction. (2)

Another study published in Eur J Echocardiography in 2006 implied Tei index as a main parameter in Echocardiography for measuring right ventricular dysfunction in COPD. This showed the presence of both right and left ventricular dysfunctions in patients with COPD. (3)

A study published in the journal LUNG INDIA in the year 2011 observed that the pulmonary hypertension, right ventricular and left ventricular dysfunction are more prevalent and their occurrence

correlated well with the severity of COPD. This study is based mainly on Echocardiographic findings. (4)

- The haemoglobin values in all the cases in are in the low normal range and no value showed polycythemia.

CLINICAL IMPLICATIONS:

Until the right ventricle fails, preoccupation with the underlying pulmonary disease may divert attention from the presence of pulmonary hypertension and the development of right ventricular enlargement by masking of clinical manifestations.

In all patients with COPD invariable of its severity, by detecting, close monitoring and appropriately treating the cardiovascular abnormalities, the morbidity and mortality can be reduced. Echocardiography serves as a main tool in assessing the cardiovascular changes in patients with COPD and should be considered in all the patients irrespective of its severity.

CONCLUSION

1. There is increase in right ventricular global dysfunction and also pulmonary hypertension in COPD patients as the severity increases.
2. All COPD patients should undergo cardiac evaluation using echocardiogram to detect early cardiac abnormalities so as to prevent cardiac mortality and morbidity.

BIBLIOGRAPHY

1. Freixa X, Portillo K, Paré C, Garcia-Aymerich J, Gomez FP, Benet M, Roca J, Farrero E, Ferrer J, Fernandez-Palomeque C, M Antó J, Barberà JA Echocardiographic abnormalities in patients with copd at their first hospital admission [Eur Respir J. 2012] - PubMed - NCBI
2. Sabit R, Bolton CE, Fraser AG, Edwards JM, Edwards PH, Ionescu AA, Cockcroft JR, Shale DJ Sub-clinical left and right ventricular dysfunction in patients with COPD [Respir Med. 2010] - PubMed - NCBI
3. V. Pyankov 1 ; Y. Chuyasova 2 ; I. Pyankova 1 1Kirov State Medical Academy, Internal Diseases Dept., Kirov, Russian Federation; 2Internal Diseases Dept., Kirov, Russian Federation
The value of Tei-index for the complex echocardiographic diagnosis of right ventricular dysfunction in patients with chronic obstructive pulmonary disease. Eur J Echocardiography Abstracts Supplement, December 2006
4. N.K.Gupta, Ritesh Kumar Agrawal, A.B.Srivastav, M.L.Ved
Echocardiographic evaluation of heart in COPD patient and its co-

relation with the severity of the disease” LUNG INDIA VOL 28
ISSUE 2 APR-JUN 2011

5. Lawrence G. Rudski, MD, FASE, Chair, Wyman W. Lai, MD, MPH, FASE, Jonathan Afilalo, MD, Msc, Lanqi Hua, RDCS, FASE, Mark D. Handschumacher, BSc, Krishnaswamy Chandrasekaran, MD, FASE, Scott D. Solomon, MD, Eric K. Louie, MD, and Nelson B. Schiller, MD, Montreal, Quebec, Guidelines for the Echocardiographic Assessment of the Right Heart in Adults: A Report from the American Society of Echocardiography (J Am Soc Echocardiogr 2010;23:685-713.)
6. Sherif F. Nagueh, MD, et al Recommendations for the Evaluation of Left Ventricular Diastolic Function by Echocardiography
7. Rennard SI, Vestbo J: Natural history of chronic obstructive pulmonary disease. Proc Am Thorac Soc 5:878–883, 2008.
8. Decramer M, Rennard S, Troosters T, et al: COPD as a lung disease with systemic consequences—Clinical impact, mechanisms, and potential for early intervention. COPD 2008; 5:235-256.
9. Burrows B, Knudson RJ, Camilli AE, et al: The “horse-racing effect” and predicting decline in FEV1 from screening spirometry. Am Rev Respir Dis 1987; 135:788-793.

10. Grover RF: Chronic hypoxic pulmonary hypertension. In: Fishman AP, ed. *The Pulmonary Circulation: Normal and Abnormal. Mechanisms, Management, and the National Registry*, Philadelphia: University of Pennsylvania Press; 1990:283-299
11. Hopkins N, McLoughlin P: The structural basis of pulmonary hypertension in chronic lung disease: remodeling, rarefaction or angiogenesis. *J Anat* 2002; 201:335-348
12. Peinado VI, Barbera JA, Abate P, et al: Inflammatory reaction in pulmonary muscular arteries of patients with mild chronic obstructive pulmonary disease. *Am J Respir Crit Care Med* 1999; 159:1605-1611.
13. Santos S, Peinado VI, Ramirez J, et al: Characterization of pulmonary vascular remodeling in smokers and patients with mild COPD. *Eur Respir J* 2002; 19:632-638.
14. Krayenbuehl HP, Turnia J, Hess O: Left ventricular function in chronic pulmonary hypertension. *Am J Cardiol* 1978; 41:1150-1158.
15. Tutar E, Kaya A, Gýulec S, et al: Echocardiographic evaluation of left ventricular diastolic function in chronic cor pulmonale. *Am J Cardiol* 1999; 83:1414-1417.

16. Vizza CD, Lynch JP, Ochoa LL, et al: Right and left ventricular dysfunction in patients with severe pulmonary disease. *Chest* 1998; 113:576-583.
17. McGoon M, Gutterman D, Steen V, et al: Screening, early detection, and diagnosis of pulmonary arterial hypertension: ACCP evidence-based clinical practice guidelines. *Chest* 2004; 126(1 Suppl):14S-34S.
18. Arcasoy SM, Christie JD, Ferrari VA, et al: Echocardiographic assessment of pulmonary hypertension in patients with advanced lung disease. *Am J Respir Crit Care Med* 2003; 167:735-740.
19. Mason: Murray and Nadel's Textbook of Respiratory Medicine, 5th ed. Copyright © 2010 Saunders, An Imprint of Elsevier. Robert J. Mason, MD, V. Courtney Broaddus, MD, Thomas R. Martin, MD, Talmadge E. King, Jr., MD, Dean E. Schraufnagel, MD, John F. Murray, MD, FRCP, DSc (Hon), Jay A. Nadel, MD, DSc (Hon), DLaw.
20. Fishman's Pulmonary Diseases and Disorders Fourth Edition. Alfred P. Fishman, MD McGraw Hill medical.

INSTITUTIONAL ETHICS COMMITTEE
MADRAS MEDICAL COLLEGE, CHENNAI -3

Telephone No: 04425305301
Fax : 04425363970

CERTIFICATE OF APPROVAL

To
Dr. R. Hariprasad
PG in MD TB & Chest Diseases
Madras Medical College, Ch-3

Dear Dr. R. Hariprasad

The Institutional Ethics Committee of Madras Medical College reviewed and discussed your application for approval of the proposal entitled " Evaluation of cardiovascular changes in chronic obstructive pulmonary disease and its correlation with the disease severity" No. 10022012.


The following members of Ethics Committee were present in the meeting held on 22.02.2012 conducted at Madras Medical College, Chennai -3.

- | | |
|---|---------------------|
| 1. Dr. S.K. Rajan, MD.FRCP.DSc | -- Chairperson |
| 2. Prof. Pregna. B. Dolia MD Vice Principal , Madras Medical College, Chennai -3 | -- Member Secretary |
| 3. Prof. Md Ali. MD DM Prof & HOD, Dept. of MGE, MMC, Chennai -3 | -- Member |
| 4. Prof Vasanthi MD Prof of Pharmacology, MMC, Ch-3 | -- Member |
| 5. Prof. E. Dhandapani, MD Prof of Internal Medicine, MMC, Ch-3 | -- Member |
| 6. Thiru. S. Govindasamy . BA.BL | -- Lawyer |
| 7. Tmt. Arnold Soulina MA , MSW | -- Social Scientist |

We approve the proposal to be conducted in its presented form

Sd / . Chairman & Other Members

The Institutional Ethics Committee expects to be informed about the progress of the study, any SAE occurring in the course of the study, any changes in the protocol and patient information / informed consent and asks to be provided a copy of the final report


Member Secretary, Ethics Committee

PROFORMA

NAME :

AGE :

SEX :

HEIGHT :

WEIGHT:

SMOKER:

If yes, no. of pack years:

H/O PT, DM, SHT:

H/O IHD:

CLINICAL FEATURES:

BP:

PR:

Hb% :

RFT/LFT :

X-RAY CHEST:

ECG :

SPIROMETRY:

ECHOCARDIOGRAPHY

RWMA YES NO

If yes,

LVd LVs

EF

 Exp Insp

LAOT E A E A

RAOT E A E A

PV Flow S D AR

IVC d End Exp Insp

TAPSE

TDI

Tricuspid annulus

S E' A' IVCT IVRT

Mitral annulus

S E' A' IVCT IVRT

RV MPI - PET

TVC-TVO

LV MPI - AET

MVC-MVO

LV systolic function

PAH

TR Severity Gradient

INFORMATION SHEET

- Your participation has been accepted.
- We are conducting a study on COPD patients among patients attending Government
- General Hospital, Chennai and for that your participation may be valuable to us.
- The purpose of this study is to assess the cardiovascular changes in COPD patients easily with
- The help of certain investigations like spirometry, blood investigation, chest x ray/CT chest, ECG and ECHO.
- The privacy of the patients in the research will be maintained throughout the study. In the event of any publication or presentation resulting from the research, no personally identifiable information will be shared.
- Taking part in this study is voluntary. You are free to decide whether to participate in this study or to withdraw at any time; your decision will not result in any loss of benefits to which you are otherwise entitled. The results of the special study may be intimated to you at the end of the study period or during the study if anything is found abnormal which may aid in the management or treatment.

Signature of investigator

Signature of participant

Date:

ஆராய்ச்சி தகவல் தாள்

சென்னை இராஜீவ்காந்தி அரசு பொது மருத்துவனைக்கு வரும் நோயாளிகளில் நெடுங்கால மூச்சுக்குழாய் அடைப்பு நோயால் (COPD) பாதிக்கப்பட்டவர்கள் குறித்த ஆய்வு இங்கு நடைபெற்று வருகிறது.

நீங்களும் ஆராய்ச்சியில் பங்கேற்க விரும்புகிறோம். இந்த ஆராய்ச்சியில் உங்களை பங்கேற்க வைத்து அதன் தகவல்களை ஆராய்வோம் அல்லது உங்கள் இரத்தத்தை பரிசோதனைக்கு உட்படுத்தி ஆராய்வோம். அதனால் தங்களின் நோயின் ஆய்வறிக்கையோ, சிகிச்சைக்கோ பாதிப்பு ஏற்படாது என்பதை தெரிவித்துக்கொள்கிறோம்.

முடிவுகளை அல்லது கருத்துகளை வெளியிடும்போதோ அல்லது ஆராய்ச்சியின் போதோ தங்களது பெயரையோ அல்லது அடையாளங்களையோ வெளியிடமாட்டோம் என்பதையும் தெரிவித்துக் கொள்கிறோம்.

இந்த சிறப்பு பரிசோதனைகளின் முடிவுகளையும் நோயின் தன்மை பற்றியும் ஆராய்ச்சியின்போது அல்லது ஆராய்ச்சியின் முடிவின் போது தங்களுக்கு அறிவிப்போம் என்பதையும் தெரிவித்துக் கொள்கிறோம்.

இந்த ஆராய்ச்சியில் பங்கேற்பது தங்களுடைய விருப்பத்தின் பேரில் தான் இருக்கிறது. மேலும் நீங்கள் எந்நேரமும் இந்த ஆராய்ச்சியிலிருந்து பின்வாங்கலாம் என்பதையும் தெரிவித்துக்கொள்கிறோம்.

ஆராய்ச்சியாளர் கையொப்பம்

பங்கேற்பாளர் கையொப்பம்

ஆராய்ச்சி ஒப்புதல் படிவம்

ஆராய்ச்சி தலைப்பு
நெடுங்கால மூச்சுக்குழாய் அடைப்பு நோயால் பாதிக்கப்பட்டவர்களின் இருதய
செயல்பாடுகள் குறித்த பன்முக ஆய்வு

பெயர் : தேதி :
வயது : உள்/ புறநோயாளி எண்:
பால் : ஆராய்ச்சி சேர்க்கை எண்:

இந்த ஆராய்ச்சியின் விவரங்களும் அதன் நோக்கங்களும் முழுமையாக
எனக்கு தெளிவாக விளக்கப்பட்டது.

எனக்கு விளக்கப்பட்ட விஷயங்களை புரிந்துகொண்டு நான் எனது
சம்மதத்தை தெரிவிக்கின்றேன்.

எனக்கு இருதய செயல்திறனையும், நுரையீரல் செயல்திறனையும்
பரிசோதனை செய்து கொள்ள சம்மதம்.

இந்த ஆராய்ச்சியில் பிறரின் நிர்பந்தமின்றி என் சொந்த விருப்பத்தின்பேரில்
பங்கு பெறுகின்றேன். இந்த ஆராய்ச்சியில் இருந்து நான் எந்நேரமும்
பின்வாங்கலாம் என்பதையும் அதனால் எந்த பாதிப்பும் ஏற்படாது என்பதையும்
நான் புரிந்துகொண்டேன்.

நான் என்னுடைய சுய நினைவுடனும் மற்றும் முழு சுதந்திரத்துடனும் இந்த
மருத்துவ ஆராய்ச்சியில் என்னை சேர்த்துக்கொள்ள சம்மதம்.

எனக்கு இரத்தம், மார்பு ஊடுகதிர், இருதய மின் வரைபடம் எடுத்து
பரிசோதனை செய்துகொள்ள சம்மதம்.

கையொப்பம்

Originality GradeMark PeerMark

Evaluation of cardiovascular changes in chronic obstructive pulmonary disease and its

BY HARI PRASAD 2010001 M.D. TUBERCULOSIS RESPIRATORY DISEASE



15%

SIMILAR

--

OUT OF 0

INTRODUCTION

Chronic Obstructive Pulmonary Disease (COPD) has considerable effects on cardiac function, including those of the right ventricle, left ventricle and pulmonary blood vessels.

Chronic Obstructive Pulmonary Disease (COPD), a common preventable and treatable disease is characterised by persistent air flow limitation that is usually progressive and associated with an enhanced chronic inflammatory response in the airways and lungs to noxious particles or gases. Exacerbations and comorbidities

Match Overview

| | | |
|---|---|-----|
| 1 | www.goneboarding.co.uk Internet source | 3% |
| 2 | Vestbo, J., S. S. Hurd... | 2% |
| 3 | Kenneth W. Presberg Publication | 1% |
| 4 | "Sunday, 30 August Publication | 1% |
| 5 | Konstadina Darsakiis, ... Publication | 1% |
| 6 | Joseph P. Lynch III. "... Publication | 1% |
| 7 | Tonino Bombardini. Publication | <1% |
| 8 | "Euroecho 8 - Abstract... Publication | <1% |



Your digital receipt

This receipt acknowledges that Turnitin received your paper. Below you will find the receipt information regarding your submission.

| | |
|------------------|---|
| Paper ID | 294876346 |
| Paper title | Evaluation of cardiovascular changes in chronic obstructive pulmonary disease and its correlation with the disease severity |
| Assignment title | Medical |
| Author | Hari Prasad 20106001 M.D. Tuberculosis Respiratory Disease |
| E-mail | drharisam@yahoo.com |
| Submission time | 25-Dec-2012 12:39PM |
| Total words | 8778 |

First 100 words of your submission

INTRODUCTION Chronic Obstructive Pulmonary Disease (COPD) has considerable effects on cardiac function, including those of the right ventricle, left ventricle and pulmonary blood vessels. Chronic Obstructive Pulmonary Disease (COPD), a common preventable and treatable disease is characterised by persistent air flow limitation that is usually progressive and associated with an enhanced chronic inflammatory response in the airways and lungs to noxious particles or gases. Exacerbations and comorbidities contribute to the overall severity in the individual patients. COPD is one of the leading causes of morbidity and mortality worldwide and results in an economic and social burden. The global...