

ROLE OF RANIBIZUMAB IN MACULAR EDEMA DUE TO BRANCH RETINAL VEIN OCCLUSION

Dissertation submitted to

THE TAMILNADU DR. M.G.R. MEDICAL UNIVERSITY

CHENNAI, INDIA



**M.S.DEGREE EXAMINATION
BRANCH – III OPHTHALMOLOGY**

MARCH 2011

This is to certify that the dissertation entitled **“ROLE OF RANIBIZUMAB IN MACULAR EDEMA DUE TO BRANCH RETINAL VEIN OCCLUSION”** is a bonafide work done by **Dr. SHORYA VARDHAN AZAD**, Postgraduate student in M.S. (Ophthalmology) during MARCH 2009 to MARCH 2011, under our direct supervision and guidance, at our institute, in partial fulfillment for the award of M.S. Degree in Ophthalmology of the Tamilnadu Dr. M.G.R. Medical University, Chennai.

Dr. Amjad Salman,

M.S

Professor of Ophthalmology

Guide

Dr. M. Rajamohan,

M.S., D.O.M.S., C.C.E.H. (London)

Professor of Ophthalmology

Co guide

Dr. C.A.Nelson Jesudasan,

M.S., D.O.M.S., FRCS (Edin. & Glas.)

Professor and Director

ACKNOWLEDGEMENT

I would like to express my profound gratitude to Professor and Director, **Dr.C.A.Nelson Jesudasan, M.S., D.O.M.S., FRCS (Edin, & Glas.)** for having assigned me this very interesting topic, for providing me all the necessary facilities and guidance to enable me to complete my study.

I am really indebted to **Prof. Dr. Amjad Salman, M.S.**, Registrar for being my guide in this study. His corrections and criticism molded every step in this study.

I would like to thank **Prof. Dr. M. Rajamohan, M.S., D.O.M.S., C.C.E.H. (London)**, who was the co-guide for the study. I express my gratitude to his customary patience and guidance taken in clarifying my various doubts and rendering his valuable advice.

I am also grateful to **Prof. Dr. Philip Aloysius Thomas, M.D., PhD.**

(Microbiology) for his guidance and inspiration throughout this study and for extending technical guidance and support.

I would like to thank my father **Prof. Dr. Raj Vardhan Azad, M.D., FRCS (Edin)**, and mother **Mrs. Sheela Azad** for their moral support and prayers.

I would also like to thank my wife **Dr Shikha Azad** for her inspiration and moral support.

I also thank all my teachers, my colleagues, especially **Dr. Rameez Hussain, Dr. Vinod Nathaniel, Dr. Achyut Pandey**, and **Mr. John Rice (Technician)**, **Ms. P. Renuga Devi (Nursing)**, **Mr. Subramani (M.R.D.)**, **Mr. Koil Pillai (M.R.D.)**, **Mr. Daniel Prince** and **Mr. Rajkumar** for their timely help and technical assistance throughout the study.

Finally I am indebted to all my patients for their sincere co-operation for the completion of the study.

CONTENTS

1. INTRODUCTION	1
2. AIM OF THE STUDY	4
3. REVIEW OF LITERATURE	5
4. MATERIALS AND METHODS	30
5. RESULTS	37
6. DISCUSSION	48
7. CONCLUSION	52
8. SUMMARY	53

BIBLIOGRAPHY

PROFORMA

INTRODUCTION

Retinal vein occlusion (RVO) is the second most common cause of retinal vascular disease after diabetic retinopathy^{1,2}. Previous studies have reported the prevalence of RVO^{3,4,5}. In the population-based Blue Mountains Eye Study (Australia), the prevalence of retinal vein occlusion was 1.6%. In the Framingham Eye Study (USA), of the 2,631 persons who underwent a screening examination, 4 of the 156 eyes found to have retinopathy had a retinal vein occlusion. The Beaver Dam Study (USA) reported a prevalence of 0.6% in patients older than 43 years.

The incidence of RVO is estimated 180 000 eyes per year in United States, and branch retinal vein occlusion is the more common of the two presentations, accounting for approximately 80% of RVO^{5,6}. Macular edema is one of the leading cause of vision loss in patients with either central or branch retinal vein occlusions (CRVO or BRVO)⁷. This edema is found to be due to hypoxia-induced up regulation of vascular endothelial growth factor(VEGF) that loosens endothelial tight junctions leading to increase in vascular permeability and deposition of exudative material^{8,9}. There have been various attempts to reduce macular edema such as macular grid photocoagulation, intravitreal injections of triamcinolone acetonide or bevacizumab , but the definitive treatment modality is yet to emerge^{10,11,12,13,14}.

The Collaborative Branch Vein Occlusion Study , a multi-center randomized clinical trial supported by the National Eye Institute, reported that argon laser photocoagulation may reduce visual loss from macular edema for those eyes that meet study eligibility criteria and are treated according to that protocol¹⁰.

Recently, there has been interest in the use of vascular endothelial growth factor (VEGF) inhibition in the treatment of BRVO because of the observation of increased VEGF in the vitreous and aqueous of patients with these conditions¹⁵. Two trials assessed the efficacy and safety of intravitreal ranibizumab (Lucentis, Genentech) in BRVO^{16,17}. The results have suggested that with intensive, monthly treatment, patients achieve very good results, superior to anything previously seen with other treatment modalities. Ranibizumab is a humanized anti-vascular endothelial growth factor monoclonal antibody fragment that has been shown to halt the growth of choroidal neovascularization (CNV) lesion and reduce vascular leakage. This anti-VEGF effect of ranibizumab also might be effective for treatment of macular edema in patients with BRVO. In one of the clinical trials, patients with macular edema due to BRVO were given either of two doses of ranibizumab , on average, had clinically and statistically significant improvements in best corrected visual acuity (BCVA) compared with patients receiving sham injections.

However, only a few studies have been done thus far regarding the use of of intravitreal ranibizumab in macular edema due to BRVO. Moreover, no prospective study has been done on Indian patients regarding use of intravitreal ranibizumab in macular edema due to BRVO. Also, no studies have so far studied the combination therapy of anti VEGF agents namely ranibizumab and bevacizumab with laser in cases with macular edema due to BRVO.

Hence this study will evaluate the anatomical and functional efficacy of intravitreal Ranibizumab and intravitreal Bevacizumab with standard laser treatment in patients suffering from macular edema due to BRVO in a prospective manner.

AIM OF THE STUDY

Primary Objectives

- To study the efficacy of ranibizumab 0.5 mg in management of macular edema due to BRVO in terms of mean change from baseline in best corrected visual acuity(BCVA) over a 6 month treatment period.

Secondary Objectives

- To study the efficacy of ranibizumab 0.5 mg in reducing intraretinal thickness changes on Optical Coherence Tomography (OCT) in eyes with macular edema due to BRVO .
- To compare the results obtained with ranibizumab therapy with those obtained with other modalities of treatment such as Laser photocoagulation and intravitreal Bevacizumab .
- To study ocular and systemic safety of intravitreal ranibizumab in eyes with macular edema due to BRVO.

REVIEW OF LITERATURE

Branch retinal vein occlusion (BRVO) is a common cause of retinal vascular disease¹⁰. It affects males and females equally and occurs most frequently between the ages of 60 and 70. The interruption of venous flow in these eyes almost always occurs at a retinal arteriovenous intersection, where a retinal artery crosses a retinal vein^{18,19}. An increased risk of BRVO has been suggested in persons with a history of systemic hypertension, diabetes, hyperlipidemia, glaucoma, smoking and age related atherosclerosis²⁰. Anti-phospholipid antibodies, elevated plasma homocysteine levels, and low serum folate levels have also been associated with increased risk of vein occlusion^{21,22,23}. In one study a decreased risk of BRVO was present in individuals with higher serum levels of high density lipoprotein (HDL) and greater alcohol consumption²⁰. Other studies have suggested an increased risk of BRVO in eyes with shorter axial lengths^{24,25,26,27}.

Clinical Features

Branch retinal vein occlusion is almost always of sudden onset; the patient presents with blurred vision or field defect and segmentally distributed intraretinal hemorrhage. Generally, intraretinal hemorrhage is less marked if the occlusion is perfused or nonischemic and is much more marked if the occlusion is nonperfused or ischemic and associated with retinal capillary nonperfusion.

The location of a branch venous block determines the distribution of the intraretinal hemorrhage; if the venous obstruction is at the optic nerve head, two quadrants of the fundus may be involved, whereas if the occlusion is peripheral to the disc, one quadrant or less may be involved with the intraretinal hemorrhage. If the venous blockage is peripheral to tributary veins draining the macula, there may be no macular involvement and no decrease in visual acuity. Rarely, a patient initially may present with very little intraretinal hemorrhage, which then becomes more extensive in succeeding weeks to months. In these instances it is presumed that an incomplete blockade at the arteriovenous crossing has progressed to more complete occlusion.

One year or more after a BRVO has occurred, the intraretinal hemorrhage may have completely reabsorbed. Without the characteristic segmental distribution of intraretinal hemorrhage, the ophthalmoscopic diagnosis may be more difficult, but the segmental distribution of vascular abnormalities during the acute phase will persist and be apparent on fluorescein angiography.

Pathogenesis

Because BRVO almost occurs at arteriovenous crossings^{18,19}, underlying arterial disease may play a causative role. In 99% of 106 eyes with BRVO, the artery was located anterior to the vein at the obstructed site¹⁸. Histopathologically, the retinal artery and vein

share a common adventitial sheath, and in some cases, a common medium²⁷. The lumen of the vein may be compressed up to 33% at the crossing site^{28,29}. The vitreous may also play a role in compression of susceptible arteriovenous crossing sites as evidenced by studies demonstrating that eyes with decreased axial length and higher likelihood of vitreomacular attachment at the arteriovenous crossing are at increased risk of BRVO^{25,30}. Some have postulated that turbulent blood flow at the crossing site causes focal swelling of the endothelium and deeper vein wall tissue leading to venous obstruction^{27,30,31}. Other reports have demonstrated actual venous thrombus formation at the point of occlusion^{29,32}.

The resulting venous obstruction leads to elevation of venous pressure that may overload the collateral drainage capacity³³ and lead to macular edema and ischemia by mechanisms that are still under investigation. Unrelieved venous pressure can also result in rupture of the vein wall with intraretinal hemorrhage²⁷.

Recently, macular edema is found to be due to hypoxia-induced up regulation of vascular endothelial growth factor(VEGF) that loosens endothelial tight junctions leading to increase in vascular permeability and deposition of exudative material^{8,9}.

Vision limiting complications

There are three main vision-limiting complications of BRVO: macular edema, macular nonperfusion, and vitreous hemorrhage from neovascularization^{34,35,36,37}.

In the acute phase (i.e., the first 3 to 6 months) after a branch vein occlusion, there is often extensive intra- retinal hemorrhage that may involve the macula and the foveal center. Under these circumstances, it is impossible to evaluate the vascular perfusion status by fluorescein angiography because the hemorrhage itself blocks the view of the retinal vessels.

Additionally, hemorrhage in the foveal center may reduce visual acuity, visual acuity that is reduced by hemorrhage may recover completely if there is no other cause for the visual loss, such as macular edema or macular non perfusion. Under these circumstances, the patient should be followed every 2 to 3 months until there is sufficient clearing of hemorrhage to allow evaluation by fluorescein angiography.

After the acute phase of the BRVO has passed and intraretinal hemorrhage has mostly reabsorbed, which usually takes 3 to 6 months, fluorescein angiography should be obtained to delineate the retinal vascular characteristics that may have prognostic significance—macular edema, macular non perfusion, and large segments of capillary non perfusion that may portend eventual neovascularization. When fluorescein angiography demonstrates macular edema with cystoid involvement of the fovea, but no capillary nonperfusion, it is presumed that the macular edema is the cause of loss of vision. Under these circumstances, about one third of patients will spontaneously regain some vision.

When macular edema is present ophthalmoscopically within the first 6 months after a BRVO and there is little or no leakage on fluorescein angiography, macular ischemia may be the cause of the macular edema. In such circumstances, the edema almost always spontaneously resorbs in the first year after the occlusion, often with return of vision³⁸.

Retinal neovascularization may develop if the BRVO produces an area of capillary nonperfusion that is more than five disc diameters, as visualized with fluorescein angiography. In case of large branch vein occlusion (involving a quadrant or more), about 50% are associated with a large area of capillary nonperfusion; of this 50%, about 40% will develop neovascularization. Retinal or disc neovascularization, or both, may develop at any time within the first 3 years after an occlusion but is most likely to appear within the first 6 to 12 months after the occlusion. Of patients who develop neovascularization, approximately 60% experience episodes of vitreous hemorrhage if the condition is left untreated.

Investigations

• Fluorescein Angiography

A fluorescein angiogram may be obtained as soon as the hemorrhages have cleared if the patient's vision is still diminished. This office-based test is usually done 3 or more months after the event. Angiography is used to determine the cause of central visual loss (edema involving the central retina or macula vs. severe retinal capillary damage involving the macula--“macular ischemia”)¹⁰.

If angiography suggests that visual loss is secondary to macular edema with good blood flow through the macular capillaries, laser photocoagulation in a “grid” pattern may be of benefit. However, if angiography demonstrates the presence of extensive macular ischemia, laser photocoagulation may not be very effective and may therefore be withheld.

- **Optical coherence tomography**

Has ability to measure retinal thickness in a quantitative fashion, optical coherence tomography (OCT) is a useful adjunct in the evaluation of patients with macular edema secondary to BRVO. It is a safe, high-resolution, non-invasive, reliable and reproducible method for detecting macular edema³⁹. OCT delineates macular changes at a stage when fundus biomicroscopy and fluorescein angiography are not very informative. The anatomical cause for the increase in macular thickness and macular edema is also well delineated. Non-ischemic maculae show an early and more rapid decline in macular thickness compared with ischemic occlusions. An increase in macular thickness at 3 months on OCT in BRVO patients could be an indication of a possible ischemic course⁴⁰.

Treatment

Treatment of BRVO can be considered under following head, namely, medical treatment, laser therapy, intravitreal triamcinolone and intravitreal anti-VEGF therapy.

Medical treatment

Anticoagulant therapy has not been shown to be beneficial in either the prevention or the management of BRVO⁴¹. Since the systemic administration of anticoagulants can be associated with systemic complications, and since anticoagulants could, in theory, increase the severity of intraretinal hemorrhage occurring in the acute phase, such therapy is not recommended⁴².

Laser therapy

The Collaborative Branch Vein Occlusion Study¹⁰, a multi-center randomized clinical trial supported by the National Eye Institute(USA), reported that argon laser photocoagulation may reduce visual loss from macular edema for those eyes that meet study eligibility criteria and are treated according to that protocol. Important eligibility criteria included fluorescein - proven perfused macular edema involving the foveal center, absorption of intraretinal hemorrhage from the foveal center, recent branch retinal vein occlusion (usually of 3 to 18 month duration), absence of diabetic retinopathy, and vision reduced to 20/40 or worse after best refraction.

In the Collaborative Branch Vein Occlusion Study, argon laser photocoagulation was applied in a grid pattern throughout the area demonstrated by fluorescein angiography to be leaking. Coagulation extended no closer to the fovea than the edge of the capillary-free zone and no farther into the periphery than the major vascular arcade. Recommended treatment parameters included a duration of 0.1 second, a 100 micron diameter spot size, and a power

setting sufficient to produce a "medium" white burn. Fluorescein angiography was repeated 2 to 4 months after the treatment, and additional photocoagulation was applied to residual areas of leakage if reduced visual acuity persisted. When improvement was defined as reading two or more Snellen lines (beyond baselines) at two consecutive visits, the treated eyes showed visual improvement more often than the untreated eyes. After 3 years of follow-up, 63% of treated eyes gained two or more line of vision, compared to 36% of untreated eyes. The average gain in visual acuity for treated eyes was one more Snellen line than in untreated eyes¹⁰.

In the application of grid pattern laser photocoagulation, it is crucial to obtain good definition of landmarks so that the center of the fovea can be identified and avoided. Since landmarks frequently may be obscured in the macula after BRVO, such cases can be managed more effectively and safely by treating well peripheral to the capillary-free zone in the first sitting. When the patient returns in 2 month for follow-up evaluation, a fluorescein angiogram may identify more clearly the amount of further treatment that needs to be applied closer to the edge of the capillary-free zone, because the pigmentation of the previous treatment is then visible. Consequently, treatment in this next sitting may be brought closer to the edge of the capillary-free zone, if that is deemed necessary because of continued edema with foveal involvement and continued visual loss. The placement of grid laser treatment in this repetitively-staged fashion may be safer and appears to be just as effective as a single treatment. It has never been established that macular edema must be treated quickly or that long-standing edema produces irreversible macular damage in the first 2 to 3 years.

In the Collaborative Branch Vein Occlusion Study, Argon blue-green wavelength was employed for the grid treatment. This is the only wavelength that has been proved effective; it is not known whether argon-green or krypton-red photocoagulation would be as effective. In other diseases, when laser treatment is applied inside the capillary-free zone, it is recognized that krypton red and argon green laser photocoagulation are absorbed less than blue-green by the xanthophyll pigment of the inner retina that is present close to the foveal center. However, because the grid treatment never comes closer to the fovea than the capillary-free zone, the Branch Vein Occlusion Study did not encounter any problems with the argon blue-green laser in this region; consequently, this laser continues to be recommended.

The Branch Vein Occlusion Study demonstrated that prophylactic scatter laser photocoagulation can lessen subsequent neovascularization and if neovascularization already exists, that peripheral scatter laser photocoagulation can lessen subsequent vitreous hemorrhage⁴³. Only eyes with the type of branch vein occlusion that shows large areas (greater than five disc diameters) of retinal capillary nonperfusion are at risk for developing neovascularization. It is recommended that laser photocoagulation be applied only after neovascularization is documented. The Branch Vein Occlusion Study data strongly suggest that photocoagulation after the development of neovascularization is as effective in preventing vitreous hemorrhage as is photocoagulation before the development of neovascularization . When neovascularization is unequivocally confirmed by fluorescein angiography, peripheral scatter laser photocoagulation can reduce from about 60% to 30% the likelihood of vitreous hemorrhage. Scatter laser photocoagulation is applied to achieve "medium" white burns (200 to 500 microns in diameter) spaced one burn width apart and

covering the entire area of capillary nonperfusion, as defined by fluorescein angiography, but not closer than 2 disc diameters from the center of the fovea and extending peripherally at least to the equator.

Familiarity with the laser treatment technique is required to individualize the treatment. Important variables, such as residual intraretinal hemorrhage, thickness of the retina from edema, location of collaterals, and presence of retinal traction influence the exact mode of therapy within the above general treatment guidelines for the management of macular edema and neovascularization. There are numerous complications of laser photocoagulation; however, it is generally recognized that with proper attention to detail, complications are infrequent. Side effects of treatment, including production of scotoma, merit careful consideration and discussion with the patient before initiation of treatment. It is particularly important to recognize that laser photocoagulation should never be placed over extensive intraretinal hemorrhage in the acute phase of branch vein occlusion because the laser energy will be absorbed by the intraretinal hemorrhage rather than at the level of the pigment epithelium, probably damaging the nerve fiber layer and possibly producing preretinal fibrosis.

Though BVO Study has been a bench mark study and laser therapy since then been the gold standard treatment, various other studies have also substantiated the beneficial role of laser^{44,45,46}. Arnarsson A et al hypothesised that the disappearance of macular edema in BRVO can be explained by the effect the laser photocoagulation has on retinal oxygenation. Increased oxygenation causes vessel constriction and shortening and lower intravascular

pressure, which reduces edema formation according to Starling's law. Lang GE et al investigated the relationship of morphological and fluorescein angiographic findings with the results of laser treatment. They concluded that laser treatment in BRVO was beneficial and resulted in significant visual improvement.

Intravitreal triamcinolone

Scott IU et al¹⁴ compared compare the efficacy and safety of 1-mg and 4-mg doses of preservative-free intravitreal triamcinolone with standard care (grid photocoagulation in eyes without dense macular hemorrhage and deferral of photocoagulation until hemorrhage clears in eyes with dense macular hemorrhage) for eyes with vision loss associated with macular edema secondary to branch retinal vein occlusion (SCORE TRIAL). They concluded that there was no difference identified in visual acuity at 12 months for the standard care group compared with the triamcinolone groups; however, rates of adverse events (particularly elevated intraocular pressure and cataract) were highest in the 4-mg group. Application to Clinical Practice Grid photocoagulation as applied in the SCORE Study remains the standard care for patients with vision loss associated with macular edema secondary to BRVO who have characteristics similar to participants in the SCORE-BRVO trial. Grid photocoagulation should remain the benchmark against which other treatments are compared in clinical trials for eyes with vision loss associated with macular edema secondary to BRVO.

Various previous studies^{47,48,49} have also showed beneficial effects of intravitreal triamcinolone therapy but have not been popular due to relatively higher incidence of complications like glaucoma and cataract and also the need for repetitive injections. McAllister IL et al found intravitreal triamcinolone down regulates VEGF, which may prevent a decrease in occludin and also inhibits an increase in glial fibrillary acidic protein (GFAP) expression in Muller cells. These events contributed to a reduction in the blood retinal barrier breakdown that occurs in BRVO and promote resolution of the associated retinal edema. Gunnlaugsdóttir E et al also found that intravitreal triamcinolone improves visual acuity in about 40% of patients with macular oedema, about 10% lose vision and about 50% remain unchanged. OCT revealed improved anatomic results with significant reduction of foveal thickness and macular oedema. Similarly Chen SD et al found that intravitreal triamcinolone was effective in reducing ischemic macular edema associated with BRVO and foveal capillary nonperfusion. . Raised IOP and development of posterior subcapsular cataract are disadvantages of this treatment.

Intravitreal anti-VEGF

Recently, there has been interest in the use of VEGF inhibition in the treatment of BRVO because of the observation of increased VEGF in the vitreous and aqueous of patients with these conditions^{8,9}. Mainly intravitreal bevacizumab (Avastin) has been used with recent introduction of intravitreal ranibizumab (Lucentis). Both will be studied in detail below.

Bevacizumab

Bevacizumab is an immunoglobulin G (IgG) composed of two identical light chains, consisting of 214 amino acid residues and two 453 residue heavy chains containing an N-linked oligosaccharide and has a molecular weight of approximately 149Kda^{50,51}.

Description⁵² - It is a clear to slightly opalescent, colourless to pale brown sterile solution for intravenous (IV) infusion, available in 100 mg and 400 mg single dose vials containing 4 mL and 16 mL, respectively of bevacizumab (25 mg/mL). Bevacizumab also contains a trehalose dihydrate, monobasic monohydrate sodium phosphate, dibasic sodium phosphate, polysorbate 20 and water for injections.

Mechanism of action⁵² - Bevacizumab is a recombinant humanised monoclonal antibody that selectively binds to and neutralises the biologic activity of human VEGF. Bevacizumab contains human framework regions with antigen binding regions of a humanised murine antibody that binds to VEGF. Bevacizumab is produced by recombinant DNA technology in a Chinese hamster ovary mammalian cell expression system in a nutrient medium containing the antibiotic gentamicin and is purified by a process that includes specific viral inactivation and removal steps. Gentamicin is detectable in the final product at ≤ 0.35 ppm.

Bevacizumab inhibits the binding of VEGF to its receptors, Flt-1 and KDR, on the surface of endothelial cells. Neutralising the biologic activity of VEGF reduces the vascularisation of tumours, thereby inhibiting tumour growth. Administration of bevacizumab or its parental murine antibody to xenotransplant models of cancer in nude mice resulted in extensive antitumour activity in human cancers, including colon, breast, pancreas and prostate. Metastatic disease progression was inhibited and microvascular permeability was reduced.

Pharmacokinetics⁵³ - Whereas vitreous concentrations of bevacizumab declined in a monoexponential fashion with a half-life of 4.32 days, concentrations of >10µg/ml bevacizumab were maintained in the vitreous humor for 30 days. Bevacizumab concentrations in the aqueous humor of the injected eye reached a peak concentration of 37.7 µg/ml 3 days after drug administration. A maximum serum concentration of 3.3 µg/ml was achieved 8 days after intravitreal injection and the concentration fell below 1 µg/ml 29 days after injection. Elimination of bevacizumab from the aqueous humor and serum paralleled that found in the vitreous humor, with half-life values of 4.88 days and 6.86 days, respectively. Very low concentrations of bevacizumab were detected in the fellow uninjected eye. Concentrations of bevacizumab in the vitreous of the fellow eye varied incrementally, from 0.35 ng/ml at 1 day to 11.17 ng/ml at 4 weeks. Concentrations of bevacizumab in the aqueous humor of the fellow eye reached their peak at 1 week, at 29.4 ng/ml, and declined to 4.56 ng/ml at 4 weeks.

Pharmacokinetics in Special Populations - The population pharmacokinetics of bevacizumab were analysed to evaluate the effects of demographic characteristics. The results showed no significant difference in the pharmacokinetics of bevacizumab in relation to age.

Children and Adolescents: No formal studies have been conducted to examine the pharmacokinetics of bevacizumab in children and adolescent patients.

Renal impairment: No formal studies have been conducted to examine the pharmacokinetics of bevacizumab in subjects with renal impairment

Hepatic impairment: No formal studies have been conducted to examine the pharmacokinetics of bevacizumab in subjects with hepatic impairment.

Complication^{54,55,56} - General complications – Cataract, Glaucoma, Vitreous Hemorrhage, Retinal detachment, Endophthalmitis.

Specific Complications - Retinal pigment epithelial rip, Submacular haemorrhage, Progression of tractional retinal detachment, Visual hallucinations.

Bevacizumab in various diseases

BRVO - Prager F et al¹¹ evaluated functional and anatomical changes after intravitreal bevacizumab (Avastin) in eyes with persistent macular oedema secondary to branch retinal vein occlusion (BRVO) or central retinal vein occlusion (CRVO). Twenty-nine consecutive eyes with macular oedema secondary to BRVO (21 eyes) or CRVO (eight eyes) were included in a prospective clinical trial. Eyes were treated with three initial intravitreal bevacizumab injections of 1 mg at a monthly interval. Retreatment was based on central retinal thickness (CRT) based on optical coherence tomography. If continuous injections were indicated up to month 6, the dose was increased to 2.5 mg. After 12 months of follow-up, mean visual acuity increased from 50 letters (20/100) at baseline to 66 letters (20/50(+1); +16 letters; $p < 0.001$) at month 12 and CRT decreased from 558 μm at baseline to 309 μm at month 12 (-249 μm ; $p < 0.001$). Patients received a mean of eight out of 13 possible injections. No drug-related systemic or ocular side effects following intravitreal bevacizumab treatment were observed. Fluorescein angiography revealed no progression of avascular areas. They concluded that Intravitreal therapy using bevacizumab appears to be a safe and effective treatment in patients with macular oedema secondary to retinal vein occlusion. However, the main limitations of this treatment modality are its short-term effectiveness and high recurrence rate.

Jaissle GB et al¹² investigated the long-term effectiveness of intravitreal bevacizumab treatment in eyes with perfused macular edema due to branch retinal vein occlusion (BRVO). 23 consecutive, previously untreated eyes with perfused macular edema were treated with intravitreal bevacizumab (1.25 mg) injections and followed for 1 year.

The main outcome measures were visual acuity (VA) and central retinal thickness (CRT). In addition, VA data were adapted to the non-logarithmic VA charts used in the previously published grid laser photocoagulation BRVO Study. The median VA gained 3.0 lines from baseline at 48 weeks. This was accompanied by a significant decrease of 39% of the median CRT. The mean number of re-injections was 1.6 during the first 6 months of follow-up and only 0.8 during the subsequent 6 months. In 65% of the cases, adapted VA data showed a gain of 1 or more lines and no eye lost more than 1 line. They stated that repetitive intravitreal bevacizumab injections result in a significant long-term improvement of VA and CRT. The number of re-injections necessary to maintain this effect declined over time. However, the treatment seems to be only slightly better than grid laser photocoagulation.

Kondo M et al¹³ evaluated the 12-month follow-up results of intravitreal bevacizumab therapy for macular edema secondary to branch retinal vein occlusion and to identify the pretreatment factors that were associated with an improvement of the final visual outcome. Fifty eyes of 50 patients with macular edema secondary to branch retinal vein occlusion received an injection of 1.25 mg/0.05 mL bevacizumab. Additional injections were done when recurrence of macular edema occurred or the treatment was not effective. The best-corrected visual acuity and foveal thickness were measured. Stepwise multiple regression analyses were also performed. Visual acuity improved significantly from 0.53 to 0.26, and the mean foveal thickness decreased significantly from 523 to 305 μm during the 12-month follow-up period. The mean number of injections was 2.0 (range, 1-4).

Stepwise multiple regression analyses showed that younger patients had both better visual acuity at 12 months and greater improvement of visual acuity during 12 months. In addition, better pretreatment visual acuity was associated with better visual acuity at 12 months but with less improvement of the visual acuity. They concluded that intravitreal bevacizumab therapy can be a long-term effective treatment for macular edema secondary to branch retinal vein occlusion.

CRVO - Costa RA et al⁵⁷ evaluated the safety, visual acuity changes, and morphologic effects associated with intravitreal bevacizumab injections for the management of macular edema due to central retinal vein occlusion (CRVO) and Hemi central retinal vein occlusion(H-CRVO). In this prospective, open-label study, 7 consecutive patients (7 eyes) with macular edema associated with central or hemicentral RVO were treated with intravitreal-injections of 2.0 mg (0.08 mL) of bevacizumab at 12-week interval. Concluded that Intravitreal bevacizumab injections of 2.0 mg at 12-week intervals were well tolerated and were associated with short-term BCVA stabilization or improvement and favourable macular changes in all patients with ischemic CRVO and associated macular edema.

Diabetic retinopathy - Haritoglou C et al⁵⁸ evaluated the efficacy of bevacizumab for the treatment of diabetic macular edema in 51 consecutive patients with diffuse diabetic macular edema. Concluded that diffuse diabetic macular edema not responding to previous treatments such as photocoagulation, intravitreal injection of triamcinolone, or vitrectomy, improvement of visual acuity and decrease of retinal thickness could be observed after intravitreal injection

of bevacizumab. Although follow-up period was too short to provide specific treatment recommendations, the short-term results encourage further prospective studies with different treatment groups and longer follow-up.

Ranibizumab

Ranibizumab (Lucentis) is a 48 Kda, monoclonal antibody fragment (Fab) derived from the same parent murine antibody as bevacizumab (Avastin). It is much smaller than the parent molecule and has been affinity matured to provide stronger binding to VEGF-A. It is able to cross the internal limiting membrane and gain access in the sub-retinal space⁵⁹.

Description⁶⁰ - Ranibizumab is a sterile, colorless to pale yellow solution in a single-use glass vial. Ranibizumab is supplied as a preservative-free, sterile solution in a single-use glass vial designed to deliver 0.05 mL of 10 mg/mL It is a aqueous solution with 10 mM histidine HCl, 10% α,α -trehalose dihydrate, 0.01% polysorbate 20, pH 5.5.

Mechanism of action⁵⁹ - Ranibizumab is a recombinant humanized IgG1 kappa isotype monoclonal antibody fragment designed for intraocular use. Ranibizumab has a molecular weight of approximately 48 kilodaltons and is produced by an E. coli expression system in a nutrient medium containing the antibiotic tetracycline.

Tetracycline is not detectable in the final product. Ranibizumab binds to and inhibits the biologic activity of human vascular endothelial growth factor A (VEGF-A). Ranibizumab binds to the receptor binding site of active forms of VEGF-A, including the biologically active, cleaved form of this molecule, VEGF110. VEGF-A has been shown to cause neovascularization and leakage in models of ocular angiogenesis. The binding of ranibizumab to VEGF-A prevents the interaction of VEGF-A with its receptors (VEGFR1 and VEGFR2) on the surface of endothelial cells, reducing endothelial cell proliferation, vascular leakage, and new blood vessel formation.

Pharmacokinetics⁶⁰ - Although vitreous concentrations of ranibizumab declined in a monoexponential fashion with a half-life of 2.88 days, concentrations of >0.1 µg/ml ranibizumab were maintained in the vitreous humor for 29 days. Ranibizumab concentrations in the aqueous humor of the injected eye reached a peak concentration of 17.9 µg/ml, 3 days after drug administration. Elimination of ranibizumab from the aqueous humor paralleled that found in the vitreous humor, with a half-life value of 2.84 days. No ranibizumab was detected in the serum or the fellow eye.

Pharmacokinetics in Special population - The population pharmacokinetics of ranibizumab were analysed to evaluate the effects of demographic characteristics. The results showed no significant difference in the pharmacokinetics of ranibizumab in relation to age.

Pregnancy - Animal reproduction studies have not been conducted with ranibizumab. It is also not known whether ranibizumab can cause fetal harm when administered to a pregnant woman or can affect reproduction capacity.

Ranibizumab should be given to pregnant woman only if clearly indicated.

Nursing mothers – it is not known whether ranibizumab is excreted in human milk. Because many drugs are excreted in human milk, and because of the potential for absorption and harm to the infant growth and development exists, caution should be advised when ranibizumab is administered to nursing woman.

Pediatric use – safety and efficacy in paediatric patients has not been established.

Geriatric use - In the controlled clinical studies, approximately 94% (822/879) of the patients randomized to treatment with Ranibizumab were >65 years of age and approximately 68% (601/879) were >75 years of age. No notable difference in treatment effect was seen with increasing age in any of the studies. Age did not have a significant effect on systemic exposure in a population pharmacokinetic analysis after correcting for creatinine clearance.

Patients with Renal Impairment - No formal studies have been conducted to examine the pharmacokinetics of ranibizumab in patients with renal impairment. Sixty-eight percent of patients (136 of 200) in the population pharmacokinetic analysis had renal impairment (46.5% mild, 20% moderate, and 1.5% severe). Reduction in ranibizumab clearance is minimal in patients with renal impairment and is considered clinically insignificant. Dose adjustment is not expected to be needed for patients with renal impairment.

Patients with Hepatic Dysfunction - No formal studies have been conducted to examine the pharmacokinetics of ranibizumab in patients with hepatic impairment. Dose adjustment is not expected to be needed for patients with hepatic dysfunction.

Complications⁵⁹ - General complications – Cataract, Glaucoma, Vitreous Hemorrhage, Retinal detachment, Endophthalmitis.

Specific complications – thromboembolic episodes, conjunctival hemorrhage, eye pain, vitreous floaters, increased intraocular pressure, and intraocular inflammation.

Ranibizumab in various diseases

BRVO - Campochiaro PA et al¹⁶ evaluated efficacy and safety of intraocular injections of 0.3 mg or 0.5 mg ranibizumab in patients with macular edema following branch retinal vein occlusion (BRAVO TRIAL). A total of 397 patients with macular edema following BRVO were enrolled in the study. They found that Mean (95% confidence interval [CI]) change from baseline BCVA letter score at month 6 was 16.6 (14.7-18.5) and 18.3 (16.0-20.6) in the 0.3 mg and 0.5 mg ranibizumab groups and 7.3 (5.1-9.5) in the sham group (P<0.0001 for each ranibizumab group vs sham). The percentage of patients who gained > or =15 letters in BCVA at month 6 was 55.2% (0.3 mg) and 61.1% (0.5 mg) in the ranibizumab groups and 28.8% in the sham group (P<0.0001 for each ranibizumab group vs sham).

At month 6, significantly more ranibizumab-treated patients (0.3 mg, 67.9%; 0.5 mg, 64.9%) had BCVA of \geq 20/40 compared with sham patients (41.7%; $P < 0.0001$ for each ranibizumab group vs sham); and CFT had decreased by a mean of 337 microm (0.3 mg) and 345 microm (0.5 mg) in the ranibizumab groups and 158 microm in the sham group ($P < 0.0001$ for each ranibizumab group vs sham). The median percent reduction in excess foveal thickness at month 6 was 97.0% and 97.6% in 0.3 mg and 0.5 mg groups and 27.9% in the sham group. More patients in the sham group (54.5%) received rescue grid laser compared with the 0.3 mg (18.7%) and 0.5 mg (19.8%) ranibizumab groups. The safety profile was consistent with previous phase III ranibizumab trials, and no new safety events were identified in patients with BRVO. They concluded that Intraocular injections of 0.3 mg or 0.5 mg ranibizumab provided rapid, effective treatment for macular edema following BRVO with low rates of ocular and nonocular safety events.

Rouvas A et al¹⁷ evaluated the effect of individualized repeated intravitreal injections of ranibizumab on visual acuity and central foveal thickness (CFT) for branch retinal vein occlusion-induced macular edema. Twenty-eight eyes of 28 consecutive patients diagnosed with branch retinal vein occlusion-related macular edema treated with repeated intravitreal injections of ranibizumab (when CFT was > 225 microm) were evaluated. Optical coherence tomography and fluorescein angiography were performed monthly. The mean best-corrected distance visual acuity improved from 62.67 Early Treatment of Diabetic Retinopathy Study letters (logarithm of the minimum angle of resolution = 0.74 ± 0.28 [mean \pm standard deviation]) at baseline to 76.8 Early Treatment of Diabetic Retinopathy Study letters (logarithm of the minimum angle of resolution = 0.49 ± 0.3 ; statistically significant, $P <$

0.001) at the end of the follow-up (9 months). The mean letter gain (including the patients with stable and worse visual acuities) was 14.3 letters (2.9 lines). During the same period, 22 of the 28 eyes (78.6%) showed improved visual acuity, 4 (14.2%) had stable visual acuity, and 2 (7.14%) had worse visual acuity compared with baseline. The mean CFT improved from 349 +/- 112 microm at baseline to 229 +/- 44 microm (significant, $P < 0.001$) at the end of follow-up. A mean of six injections was performed during the follow-up period. Our subgroup analysis indicated that patients with worse visual acuity at presentation (≤ 50 letters in our series) showed greater visual benefit from treatment. "Rebound" macular edema was observed in 5 patients (17.85%) at the 3-month follow-up visit and in none at the 6- and 9-month follow-ups. In 18 of the 28 patients (53.6%), the CFT was < 225 microm at the last follow-up visit, and therefore, further treatment was not instituted. No ocular or systemic side effects were noted. They also concluded similar findings that Individualized repeated intravitreal injections of ranibizumab showed promising short-term results in visual acuity improvement and decrease in CFT in patients with macular edema associated with branch retinal vein occlusion.

CRVO - Brown DM et al⁶¹ also evaluated efficacy and safety of intraocular injections of 0.3 mg or 0.5 mg ranibizumab in patients with macular edema after central retinal vein occlusion (CRUISE TRIAL). A total of 392 patients with macular edema after CRVO were enrolled in the study. They found Mean (95% confidence interval [CI]) change from baseline BCVA letter score at month 6 was 12.7 (9.9-15.4) and 14.9 (12.6-17.2) in the 0.3 mg and 0.5 mg

ranibizumab groups, respectively, and 0.8 (-2.0 to 3.6) in the sham group ($P < 0.0001$ for each ranibizumab group vs. sham). The percentage of patients who gained $>$ or $= 15$ letters in BCVA at month 6 was 46.2% (0.3 mg) and 47.7% (0.5 mg) in the ranibizumab groups and 16.9% in the sham group ($P < 0.0001$ for each ranibizumab group vs. sham). At month 6, significantly more ranibizumab-treated patients (0.3 mg = 43.9%; 0.5 mg = 46.9%) had BCVA of $>$ or $= 20/40$ compared with sham patients (20.8%; $P < 0.0001$ for each ranibizumab group vs. sham), and CFT had decreased by a mean of 434 microm (0.3 mg) and 452 microm (0.5 mg) in the ranibizumab groups and 168 microm in the sham group ($P < 0.0001$ for each ranibizumab group vs. sham). The median percent reduction in excess foveal thickness at month 6 was 94.0% and 97.3% in the 0.3 mg and 0.5 mg groups, respectively, and 23.9% in the sham group. The safety profile was consistent with previous phase III ranibizumab trials, and no new safety events were identified in patients with CRVO. They finally concluded Intraocular injections of 0.3 mg or 0.5 mg ranibizumab provided rapid improvement in 6-month visual acuity and macular edema following CRVO, with low rates of ocular and nonocular safety events.

Diabetic retinopathy - Nguyen QD et al⁶² compared ranibizumab with focal/grid laser or a combination of both in diabetic macular edema (DME). They concluded that During a span of 6 months, ranibizumab injections by the current protocol had a significantly better visual outcome than focal/grid laser treatment in patients with DME.

MATERIALS AND METHODS

Study Design

- It is an investigative , open-label, randomized prospective interventional study done to collect the long-term efficacy and safety data in Indian patients with visual impairment due to macular edema secondary to branch retinal vein occlusion.

Inclusion Criteria

- Patients with macular edema due to BRVO (confirmed by fundus photography, fluorescein angiography, OCT)
- Male and female aged from 35 years and above
- Baseline best-corrected visual acuity (BCVA) in the study eye Study Eye < 6/12 using Snellen chart
- Central macular thickness on OCT >250 microns
- Patients willing to provide signed, written informed consent

Exclusion Criteria

- Additional eye disease that could compromise VA
- Ocular inflammation
- Intraocular surgery \leq 1 month before presentation
- Uncontrolled glaucoma
- Prior treatments with laser photocoagulation or other intervention for macular edema due to BRVO
- Pregnancy

Treatment Groups

- Ranibizumab group - Ranibizumab(single dose) + Laser.
- Bevacizumab group - Bevacizumab (single dose) + Laser.
- Laser group – Laser only.

Study Duration

6 months.

Methodology

All eligible patients were randomized to one of the three treatment group. Patients were followed until 6 months. Primary end point in this study was to assess the efficacy of ranibizumab 0.5 mg , by evaluating mean change from baseline in best-corrected visual acuity (BCVA). Secondary endpoints in this study included the evaluation of tolerability and safety of ranibizumab 0.5 mg , and the Best corrected Visual acuity on snellens chart, intraretinal thickness changes in Optical Coherence Tomography (OCT) and Intraocular safety of intravitreal injection of Ranibizumab in comparison to intravitreal Bevacizumab and laser.

Ethics

The design and methodology of the study were reviewed by the Institutional Review Board prior to the start of the investigation. In addition, written informed consent was obtained from each individual patient prior to enrolment in the study.

Number Of Patients

30 eyes of 30 patients with macular edema due to branch retinal vein occlusion were recruited and then randomized to one of the three treatment arms.

Population

Male or female outpatients, above 18 years of age, with macular edema secondary to branch retinal vein occlusion , as determined by the ophthalmologists .

Drug Used

Lucentis (Ranibizumab) 0.5 mg (0.05 ml volume) intravitreal injection.

Avastin (Bevacizumab) 1.25 mg (0.05 ml volume) intravitreal injection.

Procedure

- In Ranibizumab group - 0.05 ml of ranibizumab containing 0.5 mg of drug was injected intravitreally.
- In Bevacizumab group – 0.05 ml of bevacizumab containing 1.25mg of drug was injected intravitreally.
- Both Ranibizumab group and Bevacizumab group underwent one sitting of laser within 7 to 10 days of anti VEGF injection.
- In Laser group – 532 nm green laser photocoagulation was applied in a grid pattern. Parameters include a duration of 0.1 second & 100 micron diameter spot size.

Visit Schedule

During this visit 1 (baseline, Week 0), the patient's eligibility for the study was assessed according to the inclusion & exclusion criteria. At Visit 1, the following information was collected to allow adequate characterization of the disease and the patient's medical history;

Workup Parameters (Baseline and follow up)

- Best corrected visual acuity
- Slit lamp biomicroscopy
- Direct and indirect ophthalmoscopy
- IOP
- Clinical fundus photography
- Fundus fluorescein angiography
- Optical coherence tomography

Follow up of patients was done 1st, 3rd and 6 months.

Efficacy Parameters

The evidence of clinical efficacy was evaluated on the basis of mean change in BCVA and CFT at 6 months. Visual acuity (VA) measurement with snellen charts, intraretinal structure changes in OCT .This evaluation was done at various time points throughout the study as explained.

Definitions

Significant visual gain (Snellen's chart) = gain of ≥ 3 lines on Snellen's chart at 6 months from the baseline.

Significant visual gain (percentage) = gain of $\geq 200\%$ in terms of mean percentage change of BCVA(Decimals) at 6 months from baseline.

Significant decrease in macular thickness (microns) = reduction of ≥ 200 microns on OCT at 6 months from baseline.

Significant decrease in macular thickness (percentage) = reduction of $\geq 200\%$ in terms of mean percentage reduction of macular thickness on OCT at 6 months from baseline.

Retreatment requirement – loss of more than 1 line or increase in CFT more than 100 microns from previous visit..

Safety and Tolerability

Safety and Tolerability assessments (both ocular and systemic) was monitored and all adverse events and serious adverse events were recorded.

Statistical Analysis

Quantitative variables under primary & secondary endpoints, BCVA measurement (Decimals) , changes in intraretinal thickness on OCT (Microns) etc. (at baseline and follow-up visit's) was described in terms of their descriptive statistics (extreme values, Minimum and Maximum), Mean, Standard Deviation.

For the Quantitative variables (as described above) , Paired 't' test in case the variables did not follow normal distribution, was performed to assess the statistical significance of the differences between baseline and end of study under each group separately.

A percentage (%) change in secondary end point was computed between the base line and end of study and will be tested by Student 't' test.

For intergroup comparisons regarding above mentioned quantitative variables in case the variables did not follow normal distribution between the three treatment groups, one way analysis of variance (ANOVA) was done.

Differences between the gender distribution in the different study groups, differences between proportions of patients exhibiting , visual gain of ≥ 3 lines and differences between proportion of patients showing $\geq 200\%$ improvement in BCVA at 6 months, and $\geq 200\%$ reduction in CFT at 6 months, were assessed for significance by the Chi-square test with Yates correction.

In all the analysis, a probability (p) value of ≤ 0.05 was considered statistically significant.

RESULTS

This investigative, open-label, prospective randomized interventional study was performed at the retina clinic of a tertiary eye care facility in southern India over a period of 12 months (1st June 2009 to 31st May 2010). Thirty patients (30 eyes), comprising 12 males and 18 females (age range 38 to 74 years), who presented with macular edema due to BRVO during the study period, who satisfied the inclusion criteria and who provided consent for participation, were included in the study.

Upon presentation (baseline) and after ensuring that all investigational requirements were satisfied, each patient was randomly assigned (by random numbers) to one of three interventional groups : ranibizumab, bevacizumab or laser. Thus, each interventional group consisted of 10 patients (10 eyes). Patient demographics and baseline ocular characteristics did not differ significantly across all the interventional groups (Tables 1, 2 and 3).

Patients who were treated with ranibizumab ranged in age from 42 to 74 years, with a mean age of 58.8 ± 9.47 years, those treated with bevacizumab ranged in age from 38 to 68 years, with a mean age of 58.4 ± 8.55 years, and those treated with laser ranged in age from 38 to 69 years , with a mean age of $57.0 \pm (SD) 8.97$ years (Table 1, Fig. 1); these differences

were not statistically significant (one-way analysis of variance [ANOVA], degree of freedom [d.f.] =2; Fisher F-value=0.110; P=0.896).

Males comprised two (20%) of 10 patients who were treated with ranibizumab, six (60%) of 10 patients who were treated with bevacizumab and four (40%) of the 10 patients who were treated with laser (Table 2); these differences were not statistically significant (chi-square with Yates correction [d.f. = 5]= 3.33; P [2 tailed] =0.6487).

In addition to macular edema, 29 (97%) of the 30 study patients suffered from associated systemic diseases, namely hypertension and/or diabetes mellitus (Table 3). Thus, hypertension alone occurred in seven (70%), diabetes mellitus alone in one (10%) and hypertension and diabetes mellitus in two (20%) of 10 patients who were treated with ranibizumab; hypertension alone occurred in eight (80%) and hypertension and diabetes mellitus occurred in one (10%) of 10 patients who were treated with bevacizumab; hypertension alone occurred in seven (70%) and hypertension and diabetes mellitus in three (30%) of the 10 patients treated with laser (Table 3). These differences were not statistically significant.

One of the key outcomes assessed was the best corrected visual acuity (BCVA) in the three interventional groups at four different points of time: baseline (presentation), and one month, three months and six months after the intervention (Table 5). At baseline, the mean BCVA

(in decimals) in the ranibizumab, bevacizumab and laser treatment groups was 0.177 ± 0.085 , 0.1663 ± 0.103 and 0.21 ± 0.12 , respectively; these differences were not statistically significant (ANOVA [d.f.=2]; Fisher F-value= 0.48; P = 0.622). The same trend was observed at the subsequent points of time when patients were evaluated. At one month after intervention, the mean BCVA (in decimals) in the ranibizumab, bevacizumab and laser treatment groups was 0.397 ± 0.17 , 0.365 ± 0.23 and 0.38 ± 0.28 , respectively; these differences were not statistically significant (ANOVA [d.f.=2]; Fisher F-value= 0.048; P = 0.953). At three months following intervention, the mean BCVA (in decimals) in the ranibizumab, bevacizumab and laser treatment groups was 0.423 ± 0.13 , 0.337 ± 0.23 and 0.399 ± 0.28 , respectively; these differences were not statistically significant (one-way ANOVA [d.f.=2]; Fisher F-value= 0.399; P = 0.1). At six months following intervention, the mean BCVA (in decimals) in the ranibizumab, bevacizumab and laser treatment groups was 0.44 ± 0.12 , 0.38 ± 0.21 and 0.399 ± 0.28 , respectively; these differences were not statistically significant (ANOVA [d.f.=2]; Fisher F-value= 0.206; P = 0.815)(Table 5).

Thus, no significant inter-group differences were noted in BCVA achieved. However, there was a significant intragroup difference when the ranibizumab group was considered in its entirety (Table 5). In these patients, the mean BCVA (in decimals) at baseline and at one month, three months and six months after intervention was 0.177 ± 0.085 , 0.397 ± 0.17 , 0.423 ± 0.13 , and 0.44 ± 0.12 respectively; this difference was statistically significant (one-way ANOVA [d.f.=3]; Fisher F-value = 8.943; P= 0.000). Similarly, significant differences

were observed between the mean BCVA at baseline (0.177 ± 0.085 decimals) and that at one month (0.397 ± 0.17 decimals)(student `t`test [d.f.=18] = 3.6603; P[2-tailed]= 0.0018), between the baseline BCVA value and that at three months (0.423 ± 0.13 decimals) [student `t`test (d.f.=18) = 5.0084; P[2-tailed]= 0.0001) and between the baseline BCVA value and that at six months (0.44 ± 0.12 decimals) [student `t`test (d.f.=18) = 5.6556; P[2-tailed]= < 0.0001)(Table 5). In this group, there were no significant differences between the mean BCVA values at one month versus three months, one month versus six months , and three months versus six months(Table 5).

No significant intragroup difference in BCVA values was observed when the bevacizumab group was considered in its entirety(Table 5). In these patients, the mean BCVA (in decimals) at baseline and at one month, three months and six months after intervention was 0.1663 ± 0.103 , 0.365 ± 0.23 , 0.337 ± 0.23 , and 0.38 ± 0.21 respectively; this difference was not statistically significant (one-way ANOVA [d.f.=3]; Fisher F-value = 2.433; P=0.081). However, significant differences were observed between the mean BCVA at baseline (0.1663 ± 0.103 decimals) and that at one month (0.365 ± 0.23 decimals)(student `t`test [d.f.=18] = 2.4933; P[2-tailed]= 0.0266), between the baseline BCVA value and that at three months (0.337 ± 0.23 decimals) [student `t`test (d.f.=18) = 2.1420; P[2-tailed]= 0.0461) and between the baseline BCVA value and that at six months (0.38 ± 0.21 decimals) [student `t`test (d.f.=18) = 2.8892; P[2-tailed]= 0.0098). In this group (bevacizumab treated),

there were no significant differences between the mean BCVA values at one month versus three months, one month versus six months , and three months versus six months(Table 5).

With reference to the BCVA values in when the laser group was considered in its entirety, no significant intragroup difference in BCVA values was observed(Table 5). In the patients who received laser, the mean BVCA (in decimals) at baseline and at one month, three months and six months after intervention was 0.21 ± 0.12 , 0.38 ± 0.28 , 0.399 ± 0.280 , and 0.399 ± 0.28 , respectively; this difference was not statistically significant (one-way ANOVA [d.f.=3]; Fisher F-value = 1.350; P=0.274). There was also no significant difference between the mean BCVA at baseline (0.21 ± 0.12 decimals) and that at one month (0.38 ± 0.28 decimals)(student `t`test [d.f.=18] = 1.7647; P= 0.946), that at three months (0.399 ± 0.280 decimals) [student `t`test (d.f.=18) = 1.9619; P= 0.0654) and that at six months (0.399 ± 0.280 decimals) [student `t`test (d.f.=18) = 1.9619; P= 0.0654](Table 5).

Another key outcome assessed was the central foveal thickness (CFT) in the three interventional groups at four different points of time: baseline (presentation), and one month, three months and six months after the intervention (Table 6). At baseline, the mean CFT (in microns) in the ranibizumab, bevacizumab and laser treatment groups was 623.2 ± 328.04 , 561.2 ± 187 and 511 ± 135.52 respectively; these differences were not statistically significant (ANOVA [d.f.=2]; Fisher F-value= 0. 589; P = 0.562).

The same trend was observed at the subsequent points of time when patients were evaluated (Table 6). At one month after intervention, the mean CFT (in microns) in the ranibizumab, bevacizumab and laser treatment groups was 236.6 ± 126.37 , 254.3 ± 106.9 and 274.1 ± 83.41 respectively; these differences were not statistically significant (ANOVA [d.f.=2]; Fisher F-value= 0.307; P = 0.738). At three months following intervention, the mean CFT (in microns) in the ranibizumab, bevacizumab and laser treatment groups was 216.0 ± 69.12 , 284.7 ± 130.4 and 207.2 ± 39.52 , respectively; these differences were not statistically significant (one-way ANOVA [d.f.=2]; Fisher F-value= 2.314; P = 0.118). At six months following intervention, the mean CFT (in microns) in the ranibizumab, bevacizumab and laser treatment groups was 216.2 ± 63.85 , 241.0 ± 88.9 and 204.1 ± 38.34 , respectively; these differences were not statistically significant (ANOVA [d.f.=2]; Fisher F-value= 0.789; P = 0.464) (Table 6).

Thus, no significant inter-group differences were noted in the CFT. However, significant intragroup differences were noted when each of the treatment groups was considered in its entirety (Table 6). In the ranibizumab group, the mean CFT (in microns) at baseline and at one month, three months and six months after intervention was 623.2 ± 328.04 , 236.6 ± 126.37 , 216.0 ± 69.12 and 216.2 ± 63.85 , respectively; this difference was statistically significant (one-way ANOVA [d.f.=3]; Fisher F-value = 12.126; P= 0.000). Similarly, in this ranibizumab treated group, significant differences were observed between the mean CFT at baseline (623.2 ± 328.04 microns) and that at one month (236.6 ± 126.37 microns) (student

`t`test [d.f.=18] = 3.4777; P[2-tailed]= 0.0027), between the baseline CFT value and that at three months (216.0 ± 69.12 microns) [student `t`test (d.f.=18) = 3.8410; P[2-tailed]= 0.0012) and between the baseline CFT value and that at six months (216.2 ± 63.85 microns) [student `t`test (d.f.=18) = 3.8512; P[2-tailed]= 0.0012)(Table 6). In this ranibizumab treated group, there were no significant differences between the mean CFT values at one month versus three months, one month versus six months , and three months versus six months(Table 6).

A significant intragroup difference in mean CFT values was observed when the bevacizumab group was considered in its entirety(Table 6). In these patients, the mean CFT (in microns) at baseline and at one month, three months and six months after intervention was 561.2 ± 187.0, 254.3 ± 106.9, 284.7 ± 130.4 and 241.0 ± 88.9, respectively; this difference was statistically significant (one-way ANOVA [d.f.=3]; Fisher F-value = 12.911; P=0.000). In this bevacizumab-treated group, significant differences were also observed between the mean CFT at baseline (561.2 ± 187.0 microns) and that at one month (254.3 ± 106.9 microns)(student `t`test [d.f.=18] = 4.5056; P[2-tailed]= 0.0003), between the baseline CFT value and that at three months (284.7 ± 130.4 microns) [student `t`test (d.f.=18) = 3.8354; P[2-tailed]= 0.0012) and between the baseline CFT value and that at six months (241.0 ± 88.9 microns) [student `t`test (d.f.=18) = 4.8903; P[2-tailed]= 0.0001). In this group (bevacizumab-treated), there were no significant differences between the mean CFT values at one month versus three months, one month versus six months , and three months versus six months(Table 6).

With reference to mean CFT values in the laser group, a significant intragroup difference was observed (Table 6). The mean CFT (in microns) at baseline and at one month, three months and six months after intervention was 511 ± 135.52 , 274.1 ± 83.41 , 207.2 ± 39.52 and 204.1 ± 38.34 , respectively; this difference was statistically significant (one-way ANOVA [d.f.=3]; Fisher F-value = 29.623; P=0.000)(Table 6). There were also significant differences between the mean CFT at baseline (511 ± 135.52 microns) and that at one month (274.1 ± 83.41 microns)(student t'test [d.f.=18] = 4.7077; P [2-tailed]= 0.0002), between the baseline value and that at three months (207.2 ± 39.52 microns) [student t'test (d.f.=18) = 6.8055; P[2-tailed]= < 0.0001) and between the baseline value and that at six months (204.1 ± 38.34 microns) [student t'test (d.f.=18) = 6.890; P[2-tailed]= <0.0001)(Table 6). In this laser treated group there were also significant differences between the mean CFT at one month and that at three months (student t'test [d.f.=18] = 2.2921; P [2-tailed]= 0.0342) and between the mean CFT value at one month and that at six months [student t'test (d.f.=18) = 2.4113; P[2-tailed]= 0.0268); however, there was no significant difference between the mean CFT value at three months and that at six months [student t'test (d.f.=18) = 0.1780; P[2-tailed]= 0.8607)(Table 6).

Another outcome assessed was the visual gain, in terms of additional lines (compared to baseline) on the Snellen's chart that could be read (Table 4, Figure 7). At one month after intervention, six (60%) of 10 eyes in the ranibizumab group, three (30%) of 10 eyes in the bevacizumab group and two (20%) of 10 eyes in the laser group showed a visual gain of ≥ 3

lines on Snellen's chart (compared to baseline); these differences were statistically significant (chi square with Yates correction [d.f.=2] = 8.5; p = 0.02). At three months after intervention, six (60%) of 10 eyes in the ranibizumab group, two (20%) of 10 eyes in the bevacizumab group and two (20%) of 10 eyes in the laser group showed a visual gain of ≥ 3 lines on Snellen's chart (compared to baseline); these differences approached statistical significance (chi square with Yates correction [d.f.=2] = 2.48; p = 0.08). At six months after intervention, six (60%) of 10 eyes in the ranibizumab group, four (40%) of 10 eyes in the bevacizumab group and two (20%) of 10 eyes in the laser group showed a visual gain of ≥ 3 lines on Snellen's chart (compared to baseline); these differences approached statistical significance (chi square with Yates correction [d.f.=2] = 3.4; p = 0.06).

An additional outcome evaluated was the mean percentage of improvement of BCVA at six months, in comparison with baseline BCVA, in the different study groups (Table 7). The mean percentage of improvement of BCVA at six months, when compared to baseline BCVA, was found to be (%) 313.6 ± 171.2 , 270.8 ± 178.2 and 191.9 ± 64.5 in the ranibizumab-treated, bevacizumab-treated and laser-treated eyes, respectively; these differences were not statistically significant across the three groups (one-way ANOVA [d.f.]=2, Fisher F-value= 1.745; P [2-tailed]= 0.194) (Table7). Similarly, no significant differences were observed in the mean percentage of improvement in BCVA between laser and bevacizumab groups (student 't' [d.f.=18]= 1.3165; P [2-tailed]= 0.2045) and no significant differences were observed in the mean percentage of improvement in BCVA

between bevacizumab and ranibizumab groups (student 't' [d.f.=18]= 0.5463; P [2-tailed]= 0.5915). However, the difference between mean percentage of improvement in BCVA between laser and ranibizumab groups approached statistical significance (student 't' [d.f.=18]= 2.09; P (2-tailed)= 0.0507).

An assessment was made of the proportion of patients (eyes) showing ≥ 200 percent improvement in best corrected visual acuity (calculated by comparing 6 month values with baseline values) in the different study groups (Table 8); this worked out to ten (100%) of 10 eyes in the ranibizumab-treated group, seven (70%) of 10 eyes in the bevacizumab-treated group and four (40%) of 10 eyes in the laser –treated group; these differences were statistically significant (chi-square test with Yates' correction [d. f. =2] = 8.58; P [2-tailed]= 0.0346).

An additional outcome evaluated was the mean percentage of reduction in CFT at six months, in comparison with baseline CFT, in the different study groups (Table 7). The mean percentage of reduction of CFT at six months, when compared to baseline CFT, was found to be (%) 279.7 ± 60.53 , 239.2 ± 55.3 and 249.8 ± 42.9 in the ranibizumab-treated, bevacizumab-treated and laser-treated eyes, respectively; these differences were not statistically significant across the three groups (one-way ANOVA [d.f.]=2, Fisher F-value= 1.545; P [2-tailed]= 0.231) (Table7).

Similarly, no significant differences were observed in the mean percentage of reduction of CFT between laser and bevacizumab groups (student 't' [d.f.=18]= 0.4789; P [2-tailed]= 0.6378), between laser and ranibizumab groups(student 't' (d.f.=18)= 1.2744; P (2-tailed)= 0.2187) and between bevacizumab and ranibizumab groups (student 't' [d.f.=18]= 1.5621; P [2-tailed]= 0.1357).

An assessment was made of the proportion of patients (eyes) showing ≥ 200 percent reduction in central foveal thickness (calculated by comparing 6 month values with baseline values) in the different study groups (Table 9); this worked out to nine (90%) of 10 eyes in the ranibizumab-treated group, eight (80%) of 10 eyes in the bevacizumab-treated group and nine (90%) of 10 eyes in the laser – treated group; these differences were not statistically significant (chi-square test with Yates' correction [d. f. =2] = 1.34; P [2-tailed] > 0.05).

DISCUSSION

Branch retinal vein occlusion (BRVO) is the second most common cause of retinal pathology after diabetic retinopathy^{1,2}. In most patients, macular edema is the predominant cause of visual loss although severe non-perfusion of perifoveal capillaries is an additional source of reduced vision⁷. Elevated intra ocular levels of VEGF have been demonstrated in eyes with BRVO and this has been linked to vascular leakage^{8,9}. Thus there is a strong rationale for using VEGF antagonists in eyes with macular edema following BRVO.

The present study was a randomized prospective interventional study comparing intravitreal ranibizumab, intravitreal bevacizumab and laser photocoagulation for the treatment of macular edema following BRVO. Each treatment group had 10 patients (10 eyes). There was no statistical differences between the three groups in age or gender distribution and in presence of associated systemic diseases (Table 1, 2 and 3). Thus for all practical purposes, the three groups were matched. All three interventions yielded improvement in visual acuity (Table 5) as well as reduction in CFT (as assessed by OCT)(Table 6) although the amount and speed of improvement differed markedly in these groups.

Both groups where intravitreal ranibizumab and intravitreal bevacizumab were used showed a rapid resolution of macular edema with improvement in visual acuity (Table 5). Other studies¹¹⁻¹³ have also shown that blocking VEGF with intravitreal anti-VEGF agents has a rapid and beneficial effect on visual function. This effect has been attributed to the reduction in vascular leakage that is mediated by VEGF.

The largest study¹⁶ to date involving ranibizumab for macular edema following BRVO (BRAVO study) found that an intraocular injection of 0.3 or 0.5 mg of ranibizumab provided a rapid, effective treatment for macular edema due to BRVO. The BRAVO study utilized a monthly injection of ranibizumab for 6 months, with option of rescue laser beginning from three months if eligible. Rescue laser eligibility was defined as clearing of haemorrhage with visual acuity of <6/12 or CFT > 250 microns¹⁶. In the present study however, a different protocol was used. All patients received anti VEGF agents at the first visit, followed by laser after 7-10 days as soon as a clear view on FFA was obtained. This was performed for 2 reasons:

- 1) to reduce the number of intravitreal injections required, thereby reducing the cost of treatment and circumventing potential adverse effects of intravitreal injections;
- 2) to provide permanent reduction in vascular leakage by photocoagulating areas of leakage as compared to the temporary effects of anti-VEGF agents.

The degree of improvement in visual acuity and reduction in CFT in the present study, where intravitreal ranibizumab was used (Table 7, 8, 9), was comparable to the BRAVO study thereby validating the efficacy of the treatment protocol used in the present study.

Although several studies have found intravitreal bevacizumab to be effective in reducing macular edema secondary to BRVO¹¹⁻¹³, it is believed that no study has compared the efficacy of intravitreal ranibizumab and bevacizumab. Intravitreal ranibizumab appeared more effective than bevacizumab in terms of final visual outcome (Table 5), and visual gain as Snellen lines at the one month, third month and sixth month follow-ups (Table 4). Similarly the reduction in central foveal thickness in ranibizumab treated patients, compared to bevacizumab and laser treated patients suggests that a larger sample size will produce a statistically significant outcome. The reason for the greater efficacy of ranibizumab is probably related to smaller molecular size, allowing rapid penetration through the retinal layers as well as greater affinity for VEGF established by ranibizumab⁵⁹.

Although laser is the current gold standard for treatment of macular edema due to BRVO, the BVO study¹⁰ found a modest improvement in patients treated with laser photocoagulation. Laser treatment cannot be given to patients with fresh venous occlusions owing to retinal haemorrhages and it takes several months for the haemorrhages to clear. During this time, severe retinal edema could compromise retinal cells leading to permanent structural damage.

Both improvement in visual acuity and reduction in central foveal thickness appeared to be better in eyes that had received intravitreal ranibizumab therapy as compared to eyes treated with laser alone during the entire study (Table 4, 5, 6, 7, 8, 9). Laser appears to have a definite role in treating macular edema due to BRVO as it produces a permanent stoppage of vascular leakage as compared to the temporary effects of intravitreal injections. Thus, use of laser could reduce need for repeated intravitreal injections.

No significant ocular or systemic side-effects were observed in patients who received intravitreal injections of ranibizumab or bevacizumab. The safety of anti VEGF agents has been documented in other studies also. However, any intravitreal injection follows a small but definite risk of complications such as retinal tears, endophthalmitis and cataract and it would seem wise to limit the number of intravitreal injections to the barest required. Moreover, when assessing the safety of a medication, the 'rule of three' should be kept in mind⁶³. This rule states that if none of the 'n' patients has the adverse effect in question, then there can be a reasonable confidence interval (95%) that the true rate of this event in the population is no more than 3 in 'n' (3/n). Thus in the present study, where 20 patients received anti-VEGF agents (10 ranibizumab group and 10 bevacizumab group), the true rate of the adverse event in question in the population is about 3/20 or 15%. Hence, more detailed studies on larger number of patients is needed to confirm the safety of these anti-VEGF agents. However, the results of the present study are certainly promising, since the confidence in the efficacy of a treatment or management approach is enhanced if the results are based on a prospective randomized trial as in the case of the present study⁶⁴.

CONCLUSION

Branch retinal vein occlusion (BRVO) is the one of the most common cause of retinal pathology after diabetic retinopathy. In most patients, macular edema is the predominant cause of visual loss although severe non-perfusion of perifoveal capillaries is an additional source of reduced vision. Elevated intra-ocular levels of VEGF have been demonstrated in eyes with BRVO and this has been linked to vascular leakage. Thus, there is a strong rationale for using VEGF antagonists such as ranibizumab and bevacizumab in eyes with macular edema following BRVO.

Although the effect of anti VEGF agents is very rapid and dramatic, the effect is short-lived and repeated injections are required which, in turn, increases the cost of treatment. If the permanent effects of laser (i.e. permanent stoppage of vascular leakage as compared to the temporary effects of intravitreal injections) can be combined with the rapid (but temporary) effect of intravitreal injections of anti-VEGF agents, then it not only reduces the number of intravitreal injections but also reduces the financial burden of treatment, which is very important in developing countries like India.

In conclusion, both ranibizumab and bevacizumab treatment in macular edema due to BRVO result in gain in visual acuity and reduction in intraretinal thickness which occurs rapidly. However, these anti-VEGF agents should always be combined with a more permanent treatment such as laser photocoagulation, which would yield much better results than any single mode of treatment alone.

SUMMARY

Ranibizumab is a recently-described molecule that exhibits an antagonistic action on vascular endothelial growth factor (VEGF). Therefore, it is potentially useful in the management of macular edema that follows branch retinal vein occlusion (BRVO). The aim of the study described in this dissertation was to demonstrate the efficacy of ranibizumab (0.5 mg, intravitreal injection) over a six-month treatment period in eyes with macular edema due to BRVO. Primary measures of efficacy demonstrated during the study period were a) an improvement in mean best corrected visual acuity (BCVA) and b) a reduction in mean central foveal thickness (CFT) , as assessed by optical coherence tomography (OCT).

This investigation was an open-label, prospective randomized interventional study which was performed at the retina clinic of a tertiary eye care facility in southern India over a period of 12 months (1st June 2009 to 31st May 2010). Thirty patients (30 eyes), comprising 12 males and 18 females (age range 38 to 74 years), who presented with macular edema due to BRVO during the study period, who satisfied the inclusion criteria and who provided consent for participation, were enrolled in the study. Upon presentation (baseline) and after ensuring that all investigational requirements were satisfied, each patient was randomly assigned to one of three interventional groups, namely ranibizumab, bevacizumab or laser. Thus, each interventional group consisted of 10 patients (10 eyes).

Patient demographics (age, gender, associated systemic diseases) and baseline ocular characteristics did not differ significantly across all the interventional groups. The mean age of the patients in the ranibizumab-treated, bevacizumab treated and laser-treated groups was 58.8 ± 9.47 years (range 42 to 74), $58.4 \pm (SD) 8.55$ years (range 38 to 68 years) and 57.0 ± 8.97 years (range 38 to 69 years), respectively; these differences were not statistically significant. Males comprised two (20%), six (60%) and four (40%) of the patients in the ranibizumab-treated, bevacizumab-treated and laser-treated groups, respectively (differences not statistically significant). In addition to macular edema, 29 (97%) of the 30 study patients suffered from associated systemic diseases, namely hypertension alone (in 70%, 80% and 70% of patients treated with ranibizumab, bevacizumab or laser, respectively), diabetes mellitus only (in 10% of ranibizumab-treated patients) and hypertension and diabetes mellitus (in 20%, 10% and 30% of patients treated with ranibizumab, bevacizumab or laser, respectively)(differences not statistically significant).

The mean BCVA in the three interventional groups was assessed at baseline (presentation), and one month, three months and six months after intervention. At baseline, there was no significant difference in the mean BCVA (decimals) between the ranibizumab, bevacizumab and laser treatment groups (0.177 ± 0.085 , 0.1663 ± 0.103 and 0.21 ± 0.12 , respectively). The same trend was observed at each of the subsequent follow-up visits. At one month follow-up, the mean BCVA (in decimals) in the ranibizumab, bevacizumab and laser treatment groups was 0.397 ± 0.17 , 0.365 ± 0.23 and 0.38 ± 0.28 , respectively [differences

not statistically significant]). At the third month follow-up, the mean BCVA (in decimals) in the ranibizumab, bevacizumab and laser treatment groups was 0.423 ± 0.13 , 0.337 ± 0.23 and 0.399 ± 0.28 , respectively (differences not statistically significant). At the sixth month follow-up, the mean BCVA (in decimals) in the ranibizumab, bevacizumab and laser treatment groups was 0.44 ± 0.12 , 0.38 ± 0.21 and 0.399 ± 0.28 , respectively (differences not statistically significant). Thus, no significant inter-group differences were noted in BCVA achieved.

Significant intragroup differences in BCVA values were noted in the ranibizumab group, both when the group was considered in its entirety (across all follow-up times) and between the baseline mean BCVA and that at one month, three month and sixth month follow-ups. In this group, there were no significant differences between the mean BCVA values at one month versus three months, one month versus six months, and three months versus six months. No significant intragroup difference in BCVA values was observed when the bevacizumab group was considered in its entirety (across all follow-up times). However, significant differences were observed between the mean BCVA at baseline and that at one month, three months and six months. In this group, there were no significant differences between the mean BCVA values at one month versus three months, one month versus six months, and three months versus six months. Similarly, there was no significant intragroup difference when the laser group was considered in its entirety.

There was also no significant difference between the mean BCVA at baseline and that at one month, three months and six months.

The mean CFT was also assessed in the three interventional groups at baseline (presentation), and one month, three month and six month follow-up visits. At baseline, the mean CFT (in microns) in the ranibizumab, bevacizumab and laser treatment groups (623.2 ± 328.04 , 561.2 ± 187 and 511 ± 135.52 , respectively) did not differ significantly. The same trend was observed at each of the subsequent follow-up visits. At the one month follow-up visit, the mean CFT (in microns) in the ranibizumab, bevacizumab and laser treatment groups was 236.6 ± 126.37 , 254.3 ± 106.9 and 274.1 ± 83.41 (differences not statistically significant). At the third month follow-up, the mean CFT(in microns) in the ranibizumab, bevacizumab and laser treatment group was 216.0 ± 69.12 , 284.7 ± 130.4 and 207.2 ± 39.52 , respectively(differences not statistically significant). At six months following intervention, the mean CFT (in microns) in the ranibizumab, bevacizumab and laser treatment groups was 216.2 ± 63.85 , 241.0 ± 88.9 and 204.1 ± 38.34 respectively (differences not statistically significant). Thus, no significant inter-group differences were noted in the mean CFT.

Significant intragroup differences in mean CFT were noted when each of the treatment groups was considered in its entirety (across all follow-up times). Significant intragroup differences in mean CFT values were noted in the ranibizumab, bevacizumab and laser treatment groups, both when each group was considered in its entirety (across all follow-up

times) and between the baseline mean CFT value and that at one month, three month and sixth month follow-ups. There were also significant differences between the mean CFT at one month and that at three months and six months in the laser treatment group. However, there was no significant difference between the mean CFT value at three months and that at six months in the laser treatment group, and also no significant differences between mean CFT values at one month, three months and six months in the ranibizumab-treated and bevacizumab-treated groups.

Visual gain in terms of additional lines (compared to baseline) on the Snellen's chart that could be read was assessed at baseline and at six months (Table 4, Figure 7). At one month after intervention, six (60%) of 10 eyes in the ranibizumab group, three (30%) of 10 eyes in the bevacizumab group and two (20%) of 10 eyes in the laser group showed a visual gain of ≥ 3 lines on Snellen's chart (compared to baseline); these differences were statistically significant. At three months after intervention, six (60%) of 10 eyes in the ranibizumab group, two (20%) of 10 eyes in the bevacizumab group and two (20%) of 10 eyes in the laser group showed a visual gain of ≥ 3 lines on Snellen's chart (compared to baseline); these differences approached statistical significance. At six months after intervention, six (60%) of 10 eyes in the ranibizumab group, four (40%) of 10 eyes in the bevacizumab group and two (20%) of 10 eyes in the laser group showed a visual gain of ≥ 3 lines on Snellen's chart (compared to baseline); these differences approached statistical significance.

There were no significant differences between the ranibizumab-treated, bevacizumab-treated and laser-treated groups when the mean percentage of improvement of BCVA at six months, in comparison with baseline BCVA, was assessed. However, the difference between mean percentage of improvement in BCVA between laser and ranibizumab groups approached statistical significance.

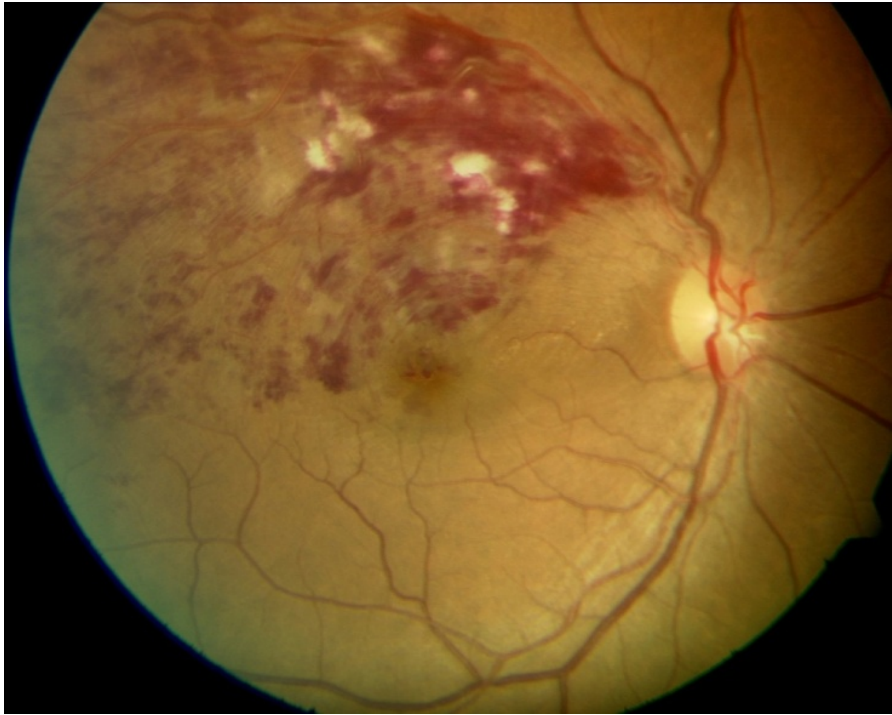
An assessment was made of the proportion of patients (eyes) showing ≥ 200 percent improvement in BCVA (calculated by comparing 6 month values with baseline values) in the different study groups ; this worked out to all 10 eyes (100%) in the ranibizumab –treated group, seven (70%) of 10 eyes in the bevacizumab-treated group and four (40%) of 10 eyes in the laser-treated group; these differences were statistically significant.

There was no significant differences between the study groups in the mean percentage of reduction of CFT at six months, in comparison with baseline CFT. Similarly, no significant differences were observed in the mean percentage of reduction of CFT between laser and bevacizumab groups, between laser and ranibizumab groups and between bevacizumab and ranibizumab groups.

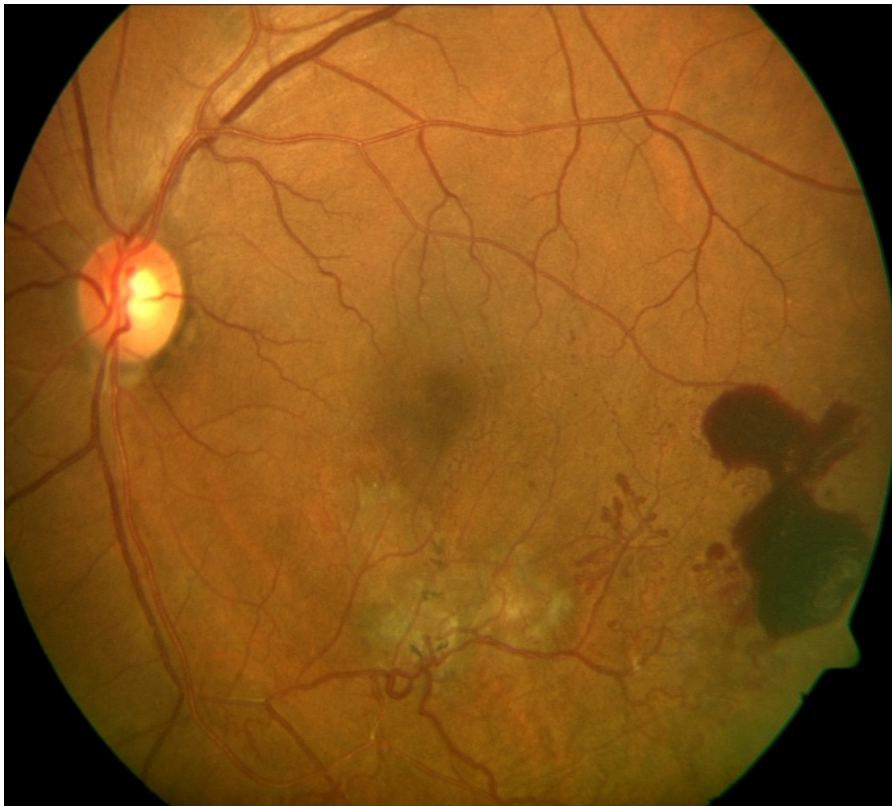
An assessment was made of the proportion of patients (eyes) showing ≥ 200 percent reduction in central foveal thickness (calculated by comparing 6 month values with baseline values) in the different study groups; this worked out to nine (90%) of 10 eyes in the laser-treated group, eight (80%) of 10 eyes in the bevacizumab-treated group and nine (90%) of 10 eyes in the ranibizumab – treated group; these differences were not statistically significant.

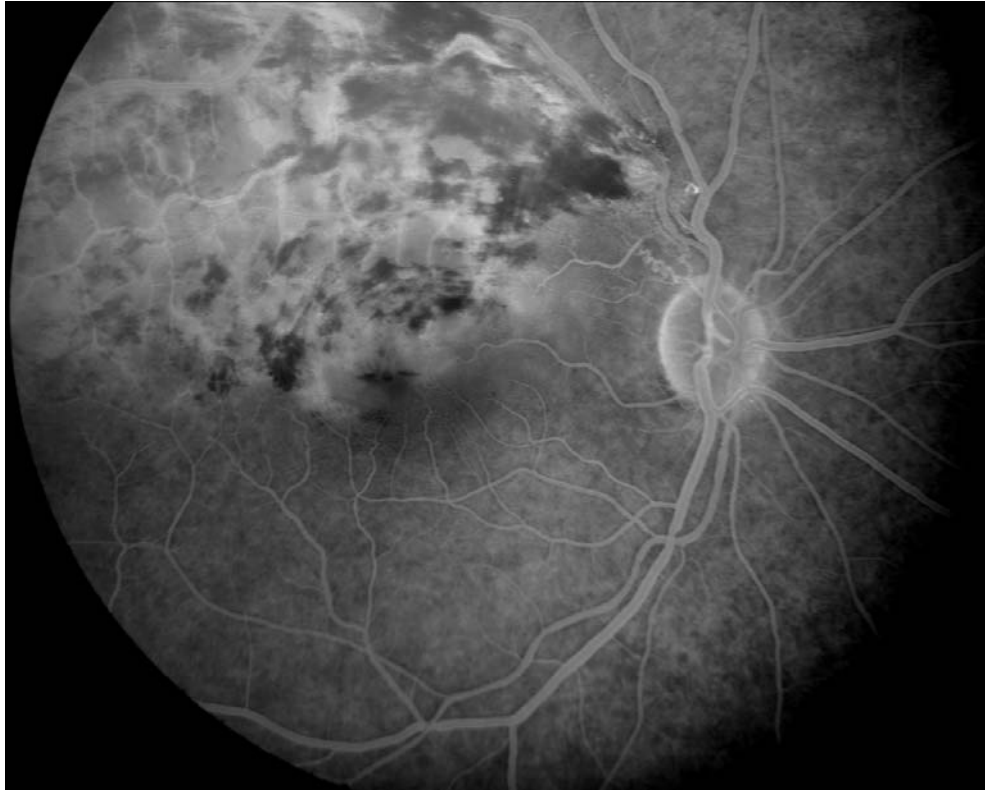Overall, intravitreal ranibizumab appeared to be more efficacious than bevacizumab in terms of final visual outcome and reduction in CFT. Although these differences were not statistically significant, the differences were notable enough to suggest that a larger sample size would yield statistically significant differences in outcome. A possible reason for the putative greater efficacy of ranibizumab is possibly related to its smaller molecular size, allowing rapid penetration through the retinal layers as well as greater affinity for VEGF.

It was also observed that both improvement in visual acuity and reduction in CFT were more notable in eyes that had received intravitreal anti-VEGF therapy (ranibizumab or bevacizumab) than in eyes that had received laser alone. However, laser appears to have a definite role in treating macular edema arising out of BRVO as it produces a permanent stoppage of vascular leakage, compared to the temporary effects of intravitreal injections. Thus, use of laser could reduce the need for repeated intravitreal injections.

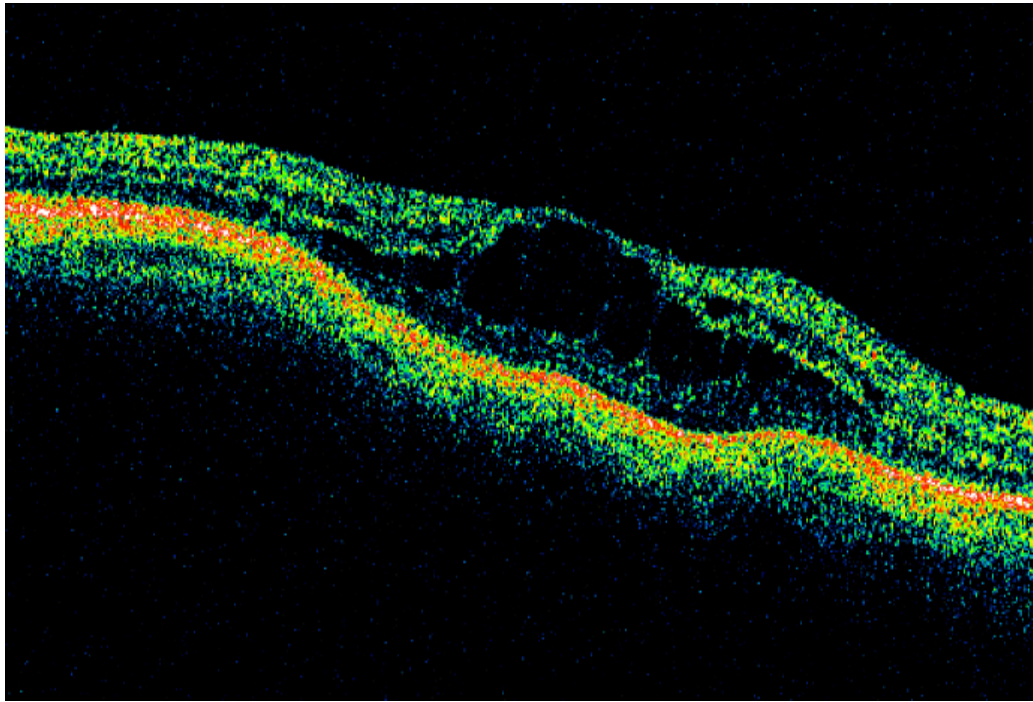


BRVO

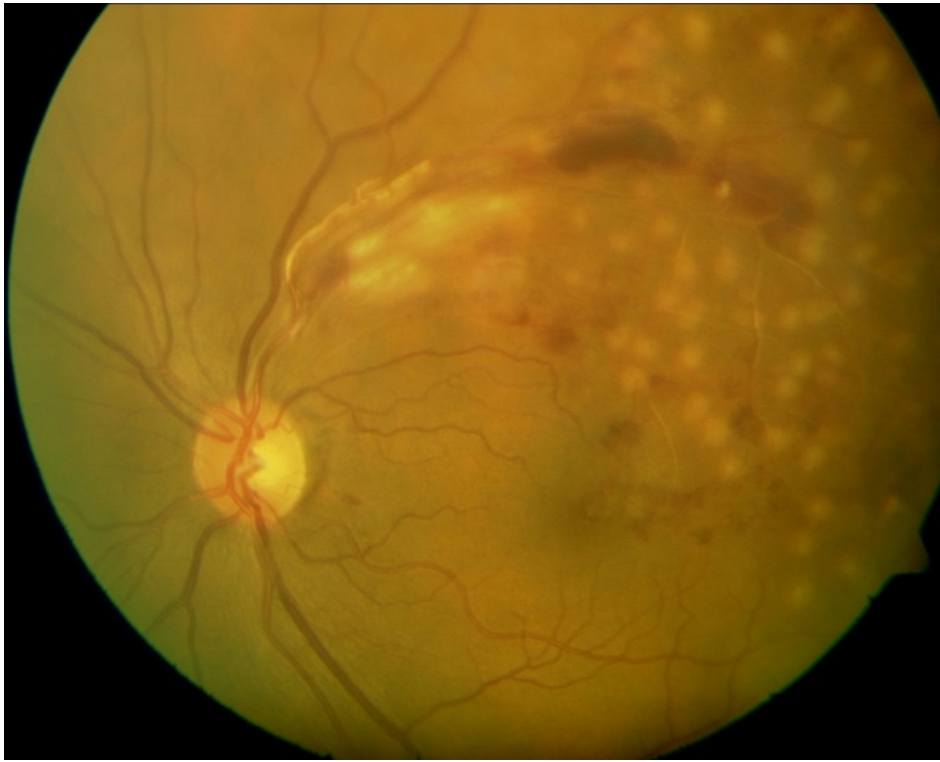




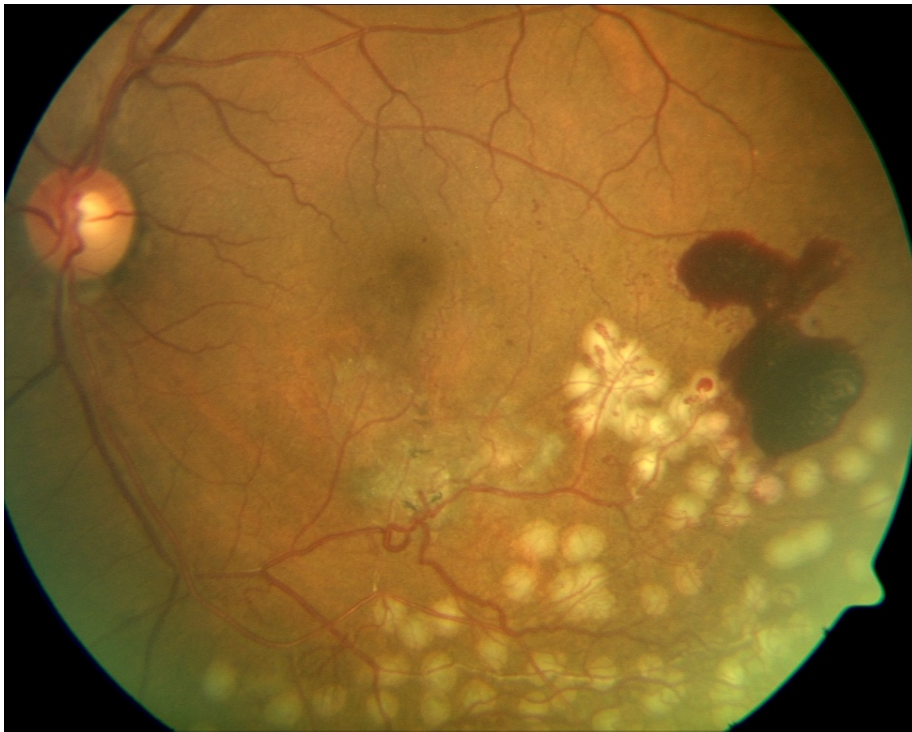
FFA

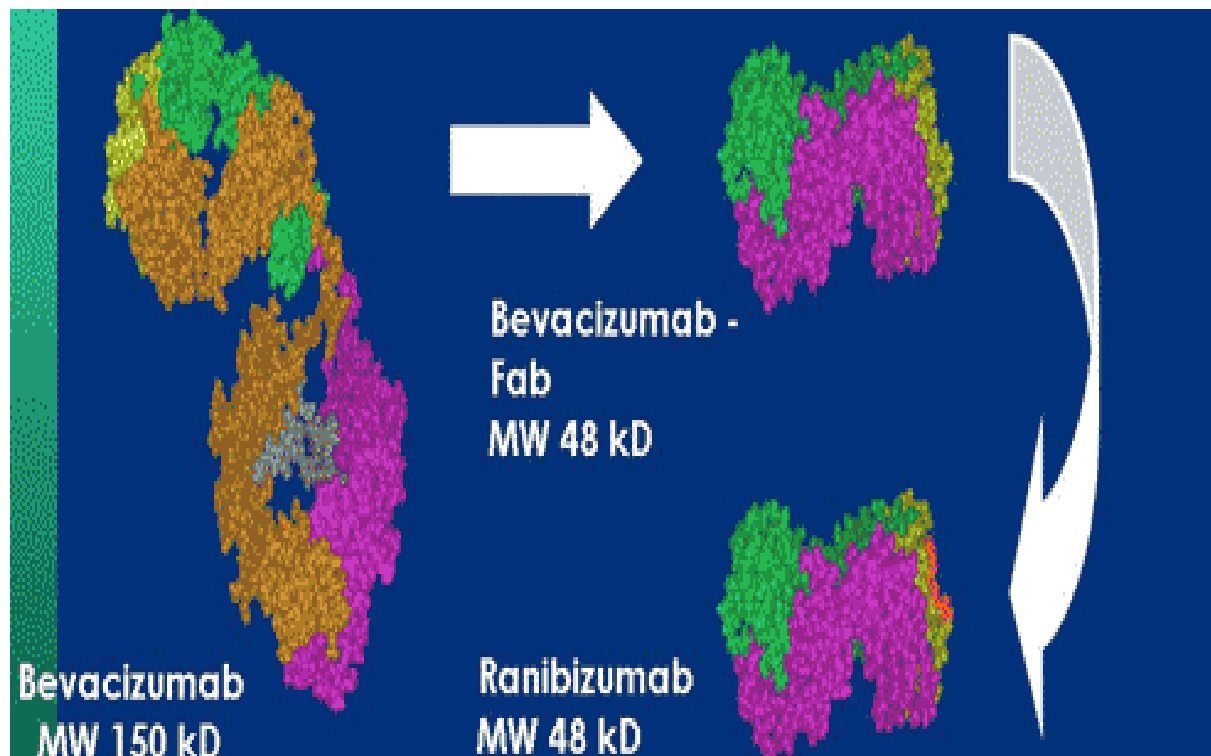


OCT

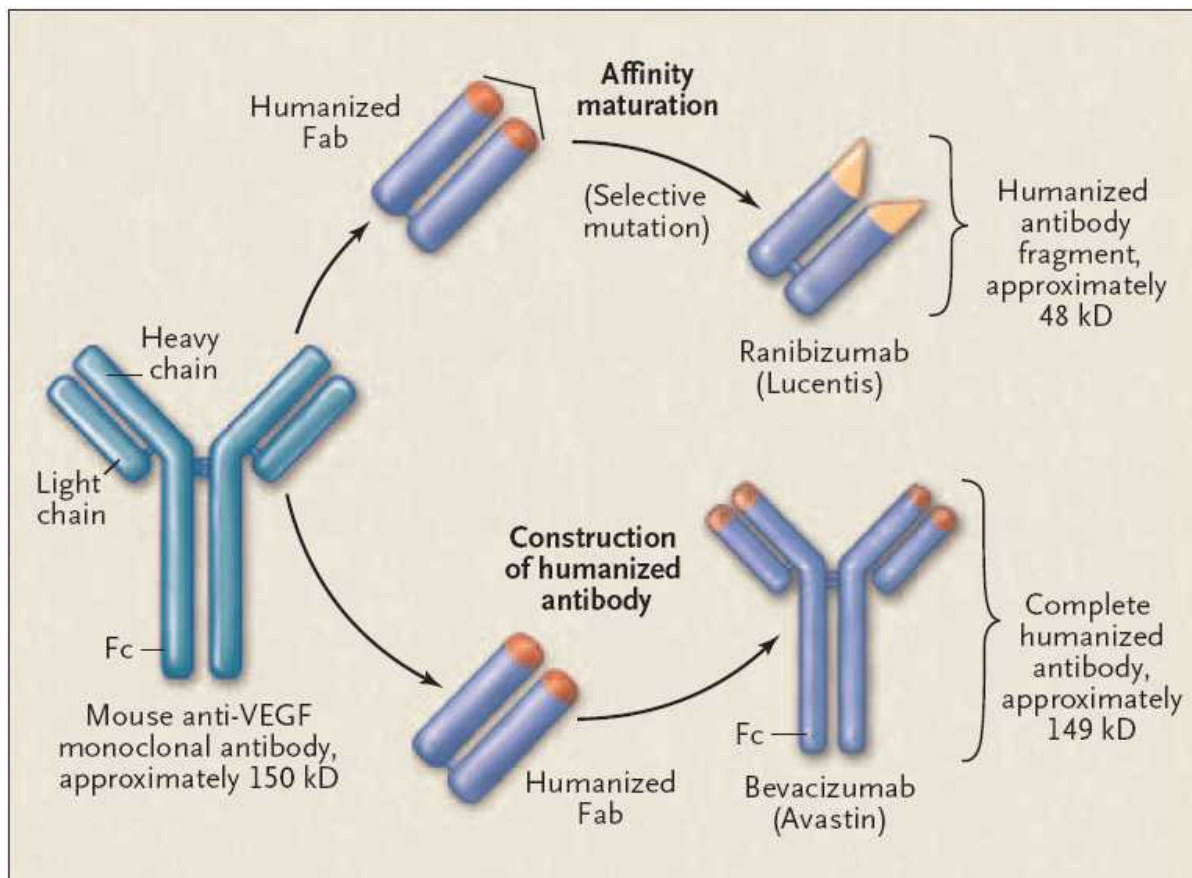


LASER



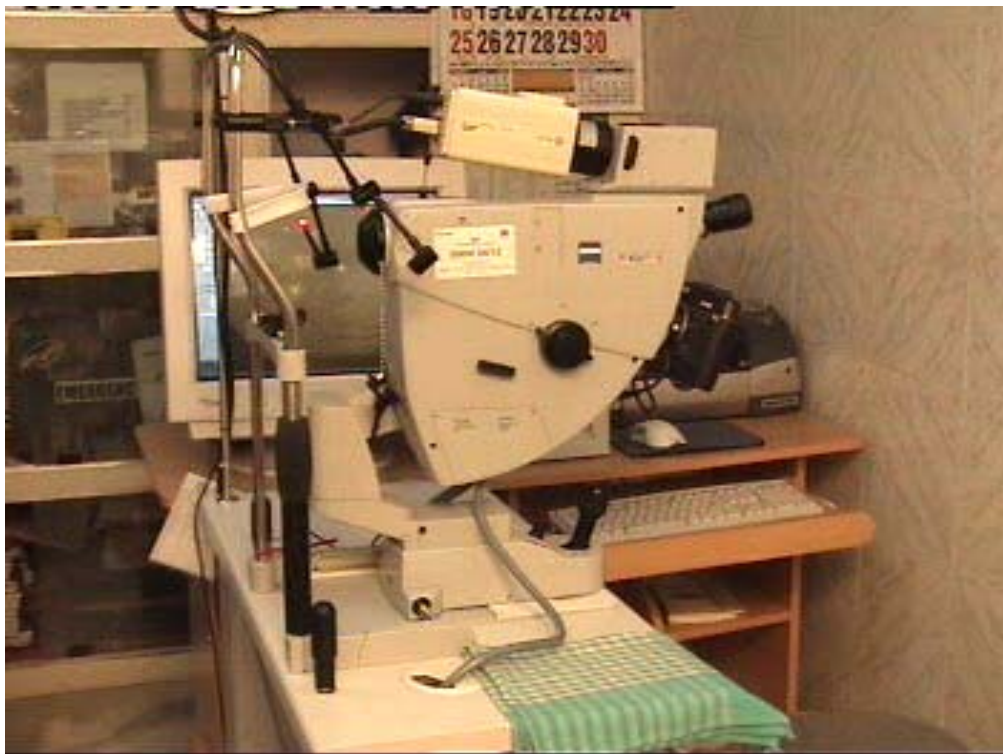

RANIBIZUMAB VS BEVACIZUMAB

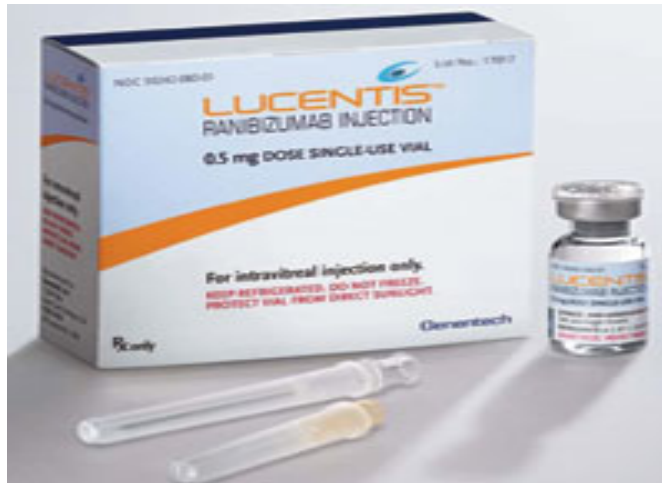



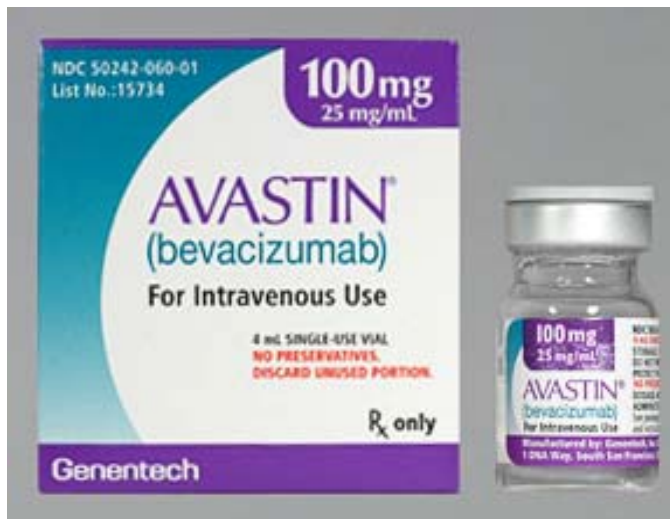OCT



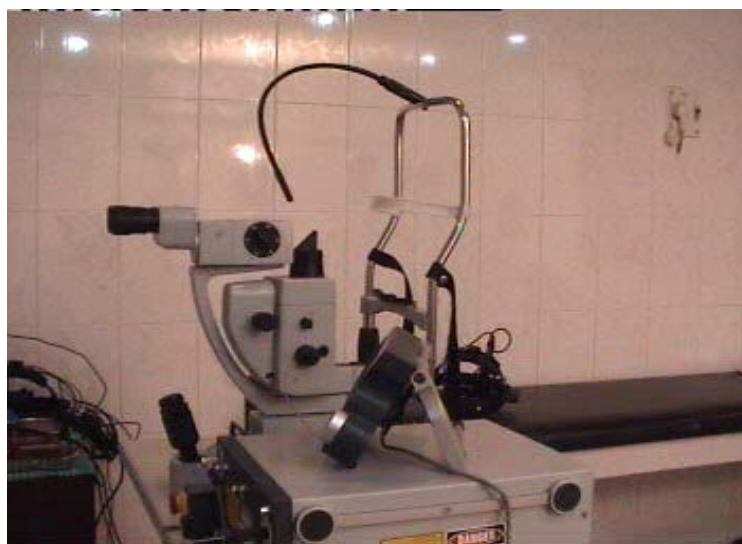FFA



RANIBIZUMAB



BEVACIZUMAB



LASER

RANIBIZUMAB GROUP

MR NO.	Age	Sex	Asso disease	BCVA (0)	CFT (0)	BCVA (1m)	CFT (1m)	BCVA (3m)	CFT (3m)	BCVA (6m)	CFT (6m)	Dose
767636	60	F	HT	0.25	615	0.5	191	0.5	216	0.5	255	1
562304	63	F	HT	0.25	396	0.5	220	0.5	221	0.5	205	1
638301	74	M	HT	0.1	384	0.16	123	0.5	156	0.5	160	1
745383	58	F	HT/DM	0.05	1527	0.25	583	0.25	404	0.25	383	1
749703	52	F	HT	0.25	500	0.66	175	0.5	181	0.5	184	1
757956	50	F	HT	0.16	634	0.33	184	0.33	179	0.33	180	1
755804	42	F	HT	0.05	564	0.25	205	0.33	183	0.33	180	1
748654	55	F	HT/DM	0.25	511	0.66	220	0.66	214	0.66	210	1
607917	66	F	HT	0.16	570	0.33	215	0.33	205	0.33	201	1
754311	68	M	DM	0.25	531	0.33	250	0.33	201	0.5	204	1
MEAN	58.8			0.177	623.2	0.397	236.6	0.423	216	0.44	216.2	1

BEVACIZUMAB GROUP

MR NO.	Age	Sex	Asso disease	BCVA (0)	CFT (0)	BCVA (1M)	CFT(1M)	BCVA(3M)	CFT(3M)	BCVA (6M)	CFT (6M)	DOSE
750670	59	M	HT/DM	0.16	343	0.5	190	0.16	527	0.5	221	2
756364	53	F	HT	0.033	558	0.1	350	0.16	289	0.25	189	1
754145	63	M	none	0.16	645	0.25	230	0.25	244	0.25	240	1
715979	65	F	HT	0.1	703	0.25	509	0.25	480	0.25	447	1
737718	68	M	HT	0.33	576	0.66	200	0.66	210	0.66	220	1
749038	60	F	HT	0.1	378	0.16	160	0.16	165	0.16	170	1
734730	54	M	HT	0.1	648	0.25	202	0.25	200	0.25	202	1
784728	64	M	HT	0.33	398	0.66	197	0.66	167	0.66	170	1
761620	38	M	HT	0.25	414	0.66	197	0.66	200	0.66	201	1
777358	60	F	HT	0.1	949	0.16	308	0.16	365	0.16	350	1
Mean=	58.4			0.1663	561.2	0.365	254.3	0.337	284.7	0.38	241	1.1

LASER GROUP

MR NO.	Age	Sex	Asso disease	BCVA(0)	CFT (0)	BCVA (1m)	CFT (1m)	BCVA (3m)	CFT (3m)	BCVA (6m)	CFT (6m)	LASER
718470	65	M	HTN	0.33	626	0.5	305	0.5	199	0.5	193	1
756760	60	M	HT/DM	0.33	388	1	179	1	180	1	164	1
730002	69	F	HT	0.33	410	0.33	252	0.5	170	0.5	164	1
727875	55	F	HT	0.16	405	0.33	230	0.33	148	0.33	179	1
745938	57	F	HT/DM	0.083	576	0.1	367	0.1	280	0.1	250	1
723630	38	F	HT	0.083	474	0.1	221	0.16	208	0.16	166	1
721118	52	M	HT/DM	0.25	648	0.33	428	0.33	220	0.33	250	1
744648	65	F	HT	0.1	751	0.16	343	0.16	243	0.16	256	1
730243	59	M	HT	0.33	328	0.66	180	0.66	184	0.66	189	1
715065	50	F	HT	0.083	504	0.25	236	0.25	240	0.25	230	1
Mean =	57			0.2079	511	0.376	274.1	0.399	207.2	0.399	204.1	1

LASER GROUP

MR NO.	Age	Sex	Asso disease	BCVA(0)	CFT (0)	BCVA (1m)	CFT (1m)	BCVA (3m)	CFT (3m)	BCVA (6m)	CFT (6m)	LASER
718470	65	M	HTN	0.33	626	0.5	305	0.5	199	0.5	193	1
756760	60	M	HT/DM	0.33	388	1	179	1	180	1	164	1
730002	69	F	HT	0.33	410	0.33	252	0.5	170	0.5	164	1
727875	55	F	HT	0.16	405	0.33	230	0.33	148	0.33	179	1
745938	57	F	HT/DM	0.083	576	0.1	367	0.1	280	0.1	250	1
723630	38	F	HT	0.083	474	0.1	221	0.16	208	0.16	166	1
721118	52	M	HT/DM	0.25	648	0.33	428	0.33	220	0.33	250	1
744648	65	F	HT	0.1	751	0.16	343	0.16	243	0.16	256	1
730243	59	M	HT	0.33	328	0.66	180	0.66	184	0.66	189	1
715065	50	F	HT	0.083	504	0.25	236	0.25	240	0.25	230	1
Mean =	57			0.2079	511	0.376	274.1	0.399	207.2	0.399	204.1	1

BIBLIOGRAPHY

1. **Klein R** .Retinopathy in population based study. *Trans Am Ophthalmol Soc* 1992;90:561-984.
2. **Gewaily D, Greenberg PB**. Intravitreal steroids versus macular edema secondary to central vein occlusion. *Cochrane Database Syst Rev* 2009;1:CD007324.
3. **Cugati S, Wang JJ, Rochtchina E, Mitchell P**.Ten-year incidence of retinal vein occlusion in an older population: the Blue Mountains Eye Study. *Arch Ophthalmol*. 2006 May;124(5):726-32.
4. **Kahn H. A.** (Department of Epidemiology, The Johns Hopkins U. School of Hygiene and Public Health, Baltimore, MO 21205), **H. M. Leibowitz, J. P. Ganley, M. M. Kini, T. Colton, R. S. Nickerson and T. R. Dawber**. The Framingham Eye Study. I. Outline and major prevalence findings. *Am J Epidemiol* 106:17–32, 1977.
5. **Klein R, Moss SE, Meuer SM, Klein BE**. The 15-year cumulative incidence of retinal vein occlusion: the Beaver Dam Eye Study. *Arch Ophthalmol*. 2008 Apr;126(4):513-8.
6. **U.S Census Beureau**. Annual Estimates of the population by sex and five year age groups for United States : April 1,2000 to July 1 2007.NC-EST2007-01.Release Date: May 1 2008. **Available at :** <http://www.census.gov/popest/national/asrh/NC-EST2007-sa.html>. Last visited 17/11/2010.
7. **Rehak J, Rehak M**. Branch retinal vein occlusion: Pathogenesis, visual prognosis, and treatment modalities. *Curr Eye Res*. 2008;33:111–131.
8. **Noma H, Funatsu H, Yamasaki M, Tsukamoto H, Mimura T, Sone T, Jian K, Sakamoto I, Nakano K, Yamashita H, Minamoto A, Mishima HK**. Pathogenesis of macular edema with branch retinal vein occlusion and intraocular levels of vascular endothelial growth factor and interleukin-6. *Am J Ophthalmol*. 2005 Aug;140(2):256-61.

9. **Chahal, P.S., Fallon, T.J., Kohner, E.M. 1986.** Measurement of blood-retinal barrier function in central retinal vein occlusion. *Arch. Ophthalmol.* 104:554-557.
10. The **Branch Vein Occlusion Study Group:** Argon laser photocoagulation for macula edema in branch vein occlusion. *Am J Ophthalmol.* 1984;98:271-282.
11. **Prager F, Michels S, Kriechbaum K, Georgopoulos M, Funk M, Geitznauer W, Polak K, Schmidt-Erfurth U.** Intravitreal bevacizumab (Avastin) for macular oedema secondary to retinal vein occlusion: 12-month results of a prospective clinical trial. *Br J Ophthalmol.* 2009 Apr;93(4):452-6.
12. **Jaissle GB, Leitritz M, Gelissen F, Ziemssen F, Bartz-Schmidt KU, Szurman P, Graefes P.** One-year results after intravitreal bevacizumab therapy for macular edema secondary to branch retinal vein occlusion. *Arch Clin Exp Ophthalmol.* 2009 Jan;247(1):27-33.
13. **Wong I, Kondo S, Chan C.** Effect of intravitreal bevacizumab (IVB) in treating macular edema secondary to branch retinal vein occlusion (BRVO). *Retina.* 2010 Apr;30(4):710.
14. **Scott IU, Ip MS, VanVeldhuisen PC, Oden NL, Blodi BA, Fisher M, Chan CK, Gonzalez VH, Singerman LJ, Tolentino M** A randomized trial comparing the efficacy and safety of intravitreal triamcinolone with standard care to treat vision loss associated with macular Edema secondary to branch retinal vein occlusion: the Standard Care vs Corticosteroid for Retinal Vein Occlusion (SCORE) study report 6. Study Research Group. *Arch Ophthalmol.* 2009 Sep;127(9):1115-28.
15. **Aiello LP, Avery RL, Arrigg PG, et al.** Vascular endothelial growth factor in ocular fluid of patients with diabetic retinopathy and other retinal disorders. *N Engl J Med.* 1994;331(22):1480-1487.
16. **Campochiaro PA, Heier JS, Feiner L, Gray S, Saroj N, Rundle AC, Murahashi WY, Rubio RG.** Ranibizumab for macular edema following branch retinal vein occlusion: six-month primary end point results of a phase III study. BRAVO Investigators. *Ophthalmology.* 2010 Jun;117(6):1102-1112.

17. **Rouvas A, Petrou P, Ntouraki A, Douvali M, Ladas I, Vergados I.** Intravitreal ranibizumab (Lucentis) for branch retinal vein occlusion-induced macular edema: nine-month results of a prospective study. *Retina*. 2010 Jun;30(6):893-902.
18. **Zhao J, Sastry, SM, Sperduto, RTX Chew, EY. and Remaley. NA.** Arteriovenous crossing patterns in branch retinal vein occlusion. The Eye Disease Case-Control Study Group. *Ophthalmology* 100 423-428.1993
19. **Weinberg D, Dodwell DG, Fern SA.** Anatomy of arteriovenous crossings in branch retinal vein occlusion. *Am J Ophthalmol* 1990; 109:298-302.
20. **Eye Disease Case-Control Study Group.** Risk factors for branch retinal vein occlusion. *Am J Ophthalmol* ;116: 286-296,1993.
21. **Lahey JM, Tunc M, Kearny J et al.** Laboratory evaluation of hypercoagulable states in patients with central vein occlusion who are less than 56 yrs of age. *Ophthalmology* 2002;109:126-31.
22. **Lahey JM, Kearney J, Tunc M.** Hypercoagulable states and central vein occlusion. *Curr Opin Pulm Med* 2003;9:385-392.
23. **Cahill MT, Stinnet SS, Fekrat S.** Meta-analysis of homocysteine, serum folate, serum vitamin b 12, and thermolabile MTHFR genotype as a risk factor for retinal vascular occlusive disease. *Am J Ophthalmol* 2003;136:1136-1150.
24. **Ariturk N, Oge, Y, Erkan, D, et al.** Relation between retinal vein occlusions and axial length. *Br J Ophthalmol* 1996; 80:633-036.
25. **Majji AB, Janarthanan M, Naduvilath TJ.** Significance of refractive status in branch vein occlusions: a case control study. *Retina* 1997;17:200-204.
26. **Simmons BD, Brucker AJ.** Branch retinal vein occlusion : axial length and other risk factors. *Retina* 1997;17:191-95.
27. **Seitz R.** The retinal vessels. St Louis: CV Mosby, 20-74: 1964.

28. **Frangieh GT, Green WR, Barraquer-Somers E.** Histopathological study of nine branch retinal vein occlusions. *Arch Ophthalmol* 1982; 100:1132-1140.
29. **Bandello F, Tavola A, Pierro L et al.** Axial length and refraction in retinal vein occlusions. *Ophthalmologica* 1998; 212:133-135.
30. **Kumar B, Yu DY, Morgan WH et al.** The distribution of angioarchitectural changes within the vicinity of the arteriovenous crossing in branch retinal vein occlusion. *Ophthalmology* 1998; 105:424-427.
31. **Clemett RS.** Retinal branch vein occlusion: changes at the site of obstruction. *Br J Ophthalmol* 1974; 58:548-554.
32. **Bowers DK, Finkelstein D, Wolff SM et al.** Branch retinal vein occlusion: a clinicopathological case report. *Retina* 1987; 7:252-259.
33. **Christoffersen NLB, Larsen M.** Pathophysiology and hemodynamics of branch retinal vein occlusion. *Ophthalmology* 1999; 106:2054-2062.
34. **Finkelstein, D. Clarkson. JG.** The Branch Vein Occlusion Study Group Branch and central retinal vein occlusion Focal points 1987. Clinical modules for ophthalmologists 5 (module 12), no 3. *American Academy of Ophthalmology*.
35. **Gutman, FA, and Zegarra, II.** Macular edema secondary to occlusion of the retinal veins. *Surv Ophthalmol* 28 462-470,1984.
36. **Hayreh SS, Rojas P, Podhajsky P et al.** Ocular neovascularization with retinal vascular occlusion. III. Incidence of ocular neovascularization with retinal vein occlusion. *Ophthalmology* 1983; 90:488-506.
37. **Joffe, L, Goldberg, RE, Magargal. LE. et al.** Macular branch vein occlusion. *Ophthalmology* 87:91-98, 1980.
38. **Finkelstein. D.** Ischaemic macular edema: recognition and favorable natural history in branch vein occlusion. *Arch of Ophthalmology* 110-1427-1434,1992.

39. **Shroff D, Mehta DK, Arora R, Narula R, Chauhan D.** . Natural history of macular status in recent-onset branch retinal vein occlusion: an optical coherence tomography study..*Int Ophthalmol.* 2008 Aug;28(4):261-8.
40. **Zhang HR, Wang X, Lu XR, Yang YF, Liu F.** . Measurement of macular edema in retinal vein occlusion using optical coherence tomography and its visual prognosis. *Zhonghua Yan Ke Za Zhi.* 2005 Oct;41(10):910-6.
41. **Hattenbach LO.** . Systemic lysis therapy in retinal vascular occlusions. *Ophthalmologie.* 1998 Aug;95(8):568-75.
42. **Hattenbach LO, Friedrich Arndt C, Lerche R, Scharrer, et al.** . Retinal vein occlusion and low-dose fibrinolytic therapy (R.O.L.F.): a prospective, randomized, controlled multicenter study of low-dose recombinant tissue plasminogen activator versus hemodilution in retinal vein occlusion. *Retina.* 2009 Jul-Aug;29(7):932-40.
43. **Branch Vein Occlusion Study Group.** Argon laser scatter photocoagulation for prevention of neovascularisation and vitreous hemorrhage in branch vein occlusion. *Arch Ophthalmol* 104:34-41, 1986.
44. **Finkelstein D.** : Argon laser photocoagulation for macular edema in branch vein occlusion. *Ophthalmology.* 1986 Jul;93(7):975-7.
45. **Arnarsson A, Stefánsson E.** : Laser treatment and the mechanism of edema reduction in branch retinal vein occlusion. *Invest Ophthalmol Vis Sci.* 2000 Mar;41(3):877-9.
46. **Lang GE, Händel A** : Results of laser coagulation of retinal branch vein occlusions. *Augenlinik mit Poliklinik, Universität Erlangen-Nürnberg. Klin Monbl Augenheilkd.* 1993 Sep;203(3):180-8.
47. **McAllister IL, Vijayasekaran S, Chen SD, Yu DY.** Effect of triamcinolone acetonide on vascular endothelial growth factor and occludin levels in branch retinal vein occlusion. *Am J Ophthalmol.* 2009 May;147(5):838-46, 846.e1-2.

48. **Gunnlaugsdóttir E, Oehman DO, Gunnarsdóttir SG, Stefánsson E.** Macular oedema and intravitreal triamcinolone injections. *Laeknabladid*. 2006 Dec;92(12):847-57.

49. **Chen SD, Sundaram V, Lochhead J, Patel CK.** Intravitreal triamcinolone for the treatment of ischemic macular edema associated with branch retinal vein occlusion. *Am J Ophthalmol*. 2006 May;141(5):876-883.

50. **M, Roodhart JM, Voest EE.** "Target practice: lessons from phase III trials with bevacizumab and vatalanib in the treatment of advanced colorectal cancer". *The Oncologist* 2007 April;12(4): 443–50.

51. **Ferrara N, Hillan KJ, Nowotny W.** Bevacizumab (Avastin), a humanized anti-VEGF monoclonal antibody for cancer therapy. *Biochem Biophys Res Commun*. 2005;333:328–35.

52. **<http://www.gene.com/gene/products/information/oncology/avastin>**

[Internet] Available from ;

<http://www.gene.com/gene/products/information/oncology/avastin>. Last visited 17/11/2010

53. **Sophie J. Bakri, MD1, Melissa R. Snyder, PhD2, Joel M. Reid, PhD3, Jose S. Pulido, MD1, Mohamed K. Ezzat, BS1, Ravinder J. Singh, PhD2.** Pharmacokinetics of Intravitreal Bevacizumab (Avastin): May 2007 Volume 114, Issue 5, Pages 855-859.

54. **Gordon M, Morales-Canton V, Solis-Vivanco A.** Complications after intravitreal bevacizumab (Avastin): Analysis of 1910 injections. *Invest Ophthalmol Vis Sci*. 2007;48:A88.

55. **Aggio FB, Farah ME, de Melo GB, d'Azevedo PA, Pignatari AC, Hofling-Lima AL.** Acute endophthalmitis following intravitreal bevacizumab (Avastin) injection. *Eye*. 2007;21:408–9.

56. **Meyer CH, Mennel S, Schmidt JC, Kroll P.** . Acute retinal pigment epithelial tear following intravitreal bevacizumab (Avastin) injection for occult choroidal

neovascularization secondary to age related macular degeneration. *Br J Ophthalmol.* 2006;90:1207–8.

57. **Costa RA, Jorge R, Calucci D, Melo LA,Cardillo JA, Scott IU.** Intravitreal Bevacizumab (avastin) for central and hemicentral retinal vein occlusions: IBeVO Study. *Retina* 2007;27:141-9.

58. **Haritoglou C, Kook D, Neubauer A, Wolf A, Priglinger S, Strauss R, Gandorfer A, Ulbig M, Kampik A.** Intravitreal bevacizumab (Avastin) therapy for persistent diffuse diabetic macular edema. *Retina.* 2006 Nov-Dec;26(9):999-1005.

59. **<http://www.gene.com/gene/products/information/pdf/lucentis-prescribing.pdf>**
[Internet] Available from : <http://www.gene.com/gene/products/information/pdf/lucentis-prescribing.pdf> . Last visited 17/11/2010.

60. **Sophie J. Bakri, MD1, Melissa R. Snyder, PhD2, Joel M. Reid, PhD3, Jose S. Pulido, MD1, Mohamed K. Ezzat, BS1,Ravinder J. Singh, PhD2.** Pharmacokinetics of Intravitreal Ranibizumab (Lucentis). December 2007 Volume 114, Issue 12, Pages 2179-2182

61. **Brown DM, Campochiaro PA, Singh RP, Li Z, Gray S, Saroj N, Rundle AC, Rubio RG, Murahashi WY. ; CRUISE Investigators .** Ranibizumab for macular edema following central retinal vein occlusion: six-month primary end point results of a phase III study. *Ophthalmology.* 2010 Jun;117(6):1124-1133.e1.

62. **Nguyen QD, Shah SM, Heier JS, Do DV, Lim J, Boyer D, Abraham P, Campochiaro PA; READ-2 Study Group.** Primary End Point (Six Months) Results of the Ranibizumab for Edema of the mAcula in diabetes (READ-2) study. *Ophthalmology.* 2009 Nov;116(11):2175-81.e1.

63. **Hanley JA, Lippman-Hand A.** If nothing goes wrong, is everything all right? Interpreting zero numerators. *JAMA.* 1983 Apr 1;249(13):1743-5.

64. **Schachat AP, Chambers WA, Liesegang TJ, Albert DA.** Safe and effective. *Ophthalmology.* 2003 Nov;110(11):2073-4.

INSTITUTE OF OPHTHALMOLOGY

JOSEPH EYE HOSPITAL

TIRUCHIRAPALLI

NAME :

AGE :

SEX :

S:NO :

ADDRESS :

M.R.NO :

PHONE :

COMPLAINTS :

PERSONAL HISTORY :
DIABETES :
HYPERTENSION :
DYSLIPEDEMIA :
CARDIAC STATUS :
FAMILY HISTORY :
TREATMENT HISTORY :

GENERAL EXAMINATION :	
B.P	URINE : ALBUMIN : SUGAR :
PULSE RATE	RBS :
CVS	

OCULAR EXAMINATION		RE	LE
VISION	Distant vision Without correction Best corrected		
	Near vision Without correction Best corrected		
IOP			
ANTERIOR SEGMENT			
	Lids and Adnexa		
	Conjunctiva		
	Cornea		
	AC		
	IRIS		
	Pupil		
	lens		

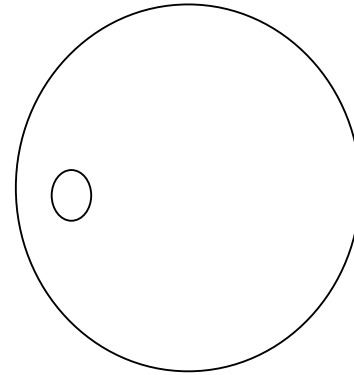
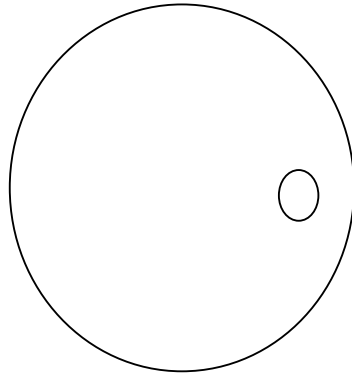
POSTERIOR SEGMENT – FUNDUS :

RE

LE

Media		
Disc		
	Colour	
	Margins	
	CD ratio	
	Neuroretinal rim	
	vessels	
Macula		
Others		
Provisional diagnosis		
RE		
LE		

Fundus photograph



FFA

OCT

Details of treatment

FOLLOW UP

Duration	BCVA	IOP	OCT	Others
0				
1 month				
3 month				
6 month				