

The Need for Diurnal Variation of Intraocular Pressure in Patients with Pseudoexfoliation of the Lens Capsule



Swetha Sara Philip

Dissertation submitted to the Tamil Nadu Dr. M.G.R. Medical
University, Chennai in partial fulfillment of the conditions for the
MS Branch III (Ophthalmology) examination to be held in
February 2007

CERTIFICATE

This is to certify that this dissertation entitled “**Need for diurnal variation of intraocular pressure testing in eyes with pseudoexfoliation**” is bonafide work done by Dr.Swetha Sara Philip in partial fulfillment of the rules and regulations for M.S Branch III (Ophthalmology) examination of the Tamil Nadu Dr. M.G.R Medical University, Chennai, to be held in February 2007.

Date:

Place: Vellore

**Dr Andrew D. Braganza
Dissertation Guide &
Professor of Ophthalmology
Department of Ophthalmology
Christian Medical College
Vellore**

ACKNOWLEDGEMENTS

I wish to express my heartfelt and sincere thanks to Dr. Andrew D. Braganza for patiently guiding me through the whole dissertation. I am grateful to Dr. Smitha Jasper for her valuable advice and help. I thank all my teachers and colleagues who have sent me patients for my study. To all the patients who agreed to participate in the study, a big thank you. I wish to thank Mr. Suresh who was willing to help me with the visual field testing of the patients. My sincere gratitude is due to the medical records department, Mr. Ravi, and the office and nursing staff for all their help. Last, but not the least I would like to thank my family for their constant love and support

Dr. Swetha Sara Philip.

TABLE OF CONTENTS

PAGE NO:

INTRODUCTION	1
AIMS	6
REVIEW OF LITERATURE	7
MATERIALS and METHODS	29
ANALYSIS and RESULTS	36
DISCUSSION	47
CONCLUSIONS	56
BIBLIOGRAPHY	57
APPENDIX I	
APPENDIX II	
APPENDIX III - PHOTOGRAPHS	

INTRODUCTION

Glaucoma is the second leading causes of blindness globally today.^[1] In India it is the third most common cause of blindness.^[2] It is estimated that glaucoma affects 12 million in India and is responsible for 12.8% of the blindness in the country.^[1] Glaucoma affects people of all ages producing serious health and economic consequences.^[3] In nearly all cases blindness from glaucoma is preventable if the disease is detected early and proper treatment is implemented.

Primary open angle glaucoma is best defined as a chronic optic neuropathy with characteristic disc and field changes. The only therapeutically modifiable causal risk factor is intraocular pressure.^[4] Overall, glaucoma can be classified based on the gonioscopic appearance of the angles, as open or closed angle glaucoma.^[3] Glaucoma can also be classified as primary or secondary glaucoma.^[3] In primary glaucoma, the disease exists without detectable contribution from other systemic or ocular disorders.^[4] Secondary glaucoma is defined purely on the basis of raised intraocular pressure (IOP) with or without disc & field changes, associated with other ocular conditions known to contribute to IOP rise.^[4] One such secondary open angle glaucoma is pseudoexfoliation glaucoma.

Pseudoexfoliation is a generalized disorder and is commonly age-related, though often overlooked, and predisposes to a number of ocular complications, especially glaucoma.^[5] It is presently acknowledged as the most common identifiable cause of secondary open angle glaucoma accounting for about 25%

of all open angle glaucomas worldwide.^[6] This has also been shown in a study from south India where pseudoexfoliation was present in 26.7% of open angle glaucoma cases studied.^[7]

Pseudoexfoliation syndrome occurs in all geographic regions world wide with reported prevalence rates varying between 5% and 40% of the general population over the age of 60years.^[6] In south India H. Arvind et al demonstrated a prevalence of 3.8% in those over 40 years of age.^[8] In another study from south India, involving a similar age group, the prevalence of pseudoexfoliation was found to be 6.0%.^[7]

The etiology of pseudoexfoliation still remains unclear.^[9] It is characterized as a disorder of extra cellular matrix associated with multifocal production of abnormal extra cellular fibrillar matrix, with the gradual accumulation of a specific fibrillar substance in virtually all tissues of the anterior segment of the eye, most importantly on the lens and pupillary margins.^[5] There is involvement of the lens, iris, ciliary body, trabecular meshwork and cornea and these changes in turn predispose to a spectrum of intraocular complications including chronic open angle glaucoma, angle closure glaucoma, lens subluxation or dislocation, pigment dispersion, poor mydriasis, posterior synechiae, blood-aqueous barrier defects and anterior chamber hypoxia, corneal endothelial decompensation and a significantly higher rate of intra- and post-operative complications in cataract surgery.^[9] Recent evidence indicates that ocular features of pseudoexfoliation syndrome are actually only one facet of a

broader systemic process that involves skin and the connective tissue portion of various visceral organs.^[9]

Pseudoexfoliation associated secondary open angle glaucoma is called pseudoexfoliation glaucoma or exfoliation glaucoma or capsular glaucoma.^[9] It develops in about half of patients with pseudoexfoliation syndrome over time.^[1] Among glaucoma patients above the age of 50 years, the frequency of pseudoexfoliation syndrome is usually high and has been reported from 10-30% in the US, 50-60% in Northern Europe and 87% in Greece.^[9] Raised intraocular pressure with or without glaucomatous damage occurs in 15-50% of pseudoexfoliation or about 6-10 times the rate in eyes without pseudoexfoliation syndrome.^[6] In a similar age group studied in south India, raised intraocular pressure was seen in 16.7% of people with pseudoexfoliation and glaucomatous damage was present in 13%.^[8] In another study from south India, the reported prevalence of glaucoma in pseudoexfoliation was 7.5%.^[7]

The probability of eyes with pseudoexfoliation going on to develop glaucoma has been reported to vary from 5% to 33% within 5 years and from 15% to 40% within 10 years.^[9] In a prospective study over 10 years the progress from unilateral to bilateral pseudoexfoliation was 38%; the progress from unilateral to bilateral glaucoma was found to be 48% of patients with bilateral pseudoexfoliation syndrome within 15 years.^[10]

Despite its clinical significance and many new insights in the recent years, pseudoexfoliation glaucoma is still underestimated and wrongly

diagnosed, leading to unexpected problems in clinical management and surgery.^[9]

There is universal agreement that compared to primary open angle glaucoma pseudoexfoliation glaucoma has a more serious clinical course and worse prognosis. It is typically associated with higher intraocular pressure levels, greater diurnal pressure fluctuations, marked pressure spikes, a higher frequency and severity of optic nerve damage, more rapid visual field loss, poorer response to medications and more frequent necessity for surgical intervention.^[13, 14]

Pseudoexfoliation glaucoma also differs from primary open angle glaucoma by a more frequent asymmetry of manifestation, more pronounced chamber angle pigmentation and acute pressure rise after mydriasis.^[15] In contrast to patients with primary open angle glaucoma, patients with pseudoexfoliation glaucoma demonstrate a normal response to steroid application i.e. about one-third respond with a distinct pressure rise.^[9]

A significant correlation between the intraocular pressure levels at the time of diagnosis and the mean visual field defect could be established only in pseudoexfoliation glaucoma and not in primary open angle glaucoma patients,^[15] suggesting intraocular pressure as the main risk factor for glaucomatous damage in this type of glaucoma.^[16]

These findings suggest that the glaucomatous damage in patients with pseudoexfoliation glaucoma may be more directly related to intraocular pressure than in primary open angle glaucoma, where the situation may be more complex.^[17] The rapid progression of pseudoexfoliation glaucoma probably

reflects the cumulative effects of the daily trauma of intraocular pressure spikes on the optic nerve.^[9]

To date there are no established data concerning the necessity of testing diurnal variation of intraocular pressure in pseudoexfoliation. There is published literature on the effects of cataract surgery in eyes with pseudoexfoliation. In this study we attempt to define the role of diurnal variation of intraocular pressure testing in the diagnosis of glaucoma in eyes with pseudoexfoliation, and also to find whether cataract surgery in pseudoexfoliation with normal intraocular pressure protects the eye from subsequent development of glaucoma.

AIMS

1. To record the diurnal variation in intraocular pressure in eyes with pseudoexfoliation syndrome.
2. To record the disc findings and visual fields in eyes with pseudoexfoliation syndrome.
3. To determine the usefulness of diurnal measurement of intraocular pressure compared to initial intraocular pressure in diagnosing pseudoexfoliation glaucoma.
4. To document the outcome of cataract surgery in patients with pseudoexfoliation in terms of intraocular pressure, disc appearance, visual improvement and field testing.
5. To use the above data to determine, if possible, the effect of cataract surgery on intraocular pressure in pseudoexfoliation syndrome and pseudoexfoliation glaucoma.

REVIEW OF LITERATURE

Glaucoma is currently the second leading causes of blindness in the world, after cataract.^[1] In many developing countries, such as India, it is the third most common cause of blindness.^[2] It is estimated that glaucoma affects 12 million people in India and causes 12.8% of the blindness in the country.^[1] As blindness due to glaucoma is irreversible, and it is seen in people of all ages, it is regarded as a significant public health and economic problem. Further, in nearly all cases, blindness from glaucoma is preventable if the disease is detected early and proper treatment is initiated and followed.^[3] Detection of the disease depends on educating the general public regarding the importance of routine eye examinations and training fellow health professionals to recognize the signs and symptoms of glaucoma.^[3]

Primary open angle glaucoma can be defined as a chronic optic neuropathy which has characteristic disc and field changes. The only therapeutically modifiable causal risk factor is intraocular pressure.^[4] Glaucoma is a multifactorial disease; elevated intraocular pressure remains an important risk factor and intraocular pressure reduction is still the only treatment of proven benefit.^[5] “Normal” intraocular pressure may be defined for the individual eye as that pressure which is sufficient to maintain the structural relationships of ocular anatomy without producing glaucomatous nerve damage.^[4] The normal range of intraocular pressure in the general population is generally accepted to be 10-21 mmHg.^[3] There are many factors that can affect intraocular pressure such as age,

sex and race. Hereditary and seasonal variation, cardiovascular factors, exercise, postural changes, neural factors, hormonal factors, refractive error, eye movements, inflammation and surgery can all affect IOP. Most importantly, IOP is not a static value but goes through a variation in level throughout the day in normal and diseased eyes.^[3]

Over the course of the day, the intraocular pressure varies an average of 3-6 mmHg in normal individuals.^[3,4] Patients with glaucoma have much wider swings. It has been found the intraocular pressure is generally found to be high in the mornings and minimum at late night or early morning. Some people peak in the afternoon or in the evenings.^[9] Most of the variation in intraocular pressure that occurs during the diurnal cycle is attributable to changes in the rate of aqueous humor production.^[18] This variation in pressure according to some investigators is in response to circulating catecholamine. The diurnal variation in intraocular pressure follows the diurnal glucocorticoid cycle, with intraocular pressure peaking about 3-4 hrs after plasma cortisol.^[3]

The concept of “target pressure” or an individually tailored intraocular pressure at which, for a given patient, significant visual loss is avoided allied with evidence that a 30% reduction in intraocular pressure limits visual field loss in normal tension glaucoma only serves to reaffirm the measurement of intraocular pressure as central to the management of glaucoma patients.^[19]

Despite this, diagnostic and management decisions are frequently made after single or infrequent intraocular pressure measurements at varying times of the day.^[20] Measurement error and diurnal intraocular pressure fluctuation may

contribute to an under-estimation of peak intraocular pressure with consequent over diagnosis of normal tension glaucoma or an incorrect belief that “target pressure” has been attained.^[21] These concerns led to the development of diurnal measurement of intraocular pressure. This could be carried out as 24 hr monitoring of intraocular pressure or clinic (office) based monitoring of intraocular pressure.^[22] Edward Hughes and co-workers demonstrated that 24 hr monitoring of intraocular pressure was better than single IOP recording in management decisions in glaucoma.^[20]

Pseudoexfoliation was described by the Finnish ophthalmologist Lindberg.^[5] Vogt emphasized the association with glaucoma and, in fact, called it glaucoma capsulare; Sampaolesi elaborated on melanin dispersion and changes in the blood-aqueous barrier in PEX; Tarkanen focused on the involvement of ciliary processes; Ringvold showed pseudoexfoliation in the conjunctiva; Garner et al showed pseudoexfoliation on the zonules and Schlötzer et al showed systemic involvement.^[5,9]

The pseudoexfoliation syndrome is characterized by formation and/or deposition of a fibrillo-granular material throughout the anterior segment, and is often accompanied by raised intraocular pressure with or without glaucomatous optic nerve and visual field damage.^[23] Although glaucoma in pseudoexfoliation has many similarities to primary open angle glaucoma, the pathogenetic mechanism of the two diseases may be quite different.^[9] Glaucoma is more prevalent and its prognosis more severe in eyes with pseudoexfoliation than in those without pseudoexfoliation.^[24-28] There is no known sex predilection for

pseudoexfoliation, but study by Randy A Karger et al found that women are more predisposed to developing pseudoexfoliation. Hormonal factors were cited to be the cause of this predilection.^[29]

Pseudoexfoliation syndrome occurs in all geographic regions world-wide with reported prevalence rates varying between 5% and 40% of the general population over the age of 60yrs.^[6] In south India, in a study done by H Arvind et al, patients equal to or above the age of 40yrs were studied. The prevalence of pseudoexfoliation syndrome in this population was 3.8%.^[8] In another study from south India, studying similar age group, the prevalence of pseudoexfoliation was found to be 6.0%.^[7]

For unknown reasons, patients can present with unilateral or bilateral involvement, which can be markedly asymmetrically. Unilateral involvement is often regarded as a precursor to bilateral involvement.^[30] Pseudoexfoliation syndrome manifests unilaterally in about 50-70% of patients and the conversion rates from clinically unilateral to bilateral disease were found to vary from 15-40% within 5yrs.^[31]

Unilateral pseudoexfoliation syndrome occurs at a younger age than bilateral disease, mostly as a consequence of prior intraocular surgery or trauma to the anterior segment, particularly to the iris, which may serve as a trigger for the premature development of pseudoexfoliation in a predisposed individual.^[9] Puska et al did not find any prognostic factors for conversion of unilateral to bilateral exfoliation.^[10]

Pseudoexfoliation syndrome is diagnosed on visualization of pseudoexfoliation material on the anterior lens capsule and/or pupillary margin. There are also less commonly appreciated signs related to loss and dispersion of pigment from the iris pigment epithelium.^[32] These include loss of pupillary ruff, pigment deposition on the iris sphincter region, iris transillumination defects, anterior chamber pigment dispersion after pupillary dilation and moderate or dense pigmentation of the trabecular meshwork.^[33-36]

Exfoliation material may be detected earliest on the ciliary processes and zonules. However, the majority of intraocular pseudoexfoliation deposits cannot be observed by direct biomicroscopy, and the accumulations on zonules, ciliary processes, and trabecular meshwork may only be detected on gonioscopy or cycloscopy or may be visualized by high resolution ultrasound biomicroscopy.^[37]

Scattered flakes of pseudoexfoliation have been observed on the endothelium. Pigment deposition usually causes a diffuse, nonspecific pigmentation of the central endothelium, occasionally having the pattern of Krukenberg's spindle.^[6] More frequently, one or more undulating pigmented lines can be observed in the peripheral cornea anterior to Schwalbe's line. Specular microscopy demonstrates a reduced endothelial cell density, even with normal intraocular pressure.^[9]

Exfoliation material can also be produced by corneal endothelial cells.^[38] In the affected areas, the endothelial layer appears irregular and discontinuous with detaching and degenerating endothelial cells. Subsequent re-endothelialization of denuded areas of Descemet's membrane by neighboring

fibroblastic endothelial cells leads to incorporation of pseudoexfoliation material, cellular debris and pigment granules into Descemet's membrane.^[6] Naumann et al have suggested that a true keratopathy, distinct from Fuch's dystrophy and pseudophakic bullous keratopathy, can be found in eyes with pseudoexfoliation and this predisposes them to early corneal endothelial decompensation with only moderate elevations of intraocular pressure or following cataract surgery.^[5]

Regardless of whether the zonules are coated with pseudoexfoliation material or are actually replaced by it, they are often frayed and broken. Abnormal zonular attachments to the lens or ciliary body may account for the development of lens subluxation or dislocation.^[9] Deposits of pseudoexfoliation material cover the crests of the ciliary processes in the pars plicata, whereas the posterior ciliary body or pars plana is generally devoid of it.^[6]

The clinically observed instability of the zonules may be explained by alterations of the zonular fibers themselves and their impaired anchorage in the defective basement membranes of the ciliary body and lens.^[39] At their origin and anchorage in the ciliary body, the zonular bundles are separated from the disrupted basement membrane of the non-pigmented epithelium by locally produced exfoliation material. The zonular bundles passing alongside the ciliary processes are focally infiltrated by exfoliation material. At their attachment to the anterior lens capsule, the zonular lamellae is focally lifted off and ruptured by masses of exfoliation material erupting through the capsular surface.^[6]

For a clinical diagnosis of pseudoexfoliation the most important diagnostic criteria are whitish flake-like deposits of pseudoexfoliation material

on anterior segment structures, particularly on the anterior lens surface and the pupillary margin, occasionally also on the posterior surface of the cornea, on the anterior surface of intraocular lens implants, and on the anterior vitreous face in aphakic eyes.^[9]

In early stages of pseudoexfoliation, it has been shown by electron microscopy that a diffuse-matte homogenous film on the surface of the anterior lens capsule consist of a layer of micro fibrils, a precursor of pseudoexfoliation fibrils, deposited from the aqueous humor.^[20, 40] As the precapsular layer becomes thicker, focal defects begin to form here by abrasive movements of the iris, often in the upper nasal quadrant, which further enlarge and become confluent to form the classical picture of manifest pseudoexfoliation syndrome.^[9]

The characteristic target-shaped pattern on the lens, consisting of a rather homogenous central disc, an intermediate clear zone, and a peripheral granular zone, can be only seen after pupillary dilation.^[8] In routine examinations without pupillary dilation, the diagnosis may be easily missed, because the central disc may be very subtle or even absent in 20-50% of cases.^[9] The central disc, corresponding to the size of the pupil, appears to result from diffuse sedimentation of pseudoexfoliation material from the aqueous, whereas the peripheral granular zone builds up undisturbed accumulation of nodular pseudoexfoliation aggregates produced by iris pigment epithelium; the intermediate clear zone is created by abrasive movements of the peripupillary iris during pupillary movement.^[20]

Variations of this general pattern include; the lack of a central disc, bridges of pseudoexfoliation material crossing the intermediate clear zone, and a layered or striated peripheral granular zone with or without curled edges.^[9] In the clinically invisible pre-equatorial region of the lens, pseudoexfoliation aggregates appear to be locally produced by the metabolically active pre-equatorial lens epithelium, to penetrate the lens capsule and loosen the attachment of the zonular fibers to the anterior lens capsule, giving rise to a pronounced zonular weakness in pseudoexfoliation eyes.^[5]

Several other clinical signs aid in the diagnosis.^[5, 31] Exfoliative material is often prominent at the pupillary border. Pigment loss from the peripupillary iris pigment epithelium and its deposition on anterior chamber structures is a hallmark of pseudoexfoliation syndrome.^[6] Pigment dispersion is caused by rubbing of the peripupillary iris against the rough anterior lens surface during pupillary movement and rupture of the degenerative iris pigment epithelial cells with liberation of melanin granules. This manifests clinically in a peripupillary atrophy producing a characteristic “moth eaten” transillumination pattern, pupillary ruff defects, pigment dispersion after pupillary dilation and deposition of melanin granules on the iris surface, the corneal endothelium and the trabecular meshwork.^[9] These signs can precede the clinical appearance of pseudoexfoliation material on the lens surface. Patients with absence of clinically identifiable exfoliative material on the anterior lens capsule or pupillary margin are called “exfoliation suspects”.^[30]

Exfoliation material accumulates within the stromal connective tissue and the anterior border layer, and in the walls of stromal blood vessels. The vessel lumens are often narrowed and may become obliterated, with marked alteration of iris vasculature in advanced cases. Vessel dropout with collateral formation and iris hypoperfusion lead to patchy iris microneovascularisation and diffuse, patchy fluorescein leakage, especially in the pupillary region.^[9] In advanced stages, the vascular wall cells degenerate completely. Degenerative changes of sphincter and dilator muscle tissues and apparent involvement of the muscle cells in exfoliation fiber formation have been described and may contribute to poor pupillary dilation.^[41]

Increased trabecular meshwork pigmentation, particularly in the inferior half, is a prominent sign of pseudoexfoliation syndrome.^[9] Unlike pigment dispersion syndrome, the distribution of the pigment tends to be uneven or patchy and less well defined. Pigment is also characteristically deposited on or anterior to Schwalbe's line (Sampolesi's line).^[6] Exfoliation material can be found in the trabecular spaces, within the trabecular beams, and in the periphery of Schlemm's canal. Most deposits are found in the juxtacanalicular tissue beneath the inner wall of Schlemm's canal and in the uveal meshwork, whereas the corneoscleral portion of the meshwork appears to be largely uninvolved.^[32]

In the juxtacanalicular tissue, pseudoexfoliation material has been found within vacuole-like spaces and surface invaginations of the endothelial cells, suggesting local production by endothelial cells that line Schlemm's canal.^[9] In eyes with advanced exfoliative glaucoma, masses of pseudoexfoliative material

accumulate along the whole periphery of Schlemm's canal, causing considerable disorganization of the normal tissue architecture.^[6]

Pseudoexfoliative material may be found on the vitreous face, on vitreous strands when the face is ruptured, on the posterior capsule and on intraocular lenses, indicating that the presence of the lens is unnecessary for its continued formation.^[6] Pseudoexfoliation associated signs that alert the clinician to the presence of pseudoexfoliation include phacodonesis, iris stroma atrophy, iris hemorrhages after pupillary dilation, increased aqueous flare values, elevated intraocular pressure and insufficient pupillary dilation, particularly if asymmetrically present.^[9]

In an ultra structural study done by T.Hammer et al,^[30] it was found that clinically unilateral pseudoexfoliation has sub clinical alteration of the contralateral noninvolved eyes. These included 1) deposits of typical pseudoexfoliation fibrils on the iris and ciliary epithelia and in the dilator muscle of the iris, 2) increased accumulation of extracellular matrix, including micro fibrils and reduplicated basement membrane material in the periphery of iris vessels, in the dilator muscle and in the juxtacanalicular tissue of trabecular meshwork, 3) degenerative changes of iris pigment epithelium and dilator muscle cells.^[42]

The etiology of pseudoexfoliation remains unclear.^[9] The characteristic fibrils, which are composed of microfibrillar units resembling elastic micro fibrils contain epitopes of elastic fibers.^[5] They appear to be multifocally produced by various extra and intraocular cell types, including the pre-equatorial lens epithelium, non-pigmented ciliary epithelium, trabecular endothelium,

corneal endothelium, vascular endothelium and virtually all cell types in iris, by active fibrillogenesis.^[6] This fibrillogenesis is accompanied by a destruction of the normal extra cellular matrix of cells, normally represented by their basement membrane and is followed by a degeneration of cells involved due to a disturbed cell-matrix interaction (degenerative fibrillopathy).^[9]

Excessive matrix accumulates may be due to increased denovo synthesis or a decreased turnover of matrix components or both and may be influenced by growth factors, proteolytic enzymes and their inhibitors and free radicals.^[9] Biochemical analyses showed significantly increased concentration of the transforming growth factors (TGF- β) both in its latent and active form, in the aqueous humor of pseudoexfoliation patients with or without glaucoma compared to age-matched controls with cataract or primary open angle glaucoma.^[42] This growth factor has been known as a powerful modulator of matrix formation in many fibrotic diseases.

There has been an increasing awareness of growth factors in aqueous humor homeostasis, leading to development of raised intraocular pressure and glaucoma.^[43, 44] As the aqueous humor bathes the anterior segment its compounds affect the metabolic functioning of cells lining the conventional outflow routes, that is, the trabecular meshwork. In humans, the trabecular meshwork is made up of collagen beams covered by endothelial like cells.^[45] The space between the beams are filled with extracellular matrix. The extracellular matrix in the subendothelial region of Schlemm's canal plays an important part in the pathogenesis of glaucoma.^[46] Elevated intraocular pressure may be attributed to

abnormal deposition of extracellular matrix resulting in a reduced filtration capacity.^[47, 48]

There are several mechanisms by which presence of certain growth factors are seen in aqueous humor. These include selective ultra filtration of low molecular weight growth factors from serum, local intraocular synthesis and release of growth factors, diffusional exchange of growth factors between aqueous and vitreous humor and selective transport system for certain growth factors.^[44] The blood-aqueous barrier contributes partial control on the types and levels of growth factors that enter the aqueous humor in health and diseases.^[45]

Other factors like basic fibroblast growth factor (bFGF)^[48] and hepatocyte growth factor (HGF)^[49] and 8-isoprostaglandin F_{2α}^[50] in the aqueous humor. It has been speculated that these findings are indicative of oxidative stress as well as an abnormality in fibrogenesis, matrix degradation and cellular response to injury in the anterior segment of pseudoexfoliation eyes.^[45]

TGFβ₁, a fibrogenic cytokine, has a pivotal role in the ocular wound healing process. It is also essential in maintenance of anterior chamber associated immune derivation.^[44] It promotes deposition of extracellular matrix by down regulating the production of proteases and stimulating the synthesis of protease inhibitor.^[45]

Connective tissue growth factor (CTGF) also plays a part in extracellular matrix deposition remodeling and wound healing by promoting collagen synthesis and regulating the expression of matrix metalloproteinases (MMP) and tissue inhibitors of matrix metalloproteinases (TIMP).^[45] It has been shown by

Van Satten et al that connective tissue growth factor levels are higher in aqueous humor of pseudoexfoliation glaucoma patient, suggesting involvement of CTGF in fibrotic pathology of pseudoexfoliation syndrome and its association with glaucoma. The high levels of CTGF has been demonstrated by western blot analysis and ELISA.^[51]

Aqueous humor from pseudoexfoliation patients also had higher levels of matrix metalloproteinases (MMP-2 and MMP-3) as well as their inhibitors TIMP-1 and TIMP-2 as compared to controls.^[52] However, levels of endogenously active MMP-2, which is the major matrix metalloproteinases in human aqueous humor, were significantly decreased as was the ratio of MMP-2 to TIMP-2. These findings suggest that an excess of TIMP-2 over MMP-2 and a reduced MMP-2 activity in the eyes of pseudoexfoliation patients may promote the abnormal matrix accumulation due to impaired matrix turnover. TIMP's also bind pseudoexfoliation material creating so-called cold spots for proteolysis.^[9]

Significantly reduced levels of ascorbic acid, an important free radical scavenger in the eye and concomitantly increased levels of 8-isoprostaglandin F_{2α}, marker of oxidative stress have further been reported in aqueous humor of pseudoexfoliation patients, suggesting a faulty antioxidative defense system and increased oxidative stress in the pathogenesis of pseudoexfoliation syndrome.^[9]

The presence of glycoaminoglycans has also been shown by application of the sulphate-binding dye cuproinic blue and by immune histochemical evidence for the presence of heparin sulphate proteoglycan, chondroitin sulphate proteoglycan, dermatan sulphate proteoglycan and hyaluronan. It has been

suggested that the HNK-1 epitope, a carbohydrate moiety present on many cell adhesiveness of pseudoexfoliative material deposits on intraocular surfaces.^[53]

Among glaucoma patients above the age of 50yrs, the frequency of pseudoexfoliation syndrome is usually high and has been reported from 10-30% in US, 50-60% in Northern Europe and 87% in Greece.^[9] Raised intraocular pressure with or without glaucomatous damage occurs in 15-50% of pseudoexfoliation or about 6-10 times the rate in eye without pseudoexfoliation syndrome. In a similar age group studied in south India, raised intraocular pressure was seen in 16.7% of people with pseudoexfoliation and glaucomatous damage was present in 13%.^[8] In another study from south India, the reported prevalence of glaucoma in pseudoexfoliation was 7.5%.^[7]

The probability of pseudoexfoliation eyes to develop glaucoma has been reported to vary from 5% to 33% within 5yrs and from 15% to 40% within 10yrs; the progress from unilateral to bilateral glaucoma was found to be 48% of patients with bilateral pseudoexfoliation syndrome within 15yrs.^[9] In a recent study involving patients with clinically unilateral pseudoexfoliation syndrome, conversion to pseudoexfoliation glaucoma was 38% in the initially non-involved fellow eyes with in 10yrs, suggesting that glaucoma may develop before there are any clinical signs of pseudoexfoliation material.^[31] In a study done by P Puska et al factors that were associated with conversion to exfoliation glaucoma were initial intraocular pressure, pupillary dilation value and the intraocular pressure difference between the fellow eyes.^[10]

Compared to primary open angle glaucoma, pseudoexfoliation glaucoma has a more serious clinical course and worse prognosis. It is typically associated with higher intraocular pressure levels, greater diurnal pressure fluctuations, marked pressure spikes, a higher frequency and severity of optic nerve damage and more rapid visual field loss, a poorer response to medications and a greater necessity for surgical intervention.^[13, 14]

Pseudoexfoliation glaucoma differs from primary open angle glaucoma by a more frequent asymmetry of manifestation, more pronounced chamber angle pigmentation and acute pressure rise after mydriasis. In contrast to patients with primary open angle glaucoma, patients with pseudoexfoliation glaucoma behave like normal persons after steroid application i.e. only one third responds with a distinct pressure rise.^[54]

The percentage area of optic disc pallor was shown to be significantly greater in eyes with pseudoexfoliation than in control eyes and the mean disc area has been reported to be significantly smaller in eyes with pseudoexfoliation, with or without glaucoma than in primary open angle glaucoma eyes and control normal eyes.^[11] There were, however, no significant differences in neuroretinal rim area, area of peripupillary atrophy, rim disk ratio, cup area and cup volume between pseudoexfoliation eyes and control or primary open angle eyes.^[11, 12] The occurrence of a small optic disc in eyes with pseudoexfoliation glaucoma is diagnostically important, because in a small optic disc glaucomatous damage may be missed and the discs may erroneously be considered normal.^[9]

The lamina cribrosa of the optic disc appears to undergo elastosis, although pseudoexfoliation material has not been identified in this region.^[9] Netland et al demonstrated a marked and site specific elastosis of the lamina cribrosa, which is more pronounced in eyes with pseudoexfoliation glaucoma than in primary open angle glaucoma, suggesting an abnormal regulation of elastin synthesis and or degradation. These alterations of the connective tissue at the level of the lamina cribrosa may increase the susceptibility of optic nerve fibers towards mechanical and ischemic damage.^[55]

The mechanical component of optic nerve damage certainly predominates but the risk of further glaucomatous damage is increased by vascular factors and pseudoexfoliation associated alteration of blood vessels.^[9] Many studies have reported general disturbance of ocular and retro bulbar perfusion in pseudoexfoliation patients with or without glaucoma.^[9] It has been shown a pronounced vasculopathy of the iris with hypoperfusion and anterior chamber hypoxia, a reduction of pulsatile ocular blood flow and a significantly diminished blood flow velocities and increased resistivity indices in the ophthalmic artery, the central retinal artery and short posterior ciliary arteries.^[56]

Higher rates of disc hemorrhages and central retinal vein occlusions have been reported in pseudoexfoliation glaucoma patients.^[57] It has also been shown that retinal vessel caliber did not differ between pseudoexfoliation glaucoma and primary open angle glaucoma.^[11] Morphological correlates of these pathophysiologic findings are perivascular accumulations of pseudoexfoliation material and elastotic alterations of vessel walls, as they have been demonstrated

by electron microscopy in the walls of iris vessels, aqueous veins, ciliary arteries and central retinal artery.^[5, 58]

A significant correlation between the intraocular pressure level at the time of diagnosis and the mean visual field defect could be only established in pseudoexfoliation glaucoma but not in primary open angle glaucoma patients, suggesting intraocular pressure as the main risk factor for glaucomatous damage in this type of glaucoma.^[15] In a study by Anastasios G et al it was found that the visual field defect in eyes with pseudoexfoliation was worse than in eyes with primary open angle glaucoma.^[54]

These findings suggest that the glaucomatous damage in patients with pseudoexfoliation glaucoma may be more directly related to intraocular pressure than in primary open angle glaucoma, where the situation may be more complex. The rapid progression of pseudoexfoliation glaucoma probably reflects the cumulative effects of the daily trauma of intraocular pressure spikes on the optic nerve.^[9]

It is presumed that increase in intraocular pressure in patients with pseudoexfoliation syndrome is secondary to increased outflow resistance that results from mechanical blockage of the trabecular meshwork by pigment and exfoliative material.^[59] In a study done by Johnson and Brubaker^[60], aqueous flow was decreased by 20% in the affected eyes. In a study by Lutjeijn et al it has been noted that ultrastructural changes in ciliary epithelium of eyes with exfoliation glaucoma that indicated increase protein synthesis and decreased

active transport in these cells and thereby increase resistance to outflow of aqueous.^[59]

Histopathological analyses indicated fundamental differences in nature of pseudoexfoliation glaucoma and primary open angle glaucoma. Primary open angle glaucoma is characterized by increased juxtacanalicular plaque material and decreased trabecular meshwork cellularity whereas both plaque material and cellularity are unchanged in pseudoexfoliation glaucoma compared to normal eyes, but there is production and deposition of the characteristic fibrillar pseudoexfoliation material.^[61]

Thus the primary cause of chronic pressure elevation in pseudoexfoliation eyes appears to be active participation of trabecular endothelial cells, particularly Schlemm's canal endothelial cells, in the generalized abnormal matrix process, leading to local production and accumulation of pseudoexfoliation material in the juxtacanalicular region of the meshwork and subsequent degenerative alteration of Schlemm's canal wall.^[62] A partial mechanism may be that a pseudoexfoliation clump could be passively washed in with aqueous flow after abrasion from the lens and pupillary margin and may be trapped in the uveal pores of the meshwork.^[29]

Even though it is most widely held that obstruction of trabecular pores by pseudoexfoliation material, either locally produced or passively deposited, is major mechanism of chronic pressure elevation, contributions due to pigment dispersion and increased aqueous protein concentrations have been proposed.^[61]

Another interesting observation has been the proliferation of corneal endothelial cells beyond Schwalbe's line resulting in pretrabecular layer of extracellular material including pseudoexfoliation fibrils produced by migrating or proliferating endothelial cells.^[58, 61] This may be a consequence of anterior chamber hypoxia in pseudoexfoliation eyes, stimulating corneal endothelial cell proliferation. Such observation may partially explain why there is a variable response to medical therapy with some patients seeming to respond so poorly.^[9]

Another point of view of increased intraocular pressure is that pseudoexfoliation is associated with angle closure or narrow angles. In a study by Layden and Shaffer^[63] 23% of their cases with exfoliation syndrome had narrow angles. Ritch^[64] found signs of pseudoexfoliation in 28% of consecutive patients with angle closure glaucoma. Eyes with pseudoexfoliation have often narrowed chamber angle^[59, 65] and smaller anterior chamber volumes and in the presence of weak zonules, a minimal anterior subluxation of the lens predisposes to development of angle closure glaucoma via pupillary block.^[65] The decrease in anterior chamber depth between the supine and prone position was shown to be greater in eyes with pseudoexfoliation.^[66]

Characteristic features of pseudoexfoliation eyes that may predispose to the development of pupillary block angle-closure glaucoma include the formation of posterior synechiae, an increased iris rigidity and decreased iris motility, an impairment of blood-aqueous barrier and increased protein concentrations of aqueous humor and anterior movement of the lens secondary to zonular weakness.^[5] In extreme and rather rare cases with marked zonular laxity, anterior

displacement of the lens may be so pronounced that a ciliary block angle-closure glaucoma is induced by contraction of ciliary muscle.^[67]

It was found that pseudoexfoliation patients with narrow or occludable angles were hyperopic, which suggests that axial length and anterior chamber related to the increased prevalence of occludable angles and angle-closure glaucoma in pseudoexfoliation.^[65]

Miotics may aggravate both pupillary block and forward movement of the lens-iris diaphragm. A narrow angle associated with pseudoexfoliation syndrome may therefore, represent an additional argument for prophylactic iridotomy.^[68] Secondary angle-closure glaucoma following central retinal vein occlusion with rubeosis iridis may also occur in pseudoexfoliation eyes, because retinal vein occlusion appears to be more common in patients with pseudoexfoliation syndrome or glaucoma, perhaps due to high intraocular pressure values.^[57]

The differential diagnoses of pseudoexfoliation syndrome are: pigment dispersion syndrome or pigmentary glaucoma, Fuch's heterochromic iridocyclitis, uveitis, diabetes mellitus etc. Retro corneal pseudoexfoliation accumulations may be misdiagnosed as inflammatory precipitates.^[9] In pigment dispersion syndrome or glaucoma, the trabecular meshwork pigmentation is dense and even compared to the irregular patchy pigmentation in pseudoexfoliation syndrome or glaucoma. The iris transillumination defects of pigment dispersion syndrome or glaucoma appear as mid peripheral radial spokes, whereas those in pseudoexfoliation appear as moth eaten patches around the pupil.^[69]

In a study done in south India, to study the profile of pseudoexfoliation in Indian population, it was found that the mean age of subjects with pseudoexfoliation syndrome is 11.16 years older than normal population studied (≥ 40 yrs). There was no sex predilection and the mean intraocular pressure was 1.29 mmHg higher than normal population. Ocular hypertensives were 9.3% and with glaucomatous optic neuropathy were 13% of pseudoexfoliation cases. The prevalence of narrow angles with pseudoexfoliation was 14.8%, which is twice the prevalence without pseudoexfoliation. It was found that nuclear sclerosis was more prevalent in eyes with pseudoexfoliation.^[8]

Goldmann applanation tonometry is the clinical standard for measurement of intraocular pressure. It determines the force necessary to flatten or applanate an area of the cornea 3.06 mm in diameter. For this area of applanation, the intraocular pressure in millimeters of mercury is equal to the force of the tonometer in grams multiplied by 10. Applanation tonometry displaces only 0.5 μ l of aqueous humor. Goldmann tonometry is quite accurate and reproducible if proper technique is used. Inter-observer variability is in the range of 0 to 3 mmHg which is less than the diurnal variation of intraocular pressure. The tear meniscus is stained with fluorescein dye, and when viewed in blue light, the fluorescence of the dye-stained meniscus is easily distinguishable from the flattened area of cornea beneath the instrument's contact surface. The examiner uses a slit lamp biomicroscope to view the surface of the applanated cornea through the centre of the prism.^[18]

An interesting and unanswered question is why some eyes with pseudoexfoliation appear to never develop glaucoma.^[70] This may be explained simply by the individual amount of pseudoexfoliation material present in the outflow structures, by inter-individual differences in managing the metabolic disturbances, by additionally required predisposing or genetic factors, or by inter-individual differences in the susceptibility to optic nerve damage, mediated by vascular or structural factors.^[9] An underlying defect in aqueous humor dynamics or involvement of glaucoma susceptibility gene may also be considered as a requirement for glaucoma development in pseudoexfoliation eyes, because patients with unilateral pseudoexfoliation syndrome may also have glaucoma in the fellow eye.^[10] Degeneration of ciliary epithelium is part of the disease, and reduced aqueous secretion may explain why some eye with pseudoexfoliation do not develop glaucoma.^[9]

There are few published studies on the effects of cataract surgery on pseudoexfoliation glaucoma.^[71] It is reported that though cataract surgery does not eliminate post operative intraocular pressure elevations, it reduces their frequency and magnitude. But the exact mechanism is not well understood.^[72]

MATERIALS AND METHODS

This study was conducted in the Department of Ophthalmology, Christian Medical College from March 2005 to June 2006.

TYPE OF STUDY:

Prospective cohort study

INCLUSION CRITERIA:

All patients found to have pseudoexfoliation in one or both eyes on presentation, with or without evidence of glaucoma.

EXCLUSION CRITERIA:

Patients were excluded from the study if any one or more of the following was present:

1. Any patient who had previously undergone any intraocular surgery in the eye with pseudoexfoliation.
2. Any patients on anti-glaucoma medications or on topical or systemic steroids.
3. Any patient with a history of ocular trauma or a documented history of uveitis.
4. Any other ocular pathology apart from age-related cataract that could contribute to development of a secondary glaucoma, eg corneal scars suggestive of suppurative keratitis.

METHODS:

All patients presenting in the OPD were screened for pseudoexfoliation as part of the routine ocular examination. Those who had pseudoexfoliation material on the corneal endothelium, the pupillary margin, the angle or on the lens were recruited for the study. Consent for participation in the study was obtained. DVT was recorded, and details of the clinical examination necessary for the study were confirmed and then entered in the proforma (see Appendix I). These included gonioscopy findings, grade of cataract, presenting IOP and dilated pupil disc appearance. Depending on the best corrected visual acuity, visual field assessment by Humphrey's Field Analyzer II was attempted.

Test for diurnal variation of intraocular pressures in all patients was done by a single observer. The diurnal variation of intraocular pressure was taken between 9:30am and 3:30pm at 2 hourly intervals. The IOP was recorded using Goldmann's applanation tonometer on a Zeiss slit lamp biomicroscope. Calibration of the tonometer was checked weekly as part of the routine maintenance protocol of the department. The same instrument was used for all recordings. Patients enrolled in this study who were undergoing cataract surgery had their diurnal variation of intraocular pressure and visual field assessment by Humphrey's Field Analyzer II repeated 6 weeks after surgery. Those not undergoing a surgical procedure were followed up every 3 months for assessment of DVT and visual field assessment.

Cataract surgery was performed according to existing department protocols. The surgical techniques used included Blumenthal manual sutureless

small incision cataract surgery, sutureless phacoemulsification and standard extracapsular cataract surgery with 10-0 sutures. An intraocular lens was routinely implanted; these were usually single piece PMMA posterior chamber lenses. Anterior chamber or sclerally fixated lenses were used as indicated. No effort was made to control or direct the type of surgery for study patients. The treatment decisions were made by personnel not involved with the study based entirely on the merits of the individual case.

Patients found to have PEX glaucoma were offered combined glaucoma and cataract surgery in accordance with the preferred practice pattern of the department. It had been debated within the department whether it was worthwhile attempting medical control of IOP followed by cataract surgery with subsequent withdrawal of medication to assess the effect that cataract surgery had on IOP in PEX glaucoma. However, because of the serious nature of the condition, its rapid progression and compliance and follow up problems, it was felt that it was ethically indefensible to deviate from established protocol for patients with IOP ≥ 30 mmHg or with advanced disc changes. It was considered permissible to offer an option of medical treatment when IOP was <30 mmHg with minimal or no disc damage. As the primary aim of the study was to determine whether DVT assisted the diagnosis of PEX glaucoma, our main concern was with patients presenting with initially normal IOP to see if DVT revealed any reading outside the normal range. PEX glaucoma was defined by the presence of intraocular pressure >21 mmHg in an eye with PEX in accordance with accepted definitions of a secondary glaucoma.

SAMPLE SIZE:

Sample Size was calculated by the formula:

$$\frac{1 + 2(Z_{\alpha} + Z_{1-\beta})^2 K}{(\log C_0)^2 (K - 1)}$$

Where Z_{α} (alpha error) = 1.96, $Z_{1-\beta}$ (power) = 0.842 (i.e. 80),

$$C_0 = \frac{1 + K g_0}{1 + K g_1}$$

$$g_0 = \frac{\rho_0}{1 - \rho_0} \quad g_1 = \frac{\rho_1}{1 - \rho_1}$$

where, θ_0 = sample reliability = 0.4

θ_1 = population reliability = 40%

K = number of replications = 1 (in this study)

By the above formula, the sample size calculated is 80. We chose to include 100 patients to allow for failure in follow up and dropouts.

STATISTICAL METHODS:

Intra Class Correlation Coefficient Ratio: Intraclass correlations (ICC) are often used as measures of agreement for items that are deemed to be in the same category or class. This test can thus be used in some situations to assess the reliability of a particular investigation. ICCs are ratios of rating variance to total variance. They compare the covariance of the ratings with total variance. For continuous parameters such as IOP, ICC is considered superior to the kappa statistic which is normally used to test agreement with dichotomous variables. We chose ICC as the most accurate and statistically acceptable test of agreement between the initial intraocular pressure recorded and the diurnal variation of tension.

Receiver Operator Characteristic Curve (ROC curve): It is a curve to establish a relationship between sensitivity and specificity.

Sensitivity is defined as the proportion of people with the disease who have a positive test for the disease. A sensitive test will rarely miss people with the disease.

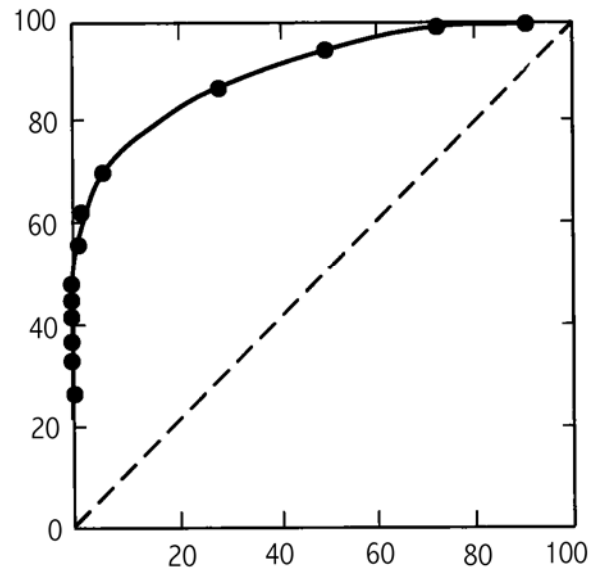
Specificity: is the proportion of people without the disease who have a negative test. A specific test will rarely misclassify people without the disease as diseased.

Test		Disease	
		Present	Absent
	Positive	A	b
	Negative	C	d

Consider the above table which is a 2x2 representation of data obtained while testing for a disease against a gold standard. The lower case letters in the four cells represent numbers of patients who fall into the categories indicated. From this table we calculate sensitivity as $a/(a+c)$ and specificity as $b/(b+d)$.

An ROC curve is constructed by plotting the true-positive rate (sensitivity) against the false positive rate (1-specificity) over a range of cut-off values. Tests that perform less well have curves that fall closer to the diagonal running from lower left to upper right. The diagonal shows the relationship between true-positive and false-positive rates that would occur for a test yielding no information i.e. a test with a 50% chance of being positive. The value of a test lies in its predictive value, and this is dependent on the actual prevalence of the condition being tested for in the population being tested. The ROC curve helps in

this situation by allowing us to decide where the best cut off point should be (at or near the “shoulder” of the ROC curve).



The over all accuracy of a test can be described as the area under the ROC curve; larger the area, better the test. A curve that perfectly discriminates between the two groups would give a curve coincided with left and top sides of the plot. A test that is completely useless would give a straight line from bottom left corner to right top corner. The ROC curve compares a particular test to the already set gold standard; in this study we had to study the usefulness of diurnal variation of intraocular pressure for diagnosing glaucoma (for which the gold standard is intraocular pressure and disc and field changes) in eyes with pseudoexfoliation.

Test of Proportion (Critical Ratio, z test):

This is a simple statistical test to determine whether the ratio of distribution of dichotomous variables in a study population is different from the distribution in the general population (more than can occur by chance). We use this test to detect any disproportion in the sex distribution of our patients and also to determine whether IOP measurements were significantly different in unilateral PEX compared to the normal eye.

Student's t-test (Paired t-test):

This test is sampling a distribution about its mean. The t test determines a probability that two populations are the same with respect to the variable tested. We used this test to determine the effect of cataract surgery on the intraocular pressure in eyes with pseudoexfoliation, by comparing the paired distribution of mean preoperative IOP and mean postoperative IOP for each operated eye.

RESULTS AND ANALYSIS

The total number of patients screened for the study was 140. Of these, 100 consented to abide by the protocol and were enrolled. The main reason given for unwillingness to participate was lack of time to spare for DVT and follow up visits.

SEX DISTRIBUTION:

There were 55 males and 45 females enrolled (Figure 1). Using the one sample test of proportion the sex distribution was not found to be significantly different from the general population ($p = 0.32$).

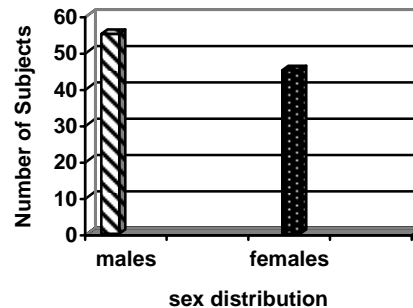


Figure 1: Sex Distribution of Subjects

DISTRIBUTION ACCORDING TO AGE:

All patients included in this study were above 40 years of age. The mean age was 64.8 (± 7.98 SD), the minimum age being 45 years and maximum age being 82 years. The maximum number of patients was in the age group of 60-69 years (Table 1; Figure 2).

Table 1: Age Distribution of Patients

Age Group (Years)	Number of Subjects
40-49	3
50-59	19
60-69	47
70-79	26
≥ 80	5

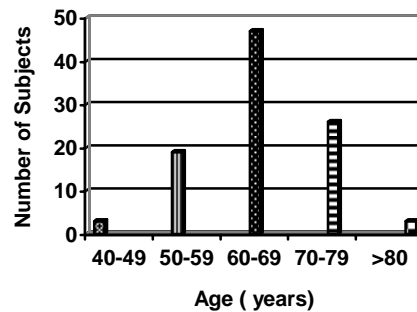


Figure 2: Bar Chart Representation of Age Distribution

Patients included in this study were those who came to our institution over a period of 15 months. These were patients who visited or were referred to our outpatient department as well as patients presenting to our outreach cataract and ocular morbidity screening camps. As expected, the majority of patients willing to enroll in the study were from within Vellore District. These numbered 81. The remaining patients were from towns and cities outside Vellore.

UNILATERAL or BILATERAL:

Patients in this study had either unilateral or bilateral presentation of pseudoexfoliation. Pseudoexfoliation material was noted on the corneal endothelium, on the pupillary margin, on the lens and in the angles. Early stages of pseudoexfoliation i.e. “brown stage” which consists of subtle changes to the

lens capsule predominantly marked by streaks of iris pigment on the zonules were also seen and included in the study.

Forty-eight patients had unilateral PEX and fifty-two had bilateral PEX. Of patients who presented with unilateral pseudoexfoliation 28 had no difference in presenting intraocular pressure between the eyes that had pseudoexfoliation and the eye that did not have pseudoexfoliation. 18 patients showed a difference between the affected and unaffected eyes and 2 patient's data were missing (see Table 2).

Table 2: Difference in presenting IOP in unilateral PEX

Number of Patients	Initial IOP (mmHg)
28	0
7	1
6	2
1	3
1	4
0	5
1	6
2	≥ 7

Using the two sample test of proportion, a p value of 0.037 was obtained, thus showing that there was no significant difference in presenting intraocular pressure between the eye having pseudoexfoliation and the eye not having pseudoexfoliation.

INITIAL IOP and DVT

The initial intraocular pressure recorded in patients with pseudexfoliation was as shown (Table 3; Fig 3). The maximum number of eyes was in the pressure range 10-14 mmHg. The data of 4 eyes were missing.

Table 3: Distribution of Presenting IOP

IOP Range (mmHg)	Number of eyes
<10	10
10-14	93
15-19	66
20-24	21
25-29	3
≥ 30	3
Missing	4

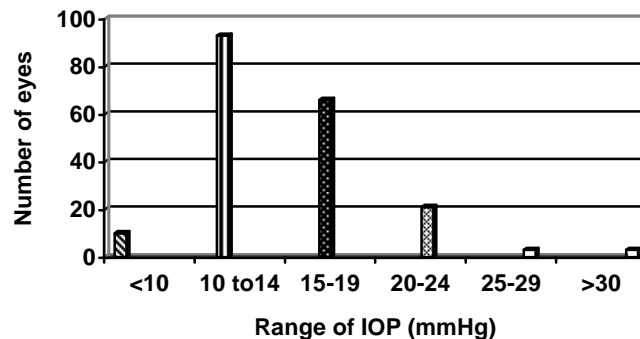


Figure 3: Distribution of Initial IOP Measurements

According to our definition of secondary glaucoma, we defined five eyes as having PEX glaucoma. Of these two underwent combined glaucoma and cataract surgery, as they either had IOP > 30 mmHg or showed advanced disc damage or both. Two more eyes were started on medical therapy and underwent cataract surgery. One patient is being followed up without surgery or medical treatment as she demonstrates no evidence of disc damage.

The details of the DVTs recorded are given below (Tables 4 and 5). Only two eyes had a DVT greater than 6 mmHg. These were eyes which had

confirmed PEX glaucoma and underwent combined cataract and glaucoma surgery. Interestingly, the remaining eyes which fulfilled the diagnostic criteria for secondary glaucoma did not demonstrate a wider than normal variation of IOP. These were eyes which did not show much evidence of damage to the optic nerve head.

We further analyzed the IOP data with ICC and ROC curves (see later).

Table 4: Variation in IOP measured by DVT (mmHg)

Variation in IOP	Number of eyes	
	RE	LE
0	14	22
1	11	07
2	48	40
3	06	05
4	12	12
5	03	03
6	01	04
≥7	00	02
missing	05	05

Table 5: Mean and standard deviation of initial IOP and DVT

Age group	Mean IOP (Initial)	Mean IOP (DVT)	
		RE	LE
40-49	18.33(±5.86)	17.83 (±4.53)	18.33 (±5.00)
50-59	14.50(±3.52)	13.92 (±3.64)	14.25 (±3.57)
60-69	15.94(±4.71)	15.25(±3.58)	16.33(±5.41)
70-79	15.13 (±4.33)	14.77 (±3.57)	15.67 (±4.55)
≥80	13.33 (±1.15)	11.62(±0.629)	12.18(±1.02)

EFFECT OF CATARCT SURGERY :

As we had 77 patients with cataract, the effect of cataract surgery on intraocular pressure was analyzed. Of the 77 undergoing cataract surgery 31

returned for the 6 week follow up visit. Using the paired t-test, we compared the preoperative and 6 week postoperative intraocular pressures (see Table 6). In this group, cataract surgery did not have any effect on the intraocular pressure in eyes with pseudoexfoliation.

Table 6: Effect of cataract surgery on IOP

Mean IOP (\pm Standard Deviation) mmHg	
Preoperative	Postoperative
15.19 \pm 3.86	15.25 \pm 4.06

$$p = 0.149$$

To assess the agreement between the initial intraocular pressure recorded and the diurnal variation of intraocular pressure, we used the intra class correlation coefficient (ICC). It was shown with this test that there was good agreement between the initial intraocular pressure recording and the diurnal variation of intraocular pressure. We analyzed the right and left eyes separately, and since both showed good agreement it was unnecessary to pool the data and do a further analysis. In practical terms, what the test showed was that the DVTs performed were likely to be highly reliable, judging from the initial IOP.

Reliability - Intra Class Correlation Coefficient for DVT and IOP (right eyes)

RELIABILITY ANALYSIS - SCALE (ALPHA)
Intraclass Correlation Coefficient

Two-way Random Effect Model (Absolute Agreement Definition):

People and Measure Effect Random

Single Measure Intraclass Correlation = 0.7359

95.00% Confidence Interval: Lower = 0.6277 Upper = 0.8162 ; P <= 0.0001

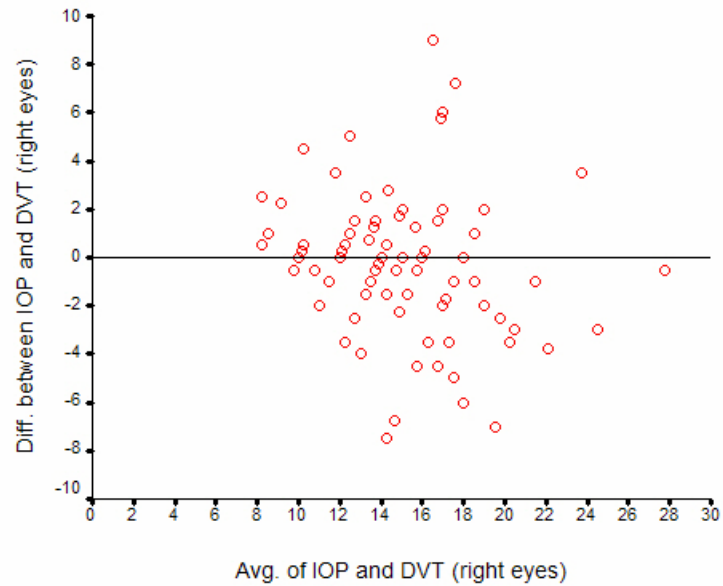


Figure 4: ICC curve for DVT and IOP (RE)

Reliability - Intraclass correlation coefficient for IOP and DVT (left eyes)

RELIABILITY ANALYSIS - SCALE (ALPHA)

Intraclass Correlation Coefficient

Two-way Random Effect Model (Absolute Agreement Definition):

People and Measure Effect Random

Single Measure Intraclass Correlation = 0.8100

95.00% Confidence Interval: Lower = 0.7272 Upper = 0.8695

P < 0.0001

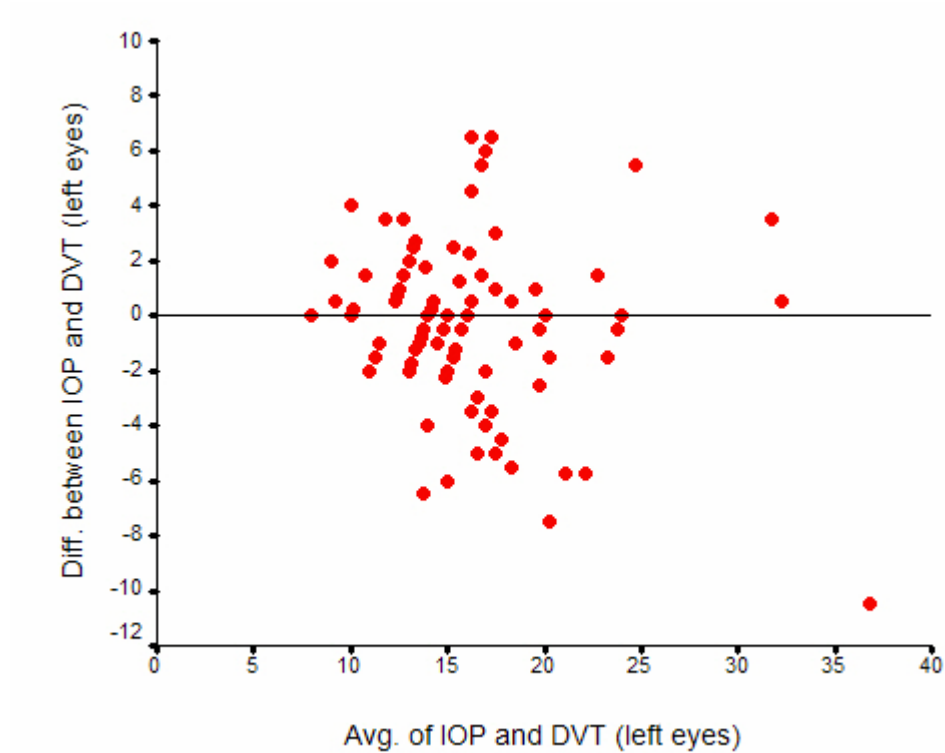


Figure 5: ICC curve for DVT and IOP (LE)

To assess the need for doing diurnal variation of intraocular pressure in eyes with pseudoexfoliation, the data was analyzed using the receiver operator characteristic curve. This analysis showed that there was no benefit in recording a diurnal variation of intraocular pressure in eyes with pseudoexfoliation in order to detect pseudoexfoliation glaucoma. The ROC curves for the right and left eyes are shown in Figures 6 & 7. From the shape of the curves it is apparent that DVT is not of any use compared to initial IOP in diagnosing PEX glaucoma.

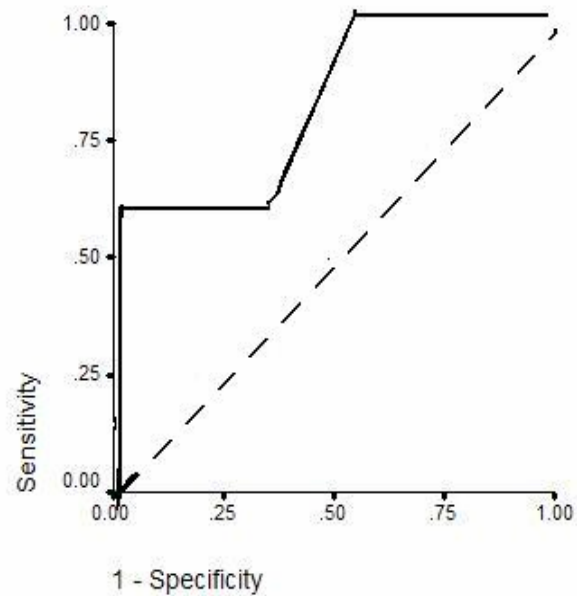


Figure 6: ROC curve for Right Eye

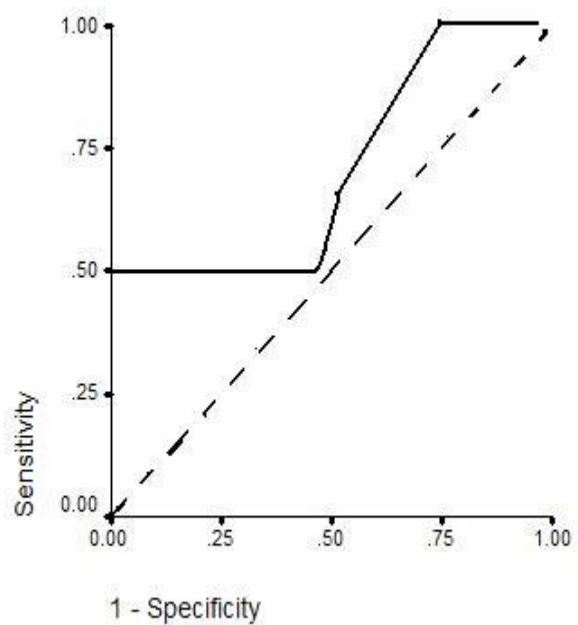


Figure 7: ROC curve for Left Eye

CUP-DISC RATIO:

The cup-disc ratio was assessed stereoscopically using the slit-lamp biomicroscope and +90D lens. Due to the presence of cataract, a detailed disc examination was not possible in most patients, though an impression of cup-disc ratio was recorded. In 13 patients even this could not be assessed due to advanced cataract. (see Table 7; Figure 8)

Table 7: Cup-Disc Ratio Distribution

Cup-disc ratio	Number of patients
0.2	9
0.3	32
0.4	22
0.5	10
0.6	8
0.7	5
0.8	1
Hazy media	13

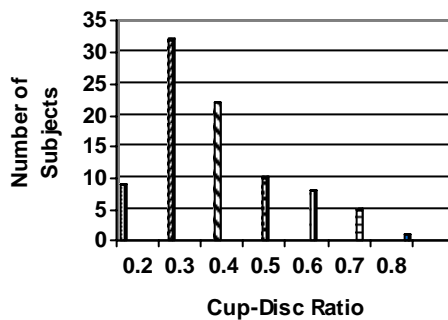


Figure 8 : Distribution of Cup-Disc Ratio

Among the patients under study, only one patient had narrow angles not judged to be occludable and the remaining had open angles. There were none with closed angles, peripheral anterior synechiae or evidence of past closure.

Other features such as the presence and density of pigmentation, Sampaolesi's lines, the distribution and density of PEX material deposition and other details were not required by the study protocol and hence not recorded.

Visual fields assessed by Humphrey's Field Analyzer II prior to cataract surgery were unreliable in all patients. Even though the visual acuity improved after cataract surgery, the repeat fields did not meet the reliability criteria. Hence analysis of visual field data could not be done.

DISCUSSION

The awareness of the importance of pseudoexfoliation syndrome has increased considerably in recent years.^[11] We have realized that it is a common disorder affecting a large proportion of our cataract and glaucoma patients, we have improved the diagnosis of early stages and we are beginning to understand the underlying pathophysiology.^[6] Pseudoexfoliation syndrome is not only an ocular disease but a generalized disorder involving abnormal production or turnover of extra cellular matrix material or both. The PEX material itself has been shown to be an abnormal basement membrane like material in several intraocular and extraocular tissues.^[8] PEX syndrome is a common age-related though often overlooked disorder. The exact trigger for production of pseudoexfoliation material remains to be identified.^[9]

There are a number of ocular complications associated with pseudoexfoliation, most notably glaucoma.^[9] Pseudoexfoliation glaucoma has sometimes been referred to as a rare secondary glaucoma, mainly seen in Scandinavian countries, but is now understood to be occurring worldwide. However, there may still be a need to increase the awareness of its importance. Previous studies have demonstrated that the prevalence of glaucoma is higher in patients with pseudoexfoliation than in those without pseudoexfoliation.^[16] Pseudoexfoliation glaucoma is identified as the most common cause of secondary open angle glaucoma.^[10] Though open angles are generally described with pseudoexfoliation, angle closure glaucoma may also occur due to the development of pupillary block secondary to posterior synechiae, increased iris

rigidity and decreased iris motility. Impairment of the blood-aqueous barrier and increased protein concentrations in the aqueous humor with weak zonules result in forward movement of the lens-iris diaphragm. PEX may also occur in eyes with an anatomic predisposition to pupillary block such as eyes with short axial length and shallow anterior chamber depth.^[9]

Glaucoma associated with pseudoexfoliation is generally considered to result from obstruction of the aqueous outflow system either by pigment or by the exfoliative material, or both.^[5] Ultra structural studies show that the progressive accumulation of pseudoexfoliation material in the trabecular meshwork causes a swelling of the juxtacanalicular tissue and a marked disorganization of the Schlemm's canal architecture.

Additional pathogenetic factors contributing to pressure rise and glaucoma development include marked pigment dispersion, increased aqueous humor protein concentrations, vascular factors and connective tissue alterations of the lamina cribosa.^[9]

Pseudoexfoliation glaucoma has a more serious clinical course and worse prognosis than primary open angle glaucoma.^[9] It is typically associated with higher mean intraocular pressure levels, greater diurnal pressure fluctuations, marked pressure spikes, a higher frequency and severity of optic nerve damage, more rapid visual field loss, poorer response to medications, and more frequent necessity for surgical intervention.^[6] Pseudoexfoliation glaucoma further differs from primary open angle glaucoma by demonstrating a more frequent asymmetry

of manifestation, more pronounced chamber angle pigmentation and acute rises in IOP after mydriasis.^[9]

There has been much speculation regarding why pseudoexfoliation is associated with a less favourable prognosis for glaucoma patients. To a certain extent the effect may be IOP mediated i.e., pseudoexfoliation may cause an increased IOP through production and deposition of pseudoexfoliation material and pigment in the trabecular meshwork and Schlemm's canal with subsequent increased outflow resistance. However, because evidence that pseudoexfoliation seems to be an independent risk factor is increasing, it also seems reasonable to look for other possible explanations.^[16] Elastosis affecting the lamina cribrosa might be a pathogenetic factor. An increased accumulation of elastic fibres in the lamina cribrosa in eyes with pseudoexfoliation glaucoma compared with eyes with POAG has been documented.^[55] An effect on blood flow through vascular changes is another possibility. The presence of pseudoexfoliation fibres has been documented in the walls of ciliary arteries.

In this study, we found a male: female ratio of 1.2:1 ($p < 0.05$) showing that there is no sex predilection for pseudoexfoliation. In a study done in south India by R Krishnadas et al where they have found a male preponderance in patients with pseudoexfoliation. On the contrary, Ritch et al found a female preponderance. Most of our patients were in the age group of 60-69years. Many patients in the older age group (i.e. ≥ 70 years) were not willing to undertake the study as they could not wait long hours in the hospital for diurnal variation of intraocular pressure recording; hence our age distribution is probably biased. Due

to the lack of data in this older age group, we are not able to demonstrate the already established fact that presence of pseudoexfoliation increases with age.^[6,7,8] All stages of pseudoexfoliation were included in the study (i.e.) from the early 'brown stage' pseudoexfoliation to the established florid pseudoexfoliation. We lack data regarding the anatomical site of pseudoexfoliation material seen in the eye. It would be interesting to look for an association between the site of pseudoexfoliation material seen and the presence of glaucoma. For example, does the presence of pseudoexfoliation material and pigment in the angle increase the risk of a rise in intraocular pressure as suggested by the postulated mechanisms of pseudoexfoliation glaucoma? So, would recording of DVT after dilation be a better indicator of glaucoma in eyes with pseudoexfoliation? Longer follow up would be needed to see whether patients with early 'brown' stage pseudoexfoliation convert to florid pseudoexfoliation and PEX glaucoma. Does intraocular pressure have any correlation with the stage of pseudoexfoliation?

Answering some of the above questions may also clarify some aspects of clinical practice. Patients with open angle glaucoma based on IOP, disc and fields will be classified as PEX glaucoma if PEX is noted. However, it is perfectly possible for a patient with POAG to have PEX. The latter may not be contributing at all to the mechanism of glaucoma, but with our current understanding of the condition, we are not able to distinguish this possible subset from patients with true PEX glaucoma.

In this study we found no difference in intraocular pressure between the normal and affected eye in cases of unilateral pseudoexfoliation. Similar observation has been made by R Krishnadas et al^[7] in a study from south India. Puska et al^[10] in their study have found a difference in intraocular pressure between the pseudoexfoliation eye and fellow non-pseudoexfoliation eye. Can race have a role in determining the intraocular pressure in eye with pseudoexfoliation? A large, multicentric study would enable us to have a better insight into this finding. Remembering the fact that PEX was originally supposed to be peculiar to Scandinavian races, and the fact that there are still “pockets” around the world where PEX is common (eg in South India), racial differences in presentation, severity and prevalence of glaucoma in this condition need to be established. Five of our 100 patients had PEX glaucoma, giving us a prevalence of 5% in our local population.

We had 3 patients with unilateral PEX with IOP <22mHg but cup-disc ratio ≥ 0.7 in both eyes. Were these patients NTG or undiagnosed POAG with pseudoexfoliation a coincidental finding? To analyze this we would have to follow these patients for progression of cupping of the optic disc and for visual field defects. There were 2 patients in this study who had raised intraocular pressure but the optic disc cupping was 0.3. Are they really secondary (pseudoexfoliation) open angle glaucoma or are they ocular hypertensives with pseudoexfoliation being a coincidental finding? These patients would also have to be followed up long term with optic disc and visual field assessment. Another interesting aspect to look for in clinically unilateral cases of pseudoexfoliation

would be any clues that would suggest the presence of pseudoexfoliation in the unaffected fellow eye. As mentioned earlier, pseudoexfoliation increases with age. Pigment dispersion after dilation, increased pigmentation of trabecular meshwork and pupillary sphincter atrophy are seen in old age and in eyes with pseudoexfoliation. Is there a difference in the amount of pigment dispersed and the pattern of trabecular meshwork pigmentation in eyes with pseudoexfoliation compared to the non-affected eye? Would these findings give us any hint about the presence of pseudoexfoliation in the clinically unaffected eye?

There is data available which documents that pseudoexfoliation eyes can have narrow angles and narrow angle glaucoma opposed to the popular belief that PEX glaucoma is a secondary open angle glaucoma. R Ritch et al found 17 out of 60 patients with closed angles. Is pupillary block the only mechanism for angle closure in these eyes? If there is pupillary block, will peripheral iridotomy help? It would be interesting to look for association between the axial length, anterior chamber depth and angle structure in eyes with pseudoexfoliation. Is hyperopia or myopia more common in pseudoexfoliation with closed angles? In our group of patients shallow chambers and narrow angles were not noted.

Large intraocular pressure variation and /or intraocular pressure spikes are major risk factors for glaucoma. DVT recording helps us to detect these variations and spikes. This test can be done in a clinic setting or as a recording over 24 hours. Konastas et al^[13] have reported that the peak level of intraocular pressure occurs more frequently outside office hours and so 24 hour recording of the intraocular pressure would give a better idea of diurnal variation. We

recorded DVT in a clinic setting. We found in our study that there was a good agreement between the initial recording of IOP and DVT. Thus DVT did not have any added benefit in identifying glaucoma in eyes with pseudoexfoliation.

While we have not, in our study, encountered any case of PEX glaucoma with an initial “normal” IOP who subsequently demonstrated a high IOP on DVT, we cannot with absolute certainty say that PEX glaucoma will present inevitably with an initially high IOP. For our sample size with a value of zero patients of PEX glaucoma with normal initial IOP, the confidence interval calculations would suggest that as many as 6% could have PEX glaucoma and normal initial IOP in a general population. Of interest, though, is the fact that no patient with initially high IOP had any recording of IOP less than 21 mmHg during the DVT. This tends to reinforce our assumption that PEX glaucoma must present with an initially high IOP.

Of equal interest is what happens to patients with normal IOP, PEX, normal discs and visually insignificant cataract. The literature seems to suggest that some proportion of them will go on to develop PEX glaucoma^[10], but there is no clinical indication of which patients are at risk for this progression. We are thus not in a position to suggest with any authority a follow up schedule for these patients. A yearly follow up for patients at risk for POAG due to ocular hypertension, family history, myopia, large cups and other established risk factors is reasonable because POAG progresses slowly. Is the same follow up schedule acceptable for patients with PEX and no glaucoma? More data is needed to answer this question.

Krupin et al^[71] and Merkur et al^[72] have shown that cataract surgery has the effect of lowering IOP in eyes with pseudoexfoliation, though the exact mechanism is not known. Does removal of the lens remove the source of the PEX material and thus interrupt the chain of events leading up to glaucoma? Could lens thickness have a role to play in raised intraocular pressure in eyes with pseudoexfoliation? Does cataract surgery only relieve the pupillary block or does it open up any other channels for drainage of aqueous? Cataract surgery causes disruption of blood-aqueous barrier, increases post-operative inflammation and damages the trabecular meshwork. It could thus exacerbate the severity of already existing PEX glaucoma or possibly precipitate the development of glaucoma in an eye “on the brink”. In eyes with pseudoexfoliation, postoperative inflammation persists for longer time than in normal eyes.^[70] Does the intraocular pressure rise after such prolonged inflammation and does permanent trabecular damage ensue? In our study, though had limited number of patients coming for the final postoperative visit, we found that cataract surgery had no effect on intra ocular pressure in eyes with pseudoexfoliation. Longer follow up and larger studies will help us to better understand the effect of cataract surgery on intraocular pressure.

In our study, visual field examination by the Humphrey’s Field Analyzer II 30-2 SITA standard program was not a reliable indicator of disc damage caused by raised intraocular pressure. The main reasons were related to unreliability of the patient’s performance during the field test. This led to bizarre field printouts that were difficult to interpret. As most patients had advanced

cataract, this is not surprising. In fact, the best visual acuity in our entire patient group was 6/24, and many had only finger counting vision.

CONCLUSIONS

1. Recording diurnal variation of intraocular pressure in eyes with pseudoexfoliation does not provide any additional benefit compared to the initial presenting IOP.
2. Initial intraocular pressure recording is sufficient to diagnose glaucoma in eyes with pseudoexfoliation. Disc changes may provide an additional indication of advanced glaucoma.
3. Visual field recordings in patients with pseudoexfoliation presenting to an ophthalmology OPD were found to be unreliable due to the profound drop in visual acuity caused by cataract.
4. Cataract surgery was not shown to have any effect on intraocular pressure in eyes with pseudoexfoliation.

BIBLIOGRAPHY

1. Quigley HA. *Number of people with glaucoma worldwide*. British Journal of Ophthalmology 1996; 80; 89-393
2. Dandona R, Dandona L. *Review of findings of Andhra Pradesh Eye Disease Study: policy implications for eye care services*. Indian Journal of Ophthalmology 2001; 49; 215-234.
3. *Epidemiology of glaucoma*. Chapter 1: pg 4-9 in Becker Shafer's Diagnosis and Therapy of Glaucoma; 6th edition, ed Hoskin HD and Michael A, Mosby International 1989.
4. Thomas R, Korah S, Padma P, Muliylil JP. *Glaucoma- An emerging preventable cause of blindness*. Indian Journal of Community Health 1997; 3; 52-63
5. Naumann GOH, Schlötzer-Schrehardt U, Küchle M. *Pseudoexfoliation syndrome for the comprehensive Ophthalmologist. Intraocular and systemic manifestations*. Ophthalmology 1998;105; 951-968.
6. Ritch R, Schlötzer-Schrehardt U. *Exfoliation syndrome*. Survey of Ophthalmology 2001; 45; 265-315.
7. Krishnadas R, Nirmalan PK, Ramakrishnan R, Thulsiraj RD, et al. *Pseudoexfoliation in rural population of southern India: The Arvind Comprehensive eye survey*. American Journal of Ophthalmology 2003;135; 830-837.

8. Arvind H, Raju P, Paul PG, Baskaran M, et al. *Pseudo exfoliation in South India*. British Journal of Ophthalmology 2003; 87; 1321-1323
9. Schlötzer-Schrehardt U, Naumann GOH. *Pseudoexfoliation Glaucoma*. Chapter 11: pg 157-176 in *Essentials in Ophthalmology*, ed by Grehn F, Stamper R; Springer Verlag Berlin Heidelberg.
10. Puska PM. *Unilateral exfoliation syndrome: conversion to bilateral exfoliation and to glaucoma: a prospective 10 year follow up study*. Journal of Glaucoma 2002;11; 517-524.
11. Jonas JB, Papastathopoulos KI. *Optic disc appearance in pseudo exfoliation syndrome*. American Journal of Ophthalmology 1997; 123; 174-180.
12. Puska P, Vesti E, Tomita G, Ishida K, et al. *Optic disc changes in normotensive persons with unilateral exfoliation syndrome: a 3 year follow up study*. Graefe's Arch Clin Exp Ophthalmology 2000; 238; 659-663.
13. Konstas AGP, Stewart WC, Stroman GA, Sine CS. *Clinical presentation and initial treatment patterns in patients with exfoliation glaucoma versus primary open angle glaucoma*. Ophthalmology Surgery and Lasers 1997; 28; 111-117.
14. Konstas AGP, Tsatos I, Kardasopoulos A. *Preoperative features of patients with exfoliation glaucoma and primary open angle glaucoma: The AHEPA study*. Acta Ophthalmology Scandinavia 1998; 76; 208-212.

15. Teus MA, Castejón MA, Calvo MA, Pérez-Salaíces P, et al. *Intraocular pressure as a risk factor for visual field loss in pseudoexfoliative and in primary open angle glaucoma*. Ophthalmology 1998; 105; 2225-2230.
16. Aasved H. *Intraocular pressure in eyes with or without fibrilloglioneitheliocapsularis*. Acta Ophthalmology 1971; 49; 601-610.
17. Ritch R, Schlötzer-Schrehardt. *Exfoliation Glaucoma* . Chapter 24: pg 171-179 in *Glaucoma in the 21st century*, ed by Weinber RN, Kitazawa Y, Kreiglstein GK. Harcourt Health Communications, Mosby International 2000.
18. Hart WM jr. *Intraocular Pressure*. Chapter 8 : pg 248-267 in 9th edition of Adler's physiology of the eye, ed by Hart WM, Mosby International 1998
19. Collaborative Normal tension glaucoma study group. *Comparison of glaucomatous progress between untreated patients with Normal tension glaucoma and patients with therapeutically reduced intraocular pressure*. American Journal of Ophthalmology 1998;126; 487-497.
20. Hughes E, Spry P, Diamond J. *24- hour monitoring of intraocular pressure in glaucoma. A retrospective review*. Journal of Glaucoma 2003; 12; 232-236
21. Kitazawa Y, Horie T. *Diurnal variation of intraocular pressure in primary open angle glaucoma*. American Journal of Ophthalmology 1975; 79; 557-566.

22. Wilensky JT, Geiser DK, Dietsche ML, et al . *Individual variability in the diurnal intraocular pressure curve*. Ophthalmology 1993: 100; 940-944.
23. Prince AM, Streeten BW, Ritch R, Dark AJ, et al. *Preclinical diagnosis of pseudoexfoliation syndrome*. Archives of Ophthalmology 1987: 105; 1076-1082.
24. Tarkkhanen A. *Treatment of chronic open angle glaucoma associated with pseudoexfoliation*. Acta Ophthalmology 1965: 43; 514-523
25. Hansen E, Sellevold O. *Pseudoexfoliation of lens capsule: I. Clinical evaluation with special regard to the presence of glaucoma*. Acta Ophthalmology 1968: 45; 1095-1104.
26. Lindblom B, Thorburn W. *Prevalence of visual field defects in capsular and simple glaucoma in Halsingland, Sweden*. Acta Ophthalmology 1982: 60; 353-361.
27. Hiller R, Sperduto RD, Krueger DE. *Pseudoexfoliation, intraocular and senile lens changes in a population based survey*. Archives of Ophthalmology 1982: 100;1080-1082.
28. Aasved H. *The frequency of fibrilopathic epitheliocapsularis (so-called senile exfoliation or pseudoexfoliation) in patients with open angle glaucoma*. Acta Ophthalmology 1971: 49;194-210.
29. Randy A, Jeng SM, Johnson DH, Hodge DO, Good MS. *Estimated incidence of pseudoexfoliation syndrome and pseudoexfoliation glaucoma in Olmsted County, Minnesota..* Journal of Glaucoma 2002: 12;193-197.

30. Hammer T, Schlötzer-Schrehardt U, Naumann GOH. *Unilateral or asymmetric pseudoexfoliation syndrome?* Archives Ophthalmology 2001: 119; 1023-1031.
31. Ritch R. *Exfoliation syndrome.* Current Opinion in Ophthalmology 2001: 12; 124-130.
32. Prince AM, Ritch R. *Clinical signs of pseudoexfoliation syndrome.* Ophthalmology 1986: 93; 803-807.
33. Aasved H. *Incidence of defects in pigmented and pupillary ruff in eyes with and without fibrillogenic epitheliocapsularis.* Acta Ophthalmology 1973: 51; 710-715.
34. Norn MS. *Iris pigment defects in normals.* Acta Ophthalmology 1971: 49; 887-894.
35. Krause U, Helve J, Forsius H. *Pseudoexfoliation of lens capsule and liberation of iris pigments.* Acta Ophthalmology 1973: 51; 39-46
36. Mapstone R. *Pigment release.* British Journal of Ophthalmology 1981: 65; 258-263.
37. Inazumi K, Takahashi D, Taniguchi T, Yamamoto T. *Ultrasound biomicroscopic classification of zonules in exfoliation syndrome.* Japanese Journal of Ophthalmology 2002: 46; 502-509.
38. Schlötzer-Schredardt U. *Corneal endothelial involvement in pseudoexfoliation syndrome.* Archives Ophthalmology 1993: 111: 666-674.

39. Schlötzer.Schredardt U. *A histopathologic study of zonular instability in pseudoexfoliation syndrome*. American Journal of Ophthalmology 1994: 118; 730-743.
40. Tetsumoto K, Schlötzer-schredardt U, Kühle M, Dörfler S. *Precapsular layer of the anterior lens capsule in early pseudoexfoliation syndrome*. Graefe's Arch Clin Exp Ophthalmology 1992: 230; 252-257
41. Asano A, Schlötzer-Schrehardt U, Naumann GOH. *A histopathologic study of iris changes in pseudoexfoliation syndrome*. Ophthalmology 1995: 102; 1279-1290.
42. Schlötzer-Schredardt U, Zenkel M, Kühle M, Sakai LY, et al. *Role of transforming growth factor- β 1 and its latent form binding protein in pseudoexfoliation syndrome*. Exp Eye Res 2001: 73; 765-780.
43. Welge-Lüßen U, Albrecht MC, Neubauer AS, et al. *Role of tissue growth factors in aqueous humor homeostasis*. Current Opinion Ophthalmology 2001:12; 94-99.
44. Tripathi RC, Borisuth NSC, Li J, et al. *Growth factors in aqueous humor and their clinical significance*. Journal of Glaucoma 1994:3; 248-258.
45. Ho SL, Dogar GF, Wang J, Crean J, et al. *Elevated aqueous humor tissue inhibitor of matrix metalloproteinase-1 and connective tissue growth factor in pseudoexfoliation syndrome*. British Journal of Ophthalmology 2005: 89; 169-173.
46. Lutjen-Drecoll E, Gabelt BAR, Tian B, et al. *Outflow of aqueous humor*. Journal of Glaucoma. 2001: 10; 842-844.

47. Tomarev SI. *Eyeing a new route along an old pathway*. Nat Med 2001:7; 294-295.
48. Gartaganis SP, Georgakopoulos CD, Exarchow AM, et al. *Increased aqueous humor basic fibroblast growth factor and hyalurnan levels in relation to the exfoliation syndrome and exfoliation glaucoma*. Acta Ophthalmologica Scandinavica 2001:79; 572-575.
49. Hu DN, Ritch R. *Hepatocytic growth factor is increased in aqueous humor of glaucomatous eye*. Journal of Glaucoma 2001; 10; 152-157.
50. Koliakos GG, Konstas AGP, Schlötzer-Schrehardt U, et al. *8-Isoprostaglandin F2 α and ascorbic acid concentration in aqueous humor of patients with exfoliation syndrome*. British Journal of Ophthalmology 2003:87; 353-356.
51. Deng P, Maddala RL, Khurana RN, et al. *Expression and regulation of connective tissue growth factor in human trabecular meshwork cells and tissues*. ARVO 2002, Abst No:1032.
52. Schlötzer-Schredardt U, Lommatzsch J, Kuchle M, Konstas AGP, et al. *Matrix metalloproteinases and their inhibitors in aqueous humor of patients with pseudoexfoliation syndrome, pseudoexfoliation glaucoma, and primary open angle glaucoma*. Invest Ophthalmic Vis Science 2003; 44; 1117-1125
53. Kubota T, Schlötzer-Schrehardt U, Inomata H, Naumann GOH. *Immunoelectron microscopic localization of HNK-1 carbohydrate epitope*

- in anterior segment of pseudoexfoliation and normal eye. Current Eye Res* 1997; 16; 231-238.
54. Konastas AGP, Jay JL, Marshall GE, Lee WR. *Prevalence, diagnostic features, and response to trabeculectomy in exfoliation glaucoma. Ophthalmology* 1999; 11; 413-423.
55. Netland PA, Ye H, Streeten BW, Hernandez MR. *Elastosis of the lamina cribrosa in pseudoexfoliation syndrome with glaucoma. Ophthalmology* 1995; 102; 878-886.
56. Yüksel N, Karabas L, Arslan A, Demirci A, et al. *Ocular hemodynamics in pseudoexfoliation syndrome and pseudoexfoliation glaucoma. Journal of Glaucoma* 2001; 108; 1043-1049.
57. Gilles WE, Brooks AMV. *Central retinal vein occlusion in pseudoexfoliation of the lens capsule. Clin Exp Ophthalmology* 2002; 30; 176-178.
58. Schlötzer-Schredardt U, Koca M, Naumann GOH, Volkholz H. *Pseudoexfoliation syndrome: ocular manifestation of a systemic disorder? Archives Ophthalmology* 1992; 110; 1752-1756.
59. Gharagozloo NZ, Baker RH, Brubaker RF. *Aqueous dynamics in exfoliation syndrome. American Journal of Ophthalmology* 1992; 114; 473-478.
60. Johnson DH, Brubaker RF. *Dynamics of aqueous humor in syndrome of exfoliation with glaucoma. American Journal of Ophthalmology* 1982; 93; 629

61. Schlötzer-Schredardt U, Naumann GOH. *Trabecular meshwork in pseudoexfoliation syndrome with or without open angle glaucoma*. Invest Ophthalmology Vis Science 1995: 36; 1750-1764.
62. Pohjanpelto P. *Influence of exfoliation syndrome on prognosis in ocular hypertension $\geq 25\text{mm}$. A long term follow up*. Acta Ophthalmol (Copenh) 1980: 64; 39-44.
63. Layden WE, Shaffer RN. *Exfoliation syndrome*. American Journal of Ophthalmology 1980: 89; 477-481.
64. Ritch R. *Exfoliation syndrome and occludable angles*. Trans Am Ophthal Society 1994: 92; 845-944.
65. Gross FJ, Tingey D, Epstein DL. *Increased prevalence of occludable angles and angle closure glaucoma in patients with pseudoexfoliation*. American Journal of Ophthalmology 1994: 117; 333-336.
66. Lanzl IM, Merté RL, Graham AD. *Does head positioning influence anterior chamber depth in pseudoexfoliation syndrome?* Journal of Glaucoma 2000: 9; 214-218.
67. Von der Lippe I, Kuchle M, Naumann GOH. *Pseudoexfoliation syndrome as a risk factor for acute ciliary block angle closure glaucoma*. Acta Ophthalmol Scandinavia 1993: 71; 277-279.
68. Aasved H. *The frequency of optic nerve damage and surgical treatment in chronic simple glaucoma and capsular glaucoma*. Acta Ophthalmology (Copenh) 1971: 49; 194-210.

69. Tarkkanen A, Kivelä T. *Unilateral capsular glaucoma after long-standing bilateral pigmentary glaucoma*. Eye 1999; 13; 212-214.
70. Ritch R. *Exfoliation syndrome-the most common identifiable cause of open angle glaucoma*. Journal of Glaucoma 1996; 3; 176-178.
71. Krupin T, Fietl ME, Bishop KI. *Postoperative intraocular pressure rise in open angle glaucoma patients after cataract or combined cataract – filtration surgery* Ophthalmology 1989; 96; 579-584
72. Merkur A, Damji KF, Mintsioulis G, Hodge WG. *Intraocular pressure decrease after phacoemulsification in patients with pseudoexfoliation syndrome*. Journal of Cataract Refractive surgery 2001; 27; 528-532.

APPENDIX I

PROFORMA FOR RECORDING DVT IN EYES WITH PSEUDOEXFOLIATION

SERIAL NO:

NAME:

HOSP:NO:

AGE:

ADDRESS:

PSEUDOEXFOLIATION: U/L B/L

PRESENTING IOP: RE LE

DISC RE LE

GRADE OF CATARACT RE LE

FIELD RE LE

DVT: RE

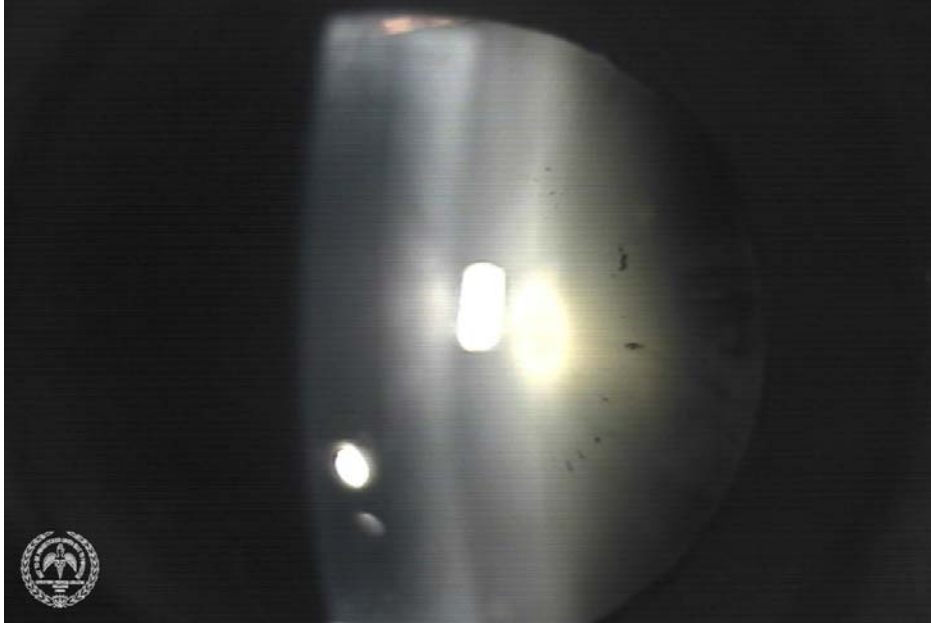DVT1	DVT2	DVT3	DVT4

LE

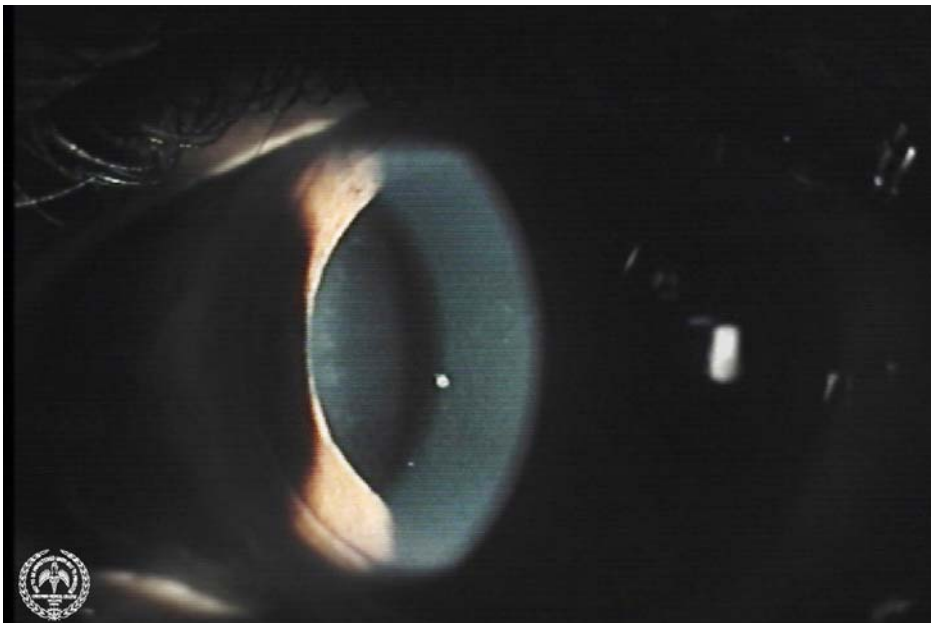
DVT1	DVT2	DVT3	DVT4

APPENDIX III

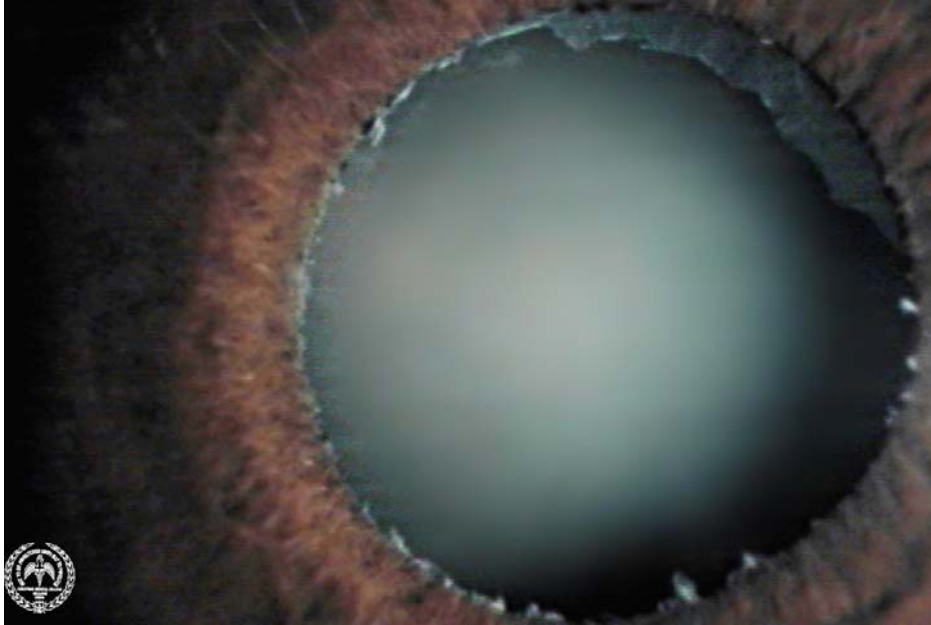EARLY 'BROWN' STAGE PEX ON THE LENS



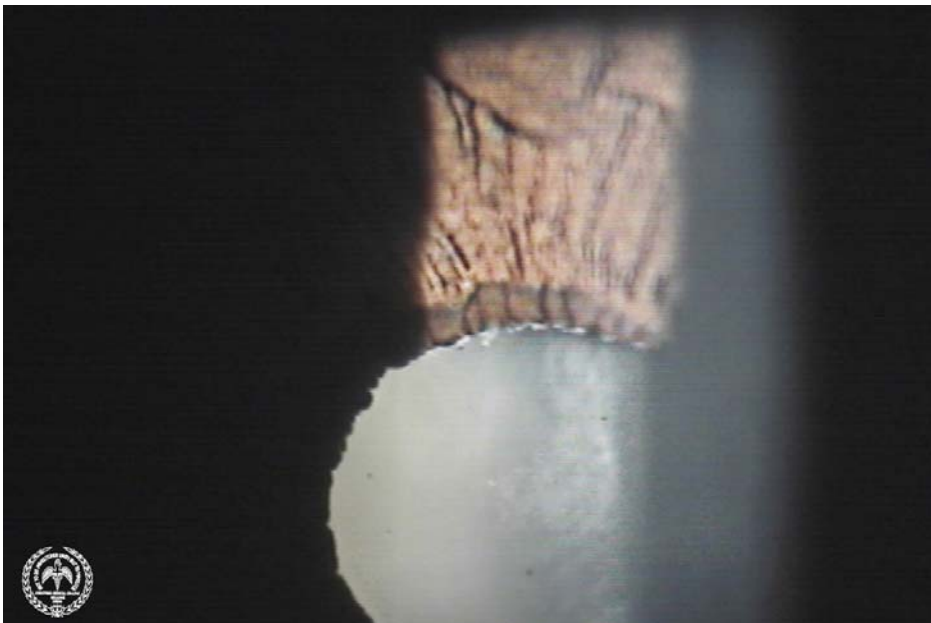
PEX MATERIAL ON THE CORNEAL ENDOTHELIUM



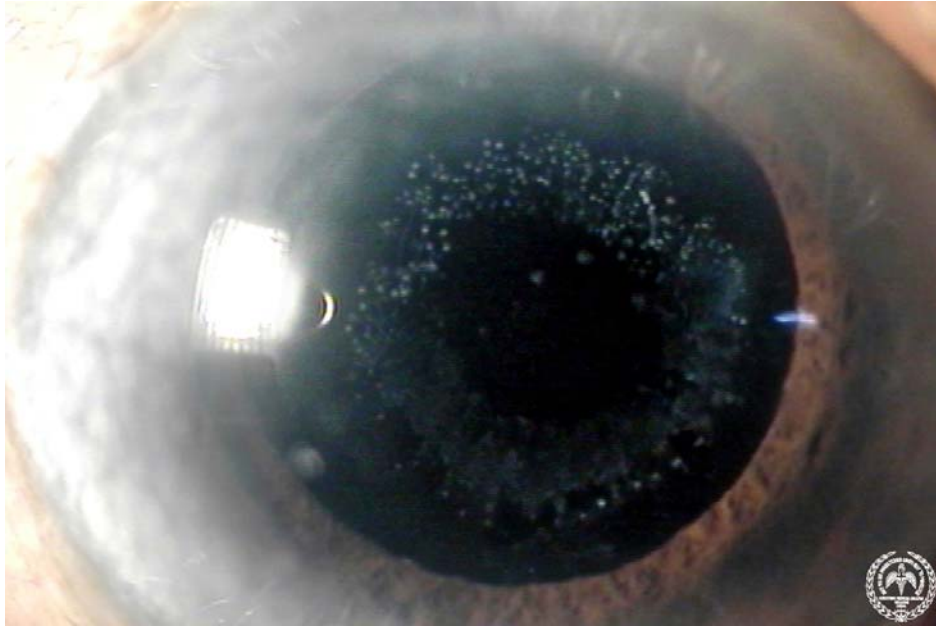
PEX ON THE LENS AND THE PUPIL



PEX ON THE PUPIL



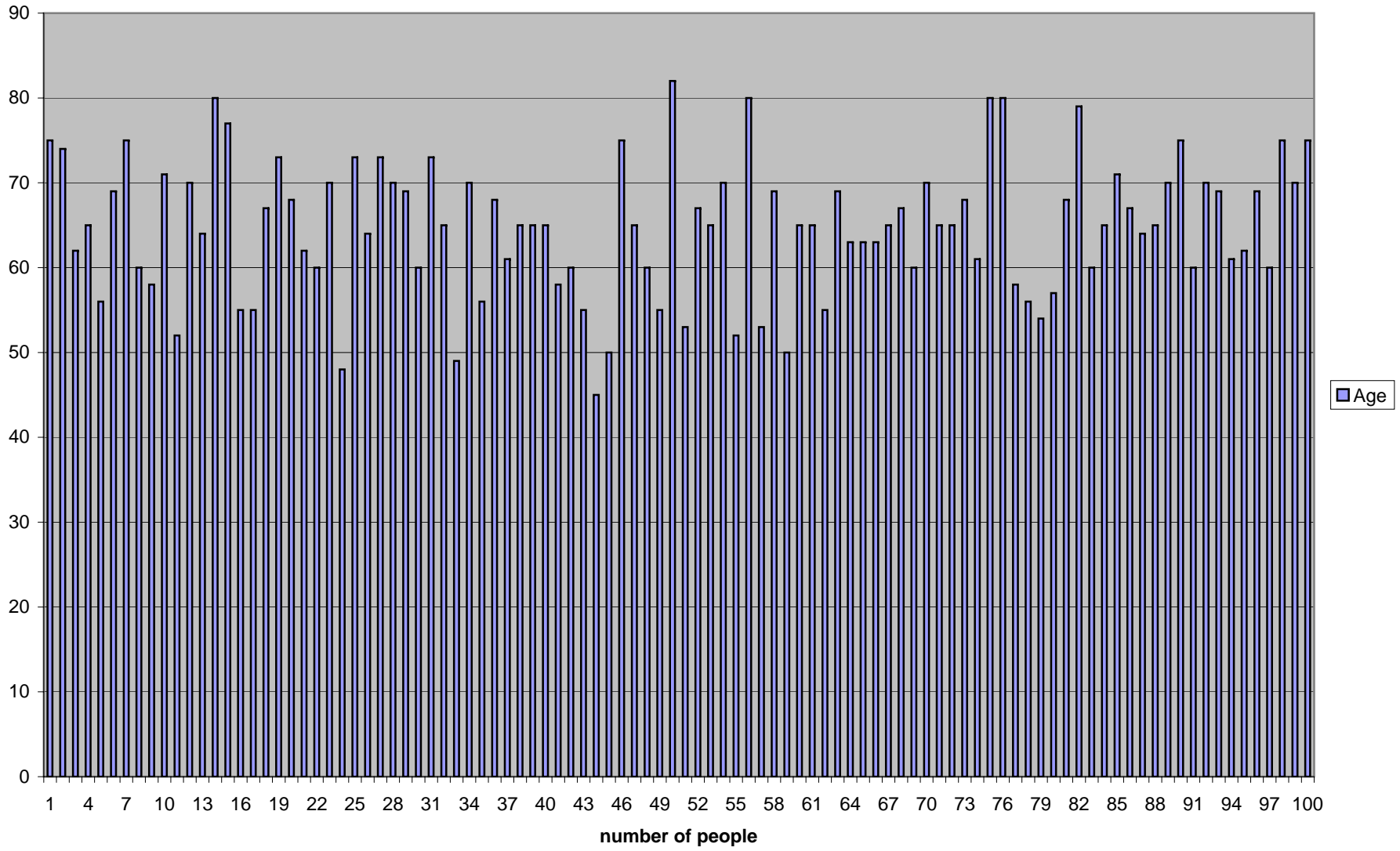
PEX ON THE IOL



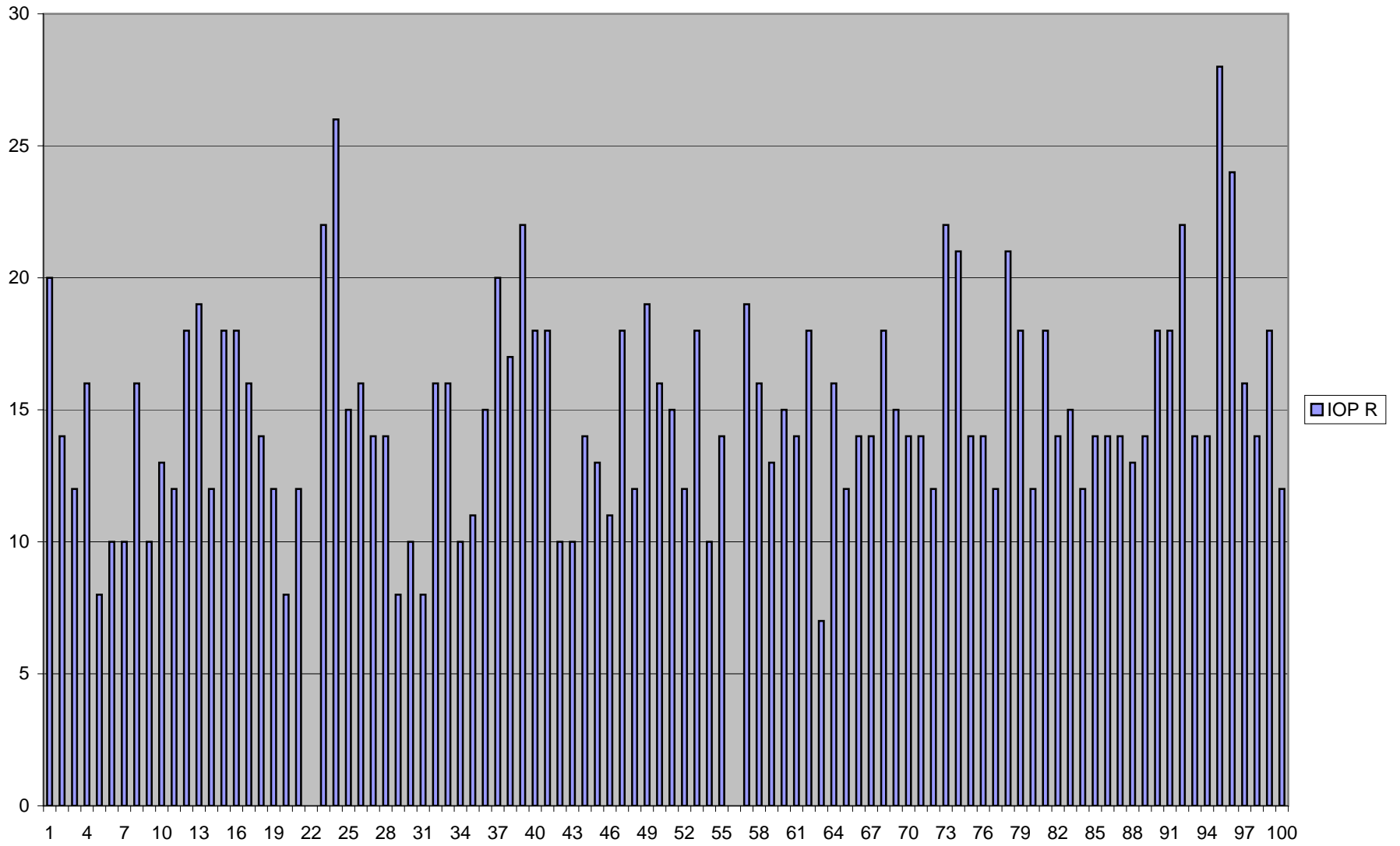
PIGMENTATION IN THE ANGLE



Age



IOP R



	Name	Age	Sex	glaucoma	U/L orB/L	IOP R	IOP L	meanIOP	DISC-R	DISC-L	CAT-R	CAT-L	catsurR
1	DHANU	75	M		B/L	20	20	20	0.3	0.3	NS2	NS2	
2	Thangavel	74	M		B/L	14	14	14	0.3	0.3	NS1+PSC	NS1+PSC	Y
3	Kasturi	62	F		B/L	12	14	13	0.6	Tilted disc	NS2-3	NS2-3	Y
4	Pappama	65	F		U/L	16	16	16	0.3	0.4-0.5	NS3+PSC	NS2+PSC	
5	Chandra	56	F		U/L	8	8	8	0.3	0.3	NS1+PSC	NS1	Y
6	Arjunan	69	M		U/L	10	42	26	0.6	0.7	NS2-3	TRIPLE	
7	Edward	75	M		B/L	10	10	10	0.6	0.6	NS1	NS1	
8	Rajamma	60	F		U/L	16	16	16	0.4	0.6	NS2	NS1	Y
9	Saraswathi	58	F		U/L	10	10	10	0.3	0.3	NS2	NS2	Y
10	Ranganath	71	M		B/L	13	14	13.5	0.3	0.3	NS1	NS1	
11	Yesodai	52	F		B/L	12	12	12	0.3	0.3	NS2+PSC	NS2+PSC	
12	Swaminath	70	M		U/L	18	20	19	0.3	0.3	NS2+PSC	PC IOL	Y
13	Chinnappa	64	M		B/L	19	19	19	0.2	0.2	NS1	NS1	
14	Devaraj	80	M		U/L	12	12	12	0.4	0.4	PC IOL	NS2-3	Y
15	Balakrishna	77	M		U/L	18	18	18	0.4	0.5	PC IOL	NS4	
16	Ruckmani	55	F		U/L	18	18	18	HAZY VIEW	NO VIEW	NS4+PSC	NS4+PSC	Y
17	Arul	55	F		U/L	16	18	17	0.4	0.5	CLEAR	CLEAR	
18	Meenakshi	67	F		B/L	14	16	15	0.3	0.3	NS4+PSC	NS2	Y
19	Mani	73	M		U/L	12	12	12	0.4	Tilted disc	NS2	Aphakia	Y
20	Thanjamm	68	F		B/L	8	8	8	0.3	0.3	NS2	NS1	Y
21	Murugan	62	M		U/L	12	12	12	0.4	0.4	NS2+PSC	PC IOL	Y
22	Alamelu	60	F		U/L				0.2	0.3	NS2	NS1	
23	Solaiamma	70	F	1	U/L	22	22	22	0.7	0.5-0.6	NS2	NS2	
24	Mumataz	48	F	1	B/L	26	24	25	0.3	0.3	NS1+PSC	NS1+PSC	
25	Latheef	73	M		B/L	15	14	14.5	0.5	0.5	NS2+PSC	NS2+PSC	Y
26	Jayabalan	64	M		B/L	16	19	17.5	HAZY VIEW	Hazy view	NS1	NS3	
27	Nagaiah	73	M		B/L	14	14	14	0.6	0.6	NS2-3	NS2-3	Y
28	Kesavan	70	M		U/L	14	14	14	0.3	NO VIEW	PC IOL	NS3-4	
29	Unnamalai	69	F		U/L	8	8	8	0.6	NO VIEW	NS2	NS2+PSC	Y
30	Rajeswari	60	F		U/L	10	10	10	0.2-0.3	NO VIEW	PC IOL	AIMC	Y
31	Ponnusam	73	M		U/L	8	9	8.5	0.3-0.4	NO VIEW	PC IOL	MC	Y
32	Sivapoosh	65	F		B/L	16	14	15	0.6	0.7	NS2+PSC	NS2+PSC	
33	Venugopa	49	M		B/L	16	16	16	0.3	0.3	NS2+PSC	NS1	
34	Srinivasan	70	M		B/L	10	11	10.5	0.3	0.3	NS1	NS1	Y
35	Gracy	56	F		U/L	11	12	11.5	HAZY VIEW	0.4	NS2+PSC	NS1+PSC	Y

DVT=diurnal variation of intraocular pressure, R=right eye, L=left eye,IOP=intraocular pressure, DVT-F=follow up,U/L=unilateral,B/L=bilateral,r=reliable,nd=not done,ur=unreliable

36	Radha	68	F		B/L	15	15	15	No view	0.4	HMC	NS2	Y
37	Babu	61	M		U/L	20	20	20	0.2	0.2	NS1+PSC	NS1+PSC	Y
38	Ram	65	M		U/L	17	16	16.5	0.3	0.4	NS1+PSC	NS1+PSC	
39	Kamalama	65	F		B/L	22	15	18.5	0.5	0.6	NS1	NS2-3	
40	Sowback	65	F		B/L	18	18	18	No view	0.3	AIMC	NS1+PSC	Y
41	Vasantha	58	F		B/L	18	13	15.5	0.3	0.3	NS1+PSC	NS1+PSC	Y
42	Jaya	60	F		B/L	10	10	10	0.4	0.5	NS2	NS2	
43	Kaniappan	55	M		B/L	10	10	10	0.4	0.4	NS2	NS2	
44	Raghu	45	M		B/L	14	14	14	0.1	0.1	CLEAR	CLEAR	
45	Prabhavati	50	F		U/L	13	13	13	0.3	0.3	NS2	NS2	Y
46	Jani Bhai	75	M		U/L	11	10	10.5	0.3	0.3	PC IOL	NS2-3	
47	Palani	65	M		B/L	18	24	21	0.4-0.5	0.5	NS2+PSC	Early NS	Y
48	Rangamma	60	F		B/L	12	12	12	HAZY VIEW	Hazy view	NS2-3	NS2-3	Y
49	Boopalan	55	M		B/L	19	17	18	No view	0.4-0.5	AIMC	NS2+PSC	Y
50	Rose	82	F		U/L	16	16	16	No view	0.4	AIMC	Aphakia	Y
51	Nallatham	53	M		U/L	15	15	15	0.7	0.7	NS1+PSC	NS1+PSC	
52	Jayalaxmi	67	F		B/L	12	14	13	0.3	0.3	NS1+PSC	NS1+PSC	
53	Srinivasulu	65	M		U/L	18	16	17	0.6	0.6	NS2	PC IOL	Y
54	Janakiama	70	F		B/L	10	10	10	HAZY VIEW	Hazy view	NS2-3	NS2-3	Y
55	Rajmurthi	52	M		B/L	14	17	15.5	0.5	0.6	NS1+PSC	NS1+PSC	
56	Duraisamy	80	M		U/L				No view	Hazy view	AIMC	Aphakia	Y
57	Saraswathi	53	F		U/L	19	19	19	0.4	0.4	Early NS	Early NS	
58	Dharmalingam	69	M		B/L	16	21	19	0.4	0.6	PC IOL	NS2	
59	Gouramma	50	F		U/L	13	16	19	0.5	0.6	NS2	NS2	Y
60	Poongavar	65	F		U/L	15	16	19	0.3	0.3	NS2+PSC	NS2+PSC	Y
61	Saminath	65	M		B/L	14	14	19	0.5	0.5	NS2+PSC	NS2+PSC	Y
62	Girija	55	F		B/L	18	15	19	No view	0.5	AIMC	NS1	Y
63	Gangulapa	69	M		B/L	7	8	19	HAZY VIEW	Hazy view	MC	NS2+PSC	Y
64	Sulochana	63	F		B/L	16	14	19	HAZY VIEW	0.5	NS2+PSC	NS1	Y
65	Vardhan	63	M		B/L	12	12	19	HAZY VIEW	Hazy view	NS3+PSC	NS3-4	
66	Mani	63	M		U/L	14	14	19	0.3	0.3	NS2+PSC	NS2+PSC	
67	Govindama	65	F		U/L	14	14	19	0.7	0.8	NS3	NS3	
68	Saroja	67	F		B/L	18	16	19	0.4	0.4	NS2	NS1	Y
69	Duraisamy	60	M		B/L	15	15	19	0.3	0.3	Early NS	Early NS	
70	Abdul	70	M		B/L	14	14	19	0.3	0.3	NS2+PSC	NS2+PSC	Y
71	Subramani	65	M		U/L	14	14	19	0.2	0.3	NS2-3	NS2-3	Y

DVT=diurnal variation of intraocular pressure, R=right eye, L=left eye, IOP=intraocular pressure, DVT-F=follow up, U/L=unilateral, B/L=bilateral, r=reliable, nd=not done, ur=unreliable

72	Muthu	65	M	1	U/L	12	24	19	0.5	0.5	PC IOL	NS1-2	
73	Dorairaj	68	M		B/L	22	22	22	0.7	0.7	NS2	NS2	
74	Rajeswari	61	F		B/L	21	21	19	0.3	0.3	CLEAR	CLEAR	
75	Lakshmi	80	F		U/L	14	14	19	No view	0.3	NS4+PSC	PC IOL	Y
76	Krishnasar	80	M		B/L	14	14	19	HAZY VIEW	0.4	NS4+PSC	NS4+PSC	Y
77	Neelamaga	58	M		U/L	12	12	19	0.4	0.4	CLEAR	CLEAR	
78	Margatham	56	F		B/L	21	21	19	0.3	0.3	NS1	NS2+PSC	
79	Santa	54	F		B/L	18	18	19	0.3	0.3	Early NS	Early NS	
80	Balaraman	57	M		U/L	12	10	19	0.2	0.2	NS3+PSC	PC IOL	Y
81	Joseph	68	M		U/L	18	20	19	0.4	0.4	PC IOL	NS3-4	
82	Muthamma	79	F		U/L	14	16	19	HAZY VIEW	0.4	NS2+PSC	NS2	Y
83	Mary	60	F		U/L	15	16	19	0.4	0.3	NS2-3	NS2-3	
84	Sakkubai	65	F		U/L	12	12	19	0.3	0.3	NS2-3	PC IOL	Y
85	Kuppan	71	M		U/L	14	14	19	0.3	NO VIEW	NS2-3+PS	MC	
86	Sivalingam	67	M		B/L	14	12	19	0.4	0.4	NS1-2+PS	NS1-2+PS	Y
87	Damodara	64	M		B/L	14	14	19	0.3	Hazy view	NS1	NS1+PSC	
88	Thanjai	65	F		B/L	13	11	19	0.3	0.3	NS2-3	NS2-3	Y
89	Yesodamm	70	F		B/L	14	16	19	No view	0.2	MC	NS2-3	Y
90	Sahu	75	M		U/L	18	19	19	0.5	0.5	PC IOL	MC	
91	Andalama	60	F		U/L	18	18	19	0.3	0.3	NS1	NS1	
92	Jeeva	70	M		B/L	22	21	19	0.3	0.3	NS1-2	NS1-2	Y
93	Guruviah	69	M		B/L	14	14	19	0.5	0.5	NS2-3	NS1	
94	Ramadoss	61	M		B/L	14	14	19	0.4	0.4	NS3-4	NS3-4	
95	Nesamani	62	M	1	B/L	28	32	19	HAZY VIEW	0.9	NS4+PSC	NS2-3	
96	Munisamy	69	M	1	U/L	24	30	19	HAZY VIEW	Hazy view	NS2	NS3	
97	Subramani	60	M		U/L	16	16	19	0.6	0.6	PC IOL	NS1-2+PSC	
98	Sampathar	75	F		U/L	14	12	19	0.2	NO VIEW	PC IOL	AIMC	
99	Bhavani	70	F		U/L	18	18	19	0.4	NO VIEW	PC IOL	AIMC	
100	Govindamr	75	F		B/L	12	12	19	0.3	0.4	NS2+PSC	NS2-3+PSC	

DVT=diurnal variation of intraocular pressure, R=right eye, L=left eye, IOP=intraocular pressure, DVT-F=follow up, U/L=unilateral, B/L=bilateral, r=reliable, nd=not done, ur=unreliable

catsurL	DVT-R1	DVT-R2	DVT-R3	DVT-R4	meandvtR	DVT-L1	DVT-L2	DVT-L3	DVT-L4	meandvtL	FIELD-R	FIELD-L	DVT-FR1
	18	20	18	16	18	18	20	20	20	19.5	ur	ur	
Y	14	12	12	14	13	12	12	12	12	12	ur	ur	10
	18	21	23	22	21	18	20	21	21	20	ur	ur	20
	16	14	16	16	15.5	14	14	14	16	14.5	ur	ur	
	8	10	8	8	8.5	10	10	10	10	10	ur	ur	14
	10	10	10	12	10.5	32	30	30	34	31.5	ur	ur	
Y	11	10	10	10	10.25	11	10	10	10	10.25	r	r	10
	16	14	16	16	15.5	16	14	14	14	14.5	ur	ur	14
	8	10	10	10	9.5	12	12	10	12	11.5	ur	ur	10
	14	15	14	14	14.25	14	15	14	14	14.25	ur	ur	
Y	12	12	12	12	12	12	10	10	12	11	r	r	9
	16	17	15	17	16.25	14	15	15	18	15.5	r	r	24
	16	14	16	12	14.5	18	14	12	12	14	ur	ur	
Y	10	12	10	12	11	10	14	14	16	13.5	ur	ur	18
Y	14	12	14	14	13.5	20	22	26	26	23.5	ur	ur	16
	21	21	18	20	20	21	21	18	20	20	ur	ur	
	16	18	18	18	17.5	16	16	16	16	16	ur	ur	
	16	16	15	16	15.75	14	14	14	16	14.5	ur	ur	
	12	12	12	12	12	14	12	14	12	13	ur	ur	
	12	12	12	14	12.5	12	12	12	12	12	ur	ur	8
	13	12	12	12	12.25	13	14	16	16	14.75	r	r	13
	15	18	16	18	16.75	14	18	18	18	17	ur	ur	
Y	26	24	26	26	25.5	28	26	28	28	27.5	ur	ur	20
	22	24	24	22	23	24	24	24	24	24	ur	ur	
	14	12	15	14	13.75	15	16	14	14	14.75			14
	14	16	16	16	15.5	16	16	14	16	15.5	ur	ur	
	14	12	14	14	13.5	16	16	16	17	16.25			20
Y	14	14	12	14	13.5	16	14	14	14	14.5	r	ur	11
	8	10	8	10	9	8	6	10	8	8	ur	ur	12
	14	14	12	14	13.5	12	14	14	14	13.5	ur	ur	10
	10	12	9	10	10.25	8	10	10	10	9.5	r	ur	22
Y	18	18	18	18	18	20	18	18	18	18.5	r	r	
	18	14	16	16	16	18	16	16	16	16.5	r	r	
	14	16	14	16	15	14	14	14	16	14.5	ur	ur	10
	10	11	11	10	10.5	10	12	10	10	10.5	ur	ur	14

DVT=diurnal variation of intraocular pressure, R=right eye, L=left eye,IOP=intraocular pressure, DVT-F=follow up,U/L=unilateral,B/L=bilateral,r=reliable,nd=not done,ur=unreliable

	16	14	14	16	15	16	14	16	14	15	ur	ur	
	12	16	16	16	15	12	16	16	16	15	r	r	
Y	14	18	16	16	16	14	14	14	16	14.5	ur	ur	14
	11	12	10	12	11.25	14	14	16	14	14.5	ur	ur	14
	18	18	20	20	19	18	20	20	20	19.5	ur	ur	
Y	10	10	10	10	10	10	10	10	10	10	ur	ur	
	14	16	14	14	14.5	14	16	14	14	14.5	r	r	
	14	15	14	15	14.5	14	15	15	15	14.75	ur	ur	
Y	16	18	16	16	16.5	18	20	20	20	19.5			22
	16	14	16	18	16	18	14	16	18	16.5	r	r	
	14	14	12	12	13	12	14	12	12	12.5	ur	ur	
	18	18	18	18	18	18	18	18	18	18	nd	ur	
	12	16	16	14	14.5	16	16	16	16	16	ur	ur	
	12	14	14	14	13.5	14	14	14	14	14	r	r	
	12	12	12	12	12	14	12	12	14	13	ur	r	
	16	16	16	16	16	16	16	16	16	16	nd	ur	
	10	10	10	10	10	10	10	10	10	10	ur	ur	
	12	10	10	10	10.5	12	10	10	10	10.5	ur	ur	
	12	10	12	12	11.5	10	10	12	12	11	nd	nd	
	14	16	16	16	15.5	12	16	16	16	15	ur	ur	
Y	16	20	18	18	18	18	20	20	20	19.5	ur	ur	
	15	16	16	16	15.75	14	16	16	16	15.5	ur	ur	14
	14	14	16	14	14.5	14	15	16	14	14.75	ur	ur	
	21	17	21	21	20	21	17	21	21	20	ur	ur	14
	18	16	17	17	17	18	17	17	17	17.25	ur	ur	
	10	8	10	10	9.5	10	10	10	10	10	ur	ur	15
	15	10	15	15	13.75	15	10	14	15	13.5	r	r	
Y	14	14	16	14	14.5	12	14	16	16	14.5	ur	ur	
Y	13	13	13	13	13	13	13	12	13	12.75	r	r	
Y	13	14	14	14	13.75	13	14	13	13	13.25	ur	ur	
	18	18	18	18	18	18	16	18	18	17.5	r	r	16
	19	18	13	15	16.25	20	19	13	13	16.25	r	r	
	14	14	14	14	14	14	14	14	14	14	ur	ur	
	18	21	20	20	19.75	16	21	20	21	19.5	ur	ur	

DVT=diurnal variation of intraocular pressure, R=right eye, L=left eye,IOP=intraocular pressure, DVT-F=follow up,U/L=unilateral,B/L=bilateral,r=reliable,nd=not done,ur=unreliable

Y	10	12	12	10	11	18	26	25	25	23.5	r	r	
Y	18	17	21	18	18.5	17	21	21	18	19.25	ur	ur	
	18	20	18	18	18.5	20	18	18	18	18.5	r	r	
	14	12	12	12	12.5	14	11	12	12	12.25	ur	r	
	10	12	12	12	11.5	12	12	12	12	12	ur	ur	
	10	10	10	10	10	10	10	10	10	10	ur	ur	
Y	14	16	16	14	15	14	16	16	16	15.5	ur	ur	
	10	12	10	10	10.5	12	12	12	12	12	r	r	
	10	10	10	10	10	10	10	10	10	10	ur	r/ng	
Y	18	18	20	20	19	20	20	20	20	20	ur	ur	
	14	14	12	14	13.5	14	13	14	14	13.75	nd	nd	
Y	12	12	10	10	11	12	12	12	12	12	nd	nd	
	12	14	14	14	13.5	12	16	14	14	14	ur	ur	
Y	22	21	21	21	21.25	22	21	21	18	20.5	ur	nd	
	15	13	11	11	12.5	15	12	11	13	12.75	ur	ur	
Y	14	14	14	14	14	14	12	12	14	13	r	r	
	14	13	14	14	13.75	14	16	14	14	14.5	ur	ur	
	12	14	14	14	13.5	14	14	14	14	14	ur	ur	
Y	16	18	20	18	18	18	17	18	19	18	ur	nd	16
	18	18	18	18	18	18	20	18	18	18.5	r	r	
	21	21	16	18	19	21	18	16	18	18.25	ur	r	
	14	14	14	12	13.5	14	14	14	14	14	ur	ur	
Y	16	14	16	18	16	18	14	16	18	16.5	ur	ur	
Y	26	28	28	28	27.5	30	32	32	36	32.5	ur	ur	26
Y	18	21	21	21	20.25	30	36	34	34	33.5	ur	ur	
Y	16	17	16	16	16.25	20	20	18	18	19	ur	ur	17
Y	14	14	12	14	13.5	14	14	14	14	14	ur	nd	
Y	16	14	14	14	14.5	16	14	16	14	15	r	nd	
Y	12	14	12	12	12.5	14	14	12	12	13	ur	ur	

DVT=diurnal variation of intraocular pressure, R=right eye, L=left eye,IOP=intraocular pressure, DVT-F=follow up,U/L=unilateral,B/L=bilateral,r=reliable,nd=not done,ur=unreliable

DVT-FR2	DVT-FR3	DVT-FR4	meanFdvt	DVT-FL1	DVT-FL2	DVT-FL3	DVT-FL4	meanFdvtL
12	12	12	11.5	12	10	12	12	11.5
18	18	18	18.5	20	19	18	18	18.75
			#DIV/0!					#DIV/0!
10	10	10	11	12	10	10	10	10.5
			#DIV/0!					#DIV/0!
10	10	10	10	12	12	10	10	11
14	16	16	15	12	16	16	16	15
10	10	12	10.5	10	10	10	10	10
			#DIV/0!					#DIV/0!
10	10	10	9.75	10	10	10	10	10
21	24	26	23.75	24	21	24	24	23.25
			#DIV/0!					#DIV/0!
20	20	20	19.5	18	20	18	20	19
16	16	16	16	16	16	16	16	16
			#DIV/0!					#DIV/0!
			#DIV/0!					#DIV/0!
			#DIV/0!					#DIV/0!
			#DIV/0!					#DIV/0!
10	10	10	9.5	10	10	10	10	10
13	12	13	12.75	12	12	13	12	12.25
			#DIV/0!					#DIV/0!
20	22	20	20.5	22	24	22	24	23
			#DIV/0!					#DIV/0!
14	14	14	14	14	14	12	14	13.5
			#DIV/0!					#DIV/0!
18	16	20	18.5	20	20	18	20	19.5
11	10	11	10.75	8	10	10	10	9.5
12	14	14	13	20	16	18	18	18
12	10	10	10.5	8	12	12	12	11
16	16	16	17.5	20	16	16	16	17
			#DIV/0!					#DIV/0!
			#DIV/0!					#DIV/0!
10	10	10	10	10	10	10	10	10
14	12	12	13	14	12	12	12	12.5

DVT=diurnal variation of intraocular pressure, R=right eye, L=left eye,IOP=intraocular pressure, DVT-F=follow up,U/L=unilateral,B/L=bilateral,r=reliable,nd=not done,ur=unreliable

			#DIV/0!					#DIV/0!
			#DIV/0!					#DIV/0!
			#DIV/0!					#DIV/0!
15	15	14	14.5	14	14	14	13	13.75
14	14	14	14	16	14	14	14	14.5
			#DIV/0!					#DIV/0!
			#DIV/0!					#DIV/0!
			#DIV/0!					#DIV/0!
			#DIV/0!					#DIV/0!
			#DIV/0!					#DIV/0!
24	22	22	22.5	22	22	22	22	22
			#DIV/0!					#DIV/0!
			#DIV/0!					#DIV/0!
			#DIV/0!					#DIV/0!
			#DIV/0!					#DIV/0!
			#DIV/0!					#DIV/0!
			#DIV/0!					#DIV/0!
			#DIV/0!					#DIV/0!
			#DIV/0!					#DIV/0!
			#DIV/0!					#DIV/0!
			#DIV/0!					#DIV/0!
			#DIV/0!					#DIV/0!
17	17	16	16	14	14	17	14	14.75
			#DIV/0!					#DIV/0!
16	16	16	15.5	14	14	16	14	14.5
			#DIV/0!					#DIV/0!
16	16	16	15.75	16	16	16	16	16
			#DIV/0!					#DIV/0!
			#DIV/0!					#DIV/0!
			#DIV/0!					#DIV/0!
			#DIV/0!					#DIV/0!
16	13	13	14.5	16	13	12	13	13.5
			#DIV/0!					#DIV/0!
			#DIV/0!					#DIV/0!
			#DIV/0!					#DIV/0!

DVT=diurnal variation of intraocular pressure, R=right eye, L=left eye,IOP=intraocular pressure, DVT-F=follow up,U/L=unilateral,B/L=bilateral,r=reliable,nd=not done,ur=unreliable

