

# **CLINICAL STUDY OF GLAUCOMA IN PSEUDOEXFOLIATION SYNDROME**

**DISSERTATION SUBMITTED FOR  
MASTER OF SURGERY DEGREE  
BRANCH III – OPHTHALMOLOGY  
MARCH 2009**



**THE TAMILNADU  
Dr.M.G.R. MEDICAL UNIVERSITY  
CHENNAI , TAMILNADU**

**Dept. of Ophthalmology**

**Govt. Rajaji Hospital**

**Madurai**

## **CERTIFICATE**

This is to certify that this dissertation entitled, “**CLINICAL STUDY OF GLAUCOMA IN PSEUDOEXFOLIATION SYNDROME**”, has been done by **Dr.S.UMA MAHESWARI** under my guidance in Department of **OPHTHALMOLOGY**, Madurai Medical College, Madurai.

I certify regarding the authenticity of the work done to prepare this dissertation.

**Dr.P.THIYAGARAJAN M.S.,D.O.,**

**PROFESSOR AND H.O.D.  
DEPARTMENT OF  
OPHTHALMOLOGY  
GOVT. RAJAJI HOSPITAL &  
MADURAI MEDICAL COLLEGE  
MADURAI**

## **DECLARATION**

I, **Dr.S.UMA MAHESWARI** solely declare that the dissertation titled, **“CLINICAL STUDY OF GLAUCOMA IN PSEUDOEXFOLIATION SYNDROME”**, has been prepared by me.

This is submitted to The Tamil Nadu Dr.M.G.R. Medical University, Chennai, in partial fulfillment of the requirement for the award of M.S.,( Ophthalmology ) Branch III degree examination to be held in March 2009.

**Place : Madurai**

**Date :**

**Dr.S.UMA MAHESWARI**

## ACKNOWLEDGEMENT

It is my bounden duty to offer my deep sense of gratitude to **Dr.P.Thiyagararajan M.S.,D.O., Professor and Head of the Department of Ophthalmology, Government Rajaji Hospital and Madurai Medical College, Madurai** for his paternal encouragement, valuable suggestions and proper guidance.

I do express my profound gratitude to **Dr.G.S.Srinivasan M.S.,D.O., Assistant Professor, Department of Ophthalmology,** for his instinct advice, high motivation and constant support.

I am deeply thankful to **Dr.A.R.Anbarasi M.S.,D.O.,** and **Dr.S.V.Chandrakumar M.S.,D.O.** for their spontaneous help and co-operation at all times.

I extend my heartfelt thanks to all my Assistant Professors and my dear Colleagues who extended their support at every step of my study.

I am grateful to **Dr.Siva Kumar M.S., Dean, Madurai Medical College,** for enabling me to utilize the clinical material available in the hospital.

Finally I am deeply indebted to the cogwheels of my study-the patients, without whom this study would not have been completed.

# CONTENTS

	<b>PART 1</b>	<b>PAGE NO.</b>
1)	INTRODUCTION	1
2)	HISTORICAL BACKGROUND	2
3)	REVIEW OF LITERATURE	4
4)	MANAGEMENT	27
	<b>PART II</b>	
5)	AIM OF THE STUDY	31
6)	MATERIALS AND METHODS	32
7)	ANALYSIS AND DISCUSSION	34
8)	RESULT	49
	SUMMARY	51
	CONCLUSION	55
	BIBLIOGRAPHY	
	PROFORMA	
	MASTER CHART	
	KEY TO MASTER CHART	

## **INTRODUCTION**

Pseudoexfoliation syndrome is a systemic disorder that is currently the most common identifiable specific entity leading to the development of glaucoma (ritch).

It commonly affects the elderly with higher intraocular pressure as pseudoexfoliation glaucoma is more severe than Primary open angle glaucoma, intra ocular pressure. Reduction helps to prevent glaucoma progression.

## **HISTORICAL BACKGROUND**

LINDBERG (1917) first described cases of glaucoma in which flakes of whitish material was adherent to the pupillary border of the iris in 50% of his patients with glaucoma. VOGT ( 1925) attributed the material to delamination of the superficial layers of the anterior lens capsule and the term glaucoma capsulare to denote the association of glaucoma with this condition WEEKERS et al (1951) coined the term senile uveal pseudoexfoliation. WILSON (1953) term it as glaucoma senilis to indicate that pseudoexfoliation was a disease of the aged.

DRORAK-THEOBALD (1954) felt that this disorder is not a true exfoliation of the lens capsule but rather represents precipitates of an unknown substance which is deposited in the anterior lens capsule and other structures in the anterior ocular segment. She suggested the term pseudoexfoliation of the lens capsule.

LAYDEN and SHAFFER( 1974) termed it as termed it as exfoliation syndrome. Other terms suggested by various authors are the following: EAGLE et al 1979- Basement membrane exfoliation syndrome

GARDNER and ALEXANDER 1984- Oxytalanosis of the aqueous  
STREETEN 1987 – Ocular elastosis

**Other names given to this syndrome are:**

1. iridociliary exfoliation with capsular pseudoexfoliation.
2. Exfoliation of the pseudo capsule.
3. Fibrillogenesis epitheliocapsularis



## **REVIEW OF LITERATURE**

### **PREVALENCE**

Pseudoexfoliation syndrome has been described to occur worldwide. Reported prevalence rates of pseudoexfoliation vary widely in different geographic locations. Age of population, racial and ethnic composition, patients selection, clinical criteria for diagnosis, thoroughness of examination and prospective versus retrospective data collection can all affect the results.

Prevalence of pseudoexfoliation ranges from 0% among Eskimos to as high as 38% in Navajo Indians. Prevalence rate in Norway is 6.3%, England 4.7%, Germany 4%, Japan 0.2%, India 2% (HILLER et al ). Prevalence of pseudoexfoliation in south India >40 years 6% Krishna das et al 2003.

Prevalence of glaucoma in pseudoexfoliation was reported by GRADLE and SUGAR as 81.8%.

Amongst Indian studies LAMBA and GIRIDHAR reported a prevalence of 30% and MARIUM and AURORA reported a prevalence 22.6% and SOOD and RATNARAJ reported a prevalence of 34% of

glaucoma in pseudoexfoliation patients. Prevalence of glaucoma in pseudoexfoliation in south India in >39 years 7.5% KRISNA DAS et al 2003.

## **EPEDEMIOLOGY**

### **AGE:**

Pseudoexfoliation syndrome common in late 50 years but becomes increasingly common in late 60s and 70s. Framingham study reported a prevalence of 0.6% for people who are 52-64 years of age, rising to 5% by 75-80 years of age. AASVED similarly found 0.4% for ages 50-59 and 7-9% rates for ages 80-89. IN SOUTH INDIA >40 years was 3.8% (ARAVIND et al 2003).

### **SEX:**

Pseudoexfoliation is more common in females than male and glaucoma has a greater predilection for men.

### **HEREDITARY:**

One study found a nine fold increase in prevalence in first degree relatives above 40 years of age suggesting autosomal dominant, autosomal recessive, mitochondrial inheritance pattern.

### **NON GENETIC FACTORS:**

Ultra violet light,autoimmunity,slow virus infection and trauma may also be involved.

### **LATERALITY:**

Conjunctival biopsy in fellow eyes of patients with unilateral pseudoexfoliation syndrome is invariably positive for pseudoexfoliation( PRINCE) the terms unilateral and bilateral are used to indicate clinically detectable involvement.

### **SYSTEMIC ASSOCIATION**

Pseudoexfoliation material has been demonstrated in lung, heart, liver, gallbladder, skin, kidney, and cerebral meninges suggesting a systemic process involving generalized abnormal connective tissue metabolism

### **CLINICAL FEATURES**

#### **CONJUNCTIVA**

Clinically conjunctiva is normal in pseudoexfoliation syndrome. Fluorescein angiography reveals loss of regular limbal vascular pattern and areas of neovascularisation in advanced cases.

## **CORNEA**

Scattered flakes of pseudoexfoliation material may be observed on endothelium. specular microscopy demonstrates a significant reduction in the endothelial cell density and pleomorphism. Patients with pseudoexfoliation have shown increased corneal decompensation due to endotheliopathy.

Central corneal thickness is also greater in eyes with with pseudoexfoliation.

BARTHOLOMEN reported a significant association of pseudoexfoliatoin with spheroidal degeneration of cornea in men but not in female.

## **ANTERIOR CHAMBER**

Pseudoexfoliation material can be seen floating in aqueous in the undilated eye. Following mydriasis, pigment dispersion is often seen.

## **ANTERIOR CHAMBER ANGLE**

Anterior chamber angle was reported to open in 83% of patients with pseudoexfoliation glaucoma. On regular examination, these is no

significant difference between normal patients and patients with pseudoexfoliation.

But a decrease in Ac depth between the supine and prone position was found to be greater in eyes with pseudoexfoliation. decrease in Ac depth has been implicated to be due to zonular weakness.

Increased trabecular pigmentation is a prominent sign of pseudoexfoliation which is of more variegated appearance and is apparent in all patients with clinically evident disease

Pigment characteristically deposited on the schwalbes line and some times as a wavy line (or) lines anterior to schwalbes line(sampaolesi line).

Although anterior chamber depth is normal in most patients, in some studies shows 9% to 18% have occludable angle and 14% have angle closure on basis of peripheral anterior synechiae.

## **IRIS AND PUPIL**

Next to the lens the pseudoexfoliation material is most prominent at the pupillary border in 32 -94% of patients.it tends to more prominent in eyes maintained on miotic therapy.

Pigment loss from the iris sphincter region is a hall mark of pseudoexfoliation which is reflected in iris sphincter region as moth eaten pattern transillumination, defect near the pupillary border.

Pigment particles, larger than those found in pigment dispersion syndrome are deposited in a whorl like fashion on the anterior stroma at the sphincter.pigment is deposited evenly over the iris surface,in contrast to its collection in iris furrows in pigment dispersion syndrome.

Fluorescein angiography of iris shows hypoperfusion, peripupillary leakage ,and neovascularization . iris hypoxia associated with atrophy of pigmented epithelium and muscle cells may account for **poor** mydriasis.

Studies of histopathological examination of iris sphincter and dilator muscle by light and electron microscopy have found fibrotic disorganized degenerative muscle tissue.

## **ZONULES and CILIARY BODY**

Pseudoexfoliation material may be detected earliest on the ciliary process and zonules. Zonular pseudoexfoliation may cause the peripheral granular zone and may appear as subtle striations of pseudoexfoliation material (or) pigment on the surface of the lens.

Horven was the first person to report the pseudoexfoliation on the zonules through a surgical coloboma. Material loosely adherent to the zonules is believed to cause degeneration of the zonules near their attachments to ciliary body. In these areas, pseudoexfoliation aggregates erupt through basement membrane and invade zonular lamellae and create weakness. Proteolytic enzymes within the pseudoexfoliation material may facilitate zonular disintegration.

## **LENS**

Pseudoexfoliation material in the form of granular whitish deposition over the anterior lens surface is the most commonly recognized feature of pseudoexfoliation syndrome. Originally described by VOGT three zonules are characteristic

### **ZONE 1( CENTRAL ZONE)**

It is a homogenous whitish sheet lying on the anterior lens capsule. The size varies from 1.25 to 2.5 mm in diameter and edge is sharp with serrations. Its size and shape depends on the pupil and the serrations due to pupillary Movements. The disc is absent in 20% of cases.

### **ZONE 2(CLEAR ZONE )**

It lies in between zone 1 and zone 3 as an annular area semi opaque capsular sheets which are arranged radially and created by rubbing of the iris over the lens capsule during physiological movement of the pupil. The inner pupillary diameter and outer diameter corresponds to largest pupillary diameter.

### **ZONE 3(PERIPHERAL ZONE )**

Good mydriasis is essential to identify this granular band. It is granular in the periphery and frosty white centrally. Radial striations are often seen. Its boundary ends on equator of the lens.

To visualize the earlier stages at the S/L, place the slit beam at 45 degree to the axis of the observation and reduce the light source and focusing temporally about 2-3 mm from the centre of the lens may help to highlight the subtle deposits on the lens surface.



Subluxation or dislocation of the crystalline lens may occur due to weakening of zonular attachment to ciliary body. phacodonesis is commonly seen, yet not associated with iridodonesis, perhaps attributable to increased iris rigidity

## **VITREOUS**

Pseudoexfoliation material is seen over the anterior hyaloid in aphakic eyes. It is easily removed; hence it is considered to be a secondary deposit

## **GLAUCOMA AND PSEUDOEXFOLIATION**

About 50% of patients with pseudoexfoliation syndrome are ultimately diagnosed to have glaucoma. Figures vary from 20-85%.

5% of patients with pseudoexfoliation syndrome and no glaucoma at the initial examination develop elevated I.O.P after 5 years and 15% develop elevated I.O.P. after 10 years.

Mean I.O.P. in normotensive eyes with pseudoexfoliation is usually higher than in those without pseudoexfoliation. In patients with increased intraocular pressure, mean I.O.P. is higher at the time of detection than in primary open angle glaucoma. Glaucomatous optic nerve head changes

and visual field damage also tend to be greater in patients with pseudoexfoliation glaucoma than in patients with primary open angle and glaucoma, suggesting an intrinsic vulnerability of the optic nerve head in pseudoexfoliation syndrome.

## **MECHANISM OF GLAUCOMA**

Glaucoma in pseudoexfoliation is associated with an open angle and normal anterior chamber depth. The most likely mechanism is blockage of the filtering meshwork by a combination of pseudoexfoliation material and pigment and accumulation of pseudoexfoliation material in juxtacanalicular region and destruction of schlemm's canal.

Angle closure glaucoma is rare and usually only coincidental. It is usually due to pupillary block caused by a combination of posterior synechia, increased iris rigidity or thickness and anterior lens movement resulting from zonular weakness. Iris is more rigid, aqueous pressure in the posterior chamber causes the iris to bulge at the weakest point which is the root, producing a pseudo plateau iris. The tendency of these eyes from posterior synechia increases the frequency and severity of pupillary block and miotic induced angle closure.

## PSEUDOEXFOLIATION GLAUCOMA AND POAG

A decade ago it was considered that glaucoma associated with pseudoexfoliation was due to primary open angle glaucoma.

A decade ago the nomenclature of glaucoma and pseudoexfoliation was as follows

<b>Pseudoexfoliation</b>		<b>Glaucoma</b>		<b>Diagnosis</b>
<b>RE</b>	<b>LE</b>	<b>RE</b>	<b>LE</b>	
+	+	-	-	BE PXF syndrome
+	+	+	+	BE POAG with PXF syndrome
+	+	+	-	RE SOAG due to PXF with LE PXF
+	-	+	-	RE SOAG due to PXF

PXF= pseudoexfoliation

POAG= Primary open angle glaucoma

SOAG= secondary open angle glaucoma

Current thinking is that glaucoma due to pseudoexfoliation is a secondary open angle glaucoma distinct from primary open angle glaucoma.

Because of the frequency of glaucoma that may be present or develop in pseudoexfoliation syndrome, visual field examination ,optic

disc photographs and tonography should be obtained if the disc or pressure is suspicious.

Following are the important clinical differences between glaucoma due to pseudoexfoliation and POAG.

1. Frequent asymmetry or unilaterality.
2. Potential for rapid escalation of I.O.P. and refractoriness to antiglaucoma therapy.
3. More favourable early response to argon laser trabeculoplasty.
4. Laser incidence of corticosteroid responsiveness.
5. Normal histopathology of outflow pathway except for the presence of extracellular pseudoexfoliation material and excessive pigmentation of the trabecular meshwork. So pseudoexfoliation glaucoma is a secondary glaucoma due to the deposited pseudoexfoliation material in the trabecular meshwork.

POAG is almost always bilateral but may be asymmetrical. It is not associated with excessive pigmentation of trabecular meshwork. It has the presence of increased extracellular plaque material with decreased cellularity and a disorganized trabecular structure.

KUCHLE et al found that aqueous protein concentration in pseudoexfoliation syndrome was significantly higher than normal and POAG patients. He also quantified flare using Laser Flare Cell Meter(LFCM)and found it to be significantly increased in pseudoexfoliation syndrome patients.

RINGVOLD et al reported that in pseudoexfoliation syndrome 74% is not associated with glaucoma. If glaucoma is present ,it usually unilateral in 18%and bilateral in 8%. In bilateral pseudoexfoliation cases 63%do not have glaucoma,24% have bilateral glaucoma and 13%have unilateral glaucoma. SZIKLAI et al reported that 34%of pseudoexfoliation glaucoma are unilateral and 66% are bilateral. Unilateral glaucoma was always in the eye with pseudoexfoliation. LAMBA and GIRIDHAR reported that 46% of their pseudoexfoliation patients had unilateral glaucoma and 54%had bilateral glaucoma

In cases of a combination of pseudoexfoliation with glaucoma in one or both eyes bilateral glaucoma with unilateral pseudoexfoliation, glaucoma was worse in the eye with pseudoexfoliation is the commonest presentation of pseudoexfoliation glaucoma and the presence of unilateral pseudoexfoliation with glaucoma in the other eye is the rarest.

## **INTRAOCULAR PRESSURE**

Various studies have shown that the average intraocular pressure in pseudoexfoliation glaucoma is higher than that in primary open angle glaucoma cases. **DAVENGER** et al reported the mean intraocular pressure of primary open angle glaucoma cases to be 25.5mm Hg and that for pseudoexfoliation glaucoma cases as 31.5mm of Hg.

**FUTA** et al found 25.5% of pseudoexfoliation glaucoma cases with intraocular pressure of 30mm Hg as against only 15% of primary open angle glaucoma cases.

**DAVENGER** et al found that patients with pseudoexfoliation have a higher mean intraocular pressure and more liable to glaucomatous damage at a certain intraocular pressure than those without pseudoexfoliation.

## **VISUAL FIELD DEFECTS**

Eyes with pseudoexfoliation glaucoma tolerate raised I.O.P. poorly and show a greater incidence of visual field defects than eyes with POAG. **HORVEN** et al reported 61.4% of pseudoexfoliation glaucoma patients having visual field defects as against 35.75% in POAG patients.

## **OPTIC NERVE DAMAGE**

Pseudoexfoliation glaucoma patients are associated with more frequent and higher degree of optic nerve damage.

LADEN and SHAFFER reported that out of 53 patients with unilateral pseudoexfoliation, 34 patients had cupping of 0.44 and 19 patients had cupping of 0.7. The non pseudoexfoliation eye showed a cupping 0.4 in 47 patients and 0.7 in 47 patients and 0.7 in 6 patients.

## **PSEUDOEXFOLIATION AND CATARACT**

Eyes with pseudoexfoliation have an increased incidence of cataract. Nuclear cataract is more common in incidence than cortical cataract. A significant number of patients with pseudoexfoliation have subluxated or dislocated lens (LAMBA and GIRIDHAR)

## **PSEUDOEXFOLIATION AND MYDRIASIS**

Poor mydriasis is well known in pseudoexfoliation syndrome. Atrophy of iris musculature and infiltration of iris stroma with pseudoexfoliation material lead to iris rigidity and cause poor mydriasis.

## **IRIS NEOVASCULARISATION**

Iris hypoxia causes atrophy of iris pigment epithelium, stroma and muscle cells and leads to neovascularisation. Fluorescein angiography reveals hypoperfusion, peripupillary leakage and neovascularisation

## **POST OPERATIVE COMPLICATIONS**

Pseudoexfoliation syndrome predisposes to complications during cataract extraction. Pupil size is the most important risk factor during the surgical manoeuvre. Zonular fragility increases the risk of lens dislocation. The lens cortex is sticky because of adhesion between cortex and capsule. Capsular rupture and vitreous loss are more common. Post operatively there is great risk of I.O.P. elevation, cellular precipitates on the IOL and posterior formation. Transient fibrinoid reactions after cataract extraction may be due to breakdown of blood aqueous barrier

## **SOURCE OF PSEUDOEXFOLIATION MATERIAL**

The origin of pseudoexfoliation material is thought to be of multifocal origin.



## **CONJUNCTIVA**

Pseudoexfoliation material has been demonstrated in both and palpebral conjunctiva. In addition it is present in the conjunctival stroma associated with endogenous elastic fibres of conjunctiva.

## **LENS**

The hallmark of pseudoexfoliation syndrome is its presence on the lens. Histologically 5 regions of the are described, comprising not only the 3 clinically observed regions (central disk, intermediate clear zone, peripheral granular zone) but also the anterior and posterior equatorial regions. The posterior capsule does not appear to be involved in pseudoexfoliation syndrome. The clinically obvious appearance of central and peripheral regions may be the result of aqueous borne deposition and polymerization because the underlying lens capsule remains intact and does not show evidence of production of pseudoexfoliation material. Intrinsic capsular changes are present in the equatorial zones leading to the conclusion that the material is produced in these areas.

Deposits that occur in the anterior hyaloid face after intracapsular cataract extraction suggest that the lens is not the only source of pseudoexfoliation material (SUGAR)

## **IRIS**

Pseudoexfoliation material has been found on the iris pigment epithelium, blood vessel wall, anterior stroma and at the pupillary margin.

Iris vasculature may contain subendothelial accumulation of the material often in conjunction with disrupted basement membrane. These changes may occlude the lumen in some areas and may explain the clinical observation of dropout and leakage of iris vessels and occasional areas of vasoproliferation seen with fluorescein angiography.

## **ZONULES**

Pseudoexfoliation material is often seen on the zonules. There is a tendency for spontaneous subluxation or dislocation of the lens in advanced cases due to weakening of zonular attachment to the ciliary body.

A study by **SCHLOTZER** on zonular instability in pseudoexfoliation syndrome has showed the typical alterations to occur at 3 sites.

- i. At their origin and anchorage in ciliary body.
- ii. In the pars plicata of ciliary body.
- iii. At their attachment to the anterior lens capsule.

## **TRABECULAR MESHWORK**

Pseudoexfoliation material is present in the aqueous channels of the trabecular meshwork, the inter trabecular spaces, juxtacanalicular tissue and Schlemm's canal all consistent with a washing in and deposition of aqueous borne material.

## **SKIN**

A study by STREETEN found the pseudoexfoliation material in retro auricular skin and eye lid skin primarily along with elastic fibrils.

## **PSEUDOEXFOLIATION SYNDROME**

### **A SYSTEMIC DISORDER**

SCHLOTZER and STREETEN found fibrils similar to pseudoexfoliation material in skin, myocardium, Lung, Liver, gall bladder, kidney and cerebral meninges and this points to the possibility of pseudoexfoliation syndrome being a local manifestation of a systemic disorder.

## **HISTOLOGY OF PSEUDOEXFOLIATIVE MATERIAL**

Though pseudoexfoliation syndrome has been a recognised entity for over 80 years, the essential nature of pseudoexfoliation material in the anterior segment of the eye is still obscure.

## **ELASTIN**

Pseudoexfoliation material is a homogenous eosinophilic, PAS positive staining substance under light microscopy. Periodic Acid Schiff staining indicates a material rich in polysaccharides. Transmission electron microscopy shows pseudoexfoliation material to be afibrillar protein arranged in an irregular meshwork.

Immunoelectron microscopy revealed elastin and tropoelastin. These observations lead to the theory that pseudoexfoliation is a type of elastosis.

NETLAND did an electron microscopic study of optic nerve head of eyes with pseudoexfoliation syndrome and glaucoma and found site specific elastosis in the lamina cribrosa of these patients, suggesting an abnormal regulation of elastin synthesis in optic nerve head of patients with pseudoexfoliation syndrome.

## **BASEMENT MEMBRANE**

Immuno histochemical studies have shown heparin sulphate, chondroitin sulphate, proteoglycans, laminin, fibronectin and amyloid P protein to be integral constituents of pseudoexfoliation

material. It indicates pseudoexfoliation material maybe a basement membrane proteoglycon (**SCHLOTZER**).

## **AMYLOID**

Several studies have found that pseudoexfoliation material reacts with stains suggestive of amyloid like congo red, thioflavin and thioflavins. Both amyloid and pseudoexfoliation material stain with ruthenium red and react positively for tyrosine and tryptophan on histochemical tests. Several patients with amyloidosis have reported to have deposits on the equator of the lens capsule and on the iris surface similar to pseudoexfoliation material(**RINGVOLD**).

## **DIFFERENTIAL DIAGNOSIS**

The important entities in the differential diagnosis of pseudoexfoliation syndrome are the following:

### **a. PIGMENT DISPERSION SYNDROME**

Pigment dispersion syndrome is bilateral, symmetrical and occurs commonly in fourth and fifth decades. Males are more commonly involved. It occurs more in whites and in myopes. On the other hand, pseudoexfoliation syndrome usually occurs above 50 years. Both males and females are affected and there is no racial predisposition and no

association with myopes. Pigmentation in pigmentary glaucoma is more distinct and appears as a band in the angle. Krukenberg's spindle is commonly seen in corneal endothelium. In pseudoexfoliation syndrome the pigmentation is less distinct and is in a discontinuous, segmented pattern. Transillumination defects in pigmentary glaucoma are mid stromal and slit like but in pseudoexfoliation syndrome they are at pupillary margin.

#### **b. TRUE EXFOLIATION**

The exfoliation of the lens capsule is seen in those who are exposed to high temperature such as glass blowers. It is associated with cataract but only rarely associated with glaucoma. The deposit from the heat induced cataract is rolled up as a clear diaphanous membrane with a free edge floating in the aqueous in contrast to the frosty appearance seen in pseudoexfoliation syndrome.

#### **c. IRITIS WITH PIGMENT DISPERSION**

Iritis with pigment dispersion on the meshwork and adhesions of pupillary margin to the anterior lens capsule can be differentiated by the absence of pseudoexfoliation material on the anterior lens capsule.

#### **d. OTHER CONDITIONS**

Characterised by pigment changes such as Fuchs heterochromic iridocyclitis, pigmentation of the chamber angle with ageing or after surgery and pigmentation of the chamber angle with ageing or after surgery and pigmentation secondary to intraocular tumors can usually be differentiated.

## **MANAGEMENT**

### **GLAUCOMA**

The frequent occurrence of glaucoma in pseudoexfoliation syndrome and its aggressive nature requires in pseudoexfoliation syndrome and its aggressive nature requires the clinician to be wary of the condition. Regular periodic examinations should be performed with initial baseline optic drawings or photographs. Tonography may give an indication of the functioning of outflow channels in patients with borderline or abnormal values indicating more frequent follow up.

### **MEDICAL**

Once glaucoma is diagnosed, standard antiglaucoma medications used for POAG are used. Regular examinations are again important because I.O.P. will become more difficult to control with time (BLIKA and SAUNTE). Miotics may lead to synechia between the papillary margin and anterior lens capsule. Therefore miotic use should be accompanied by frequent dilatation. However, dilatation may also result acute rise I.O.P. accompanied by diffuse pigment dispersion in the anterior chamber.



Miotics increase the aqueous outflow and by the inhibiting papillary movement, decrease the amount of pseudoexfoliation material and pigment dispersion by irido lenticular contact(MAPSTONE).

Recently it was found that timolol 0.5% and Dorzolamide 2% { fixed combination } and Latanoprost are efficacious in the treatment of newly diagnosed pseudoexfoliation glaucoma but still long term efficacy requires further study .

Since pseudoexfoliation is associated with elevated homocysteine. the vitamins like vitamins B12, vitamins B Complex and folic acid can reduce the homocysteine level may be helpful.

## **LASER**

Argon laser trabeculoplasty is especially successful in pseudoexfoliation syndrome. Studies report average initial success rate is thought to be due to the higher starting I.O.P. and the generally increased trabecular pigmentation. As in POAG, success rates decrease with time, averaging 50% or less in 5 years(RITCH).

## **SURGERY**

1. Trabeculectomy can be done in pseudoexfoliation syndrome with results comparable to those in POAG. There do not appear to be unusual complications(KONSTAS).
2. TRABECULOTOMY has been advocated as an alternative surgical procedure(GILLIES)
3. In cataract surgery the choice of IOL is also imported in eyes in pseudoexfoliation. Heparin surface modified PCIOL were found to be associated with fewer post operative fibrinoid reactions less frequent pigment and cellular deposits and posterior synechiaae formation.
4. JACOBI et al have reported success with trabecular aspiration, a technique designed to remove pseudoexfoliation material from the trabecular meshwork.

## **CATARACT EXTRACTION**

Although lens extraction is not advocated for the management of glaucoma in pseudoexfoliation syndrome, cataract extraction for improvement of visual acuity is frequently indicated and requires special consideration in these patients. There is increased incidence of complications like poor mydriasis, zonular dialysis and vitreous loss.

Preoperatively the surgeon should look for evidence of zonular dialysis such as phacodonesis and asymmetrical anterior chamber depth.

If extracapsular extraction is to be performed, several precautions should be considered : gentle anterior capsulotomy, longer corneoscleral incision, hydrodissection of nucleus, gentle nucleus expression and irrigation and aspiration of the remaining cortex(LUMME).

## **PART-2**

### **AIM OF THE STUDY**

To determine the association of glaucoma in pseudoexfoliation syndrome with respect to

1. Demographic study of pseudoexfoliation.
2. Incidence and type of glaucoma in pseudoexfoliation.
3. Study of lens morphology in pseudoexfoliation.
4. Response to treatment

## MATERIALS AND METHODS

100 patients with pseudoexfoliation syndrome who attended the Department Of Ophthalmology, Government Rajaji Hospital, Madurai between January 2007 and november 2008 were included in the study.

The patient's selection criteria for the study was the presence of pseudoexfoliation material on the pupillary border and /or the lens.

All the patients were subjected to a detailed slitlamp examination and the following clinical signs were specifically looked for :

- Conjunctiva-congestion
- Cornea-edema, pigmentation, pseudoexfoliation material
- Anterior chamber –depth, flare, cells, pseudoexfoliation material, pigment dispersion
- Iris-pattern, transillumination defects
- Pupil-size, reaction to light, pseudoexfoliation material, dilation with mydriatics
- Lens-Pseudoexfoliation material, cataractous or not.

Pupil was dilated as a routine in most of the cases to note the three zones of pseudoexfoliation material on the lens capsule. glaucoma workup was done for all patients which included visual acuity , tonometer with schiotz tonometer, tonography, perimetry with bjerrum screen and gonioscopy with goldmann three mirror lens.

During gonioscopy the angle stasis was assessed and the presence of pseudoexfoliation material and increased pigmentation on the angle were noted.

## ANALYSIS AND DISCUSSION

**TABLE - 1**

### LATERALITY

Laterality	No. of cases with pseudoexfoliation	%	No. of eyes with pseudoexfoliation
unilateral	47	47	47
bilateral	53	53	106
total	100	100	153

The higher incidence of bilateral pseudoexfoliation in this study is in accordance with other studies (BARTHOLOMEN).

This could be due to possibility that unilateral cases invariably become bilateral at a later date. Henry et al found the probability of pseudoexfoliation developing in the fellow eye to be 6.8% after 5 years & 16.8% after 10 years.

In this study 47 patients with unilateral pseudoexfoliation have a risk of developing pseudoexfoliation in other eye later. Hence these patients need the follow up.

**TABLE 2**  
**UNILATERAL CASES**

EYE	NO	%
RE	24	51.06
LE	23	48.94
TOTAL	47	100

Of these patients, 53 had bilateral pseudoexfoliation and 47 had unilateral pseudoexfoliation. Thus totally 153 eyes of 100 patients had pseudoexfoliation. In unilateral cases, Right eye was more affected than the Left eye.

**TABLE 3**

Age groups	unilateral		bilateral		total	
	no	%	no	%	no	%
< 50 yrs	4	8.5	3	5.6	7	7
51to60 yrs	19	40.4	14	26.4	33	33
61to 70 yrs	22	46.8	30	56.6	52	52
71to80 yrs	2	4.2	3	5.6	5	5
> 80	–	–	3	5.6	3	3
<b>total</b>	<b>47</b>	<b>100</b>	<b>53</b>	<b>100</b>	<b>100</b>	<b>100</b>



The most common age group in unilateral and bilateral cases was between 61 and 70 years and in bilateral and unilateral cases the next common age group was between 51 and 60 years.

The youngest patients in the study was 50 years old and the oldest patient was 94 years

**Table – 4**

sex	unilateral		bilateral	
	no	%	no	%
males	25	53.20	30	56.60
females	22	46.80	23	43.40
total	47	100	53	100

Out of 100 patients with pseudoexfoliation, 55 were males and 45 were females . In both unilateral and bilateral pseudoexfoliation groups, there was a mild male preponderance and most of the patients were agricultural workers. TAYLOR and RESNIKOFF et al suggested that pseudoexfoliation syndrome could be related to environmental factors and exposure to ultraviolet light. In this study can be explained to some extent by the fact that in Indian males are more likely to have outdoor activities than females.

**TABLE 6:**

<b>SEX</b>	<b>Total no. of pseudoexfoliation</b>	<b>With out glaucoma</b>		<b>with glaucoma</b>	
		<b>no</b>	<b>%</b>	<b>no</b>	<b>%</b>
male	55	29	53.70	26	56.52
female	45	25	46.30	20	43.48
total	100	54	100	46	100

In both groups with and without glaucoma males are predominant. Reports in literature regarding the sex incidence vary. HANSEN reported a female predominance in the non glaucomatous pseudoexfoliation group. LAMBA and GIRIDHAR reported a definite male predominance with incidence similar to this study.

### **GLAUCOMA ASSOCIATION**

Incidence of glaucoma in this study was 46% and 54% had no glaucoma. Incidence of glaucoma in pseudoexfoliation syndrome varies in different races and in different locations.

**TABLE - 7**

<b>LOCATION</b>	<b>INCIDENCE OF GLAUCOMA</b>	<b>YEAR</b>
Japan	63%	1988
Spain	49%	1989
Norway	30%	1991

This variation of incidence could be attributed to the difference in the racial pre disposition (Asian Vs western)

**TABLE 8**

**TYPE OF GLAUCOMA**

<b>TYPE OF GLAUCOMA</b>	<b>NO</b>	<b>%</b>	<b>IOP &gt; 30 mm of Hg</b>
OPEN ANGLE	37	80.43	19
ANGLE CLOSURE	9	19.57	2
TOTAL	46	100	21

Thus open angle glaucoma is more common in pseudoexfoliation syndrome than angle closure glaucoma . this could be explained that pseudoexfoliation and POAG share the same mechanism of out flow obstruction and also mechanism of rise in IOP in pseudoexfoliation associated open angle glaucoma may include local production of

pseudoexfoliation material ,endothelial cell damage of trabecular meshwork and passive deposition of pseudoexfoliation material and pigment originating from elsewhere in the anterior segment. [GILLES W. E. BROOKE AMV]

### **OPEN ANGLE GLAUCOMA**

<b>OPEN ANGLE GLAUCOMA</b>	<b>NO.</b>	<b>%</b>
Unilateral	4	10.81%
Bilateral	33	89.19%
<b>Total</b>	<b>37</b>	<b>100%</b>

### **UNILATERAL OPEN ANGLE GLAUCOMA**

Out of 4 patients with unilateral open angle glaucoma 3 patients had pseudoexfoliation in both eyes and 1 patient had pseudoexfoliation in one eye These patients require regular follow up and periodical evaluation as there is a high risk of developing glaucoma in other eye. HENRY et al had shown that the probability of the other eye developing glaucoma to bilateral 5.3% after 5 years and 15.4% after 10 years.

### **BILATERAL OPEN ANGLE GLAUCOMA**

Out of 33 patients with bilateral open glaucoma 26 patients had bilateral pseudoexfoliation and 7 patients had pseudoexfoliation In this

could be explained that pseudoexfoliation and POAG share the same mechanism of outflow obstruction.

Price and Speakman have proved that conjunctival biopsy in fellow uninvolved of patients with unilateral pseudoexfoliation is invariably positive for pseudoexfoliation material. Mizuno has shown that cycloscopy examination of the uninvolved fellow eyes invariably showed evidence of pseudoexfoliation material on zonules and ciliary processes. Thus the clinically uninvolved fellow eyes also might have pseudoexfoliation material evidenced by conjunctival biopsy and cycloscopy but not detectable by routine S/L examination.

Sziklai et al reported that 34% of pseudoexfoliation are unilateral and 66% are bilateral.

Lamba and Giridhar reported that 46% of pseudoexfoliation had glaucoma and 54% had bilateral glaucoma. Thus bilateral glaucoma is more prevalent than unilateral.

## ANGLE CLOSURE GLAUCOMA

**TOTAL: 9**

ANGLE CLOSURE GLAUCOMA	NO.
SECONDARY ANGLE CLOSURE	6
SUBLUXATED LENS	5
INTUMESCENT LENS	1
PRIMARY ANGLE CLOSURE GLAUCOMA	3

### **Secondary angle closure glaucoma:**

Out of 6 patients of secondary angle closure glaucoma, 5 patients had subluxated lens and 1 patient in the intumescent stage of immature cataract. There was no history of trauma in these patients

### **Primary angle closure glaucoma**

In 3 patients there was no other secondary factor involved for angle closure except for the presence of pseudoexfoliation. Of 3 patients 1 had unilateral pseudoexfoliation and 2 had bilateral pseudoexfoliation. They are diagnosed as primary angle closure glaucoma. The possible mechanism in this study could be a pupillary block by anterior shift of iris lens diaphragm due to weakened zonules, rigid, constricted, non-dilated eye. This study shows 26 patients had poor mydriasis.

Epstein et al had highlighted the increased incidence of angle closure glaucoma in pseudoexfoliation syndrome. Hence pseudoexfoliation should be considered as a risk factor for angle closure glaucoma also.

## CLINICAL FEATURES

**TABLE 9**

	<b>FEATURES</b>	<b>PATINTS NO.</b>
conjunctiva	pterygium	16
cornea	Pig/kp/sph degeneration	2/0/8
ac	pxf	3
iris	Pupillary ruff defects	2
pupil	Non dilation/pxf	26/100
lens	pxf	53

16 Patients had pterygium and 8 patients had spheroidal degeneration Bartholomen reported association of pseudoexfoliation with spheroidal degeneration of the cornea these features are more likely to be present as a coincidental to sun light exposure.

26 patients with pseudoexfoliation did not respond to mydriatics. This nondilatation of pupil is a well recognized entity in

pseudoexfoliation syndrome. This could be attributed to the intrinsic degenerative changes occurring in the sphincter pupillae of pseudoexfoliation eyes .

Pseudoexfoliation material was seen in the pupillary margin in all patients .the three classic zones of pseudoexfoliation material deposition on the lens were noted in 53 patients .

## **VISION**

Most of the patients had visual acuity  $<6/36$ . the defective vision was mainly due to the presence of glaucoma and associated cataract.

## **GONIOSCOPY**

Trabecular hyperpigmentation was noted in most of the patients sampaolesi line was present in 46 patients. Pigmentation was more in the eye with increased tension in bilateral cases .

## **TONOMETRY**

Out of 46 patients with raised IOP 13 patients had IOP more than 30mm of Hg (28.31%).

Futa et al found 25.5% of pseudoexfoliation glaucoma cases with IOP of 30mm of Hg.



Davenger et al reported the incidence mean IOP of POAG as 25.5mm of Hg and pseudoexfoliation cases as 31.5mm of Hg.

### **FIELDS:**

Out of 46 patients with glaucoma 20 patients had visual field defect (43.47%) 12 patients had Double Arcuate scotoma, 5 patients had enlargement of Blind Spot and 1 patient had tubular vision.

Horven et al reported 61.4% of pseudoexfoliation glaucoma have visual field defects against 35.75% in POAG.

### **FUNDUS**

In 46 Patients with glaucoma 12 patients had 0.7 – 0.8 cupping 21 patients had cupping of 0.4, 13 patients had Haziness of fundus due to cataractous changes.

Layder & Shaffer reported in his study of 53 patients 34 patients had cupping 0.4 and 19 patients had cupping with 0.7.

### **SYSTEMIC ASSOCIATION**

4 patients had diabetes mellitus and 3 patients had hypertension.

## LENS STATUS AND GLAUCOMA

TABLE 10

Lens status	No. of eyes			TOTAL
	normal	OAG	ACG	
Nuclear cat	42	30	1	73
Cortical cat	17	22	10	49
IMC	14	20	4	38
MATURE	3	1	1	5
HYPER MATURE	-	1	5	6
aphakia	3	-	-	3
Clear lens	2	-	-	2
PCIOL	8	18	-	26
TOTAL	72	70	11	153

Out of 153 eyes with pseudoexfoliation the incidence of nuclear cataract is 47.71% and that of cortical cataract is 32.02%.

The increased incidence of nuclear cataract found in this study is in accordance with similar reports from other studies ( SOOD, SELAND ). Of the 4 eyes with open angle glaucoma 75% had Nuclear cataract and 25% had cortical cataract.

<b>Cataract</b>	<b>Without glaucoma</b>	<b>With glaucoma</b>	
		<b>OAG</b>	<b>ACG</b>
Nuclear	57.53	41.10	1.37
Cortical	34.7	44.9	20.40

Thus in pseudoexfoliation eyes, cortical cataract was less common in incidence but more commonly associated with glaucoma when compared to nuclear cataract which was more common in incidence but less commonly associated with glaucoma. A similar observation has been made by Seland.

In the study of 70 eyes with open angle glaucoma 42.85% had nuclear cataract and 31.42% had cortical cataract

Out of 9 eyes with angle closure glaucoma 9.1 % had nuclear cataract & 91% had cortical cataract. Thus in eyes with open angle glaucoma nuclear cataract was more common but in eyes with Angle closure glaucoma cortical cataract was more common.

## **TREATMENT:**

Out of 100 pseudoexfoliation 46 patients were having glaucoma. Among the 46 glaucoma patients, the following 16 patients with a secondary cause for their glaucoma were advise early surgical treatment after control of the high I.O.P. medically

1. Secondary angle closure glaucoma due to
  - a. Subluxated lens - 5
  - b. Intumescent cataract - 4
2. Phacolytic glaucoma - 1

The remaining 30 glaucoma patients were subjected to medical treatment after a detailed medical history and examination. The patients were randomly divided into 2 groups, each with 15 patients. One group was treated with Timolol 0.5% eye drops twice daily and the other group was treated with Pilocarpine 2% eye drops 4 times daily.

The patients were assessed at the end of 2 months with reference to control of I.O.P. visual acuity, fundus and field changes.

Patients with good response to a single drug were advised to continue the same treatment with periodical review. Other patients with poor response to single drug were subjected to treatment with a

combination of Timolol 0.5% eye drops BD and Pilocarpine 2% eye drops QID for another 2 months.

At the end of 4 months patients were assessed and patients with good response were advised to continue the treatment with periodical review. Patients with poor response were subjected to antiglaucoma surgery at the end of 4 months and assessed after 2 months.

## **RESULT**

### **Groups – I**

Out of 15 patients Timolol 0.5% bid for 2 months

1. No of eyes : 15

Responders :3

Poor responders:12

2. combination of Timolol 0.5%/ pilocarpine 2% qid on 3<sup>rd</sup> and 4<sup>th</sup> months

No of patients :12

Responders: 5

Poor responders :7

3. combined surgery was done for 7 patients.

### **GROUP - II**

1. Pilocarpine 2% qid for 2 months

No of patients :15

Responders :9

Poor responders:6

2. combination of Timolol 0.5% /Pilocarpine 2% qid on 3<sup>rd</sup> and 4<sup>th</sup> month

No of patients :6

Responders :4

Poor responders:2

combined surgery was done for 2 patients out of 46 patients 21 patients responded to medical therapy (45.65%) and 25 patients underwent combined surgery (54.34%). Soderstrom et al studies showed Timolol /Pilocarpine combination found a greater IOP reduction than a single drug. Koontas AGP jay JLOPH shows pseudoexfoliation patients has better response to filtering surgery than medical therapy Out of 25 patients 5 patients had posterior capsular rent( 20%) and 1 patient had vitreous loss was observed during surgery (4 %). Nauman et al observed posterior capsular tear in 4.2% in pseudoexfoliation compared to 2.8% in eyes without pseudoexfoliation .SCHOWLENS et al also found the incidence of capsular break and vitreous loss occur significantly more ( $p < 0.005$  ). Poulique et al found the incidence of capsule zonular rupture (22.5%) in these patients it may be related to a pupillary diameter and zonular fragility and produce increased of zonular dialysis and vitreous loss.

At the end of 2 months post operative period reviewed 20 patients showed non progression of glaucoma and 5 patients did not come for follow up..

## **SUMMARY**

### **LATERALITY**

53% of patients had bilateral pseudoexfoliation and 47% had unilateral pseudoexfoliation. Thus bilateral pseudoexfoliation is more common and this could be due to the possibility that the unilateral cases invariably become bilateral at a later date. In unilateral patients RE was involved in 51.06% and LE in 48.94%

### **AGE GROUP**

The most common age group in both unilateral and bilateral cases was 61-70 years. . Hence pseudoexfoliation syndrome is a disease of aged.

The youngest patient was 50 years old and the oldest patient was 94 years old.

### **SEX**

55% of pseudoexfoliation patients were males and 45% were females. As ultraviolet light is a possible factor related to pseudoexfoliation syndrome, the definite male preponderance could be explained partly by the fact that males are more involved with outdoor activities than females.



## **GLAUCOMA ASSOCIATION**

46% of pseudoexfoliation patients had glaucoma while 54% had no evidence of glaucoma.

## **TYPE OF GLAUCOMA**

Out of 46 patients with glaucoma, 37 patients had open angle glaucoma and 9 patients had angle closure glaucoma.. Thus, open angle glaucoma is more common in pseudoexfoliation syndrome.

## **OPEN ANGLE GLAUCOMA**

Out of 37 pseudoexfoliation patients with open angle glaucoma,4 had unilateral glaucoma and 33 had bilateral glaucoma. Out of 4 patients with unilateral open angle glaucoma,3 had pseudoexfoliation in both eyes but 1 had pseudoexfoliation in one eye. These patients have a high risk of developing glaucoma in the other eye and hence were advised a periodical review. 1 patient with bilateral open angle glaucoma had pseudoexfoliation in both eyes

Out of 33 patients with bilateral open angle glaucoma 26 had pseudoexfoliation in both eyes and 7 had pseudoexfoliation in one eye . Thus 7 patients with unilateral pseudoexfoliation had glaucoma not only

in the affected eye but also in the clinically uninvolved eye .Thus the clinically uninvolved has the risk of developing glaucoma.

### **ANGLE CLOSURE GLAUCOMA**

Out of 46 patients with glaucoma 9 had angle closure glaucoma .Of the 9 patients, 6 had secondary angle closure glaucoma ( 5 due to subluxated lens and 1 due to intumescent immature cataract). The 5 patients with subluxated lens had no history of trauma and had spontaneous subluxation probably due to weaking of zonules by pseudoexfoliation material

In the remaining 3 patients there was no other secondary factor involved .except for pseudoexfoliation . these patients are more likely to have primary angle closure glaucoma with pseudoexfoliation .

### **CLINICAL FEATURES**

In 26 patients, pupil did not respond to mydriasis probably due to intrinsic degenerative changes occurring in the sphincter pupillae in pseudoexfoliation syndrome.

47.71% of pseudoexfoliation eyes had nuclear cataract while 32.02% had cortical cataract.Thus nuclear cataract was more common in

pseudoexfoliation syndrome. 3 eyes was present in aphakia, 2 eyes with clear lens and 26 eyes with PCIOL.

Of 73 pseudoexfoliation eyes with nuclear cataract, 57.53% were normotensive while 41.1% had open angle and 1.37% had angle closure glaucoma ,whereas of 49 eyes with cortical cataract, 34.7% were normotensive ,44.9% were open angle glaucoma and 20.40 % had angle closure glaucoma while the remaining 2.5% had glaucoma. Thus, in pseudoexfoliation eyes, nuclear cataract was more common in incidence than cortical cataract.. the cortical cataract is less in incidence in pseudoexfoliation than nuclear but more in incidence with glaucoma

## **TREATMENT**

Out of 46patients with glaucoma 21 patients responded to medical treatment (45.65% )and 25 patients underwent surgical treatment (54.34%)

Out of 25 patients 5 patients developed posterior capsular rent (20%) and 1 patient had vitreous loss (4%).after 2 months of followup post operatively 20 patients showed non progression of glaucoma and 5 did not come for review.thus the patients with pseudoexfoliation responds well to surgical treatment.

## **CONCLUSION**

### **PSEUDOEXFOLIATION**

1. Bilateral pseudoexfoliation was more common than unilateral pseudoexfoliation.
2. The maximal incidence of pseudoexfoliation in both unilateral and bilateral cases were in the age group 61-70 years..
3. Pseudoexfoliation syndrome, though a disease of the elderly, can also occur in 50 years age group.
4. The youngest patient reported in this study 50 years old and the oldest patient was 94 years old.
5. Males predominated in all groups of pseudoexfoliation patients, unilateral and bilateral, and with or without glaucoma.

### **GLAUCOMA**

1. There is a risk of developing glaucoma in pseudoexfoliation patients.
2. Open angle glaucoma is more common in pseudoexfoliation syndrome ..
3. The clinically uninvolved eye of unilateral cases has a risk of developing glaucoma.

4. In pseudoexfoliation eyes, nuclear cataract was more common in incidence compared to cortical cataract
5. In pseudoexfoliation eyes with glaucoma cortical cataract was more common than nuclear cataract
6. pseudoexfoliation patients responds well to combination of drugs than single drug and has more responds to surgical therapy than medical therapy.
7. patients with pseudoexfoliation are more prone to posterior capsular tear and vitreous loss during cataract surgery can be reduced by prior anticipation.

## BIBLIOGRAPHY

1. STREENTEN B.W.et al: pseudoexfoliative fibrilopathy in conjunctiva, ophthalmology 94 :1439,1987.
2. EAGLE R.C .J. et al: Arch opthal 97 :510, 1979 Basement membrane exfoliation syndrome.
3. GARDNER A, ALEXANDER R.A: pseudo exfoliation Disease, BJO 68:1984.
4. DVORAK THEOBALD AJO 37:1, 1954 pseudoexfoliation of lens capsule
5. **SUGAR** H.S Onsetof exfoliation syndrome after I.C.C.E,AJO 89:601,1980.
6. HILLER.R. et al: Pseudo exfoliation I.O.P and senile lens changes in a population based survey: Arch of Oph 100:2,1982.
7. LAYDEN W.E:Exfoliation syndrome: The secondary glaucoma, St Louis 1982 Mosby.
8. LAMBA P.A. GIRIDHAR A: pseudoexfoliation syndrome I.J.O.32:169,1984.
9. MARIUM M.K.. AURORA A. pseudoexfoliation an immunological disease ? xxv international congress of ophthalmology,Roma immunology abstract 48:1986.
10. AASVED H: Frequency of fibrilopathia epithelio capsularis with open angle glaucoma: Acta opthal 49 : 194 ,1971.

11. PRINCE A.M. RITCH R: Clinical signs of pseudoexfoliation syndrome: ophthalmology 93 ,803,1986.
12. TARKKANEN: Pseudoexfoliation of the lens capsule Acta. ophthal 47:161,1969.
13. KUCHLE M et al : protein quantification and electrophoresis aqueous humor of pseudoexfoliation eyes : Invest. Ophthal vis. Sci. 35: 748,1994.
14. SZIKLAI P. SAVEGES I:Glaucoma capsulare in patients with open angle glaucoma in Hungary. Acta Oph.66 suppl 184: 44,1988.
15. RINGVOLD et al : The middle Norway eye screening study 2:Prevalence of simple and capsular glaucoma. Acta. Oph. 69:273 ,1990.
16. TAYLOR. H.R.:The environment and lens :BJO 64: 303, 1980.
17. RESNIKOFF et al:Climatic droplet keratopathy , exfoliation syndrome and cataract:BJO 75:734,1991
18. HANSEN E et al:Pseudoexfoliation of lens capsule :Acta. Oph. 48:446,1970
19. SPEAKMAN et al;The conjunctiva on senile lens exfoliation:Oph .94:1757,1956.
20. MIZUNO K et al: Cycloscopy of pseudoexfoliation:AJO 87:513,1982.

21. EPSTEIN et al: Increased prevalence of occludable angles and angle closure glaucoma in patients with pseudoexfoliation :AJO 117(3) :333,1994.
22. SELAND : Cataract in exfoliation syndrome oph soc of u.k. 102: 375,1982.
23. SOOD N .N, et al :Pseudoexfoliation of the lens capsule :orient Arch. Oph. 6:62,1968.
24. RITCH R:Exfoliation syndrome ,most common identifiable cause of open angle glaucoma :J.glaucoma 3:176,1994.
25. TAYLOR H.R.et al : Pseudoexfoliation of lens in Australian Arboriginnes : BJO 61 :475,1977.
26. RESNIKOFF et al:climatimatic droplet keratopathy, exfoliation and cataract:BJO 75:734,1991. 24HANSEN E et al : pseudoexfoliation of lens capsule : Acta oph. 48:446,1991
27. PRINCE and RITCH R:preclinical diagnosis of pseudoexfoliation : Arch oph.105:1076,1987.
28. MIZUNO K et al: cycloscopy of pseudoexfoliation :AJO 87:513,1982
29. SELAND: Cataract in exfoliation syndrome Oph .soc of UK 102:375,1982.
30. SOOD N.N.et al:Pseudoexfoliation of lens capsule:Orient Arch. Oph 6:62, 1968.



31. RITCH R: Exfoliation syndrome the most common identifiable cause of open angle glaucoma: J glaucoma 3:176,1994.
32. AAO OPH.vol.108 p.no.1043: Ocular hemodynamics in pseudoexfoliation syndrome and pseudoexfoliation glaucoma. JUNE 2001.
33. JOURNAL OF GLAUCOMA dec .2002 vol. 11 (4-6) p.no.517 conversion to unilateral to bilateral and to glaucoma.
34. EYE Vol. 17 no 1 JAN 2003 p. no.41: The efficacy and safety of timolol0.5%and dorzolamide 2% fixed combination vs latanoprost in pseudoexfoliation glaucoma
35. JOURNAL OF GLAUCOMA june 2003 vol.12 (1-3): Estimated incidence of pseudoexfoliation syndrome and pseudoexfoliation glaucoma.
36. ARCHIVES of ophthalmology Jan. 2004 vol. 122 (1-4)p.29: factors associated with long term progression or stability in pseudoexfoliation glaucoma.
37. JOURNAL OF GLAUCOMA VOL.11 (1-4) march 2005 p.no.386 risk of glaucoma in ocular hypertension.
38. INVESTIGATIVE OPHTHAL. And visual science NOV 2005 (p.no. 4170) VOL.96,no.9: pathophysiological changes in optic nerves with primary open angle glaucoma and pseudoexfoliation glaucoma.

**PROFORMA**  
**CLINICAL STUDY OF GLAUCOMA IN**  
**PSEUDOEXFOLIATION**

1. Name

Age/sex

HospitalNo.

date/address/occupation

2.symptoms/duration

Defective vision

Pain /redness

3.past history

Previous episodes

Medical treatment

Surgery

Trauma

4.medical history

Diabetes

Hypertension

Asthma

## 5.ocular examination

	RE	LE
Conjunctiva		
Cornea		
Clear		
Oedema		
Pigmentation		
K.P.		
Others		
A.C.		
Depth		
Flare		
Cells		
Pseudoexfoliation material		
Iris and pupil		
Pseudoexfoliation material		
Colour pattern		
Iridodonesis		
Dilatation with mydriatics		
Posterior synechiae		
Lens		
Pseudoexfoliation material		

Cataract

Nuclear

Immature

Mature

Hyperature

Aphakia

Subluxation

Dislocation

Intumescence

PCIOL

GONIOSCOPY

RE

LE

Grading

Pigmentation

Pseudoexfoliation material

Sampaolesi line

Vision

Tension

Tonography

Fields

Fundus

Diagnosis

Treatment

1. Medical

2. Surgical

3. Review

## MASTER CHART

No	Name	Age	Sex	Hosp No	Cornea		A-C		Iris and pupil		Lens		Vision		Tension		Tonography		Field		Gonio		Fundus		Diagnosis	Treatment
					R	L	R	L	R	L	R	L	R	L	R	L	R	L	R	L	R	L	R	L		
1	karupusamy	65	m	120624	p	p	nd	ppd	x	x	ncx	pciol	6/60	6/18	23.8	17.3	0.06	0.22	n	n	3	3	0.3	0.4	B/OAG	ST
2	alagar	66	m	25031	p	p	nd	ppd	x	x	ncx	pciol	6/36	6/24	23.8	17.3	0.08	0.2	n	n	3	3	0.4	0.4	B/UOAG	ST
3	kuppan	68	m	22335	sp	sp	nd	ppd	x	x	ncx	pciol	6/60	6/12	25.8	17.3	0.06	0.03	n	n	3	3	0.4	0.4	B/UOAG	ST
4	veerapandi	65	m	2431	sp	sp	nd	nd	x	—	ncx	nc	6/36	6/36	25.8	17.3	0.08	0.22	n	n	3	3	0.4	0.4	U/UOAG	SC
5	muthupandi	64	m	119703	sp	sp	nd	nd	x	—	ncx	nc	6/36	6/36	25.8	17.3	0.08	0.22	n	n	3	3	0.4	0.4	U/UOAG	SC
6	muniammal	60	f	355899	as	as	nd	nd	x	—	cc	lc	6/60	6/24	14.6	14.6	0.2	0.2	n	n	3	3	0.3	0.3	U	R-CAT SX
7.	parvathi	60	f	25139	as	as	d	nd	x	x	aph	cc	+10/6/24	5/60	17.3	17.3	0.2	0.3	n	n	3	3	0.3	0.4	B	L CAT SX
8	Muthu petchi	60	f	25022	as	as	nd	nd	x	x	cc	lc	6/36	6/18	14.6	14.6	0.2	0.2	n	n	3	3	0.3	0.3	B	RR
9	ammaasi	70	f	25028	as	as	sh	sh	x	x	ccx	cc	6/36	6/36	37.2	37.2	0.08	0.08	ars	ars	1	1	0.7	0.7	B/PACG	COM SX
10	meenakshi	68	f	11947	as	as	nd	nd	x-n	X -n	cc	cc	5/60	5/60	25.8	23.8	0.06	0.06	Tub vn	Tub vn	3	3	0.8	0.8	B/BOAG	SP
11	Muthu mari	66	f	25052	as	as	nd	nd	x-n	x-n	cc	cc	6/36	6/36	37.2	37.2	0.08	0.08	ars	ars	3	3	0.4	0.5	B/BOAG	COM SX
12	mari	66	m	118231	sp	sp	nd	nd	x	—	ccx	lc	6/60	6/18	27.2	23.8	0.08	0.06	EB	EB	3	3	0.4	0.4	U/BOAG	SC
13	nandappan	68	m	118741	sp	sp	nd	nd	x	—	NCX	NC	6/60	4/60	27.2	27.2	0.08	0.08	EB	EB	3	3	0.4	0.4	U/BOAG	SC
14	pandiyan	60	m	112731	as	as	nd	ppd	x	x	nc	pciol	6/36	6/18	14.6	14.6	0.3	0.3	n	n	3	3	0.3	0.3	B	RR
15	raku	65	f	248321	as	as	sh	sh	x-n	—	nc	lc	6/60	6/24	30.4	20.6	0.06	0.12	ars	ars	1	1	0.8	0.8	U/UPACG	COM SX
16	ramuthai	65	f	24552	pt	pt	ppd	nd	x	x	pciol	ccx	6/36	6/60	25.8	25.8	0.06	0.06	n	n	3	3	0.4	0.4	B/BOAG	SP
17	nagammal	65	f	25551	pt	pt	ppd	nd	x	x	pciol	ccx	6/24	6/60	25.8	25.8	0.08	0.08	n	n	4	4	0.4	0.4	B/BOAG	SP
18	Rasu devar	60	m	25337	as	as	nd	nd	x	x	nc	nc	6/36	6/36	17.3	17.3	0.22	0.22	n	n	4	4	0.3	0.3	B	CAT SX
19	Siva lakshmi	68	f	25108	as	as	sh	sh	x	x-n	ccx	cc	6/60	6/24	37.2	37.2	0.08	0.08	ars	ars	0	0	0.8	0.8	B/BACG	COM SX
20	alagammal	65	f	287734	pt	pt	ppd	nd	x	x	pciol	ccx	6/24	6/60	25.8	25.8	0.06	0.06	n	n	3	3	0.4	0.4	B/BOAG	SP
21	karuppaiya	60	m	30921	as	as	nd	nd	x	x	nc	nc	6/60	6/60	17.3	17.3	0.22	0.22	n	n	3	3	0.3	0.3	B	CAT SX
22	lakshmi	66	f	10712	as	as	ppd	nd	x	x	pciol	ccx	6/18	6/36	25.8	25.8	0.08	0.08	n	n	3	3	0.4	0.4	B/BOAG	SP
23	shanmugham	56	m	289045	cl	cl	ppd	nd	x	x	pciol	cc	6/24	6/60	14.6	14.6	0.26	0.3	n	n	3	3	0.3	0.3	B	CAT SX
24	Sivan kalai	58	m	24345	cl	cl	ppd	nd	x	x	pciol	cc	6/24	5/60	17.3	17.3	0.22	0.22	n	n	4	4	0.3	0.3	B	CAT SX
25	vellachi	70	f	31168	as	as	sh	sh	x-n	x-n	hmc	cc	hm	6/60	43.4	20.6	0.06	0.22	np	np	h	h	h	h	U/USACG	COM SX
26	sokku	68	f	49819	as	as	ppd	nd	x	x	pciol	ccx	6/36	6/18	25.8	25.8	0.08	0.08	n	n	3	3	0.4	0.4	B/BOAG	SP
27	rakkammal	60	f	5370	as	as	nd	deep	x	—	aph	cc	6/60	6/36	17.3	17.3	0.22	0.22	n	n	3	3	0.3	0.3	U	RR
28	nagammal	60	f	18925	as	as	nd	ppd	x	x	cc	pciol	5/60	6/24	14.6	14.6	0.22	0.22	n	n	4	4	0.3	0.3	B	CAT SX
29	Ramanujam	58	m	25296	as	as	nd	nd	x	x	nc	nc	6/60	6/60	17.3	17.3	0.3	0.3	n	n	3	3	0.3	0.3	B	CAT SX
30	Alagarsamy	78	M	31998	as	as	nd	nd	x	x	nc	nc	6/36	6/36	14.6	17.3	0.3	0.22	n	n	4	4/sam	0.3	0.3	B	—
31	Rakkammal	65	f	11920	as	as	ir	nd	x-n	—	hmc	cc	hm	6/60	37.2	20.6	0.06	0.20	np	np	1	3/sam	h	h	U/USACG	COMSX PCR

No	Name	Age	Sex	Hosp No	Cornea		A-C		Iris and pupil		Lens		Vision		Tension		Tonography		Field		Gonio		Fundus		Diagnosis	Treatment
					R	L	R	L	R	L	R	L	R	L	R	L	R	L	R	L	R	L	R	L		
32	Arakayee	68	f	119420	as	as	sh	nd	x-n	-	hmc	cc	hm	6/60	37.2	18.6	0.08	0.2	np	np	1	3/sam	h	h	B/USACG	COM SX PCR
33	Bose	65	m	3221	sp	sp	nd	nd	x	-	ncx	nc	4/60	5/60	23.8	27.2	0.10	0.08	EB	EB	3	3	0.4	0.4	U/BOANG	SC
33	Azhagi	70	f	54720	as	as	ppd	nd	x	x	pciol	ccx	6/24	6/24	25.8	23.8	0.06	0.06	n	n	3/ sam	3/ sam	0.4	0.4	B/BOAG	muniamma
34	Paramasivam	75	m	51372	as	as	nd	nd	x	x	nc	nc	6/60	6/60	17.3	17.3	0.2	0.2	n	n	3	3	0.3	0.3	U	CAT SX
35	Karuppasamy	66	m	48242	sp	sp	nd	nd	x	-	ccx	ccx	4/60	4/60	23.8	23.8	0.08	0.08	Np	np	3	3	h	h	U/BOAG	COM SX
36	Valarmathi	65	F	24942	as	as	ppd	nd	x	x	pciol	ccx	6/18	6/18	23.8	23.8	0.06	0.06	n	n	3	3	0.4	0.5	B/BOAG	COM SX
37	Liyagath Ali	65	M	24905	SP	sp	nd	nd	x	-	ccx	ccx	4/60	3/60	25.8	23.8	0.06	0.08	np	np	3	3	H	H	U/BOAG	COM SX
38	Kathammal	66	F	50372	as	as	sh	nd	x-n	-	hmc	cc	pl	6/24	46.4	20.6	0.06	0.22	ars	n	0	3	0.7	0.4	U/USACG	COM SX
38	Ilakkiyammal	65	F	50722	as	as	ppd	nd	x	x	pciol	ccx	6/24	6/24	23.8	23.8	0.04	0.06	n	n	3	3	0.4	0.4	B/BOAG	COM SX
39	Thiruvettai	66	M	322140	as	aS	nd	nd	x	-	ncx	nc	1/60	2/60	25.8	25.8	0.08	0.08	np	np	3	3	h	h	U/BOAG	COM SX
40	Arulpandi	65	M	15404	as	as	ir	nd	x	-	Hmc	cc	hm	6/24	37.2	20.6	0.08	0.20	ars	n	1	3	0.8	0.4	U/USACG	COM SX
41	Iyammal	66	F	25899	as	as	ppd	nd	x	x	pciol	ccx	6/18	6/36	25.8	25.8	0.06	0.06	n	n	3	3	0.4	0.4	B/BOAG	SC
42	Sevali	65	f	119703	cl	cl	ppd	nd	x	x	pciol	ccx	6/24	6/36	23.8	23.8	0.06	0.08	n	n	3	3	0.4	0.4	B/BOAG	SC
43	Angammal	68	f	22900	as	as	ppd	nd	x	x	pciol	ncx	6/24	6/60	25.8	23.8	0.06	0.06	n	n	3	3	0.4	0.4	B/BOAG	SP
44	Pandian	65	M	32942	as	as	nd	nd	x-r	x-r	ncx	nc	1/60	1/60	25.8	25.8	0.06	0.06	np	np	3	3	h	h	U/BOAG	RC/SX
45	Subramani	69	m	339223	as	as	sh	md	x-n	x-n	int	cc	3/60	6/36	17.3	37.2	0.12	0.06	n	ars	3	1	0.4	0.8	B/USACG	SX
46	Vellaisamy	68	m	661233	as	as	ndx	nd	x-n	x-n	ncx	nc	2/60	1/60	25.8	25.8	0.08	0.08	np	np	3	3	h	h	B/BOAG	RC/SX
47	Sanmugam	68	m	3151021	as	as	nd	nd	x	x	nc	nc	6/60	6/36	37.2	37.2	0.08	0.08	ars	ars	3	3	0.8	0.8	B/BOAG	RC/SX
48	Palanisamy	68	m	244552	as	as	nd	nd	x	x	nc	nc	6/60	6/36	37.2	37.2	0.08	0.08	ars	ars	3	3	0.8	0.8	B/BOAG	SX
49	Karupusamy	70	m	47633	as	as	nd	nd	x-n	x-n	ncx	nc	5/60	2/60	23.8	24.8	0.06	0.06	np	np	3	3	h	h	B/BOAG	RCSX
50	Sellappan	70	m	10852	as	as	nd	nd	x	x	Ncx	nc	3/60	5/60	23.8	25.8	0.06	0.08	np	np	3	3	h	h	B/BOAG	RCSX
51	Krishnamoorthy	68	m	46942	as	as	nd	nd	x	x	Ncx	nc	2/60	2/60	25.8	25.8	0.08	0.08	np	np	3	3	h	h	B/BOAG	RCSX
52	Pandy	66	m	42601	as	as	nd	nd	x-n	x	Ncx	mc	1/60	hm	25.8	23.8	0.08	0.08	np	np	3	3	h	h	B/BOAG	RCSX
53	Jayaraman	65	m	73052	as	as	nd	nd	x	x	Ncx	nc	6/60	6/60	23.8	24.8	0.06	0.06	ars	ars	3	3	h	h	B/BOAG	SX
54	Sakthivel	66	m	53598	as	as	nd	nd	x-n	x-n	Ncx	nc	6/36	6/60	25.8	24.8	0.06	0.08	eb	eb	3	3	0.7	0.7	B/BOAG	Sx
55	Karuthapillai	68	m	49292	as	as	nd	ppd	x-n	x-n	Ncx	pciol	6/60	6/24	23.8	25.8	0.08	0.08	ars	ars	3	3	0.7	0.7	B/BOAG	Sx
56	Veeramani	65	m	25139	as	as	ppd	ppd	x	x	Pciol	Pciol	6/80	6/24	30.4	30.4	0.08	0.08	Ars	Ars	3	3	0.7	0.7	B/BOAG	FILSX
57	Arumugam	66	m	25457	as	as	nd	lr	x-n	x-n	Nc	Hnc	6/36	Pl	46.4	46.4	0.06	0.06	Ars	Ars	3	3	0.8	0.8	B/BOAG	SX
58	Alagarsamy	75	m	119470	as	as	nd	nd	-	x	Ncx	Ncx	6/24	6/36	17.3	14.6	0.22	0.22	N	n	3	3	0.3	0.3	U	RR
59	Pandiyan	75	m	320822	Pt	Pt	Nd	Nd	-	X	Ncx	Ncx	6/36	6/24	17.3	17.3	0.24	0.22	N	N	3	3	0.3	0.3	U	
60	Veerapandi	82	M	118825	Pt	Pt	Nd	Nd	-	X	Nc	Ncx	6/60	6/60	17.3	17.3	0.3	0.3	N	N	3	3	0.3	0.3	U	CAT SX

No	Name	Age	Sex	Hosp No	Cornea		A-C		Iris and pupil		Lens		Vision		Tension		Tonography		Field		Gonio		Fundus		Diagnosis	Treatment
					R	L	R	L	R	L	R	L	R	L	R	L	R	L	R	L	R	L	R	L		
61	Suryakannan	94	m	118989	Pt	Pt	Nd	Nd	-	X	Nc	Nc	6/36	6/60	17.3	17.3	0.2	0.2	N	N	3	3	0.3	0.3	U	CAT SX
62	Karuppasamy	85	M	118662	Pt	Pt	Nd	Nd	-	X	Nc	Nc	6/60	6/60	17.3	14.6	0.22	0.3	N	N	3	3	0.3	0.3	U	CAT SX
63	Arulpandi	75	M	118741	Pt	Pt	Nd	Nd	-	X	Ncx	Ncx	5/60	5/60	17.3	17.3	0.2	0.2	Np	Np	3	3	H	H	U	CAT SX
64	china alagan	68	M	118231	As	As	Nd	Nd	-	X	Ncx	Ncx	6/60	6/60	14.6	14.6	0.24	0.24	N	N	3	3	0.3	0.3	U	CAT SX
65	Paramasivam	66	M	322140	As	As	Nd	Nd	-	X	Nc	Nc	6/60	6/36	17.3	14.6	0.22	0.22	N	N	3	3	0.3	0.3	U	CAT SX
66	Ayyavu	50	M	24557	Cl	Cl	Nd	Nd	-	X	Nc	Ncx	6/36	6/36	14.6	14.6	0.24	0.24	n	n	3	3	0.3	0.3	U	CAT SX
67	Karuppiyah	50	M	9219	Cl	Cl	Nd	Nd	-	X	Nc	Ncx	6/24	6/36	14.6	17.3	0.22	0.22	N	N	3	3	0.3	0.3	U	CAT SX
68	Katthavarayan	50	M	8920	Cl	Cl	Nd	Nd	-	X	Nc	Lc	6/36	6/18	17.3	17.3	0.22	0.22	N	N	3	3	0.3	0.3	U	RR
69	Alagappan	50	m	5337	Cl	Cl	Nd	Nd	-	X	Nc	Lc	6/24	6/24	17.3	17.3	0.2	0.2	N	N	3	3	0.3	0.3	U	RR
70	Pandian	94	M	5305	as	as	Nd	Nd	-	X	Nc	Nc	6/60	6/60	17.3	17.3	0.2	0.2	N	N	3	3	0.3	0.3	U	CAT SX
71	Veerananan	81	M	53473	As	As	Nd	Nd	-	X	Nc	lmc	6/60	6/60	17.3	17.3	0.2	0.2	N	N	3	3	0.3	0.3	U	CAT SX
72	Thirumal	50	M	98125	as	as	Nd	Nd	-	X	Nc	Nc	6/60	6/36	14.6	14.6	0.2	0.2	N	N	3	3	0.3	0.3	U	CAT SX
73	Supramani	50	M	52745	Cl	Cl	Nd	Nd	-	X	Nc	Nc	6/36	6/36	14.6	14.6	0.2	0.2	N	N	3	3	0.3	0.3	U	CAT SX
74	Veluchamy	50	M	51675	As	As	Nd	Nd	X	X	Nc	Nc	6/36	6/36	17.3	17.3	0.3	0.3	N	N	3	3	0.3	0.3	U	CAT SX
75	Petchi	60	F	51882	As	As	Ppd	Ppd	X	X	Pciol	Pciol	6/36	6/36	14.6	17.3	0.2	0.2	N	N	3	3	0.3	0.3	B	CAT SX
76	Saroja	55	F	52777	Cl	Cl	Ppd	Nd	X	X	Pciol	Cc	6/36	6/60	14.6	14.6	0.2	0.2	N	N	3	3	0.3	0.3	B	CAT SX
77	Annathal	55	F	135837	As	As	Nd	Nd	X	-	Cl	Cl	6/24	6/24	17.3	17.3	0.2	0.2	N	N	3	3	0.3	0.3	U	RR
78	Muniammal	56	F	135289	As	As	Nd	Nd	X	-	Pciol	Cl	6/24	6/24	17.3	17.3	0.2	0.2	N	N	3	3	0.3	0.3	U	RR
79	Meenakshi	58	F	142586	As	As	Deep	nd	X	-	Aph	Lc	6/36	6/24	14.6	17.3	0.3	0.3	N	N	3	3	0.3	0.3	U	RR
80	Annalakshmi	60	F	143956	As	As	Deep	Nd	X	-	Aph	Cc	6/60	6/36	17.3	17.3	0.2	0.2	N	N	3	3	0.3	0.3	U	CAT SX
81	Mahalakshmi	55	F	146972	As	as	Nd	nd	X	-	Cc	Cc	6/36	6/36	17.3	17.3	0.2	0.2	N	N	3	3	0.3	0.3	U	CAT SX
82	Kanagammal	55	F	15682	Cl	Cl	Nd	Nd	X	-	Cc	lmc	6/36	6/24	17.3	17.3	0.2	0.2	N	N	3	3	0.3	0.3	U	CAT SX
83	Packiyam	62	F	3152	As	As	Nd	Nd	X	-	Cc	Lc	6/36	6/18	14.6	14.6	0.2	0.2	N	N	3	3	0.3	0.3	U	RR
84	Kunjarammal	55	F	59521	As	As	Nd	Nd	X	-	Cl	Lc	6/24	6/36	17.3	17.3	0.2	0.2	N	N	3	3	0.3	0.3	U	CAT SX
85	Sivali	60	F	52578	As	As	Nd	Nd	X	-	Cc	Cc	6/36	6/36	17.3	17.3	0.2	0.2	N	N	3	3	0.3	0.3	U	CAT SX
86	Angammal	60	F	56925	As	As	Nd	Nd	X	-	Ccx	Cc	6/36	6/36	14.6	14.6	0.3	0.3	N	N	3	3	0.3	0.3	U	CAT SX
87	Alagu	60	F	62954	As	As	Nd	Nd	X	-	Cc	Cc	6/60	6/36	17.3	17.3	0.2	0.2	N	N	3	3	0.3	0.3	U	CAT SX
88	Nallammal	60	F	697258	As	As	Nd	Nd	X	-	Cc	Lc	6/36	6/18	17.3	17.3	0.3	0.3	N	N	3	3	0.3	0.3	U	RR
89	Subbammal	60	F	52962	As	As	Nd	Nd	X	-	Cc	Cc	6/36	6/36	14.6	14.6	0.2	0.2	N	N	3	3	0.3	0.3	U	CAT SX
90	Nallammal	55	F	149293	As	As	Nd	Nd	X	-	Cl	Cl	6/24	6/24	14.6	17.3	0.2	0.2	N	N	3	3	0.3	0.3	U	RR
91	Valli	60	F	526927	As	As	Nd	Nd	X	-	Ccx	cc	6/36	6/36	17.3	17.3	0.2	0.2	N	N	3	3	0.3	0.3	U	CAT SX
92	Nachayammal	60	F	57462	As	As	Nd	Nd	X	-	Mc	Cc	Hm	6/36	17.3	17.3	0.3	0.3	Np	N	3	3	H	0.3	U	CAT SX



No	Name	Age	Sex	Hosp No	Cornea		A-C		Iris and pupil		Lens		Vision		Tension		Tonography		Field		Gonio		Fundus		Diagnosis	Treatment
					R	L	R	L	R	L	R	L	R	L	R	L	R	L	R	L	R	L	R	L		
93	Jeyalakshmi	55	F	14346	As	As	Nd	Nd	X	X	Cc	Ccx	6/36	6/36	14.6	14.6	0.3	0.3	N	N	3	3	0.3	0.3	B	RR
94	Chittupillai	60	F	14117	As	As	lr	nd	X	-	Mc	Cc	Pl	6/60	17.3	17.3	0.2	0.2	N	N	3	3	H	H	U	CAT SX
95	Alagu	60	F	13739	As	As	lr	Nd	X	-	Mc	Ccx	Hm	6/60	14.6	14.6	0.3	0.3	N	N	3	3	h	0.3	U	CAT SX
96	Sarasu	60	F	15692	As	As	Nd	Nd	X	-	Ccx	Cc	6/60	6/60	17.3	17.3	0.3	0.3	N	N	3	3	0.3	0.3	U	CAT SX
97	Ayyammal	60	F	45692	As	As	Nd	Nd	X	-	Cc	Cc	6/36	6/36	14.6	14.6	0.2	0.2	N	N	3	3	0.3	0.3	U	CAT SX
98	Ariyanatchi	58	F	153625	As	As	Nd	Nd	X	X	Lc	Lc	6/24	6/24	17.3	17.3	0.2	0.2	N	N	3	3	0.3	0.3	U	RR
99	Ponnuthai	55	F	11725	Cl	Cl	Nd	Nd	X	X	Cc	Cc	6/36	6/36	14.6	14.6	0.2	0.2	N	N	3	3	0.3	0.3	U	RR
100	Mahalashmi	60	F	14526	As	As	Nd	Nd	X	X	Cc	Cc	6/60	6/60	17.3	14.6	0.2	0.2	N	N	3	3	0.3	0.3	U	CAT SX

# KEY TO MASTER CHART

R-Right Eye

L-Left Eye

## Sex

M-Male

F-Female

## Corneal

CL-Clear

AS-Arcus Senilis

Sp-Spheroidal degeneration

X-pseudoexfoliation material

## Anterior Chamber (A.C)

Nd – Normal depth

Sh. Shallow

D-Deep

I- Irregular

PPD – Pseudophakicdepth

X-Pseudoexfoliation material

## Iris & Pupil

X-Pseudoexfoliation material

r-Pupillary ruff defects

n- Non dilatation of the pupil

## Lens

NC – Nuclear cataract

IMC – Immature cataract

MC-Mature cataract

HMC – Hypermature cataract

S-Subluxated

Cl – Clear

## **Gonioscopy**

0,1,2,3 – Shaffer’s grading

X – pseudoexfoliation material

Nv – No view

## **Fields**

N – Normal

Ars – Arcuate Scotoma

Np- Not possible

Tub vn – Tubular vision

## **Fundus**

N-Normal

Nv – No view

## **Diagnosis**

U- Unilateral pseudoexfoliation

B – Bilateral pseudoexfoliation

UOAG- Unilateral open angle glaucoma

BOAG – Bilateral open angle glaucoma

UACG – Unilateral angle closure glaucoma

PACG – Bilateral Primary angle closure glaucoma

SCG – Secondary angle closure glaucoma

## **Treatment**

ST – Sensitive to timolol

PC – Posterior capsular rent

SC – Sensitive to combination

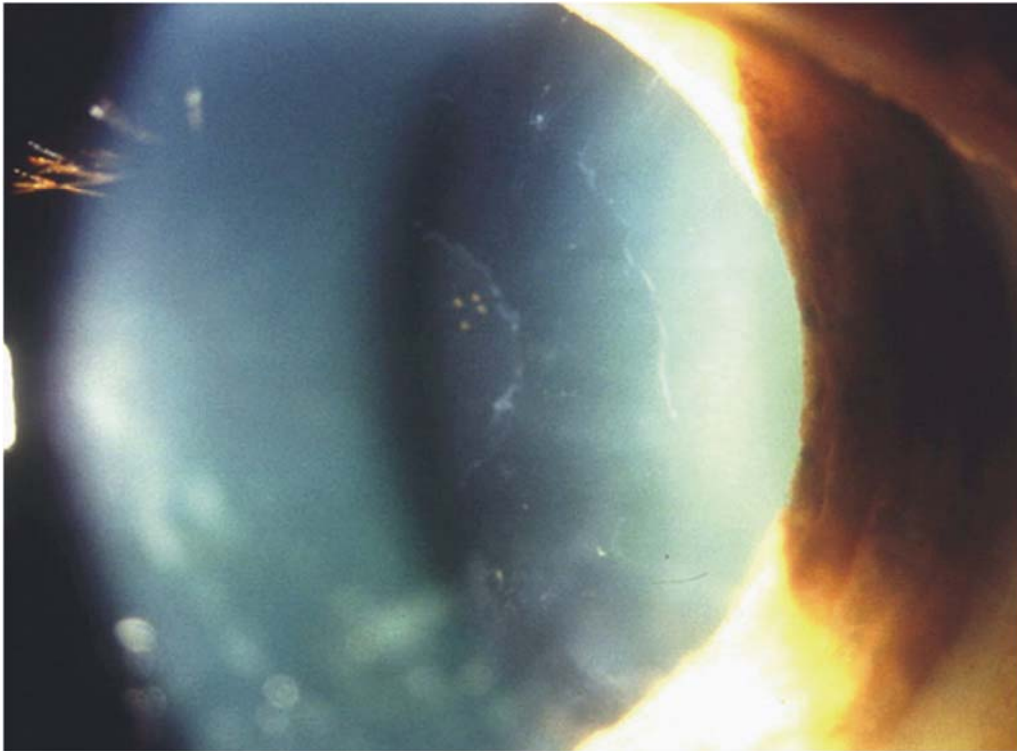
V- Vitreous loss

RC – Resistant to combination

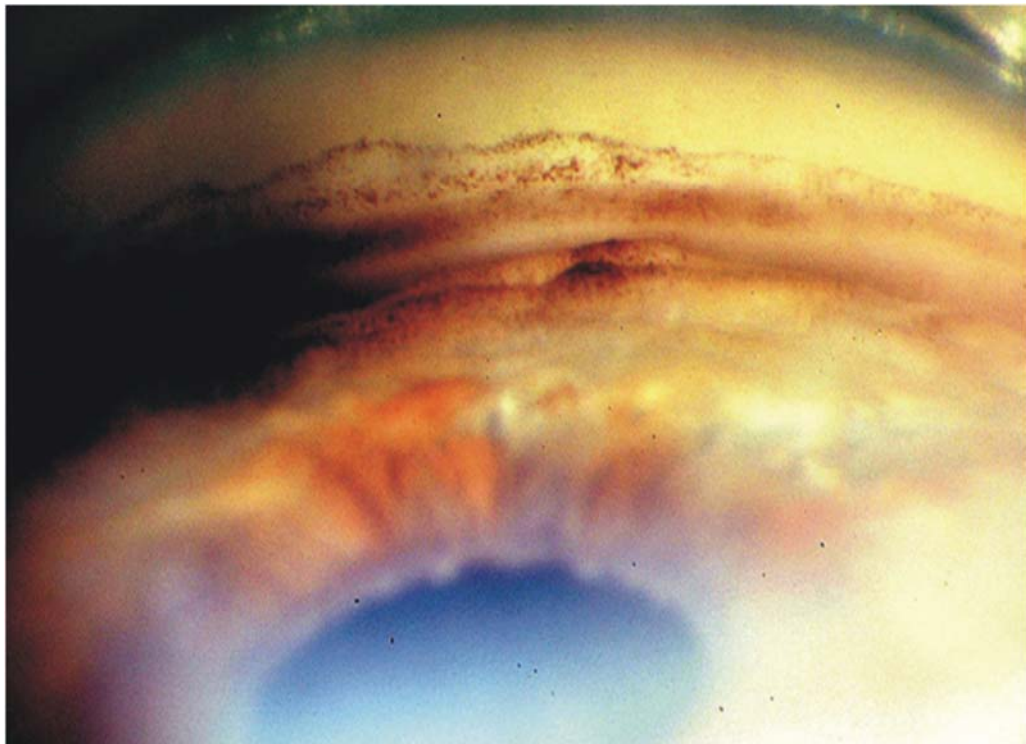
SX – Surgery

SP – Sensitive to pilocarpine

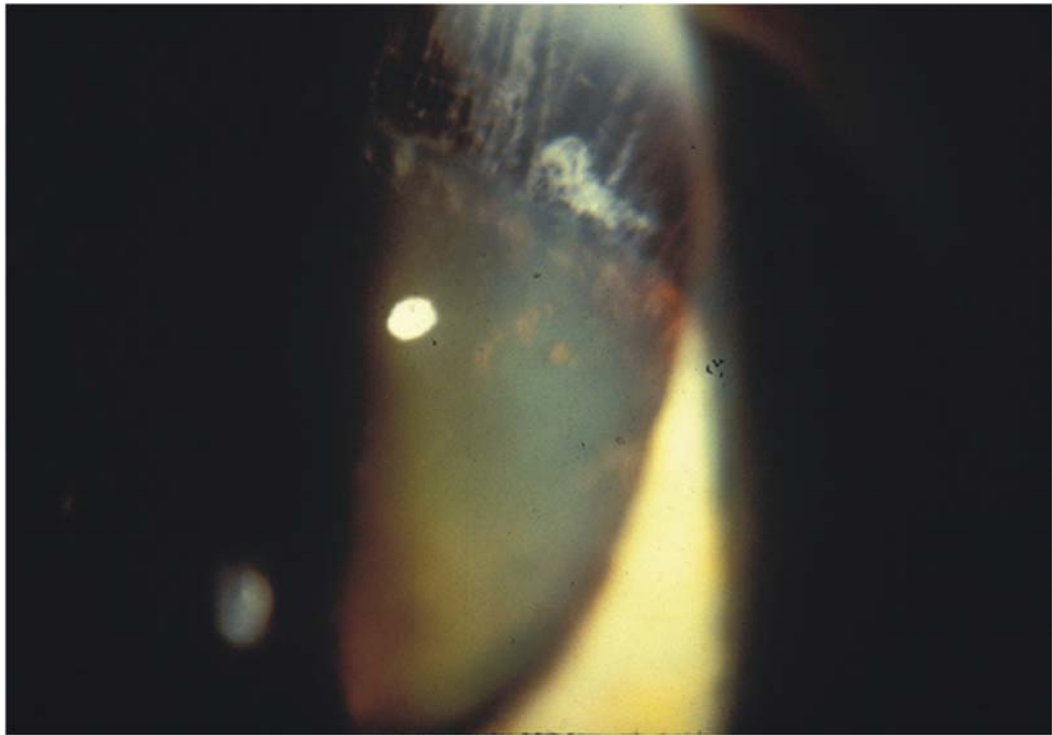
## **PSEUDOEXFOLIATION OF LENS**



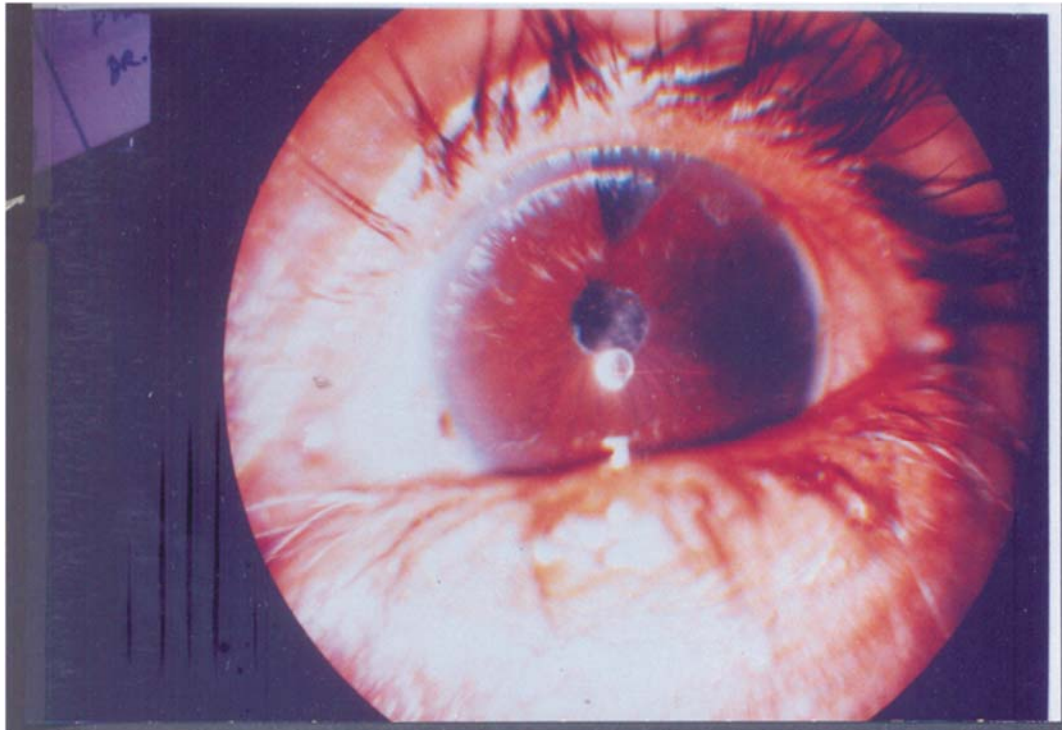
## **HYPERPIGMENTATION IN THE ANGLE**



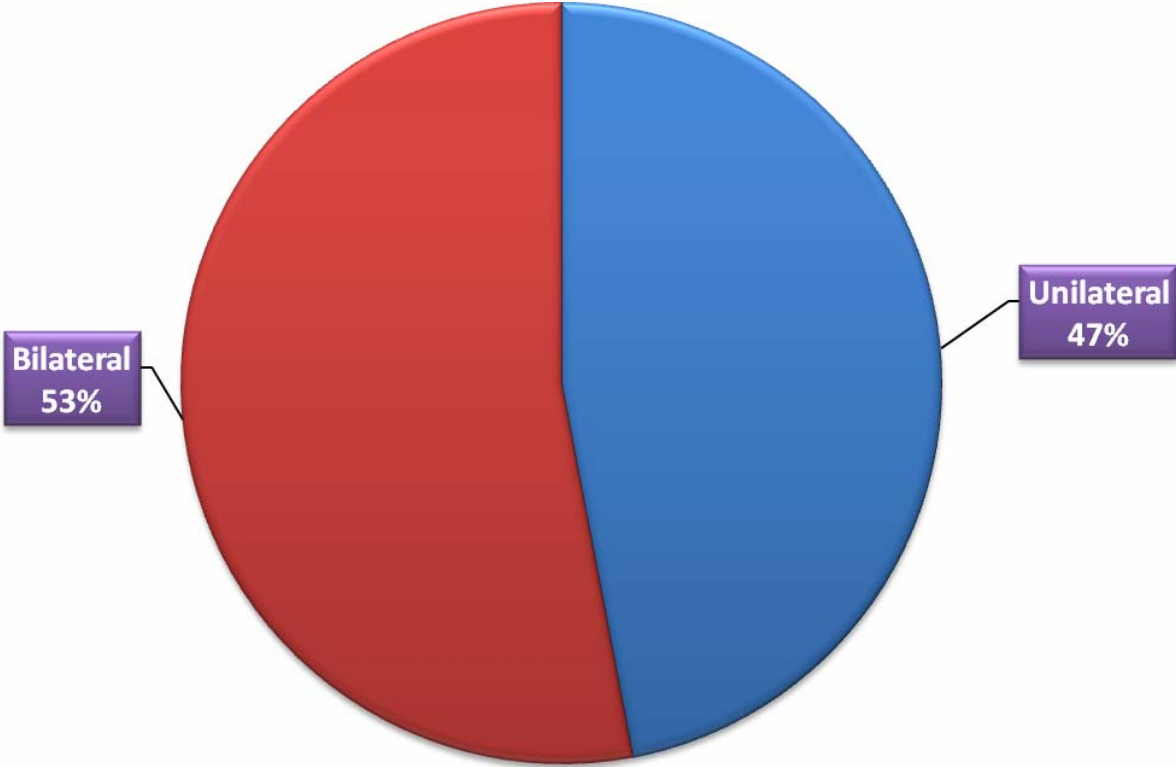
## **SUBLUXATION OF LENS**



## **PSEUDOEXFOLIATION IN APHAKIA**

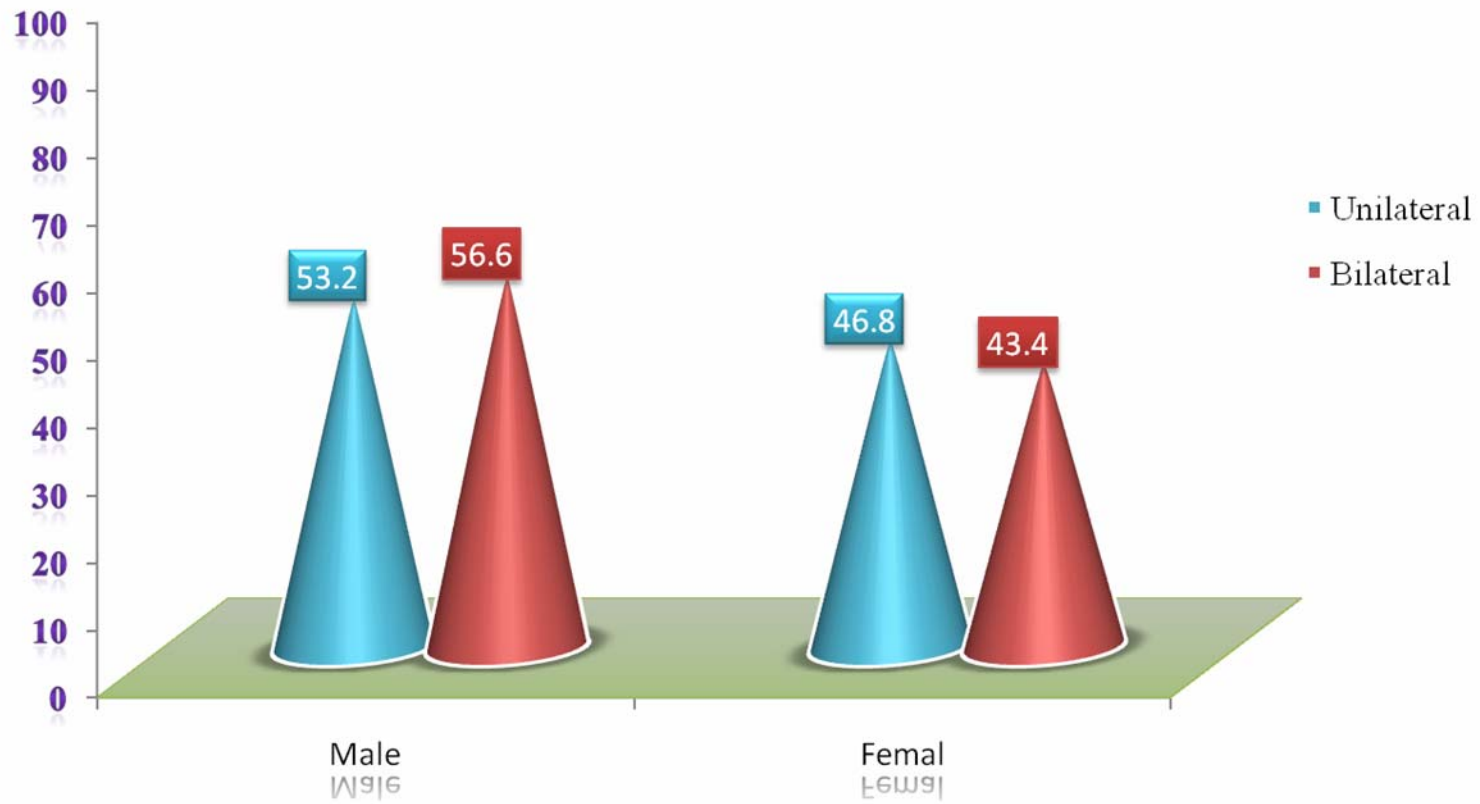


# LATERALITY

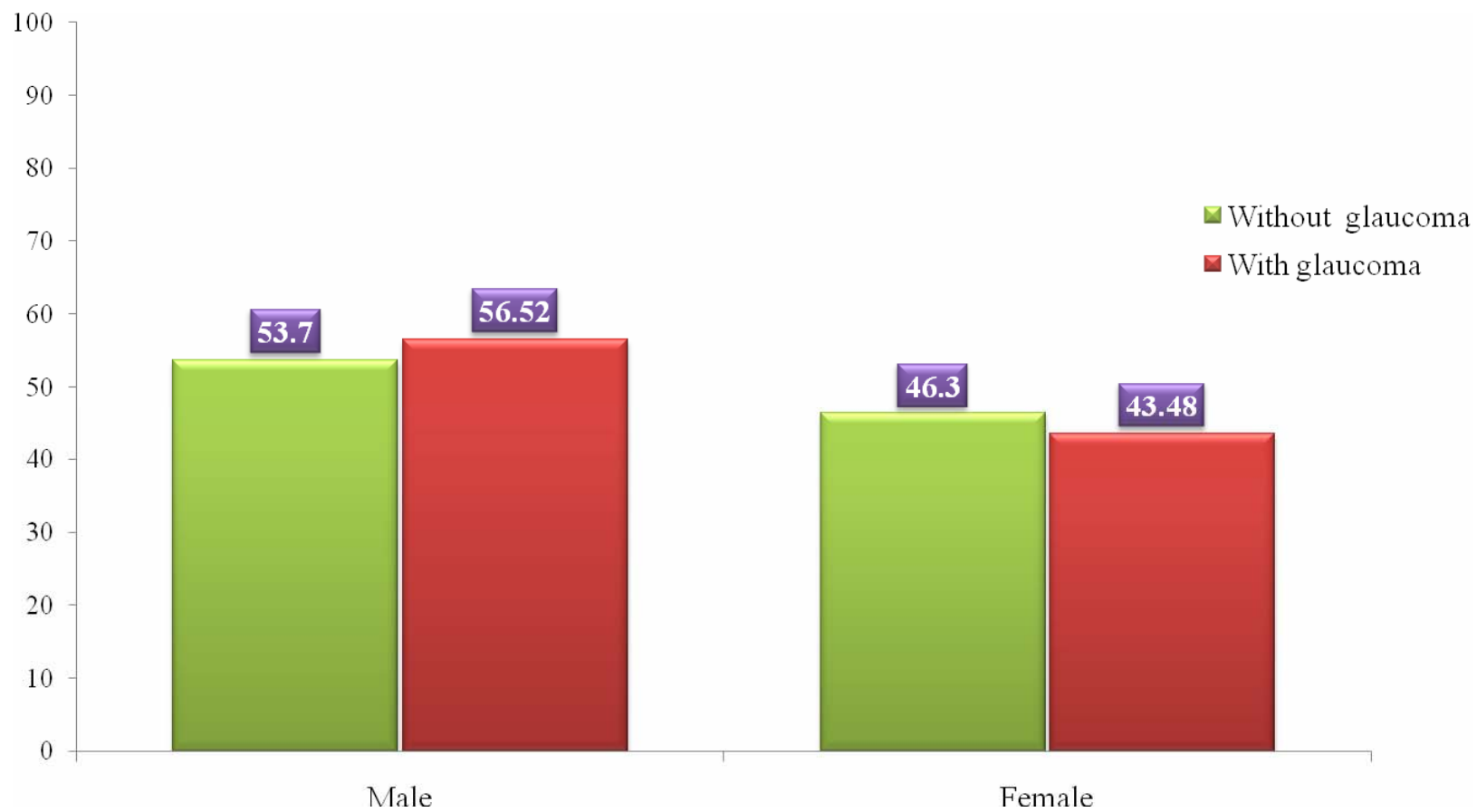




## SEX LATERALITY



## GLAUCOMA ASSOCIATION



# AGE PREVALENCE

