

TO STUDY VERSATILITY OF LATERAL  
SUPRAMALLEOLAR FLAP AS A RECONSTRUCTIVE  
TOOL FOR ANKLE AND FOOT DEFECTS

*Dissertation submitted to*

THE TAMILNADU DR.M.G.R.MEDICAL UNIVERSITY

*In partial fulfillment of the  
regulations for the award of the degree of*

MCH (PLASTIC SURGERY)  
BRANCH III



THE TAMILNADU Dr.M.G.R.MEDICAL UNIVERSITY  
CHENNAI, INDIA

AUGUST 2009

## **DECLARATION**

*I solemnly declare that this dissertation "To study versatility of Lateral supramalleolar flap as a reconstructive tool for ankle and foot defects" was prepared by me in the Department of Plastic, Reconstructive and maxillofacial surgery, Madras Medical College and Government General Hospital, Chennai under the guidance and supervision of professor and HOD Department of Plastic, Reconstructive and maxillofacial surgery, Madras Medical College and Government General Hospital, Chennai between 2006 and 2009.*

*This dissertation is submitted to the TamilNadu Dr. MGR Medical University, Chennai in partial fulfillment of the university requirements for the award of degree of MCh plastic surgery.*

Place : Chennai

Date :

## **ACKNOWLEDGEMENT**

I am thankful to the Dean, Madras Medical College and Government General Hospital, Chennai for permitting me to carry out this study.

I am very grateful to my teacher and guide Professor K.V.Alalasundaram M.S.,MCh., Professor and HOD, Plastic, Reconstructive and maxillofacial surgery, Madras Medical College and Government General Hospital, Chennai for his expert guidance and help without which this study would not have been possible. I would also extend my gratitude to Prof. V.Jayaraman and Prof.Palanivelu, Department of Plastic, Reconstructive and maxillofacial surgery.

I sincerely thank Dr. Anand Subramaniam(Reader), Dr.K.Gopalakrishnan(Reader), Dr.Jayavel Rajkumar, Dr.T.M.Balakrishnan, Dr. Udesh Ganapathy and Dr.Sridevi (Assistant professors) Madras Medical College who gave me

encouragement and moral support for completion of this study.

I thank the postgraduates and staff of the department of plastic surgery, Madras Medical College and Government General Hospital, Chennai for their help and constant support. Last but not least I thank all my patients without whose co-operation this study would not have been possible.

## **INDEX OF CONTENTS**

<b>S.No</b>	<b>TITLE</b>	<b>PAGE</b>
1.	INTRODUCTION	
2.	AIMS AND OBJECTIVES	
3.	MATERIALS AND METHODS	
4.	REVIEW OF LITERATURE	
5.	OBSERVATIONS AND RESULTS	
6.	DISCUSSION	
7.	CONCLUSION	
8.	BIBLIOGRAPHY	

## Appendix

## **INTRODUCTION**

Reconstruction of soft tissue defects in ankle and foot is challenging because of more bony prominences and easy exposure of tendons, nerves and vessels. Use of skin graft to cover these sites is of not ideal choice because more morbidity results due to cover of mobile structures thereby the function is also impaired. Hence use of fasciocutaneous flaps to cover these sites brings in a better vascularity to the site and thereby provides a stable cover to the vital structures.

The lateral supramalleolar flaps have been used in the past two decades as fasciocutaneous flaps for reconstruction of ankle and foot defects. Even though free flaps are a option for reconstruction of such defects, the expertise and facilities for microsurgery are not available everywhere.

Local flaps also provide better colour match.

Advantages of fasciocutaneous flaps are ease of elevation, less bulk, high reliability, easier transfer in comparison with muscle of musculocutaneous flaps.

Lateral Supramalleolar flaps are fasciocutaneous flaps, alternative to free flaps for reconstruction of ankle and foot defects.

As a rotation flap it can also be used for reconstruction for defects in medial aspect of distal third leg also Proximally based flaps are used to reconstructive defects around ankle.

Distally based flaps are used to reconstruct whole of dorsum of foot, medial and lateral arches of foot or the heel region.

It is also useful to cover defects of stump resulting from transmetatarsal amputations.

Donor site is covered by split skin grafts.



The lateral supramalleolar flaps can be used as a sensory flap by suturing superficial peroneal nerve to a nerve at the recipient site.

It is not useful for reconstruction of defects in weight bearing regions.

The anastomosis in and around the regions of lateral malleolus is useful in raising this fasciocutaneous flap which can be based either proximally or distally.

This cadaveric and clinical study is aimed to establish the reliability and versatility of this flap.

## **AIMS AND OBJECTIVES**

The aim of this study is to evaluate the usefulness of anastomosis around the lateral malleolar region in raising a fasciocutaneous flap for soft tissue reconstruction of ankle and foot defects and to ascertain the dimensions in raising a flap within the safe limits.

## **MATERIALS AND METHODS**

### **AIM OF THE STUDY**

Using Lateral supramalleolar flap as a versatile reconstructive tool for defects in ankle and foot.

Duration of the study:

September 2006-April 2009

### **VENUE OF THE STUDY**

Department of Plastic, Reconstructive, Maxillofacial surgery, Madras Medical college, Government General Hospital and Department of Anatomy, Madras Medical College.

### **PATIENT SELECTION CRITERIA**

- 1) 20 in number
- 2) Patients with defects in ankle and foot regions .

- 3) No exclusion criteria.
- 4) Pre-operative Doppler study was done with 8MHz hand held Doppler.

## **METHOD OF THE STUDY**

After measuring the exact defect size, planning of Lateral Supramalleolar flap is done. The flap is raised from lateral aspect of lower leg . It is based on the Peroneal artery perforator communicating to the lateral malleolar artery anterior branch as a proximally based flap or as a distally based flap based on the communications of lateral tarsal artery at the level of sinus tarsi. Based on the site and the size of required flap it is based either proximally or distally. Dissection is proceeded from leg to foot. The superficial peroneal nerve along with the superficial peroneal nerve artery which is a branch of anterior tibial artery is included in all the flaps. This flap is a neurocutaneous flap with the

inclusion of superficial peroneal nerve . It is also a reverse flow flap.

Measurements were made with digital calipers and scales. Patterns were cut. Planning in reverse were also done to take required length of pedicle. Digital photography were taken.

Cadaver dissections were done in which the peroneal artery perforators and the communications with anterior lateral malleolar artery and communications at the level of sinus tarsi with lateral tarsal artery were confirmed.

## **REVIEW OF LITERATURE**

At the beginning of the 1920s all the concepts, anatomical knowledge and technical abilities were sufficiently established to make possible flap surgery and even the free vascular flap as we know it now. The principal obstacle to development was the dogma of the never-to-be-exceeded length/breadth ratio of 1:1. Advances took place in the early 1980s, first, a Chinese military surgeon, Yang Kuofan, elevated a skin flap based on a main artery which is not the vascular axis of the flap (the radial forearm flap). 'thus a new type of vascularization of the skin was defined and characterized by the septal arteries.

Second, in 1981, Ponten from England demonstrated empirically the survival of a pedicled flap taken from the leg with a length/breadth ratio of 4:1 when the skin is elevated with the subcutaneous tissue and the fascia en bloc. Ponten, at

that time, did not explain the basis of this technique, but clearly emphasized the role of the fascia.

Third, in 1982, Chinese authors took a new step in proposing the distally based pedicled island flap, which seemed extravagant as it defied Harvey's law for the venous return.

All these new discoveries stimulated in the 1980s the interest in anatomy in order to find new applications and undescribed flaps. Next, secondary vascular axes, such as the interosseous arteries of the forearm, intermetacarpal arteries of the hand or ramus perforans of the peroneal artery at the ankle, may be utilized to design large flaps. The reverse-flow phenomenon and the presence of intervening joints, which are variable vascular anatomical crossroads, permit at every level of each limb the elevation of island flaps with a reversed pedicle or peninsular flap with a distal skin hinge.

The venous drainage is thus obtained by a reverse venous flow through the valves. The venous blood flow, beyond the point of rotation of the pedicle, runs again in a physiological direction. Blood should pass from the venae comitantes to a non-dissected vein (normal venous flow). This passage is often made through a short segment which links the venae comitantes and a superficial vein. Sometimes a competent valve exists in the communicating segment and impedes a normal return of the reverse flow. This is probably the explanation for some cases of venous congestion which are observed without technical error.

Lateral supramalleolar flap is based on the perforating branch of peroneal artery. The peroneal artery runs with the flexor hallucis longus muscle in posterior compartment; it enters the anterior compartment of leg by piercing the interosseous membrane between tibia and fibula 5-7 cm above the ankle joint. At its emergence, the perforating branch of the artery gives a relatively constant skin perforator which



supplies a large area on the lateral aspect of distal 1/3 of leg. This supramalleolar flap is based on this branch. Yoshimura was first to describe the proximally and distally based peroneal island flap in 1985 based on sacrifice of peroneal artery.

Masquelet<sup>2</sup> in 1988 described the lateral supramalleolar fasciocutaneous flap based on cadaveric and patient study. Without compromise to the major blood vessels of the foot including the peroneal artery, this flap has proved to be a reliable fasciocutaneous flap for the loco regional coverage of distal third of the leg, ankle, perimalleolar region, dorsum and plantar aspect of foot,<sup>2-5</sup> except weight bearing region of heel,<sup>3-6</sup> as the flap is insensate and relatively thin. The pedicle of the flap is long ,8.0 cm in rotation flaps to 15 cm in distally based flaps with compound pedicle<sup>4</sup> and the pivot point of pedicle is sinus tarsi which increases the arc of rotation. The flap is most commonly employed as distally based pedicle island flap. The potential problems of the flap<sup>2</sup> include some amount of venous

congestion in reversed island flaps and anatomic vascular variations<sup>2,7,8</sup>. The usefulness of lateral supramalleolar flap has been demonstrated by its use as a delay flap for tendoachilles<sup>9</sup> coverage in difficult situations like Werner's syndrome, coverage of ischemic ulcer in Buerger's disease,<sup>7</sup> and limb reconstruction.<sup>8</sup> Certain anatomic variations of the flap include the inconstant but frequent presence of a proximal inferolateral collateral artery,<sup>7</sup> presence of the anterior peroneal artery, presence of a vascular network instead of a well defined artery, absence of perforating branch of the peroneal artery<sup>7</sup> and the basis of cutaneous circulation solely on anterior tibial perforators.

Flap delay has evolved over years subsequent to better understanding of vascular anatomy of flaps<sup>10,11</sup>. The application of surgical delay in flap surgery is multifold. It can be used to define the survival length of an unknown flap, to improve circulation in a known flap or to increase the viable length of a known flap by strategic division of vessels along

the flap axis, reversed pedicle or peninsular flap with a distal skin hinge.

Finally, pedicle flaps may be developed that are drained or fed by a superficial vein or a superficial sensitive nerve. These techniques, whose applications are still relatively untested, are the basis of continuing controversies concerning the physiology of flaps.

## **RECONSTRUCTION OF ANKLE AND FOOT DEFECTS**

### **LATERAL CALCANEAL ARTERY SKIN FLAP**

It is axial pattern flap with lateral calcaneal artery ; lesser saphenous vein and sural nerve. Lateral calcaneal artery is constant terminal branch of peroneal artery but occasionally can present as a branch of posterior tibial artery also. This artery is paralalled by pair of small veins. From here artery descends into deeper plane lie over extensor retinaculum covering peroneus longus and peroneus brevis tendons. Artery bifurcates toward planter surface of heel and head of fifth metatarsal. Sural nerve is anterior to the artery and parallels it and lies within 10mm of the artery.

Proximal 8cm of flap that is vertical distance between lateral malleolus and plantar surface of heel is completely axial. The flap can be extended upto 6cm more distally

including a random portion proximal to base of fifth metatarsal.

The course of calcaneal artery is marked on the skin. Length and width of flap are planned in reverse. The pedicle of flap is above the level of lateral malleolus. Base of flap should be atleast 4cm wide. Flap can be raised as island but damage to short saphenous vein during rotation must be prevented.

When large flap to cover plantar heel is required, random area in base of fifth metatarsal is also dissected. Useful in diabetics as these vessels not affected by diabetic arteriosclerosis.

### **PLANTAR ARTERY - SKIN FASCIA FLAP**

Useful in reconstruction of plantar surface of foot. Incorporation of nerves maintain the sensation. Proximally

based flap for defects in plantar aspect of calcaneus, posterior surface of calcaneum, insertion of Achilles tendon.

Distally based flap to cover defects over metatarsal head region.

Posterior tibial artery divides as lateral and medial plantar artery and calcaneal artery. The lateral plantar artery crosses the foot in plane between flexor digitorum brevis and quadratus plantae, in central third of foot it turns medially passing deep to adductor hallucis muscle to form plantar arch. Connections between deep plantar artery and medial plantar artery with plantar arch is common. Common digital arteries originate from plantar arch and supply the toes.

Medial plantar artery courses superficial to quadratus plantae and deep to abductor hallucis and flexor digitorum brevis muscles. After connecting with plantar arch, it terminates in big toe. The calcaneal artery perforates flexor

digitorum brevis and plantar fascia near their origin from the os calcis, it pass posteriorly, supply weight bearing calcaneal skin.

### **PROXIMALLY BASED FLAP**

Lateral plantar artery divides proximal to plantar arch. Flexor digitorum brevis and plantar fascia are divided proximally from calcaneus and distally at level of skin incision, which is located just proximal to metatarsal head weight bearing region. Donar site closed with SSG.

### **DISTALLY BASED FLAP**

Lateral plantar artery is divided just anterior to calcaneus. Lateral plantar nerve is left in situ. The flexor digitorum brevis muscle and plantar fascia are divided as before.

Proximally based is a neuro sensate flap but not distally based flap.

## **DORSALIS PEDIS FLAP**

Flap consists of skin, subcutaneous tissue and most superficial layer of fascia of dorsum of foot supplied by dorsalis pedis artery through its subcutaneous branches between first and second toe long tendons. Sensations through superficial and deep peroneal nerve.

Used to cover defects of medial, lateral foot, front, both sides of ankle, both malleoli.

## **DISADVANTAGE**

Difficult and tedious dissection, easy to dissect the flap from its artery, sensory deficit of entire dorsum of foot. SSG cover to donor site.

If foot is not supplied by posterior Tibial and dorsalis pedis arteries, flap should not be used.



Dorsalis pedis artery(DPA) is extension of anterior tibial artery, enters foot beneath extensor retinaculum of ankle where it lies on tarsal bones from proximal to distal in tarsal region it gives of lateral tarsal, medial tarsal, arcuate artery at tarsometatarsal level. All these branches are deep to extensor tendons of the foot and can't be elevated with the flap. As they reach first intermetatarsal space it dips plantarward through interosseous muscle to join the plantar arch and gives off its terminal branch the first dorsal metatarsal artery (FDMA). In 80% cases FDMA lie superficial or just within first dorsal interosseous muscle but 20% lie deep in intermetatarsal space.

Venous drainage through, long, short saphenous veins formed from dorsal venous arch. First web space supplied by Deep peroneal nerve and remaining dorsum of foot by superficial peroneal nerve.

Pulsation of dorsalis pedis artery may be transmitted distally through plantar arch anastomosis so occlude posterior tibial artery and check for dorsalis pedis artery pulsations.

The connection between dorsalis pedis artery and subcutaneous tissues is not firmly adherent hence there is more possibility of flap getting detached. Flap is elevated from distal, medial aspect to proximal aspect. The first dorsal metatarsal artery is included with flap and dissected proximally. The dorsalis pedis flap can be raised from web spaces to extensor retinaculum and across entire breadth of the dorsum of the foot mostly centering the dorsalis pedis artery pedicle. For lateral surfaces of dorsum of foot to be included in the flap a prior delay of the flap is necessary.

Flap can be raised as island flap tunneled under a skin bridge and cover defects around ankle.

## **DORSALIS PEDIS MYOFASCIAL FLAP**

Composed of deep fascia of dorsum of foot and underlying extensor digitorum brevis muscle. Safe local flap with minimal donor site morbidity. Useful in defects in lower half of leg and malleolar region. Donor site closed primarily. Patency of anterior and posterior tibial vessels is mandatory before flap harvest. Extensor digitorum brevis muscle included in the flap is elevated from distal to proximal, ligating deep and side branches of dorsalis pedis artery. If flap to be extended to lower leg, extensor retinaculum must be cut. Flap spread over the defect and covered with skin graft. Donor site closed primarily.

## **MEDIALIS PEDIS FLAP**

Fasciocutaneous flap based on Medial plantar artery. Useful to cover tip of medial malleolus, area of insertion of Achilles tendon, defects of medial aspect of heel.

## DISADVANTAGE

*Non sensate*

*Donor site - skin grafting*

Medial plantar artery divides into superficial and deep branches, the former emerges from septum between abductor hallucis and Flexor digitorum brevis muscle. It gives off 2-4 cutaneous branches for plantar arch and constitutes arterial axis of medial plantar artery flap. Deep branches divides as lateral and medial aspect. Lateral penetrates sole of foot and anastomose with deep plantar arch, medial once reach base of first metatarsal to anastomose with first plantar metatarsal artery.

The medial branches crosses terminal part of tibialis posterior tendon on which it lies just behind navicular tuberosity. It takes oblique course parallel to medial aspect of foot. At distal end of tibialis posterior tendon, artery gives

cutaneous branches from navicular bone to mid shaft of first metatarsal which is territory of medialis pedis flap.

Flap is raised from plantar to dorsal, posterior to anterior abductor hallucis muscle is retracted. Release of the pedicle → ligation of deep and superficial branches of medial plantar artery distal to cutaneous branches supply the flap. Pedicle is dissected upto posterior tibial artery. Donor site is covered with skin graft.

### **EXTENSOR DIGITORUM BREVIS MUSCLE FLAP**

The extensor digitorum brevis muscle may be transposed proximally to cover the ankle, the dorsal foot and malleolar wounds, provided the anterior tibial-dorsalis pedis artery has antegrade blood flow. The blood supply to the muscle is derived from the lateral tarsal artery, which is a branch of the dorsalis pedis artery at the level of the distal edge of the extensor retinaculum. Exposure is obtained through a curvilinear incision on the foot dorsum that communicates

with the wound to be closed. The entire dorsalis pedis pedicle is divided distally to the origin of the lateral tarsal vessel to provide the needed arc of rotation for muscle transposition. The long extensors are dissected off the underlying short extensor muscle slips, and then the dorsalis pedis artery and its associated veins are divided distal to the extensor digitorum brevis. The medial tarsal branches are ligated as the dissection proceeds proximally. The lateral tarsal vessels are elevated with the muscle while the origin and tendinous extensions of the muscle are divided. The four slips of the muscle are broad and thin, measuring 4.5\*6cm in the adult, making the flap useful for relatively small wounds.

## **ABDUCTOR DIGITI MINIMI MUSCLE FLAP**

Used to cover defects of heel, lateral surface of ankle and lower leg originates from calcaneum and as a narrow tendon inserts near base of fifth metatarsal extension lateral side of proximal phalanx of little toe in common with flexor digiti minimi brevis.

Neurovascular bundle close to origin. Muscle detached from insertion, dissected proximally. Origin can also be detached based on pedicle can be used to cover the defects.

## **ABDUCTOR HALLUCIS BREVIS MUSCLE FLAP**

Used to cover defects over heel and medial aspect of ankle joint and medial malleolus, dorsum of foot. Originates from calcaneus and insert into medial side of proximal

phalanx of big toe. Neurovascular supply from medial plantar nerve and vessels.

Muscle is detached at insertion and rotated to fill the defect donor site closed primarily.

Flexor Digitorum Brevis, Flexor Hallucis brevis, extensor digitorum brevis muscles can also be used to cover defects around ankle and foot.

Local fasciocutaneous flaps for reconstruction of dorsal foot and ankle regions:

The deep fascia of the dorsum of the foot, not thick as the crural fascia is a distinct layer except at the ankle where it tends to blend with the extensor retinaculum. All three major arteries nourishes these fascia with the perforators. The posterior tibial vessels dominate in their supply to the posteromedial ankle and foot. The peroneal supply the posterolateral region and the central portion by the anterior



tibial vessels, the terminating dorsalis pedis and the first dorsal metatarsal arteries.

#### Flap Design:

A length:width ratio not exceeding 1.8:1 allows undelayed flap transfer, without risk of necrosis. The flap should be chosen such that it includes the perforator with it at its base. When based proximally, the flap will be potentially sensate and a subcutaneous vein can be included for better venous drainage. The extensor retinaculum must be kept with the deep fascia at the ankle area, to avoid injuring the fascial plane. This may not be an option in patients with compromised vascularity. In these cases, a vertical or horizontal bipedicle flap to maximize the number of perforators may at the expense of less freedom in flap mobility.

#### Operative Technique:

Once the boundaries have been marked, the margin furthest from the flap base should be raised first to identify the plane under the deep fascia. Rapid and bloodless dissection toward the flap pedicle should follow until inset without tension is possible. A small backcut in the deep fascia, avoiding any vascular structures, can facilitate this. Paratenon, if exposed, is carefully preserved, or tendons are buried under adjacent soft tissue to enhance the take of a skin graft, invariably required to close the donor site. Postoperative immobilization and bedrest are obviously important to ensure healing .

To summarise, a random local, fasciocutaneous flap from the dorsum of the foot or ankle can often solve the problem of covering small defects, without resorting to a free flap.

***Distant flaps:-*** Reverse Sural artery based flaps

Inferiorly based Fasciocutaneous flaps

### **REVERSE SURAL ARTERY BASED FLAP**

Used to cover defect of ankle, dorsum and heel of foot. Based on reverse flow in median sural artery running with sural nerve, communicating with peroneal artery perforators at about 5cm and 10cm between lateral malleolus and Tendo Achilles. The pedicle is islanded and tunneled to cover the defect donor site covered with skin graft maximum limit upto junction of upper one-third to lower two-third of calf region. Larger size flaps can also be raised but prior delay is required.

### **INFERIORLY BASED FASCIOCUTANEOUS FLAP**

Used to cover defects around ankle and dorsum of foot.

Based on perforators along posterior tibial vessels in medial aspect of leg. Upper limit is upto 10cm below popliteal crease . Posterior tibial artery perforator lies 2cm from medial border of tibia at 7cm and 10cm levels based on these

perforators flap is raised but the arc of rotation of this flap limits the area of defect coverage.

## **MICROVASCULAR FREE TISSUE TRANSFER**

The microvascular free tissue transfer has broken all limitations of size, quality and availability of donor tissue. It is a single staged procedure. The limitations are technical training required for microsurgery, long duration of the procedure, and the costs involved. Free flaps useful for covering the soft tissue defects at the site of the foot . The use of the muscle flap brings better vascularity thereby better wound healing and protection of the exposed bone. The use of neurosensate free flaps have revolutionized reconstruction of the weight bearing regions of the foot. By proper education of the patients the recurrence of any ulcers at the sites of weight bearing regions can be avoided.

## THE FOLLOWING OPTIONS ARE AVAILABLE

- 1) *Anterolateral thigh flap*: Larger size flaps can be raised to cover defects in leg and foot. The disadvantage is bulk in the flap however it can be thinned before transfer. Donor site closure is done primarily in a small flap but for a larger one split skin grafting is required.
- 2) *Scapular / Parascapular flaps*: Thin flaps can be harvested, ideal for reconstruction of dorsum of foot defects. Disadvantage of change of position of the patient is required for this flap
- 3) *Free groin flap*: Thin flap, large size can be harvested
- 4) *Lateral arm flap*: Thin flap useful for smaller defects, donor site can be closed primarily.

Various other free flaps are available, mainly depends on the expertise of the surgeon.

## **VASCULAR ANATOMY OF LATERAL SUPRAMALLEOLAR FLAPS**

The vascular supply to Lateral Supramalleolar flap is provided by anastomotic arcade of the ankle. The key anatomic vascular structure is the perforating branch of the peroneal artery, which pierces the interosseous membrane at the distal tibiofibular angle, just proximal to the anterior tibiofibular ligament. It anastomosed at a variable level with the anterior lateral malleolar artery arising from the anterior tibial artery, courses on the anterior tibiofibular ligament, and then descends to the level of the sinus tarsi, where it anastomoses with the lateral tarsal artery and branches issuing from the lateral plantar artery. Between its emergence from the interosseous membrane and tibiofibular ligament, the perforating artery gives off one or two ascending branches to

the skin of the distal half of the lateral aspect of the leg, which constitutes the territory of the flap.

The perforating branch of the peroneal artery is accompanied by small venae comitantes. The branch is sometimes very large and in some cases, may replace the distal part of the anterior tibial artery. In other rare cases, the perforating branch anastomoses with the anterior tibial artery that courses on the anterior tibiofibular ligament.

The cutaneous branches issuing from the perforating branch run anteriorly to the fibula and anastomose with the vascular network that accompanies the superficial peroneal nerve which is a branch of anterior tibial artery. This enters the subcutaneous tissue at the junction of the middle and distal thirds of the leg, and divides into medial and lateral branches at the level of the ankle joint.

Beyond the level of anastomosis of anterior division of lateral malleolar artery to the peroneal artery perforator, the artery runs below the extensor retinaculum and then the extensor digitorum brevis muscle in the ankle region. At the level of sinus tarsi, it anastomoses with lateral tarsal artery, a branch from dorsalis pedis artery and with branches from lateral plantar artery.

These constant anatomic considerations allows various flaps to be raised. Based on the emergence of the branch through the interosseous membrane-Ramus perforans, a rotation flap can be raised to cover defects of lower leg defects. But the rotation cannot exceed 90 degrees. A proximally based pedicled flap is based on the anterior lateral malleolar artery, the perforator branch is ligated and severed just proximal to the cutaneous branches to the flap, and just distal to the anastomosis with the anterior lateral malleolar artery. In this case, the flap is supplied by the anterior lateral malleolar



artery and through the skin branches issuing from the perforating branch.

A distally based island pedicled flap is based on the perforating branch, which is ligated and divided just proximal to the cutaneous branch, and released as far as the sinus tarsi that constitutes the pivot point of the pedicle. The length of the pedicle is approximately 7 cm, the venae comitantes are sufficient to ensure venous return. When the perforating branch is interrupted in its course distal to the cutaneous branch to the flap, the skin paddle is designed proximally on the lower half of the leg, and the flap is supplied by a subcutaneous fascial pedicle.

A subcutaneous fascial pedicle in continuity with the vascular axis of the perforating branch, until it reaches the sinus tarsi is useful in raising a distally based fasciocutaneous flap. The pedicle length is approximately 15 cm. This flap survives on the anastomosis around the sinus tarsi level with

the lateral tarsal artery which is a branch of the dorsalis pedis artery. Since this anastomosis is closely related to the periosteum of the bone the dissection is proceeded subperiosteally from the level inferior tibiofibular ligament to avoid damage to the pedicle thereby increasing the length of the pedicle. To avoid compression on the pedicle the extensor retinaculum is divided and the extensor digitorum muscle is also divided to mobilise the pedicle to the level of sinus tarsi.

In a variation of the lateral supramalleolar flap, the flap can be raised as a fascial flap without the skin and can be turned over to cover the defects of the lateral malleolus provided the ramus perforans is intact. The raw area is covered with skin graft.

## **PROCEDURE OF RAISING THE FLAP**

- Dimensions of the skin defect in ankle or foot are recorded.

- A handheld Doppler ultrasound scanner is used to locate the Ramus perforans and the perforating branch at the sinus tarsi level.
- Tourniquet is applied.
- Patient in supine position and sandbag under the ipsilateral buttock.
- In distally based pedicled flap, the incision is marked anterior to lateral malleolus and reaches the depression of the sinus tarsi on the lateral aspect of the hindfoot.
- The skin, including the fascia is incised in continuity, along the anterior margin of the flap, and anterior to lateral malleolus.
- Posterior hinge is maintained.

- The pedicle is first exposed, lying deep to the extensor retinaculum, which is incised.
- The muscles of extensor compartment are gently retracted, exposing the lower part of the tibiofibular space, in order to identify the vascular structure, chiefly, the cutaneous branch to the flap.
- The perforating branch is ligated and severed just proximal to the cutaneous branch.
- The anastomosis with the anterior lateral malleolar artery is ligated and divided.
- The posterior margin of the flap is incised, including the fascia.
- The superficial peroneal nerve is severed proximally and its proximal end is buried in the muscles.

- The fascial septum attached to fibula is released from proximal to distal.
- At the level of the course of the cutaneous branch to the flap, the septum is subperiosteally released to protect the supplying branches.
- The pedicle is isolated with its surrounding loose areolar tissue, until it reaches the sinus tarsi.
- The posterior edge of the fascia of the extensor digitorum brevis muscle should be divided, in order to avoid compression of the pedicle when it is turned.
- Closure of the donor site by suturing peroneal and extensor muscles together .
- A split skin graft is applied.

- A distally- based island flap with subcutaneous fascial pedicle is useful when the perforating artery is viable at its emergence, but is interrupted distally.
- The subcutaneous fascial pedicle is subdermally dissected to 2cm in width.
- If perforating artery is viable until the sinus tarsi, it can be dissected in continuity with the subcutaneous fascial pedicle.
- A proximally-based island flap can be raised when the defect is around the ankle joint. The flap can be raised on the anterior lateral malleolar artery.

#### **V-Y BAUDET PRINCIPLE:**

This principle is useful in obtaining a lengthy pedicle so that the flap can be useful to cover defects even in the dorsum of the toes (Distally based lateral supramalleolar flap).

The Ramus perforans is ligated at the site of entry from the interosseous membrane between the tibia and fibula , by doing so the pedicle of the flap can be lengthened upto sinus tarsi level and basing the flap on the anastomosis with the lateral tarsal artery which is a branch from the dorsalis pedis artery.

## **FLAP DESIGN**

The boundries of the largest flap are proximally, the middle of the leg, anteriorly, the crest of the tibia, posteriorly the fibula, and distally the emergence of the perforating branch. The design of the flap should always include this dimensions, length can be increased by taking it as a distally based on the anastomosis around the sinus tarsi.

## **ADVANTAGES OF LATERAL SUPRA MALLEOLAR FLAPS**

It is reverse flow fasciocutaneous flap raised from lower third of lateral aspect of the leg used to cover defects of ankle

region, dorsum of foot and posterior aspect of leg. It provides a stable cover across the ankle joint so that all the vital structures are protected. Its versatility is appreciated when microsurgical facilities are not available.

## **DISADVANTAGES OF THE FLAP**

*Donor site morbidity* - The raw area exposed is covered with split thickness graft. This is not aesthetically good in young females.

*Sacrifice of Superficial peroneal nerve* - This is cut and raised along with the superficial peroneal nerve artery because the flap survives based on the communications between this artery and anastomosis around the ankle. Hence there is sensory deficit in the distribution of superficial peroneal nerve - dorsum of foot except the first web space which is supplied by the deep peroneal nerve.



Postoperative care:

After the inset of lateral supramalleolar flap and donor site being covered with skin graft a non adherent dressing is done. Since , the flap is crossing the ankle joint , the joint motion is restricted by immobilizing in a posterior splint. The whole of the lower limb is elevated for proper venous drainage and paves way for the oedema to settle. Initially passive joint mobilization is done and once the graft had settled well then active mobilization of ankle joint is begun. Postoperative compression stockings are worn for upto 6 weeks later to decrease the size of the flap transferred.

#### **CADAVERIC DISSECTION:**

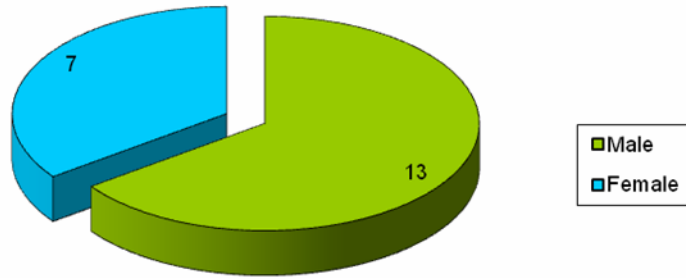
The dissections done in the cadaver showed the consistent anastomotic network between the peroneal artery and the anterior tibial artery around the ankle region. The

perforating branch of the peroneal artery divided into ascending and descending branches, the ascending anastomosed to the superficial peroneal nerve artery and the descending branch continued downed anastomosed with anterior division of lateral malleolar artery which is a branch of the anterior tibial artery. Further down tracing the course in the ankle, the extensor retinaculum was cut and the extensor digitorum brevis muscle was cut. The anastomosis with the lateral tarsal artery at the level of sinus tarsi was confirmed. The descending branch of the peroneal perforator ran in an subfascial plane and the ascending branch in a suprafascial plane.

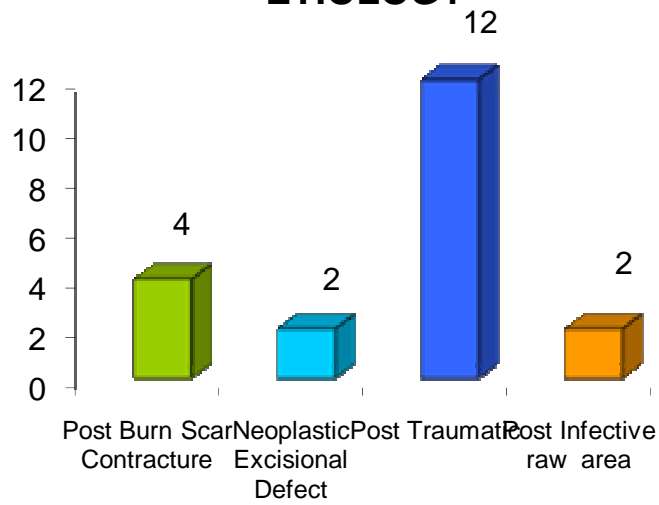
## **OBSERVATIONS AND RESULTS**

- 1) The flap was mainly raised within the dimensions described, the middle of the leg, anteriorly the crest of the tibia, posteriorly, the fibula and distally the anastomosis with the anterior lateral malleolar artery in proximally based flap and upto sinus tarsi in distally based flaps.
- 2) There were 20 patients in the study, 13 males and 7 females.
- 3) The soft tissue defects were due to
  - a) Post traumatic
  - b) Post infective
  - c) Post burns scar contracture
  - d) Neoplastic excisional defect.

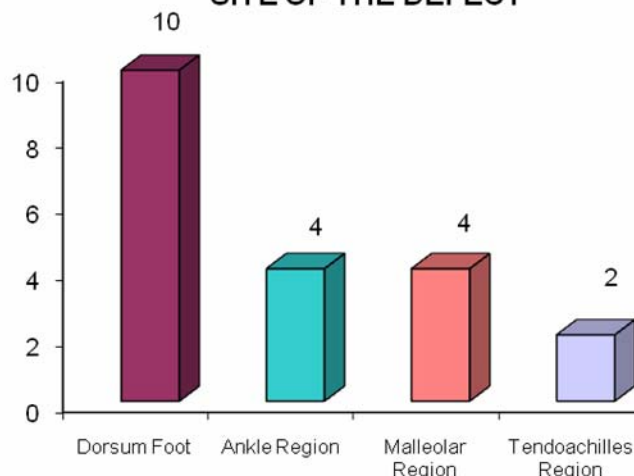
### SEX DISTRIBUTION



### ETIOLOGY



### SITE OF THE DEFECT



- 4) Diabetic status of the patients were included,  
6 patients were diabetic.
- 5) The sites of soft tissue defects included,
  - a) Dorsum of foot
  - b) Malleolar region
  - c) Tendo Achilles region
  - d) Ankle region
- 6) Out of 20 cases, 2 were distally based and others  
were proximally based flaps

- 7) The length of pedicle on an average ranged between 4-6cm for proximally based and 11-13cm for distally based flaps.
- 8) The standard markings for the flaps were crossed in 4 cases, that is the upper limit was extended beyond the middle of the leg for 1-3 cms.
- 9) The site of emergence of the Ramus Perforans ranged from 4.6-5.2 cms
- 10) The average size of the soft tissue defect was about 4\*3cm to 7\*4 cms.
- 11) Regarding anatomical variations encountered in the dissections, in one case Ramus Perforans was larger and there were no communication with anterior lateral malleolar artery, a proximally based flap was raised to cover a defect in the dorsum of foot.

- 12) Complications:
  - a) Donor site graft loss in one case
  - b) Distal necrosis in two cases (one case territory of middle of leg was crossed and other was due to pedicle kinking)
  - c) Venous congestion in two cases which settled in two days.
- 13) Necessity of second surgery in above three cases
- 14) All patients had full range of movement across the ankle joint
- 15) The donor site in the lower third leg graft site settled well and patients usually covered these sites with pants or saree.

## **DISCUSSION**

This study has helped to evolve a methodology of dissection for safe raising of Lateral Supramalleolar flaps based on the anastomotic network around the lateral malleolar region - communications between the peroneal artery and branches from the anterior tibial artery. This flap is a versatile one in that it can be used to cover defects in the regions of lower leg, ankle region, dorsum of foot upto head of the metatarsals and the tendocalcaneal regions. The perforator of the peroneal artery, the Ramus Perforans, provides blood supply to proximally based flap only upto middle of the leg. The random segment of its vasculature extends upto 1-3 cms beyond middle of the leg which is not reliable, in the study it was found that this random segment when included in our four cases presented as distal necrosis in one case which was distally based on the pedicle at the level of sinus tarsi. The extensor retinaculum was opened and extensor digitorum



brevis muscle was cut and released in all distally based flaps to avoid compression of the pedicle upto the level of sinus tarsi.

The reverse flow through the artery accompanying the superficial peroneal nerve, the superficial peroneal nerve artery (SPNA) a branch from the anterior tibial artery is the main source of blood supply to the flap. Beyond middle third and lower third junction the superficial peroneal nerve and artery pierces the deep fascia and runs in a deeper plane, hence the survival of the flap beyond the territory of middle of the leg is precarious.

In places of non availability of microsurgical facilities this flap is a versatile one in reconstructions of defects of foot, ankle regions. Local flap provides better color match, texture to the site of reconstruction. It is easy to raise this flap and cost effective. Even though the donor site morbidity is present it is always acceptable by the patient.

## **CONCLUSION**

- 1) The Lateral Supramalleolar flap based on the anastomosis around the ankle lateral malleolar region is a reverse flow flap useful in the reconstructions of the defects in ankle and foot regions.
- 2) Preoperative Doppler is required to confirm this anastomotic network before planning the flap.
- 3) The flap is limited to the dimensions of middle of the leg above, medially crest of tibia and laterally fibula. It can be raised as proximally based on the Ramus perforans or distally based on the communications at the level of sinus tarsi.
- 4) It is a local flap which gives good colour match, texture and thickness to cover the exposed tendons, bones and vessels in the foot and ankle regions.
- 5) Even though donor site morbidity occurred, the ankle joint movements were well restored.

## **BIBLIOGRAPHY**

- 1) Yoshimura M, Shimada T, Imura S, Shimamura K, Yamauchi S. Peroneal island flap for skin defects in the lower extremity. *J Bone Joint Surg Am* 1985; 67(6):935-41.
- 2) Masquelet AC, Beveridge J, Romana C, Gerber C. The lateral supramalleolar flap. *Plast Reconstr Surg* 1988; 81(1): 74 - 81.
- 3) Leung PC, Hung LK, Leung KS. Use of the medial plantar flap in soft tissue replacement around the heel region. *Foot Ankle* 1988;8(6):327-30.
- 4) Menesi L. [The lateral supramalleolar fasciocutaneous flap and its modification]. *Magy Traumatol Ortop Kezseb Plasztikai Seb* 1994; 37(4): 371-4.

- 5) Valenti P, Masquelet AC, Romana C, Nordin JY. Technical refinement of the lateral upramalleolar flap. *Br J Plast Surg* 1991;44(6):459-62.
- 6) Nohira K, Shintomi Y, Sugihara T, Ohura T. Replacing losses in kind: improved sensation following heel reconstruction using the free instep flap. *J Reconstr Microsurg* 1989; 5(1) : 1-6.
- 7) Saitoh S, Hata Y, Murakami N, Seki H, Kobayashi H, Shimizu T, et al. The 'superficial' peroneal artery: a variation in cutaneous branching from the peroneal artery, nourishing the distal third of the leg. *Br J Plast Surg* 2001;54(5):428-33.
- 8) Wolff KD. The supramalleolar flap based on septocutaneous perforators from the peroneal vessels for intraoral soft tissue replacement. *Br J Plast Surg* 1993;46(2):151-5.

- 9) Beveridge J, Masquelet AC, Romana MC, Vinh TS. Anatomic basis of a fascio-cutaneous flap supplied by the perforating branch of the peroneal artery. *Surg Radiol Anat* 1988;10(3):195-9.
- 10) Cormack GC, Lamberty BG. A classification of fasciocutaneous flaps according to their patterns of vascularisation. *Br J Plast Surg* 1984;37(1):80-7.
- 11) Whetzel TP, Barnard MA, Stokes RB. Arterial fasciocutaneous vascular territories of the lower leg. *Plast Reconstr Surg* 1997;100(5):1172-85.
- 12) Our experience with the lateral supramalleolar island flap for reconstruction of the distal leg and foot: A review of 20 cases by: Efterpi Demiri, Periclis Foroglou, Dimitrios Dionyssiou, Antonios Antoniou, Paraskevas Kakas, Leonidas Pavlidis, Lampis Lazaridis

- 13) Technical refinement of the lateral supramalleolar flap P VALENTI, AC MASQUELET, C ROMANA, JY NORDIN - British journal of plastic surgery, 44:66,459-462, Elsevier, 1991. Traumatisme; Trauma; Traumatismo Cited by 17 - Related articles - Web Search - All 2 versions
- 14) The Lateral Supramalleolar Flap: Experience With 41 Flaps. P Voche, M Merle, JD Stussi - Annals of Plastic Surgery, 2005 - annalsplasticsurgery.com Cited by 9 - Related articles - Web Search - All 3 versions.
- 15) Grabb's encyclopedia of flaps 2<sup>nd</sup> edition volume III by Berish Strauch , Luis O. Vasconez and Elizabeth J. Hall-Findlay.

- 16) YH Lee, SK Rah, SJ Choi, MS Chung, GH Baek - Plastic and Reconstructive Surgery, 2004 - plasreconsurg.com Soft-tissue reconstruction of the dorsum of the foot and ankle has long been a challenge for reconstructive surgeons. Limitations in the available local tissue and donor-site morbidity restrict the options. In an effort to solve these ...
- 17) Therapeutic possibilities of the lateral supra-malleolar flap and its variations. Apropos of 6 ... D Le Nen, E Stindel, P Caro, F Dubrana, C Lefevre - Ann Chir Plast Esthet, 1996 - ncbi.nlm.nih.gov The distally based lateral supramalleolaire flap with a retrograde blood flow on the perforating branch of the peroneal artery is a good flap to treat loss of skin involving the ankle, the region behind the Achilles tendon, and the dorsum of foot.

- 18) Lateral Supramalleolar Flap for Heel Coverage in a Patient with Werner's Syndrome. M Okazaki, K Ueda, K Kuriki - *Annals of Plastic Surgery*, 1998 - [annalsplasticsurgery.com](http://annalsplasticsurgery.com)
- 19) Grabb WC, Argenta LC, the lateral calcaneal artery skin flap (LCA, LSV, Sural Nerve skin flap) plastic reconstructive surgery 1981:68:723
- 20) Wessler S, Schlesinger MJ, studies in peripheral arterial occlusive disease I methods and pathologic findings in amputated limbs. *Circulation* 1953,7:641.
- 21) Barner HB, Kaiser GC, Willman VL, Blood flow in the diabetic leg circulation 197:43:391
- 22) Man D, Acland R, the microarterial anatomy of DPA and its clinical application plastic reconstructive surgery 1980:65:419



- 23) McCraw JB, Furlow LT Jr, the dorsalis pedis arterialized flap Plastic reconstructive surgery 1975:55:177
- 24) Ismail TIA:- the dorsalis pedis Myofascial flap plastic reconstructive surgery 1990:86:573
- 25) Landi A Soragni O Monteleone. The extensor digitorum brevis muscle island flap for soft tissue loss around the ankle plastic reconstructive surgery 1985 :75:892
- 26) Romana MC, Masquelet AC, vascularisation of inner border of foot, surgical applications surgery Radiol Anat 1988:11:177 Masquelet AC, Romana MC, the medialis pedis flap, a new F/C flap, plastic reconstructive surgery 1990:85:765

## **PROFORMA**

NAME:

PS No:

AGE:

ADM No:

SEX:

D.O.Adm:

ADDRESS:

D.O.Surg:

D.O.Dis:

Ph no:

PRESENTING COMPLAINTS

HISTORY OF PRESENT ILLNESS

PAST HISTORY: Comorbidity:

PERSONAL HISTORY Smoker/ non-smoker

TREATMENT HISTORY

GENERAL EXAMINATION

## CLINICAL EXAMINATION

### PROVISIONAL DIAGNOSIS:

1.Site of the defect

2. Size of the defect

OPERATION :

Date:

1. Type of the flap

2. Dimensions of the flap in cms

3. Anatomical variations

4. Location of Ramus Perforans

(photographs)

FOLLOW UP:

<i>S.No</i>	<i>Name</i>	<i>Age</i>	<i>Sex</i>	<i>Etiology</i>	<i>Medical disability</i>	<i>Site of Defect</i>	<i>Proximally or Distally Based</i>	<i>Length of Pedicle</i>	<i>Upper Limit Middle of leg</i>	<i>Site of RamusPerforans From intermalleolar level</i>
1.	Venkatesh	42	M	Post Burns Scar Contracture		Dorsum foot	P	6cm	-	4.2cm
2.	Masthan	29	M	Neoplastic excisional defect		Malleolar Region	P	7cm	-	5.2cm
3.	Savithri	52	F	Post Traumatic	Diabetic	Dorsum foot	P	5cm	-	4.5cm
4.	Rajendran	43	M	Post Infective Raw Area		Dorsum Foot	D	7cm	-	4.8cm
5.	Alexander	60	M	Post Traumatic	Diabetic	Dorsum Foot	P	5.4cm	-	4.4cm
6.	Shanthi	35	F	Post Traumatic		TA Region	D	11cm	-	4.6cm
7.	Ramayee	58	F	Post Traumatic	Diabetic	Dorsum foot	P	5cm	Crossed	4.4 cm

<i>S.No</i>	<i>Name</i>	<i>Age</i>	<i>Sex</i>	<i>Etiology</i>	<i>Medical disability</i>	<i>Site of Defect</i>	<i>Proximally or Distally Based</i>	<i>Length of Pedicle</i>	<i>Upper Limit Middle of leg</i>	<i>Site of RamusPerforans From intermalleolar level</i>
8.	Arun Kumar	26	M	Post Infective Raw Area		Malleolar region	P	6cm	-	4.8cm
9.	Devi	42	F	Post Burns Scar Contracture		Dorsum foot	P	5cm	-	5.1cm
10.	Suresh	19	M	Post Traumatic		Ankle Region	P	4 cm	Crossed	5.1cm
11.	Srinivasan	30	M	Neoplastic excisional defect	Diabetic	Dorsum Foot	P	4cm	-	5.2cm
12.	Jayarani	48	F	Post Traumatic		Ankle region	P	3cm	-	5cm
13.	Bagyalakshmi	51	F	Post Traumatic	Diabetic	Ankle region	P	4cm	-	5.1cm
14.	Jagadish	47	M	Post Traumatic		TA Region	D	12cm	Crossed	4.8cm

<i>S.No</i>	<i>Name</i>	<i>Age</i>	<i>Sex</i>	<i>Etiology</i>	<i>Medical disability</i>	<i>Site of Defect</i>	<i>Proximally or Distally Based</i>	<i>Length of Pedicle</i>	<i>Upper Limit Middle of leg</i>	<i>Site of RamusPerforans From intermalleolar level</i>
15.	Gopal	32	M	Post Burns Scar Contracture		Malleolar Region	P	5cm	-	4.6cm
16.	Ramu	29	M	Post Traumatic		Dorsum foot	P	4cm	-	4.4cm
17.	Rani	30	F	Post Burns Scar Contracture		Ankle Region	P	5cm	-	4.9cm
18.	Gopi	31	M	Post Traumatic		Dorsum foot	P	6vm	-	5cm
19.	Bhavani	47	M	Post Traumatic	Diabetic	Malleolar Region	P	5cm	-	4.8cm
20.	Raghavi	40	M	Post Traumatic		Dorsum Foot	P	4cm	Crossed	4.9cm

P – Proximally based      D – Distally based