

**Compare the Diagnostic Accuracy of
Sonourethrogram and Retrograde
Urethrogram**

Dissertation submitted to
**THE TAMIL NADU DR. M.G.R. MEDICAL UNIVERSITY
CHENNAI.**

*In partial fulfillment of the Regulations
for the Award of the Degree of*

**M.Ch., BRANCH IV
GENITOURINARY SURGERY**



**DEPARTMENT OF GENITOURINARY SURGERY
KILPAUK MEDICAL COLLEGE
CHENNAI – 600 010.**

FEBRUARY 2006

CONTENTS

Introduction

Aim

Review of Literature

Materials and Methods

Results

Discussion

Conclusion

Bibliography

Appendix - I

Appendix - II

ACKNOWLEDGEMENT

I express my sincere thanks to **Dr.G.Ilangovan**, M.D., D.D., DIH., Ph.D., Dean, Kilpauk Medical College for permitted me to conduct the study.

I am grateful to **Prof.M.G.Rajamanickam**, M.S. M.Ch. (Uro) for assigning this topic and providing me with valuable guidance.

I thank **Prof.P.Vairavel** DGO., M.S., M.Ch., (Uro) for his excellent guidance.

My profound gratitude to radiologists **Dr.Rajan**, M.D., Precision Diagnostics Ltd., **Dr.Nirmala**, M.D., who with their vast knowledge and experience provided me with all the necessary facilities and guidance.

My sincere thanks to **Assistant Professors Dr.P.Leela Krishna, Dr.N.Muthulatha, Dr.R.Jayaganesh, Dr.G.Sivashankar, Dr.M.Deepak, Dr.A.Senthilvel.**

I am indebted to all the patients in the study for their co-operation.

INTRODUCTION

Stricture urethra is a very common urological disease. We perform on an average 12 Visual Internal Urethrotomies and one urethroplasty per month. Common Etiology being inflammatory anterior urethral strictures and post traumatic bulbomembranous strictures. The standard diagnostic modality we use is Retrograde urethrogram and Combined Cysto Urethrogram. Since sonography has become the urologist's stethoscope, we evaluated stricture urethra with sonourethrogram and compared sonourethrogram to RGU, weighing the pros and cons of each.

AIM

To compare the diagnostic accuracy of sonourethrogram and Retrograde Urethrogram.

To find out the degree of spongiofibrosis by sonourethrogram.

Application of doppler USG to locate the bulbourethral arteries in men with normal urethra and to study anatomical alterations in men with urethral stricture.

Parameters that have a major influence on the selection of therapy in urethral stricture disease being exact length of stricture, its location, density and percentage narrowing of urethral lumen. Identifying the exact location of bulbourethral arteries could help avoid injury to the vessels during VIU.

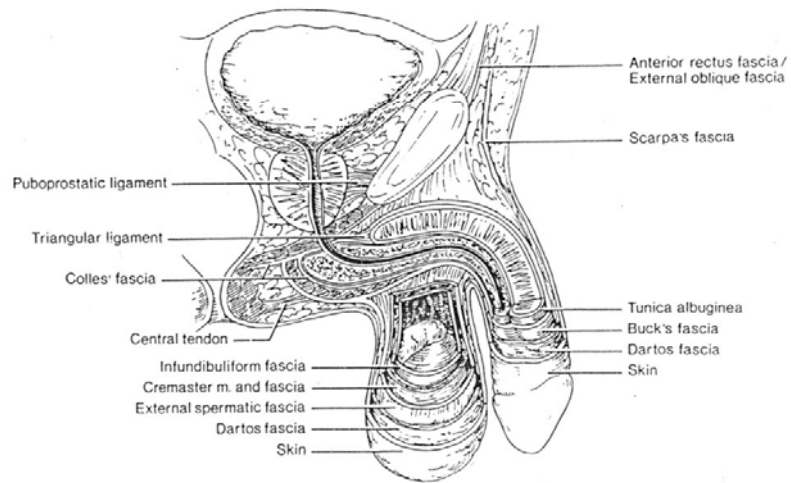
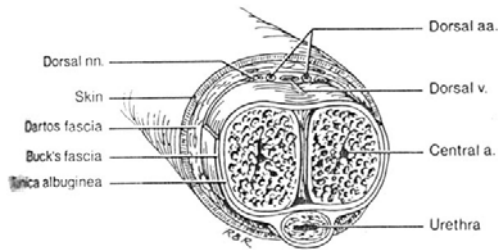
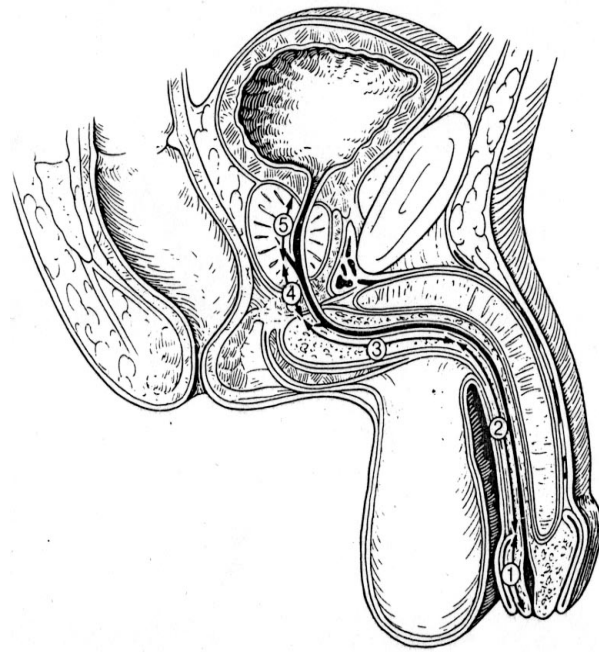
REVIEW OF LITERATURE

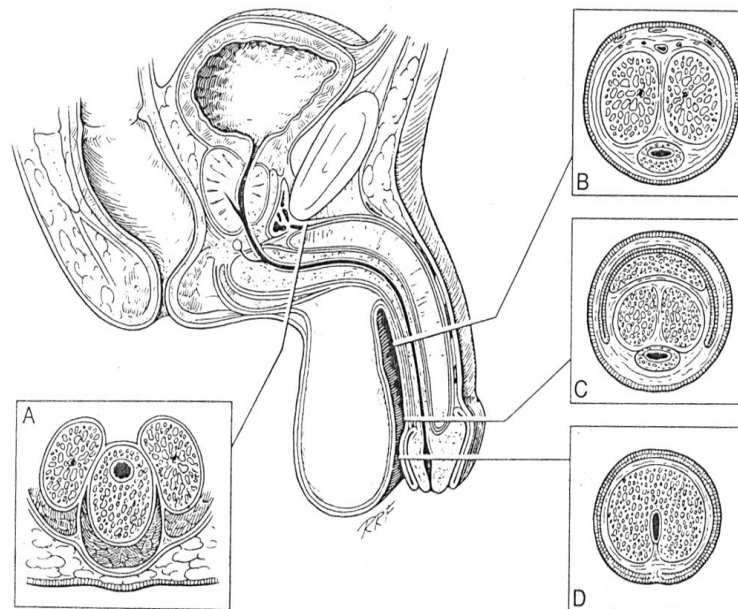
URETHRAL STRICTURE DISEASE

Anatomy(12)

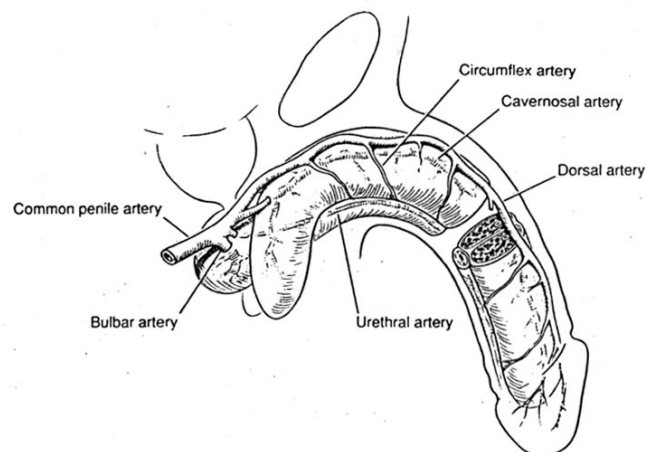
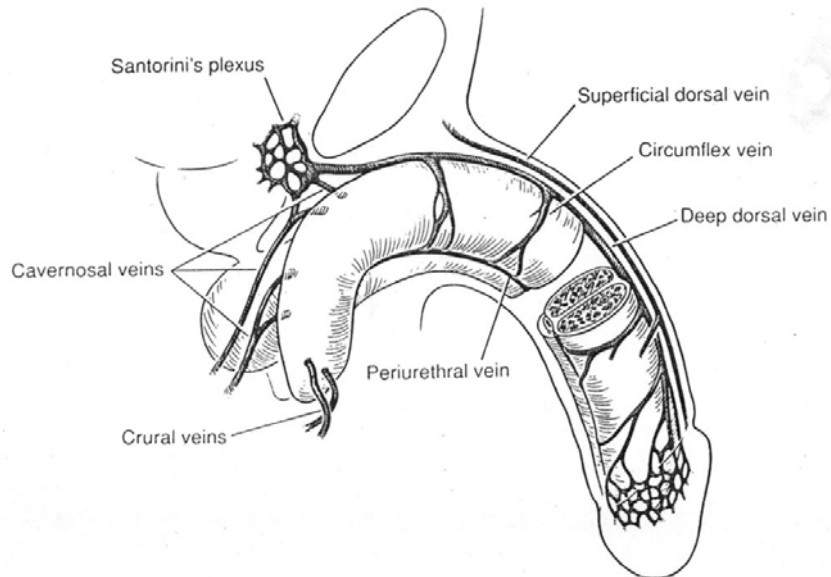
For purposes of discussion, the urethra can be divided conceptually into five divisions: 1. The prostatic urethra lies proximal to the verumontanum and is surrounded by the prostatic glandular tissue. 2. The membranous urethra is a short segment of urethra surrounded in its entirety by the external urethral sphincter. 3. The bulbar urethra lies distal to the external spincter and proximal to the suspensory ligaments of the penis; it is covered by the bulbospongiosus muscles and is centrally located in the bulbospongiosum. 4. The penile urethra is also located centrally in the bulbospongiosum but lies distal to the suspensory ligaments of the penis. The fossa navicularis portion of the urethra lies within the glans penis and terminate at the junction of the urethral epithelium and the skin of the glans. 5. The prostatic and membranous portions of the urethra are sometimes referred to together as the posterior urethra, whereas the bulbar and penile urethra are sometimes called the anterior urethra.

The urethra is eccentrically placed in relation to the corpus spongiosum in the bulbous urethra and is much closer to the dorsum of the penile structures. As one moves distally, the pendulous or penile urethra becomes more centrally placed within the corpus spongiosum.





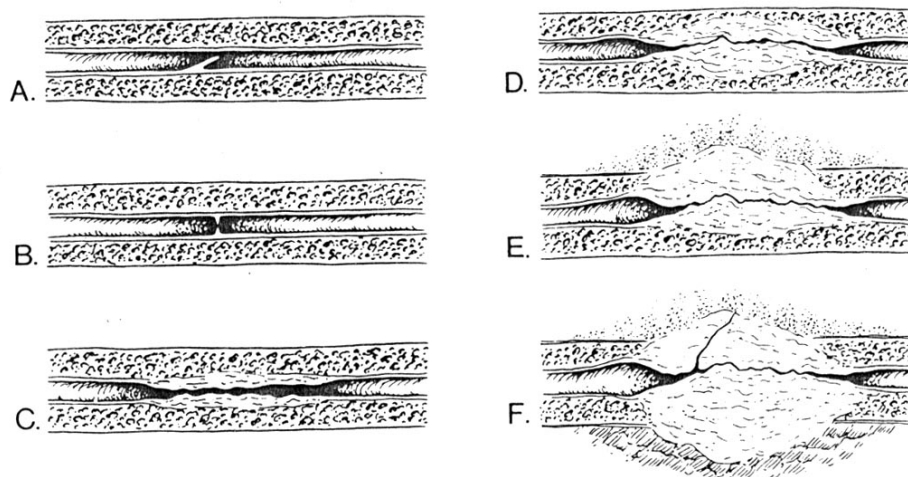
Diagrammatic cross sections of the anterior urethra. A the bulbous urethra. The urethra is eccentrically placed in the corpus spongiosum. Proximally, the corpora cavernosa have split into individual crura, with the urethra are intimately fused, separated only by septal fibers. C. At the coronal margin, the urethra remains relatively centrally placed, and the corpora cavernosa are fused, again separated by septal fibers. The spongy tissue of the corpus spongiosum has become incorporated as the deep tissues of the glans. D. The fossa navicularis widens somewhat in caliber and is totally surrounded by the spongy erectile tissue of the glans penis.



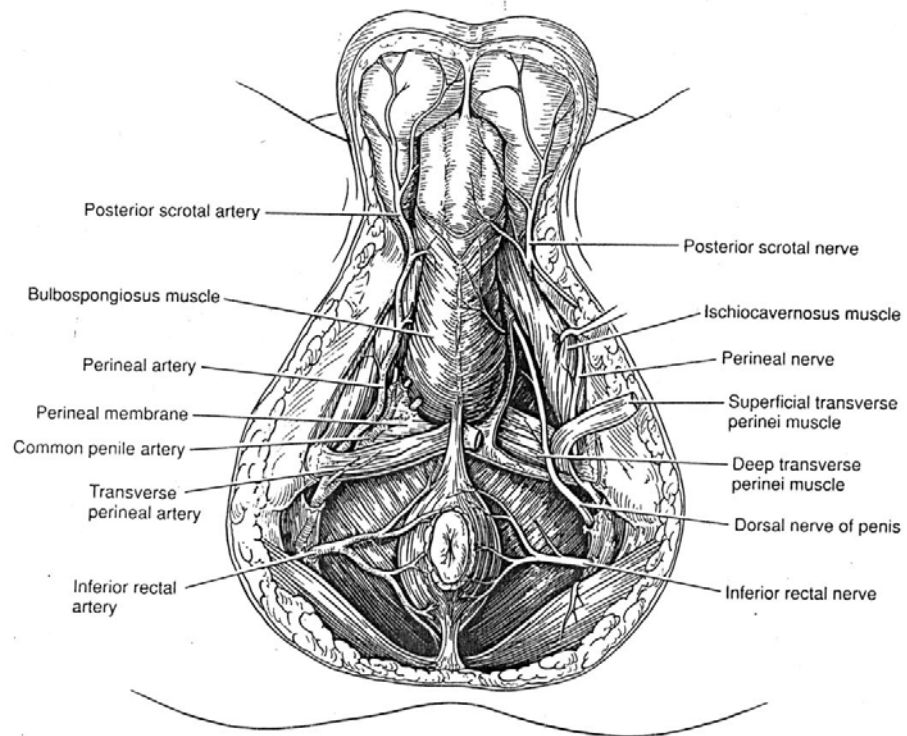
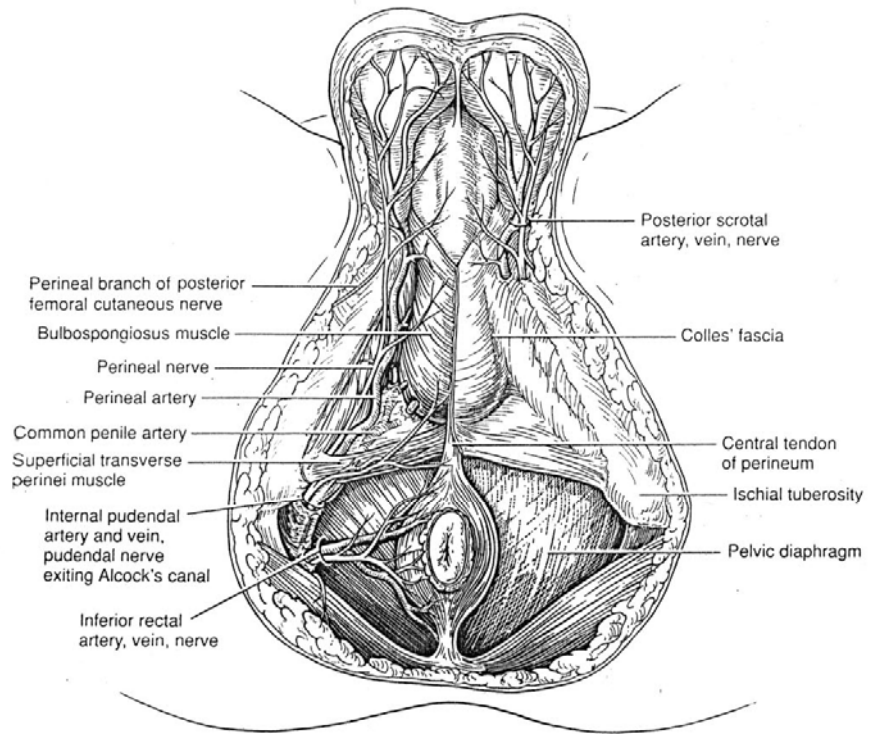
The genital skin has a dual (proximal and distal) and bilateral blood supply, forming a fasciocutaneous system. The corpus spongiosum receives blood from the common penile artery, the terminal branch of the internal pudendal artery. The corpus spongiosum also has a dual blood supply, with both a proximal blood supply and a retrograde blood supply by way of the dorsal arteries as they arborize in the glans penis.

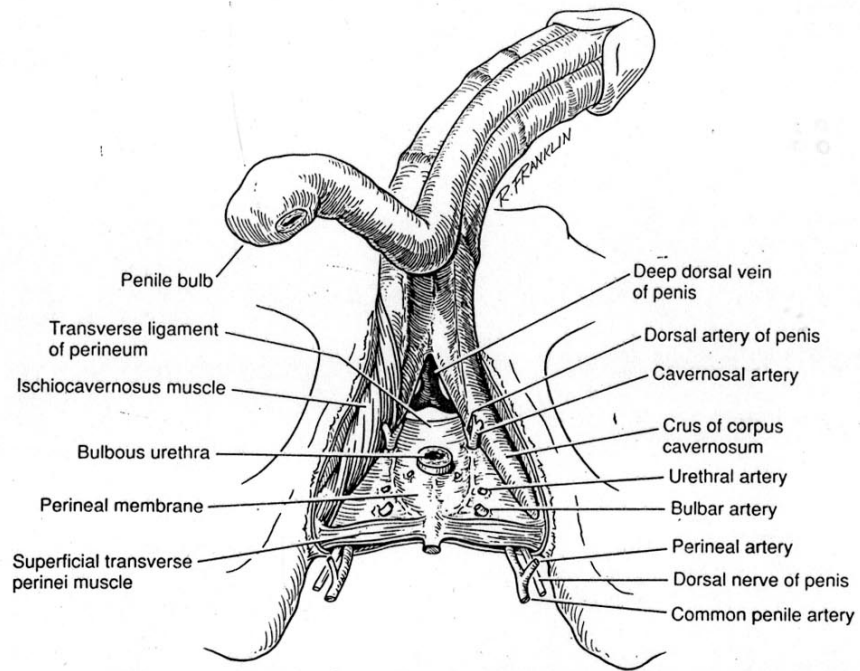
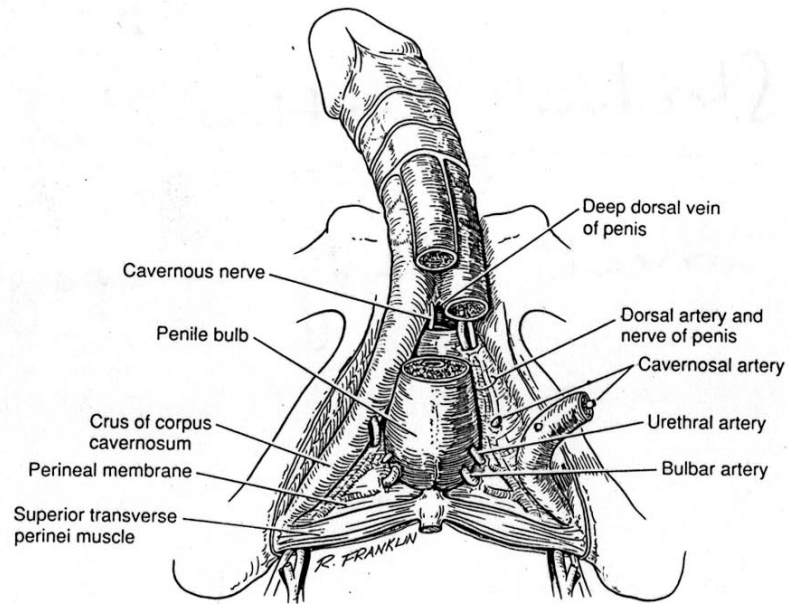
The term urethral stricture generally refers to anterior urethral disease, or a scarring process involving the spongy erectile tissue of the corpus spongiosum. Posterior urethral "strictures" are not included in the common definition of urethral stricture. Posterior urethral stricture is an obliterative process in the posterior urethra that has resulted in fibrosis and is generally the effect of distraction in the area caused by either trauma or radical prostatectomy.

Any process that injures the urethral epithelium or the underlying corpus spongiosum to the point that healing results in a scar can cause anterior urethral stricture.



A. Mucosal fold. B. Iris constriction. C. full-thickness involvement with minimal fibrosis in the spongy tissue. D. Full-thickness spongiofibrosis. E. Inflammation and fibrosis involving tissues outside the corpus spongiosum. F. Complex stricture complicated by a fistula. This can proceed to the formation of an abscess, or the fistula may open to the skin or the rectum.





Etiological factors(9) include trauma, including iatrogenic trauma - post catheterisation, post TURP, open surgery, bulbar penoscrotal being common sites. Occasionally entire anterior urethra may be involved. Perineal trauma is in important etiology in bulbar strictures.

Inflammatory stricture due to BXO being a common cause.

Post infective strictures are the result of gonococcal, chlamydial, non specific bacterial, rarely tuberculous or syphilitic in origin.

Chemical strictures due to injection of corrosives.

Radiation induced strictures do occur.

Primary amyloidosis is a rare cause.

Urethral carcinoma may present as stricture disease.

Paediatric strictures are rarely congenital, most often after urethroplasty for hypospadias, fulguration of posterior urethral valves, cystoscopy for urethral bleeding and indwelling catheter drainage.

Patients who have urethral strictures often present with obstructive voiding symptoms or urinary tract infections such as prostatitis or epididymitis. Some patients also present with urinary retention. Most of these patients are found to have obstructive voiding symptoms for a long period of time before progressing to complete obstruction. Most cases are managed with dilatation and catheterisation. When this is not possible suprapubic cystostomy is done.


After a course of antibiotics when the culture is sterile, further investigations are ordered for. These include the standard retrograde urethrogram or combined cystourethrogram and ultra sonography of kidney ureter, bladder area. Uroflometry may give a clue. Sonourethrogram is an evolving technic in the evaluation of urethral strictures. The length and location of the strictures can be determined with RGU, Sonourethrogram and urethroscopy. The depth and density of the scar in the spongy tissue can be deduced from physical examination, appearance of urethra. In contrast studies, the amount of elasticity noted on urethroscopy and depth and density of fibrosis as evidenced by sonourethrogram. These investigations are best carried out under the direct supervision of the surgeon responsible for the treatment.

RGU is done by retrograde injection of contrast like sodium diatrizoate loaded in a 20 cc syringe with the nozzle placed in the meatus and glans pinched ventrally, under flourosopic guidance.

Sonourethrography is done by retrograde injection of saline or lignocaine jelly and evaluating the urethra using 5 or 7 Mhz sonor probe.

MRI(7) is another valuable diagnostic modality which can give an anatomical orientation as to the length of the stricture, depth and degree of malalignment.

Uroflometry reveals a curve like this



Micturitional pressure profile(4) can suggest the presence of strictures.

Flexible cystoscopy under local anesthesia has simplified the evaluation of stricture disease. The urethra proximal and distal to the stricture segment should be assessed for planning the proper therapy.

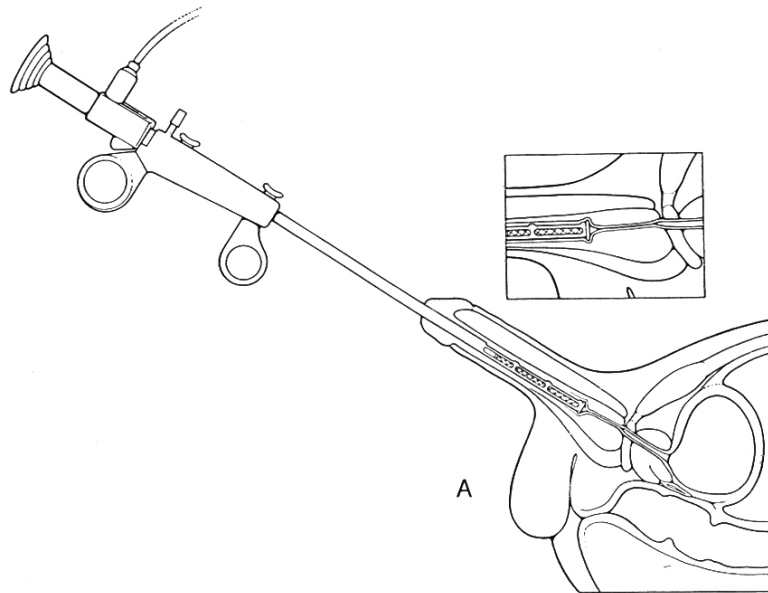
Treatment of urethral stricture disease

- **Urethral dilatation(12)** for a patient with an epithelial stricture without spongiofibrosis is curative. Dilatation may be done using balloon, teflon dilators or bougies.
- **Visual Internal Urethrotomy(12)** refers to any procedure that opens the stricture by incising or ablating it transurethrally. This may be by cold knife or laser knife (carbon dioxide, argon, KTP, Nd:YAG, holmium YAG (Ho-YAG), and excimer lasers. Internal urethrotomy is made as a single incision at 12 O' Clock position. Strictures at the bulbous urethra that are less than 1.5cm in length and not associated with dense, deep spongifibrosis (i.e., straddle injuries) can be managed with internal urethratomy with a 74% moderately long term success rate. VIU is not done in the penileurethra for fear of erectile dysfunction penileurethra may be dilated using OTIS urethrotome. In VIU we

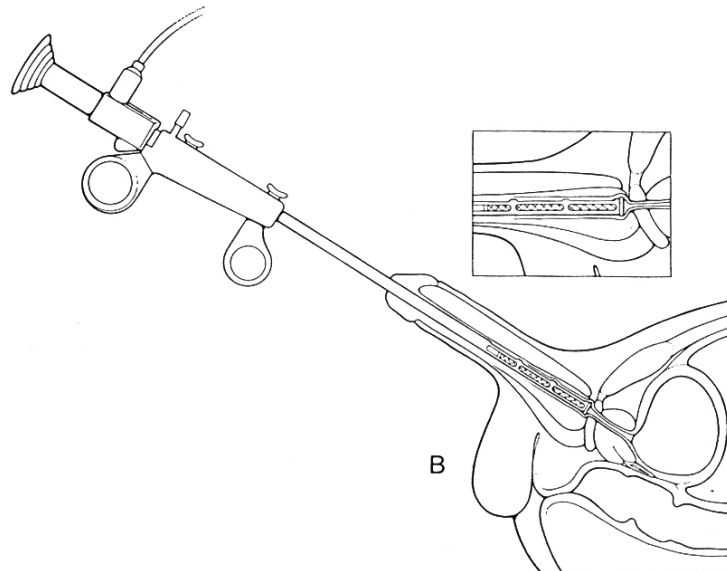
incise the scar in the hope that epithelialisation will progress completely before wound contraction.

- **Urethral stents(10)** removable and permanently implantable are another modality used in opposing the forces of wound contraction after internal urethrotomy or dilatation. Removable urethral stents are designed to prevent the process of epithelialization from incorporating the stent into the urethral wall and are left in place for as long as 6 months to 1 year before they are removed.
- The two main urethral stents available today are the urolume endourethral prosthesis and the Urocoil. The main difference between the two stents is that the UroLume is designed to be a permanent prosthesis, whereas the Urocoil is designed to be removed.
- Ideal patients for the Urolume should have a bulbar urethral stricture ≤ 3 cm in length and have 5mm of healthy urethra distal to the sphincter.
- In patients with prior prostate surgery a high degree of vigilance required because placing the stent too close to the external urethral sphincter will leave the patient incontinent.
- Mean symptom score following insertion of the Urolume decreased from 12.5 to 3.7. Mean peak flows increased from 9.9 to 24 ml/sec. All results were sustained at 2-year follow-up.

Technique of placement of urolume for proximal bulbar stricture

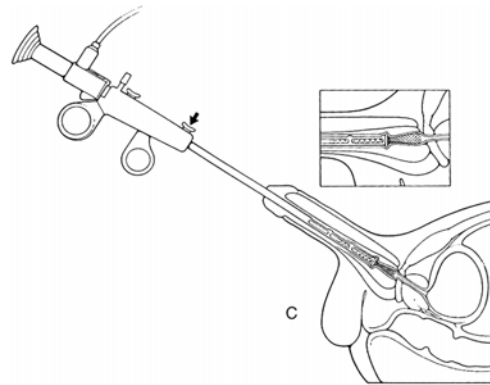


- A. Urethral stricture has been dilated or incised. The delivery tool with a stent is advanced to the area of stricture

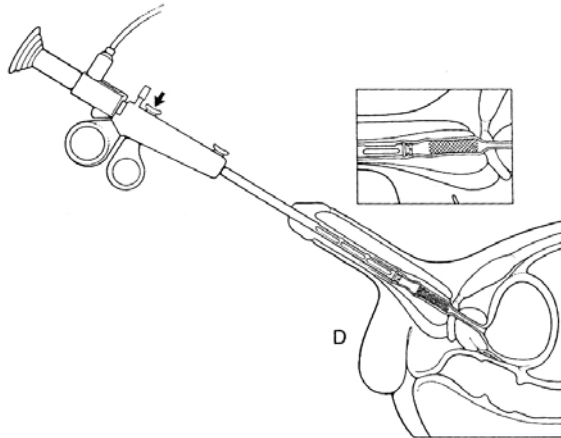


- B. The delivery tool is advanced to just distal to the external urethral sphincter.

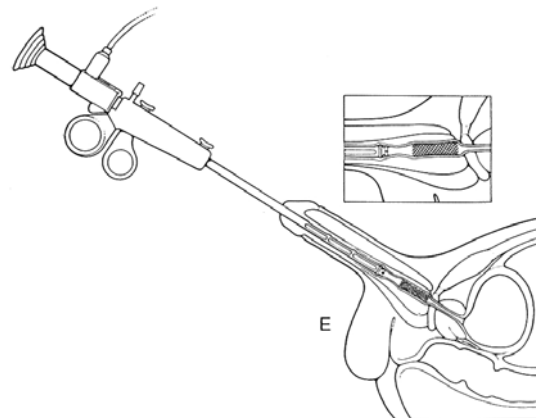
- C. The Stent is advanced but not deployed from the delivery tool.
The correct position with relation to the external sphincter is visualised directly



- D. The stent after being correctly placed, is deployed from the delivery tool.



- E. The delivery tool is removed, leaving the stent positioned across the area of stricture.



- Only 15% patients required retreatment for urethral narrowing within or adjacent to the stent; 4% have required removal of the stent since the study began.
- Hyperplastic tissue growth was noted in 45% of patients treated with the Urolume; however, in 82% of these patients growth was mild and did not require treatment.
- Urethroplasty, not trauma, is the major risk factor for restenosis.
- The Urocoil design philosophy is that the residual stricture scar will become molded to a wider diameter following prolonged stenting to facilitate urine flow.
- In patients treated with the Urocoil, flows improved from 0 to 16 to 32 ml/sec over an 8-month follow-up

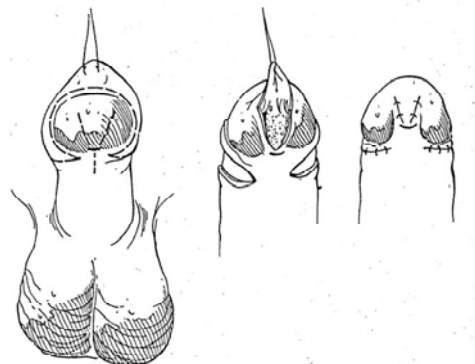
URETHROPLASTY(11)

Many urethroplasty techniques have been described and it is true to say there is no single technique appropriate for the management of all strictures. Techniques may be broadly grouped into anastomotic and substitution repairs. In substitution repairs the urethral lumen is augmented using either flap or graft techniques, with the grafts customarily obtained from penile skin although buccal mucosa is a current alternative. Some techniques involve a combination of anastomotic and substitution approaches and may be performed in single or multiple stages. SIS small intestinal submucosa is emerging as a new substitute.

The selection of appropriate repair is governed to a large degree by the location of the stricture, its length and the presence of local adverse features such as fistulas, inflammation, or scarring. The goal of surgical repair should not be to achieve urethral patency, but to avoid compromising normal sexual function and to avoid altering penile cosmetics. Repair of pendulous urethral strictures can result in penile chordee if urethral shortening results, so that stricture excision and anastomotic repairs are relatively contraindicated, and indeed, even skin graft repairs in the penile urethra may prove inelastic. Hence, flap repairs are optimal in this location. In the bulbar urethra, strictures may result from straddle injury in which case they are short and may be repaired by excision and reanastomosis. Inflammatory strictures tend to be longer and are treated by on lay graft or flap techniques. Pelvic fracture urethral injury often causes distraction defects of the membranous urethra; these are invariably managed by a perineal anastomotic repair.

In performing urethroplasty care must be taken to extend the repair proximally and distally into healthy urethra. Failure to accomplish this is likely the commonest cause for recurrent stricture following surgical repair.

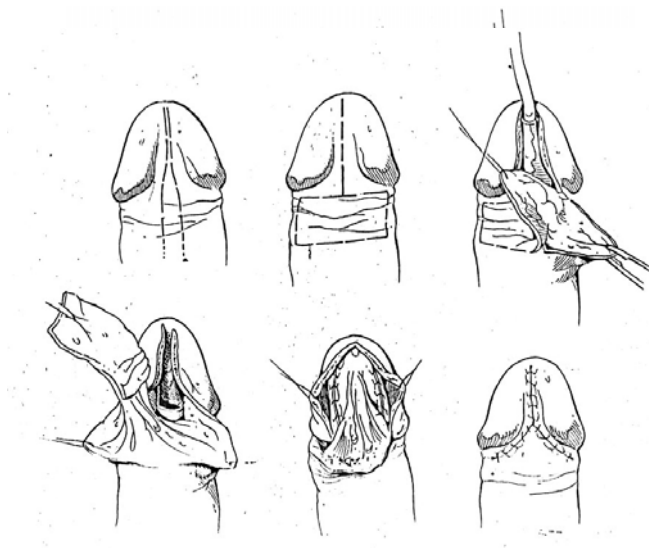
SURGICAL TECHNIQUE



Glans flap meatoplasty.

Strictures in the glanular urethra are most commonly due to inflammatory conditions, instrumentation, or improper circumcision. Surgical repair of these strictures may be accomplished by simple meatotomy, a glans based Y-V advancement flap for very distal stenosis, or a ventral shaft skin onlay flap in the case of stricture involving the entire fossa navicularis.

For Y-V advancement a V-shaped incision is made on the dorsal aspect of the glans with the apex terminating at the urethral meatus. A dorsal midline extension of this incision is made into the urethra to widen the lumen to accept a 22-Fr sound. The glans flap can be elevated using skin hooks and sharp dissection to allow its mobilization into the most proximal limit of the dorsal urethral incision where it is anchored with a 4-0 polyglycolic acid (PGA) suture. Care must be taken to leave this glans flap with a wide base to avoid vascular compromise. A 14-Fr Foley catheter is left in place for approximately 5 days.

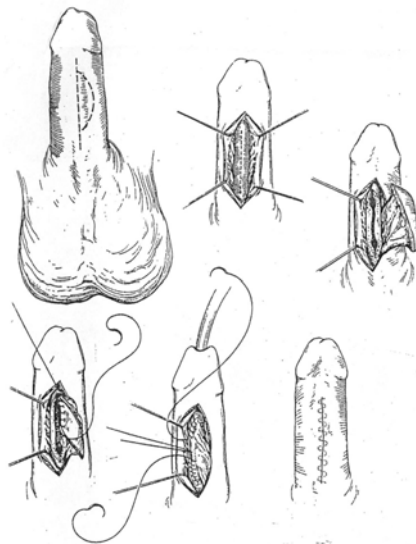


More extensive strictures of the glanular and distal penile urethra may result from balanitis xerotica obliterans (BXO). These are best treated with a flap of skin obtained from the penile shaft. The flap may be fashioned as an onlay or as a tube, depending on the extent of the disease. There are a number

of variation of this technique but one commonly used is depicted in figure 51-2. In performing this procedure it is important that the repair be continued into healthy urethra proximal to the stricture, and in cases where BXO is the cause, strictured urethral excision and tubed skin flap replacement may be optimal. An excellent cosmetic result can be achieved by mobilization of glans wings and their reapproximation around the neourethra. A 14-Fr urethral Foley catheter remains in place for 7 days following the repair.

Strictures of Pendulous Urethra

Pendulous urethral strictures are most often repaired using an onlay flap of penile skin. Although many variations of this technique have been described, the laterally based predicted island flap originally described by Orandi gives excellent results and is technically forgiving. It is generally suitable for repairs measuring up to 8 cm (depending on penile length), although longer repairs can be performed by harvesting a penile flap that has a vertical and a distal circumferential component. A flap width up to 25mm can be used without compromising penile skin closure.



The patient is placed in either lithotomy or a supine frog-legged position. Methylene blue is injected retrogradely into the urethra to accentuate the stricture margins. An incision is made along the ventral penile raphe through Buck's fascia down to the strictured segment of urethra. Using skin hooks to elevate the flap and fine scissors for dissection, on skin margin is mobilized from the corpus cavernosum for 10 to 15 mm staying deep to Buck's fascia. With the urethra adequately exposed, a suitable catheter or filiform is placed in the urethral lumen as a guide and the urethra incised ventrally along the stricture. This incision is then extended using scissors to expose at least 1 cm of healthy urethra proximal and distal to the stricture. Significant blood loss can be controlled by oversewing the urethral edge with 5-0 PGA suture, although this is seldom necessary. An onlay flap of suitable width to achieve a 24-Fr lumen (generally 18 to 25 mm) is then outlined on the mobilized lateral penile shaft skin. The flap length corresponds to the length of the urethrotomy and is tapered at the proximal and distal ends. Care must be taken not to incorporate a significant segment of hair-bearing shaft skin in the repair.

Once the flap has been outlined, the projected new skin edges are approximated in the midline to ensure that wound closure will be possible with a minimum of tension after the flap has been raised. The lateral aspect of the flap can then be incised superficially through subcutaneous connective tissue, leaving the underlying dartos and deeper Bucks fascia intact. With exposure of the correct tissue plane, the lateral penile shaft skin will retract with minimal additional dissection.

The medial border of the island flap is then anchored to the lateral edge of the open urethra with 5-0 PGA stay sutures. Beginning at the distal margin, the flap is sutured to the urethra using a running 5-0 PGA suture, incorporating the urethral epithelium in the closure.

When the lateral suture line is complete, the free edge of the island flap can be rolled over and secured with 5-0 PGA stay sutures to the other urethral margin, recreating and augmenting the urethral lumen. A similar running suture line is performed with 5-0 PGA to complete the onlay repair. A 14- to 16-Fr Silastic Foley catheter is placed for urine diversion and stenting. Local wound drainage may be accomplished with a 7-Fr suction drain placed underneath the vascular pedicle along the length of the flap if necessary. This guards against hematoma or urinoma formation and potential flap compromise.

Wound closure is performed in two layers using 4-0 interrupted PGA suture. Care must be taken when approximating the subdermal connective tissue of the skin margins to not injure the vascular pedicle of the flap. This first layer of closure serves to cover the exposed urethral suture line and minimize the risk of fistula formation. Final skin closure is performed with a running subcuticular 4-0 PGA suture. The wound is supported with adhesive strips and covered with a gauze and loosely applied Coband® dressing to reduce edema formation. The Foley catheter is secured to the abdominal wall and remains in place for up to 3 weeks. The suction drain is usually removed within 24 hours and the supportive dressing taken down on the third postoperative day. The patient is allowed to ambulate on the first day following surgery and he may be discharged within 24 to 48 hours.

Upon return visit at 3 weeks a pericatheter retrograde urethrogram is performed. If there is no extravasation at the repair site, the catheter is removed and the patient resumes normal voiding. Further follow-up is at 3 months and then annually.

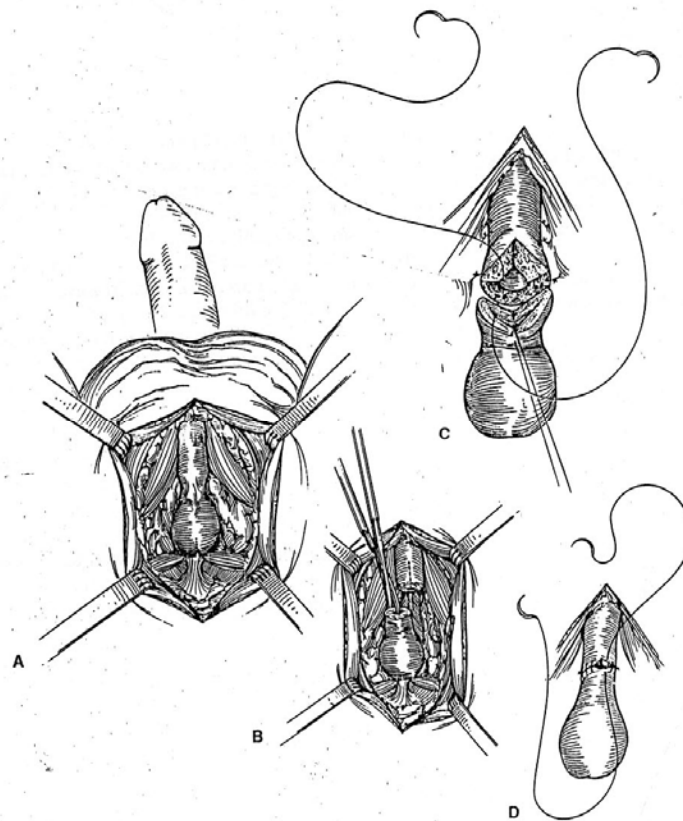
Bulbar urethral Stricture Repair

Anastomotic Urethroplasty

Strictures in the bulbar urethra are most often of traumatic origin from straddle injury, endoscopic instrumentation, or catheterization. When the less than 1 cm in length, these are best repaired with primary anastomosis following excision of the stricture.

The patient is placed in the lithotomy position with the buttocks at the edge of the table. We have not found any exaggeration of this position to be necessary. Following retrograde injection of methylene blue into the urethra, a lambda incision is made 2 cm above the anus to the base of the scrotum. Subcutaneous tissue is divided using cautery to expose the underlying bulbospongiosus muscle. The bulbospongiosus is incised sharply in the midline and separated from the underlying bulbar urethra. Circumferential mobilization of the bulbar urethra is facilitated by sharply dividing the reflection of Buck's fascia lateral to the urethra where it drapes over the corporal bodies just proximal to the crus. A space deep to Buck's fascia and between the separating corporal bodies is entered on each side, and a right angle clamp can then be passed over the roof of the urethra to commence the dorsal dissection. This dorsal dissection, separating the urethra from the corporal bodies, is then

continued sharply until the entire strictured urethra has been mobilized. Further mobility of the proximal bulbar urethra is obtained by dividing the ventral attachments to the perineal body.



Anastomotic repair of bulbar urethral stricture that may follow straddle injury. (A) The urethra is exposed through a midline perineal incision and the stricture site identified and excised. (B) Following stricture excision apposing spatulations of 1 cm are accomplished. (C) The distal urethral opening is spread-fixed to the underlying corporal body and spatulated anastomosis performed with interrupted sutures. (D) The anastomosis is completed and additional tension-relieving sutures between urethral adventitia and adjacent corporal bodies are placed to avoid anastomotic tension during erection.

A 16-Fr catheter is advanced to the strictured segment and the urethra transected at this point. The strictured segment is excised proximally to expose healthy urethral tissue. It should be emphasized once again that complete removal of fibrotic tissue with exposure of healthy proximal and distal urethra is essential for successful repair, but no more than 1 cm of urethra should be excised. If the urethral ends appose in a tension-free fashion they are spatulated sharply for 1 cm. The proximal urethral segment is spatulated on its dorsalside and the distal end on the ventral aspect. Using 4-0 interrupted

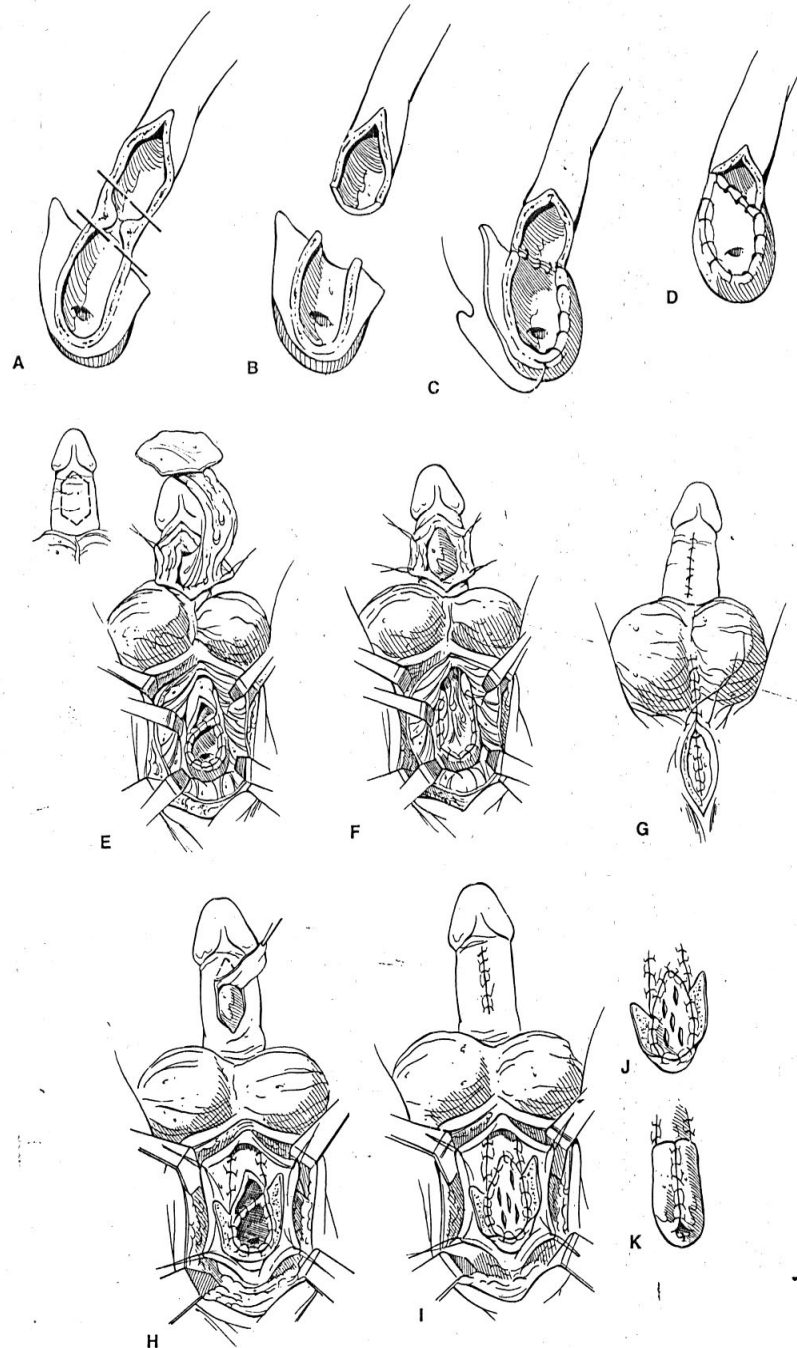
PGA suture the dorsal aspect of the distal urethra is spread-fixed to the underside of the tunica albuginea of the corporal bodies to anchor and stabilize the anastomosis. Circumferential full-thickness anastomotic sutures of 4-0 PGA complete the repair by approximating the proximal spatulated urethra to the spread-fixed distal segment. A 16-Fr silastic catheter, fenestrated in the bulbar portion, is used to stent the repair.

Jackson-Pratt suction drain is placed in the perianastomotic space and the soft tissue closed using interrupted 3-0 PGA suture. the bulbospongiosus and subcutaneous connective tissue are approximated in the midline in two layers with interrupted 3-0 PGA suture. Final skin closure is made with a running subcuticular 4-0 PGA suture. The perineum is dressed and bolstered with fluff gauze. A 14- to 16-Fr Foley catheter is placed to stent the repair and is secured to the abdominal wall to minimize traction and pressure on the urethra. It may be removed between 7 and 14 days postoperatively and ideally its removal is preceded by a pericatheter urethrogram to ensure an absence of extravasation.

Augmented Anastomotic Urethroplasty

Bulbar urethral strictures of more than 1 cm in length cannot be repaired by the above anastomotic procedure without the risk of causing some penile, chordee. Excision of 1cm or urethra and a subsequent 1-cm spatulated repair results in a total of 2 cm of urethral shortening an amount that can be easily accommodated by the elasticity of the mobilized urethra. Note that the distal urethra should only be mobilized to the suspensory ligament of the penis. If a 2-cm stricture is excised and a 1-cm spatulated anastomosis performed, the


total shortening would be 3cm, and this is excessive. Hence, a variety of other options may be used for strictures that are 1 cm or more in length.



Augmented roof strip anastomotic repair. (A-D) A healthy roof strip of urethra is created by stricture excision and roof strip reanastomosis. (E-G) An appropriately sized and shaped island of ventral penile skin is mobilized on its vascular pedicle, tucked through the scrotum, and sutured over the anastomosis augmenting its caliber. (Closure is in layers.) (H-K) This series illustrates the augmented roof strip anastomotic repair using a fenestrated full-thickness skin graft from the ventral penile shaft rather than a pedicled island of penile skin.

For strictures of upto 2 cm in length, stricture excision and augmented anastomotic repair is a good option. This procedure is similar to the above technique (anastomotic urethroplasty), the 2-cm segment being excised, but the urethra is then spatulated proximally and distally for 1 cm into healthy urethra on the same side, i.e. at the 6 o' clock position (ventral spatulation). The unspatulated dorsal urethral ends are then approximated end-to-end in a spread-fixed fashion, securing the anastomosed urethral roof strip to the overlying corporal body. The anastomosis is not completed circumferentially, resulting in a diamond-shaped ventral urethral defect into which is laid either a graft of penile skin or buccal mucosa or, alternatively, a diamond-shaped flap of penile skin mobilized on a pedicle through the scrotum. This repair is called an augmented roof strip anastomosis while augmenting the anastomotic site with a graft or flap. Total penile shortening is limited to 2 cm, which is acceptable. This repair may also be performed as a floor strip anastomosis, placing the augmenting graft on the dorsal aspect where it is spread-fixed to the overlying corporal body. This may be a superior technique in that the spread fixation of the augmenting graft reduces the risk of shrinkage and enhances graft take because of the apposition to the corporal body. These repairs are stented with a 16-Fr silastic Foley catheter and the perineal area is drained with a suction drain. Closure is routine and postoperative care is similar to that to the previous technique. If a graft is used, catheter removal is deferred for 3 weeks following surgery and is preceded by urethrography.

Onlay Bulbar Urethroplasty



The dorsal onlay graft bulbar urethroplasty. (A) Exposure of the urethra. (B, B1) Fenestrated graft sutured to under surface of corporal body. Strictured portion of urethra either excised or rotated. (C) Suture of opened urethra to dorsal onlay graft. (D) Completed repair.

In the case of more extensive bulbar strictures which are usually of inflammatory etiology, it is rarely possible to complete any type of anastomotic repair without causing significant penile chordee and tension on the anastomosis. In these situations we have found success using a free skin graft onlay applied to the dorsal aspect of the strictured portion of the bulbar urethra. The urethral bulb is exposed circumferentially in the fashion previously

described. A 16-Fr catheter is advanced to the site of narrowing and the urethra rotated 180 degrees to expose its dorsal aspect. Stay sutures of 4-0 silk are placed along the exposed dorsal aspect and the urethra is then incised along the strictured segment in the 12 o' clock (dorsal) position, extending the incision into healthy urethra proximal and distal to the stricture. Confirmation of proximal and distal patency is confirmed with a 26-Fr bougie à boule/ A suitable skin donor site is selected on the ventral penile shaft or prepuce and a graft harvested. The graft is spread fixed on a paraffin block and defatted using scissors. It is then fenestrated with a scalpel, and sized and shaped to fit the defect created by urethral incision. This graft is anchored in a spread-fixed fashion to the corporal bodies opposing the dorsally incised strictured urethra using 4-0 interrupted PGA suture. The urethra is then rotated back to its normal anatomic position and the margins of the urethral incision sutured to the fixed graft edge and corporal body using interrupted 4-0 PGA suture. In this fashion, the dorsal graft becomes the new urethral roof, augmenting the urethral caliber at the stricture site. A 16-Fr Foley catheter with fenestrations at the graft site placed and the wound closed in three layers as described. This dorsal approach mitigates blood from a ventral bulbar incision and provides excellent graft stabilization.

Panurethral Stricture or Failed Urethroplasty

The management of extensive stricture of the anterior urethra involving both the pendulous and bulbar portions can be challenging. These are usually of inflammatory origin and can be upto 20 cm in length. Urethral repair in these circumstances is undertaken either by combination repairs using grafts

and flaps or by multistaged repairs that may also use perineal inlays of full or split-thickness skin graft.

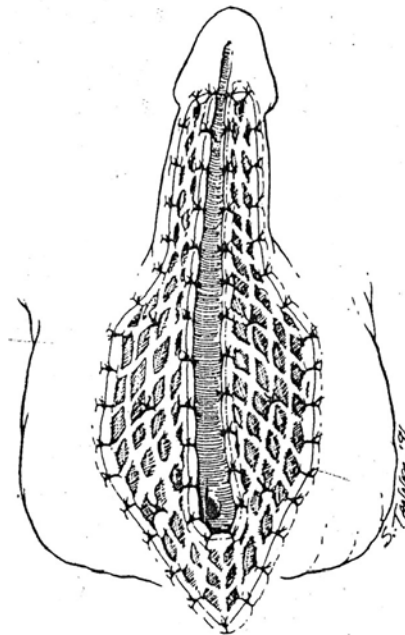
One-Stage Combination Urethroplasty

One-Stage combination procedures make use of both a flap repair, as described previously for the pendulous portion of the urethra, and a skin graft repair, as described for the bulbar area, with the two procedures being performed in continuity. The patient is placed in the lithotomy position for access to the perineum as well as the penile shaft. In the uncircumised male the prepuce can be used as a skin graft donor site, leaving the remaining shaft skin for island pedicle flap construction. If the prepuce is absent, a careful assessment of stricture length must be made in order to deploy penile shaft skin most effectively for the repair. In the event there is insufficient penile skin an alternate donor site such as buccal mucosa is used for the graft repair of the contiguous scrotal/bulbar urethra.

A ventral incision is made over the pendulous urethra and this portion of the stricture is repaired using a ventral onlay repair in the fashion of Orandi, as described earlier. The more proximal scrotal and bulbar portion of the stricture is then repaired in continuity by a dorsal or ventral onlay graft of penile skin or buccal mucosa. This portion of the repair is approached through a separate incision in the perineum for exposure of the bulbar urethra. This onlay may be performed either dorsally or ventrally, although our preference is for the former because of improved stabilization of the graft. If a dorsal onlay is used, the bulbar urethra is circumferentially mobilized as far distally as the proximal

limit of the penile flap repair and the urethra is then incised dorsally through the stricture, with the distal limit being the visible ventral onlay. A dorsal onlay graft is completed as described earlier using 4-0 PGA suture. Hence, the long stricture is repaired by an onlay flap for the pendulous portion and an onlay graft for the more proximal portion, with the procedures being completed nose to tail. Wound drainage is established with a fenestrated suction drain. A 16-F silastic Foley catheter fenestrated in the bulbar region is left in place for 3 weeks.

Staged Repair



Staged urethroplasty for full-length stricture disease using meshed split-thickness skin graft. The meshed graft is laid alongside the marsupialized urethra so that the urethra will be tubularized from the graft rather than from the scrotal skin. Tubularization of the neourethra is delayed for 2 to 6 months.

Extensive anterior urethral stricture disease, particularly full-length stricture, stricture complicated by fistula, inflammation, etc., long recurrent stricture following prior failed repairs and in the absence of a good donor site for urethral substitution, are best managed by staged procedures. Historically,

such repairs were [performed as scrotal inlay procedures; however, the resulting neourethra was then formed scrotal skin, which has proven to give suboptimal results. Variations on this theme now inlay fenestrated full-thickness preputial or split-thickness thigh skin alongside the marsupialized urethra in the first stage so that the urethra is ultimately made from this tissue in the second stage. Full-thickness skin is superior for this purpose but is not often available in communities in which circumcision is common. Split-thickness skin is generally harvested from the inner thigh, which is easily accessible with a patient in the lithotomy position. The strictured anterior urethra is exposed through a ventral perineal midline perineal incisions that may even bifurcate the scrotum and it is incised along the length of the stricture to healthy spongiosal tissue proximally and distally. This is checked by calibrating the urethra with 28- and 24-Fr bougie à boule, which should pass easily through the proximal and distal ostia, respectively, at the limit of the urethrotomy. Using a dermatome set to 20 thousandths of an inch a thick-split thickness graft is harvested from the thigh and meshed to a ratio of 1:1.5. A strip of meshed graft measuring 3 to 5 cm is then inlayed around the marsupialized strictured urethra. Medially it is sutured to the incised urethral margin and laterally to the incised scrotal and perineal skin edges using 4-0 PGA. This width to graft allows for the up to 50% shrinkage that may occur without leaving too little skin for second-stage urethral tubularization. A suprapubic tube is placed for urinary diversion in the postoperative period and the graft is dressed with an Adaptic gauze and sterile cotton fluffs soaked in Bunnell's solution. The penis is kept on the abdominal wall and erection prophylaxis is administered. The donor site is covered with xeroform gauze and

heat lamp application begun on the second postoperative day. The patient is mobilized with care the day after surgery.

Completion of the repair is delayed for at least 12 weeks to allow thorough vascularization of the skin graft. The proximal and distal urethral openings should again freely calibrate to 28 and 24 Fr, respectively, prior to second-stage closure. If the ostia have narrowed, revision rather than dilation should be undertaken, usually using a Y-V advancement technique. Second-stage repair is begun by incising the graft circumferentially to approximately 28-Fr. The tubularization is performed by midline anastomosis using 4-0 PGA running suture, interlocking every third pass. A fenetreated 16-Fr silastic Foley is placed and the wound closed in layers using 4-0 PGA interrupted suture.

MATERIALS AND METHODS

Retrograde Urethrogram - 60% meglumine diatrizoate 10ml + 10 ml of normal saline was loaded in a 20cc syringe with a small cannula fixed to the nozzle, the tip of which was placed in the meatus contrast injected and overhead film exposure made with the patient in 45 degree oblique position, lying on either side and the dependent thigh acutely flexed.

Sonourethrogram - High frequency linear array transducers 5 MHz and 7 MHz were used to evaluate the urethra. Images obtained in longitudinal and transverse planes by placing the probe on the ventral aspect of penis and perineum. The anterior urethra which passes through the length of penis is not visualized when collapsed, but it imaged when distended by retrograde injection of saline loaded in 20 cc syringe, the nozzle of which is placed in the meatus. With the tip of penis pinched manually. The flow of saline through the urethra was also observed during real time imaging.

(9,2)The pendulous urethra lies in the corpus spongiosum of body of penis, while the central portion known as bulbar urethra extends from urogenital diaphragm to the suspensory ligament of penis at the peno-scrotal junction. The corpus spongiosum comprises of endothelial lined sinusoids, appears homogenous in echotexture surrounded by a thin fibrous layer of tunica albuginea identified as a thin echogenic line. Stricture is identified by narrowing of urethral lumen, nodularity of its margin, echogenicity of corpus spongiosum. With increasing fibrosis the spongy tissue appears hyperechonic and may even exhibit acoustic shadowing.

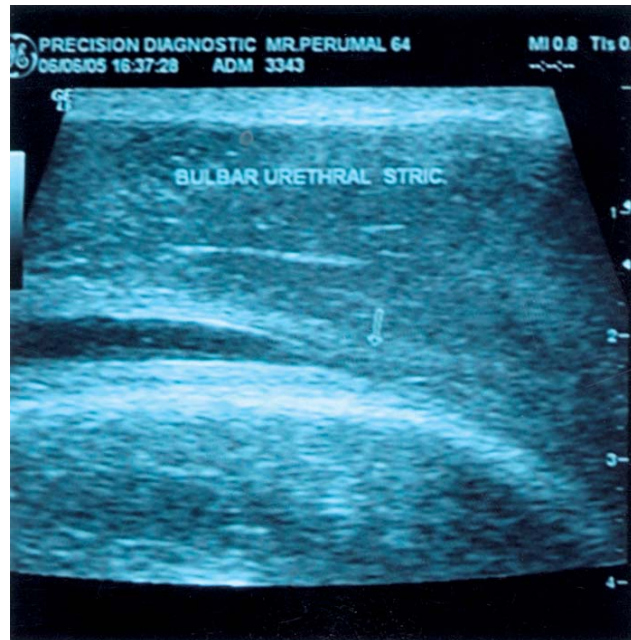
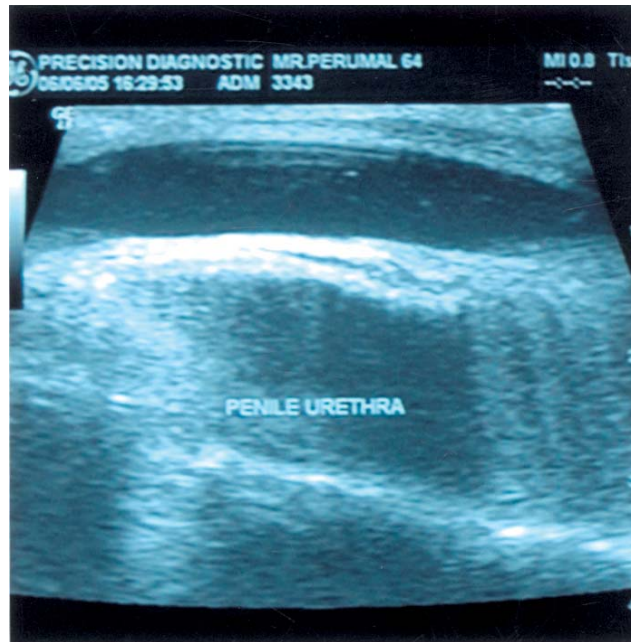(12) A urethral stricture is composed of inelastic scar tissue that forms in response to an insult to the urothelium. The resultant stricture will vary in length and depth of involvement. An evaluation of the depth of the urethral stricture may be made with real-time ultrasound with the urethra filled with lubricating jelly. Devine et al., classified urethral strictures into categories on the basis of depth of invasion into the surrounding spongiosum. Stage A is a mucosal fold, stage B is a small iris constriction not involving the spongiosum, stage C is a full-thickness involvement of the urethra without any underlying spongiosum inflammation, stage D is a full thickness stricture with spongiofibrosis stage E involves inflammation and fibrosis outside of the spongiosum itself and stage F is a complex stricture complicated by a fistula.

The length of stricture, degree of spongiofibrosis, flow of saline thro the posterior urethra into the bladder, intraluminal pathology were noted.

(6) After conventional grey scale imaging to evaluate the extent of disease, the location of bulbourethral arteries was evaluated using doppler USG and later compared to their location in men with normal urethra.

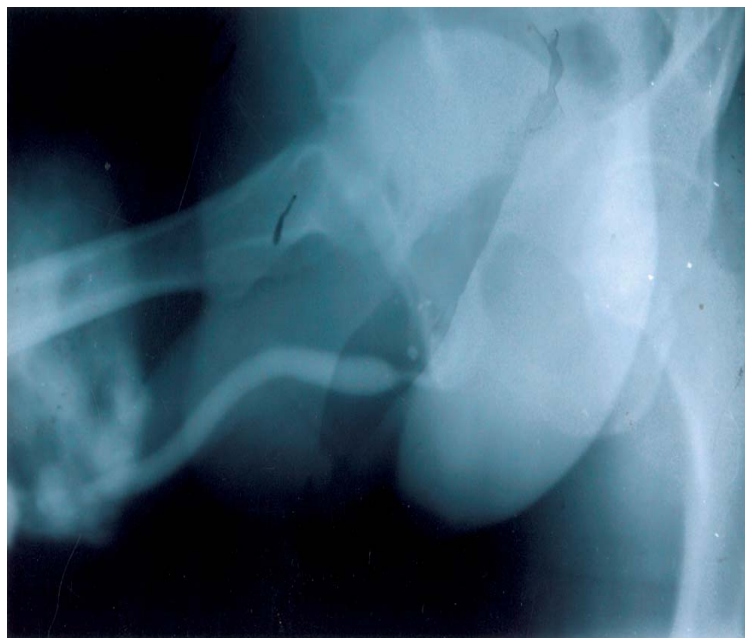This prospective study was done at Government Royappettah Hospital and Kilpauk Medical College Hospital. The study period being January 2004-September 2005.

Culture negative anterior urethral strictures were evaluated first by RGU/CUG followed by sonourethrogram. All cases included in the study were fresh cases with no prior VIVs or urethroplasties. Pelvic fracture urethral distraction defects (PFUDD) were excluded.

Case A. Sonourethrogram and RGU of a case of bulbar urethral stricture

Sonourethrogram showing a soft bulbar strictures with little spongiofibrosis and proximal entry of saline into posterior urethra

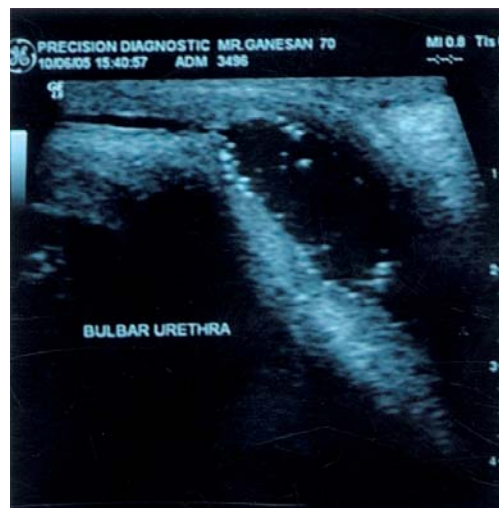
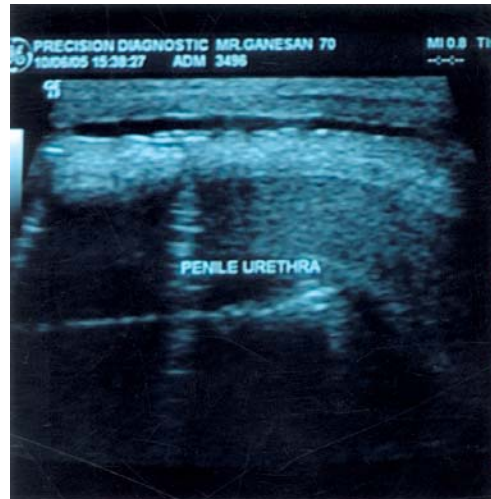Case A.



RGU reveals an annular bulbar strictures

Case B.

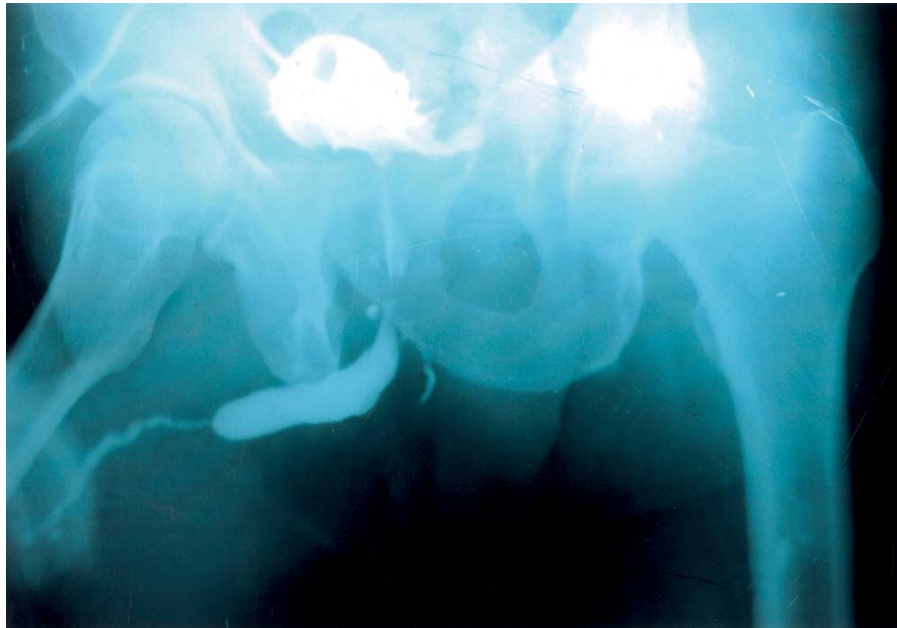
Sonourethrogram



Penile Urethral Stricture with proximal dilatation of the bulb and appreciable saline entry into the posterior urethra

Case B.

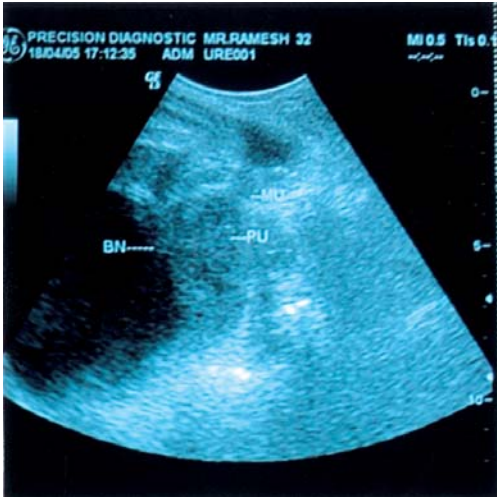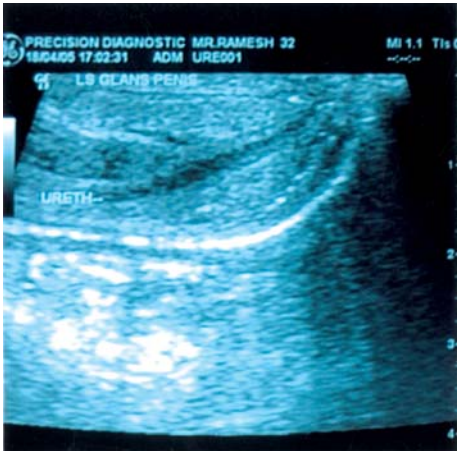
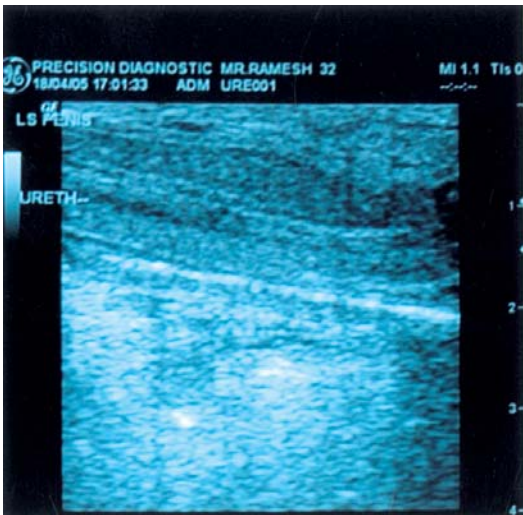
Retrograde Urethrogram



**Penile urethral narrowing with proximal dilatation of bulb
Contrast entry into the bladder**

Case C.

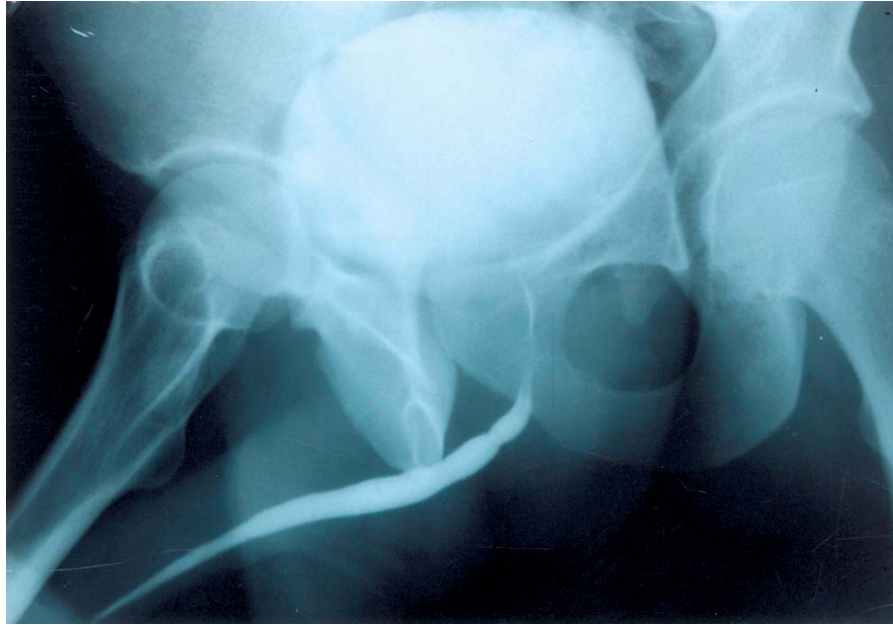
Sonourethrogram



Diffuse narrowing of the entire anterior urethra

Case C.

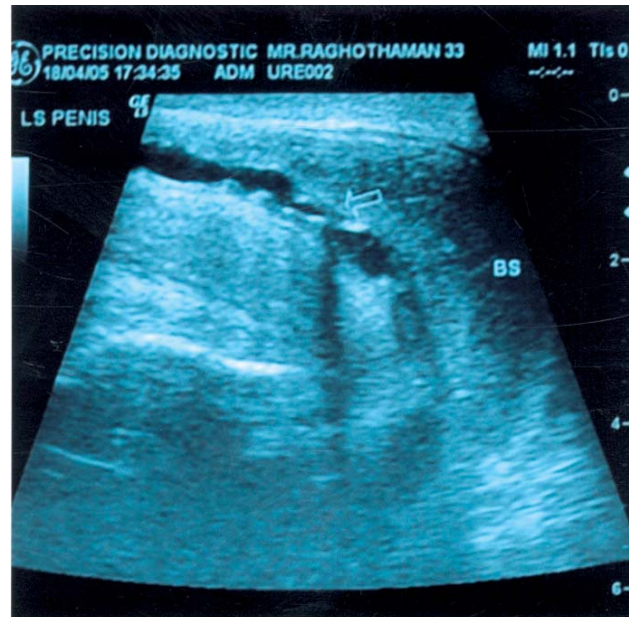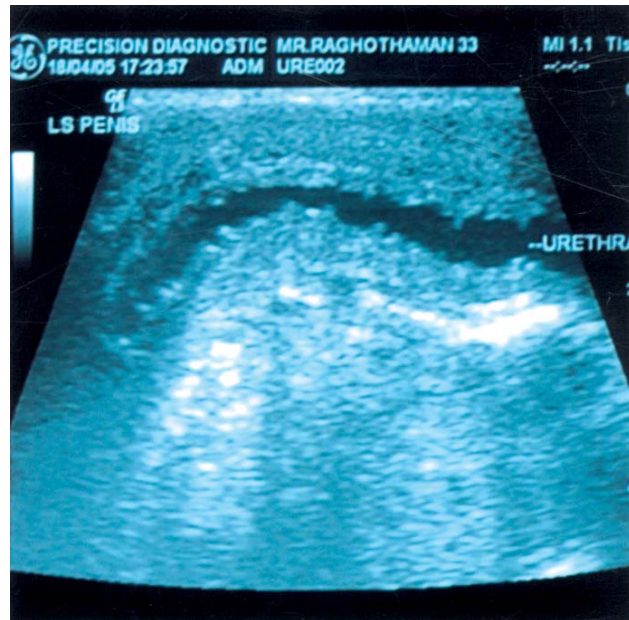Retrograde Urethrogram



Anterior Urethral Stricture

Case D.

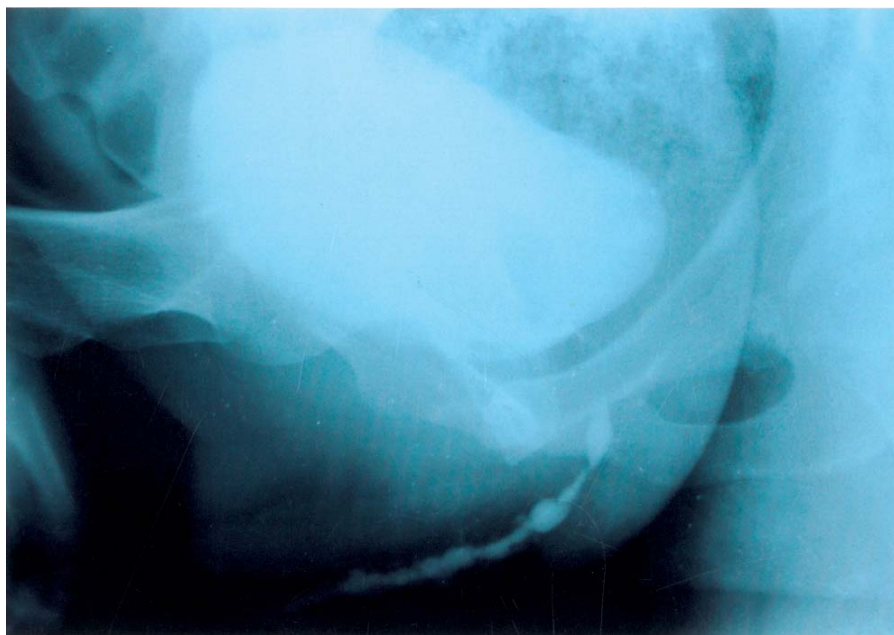
Sonourethrogram



Pan anterior urethral beaded stricture with severe spongiofibrosis in the region of bulb

Case D.

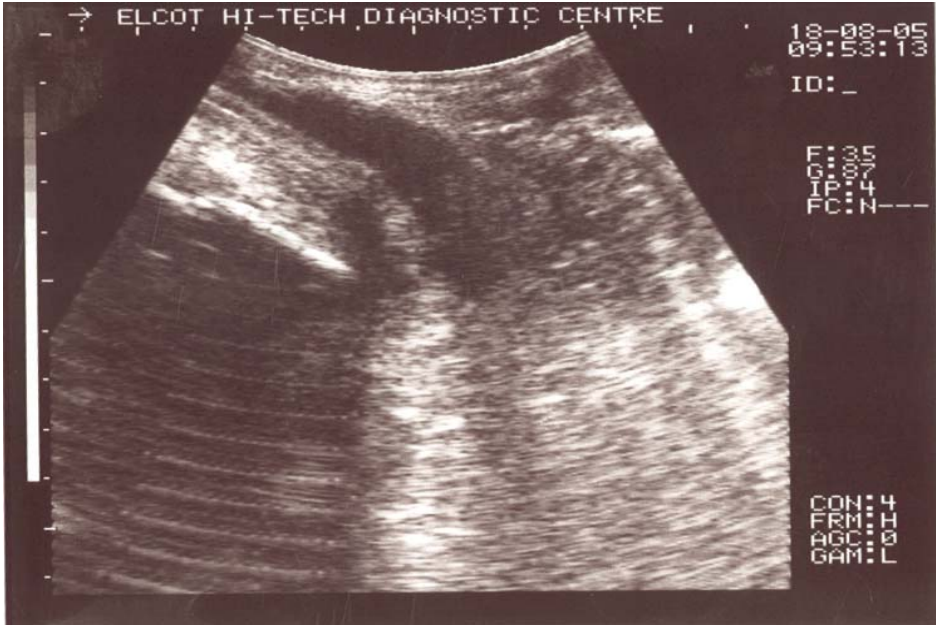Retrograde urethrogram



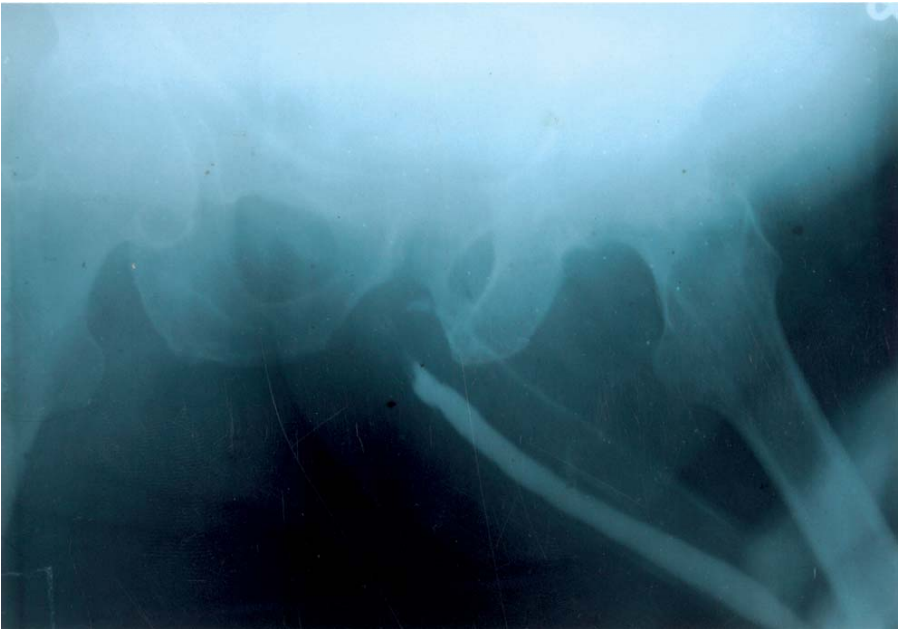Beaded anterior urethral stricture with contrast entry into the bladder

Case E. Blind ending bulbar stricture

Sonourethrogram

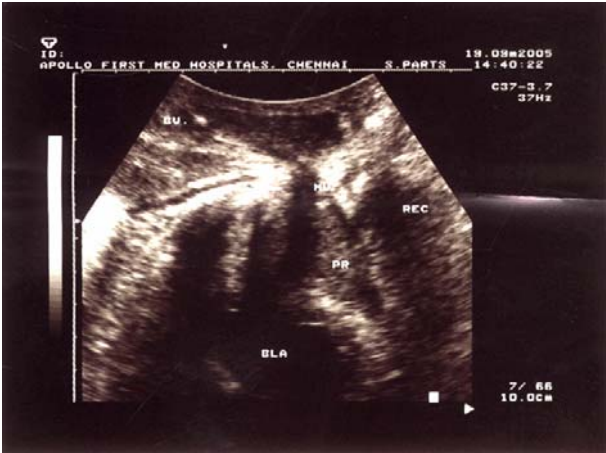
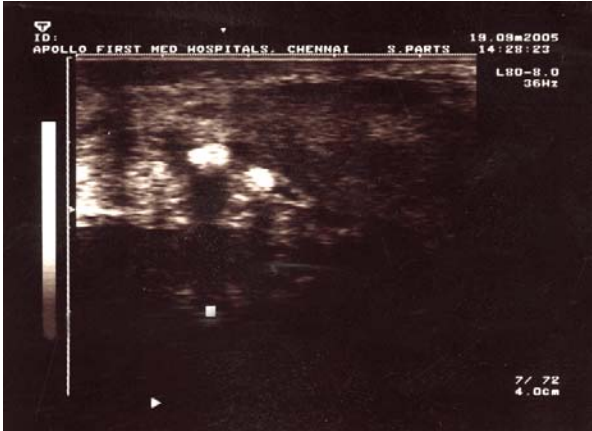
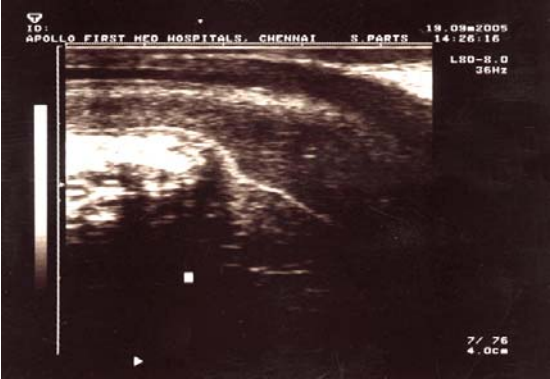
Retrograde Urethrogram



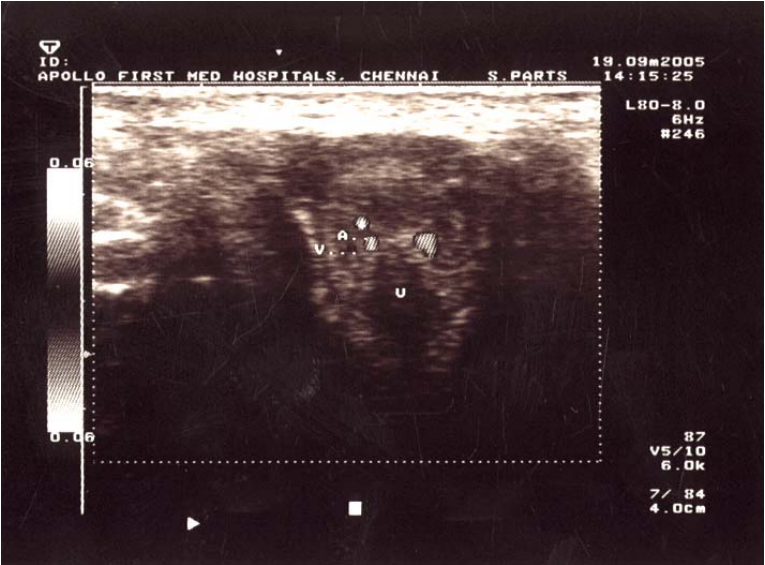
Case F.

Sonourethrogram of a case with pan anterior urethral stricture demonstrating total obliteration of the lumen and severe grades of spongiofibrosis in the region of bulb evidenced by hyperechogenicity with some acoustic shadowing. The length of the stricture shown by sonourethrogram 4.8 cm

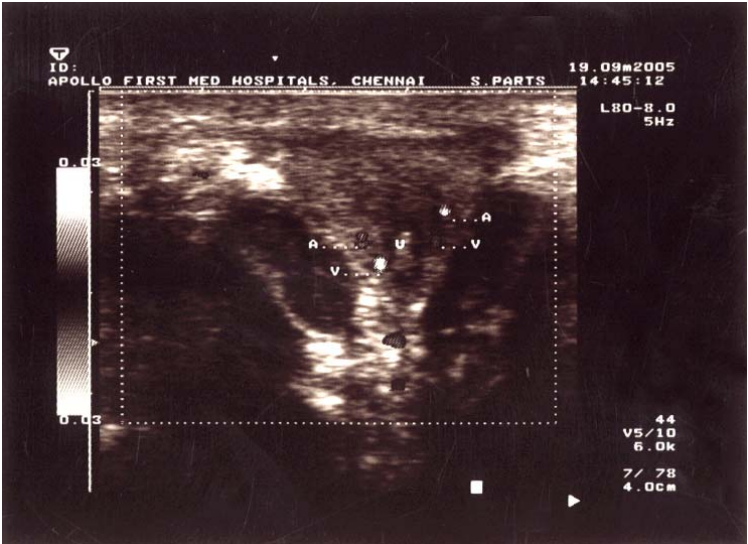

Case E & F.

Doppler ultrasound of Case E (normal urethra) showing symmetry of bulbourethral vessels



Case F. Doppler USG of urethral stricture case revealing asymmetry of bulbourethral vessel



RESULTS

No. of cases studied - 50 cases. The parameters studied being length of stricture, degree of spongiosfibrosis, percentage narrowing of urethral lumen. The results were correlated to urethroscopy - SPC scopy, VIU and urethroplasty findings of the same.

Doppler USG localisation of bulbourethral arteries was done in 15 normal men and 15 men with urethral stricture.

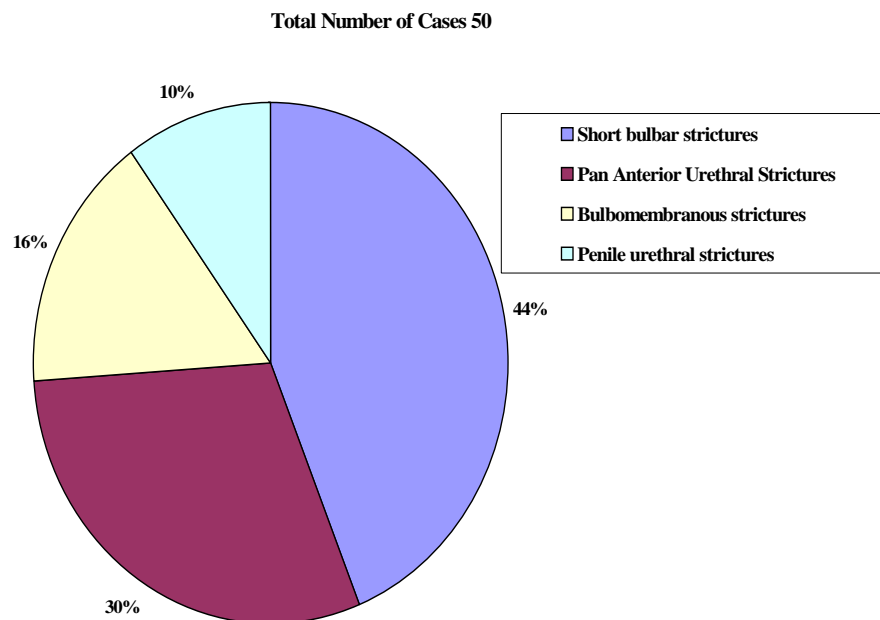
Out of 50 cases studied

Short bulbar strictures - 22 cases

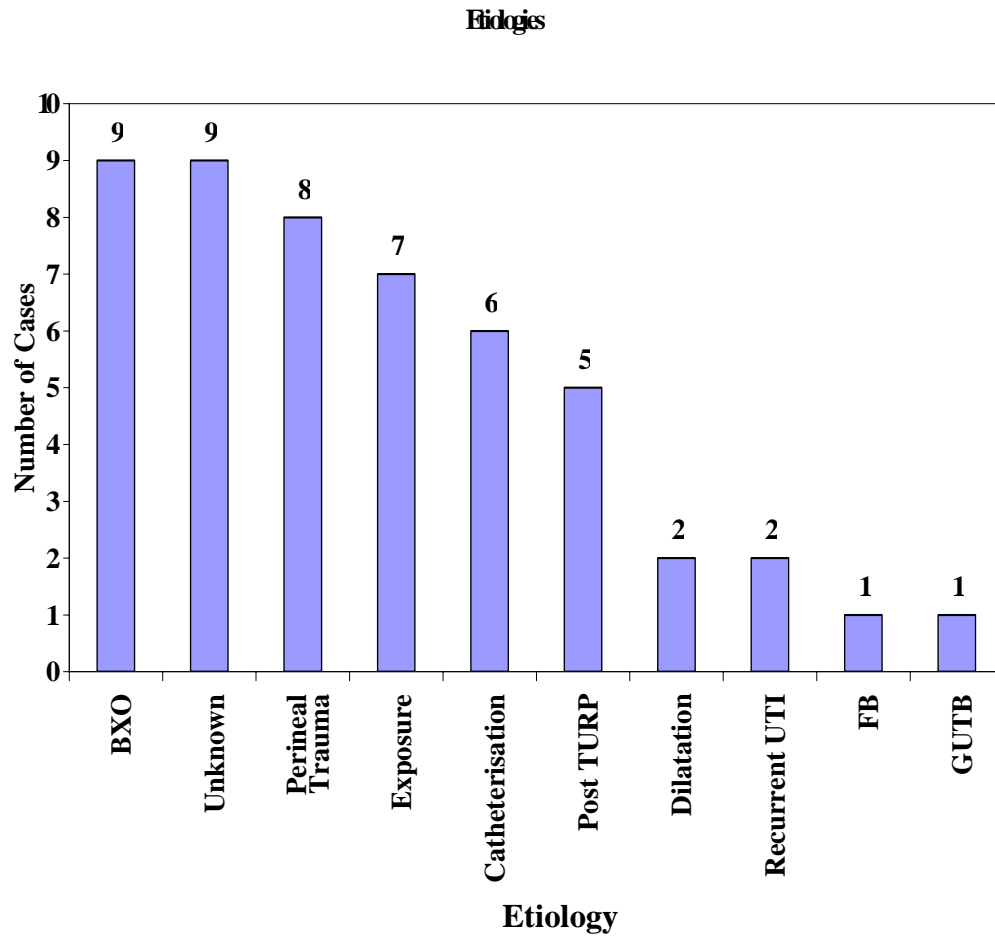
Stricture of pendular and bulbar urethra - 15 case

Bulbomembranous stricture - 8 cases

Penile urethral stricture - 5 cases.



Common etiologies are BXO, post bacterial urethritis sequelae, traumatic catheterisation or long-term indwelling catheters, perineal trauma, post TURP, unknown etiology. One case was associated with extensive GUTB.



BXO	9	Post TURP	5
Unknown	9	Dilatation	2
Perineal Trauma	8	Recurrent UTI	2
Exposure	7	FB	1
Catheterisation	6	GUTB	1

There was no major discrepancy in the length of penile urethral strictures measured by RGU and sonourethrograph, compared with scopy/operative findings.

In bulbar strictures there was a marked discrepancy between RGUs and sonourethrograph findings. Sonourethrograph measured length was more than that detected by RGU in 33 out of 45 cases (73%). Length discrepancy varied between 2mm and 2.5cm. Out of these 33 cases, in 7 cases sonourethrography correctly indicated a reconstructive procedure different from that originally suggested by conventional urethrography.

% narrowing of urethral lumen was measured by the urethral diameter at the area of maximum stenosis and at the normal distal urethra. There was not much of a discrepancy between sonourethrograph and RGU. When there was 74% or more narrowing of urethral lumen outcome of VIU was poor.

The degree of spongiofibrosis which could be identified only by sonourethrograph influenced therapeutic decisions. in 7% of cases. For example in one case RGU revealed a bulbar stricture with negligible proximal contrast entry. Sonourethrograph revealed severe spongiofibrosis evidenced by hyperochoic strictured segment with no appreciable lumen. Instead of trial UIV, anastamotic urethroplasty was done. Peroperatively the excised stricture segment showed near total occlusion of lumen with intraluminal and wall calcification.

All strictures diagnosed by RGU were detected by sonourethrogram also. Out of 50 cases 7 cases showed urethral dilatation proximal to stricture site detectable by both RGU and sonourethrogram.

2 cases had associated diverticulum with diverticular stones, picked up by both RGU and SU. The stones appeared as radiolucent filling defects in RGU and as well defined hyperechogenic intraluminal lesion in SU.

In RGU absent entry of contrast into posterior urethra may be due to sphincter spasm. It may not be possible to repeat the study due to the limited availability of contrast or fluoroscopy/overhead x-ray. Doubt may arise as to whether they are strictures or sphincter spasm in cases which do not demonstrate typical coming. There were 2 such cases in our study. Which when evaluated by SU showed free flow of saline thro the suspected segment which showed no spongiofibrosis and corresponded to membranous urethra abutting the apex of prostate.

The posterior urethra was identified in most of the cases and movement of saline through posterior urethra and entry into the bladder as a jet was discernable in 40% of cases. Technical difficulties do exist in visualizing posterior urethra by transperineal sonar. TRUS would be ideal in men to visualize posterior urethra. In women the entire urethra can be visualised excellently by trans vaginal sonar.

Doppler USG location of bulbar urethral arteries was done in 15 men with normal urethra and 15 men with urethral stricture. Contrary to the popular belief that bulbourethral arteries are located at 3 and 9 o'clock positions, we found that there was no predictable pattern for their anatomy in both normal men as well as in men with urethral stricture. But in normal men and symmetry of bulbourethral vessels was maintained, while in stricture cases there was loss of symmetry. In 2 cases of dense stricture they were identifiable on only one side. The distance of the vessel from the urethral lumen was found to be shorter in stricture cases. In normal urethras the average distance was 2.5mm while in stricture urethras it was 1.9mm. These observations might have implications in treating stricture disease with VIU, as they could help avoid injury to bulbourethral arteries.

DISCUSSION

Sonourethrogram was positive in all cases in which RGU showed strictures, comparable to the study(15) conducted by Ravi Pushkarna, Satish K.Bhargava, Mukta Jain, ultrasonographic evaluation of abnormalities of the male anterior urethra.

In penile urethral strictures there was no discrepancy in the length of stricture measured by RGU Vs SU. Similar to the study(16) by Nash, Peter A, MCAinch, Jack W., Bruce, Jeremy E., Hanks, Douglas K. Published in Journal of Urology 154(1) 72-76 July 1995.

In bulbar stricture the SU measured length was more than RGU measurement length in 33 out of 45 cases (73%). The discrepant length varied between 2mm and 2cm similar to the study(16) by Nash, Peter A, MCAinch, Jack W., Bruce, Jeremy E., Hanks, Douglas K. Published in Journal of Urology Vol.154(1) 72-76 July 1995.

Percentage narrowing of urethral lumen evaluated by RGU and SU showed not much of a difference and when the percentage narrowing was more than 74% VIU outcome was poor comparable to the study(14) conducted by Manhari, Anil, Chaudhury, Mimanshu, Kapoor, Rakesh, Srivastava, Aneesh, Dukey, Deepak, Kumar, Anant Journal of Urology 173(5) 1595-1597 May 2005. **Can outcome of IU for short segment bulbar Urethral stricture be predicted?**

Spongiofibrosis(17) can be detected only by S.U. Even small strictures that have no urodynamic effect can be detected by S.U. Periurethral cuffing is an indicator of poor VIU outcome.

Conclusion of colour Doppler USG localisation of Bulbourethral arteries was comparable to that of the study(13) by Jhekkka Adiyat Kishore, Suresh Bhat & Roy P.John - Colour Doppler USG location of the Bulbo urethral arteries and its impact on surgical outcome published in BJU vol 98 September 2005. Conclusion of the above study revealed that there was no predictable pattern for their anatomy. In men with stricture disease there was loss of symmetry in all cases and the mean distance of the urethral artery. From the lumen urethra was 1.88 mm in stricture cases and 2.6mm in normal urethra. In our study in normal urethra the average distance was 2.5mm and in stricture cases it was 1.9mm.

CONCLUSION

We believe that sonourethrography is a very useful modality in the evaluation of anterior urethral strictures. It is superior to retrograde urethrography in stricture length and spongiofibrosis assessment, which aid in choosing the ideal therapeutic approach. By preoperatively identifying bulbar strictures too long for resection and end-end anastomosis, we may plan for flap or graft procedure. Excision and end-end anastomosis may be planned for strictures appearing sonographically 25mm or less and substitution urethroplasty for longer strictures. Dense strictures as evidence by higher grade of spongiofibrosis and more than 75% luminal narrowing predict poor VIU outcome and in such stricture the bulbourethral arteries lie very close to the lumen and be a source of torrential bleed during VIU.

Sonourethrography is good for the patient for a number of reasons. Multiple examinations are often required in stricture cases and hence reduces exposure to radiation. The 3 dimensional nature of urethra can be appreciated on sonourethrography which is a simple, convenient and rapid investigatory modality. Both cross sectional and longitudinal images can be easily obtained. The procedure is well tolerated by patients, who are protected from the allergic and anaphylactic reactions induced by iodinated contrast extravasation during RGU. Intraluminal filling defects including stones and growth FB, can be visualised by sonourethrography. Subtle changes associated with urethritis are identifiable. Antegrade sonourethrography may come to play a major role in post hypospadias repair cases, where placement of injection port in the neo-meatus may be difficult and descending SU may be more physiological. TRUS or trans vaginal sonar visualisation of urethra and bladder may play a major role in future in the evaluation of voiding dysfunction.

BIBLIOGRAPHY

1. Urology by John Blandy and Christopher Forwel 2nd edition chapter 32 Urethra and penis
2. Clinical ultrasonography a comprehensive test Abdominal and general ultrasound, 2nd edition, vol.2, edited by Hilton B Mere, Cosgrove, Keith, Pat Forrant, pg.655.
3. Grainger and Allison's Diagnostic radiology, 4th edition, vol.3.pg.2293.
4. UCNI May 1996 Urodynamics I, pg.263.
5. Uroradiology illustrated Seung Hyup Kim Chapter 18 urethral diseases Chang Kyu Seong and Lee B.Talner.
6. Clinical USG a comprehensive text Abdominal and general USG, Vol.1 Chapter 6 Doppler.
7. CT and MR imaging of whole body Vol.2, 4th edition John R.Hage, Charles F.Lanzieri. Robert C.Gilkeson Imaging of abdomen and pelvis.
8. Clinical application of doppler USG 2nd edition editor Kenneth Taylor, Peter Burns, Peter Wells, Chapter 2, Instrumentation including colour flow imaging by Peter N.T.Wells.
9. Clinical urography Pollack 2nd edition Vol.1 Chapter 11 USG evaluation of urinary tract Leslie M.Scott, Peter Burns, Janis L.Brown Lynwood Hammers, Arthur, T.Rosen Field.
10. Smith's textbook of endourology vol.2 ch.84, ch.76.

11. Glenn's urologic surgery 5th edition, ch.51 urethral stricture and disruption. E.James Wright and George D.Webster.
12. Campbell's Urology 8th edition, Ch.110 Surgery of Penis and Urethra Gerald H.Jordan MI) Stew M.Schollosshery M.D.
13. Colour Doppler USG localisation of bulbo urethral artery, and its impact on surgical outcome. Thakke Adiyat Kishore, Suresh Bhat, Roy, P.John, BJU Vol.96, Sept. 2005.
14. Can outcome of IU for short segment bulbar urethral stricture be predicted? Journal of urology 173(5) May 2005.
15. USG evaluation of abnormalities of the male anterior urethra Ravi Push Karna, Satish K.Bhargava Mukta Jain Indian Journal of Radiology Image 2000; 10: 2: 89-91.
16. Sonourethrography in the evaluation of anterior urethral stricture Journal of Urology 154 (1) 72-76 July 2005, Nash, Peter A. Jack W. Bruce, Jeremy E. Hanks, Douglas K.
17. McAninch JW, Laing FC, Jaffery B, Jr.; Sonourethrography in the evaluation of urethral stricture: a preliminary report, J Urol.1998; 139: 294-297.
18. Merkle W, Wagner W: Sonography of the distal male urethra - new diagnostic procedure for urethral strictures: results of a retrospective study. J Urol. 1988; 140: 1409-1411.

19. Cluck CD, Bundy AL, Fine c, et al: Sonographic Urethrogram: comparison to roentgenographic techniques in 22 patients. J Urol.1988; 140: 1404-1408.
20. Edward M, Mullin Lloyd J, Paterson & David, Paulson F.Retrograde Urethrogram : diagnostic aid & hazard, J. Urol. 1973; 110: 464-466.
21. Heinenreich A, Derschum W, Bonfig R, Wilbert, D.M. Ultrasound in the evaluation of urethral stricture disease: a prospective study in 175 patients. British Journal of Urology. 1994; 74: 93-98.

APPENDIX - I

Proforma

Period of study Jan 2004 - September 2006. Study done at GRH & KMCH
 Inclusion criteria - Anterior urethral stricture, urine culture sterile, fresh cases with no previous urethral surgery. Exclusion criteria - culture positive, PFUDDs.

Case sheets prepared included the following

Name

Age

I.P.No.

Address

Detailed History including exposure history, TB, perineal and pelvic injury, catheterisation, UTI, urethral bleeding.

Clinical Examination

Lab Investigation

Urine Albumin, Sugar, Deposit

Urine culture sensitivity

Blood Urea, Sugar, creatinine

Hb, TC, DC, ESR, BT, CT.

X-ay Chest, ECG

X-ray KUBU, USG, KUBU

VDRL, HIV

Uroflow

RGU, SU

Appendix - II

I. Pan Anterior Urethral Strictures

	Name	Age	Etiology
1.	Mr.Ramesh	32	BXO
2.	Mr.Ragothaman	33	Catheterisation
3.	Mr.Arumugam	57	BXO
4.	Mr.Sivaji	40	BXO
5.	Mr.Govindan	32	Unknown
6.	Mr.Jaiganesh	29	Unknown
7.	Mr.Alagumuthu	49	Exposure
8.	Mr.Swaminathan	40	Catheterisation
9.	Mr.Somu	46	Recurrent UTI
10.	Mr.Anburose	42	BXO
11.	Mr.Dasavadan	38	BXO
12.	Mr.Govindarajan	35	Unknown
13.	Mr.Ramesh	21	BXO
14.	Mr.Saravannan	32	Exposure
15.	Mr.Gangadaran	35	Unknown

II. Short Bulbar Strictures

	Name	Age	Etiology
1.	Mr.Syed Kaja	68	Unknown
2.	Mr.Perumal	64	Unknown
3.	Mr.Rathnam	70	Unknown
4.	Mr.Rakesh	23	Exposure
5.	Mr.Venkatesh	31	Exposure
6.	Mr.Govindan	35	Unknown
7.	Mr.Venkataswamy	62	Exposure
8.	Mr.Mohan Gandhi	29	Perineal Trauma
9.	Mr.Ramanathan	45	GUTB
10.	Mr.Yasin	18	Perineal Trauma
11.	Mr.Sahul Hameed	64	Catheterisation
12.	Mr.Ramachandran	66	Catheterisation
13.	Mr.Arumugam	56	Dilatation
14.	Mr.Subramani	60	Post TURP
15.	Mr.Abdul Gani	76	Post TURP
16.	Mr.Anbu	42	Recurrent UTI
17.	Mr.Karuppuswamy	55	Dilatation
18.	Mr.Rajamani	62	Perineal Trauma
19.	Mr.Venkatesan	72	Post TURP
20.	Mr.Harun Basha	28	Exposure
21.	Mr.Iyyannar	52	Post TURP
22.	Mr.Radhakrishnan	28	Perineal Trauma

III. Bulbo membranous Stricture

	Name	Age	Etiology
1.	Mr.Thirumal	45	Perineal Trauma
2.	Mr.Dayalan	38	Perineal Trauma
3.	Mr.Sanyam	62	Catheterisation
4.	Mr.Gopal	72	Post TURP
5.	Mr.Karuppaih	32	Perineal Trauma
6.	Mr.Velu	58	Unknown
7.	Mr.Saravanan	38	Exposure
8.	Mr.Palani	22	Perineal Trauma

IV. Penile Stricture

	Name	Age	Etiology
1.	Mr.Natarajan	40	BXO
2.	Mr.Moorthy	22	BXO
3.	Mr.Prehaladan	30	BXO
4.	Mr.Elumalai	32	FB
5.	Mr.Johnson	38	Catheterisation