

DISSERTATION

on

**A Prospective and Retrospective Analysis of Functional
Outcome of Proximal Humeral Fractures Treated with
Proximal Humerus Internal Locking Osteosynthesis
System. (PHILOS)**

*Submitted in
partial fulfilment of requirements
for the award of*

**M.S. DEGREE - BRANCH II
ORTHOPAEDIC SURGERY**

**THE TAMILNADU DR. M. G. R. MEDICAL UNIVERSITY
CHENNAI – TAMILNADU**



MADRAS MEDICAL COLLEGE

CHENNAI – 600003

APRIL 2015

CERTIFICATE

This is to certify that this dissertation titled “**A PROSPECTIVE AND RETROSPECTIVE ANALYSIS OF FUNCTIONAL OUTCOME OF PROXIMAL HUMERAL FRACTURES TREATED WITH PROXIMAL HUMERUS INTERNAL LOCKING OSTEOSYNTHESIS SYSTEM (PHILOS)**” is a bonafide work done by **DR.D.PRAVEENKUMAR**, during the period of his Post graduate study from April 2012 to April 2015 under the guidance and supervision of **Prof. Dr.A.Pandiaselvan. M.S.Ortho., D.Ortho.,** Professor of Orthopaedics, Institute of Orthopaedics and Traumatology, Madras Medical College, Rajiv Gandhi Government General Hospital, Chennai-600003, in partial fulfillment of the requirements for **M.S.ORTHOPAEDIC SURGERY** degree (BRANCH II) Examination of The Tamilnadu Dr. M.G.R. Medical University to be held in April 2015.

Prof.A.Pandiaselvan

Professor,

Institute of Orthopaedics and Traumatology
Madras Medical College

Rajiv Gandhi Govt. General Hospital,
Chennai – 600003

Prof.R.Arunmozhimaran Vijayababu

Director,

Institute of Orthopaedics and Traumatology
Madras Medical College

Rajiv Gandhi Govt. General Hospital,
Chennai -600 003.

Dr.R.Vimala, M.D.,

Dean,

Madras Medical College,

Rajiv Gandhi Govt. General Hospital,
Chennai – 600003.

DECLARATION

I declare that the dissertation entitled “**A Prospective and Retrospective Analysis of Functional Outcome of Proximal Humeral Fractures Treated with Proximal Humerus Internal Locking Osteosynthesis System .**” submitted by me for the degree of M.S is the record work carried out by me during the period of **June 2012 to September 2014** under the guidance of **Prof. Dr.A.Pandiaselvan. M.S.Ortho., D.Ortho.,** Professor of Orthopaedics, Institute of Orthopaedics and Traumatology, Madras Medical College, Chennai-3. This dissertation is submitted to The Tamilnadu Dr.M.G.R. Medical University, Chennai, in partial fulfillment of the University regulations for the award of degree of M.S.ORTHOPAEDICS(BRANCH-II) examination to be held in April 2015.

Dr.D.PRAVEENKUMAR
Post Graduate,
Institute of Orthopaedics
& Traumatology,
Madras Medical College,
Chennai -600003

Place: Chennai

Date:

ACKNOWLEDGEMENT

I express my thanks and gratitude to our respected Dean **Dr.R.VIMALA M.D.**, Madras Medical College, Chennai – 3 for having given permission for conducting this study and utilize the clinical materials of this hospital.

I sincerely thank my Guide **PROF. Dr.A.PANDIASELVAN M.S.Ortho., D.Ortho.**, Professor of Orthopaedics, Institute of Orthopaedics and Traumatology for his efforts, advice, guidance and unrelenting support during the study.

I have great pleasure in thanking **PROF. Dr.R.ARUNMOZHIMARAN VIJAYABABU M.S,Ortho., D.Ortho.** Director, Institute of Orthopaedics and Traumatology, for his guidance and constant advice throughout this study.

My sincere thanks and gratitude to **PROF. Dr.N.DEEN MUHAMMAD ISMAIL M.S,Ortho., D.Ortho.** Professor, Institute of Orthopaedics and Traumatology, for his guidance and constant advice throughout this study.

My sincere thanks and gratitude to, **PROF. Dr.M.SUDHEER M.S.Ortho.,D.Ortho.**, Additional Professor, Institute Of Orthopaedics and Traumatology, for his constant inspiration and advise throughout the study.

My sincere thanks and gratitude to, **PROF. Dr.V.SINGARAVADIVELU. M.S.Ortho., D.Ortho.** Professor, Institute Of Orthopaedics and Traumatology, for his guidance and valuable advice provided throughout this study.

My sincere thanks and gratitude to **PROF. Dr.NALLI.R.UVARAJ M.S.Ortho.,D.Ortho.** Professor,InstituteOf Orthopaedics andTraumatology, for his valuable advice and support.

I am very much grateful to **PROF. Dr. S. KARUNAKARAN.M.S.Ortho.,** for his unrestricted help and advice throughout the study period.

I sincerely thank **Dr.Kingsly, Dr.Kaliraj, Dr.Muthalagan, Dr. Prabhakar, Dr.Senthil Sailesh, Dr. Kannan, Dr.Muthukumar, Dr. Hemanthakumar, Dr.Nalli.R.Gopinath, Dr.Mohammed Sameer, Dr.Sarathbabu, Dr. Pazhani, Dr. Suresh Anand, Dr. Saravanan, Dr. RajGanesh,** Assistant Professors of this department for their valuable suggestions and help during this study.

I thank all anaesthesiologists and staff members of the theatre and wards for their endurance during this study.

I am grateful to all my post graduate colleagues for helping in this study. Last but not least, my sincere thanks to all our patients, without whom this study would not have been possible.

A PROSPECTIVE & RETROSPECTIVE ANALYSIS OF FUNCTIONAL OUTCOME OF PROXIMAL HUMERAL FRACTURES TREATED WITH PROXIMAL HUMERUS INTERNAL LOCKING OSTEOSYNTHESIS SYSTEM

ABSTRACT

INTRODUCTION

Fractures of proximal humerus account for about 4 to 5% of all fractures. It is the third most common fracture after hip fracture and colles fracture in elderly patients. As the technology has advanced, the elderly people no longer need to be denied effective surgical treatment.

AIM OF THE STUDY

In this study we have analyzed 20 cases of proximal humeral fractures treated surgically using PHILOS plates admitted at Institute of Orthopaedics & Traumatology, Rajiv Gandhi Govt General Hospital, Madras Medical College, Chennai from June 2012 to September 2014.

The aim of the study was to analyze the functional and radiological outcome and to assess the complications of proximal humeral fractures treated using PHILOS plates.

MATERIAL AND METHODS:

Patients with proximal humerus fractures, who are skeletally mature and age more than 18 years satisfying Neer's criteria for operative displacement i.e. displacement of >1 cm between the major fracture fragments or angulation of the articular surface of >45 degrees and Neer's two, three and four part fractures were included in the study.

Patients with open fractures, pathological fractures, with associated neurovascular injury and associated head injury were not included. All patients were evaluated with standard anteroposterior radiographs of the affected shoulder and most of them were further evaluated with Neer's three view trauma X rays. CT Scan and 3D CT were taken if needed.

Radiological evaluation of the fractures was done and were classified according to Neer's four part classification system. 12 patients (60%) had two part fractures, 7 (35%) had 3 part fractures and 1(5%) had four part fractures. Fracture dislocations were present in 2 patients. The patients were operated by the standard anterior deltopectoral approach or deltoid splitting approach using PHILOS plates.

All the patients were reviewed at two weeks interval, for first three months and later every month. During follow up, patients were clinically evaluated for pain and function. The minimum follow-up period was 3 months and maximum follow up period was 8 months. Radiological evaluation of fracture union was observed by serial x rays.

RESULTS AND OBSERVATION

Majority of injured patients were females (60%) and the highest number of patients were in their 5th decade (35%). Free fall at ground level was the most common mode of injury (50%) but one patient had post-epileptic fall causing the fracture. No case with bilateral fractures was reported. Neer's 2 part fracture is the most common type in 60% patients. Greater Tuberosity fractures were the predominant type in 2 part fracture. 4 part fractures accounted for only 5% of patients. Fracture dislocation were present in 2(10%)

of patients. Early complications like wound gaping, skin necrosis and deltoid atony were encountered. Late complications like malunion of greater tuberosity and joint stiffness were encountered.

Constant and Murley's score was used to assess the functional outcome of our patients. The average constant score in our study with 20 patients was 82.4.

CONCLUSION

Finally we concluded that displaced proximal humeral fractures when treated surgically produce greater range of movements (ROM), less pain and less stiffness. Functional outcome is better with isolated fractures than with fracture dislocations. Functional outcome of 2 part fractures is better than 3 part and 4 part fractures. Radiological outcome assessed by means of quality of reduction and union of fracture in two and three part fractures is better than in four part fractures.

KEYWORDS

Proximal humeral fractures, PHILOS plates, Neer's classification, Constant score.

CONTENTS

Sl. No.	TITLE	PAGE No.
1	INTRODUCTION	1
2	AIM OF THE STUDY	3
3	HISTORY & REVIEW OF LITERATURE	4
4	ANATOMY OF SHOULDER JOINT	11
5	BIOMECHANICS	25
6	CLASSIFICATION	27
7	MECHANISM OF INJURY	34
8	CLINICO-RADIOLOGICAL EVALUATION	37
9	METHODS OF TREATMENT	45
10	SURGICAL APPROACHES	63
11	MATERIALS AND METHODS	71
12	OBSERVATIONS	80
13	RESULTS	82
14	COMPLICATIONS	93
15	DISCUSSION	104
16	CONCLUSION	111
17	ILLUSTRATIVE CASES	112
18	ANNEXURES EVALUATION FORM BIBLIOGRAPHY PROFORMA ABBREVIATIONS ETHICAL COMMITTEE APPROVAL FORM TURNITIN DIGITAL RECEIPT ANTI PLAGIARISM REPORT PATIENT CONSENT FORM MASTER CHART	126

INTRODUCTION

Proximal humeral fractures account for about 4 to 5% of all fractures^{1,2,3,4,5,6}. It accounts for up to 45% of all humeral fractures⁷. It is the third most common fracture after hip fracture and colles fracture in elderly patients⁸. It is important to recognize these fractures early. Numerous authors have suggested that non operative treatment^{9,10,11} can be acceptable for two, three and four part fractures of proximal humerus in elderly patients but pain, stiffness, loss of function and muscle power have been described in more percentage of patients following this conservative approach.

Fractures of Proximal Humerus have gained more attention recently. Diagnosis has been facilitated with adaptation of 3-right angled trauma series X-rays^{2,12,13,14} supplemented with CT or MRI. With more standard use of Neer's 4-part Classification system for fracture and fracture dislocation, a protocol for management and comparison of long term outcome of similar injuries has been made possible^{15, 16, 17}.

Emphasis is placed on complete and accurate diagnosis and formulation of safe and simple standard techniques for fracture realignment, restoration of anatomic stability, fracture healing, cuff integrity, regaining movement and function.

There have been improvements in fixation techniques and in the understanding of the role of prosthetic replacement^{19,20,21,22} to maximise anatomic restoration and minimising immobilisation time, during which period stiffness develops.

The elderly people no longer need to be denied effective surgical treatment, especially at a time in life, when the shoulders are often needed for ambulation with canes and crutches. Maintenance of good shoulder function will surely make a good difference to their independent life style.

In this study we have analysed the functional and radiological outcome of twenty (20) cases of proximal humeral fractures treated surgically using PHILOS plates. (Proximal Humerus Internal Locking Osteosynthesis System)

AIM OF THE STUDY

1. To analyze the functional and radiological outcome of twenty patients with proximal humeral fractures treated using PHILOS plates.
2. To assess the complications of proximal humeral fractures treated using PHILOS plates.

REVIEW OF LITERATURE

Historical Review

Fractures of proximal humerus were first documented by Hippocrates⁷ in 460 BC. He also described a method of weight traction that aided bone healing. However, till the end of 19th century, knowledge about this fracture was less.

Kocher introduced an anatomic classification of proximal humerus fractures in 1896 in an attempt to improve the diagnosis and treatment but this was not descriptive enough and it lacks consistency.

In 1893 Pean described the first prosthetic arthroplasty of the shoulder joint. He replaced the proximal part of the humerus in a young man who had TB involving the shoulder joint with a platinum and rubber prosthesis.

During the early 20th century, various methods of closed reduction, traction and abduction splints were developed to achieve and maintain alignment of these fractures with inconsistent results.

In 1932, Roberts reported that the use of conservative treatment and prolonged immobilization was less satisfactory than treatment with simpler forms of fixation and early motion. During the same period open reduction and definitive fixation of severely displaced fractures and with dislocations gained importance in an effort to gain better anatomical alignment and functional restoration.

The first systematic approach of surgical fixation for proximal humerus fractures was described by Lane and Lambotte. Subsequently, other surgeons described many methods of surgical repair and fixation of proximal humeral fractures including percutaneous pins, blade plates, intramedullary nails, plate and screws and tension band fixation.

Codman during the year 1934 divided the fracture into four parts namely, Head, Greater Tuberosity, Lesser Tuberosity and Shaft along epiphyseal lines. This became the basis of Neer's classification of fractures of proximal humerus.

During the year 1949, Widen first reported on Intramedullary Nailing of transcervical fractures of proximal humerus and credited Palmer with the development of the technique.

In 1950, Rush described his methods of intramedullary nailing which later became popular as rush pins.

In the early 1950s, use of humeral head prosthesis was first described for fractures of proximal humerus. The original Charles Neer I prosthesis was designed in 1951.

In 1955, Neer reported good results with the use of metal humeral head prosthesis in 27 patients with dislocation.^{22,23}

In 1970, Charles Neer of Newyork proposed his classic 4 part classification based on Codman's 4 parts.

In early 1970's AO ASIF group popularised the use of AO plates and screws for displaced fractures and fracture dislocations.

In 1972, Bichel designed a Total Shoulder Prosthesis of the ball and socket type²⁴. In the same year, the Stanmore Total Shoulder Replacement, also a Ball and Socket design was developed for patients with Rheumatoid Arthritis²⁴.

In 1973, the original Neer I prosthesis was revised by Neer, as Neer II prosthesis, to improve the results.

Newer prosthesis like Grammont reverse shoulder prosthesis has been designed for even better function.

Percutaneous pinning and minimal fixation have now become the order of the day with principles of biological fixation.

Recently, a new concept has evolved in treating osteoporotic fractures. Fixed angle stable locking plates have been developed which lock screws to the plate and hence forms fixed angle construct.

Controversies still exist whether to do conservative or operative management. The recent trend is to surgically treat the patients with locking compression plates. Various studies have been done on this.

A total of 72 patients were studied retrospectively by Jan -Magnus Bjorkenheim. The patients were followed for a period of 12 months. All of them had fracture of the proximal humerus treated surgically with PHILOS plates between February 2002 to January 2003. Constant Score was used and it was inferred that the final functional outcome was better even in geriatric patients. 2 patients had non union and 3 patients developed humeral head avascular necrosis. Two patients had

failure of implants. The final interpretation was made that the PHILOS method was safe and can be advised for the treatment of these fractures in patients with reduced mineral density of bone²⁵.

C.P.Charalambous et al in 2007 analysed a total of 25 cases of fractures of Proximal humerus treated with PHILOS plates. 20 patients were found to have fracture union with an average neck shaft angle of 127.2⁰. Five cases needed revision surgery for failure to unite or failure of implant. Author concluded that PHILOS plate is effective for giving fracture stabilization but knowledge of potential hardware complication is essential²⁶.

Kenmal A. Egol²⁷ (2008) conducted a retrospective analysis of 51 patients with fracture of proximal humerus managed with PHILOS plates between February 2003 and January 2006 with a minimum follow up of 6 months. Out of this, 12 patients (24%) developed complications with a success rate of 76%.

MA Fazal, FS Haddad (2009) conducted a prospective study of 27 individuals with displaced proximal humerus fractures

managed with PHILOS plate fixation. All fractures were united except for one patient who developed a complication of screw penetration with subsequent failure to unite and avascular necrosis. The study concluded that fixation with PHILOS plate provided stable fixation, less hardware problem and helped to attain early range of motion²⁸.

AA Martinez (2009), conducted a retrospective study of 58 patients (31 males & 27 females) in the age group 36 to 73 (average 61) years with fractures of proximal humerus treated with PHILOS plates with a follow up of 1 to 1 1/2 years. All patients had satisfactorily healing of fractures. One patient with a valgus 4 part fracture had malunion. Outcome was extremely good in 13 patients, good in 36 patients, moderate in 8 and poor in one. Average Constant Murley score was 80. The study concluded that PHILOS plate fixation was an appropriate treatment for Proximal humerus fractures²⁹.

Agarwal et al, 2010 conducted a prospective study of 56 cases having an acute fracture of proximal humerus treated with PHILOS plates with follow up for 2 years. 47 patients were evaluated by Constant Murley score. Final outcomes were excellent in 17% of patients, good in 38.5% of patients, moderate in 34% of patients and poor in 10.5% of patients. Constant Murley score was

poorer for AO, OTA type 3 fractures. The study concluded that PHILOS plates produced good functional outcome. Results were better than non-locking plates in osteoporotic fractures of the geriatric age group³⁰.

Rose et al (2007) evaluated the use of PHILOS plates in 16 patients aged around 51 years. The study group consisted of 5 two part, 9 three part and 2 four part fractures. Out of the fractures that healed, good functional outcome was made out (average elevation 132 degrees, average external rotation 43 degrees) within an average follow up of one year³¹.

In 2008, Andrew H.Crenshaw Jr, Edward A. Perez in their study concluded that in young patients, internal fixation with PHILOS plates are successful if damage to humeral head blood supply is avoided by keeping soft tissue stripping to a minimum. In young, active patients with four part proximal humeral fractures, fixation with PHILOS plates is the management of choice³².

ANATOMY OF THE SHOULDER JOINT

Developmental Anatomy

The ossification of humerus is from 1 primary centre and 7 secondary centres. The primary centre appears in the middle of the diaphysis during the 8th week of development³³. The proximal humeral epiphysis is spherical in shape in infants.

The upper part ossifies from 3 secondary centres, 1 centre for the head (first year), 1 centre for the greater tubercle (second year), and 1 centre for the lesser tubercle (fifth year). These 3 fuse and form epiphysis during the 6th year and this epiphysis in turn fuses with the diaphysis during the 20th year³⁴. The epiphyseal line encircles bone in the level of the lowest margin of the head. This is the growing end of the bone (remember that the nutrient foramen is always directed away from the growing end).

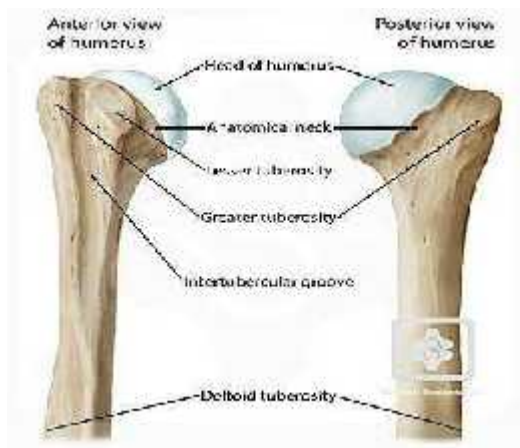The lower part ossifies from 4 centres forming two epiphyses. The centres are as follows: one for capitulum and lateral flange of the trochlea (first year), one for medial flange of the trochlea (9th

year), and one for lateral epicondyle (12th year). Three fuse during the 14th year forming an epiphysis, which fuses with the diaphysis around 16 years. The centre for medial epicondyle appears at four to six years forming a separate epiphysis, and fuses with the diaphysis during the 20th year³⁵.

Relevant Anatomy

Understanding the anatomy of shoulder joint is very important because function of glenohumeral joint depends on correct alignment and interaction of its anatomical structures.

Humerus is the longest and largest bone in the upper limb³⁵. It has an expanded upper (proximal) end called "PROXIMAL HUMERUS", a shaft and a lower (distal) end.



The Proximal Humerus consists of the following:

- Humeral head
- Greater Tuberosity
- Lesser Tuberosity
- Bicipital Groove (Intertubercular Sulcus)
- Proximal Humerus shaft

Head

The head is larger in size than the glenoid cavity and it forms about one third of a sphere. The head which is directed medially, backwards and upwards, articulates with the glenoid cavity of the scapula and forms the shoulder joint. Its articular surface is lined by hyaline cartilage.

Greater Tuberosity

It is a projection which is most lateral on the proximal end of humerus. Its posterior part has 3 impressions; upper, middle and lower into which muscles like supraspinatus, infraspinatus and teres minor are inserted respectively. It is covered by deltoid producing the rounded contourness of the shoulder.

Lesser Tuberosity

It is a projection on the anterior part of the upper end and the multipennate subscapularis muscle gets inserted into it.

Inter Tubercular Sulcus

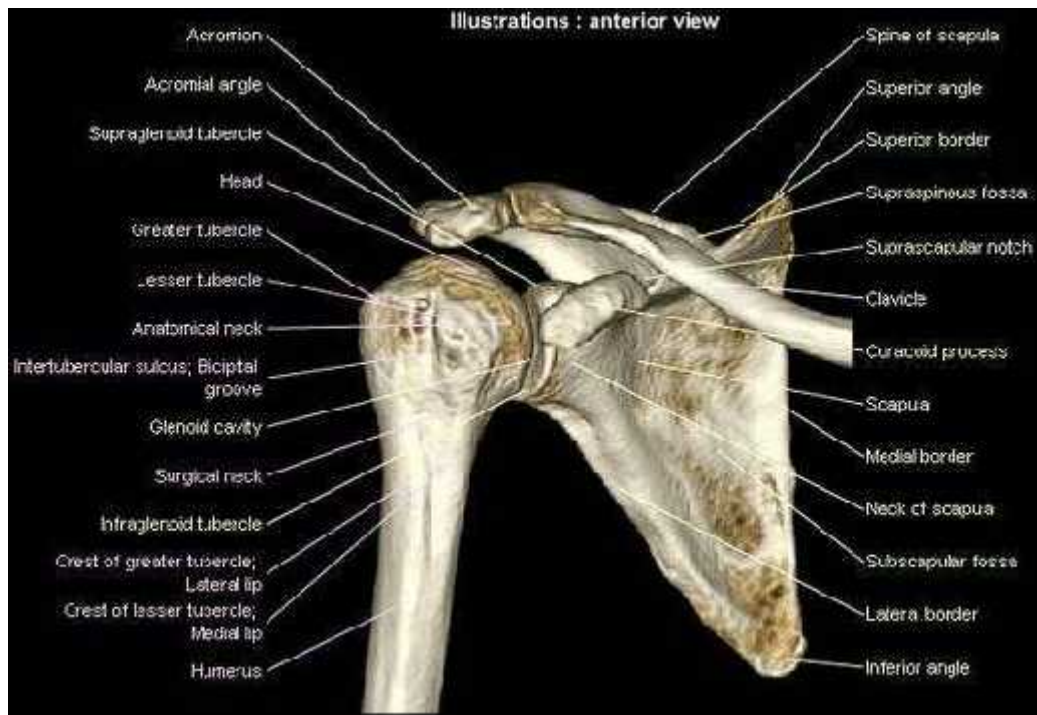
It is also known as bicipital groove. It separates lesser tubercle from the medial side from the anterior part of the greater tuberosity. The sulcus has medial and lateral lips that represent downwardly prolonged parts of the lesser and greater tuberosities. The pectoralis major is inserted into the lateral lip of the intertubercular sulcus. The insertion is bilaminar. The latissimus dorsi is inserted into the floor of the intertubercular sulcus. The teres major is inserted into the medial lip of the intertubercular sulcus^{33,35}. The contents of the intertubercular sulcus are; the tendon of long head of biceps and its synovial sheath and the ascending branch of the anterior circumflex humeral artery. The tendon of long head of biceps is covered by transverse humeral ligament.

Anatomical Neck

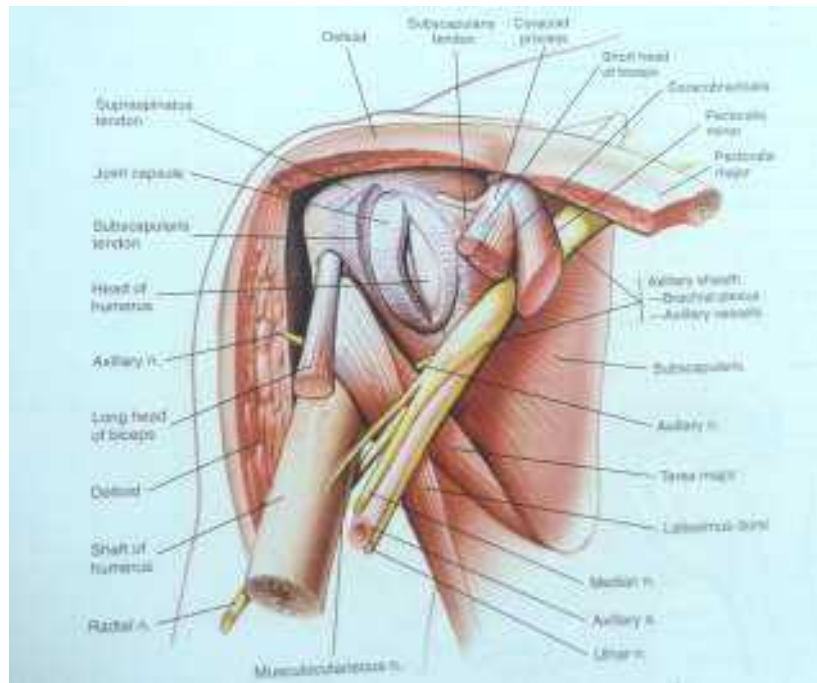
The line delineating the head from the other part of the upper end is known as the anatomical neck. It is a slight constriction, adjoining the articular surface, formed at the meeting point of head and tuberosities. The boundaries are variable without a distinct line.

Surgical Neck

The narrow line which separates the upper end of the humerus from the shaft is known as the surgical neck. It lies below the greater and lesser tubercles.



ANTERIOR VIEW OF THE SHOULDER



ANATOMY OF THE ANTERIOR PORTION OF THE SHOULDER

Glenoid

The Glenoid is a shallow, convex structure which is like an inverted "comma", approximately one third to one fourth of the surface area of the humeral head³⁶. It articulates with the head of humerus and the glenoidal labrum and capsule gets attached to it.

Glenohumeral Joint

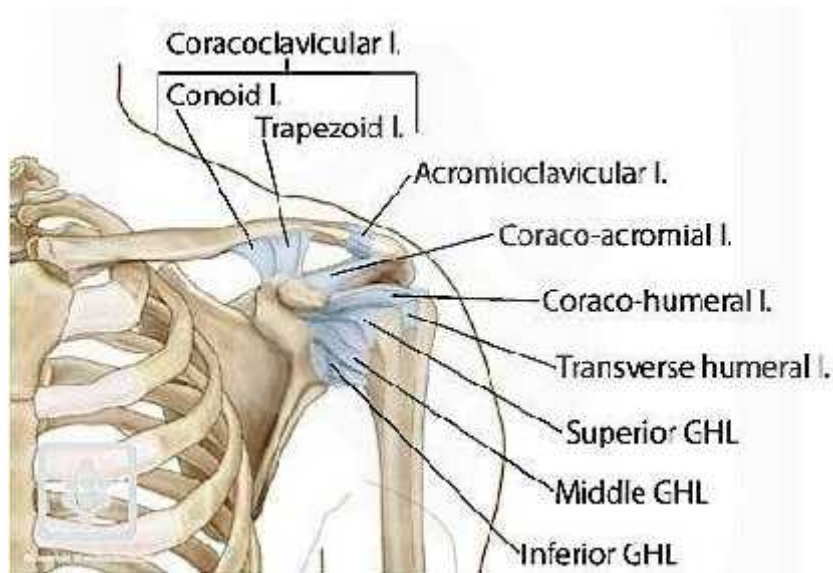
The shoulder joint is a synovial joint of the ball and socket variety³⁷. The joint is formed by articulation of the scapula and the head of the humerus. Therefore, it is also known as glenohumeral articulation. This joint has the greatest range of motion than any other joint in the body.

It is a weak joint structurally because of the small and shallow glenoid cavity which holds the humeral head in place. The humeral head size is four times larger than the size of the glenoid cavity. However this arrangement allows greater range of motion.

The following factors maintains the stability of the joint;

1. The coracoacromial arch or secondary socket for the humeral head.
2. The rotator cuff of the shoulder. (Musculotendinous cuff)
3. The glenoidal labrum, helps in deepening the glenoid fossa.

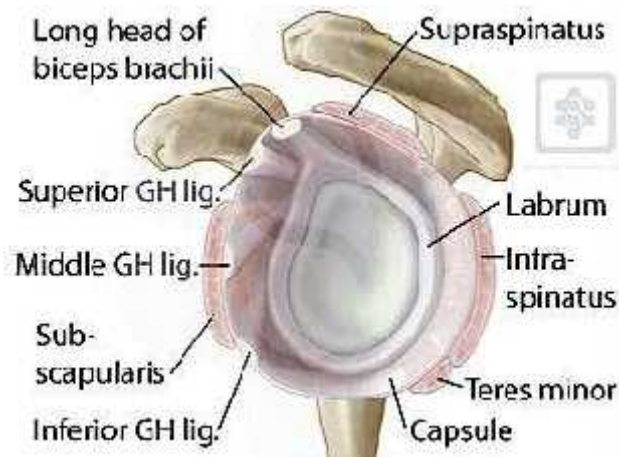
Additional stability is also provided by the long head of biceps, long head of triceps, pectoral girdle muscles and atmospheric pressure.



Stabilizers of the Shoulder Joint

The static stabilizers⁴² of the shoulder joint are

- a) Fibrous capsule
- b) Glenohumeral ligament
- c) Coracohumeral ligament
- d) Transverse humeral ligament
- e) Glenoidal labrum



Stabilizers of the Shoulder Joint

The dynamic stabilizers of the shoulder joint are the musculotendinous cuff of the shoulder or rotator cuff, deltoid, trapezius, serratus anterior, latissimus dorsi, rhomboids and levator scapulae.

The 3 main factors that maintain the dynamic stability of fully developed shoulder joint⁴¹

1. Normal retrotilt of glenoid articular surface in relation to the axis of the scapula.
2. Optimum retrotorsion^{38,39} of the head of the humerus in relation to shaft.
3. Balanced power of the horizontal steerers.

Rotator Cuff or Musculotendinous Cuff

This is a fibrous sheath formed by the 4 flattened tendons which blend with the shoulder joint capsule and strengthen it. The muscles which form the rotator cuff arise from the scapula and are inserted into the lesser and greater tubercles of the humerus. It is formed by Supraspinatus, Infraspinatus, Teres minor and Subscapularis.

The rotator cuff muscles act to stabilize the head, which provide a fulcrum for abduction.

Surgical Anatomy

As the muscles of rotator cuff are attached to the tuberosities, it is vital to know the direction of pull of their fibers, because this facilitates an understanding of displacement of the fractured tuberosity fragments.

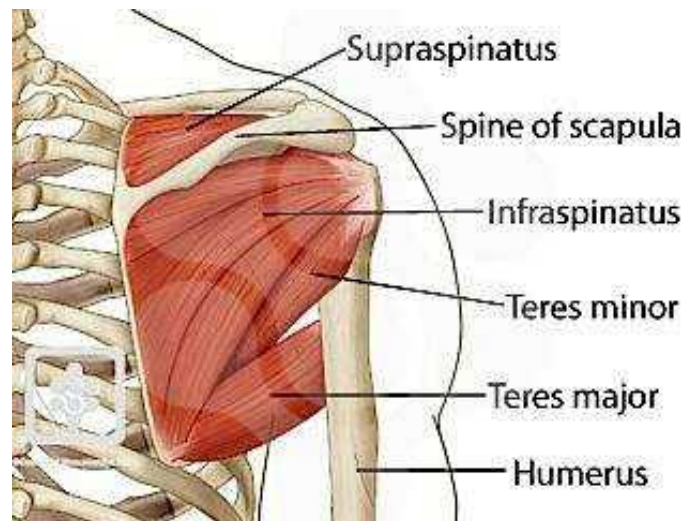
In fractures of greater tuberosity, the fragment will be pulled superiorly and posteriorly because of supraspinatus, infraspinatus and teres minor insertion. Reduction can be achieved by slight abduction and a tension band fixation neutralizes initial displacement forces.

In fractures of lesser tuberosity, the fragment will be pulled anteriorly and medially by the subscapularis muscle. Horizontal fixation best neutralizes these fractures.

During closed reductions the long head of biceps acts as a tether and blocks reduction. Also during surgical procedures, it is a crucial landmark from which rotator interval is identified, so that fracture fragments are properly identified and muscles of rotator cuff are preserved. Also adequate tension in long head of biceps is used to assess alignment in prosthetic replacement.

The deltoid inserting into the deltoid tuberosity can cause displacement of fracture of shaft at the surgical neck of humerus.

The pectoralis major inserting into the lip of intertubercular sulcus (bicipital groove) can displace the proximal humeral fracture medially, as usually seen in surgical neck fractures.



Posterior view of right Shoulder

The axillary artery and brachial plexus are just medial to coracoid process and precaution should always be taken to avoid injury when osteotomising coracoid for better exposure. It is always wise to remember that the lateral side is the best side and the medial side is not safe when osteotomising coracoid.

Axillary nerve leaves the posterior wall of axilla by penetrating the quadrangular space. Then it winds around the humerus and enters the deltoid muscle posteriorly about 7 cm from the tip of acromion process. Hence care should be taken during dissection of deltoid.

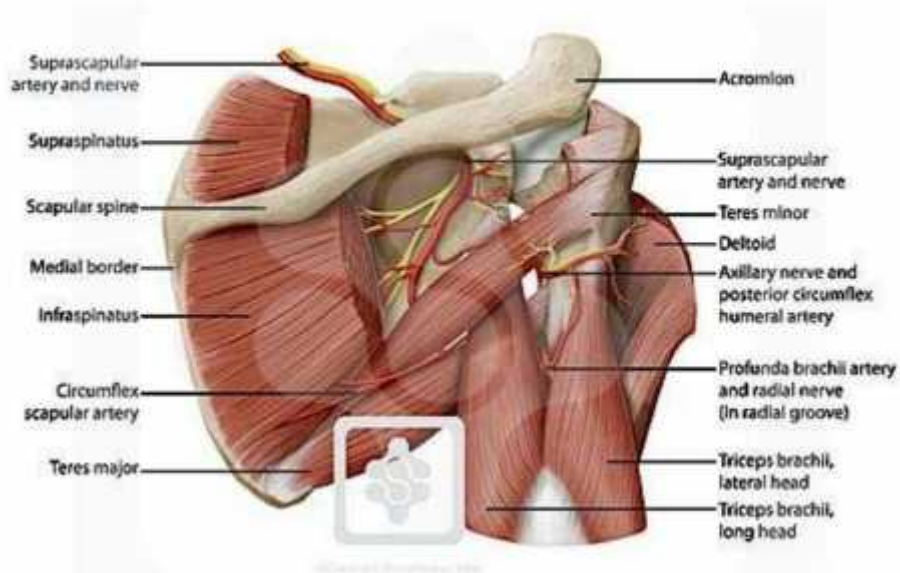
Blood Supply

1. Anterior circumflex humeral vessels
2. Posterior circumflex humeral vessels
3. Suprascapular vessels
4. Subscapular vessels

The major blood supply to the humeral head is from anterior circumflex humeral artery, a branch of third division of axillary artery. Laing was the first to describe the arcuate artery^{42,43} which is a continuation of ascending branch of anterior circumflex humeral artery. This supplies blood to a larger portion of head of the humerus. It enters the bone in the area of intertubercular sulcus.

Contribution also comes from the branches of posterior circumflex humeral artery entering the posteromedial aspect of the proximal humerus, metaphyseal vessels and vessels of the greater and lesser tuberosities⁴⁴ and small vessels entering through the rotator cuff insertion.

When the anterior circumflex humeral artery is injured close to its entrance to humeral head, it is more likely that the blood supply to the head will be compromised resulting in avascular necrosis of head of humerus⁴⁵.



Neuro Vascular Anatomy of Shoulder Joint

Nerve Supply

1. Axillary nerve
2. Musculocutaneous nerve
3. Suprascapular nerve

The shoulder joint is richly supplied by branches from the axillary, musculocutaneous and suprascapular nerves following the Hiltons law⁴⁶.

BIOMECHANICS

The glenohumeral joint is the least stable but has the greatest range of mobility than any other joint in the body.

It is a load bearing joint with significant forces acting across glenohumeral articulation. When the arm is held in 90° of abduction, the joint reaction force equals 90% of body weight^{2,47}.

The shoulder joint is exactly not located in the sagittal or coronal plane of the body. Its axis of motion begins on the curved chest wall, 35° to 45° away from the sagittal plane of the body.

The humeral head is retroverted 30° to 40° to articulate with the scapula and the average adult humeral head has a radius of curvature of 44mm^2 ,^{38,39}. At any particular time, only 25% to 30% of humeral head articulates with the glenoid cavity. The presence of glenoidal labrum increases the area of contact.

The intact humeral head is the fulcrum through which the rotator cuff and the long head of biceps act. The resulting force coupled with the action of deltoid muscle provides elevation of the arm while fixing the head within the glenoid cavity. When the humeral head that acts as a fulcrum is damaged or destroyed by fracture, dislocation, avascular necrosis or surgical resection rotator and elevator movements of the shoulder joint are lost.

Avulsion of greater tuberosity is pathognomic of concomitant rotator cuff tear². This will destabilize the shoulder and allows superior subluxation to occur with attempted elevation. There is also loss of lever arm and loss of active power. Also this will lead to subacromial impingement with loss of normal gliding motion of shoulder³⁶.

Thus pain, poor motion, loss of strength and endurance can result after Proximal humeral fracture if proper anatomy is not restored.

CLASSIFICATION

A system for the classification of fractures occupy a central role in the practice of orthopaedic surgery. The classification must be comprehensive enough to encompass all the factors, yet specific enough to allow accurate diagnosis and ideal management. It must be flexible enough to accommodate variations and allow logical deductions for treatment. It should also be both reliable and reproducible.

Kocher's Classification

This was devised in 1896 based on the different anatomic levels of the fracture namely,

- a) Anatomic neck.
- b) Epiphyseal region.
- c) Surgical neck.

Limitations

- It does not account for multiple fractures that occurs at various sites.
- It does not differentiate between displaced and undisplaced fractures

Watson-Jones Classification

This classification is based on the mechanism of injury and it is divided into 3 types namely,

- a) Abduction type
- b) Adduction type
- c) Contusion Crack Fractures

Limitations

Depending on whether X-rays are taken in internal rotation or external rotation, fracture can become either an abduction or adduction fracture and hence not very reliable.

Codman

In 1934 Codman made a vital contribution to the understanding of proximal humeral fractures by proposing that proximal humerus fractures can be separated into 4 distinct fragments occurring along the anatomic lines of epiphyseal union. These are,

- a) Anatomic head
- b) Greater tuberosity
- c) Lesser tuberosity
- d) Shaft

This formed the basis of future NEER'S classification.

Limitations

It does not describe about biomechanical forces causing displacement or plan for treatment.

Neer's Four Part Classification

In 1970 Charles Neer of Newyork proposed the first truly comprehensive system that considered the anatomy and biomechanical forces and related it to diagnosis and treatment. It is based on Codman's four parts. When any of the 4 major fragments is displaced >1cm or angulated more than 45° then the fracture is considered displaced. It is classified as

- a) Undisplaced fracture
- b) 2 part fracture
- c) 3 part fracture
- d) 4 part fracture

Neer's Fracture Dislocation

A fracture dislocation exists, when the head is dislocated outside the joint space, not simply rotated and there is, in addition, a fracture.

It is classified according to the direction of dislocation as

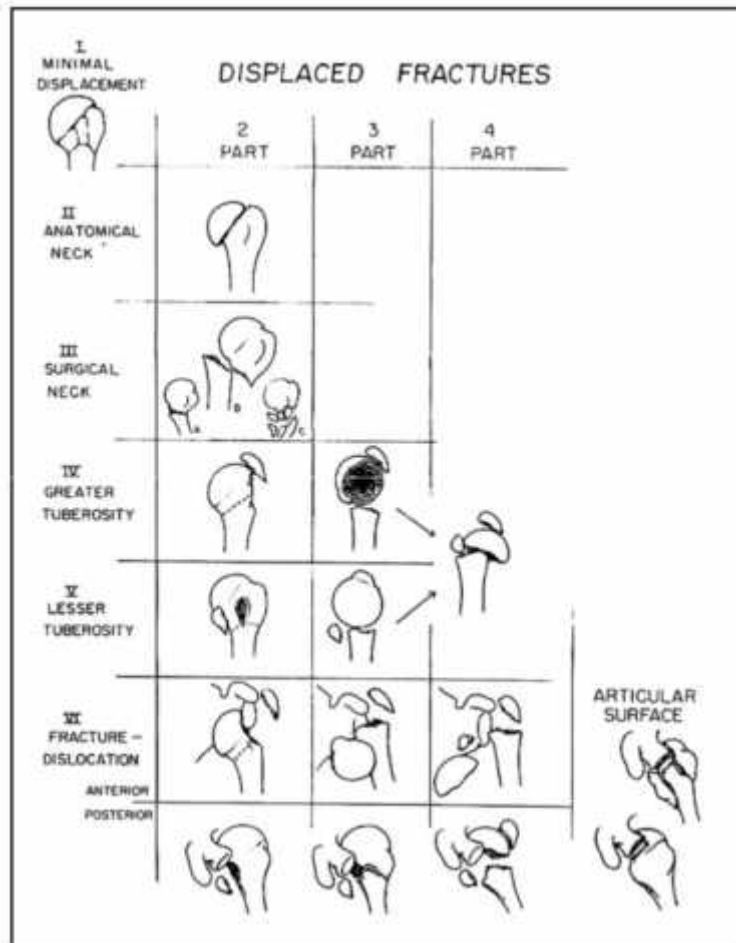
- a) Anterior Dislocation
- b) Posterior Dislocation

Based on number of fracture fragments as

- a) 2 part Fracture Dislocation
- b) 3 part Fracture Dislocation
- c) 4 part Fracture Dislocation

Or as special fractures as

- a) Head splitting fractures
- b) Impression fracture
- c) Valgus impacted fracture



NEER CLASSIFICATION

AO Classification

Jacob & Colleagues and AO-ASIF group have applied AO System to Proximal Humeral fractures. This system is divided into 3 types according to increasing severity of injury.

Type A

Extra articular

Involves 2 of the 4 fragments

No vascular isolation of articular segment

No risk of avascular necrosis

Least severe.

Type B

Partial intraarticular

Involves 3 of four fragments

Low risk of avascular necrosis

Partial vascular isolation of head

More severe

Type C

Intraarticular

Involves all four fragments

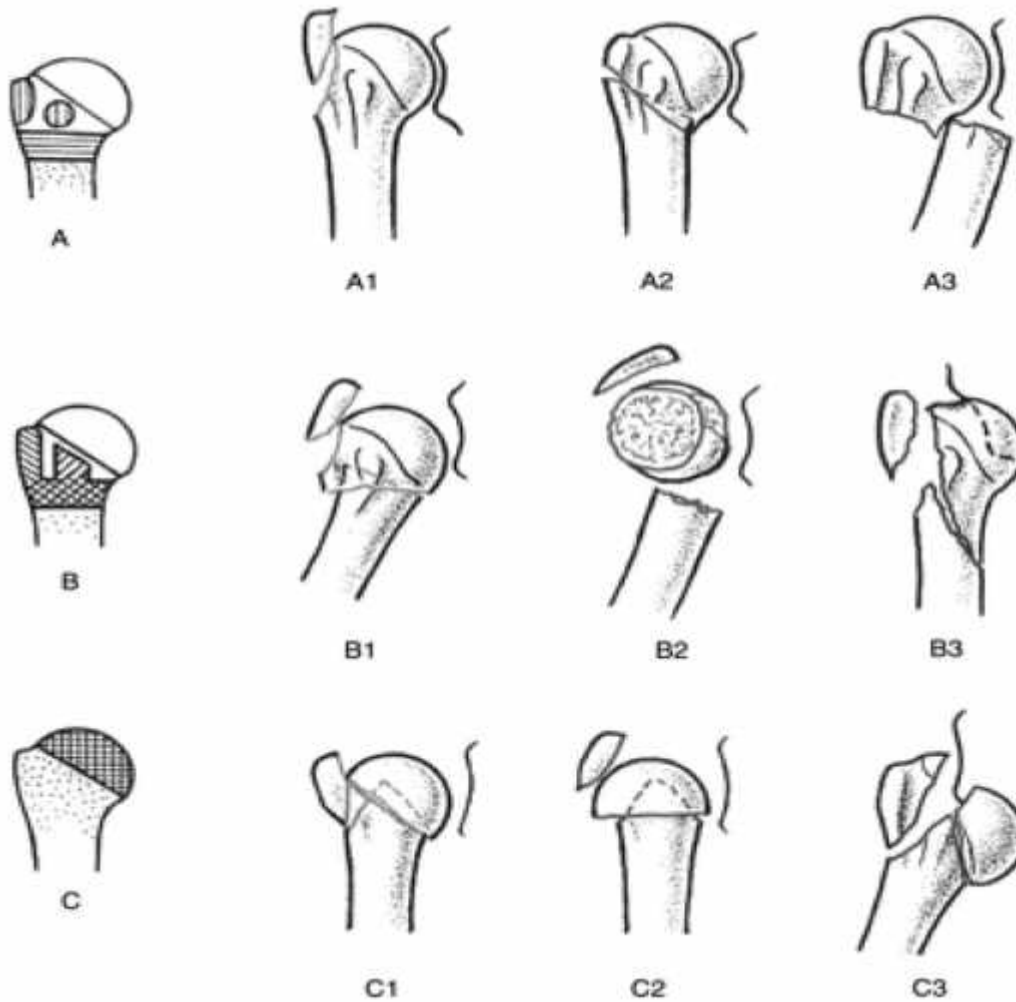
Complete vascular isolation of articular segment

More risk of avascular necrosis

Most severe

In addition each alphabetical injury is subdivided numerically with higher numbers indicating greater severity.

AO CLASSIFICATION



Of all, the Neer's classification has stood the test of time and still the most commonly followed the world over. It has important implication for both treatment options and outcomes^{48,49,50,51}.

We also have followed the Neer's classification in our study.

MECHANISM OF INJURY

Fractures of the proximal humerus have a bimodal age distribution. Fractures in adolescents and younger adults are usually produced by high energy injuries, mainly from road traffic accidents (RTA), sports injuries, falls from height or gun shot wounds. In these patients it is often associated with significant soft tissue injury and poly trauma. However these are much less common than fractures in the elderly, which are usually low energy osteoporotic injuries. More than three quarters follow low energy domestic falls and the risk of fracture is increased in sedentary people with low bone mineral density (BMD), a family history of osteoporotic fractures, frequent falls and evidence of impaired balance^{52,53}.

Middle aged patients who sustain low energy fractures frequently have a predisposing medical comorbidity or are physiologically older through the effects of alcohol, drug or tobacco overuse. Any other condition that produces osteoporosis at an earlier age will also increase the risk of fractures; in females, an early menopause is probably the most common of this.

During impact on the shoulder, the head of the humerus is thought to fracture on the hard packed bone of the glenoid, which acts as an anvil. The interaction of this external force with the forces generated by the intrinsic shoulder musculature, and the quality of the proximal humeral bone stock, determines the initial fracture configuration and any ensuing displacement. Elderly patients, with advanced osteoporosis or with medical comorbidities, are more likely to have displaced fractures.

A proximal humeral fracture may occur from direct impact to the shoulder or indirectly by transmission of forces from a fall on to the outstretched arm. Depleted protective neuromuscular responses, because of a delayed reaction time, cognitive impairment, neuromuscular disorders, impaired balance, or acute intoxication, raise the risk of a fall directly onto the shoulder^{54,55}.

The non dominant arm is also affected in up to three quarters of cases, suggesting an association with reduced strength of neuromuscular coordination. Diminished protective responses are an indirect measure of poor physiologic status, and this may explain why patients who sustain proximal humeral fractures from direct impact on

the shoulder tend to be frailer than those who sustain wrist fractures, where the arm is outstretched to break the fall.

A fracture that occurs after little or no trauma may be pathologic from metastatic tumour deposits, or rarely caused by a primary bone tumour or infection. In contrast, persistence of shoulder pain after a significant injury may be caused by an occult fracture (typically of the greater tuberosity), or a rotator cuff injury. This may be detectable using ultrasound or magnetic resonance imaging (MRI).

Another mechanism of injury described by Codman, is increased rotation of the arm particularly in the abducted position when a fracture occurs. Moreover the humerus locks against the acromion producing a pivotal position, facilitating a fracture.

Fractures of proximal humerus can result from a direct blow to the side of the shoulder. But the indirect mechanism is usually associated with greater degree of fracture displacement than the direct mechanism⁵⁶.

CLINICO-RADIOLOGICAL EVALUATION

History

A detailed history should include patient's health, handedness, occupation and details of injury. A good understanding of patients general health (i.e. whether he or she has osteoporosis or metabolic disorder or seizures) is of critical importance as it will predict the outcome of surgical fixation.

Clinical Presentation

Most patients with proximal humeral fractures present acutely and hence the most common clinical features are pain, swelling and tenderness around the shoulder joint especially in the region of greater tuberosity.

Ecchymosis usually becomes visible within 24-48 hrs and may spread to chest wall, flanks and distally down the extremity.

Associated crepitus may be present with motion of the fracture fragments, if they are in contact.

A complete neurovascular evaluation is always necessary in all patients with proximal humerus fractures.

The most common nerve that is injured with these fractures is Axillary nerve and hence sensation over deltoid insertion must be checked for. Motor function is tested by asking the patient to attempt shoulder abduction against the examiner's hand while the deltoid muscle belly is palpated for contractions.

Imaging

Precise radiographs are critical in establishing an accurate diagnosis in shoulder trauma. Most often injuries are missed with radiographs obtained in the plane of body rather than in the plane of scapula. To overcome this limitation, 3 view right angled trauma series was introduced. In addition CT scan, 3D CT Reconstruction, Arthrography, and MRI all allow the shoulder injuries to be more precisely defined.

Trauma Series

The 3 view Right angled Trauma Series was popularized by Charles Neer. Trauma series view still remains the best initial method of diagnosing fractures of Proximal Humerus as it allows assessment of

fracture in 3 separate perpendicular planes, so that accurate assessment of the fracture displacement can be obtained. It consists of the following:

a) AP VIEW IN THE PLANE OF SCAPULA

For scapular plane AP View, the posterior aspect of the injured shoulder is placed against X ray plate and the contralateral shoulder is rotated out approximately 40°. This allows visualization of Glenohumeral joint space without any bony superimposition.

b) LATERAL VIEW IN THE PLANE OF SCAPULA

The lateral view in scapular plane is obtained by placing the anterior aspect of the injured shoulder against X ray plate and rotating the contralateral shoulder out approximately 40°. The X ray tube is then placed posteriorly along the spine of the scapula. Here scapula appears 'Y' shaped with the glenoid in the centre and the 2 upper limbs of the 'Y' formed by acromion and coracoid with vertical limb formed by scapular body. This provides a true lateral view of the shoulder.

This view clearly demonstrates the displacement of the tuberosities and direction of dislocation.

c) AXILLARY VIEW

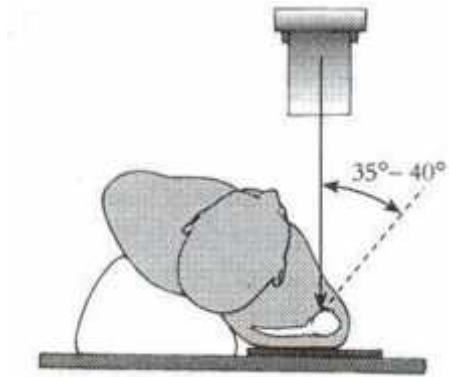
This allows for assessment of the shoulder in the axial plane and is vital for assessing the degree of tuberosity displacement, articular surface of the glenoid and relationship of humeral head to the glenoid.

Here the arm is held in mild abduction of 30° and the X ray plate is positioned above the patient's shoulder. The X ray beam goes inferior to superior.

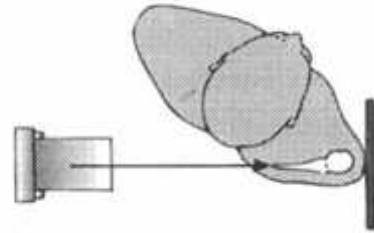
Another method is VELPEAU AXILLARY VIEW⁵⁷ where the arm is not removed from sling. The patient is seated and tilted obliquely backward 45°. The plate is placed on the table and X ray beam is shot from above.

The advantage of these views is that it can be taken without removing the sling from patient's arm. They can be done in either sitting, standing or prone position with minimal discomfort to the patient.

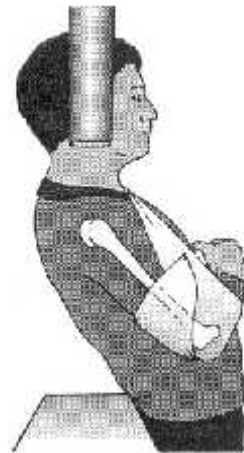TRAUMA SERIES - RADIOGRAPH POSITIONS



Anteroposterior View
in the
Plane of
Scapula



Lateral View in the
Plane of
Scapula
a



Velpeau Modified
Axillary
View
w

Special Views

Stripp axillary lateral⁵⁸ and the Trauma axillary lateral⁵⁹ views are described as special views.

Anterior glenoid rim fractures or ectopic calcification in many anteroinferior glenoid labral detachments with instability can be delineated with West Point Axillary View or alternatively, the Cuiollo Supine Axillary View with arm in external rotation.

The Bloom Obata Apical Oblique View⁶⁰ is specifically for defining whether there is a fracture dislocation or not.

Screening Views

There are 5 standard Radiographic projections¹⁴ which are helpful in screening patients with shoulder complaints. The first three views are Anteroposterior views in

- 1) Internal Rotation
- 2) External rotation
- 3) 100 degree Abduction.

The remaining 2 views are the Axillary and Bicipital Groove views. Single contrast Arthrography is invaluable in diagnosing full thickness tears of rotator cuff, adhesive capsulitis and lesions of the biceps. It is also useful in determining deep surface incomplete cuff tears and occasionally anterior instability.

Tomograms

Tomograms can be useful in evaluating Proximal Humerus fracture for nonunion or articular surface incongruity but this is largely replaced by CT scan.

CT Scan

CT scan is now the investigation of choice for evaluating Proximal Humerus fracture. It helps to find

- a) Displacement of tuberosity fragments
- b) Degree of articular involvement with head splitting fractures
- c) Impression fracture
- d) Glenoid rim fracture
- e) Chronic fracture dislocation.

Reconstruction CT

Though not available in all centres, it is extremely valuable to get a 3D Reconstruction model of the fracture, which helps in planning treatment, especially in complex fracture patterns.

MRI

MRI is useful in showing relation of tuberosity fragments to rotator cuff tendons. It also helps in assessing associated rotator cuff injuries.

METHODS OF TREATMENT

The ultimate goal in the treatment of all fractures is making the patient return to usual daily activities as soon as and to as nearly as normal an extent as possible. Various modalities of treatment of Proximal Humerus Fractures have been advocated through the years creating a great deal of controversy and at times confusion. Sound judgement is required to determine the appropriate treatment for each fracture.

The various methods that are available are:

- a) Closed Reduction
- b) Initial immobilization and early motion
- c) Percutaneous pinning and external fixation
- d) Plaster splint and cast
- e) Skeletal traction
- f) Open reduction and internal fixation
- g) Prosthetic replacement

a. Closed Reduction

For years this has been a popular method of management for various types of Proximal Humerus Fractures. However, it is essential to distinguish between those fractures, which are suitable and those which are not.

Forcible and repeated attempts at closed reduction may complicate a fracture by causing further displacement, angulation, fragmentation or neurovascular injury.

Various types of reduction manouveres have been used with mixed results. Watson and Jones described a classic technique of hyperabduction and traction to achieve a closed reduction.

Displaced lesser tuberosity fractures can be treated by closed reduction if it does not block internal rotation⁶¹.

Three and four part fractures are unstable and difficult to treat by closed reduction. Recent literature has reported poor results with closed reduction, with more incidence of pain, malunion and avascular necrosis.

b. Initial immobilisation and Early Motion

Initial immobilisation and early motion has been described with varying degrees of success for minimally displaced fractures. The shoulder joint has a large capsule, allowing a wide range of motion that can compensate for even moderate amounts of displacement. The arm is held by a sling at the side as in Velpeau position. Gentle range of motion exercises are usually started by 7 to 10 days, when pain has reduced and patient is less apprehensive.

c. Plaster Splints & Casts

Older literature suggested that reduction in an abducted and flexed position was essential for proper alignment of the fractures and advocated shoulder spica casts and braces to maintain reduction, which were extremely cumbersome and uncomfortable for the patient.

The use of hanging arm cast for fracture of Proximal Humerus should be avoided, because of the tendency for distraction at the fracture site leading to non-union or mal-union.

d. Percutaneous Pins

Percutaneous pinning may be used after closed reduction if reduction is unstable. Jacob and co-workers have outlined the technique and reported satisfactory results in 35 of 40 cases.

Though this method of treatment is technically demanding it offers advantage of less soft tissue disruption and minimal fixation thus decreasing the prevalence of avascular necrosis.

For unstable but reducible fractures of surgical neck, percutaneous pin stabilization remains a reasonable option.

e. Skeletal Traction

The use of traction is not commonly indicated but may be useful in the management of comminuted fractures.

The shoulder is flexed to 90° and elbow is also flexed to 90°. A threaded 'K' Wire or Steinmann pin is inserted in the ulna, and the forearm and wrist suspended in a sling. The goal is to try to hold the shaft fragments in a neutral position. When there is sufficient callus formation, the traction can be discontinued and the patient's arm placed in a sling or spica cast.

f. Open Reduction & Internal Fixation

Closed reduction and external fixation has been unable to correct deformity and maintain reduction sufficiently and hence open reduction and internal fixation has gained popularity⁶². Non-operative treatment of 3-part and 4-part complex fractures often results in malunion and shoulder stiffness. In younger or active elderly patients, surgical treatment should be considered. Otherwise the articular joint surface may compromise long term shoulder function to a larger extent⁵⁹. The

aim of internal fixation should be anatomical reduction and stable fixation allowing for early range of motion of the shoulder. The internal fixation of complex fractures of the Proximal Humerus restores good shoulder function. The recent trend is towards limited dissection of the soft tissue around the fracture fragments and the use of minimal amount of hardware required for stable fixation.

Indications for ORIF

- a) Displaced two part anatomic neck fractures in young adults.
- b) Displaced two part surgical neck fractures with soft tissue interposition preventing closed reduction or if reduction is unstable.
- c) Greater tuberosity fractures displaced more than 5 mm
- d) Displaced isolated lesser tuberosity fracture especially if fragment is large and blocks internal rotation.
- e) All displaced three part fractures
- f) Displaced four part fractures
- g) In 20% to 40% of head impression fracture

The choice of surgical approach is decided by the fracture pattern and includes an extended deltopectoral approach and superior

deltoid- splitting approach⁶⁴.

In general, 2-part, 3-part and 4-part fractures in younger, active patients are treated with Open Reduction and Internal Fixation and 4-part fractures in elderly, osteoporotic bone are treated with Hemiarthroplasty⁶⁵. Recently for 3 part & 4 part osteoporotic fractures, fixed angle stable locking plates (PHILOS plates) are used with increasing results.

Implant Selection:

Two part anatomic neck fractures:

Two part anatomical neck fractures account for 0.8% of upper humeral fractures.

Fortunately anatomic neck fractures are rare. The prognosis for survival of head is poor, because it has been completely deprived of its blood supply.

However several authors^{49,66,67,68,69} recommend an attempt at

open reduction and internal fixation with screws or locking compression plates if the patient is young and prosthetic replacement in older individuals.

Two part surgical neck fractures:

The surgical neck fractures are the most common type of the Proximal Humerus fractures^{3,5,6}. It occurs in all age groups. Displaced fractures can disrupt the function of the upper extremity. Displaced surgical neck fractures can be managed by various techniques; commonly used are percutaneous pin fixation, antegrade and retrograde insertion of intramedullary nails, combination of Ender's nail and suture techniques, plate and screw fixation and External fixation^{4,6,9}.

Two part greater tuberosity fracture:

Represents 3% of proximal humeral fractures. 15-30% anterior dislocations are associated with greater tuberosity fractures. Greater tuberosity fractures displaced greater than 5 mm require open reduction and internal fixation, because the posterior and superior displacement of the fragment will cause impingement beneath the acromion.

Screws, tension band wiring, suture materials, plates and screws, percutaneous pinning, have all been proposed. The rent in the rotator cuff that occurs with displaced greater tuberosity fracture must be repaired. Timing and proper treatment of these injuries is crucial as malunion and rotator cuff dysfunction may lead to pain, loss of motion and subsequent disability.

Two part lesser tuberosity fracture:

Displaced isolated lesser tuberosity fractures are rare but requires internal fixation with non-absorbable sutures or wires or screw if the fragment is large and blocks internal rotation.

Some authors have described a method of removal of bone fragment and suturing of subscapularis tendon to the cortical edge of fracture site.

Avulsion fracture of the upper part of the Lesser Tuberosity appears to have been caused by hyperextension and hyperexternal rotation of the shoulder.

Three -part fracture:

Three part fractures represent 13% to 16% of all proximal humeral fractures. Open reduction and internal fixation is the treatment of choice for displaced three part fracture of Proximal Humerus. It is important to avoid extensive exposure and soft tissue dissection of fragments which may compromise blood supply. Intramedullary nails are usually not adequate to neutralize deforming forces. The AO buttress plate gives good results but may require extensive soft tissue stripping.

Hawkins and Co-workers⁶⁶ reported good results in 14 of 15 patients treated with "figure of 8" wire for three part fractures. In osteoporotic bones, wire or non-absorbable suture can be passed through rotator cuff as well as bone of tuberosity and then attached to shaft. This gives sufficient stability to begin early motion. Tension Band Wiring (TBW) is an accepted method of treatment for three (3) part fractures.

PHILOS plates improve torsional resistance in the stabilization of 3-part Proximal Humerus Fractures. It has good torsional fatigue

resistance and stiffness than blade plate³.

Four part fracture:

It is about 5% of all Proximal Humerus Fractures⁴, and 19% incidence of humeral head necrosis occurs in these fractures⁷¹.

Open reduction and internal fixation of four part fractures with pins, rods, plates and screws can be done but the results usually are not promising. These fractures usually occur in elderly people in whom osteoporosis⁹⁶ and poor bone quality preclude any stable internal fixation. Prosthetic replacement offers a distinct advantage in these fractures permitting early motion and return to work. The recent concept of PHILOS plates in these patients is gaining momentum.

In general, surgical treatment of 2-part and 3-part Proximal Humeral fractures is difficult and needs familiarity with more than one method of fixation. Poor bone quality stock, comminution, and the deformity forces of the rotator cuff on the tuberosities influence the choice of operative approach and fixation techniques. Closed reduction and percutaneous pinning offer the potential advantage of less soft-tissue

dissection; however, good bone quality and minimal comminution are prerequisites⁶⁴.

PHILOS PLATE



CONVENTIONAL LCP



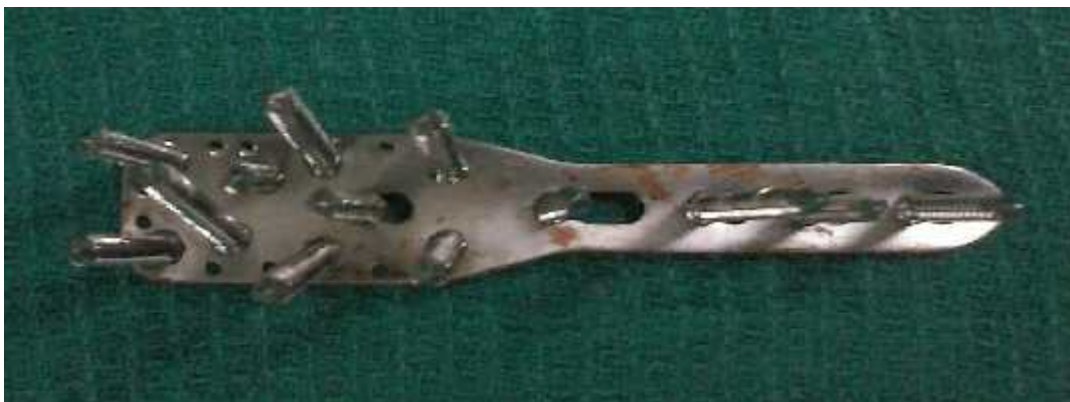PHILOS Plates:

Proximal Humeral Fractures in older patients with osteoporosis present challenges to conventional plates and screws resulting in early loosening and failure. To overcome this difficulty, PHILOS plate is being used. It is also used in complex 3 part and 4 part fractures. PHILOS plate provides stable screw fixation construct within the head. Angular stability is provided between the plate and the locking head screws, allowing the implant to act as internal fixator. Load transfer between the fragments occur over the implant. It provides great resistance against bending and torsional forces than conventional plates^{9,11}. Additional holes permit fixation of rotator cuff with greater tuberosity.

The plate is placed on the lateral side of humerus, approximately 5 mm below the tip of greater tuberosity. Temporary fixation of plate with 1.8mm Kirschner wires is done. The proximal locking screws were inserted into the humeral head before the distal screws were inserted into the humeral metaphysis or diaphysis. The screws alternatively converge and diverge gaining greater purchase and superior screw pullout strength. Standard AO cortical screws were

used to fix the plate to the shaft. Instead cancellous screws were used in severely osteoporotic bone. In Koukakis et al⁹¹ study average Constant shoulder score was 76.1%. Only one patient had avascular necrosis. There were no cases of impingement syndrome⁶. PHILOS plates improve torsional resistance in the stabilization of 3 part fractures^{7,8}.

DIRECTION OF HUMERAL HEAD SCREWS IN PHILOS PLATE



Advantages of PHILOS PLATE over Conventional LCP:

- PHILOS plate is a part of the latest generation of locking compression plates that is designed specifically for fractures of the proximal humerus.
- The PHILOS plate has locking screws that provide angular stability and better hold even in osteoporotic bone.
- The screws are placed in converging and diverging directions to provide an optimal repartition of the screws and a stable fixation.
- Thus the PHILOS plate can provide an excellent stable construct even in multifragmented osteoporotic proximal humeral fractures.
- Thus the patient can mobilize the shoulder earlier postoperatively.

Prosthetic Replacement:

In the early 1950s, the use of humeral head prosthesis was first reported for proximal humerus fracture. The original Neer's I prosthesis was designed in 1951. In 1953, Neer reported the first use of this prosthesis for complex fracture dislocation of Proximal Humerus. The original prosthesis was revised by Neer in 1973 [Neer II] to a more anatomic surface design.

Aim is to establish ideal humeral head version and proper myofascial sleeve tension within the rotator cuff and deltoid musculature¹¹. The prosthesis has two head sizes 15 & 22 mm in thickness. The larger size gives better leverage and mechanical advantage for forward elevation but the smaller size may be required for coverage by the rotator cuff. There are three stem sizes 7, 9.5 and 12mm and two stem length 125 and 150mm. Longer stem length are available, if needed to bridge a shaft fracture²¹. Recently modular hemiarthroplasty has been used in management of complex fractures of Proximal Humerus. The modular humerus design offers greater flexibility in head sizes, perhaps allowing more precise tensioning of soft tissues.

Moreover the ability to disassemble the component allows easier access to the glenoid if revision to a total replacement is contemplated later^{72,73,74,75}.

A new shoulder prosthesis design for Proximal Humerus Fracture has been developed. The rim of the articular

component of this prosthesis has multiple holes to which the bone-tendon junction of the rotator cuff is fixed, to allow an anatomic reconstruction of the glenohumeral unit.

Indications for prosthetic replacement⁷⁶:

- a) Displaced anatomic neck fracture in adults
- b) Extensive head impression, splitting or crushing fractures.
- c) Three part fractures that are tenuous and unstable after attempted open reduction.
- d) Unstable four part fracture dislocation
- e) In chronic cases of avascular necrosis, malunion or nonunion⁹⁸ with joint incongruity.
- f) Neglected chronic dislocation⁹⁹.
- g) Greater than 40% head impression fractures
- h) Non union of surgical neck of humerus

Prosthetic replacement is a likelihood treatment in osteoporotic patients with 4 part fractures, fracture dislocation, split fractures with more than 40% articular surface involvement, anatomic neck fracture, dislocation present for longer than 6 months. Early prosthetic replacement has better functional outcome than

late reconstructive prosthetic replacement¹¹.

In osteoporotic bone bulky, rigid and stiff implants are inadequate and may lead to more damage. Load sharing, not load bearing compound constructions are the aim. Obtaining adequate elastic buttressing is the key element in achieving the necessary load sharing⁷⁷.

The functional outcome is governed by the security of tuberosity- muscle cuff repair, adequate protection after surgery and long term physiotherapy.

Constrained Replacement

Patients who require arthroplasty but do not have a functional rotator cuff mechanism will be benefitted from the use of constrained replacement. If, in addition, the acromion fulcrum and loss of deltoid is present, then there is a greater reason for constrained replacement.

The optimal prosthetic reconstruction of the shoulder is dependent on prosthetic design, soft tissues, postoperative healing and rehabilitation, and the long term biologic response to the implant.

SURGICAL APPROACHES

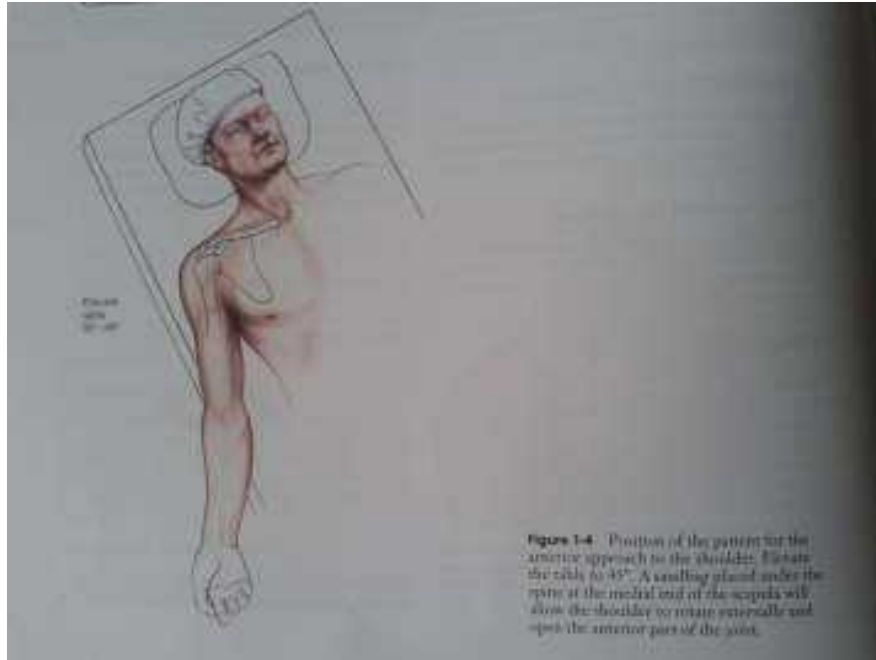
There are many approaches used for treatment of fractures of Proximal Humerus. An approach which allows greatest visualization for performing a repair or fixation with the least disruption of soft tissues should be chosen for better functional recovery⁷⁸.

The various approaches are

- A. Anterior deltopectoral approach
- B. Deltoid approach
- C. Superior approach
- D. Posterior approach

Only the approaches that we have used in our study have been dealt below.

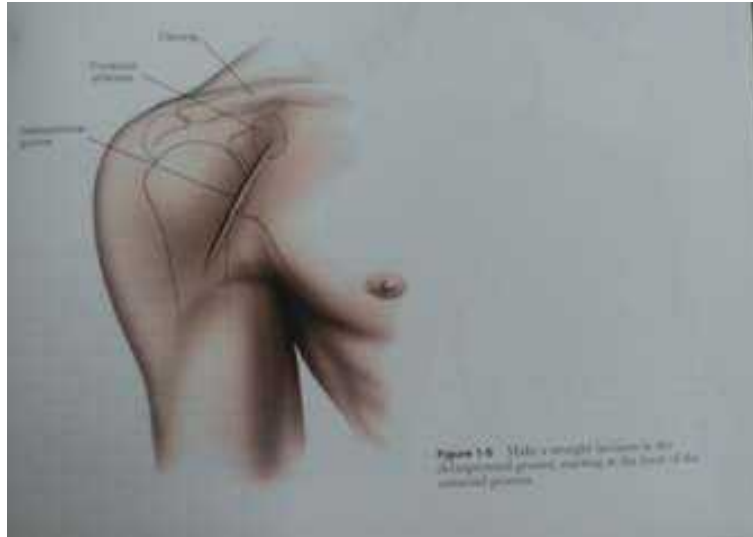
Position of the patient



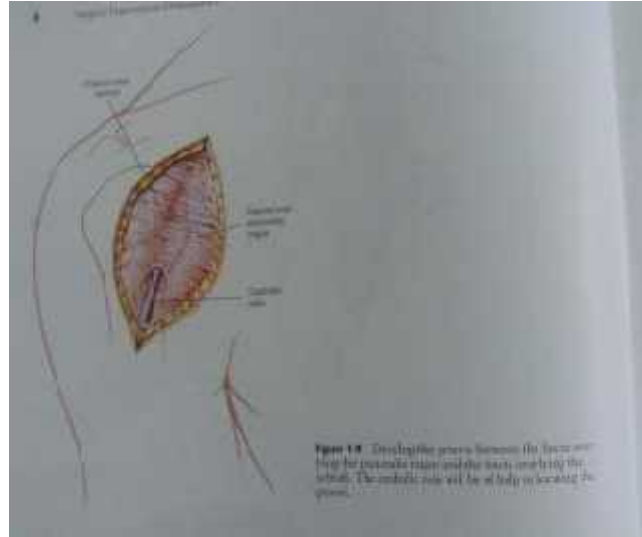
Place the patient supine on the operating table. Place a sand bag between the spine and medial border of scapula to push the affected side forward while allowing the arm to fall backward thus opening up the front of the joint. Elevate the head of the table to 30° to 45° to reduce bleeding and to allow blood to drain away from the operative field.

A. Anterior deltopectoral approach

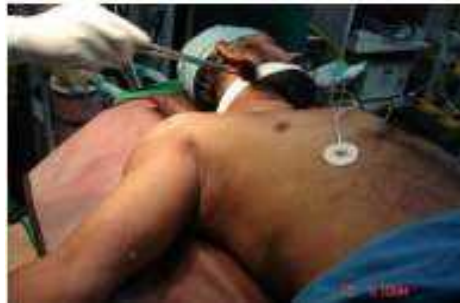A 15cm long incision is made from above the coracoid and carried distally in the line of deltopectoral groove to the deltoid insertion. The internervous plane lies between deltoid, which is supplied by axillary nerve and pectoralis major which is supplied by medial and lateral pectoral nerves. The cephalic vein is preserved with retraction towards either the deltoid or pectoralis major.



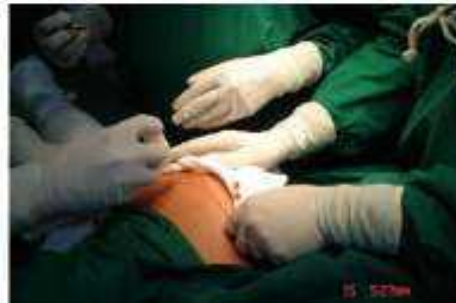Delto Pectoral Approach



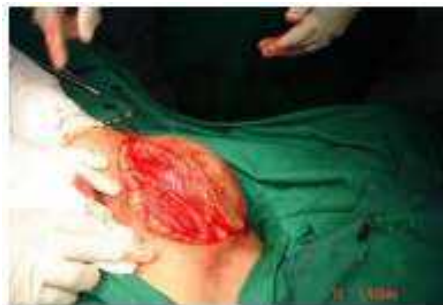Identifying Delto Pectoral Groove



1. Painting & Draping



2. Skin incision



3. Identifying Delto Pectoral Groove

Rarely it may be ligated. The clavipectoral fascia is incised. The muscles attached to the coracoid are retracted medially. With the arm abducted, anterior 1cm of deltoid is released and retracted laterally and retained with Richardson retractor. The long head of biceps, the key to anatomy of upper humerus is found under the insertion of pectoralis major. Palpate it as it proceeds upwards, but do not dissect it free, for fear of avascular necrosis. If lesser tuberosity is not fractured access is gained to the front of the joint by means of a directed subscapularis and capsular longitudinal arthrotomy. Rarely coracoid osteotomy may be required for better exposure.

B. Deltoid splitting approach

Start the incision at the anterolateral tip of acromion and carry it distally over the deltoid muscle about 5 cm. Identify the tendinous interval 4-5 cm long between anterior and middle thirds of the deltoid, splitting the muscle here provides a fairly avascular approach to the underlying structures. Next, incise the thin wall of subdeltoid bursa and explore the rotator cuff and tuberosities.

Intra operative complications include:

- a) Fracture of shaft of humerus from forceful manipulation.
- b) Displacement of previously undisplaced fracture.
- c) Poor holding of K wires and sutures in tuberosities in osteoporotic bone
- d) Damage to deltoid with retraction
- e) Damage to axillary artery
- f) Damage to axillary nerve
- g) Damage to brachial plexus
- h) Torrential bleeding

Post-operative care and rehabilitation

Proper postoperative rehabilitation is necessary to obtain and maintenance of satisfactory range of motion, strength and shoulder function^{70,78,79}.

Rehabilitation should be custom tailored to the patient and the fracture pattern, and is easier, more comfortable and assured with stable

internal fixation. If fracture fixation is stable, then physiotherapy can be initiated soon. The most accepted and useful rehabilitation protocol is the three-phase system devised by Hughes and Neer⁸⁰.

Application of this system is variable and depends on the fracture pattern, stability of fracture fixation and ability of patient to comprehend the exercise programme.

Phase I:

Phase I exercises are started early in the postoperative period, usually between 5th and 10th post-operative day. After stable surgical fixation, passive exercises can be started within 24-48 hours. The surgeon should start elbow flexion and extension. Then gently assist the patient with pendulum exercises. The next exercise is supine external rotation with a stick. Assisted forward elevation and pulley exercises are started after three weeks. Isometric exercises are initiated at four weeks.

Phase II:

This phase involves early active, resistive and stretching exercises. The first exercise is supine active forward elevation. During each session 3 sets of 10-15 repetitions are done regularly. This is followed by stretching for forward elevation on top of the door. The most important exercise to achieve abduction and external rotation is to place the hands behind the head with arm abducted and externally rotated.

Phase III:

Resistive strengthening exercises are started at three months during this phase. Arm is stretched higher on top of wall by leaning the trunk onto the wall. Prone stretching for forward elevation is also useful. Light weight can be carried after three months. Weights are started at one pound and increased at one pound increments with the limit being 5 pounds. Strength can be achieved with effective functional activity. A well supervised rehabilitation protocol is essential for the success of any fracture treatment. Even a perfect surgical repair will not achieve good results, without proper rehabilitation efforts⁸¹.

MATERIALS AND METHODS

This prospective & retrospective study is an analysis of functional outcome of 20 cases of surgically managed fractures of proximal humerus using PHILOS plates undertaken at Institute of Orthopaedics and Traumatology, Rajiv Gandhi Govt General Hospital, Madras Medical College, Chennai from June 2012 to September 2014. Of the 20 patients, 12(60%) were females and 8(40%) were males. (Table-I). The age of the patients ranged from 18-70 years. The mean age of the patients was 51 years.(Table- II).

METHODOLOGY (MATERIALS AND METHODS)

- Study topic** : Prospective & retrospective analysis of functional outcome of proximal humeral fractures treated with PHILOS plates.
- Study Design** : Prospective & retrospective Study
- Study Venue** : Institute of Orthopaedics & Traumatology, Rajiv Gandhi Govt General Hospital, Madras Medical College.

- Sample Size** : Twenty (20)
- Study Period** : June 2012 to September 2014
- Data Collection** : Collection of data as per proforma with consent from the patients admitted in Orthopaedic ward, Madras medical College

Inclusion Criteria:

Patients with proximal humerus fractures, who,

- i. Are skeletally mature and age more than 18 years
- ii. Satisfy Neer' s criteria for operative displacement i.e. displacement of >1 cm between the major fracture fragments or angulation of the articular surface of >45 degrees.
- iii. Neer' s two, three and four part fractures.

Exclusion Criteria:

Patients with

- i. Open fractures
- ii. Pathological fractures(due to tumours)
- iii. Associated neurovascular injury
- iv. Associated head injury

Pre op assessment:

After initial resuscitation a detailed history was taken and thorough clinical examination done to rule out any other associated injuries. Distal neurovascular status was assessed.

Investigations:

Routine investigations like complete hemogram, blood sugar, renal function tests, serum electrolytes, blood grouping and typing, bleeding time, clotting time, chest x ray PA view, ECG were done. Radiographs of the affected shoulder were taken in AP, Lateral and Axillary views and fractures were classified according to Neer' s classification. CT pictures were taken in selected patients with complex fracture patterns to know the articular involvement. Anaesthetic fitness was obtained for all the patients before surgery.

Prophylactic Antibiotics:

All patients received 1 gram of cefotaxime intravenously thirty minutes prior to surgery.

Anaesthesia:

Twelve patients were operated under supra clavicular and interscalene block. Combined general anaesthesia with inter scalene block was used in remaining eight patients in view of anticipatory increase in duration of surgery due to difficulty in fracture reduction.

Positioning the patient:

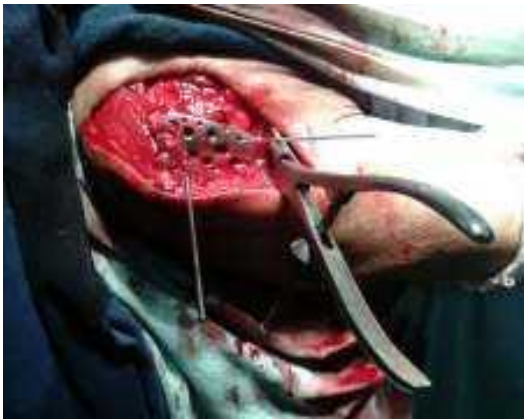All patients were positioned supine on the table with a sand bag between the spine and medial border of the scapula in order to push the affected side forward and to open up the front of the joint.

Surgical Approach:

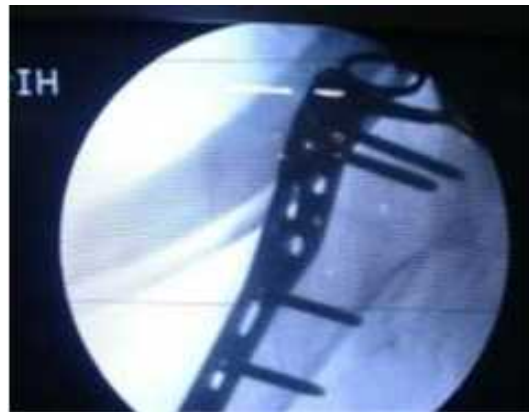Sixteen patients were operated using standard deltopectoral approach. Four patients were operated using deltoid splitting approach.

Operative Technique:

After incising the skin, subcutaneous tissue, fascia and muscle, the conjoint tendon was retracted medially. The fragments were reduced indirectly and temporarily fixed with the help of 1.5 or 1.8 mm K wires under image intensifier control.



TEMPORARY K - WIRE FIXATION



C - ARM IMAGE

After obtaining acceptable reduction, the PHILOS plate was placed atleast 8mm distal to the upper end of the greater tuberosity. The long head of biceps tendon was identified and preserved. The plate was then placed lateral to the long head of biceps without compromising its function. The humeral head fragment as well as the metaphyseal shaft was fixed with locking head screws. Standard length wires were inserted into the humeral head through a guide and the length of screw determined by placing a measuring device over the protruding wire. The corresponding length locking screw was then inserted using a specifically designed screw driver. The final position of the implant was checked with image intensifier in multiple planes. The shoulder was checked for stability of fixation, range of movements and absence of impingement. None of our patients required bone grafting. Suction drain kept insitu and closure was with 2/0 vicryl to muscle, fascia and subcutaneous tissue , 2/0 ethilon sutures to the skin.

Fracture-Dislocation

In cases of irreducible fracture dislocation, the coracoid was predrilled and osteotomised and retracted with the tendon. Arm was externally rotated and blunt instrument passed between subscapularis

and capsule and stay sutures applied. The same was divided one inch from its insertion and retracted. Capsule was incised longitudinally to open the joint and reduce the articular fragment.

Post op period:

Drain was removed on the second post operative day. Intravenous antibiotics continued till eighth post operative day. Sutures were removed on 12th post operative day.

Post op Xrays:

X rays are taken in the immediate post op period to document the fracture alignment, reduction and fixation. There after X rays are repeated at every 3 to 4 weeks interval to monitor the fracture union and to detect any implant loosening, deviation, screw penetration, screw backout, impingement and failure.

Functional Outcome Assessment :

Post op functional outcome was assessed by using Constant and Murley Score.

Radiological Outcome:

Post op radiological outcome was evaluated by taking serial X rays at follow up documenting on quality of reduction, fracture alignment, restoration of articular congruity, fracture union, PHILOS plate deviation, screw penetration, backout, implant loosening and failure.

Instruments and Implants used:



1. Kirschner 'K' wire (1.5mm)
2. Kirschner 'K' wire (1.8mm)
3. Drill Sleeve (4mm)
4. Drill Bit (3mm)

- 5 Screw Driver (3.5mm)
- 6 Cortical Locking Screw (4mm)
7. Cancellous Locking Screw (4mm)
- 8 PHILOS Plates

Post-Op Rehabilitation

In all patients the arm was placed in an arm sling, cuff and collar or shoulder immobilizer.(Table XV). Prophylactic antibiotics which were started before surgery were continued for 48 and 72 hours postoperatively. In few patients ice packs were used to minimise the swelling. Passive elbow flexion and extension were started by 24-48 hrs. Sutures were removed by 12th post op day.

Phase I exercises consisting of pendulum exercises were started from the first week. Gentle passive forward flexion, internal and external rotation exercises were initiated by third week. Phase II exercises consisting of active range of motion exercises and resistive exercises were started by 4-6 weeks. Phase III exercises consisting of advanced stretching and strengthening exercises were started by 3 months. Lifting of light weight objects were started after 3 months.

OBSERVATIONS

- Majority of injured patients were females (60%).
- Highest numbers of patients were in their 5th decade (35%).
- Free fall at ground level was the most common mode of injury (50%)
- Post-epileptic fall caused fracture of Proximal Humerus in one patient.
- No case with bilateral fractures was reported.
- All were right handed persons and the dominant arm was involved in 15 (75%) patients.
- Post menopausal osteoporotic females accounted for 50% of patients.
- 16 (80%) patients reported to hospital within five days of injury.
- 25% of patients had undergone previous native treatment either in form of massage, splinting or attempted reduction and splinting.
- 8 patients had associated fractures.
- All the patients had closed injuries
- Neer's 2 part fracture is the most common type in 60% patients.

- Greater Tuberosity fractures were the predominant type in 2 part fracture.
- 4 part fractures accounted for only 5% of patients
- Fracture dislocation were present in 2(10%) of patients.
- None of our patients required post op immobilization with POP.
- Patients were taken up for surgery on an average of 6 days after admission.
- 60% patients did not have any pain during follow-up
- The average range of active elevation was 126.25 degrees
- The average range of active external rotation 47 degrees.
- The average range of abduction 123.25 degrees
- 17(85%) of patients had normal muscle strength in shoulder.
- Patients with 2 part fracture had better functional outcome than 3 and 4 part fracture.
- All fractures unite within an average period of ten weeks.
- No cases of implant loosening or failure were encountered.

RESULTS

TABLE - I

SEX DISTRIBUTION

S. No.	Sex	No. of Patients	Percentage
1.	Females	12	60
2.	Males	8	40

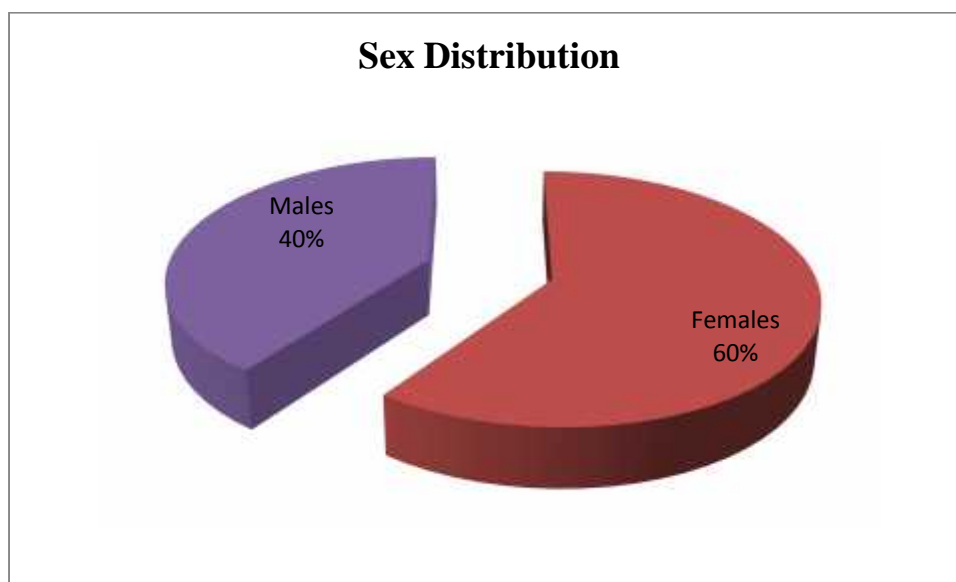


TABLE - II

**AGE
DISTRIBUTION**

S. No	Age group	No. of Patients	Percentage	Males	Females
1	15-20	1	5	1	0
2	21-30	2	10	2	0
3	31-40	2	10	1	1
4	41-50	5	25	2	4
5	51-60	7	35	1	5
6	>61	3	15	1	2

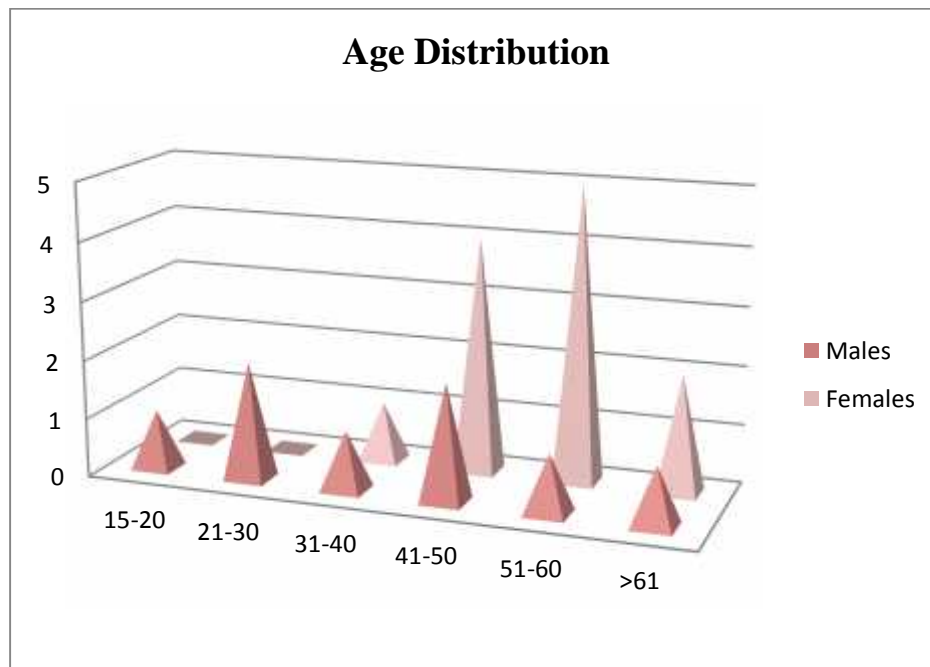


TABLE III
MODE OF INJURY

S. No.	Mode of injury	No. of Patients	Percentage
1	Fall at ground level	10	50
2	RTA	6	30
3	Fall from height	3	15
4	Epilepsy	1	5

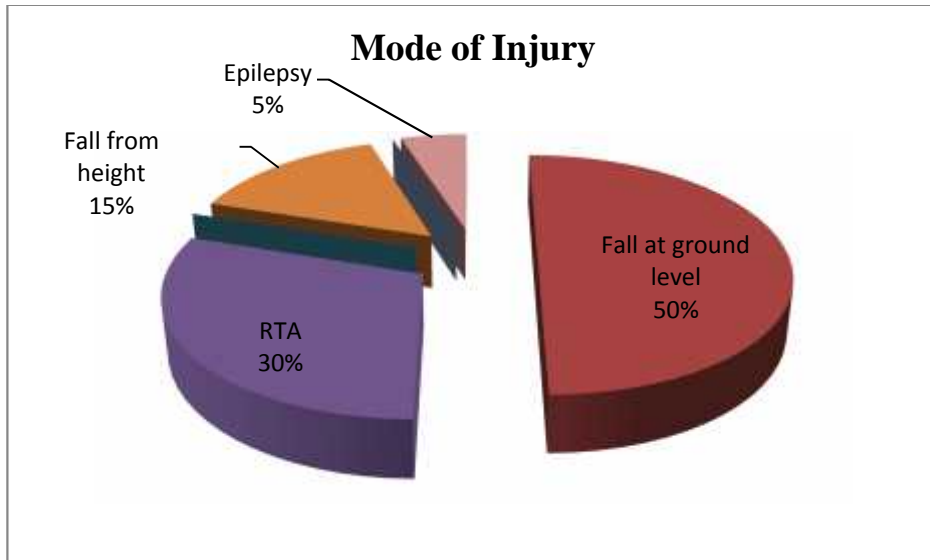


TABLE - IV

OCCUPATION

S. No	Occupation	No. of Patients
1	Labourer	5
2	House wife	5
3	Skilled worker	6
4	Professional	1
5	Student	1
6	Business	2

TABLE – V

SIDE

S.No	Side	No. of
1	Unilateral	20
2	Bilateral	0

TABLE- VI

SIDE INVOLVED

S.No	Side involved	No: of patients
1	Dominant(Right)	15
2	Non-dominant(Left)	5

Sixteen patients presented to us within five days after injury,(Table- VII) and 5 patients had previous treatment either in the form of native splinting, massage or POP application. (Table - VIII)

TABLE - VII
DURATION

S. No	No of days Since injury	No. of patients
1	0-5 days	16
2	6-10 days	3
3	11-15 days	1

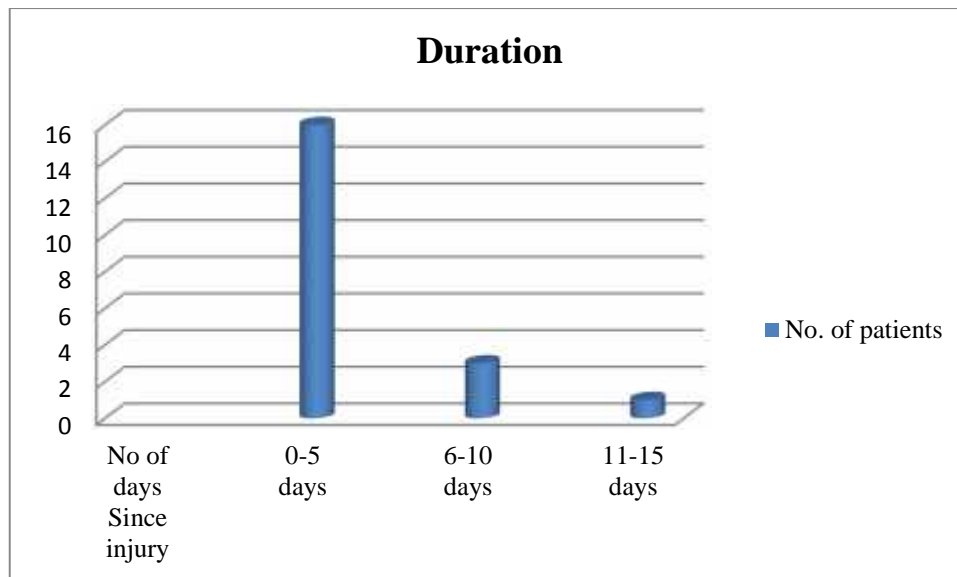


TABLE - VIII
PREVIOUS TREATMENT

S. No	Previous treatment	No. of patients	Percentage
1	Massage	2	10
2	Massage and splinting	0	0
3	Splinting	1	5
4	Attempted reduction with splinting	1	5
5	POP	1	5
6	No native treatment	15	75

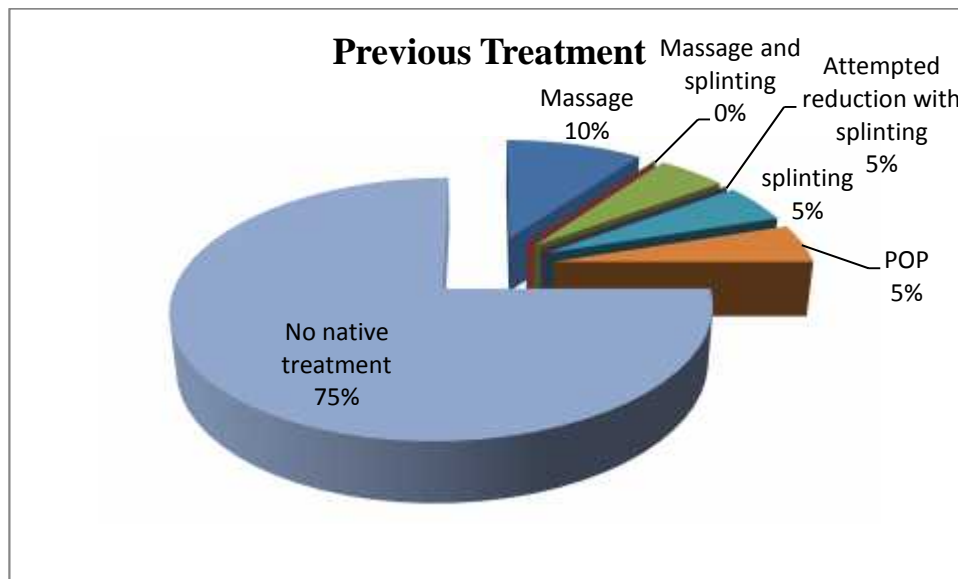


TABLE - IX

S. No	Fracture	No. of patients
1	Closed	20
2	Open fracture	0

TABLE - X

S. No.	Associated injuries	No. of
1	Fracture metacarpal	2
2	Fracture patella	1
3	Fracture distal radius	2
4	Fracture SOH	1
5	Fracture NOF	1
6	Fracture BB Forearm	1

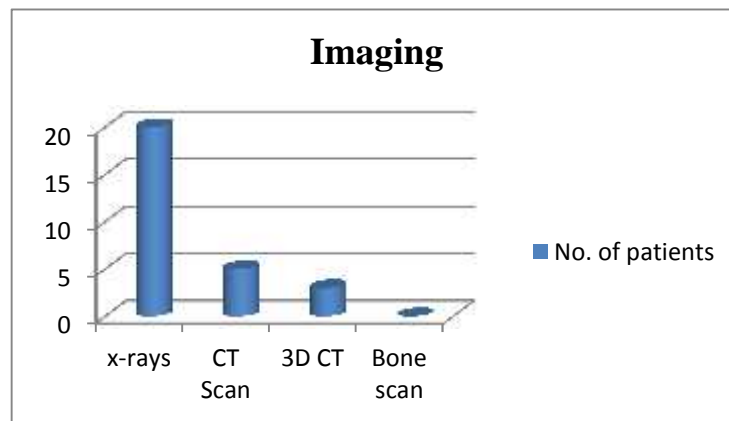
All patients were evaluated with standard anteroposterior radiographs of the affected shoulder and most of them were further evaluated with Neer's three view trauma series which involves the AP, lateral view in the plane of scapula and axillary lateral view. CT Scan was done in 5 patients with complex fracture dislocations, to

delineate the fracture pattern and the direction of dislocation and for 3 patients 3D CT was taken to ascertain the position of the fragments (Table - XI).

TABLE - XI

IMAGING

S. No	Imaging	No. of patients
1	x-rays	20
2	CT Scan	5
4	3D CT	3
3	Bone scan	0



Radiological evaluation of the fractures was done and were classified according to Neer's four part classification system.

Based on Neer's system 12 patients (60%) had two part fractures, 7 (35%) had 3 part fractures and 1(5%) had four part fractures. (Table-XII) Fracture dislocations were present in 2 patients (Table-XIII).

TABLE - XII
TYPE OF FRACTURE

S. No	Neer's type	No. of patients	Percentage
1	2 part	12	60
2	3 part	7	35
3	4 part	1	5

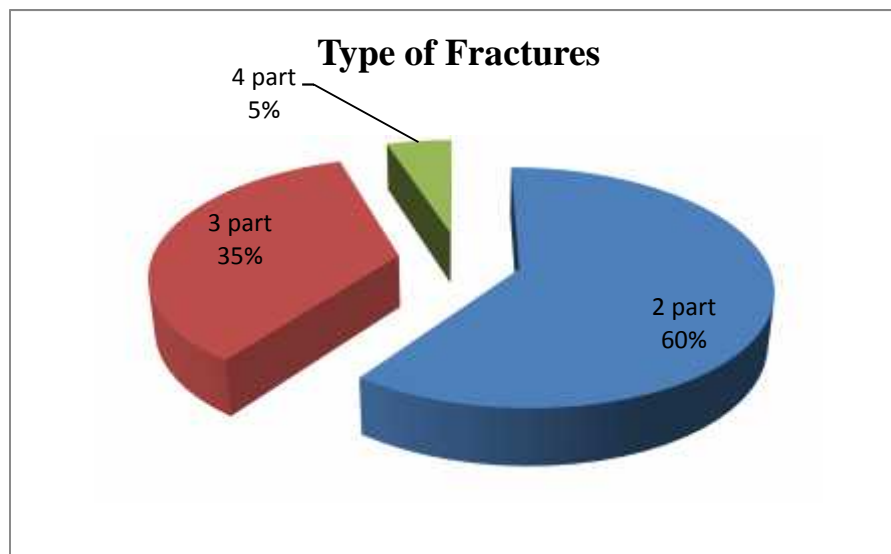


TABLE - XIII

**FRACTURE
DISLOCATION**

S. No.	Dislocation	No. of patients	Percentage
1	No	18	90
2	Dislocation	2	10
	2 part	0	0
	3 part	2	10
	4 part	0	0

The indications for surgery were displacement of more than 1 cm between the fracture fragments and angulation of the articular surface more than 45°. Patients not satisfying these criteria were treated conservatively and not included in this study.

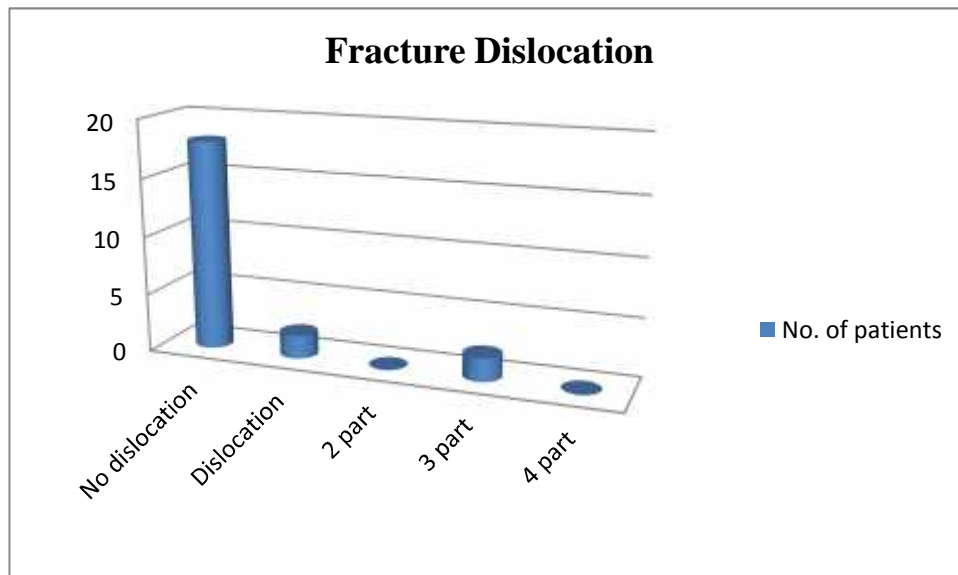
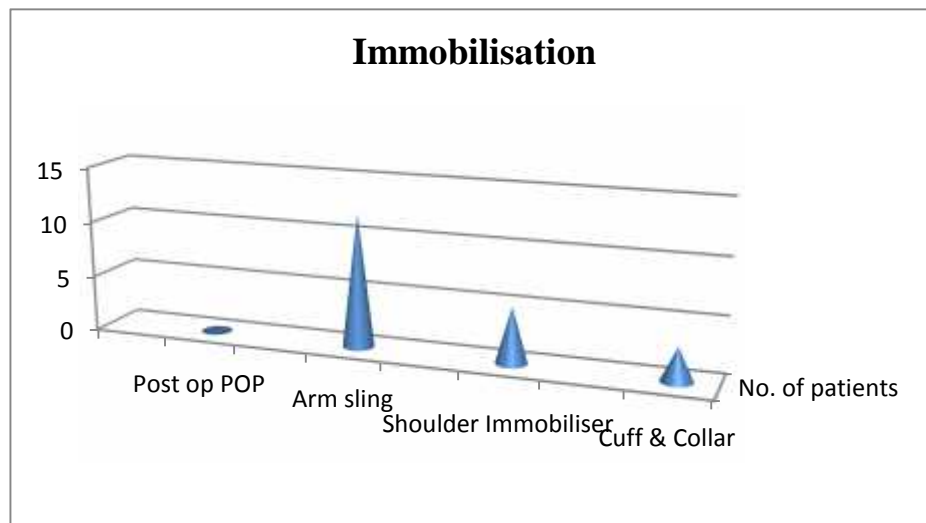


TABLE - XV

POST-OP IMMOBILISATION

S. No.	Immobilization	No. of patients
1	Post op POP	0
2	Arm sling	12
3	Shoulder Immobiliser	5
4	Cuff & Collar	3



All the patients were reviewed at two weeks interval, for first three months and later every month. During follow up, patients were clinically evaluated for pain and function. Radiological evaluation of fracture union was observed by serial x rays.

COMPLICATIONS

Early Complications

Early complications were encountered in 3 (15%) patients.

[TableXVI].

1 patient with diabetes mellitus developed wound gaping due to infection requiring secondary suturing after glycaemic control.

1 patient with 3 part fracture developed skin necrosis which resolved with intravenous antibiotics.

1 patient had deltoid atony after surgery which improved with sling and strengthening exercises.

TABLE XVI

EARLY COMPLICATIONS

S. No	Complications	No. of Patients
1	Skin necrosis	1
2	Wound gaping	1
3	Deltoid atony	1

Late Complications

Late complications were encountered in 5(25%) of patients. [Table-XVII].

1 patient with 3 part fracture had malunion of greater tuberosity, restricting abduction above 90°.

The patient who had deltoid atony initially after surgery had mild inferior instability which was not incapacitating for the patient.

2 patients had joint stiffness. Both patients later required manipulation under general anaesthesia.

1 patient developed Heterotopic ossification with 3 part fracture, probably because the patient had exercised native treatment in the form of many attempted reduction, massage and splinting.

TABLE-XVII

LATE COMPLICATIONS

S. No	Late complications	No. of Patients
1	Malunion	1
2	Joint stiffness	2
3	Instability	1
4	Nonunion	0
5	Infection	0
6	Heterotropic Ossification	1

The patients were followed up at regular intervals every two weeks interval during the first 3 months and every 1 month thereafter. The minimum follow-up period was four months and maximum follow up period was 8 months.

The results were evaluated during follow up by taking into consideration the following factors:

- 1) Pain
- 2) Range of motion
- 3) Strength
- 4) Stability
- 5) Function
- 6) Radiological documentation of fracture union
- 7) Anatomic restoration

Constant And Murley Score:

Constant and Murley's score^{82,83,84,85,86} was used to assess the functional outcome of our patients.

PAIN

Post op pain was recorded on a scale of 0-5points, where points were given according to the following criteria

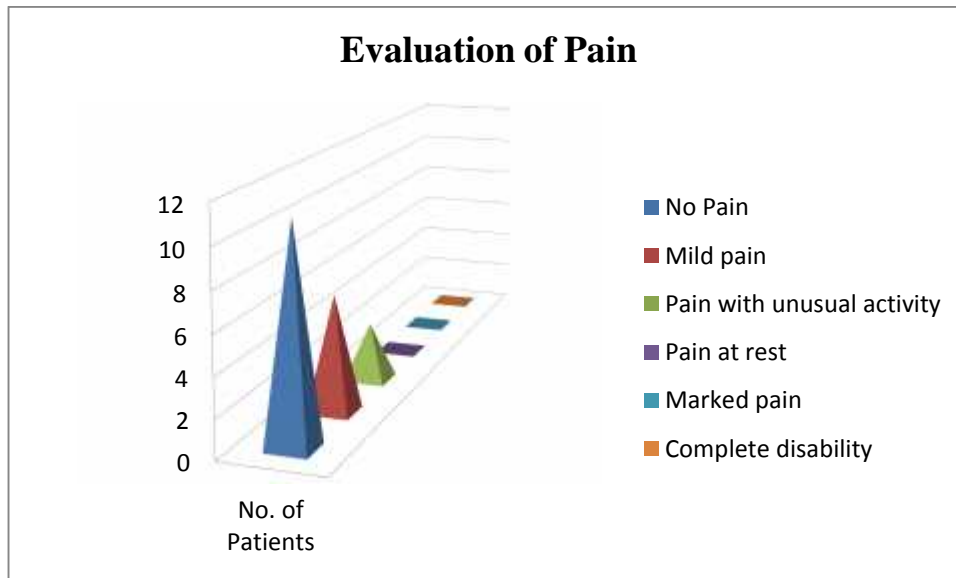
TABLE - XVIII

Pain scale	Points
No pain	5
Mild pain	4
Pain after unusual activity	3
Pain at	2
Marked pain	1
Complete disability	0

11(55%) patients said that may had no pain and 6(30%) patients had only mild pain, 3(15%) patients had pain after unusual activity . None of our patients had pain at rest or disabling pain. [Table-XIX]

TABLE-XIX
EVALUATION OF PAIN

Sl. No	Pain	No. of Patients
1	No Pain	11
2	Mild pain	6
3	Pain with unusual activity	3
4	Pain at rest	0
5	Marked pain	0
6	Complete disability	0



FUNCTIONAL OUTCOME

Functional outcome was evaluated with ability to perform day to day activities. Points were given according to the following scale

4 - normal

3 - mild compromise

2 - with difficulty

1 - with aid

0 - unable

NA - not available

Functional results were graded by following criteria:

Good functional result 3.5 - 4.0 points

Fair 2.5 - 3.4 points

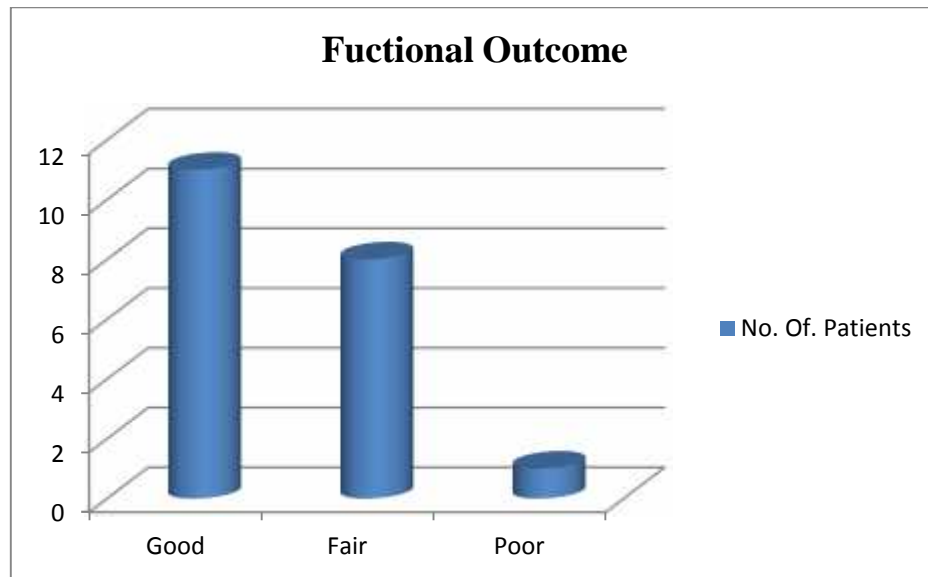
Poor < 2.5 points

11 (55%) of the 20 patients had good functional result, 8 (40%) had fair functional results and 1(5%) had poor functional result. [Table-XX]

TABLE-XX

FUNCTIONAL OUTCOME

S. No	Functional outcome	No: of patients
1	Good	11
2	Fair	8
3	Poor	1



Muscle Strength

Muscle strength was evaluated for the muscles around the shoulder and points allotted accorded to strength as follows;

Normal -5

Against Resistance -4

Against Gravity -3

With Elimination of Gravity -2

Flicker -1

Paralysis - 0

17 (85%) of patients had normal muscle strength in all the muscle groups evaluated and 2 (10%) patients had good muscle strength and 1 (5%) patient had fair muscle strength.

TABLE-XXI

MUSCLE STRENGTH

S. No	Muscle Strength	No: of patients
1	Normal	17
2	Against slight resistance	2
3	Against gravity	1
4	With elimination of	0
5	Flicker	0
6	Paralysis	0

Range of Motion

Range of Motion was evaluated during each follow up and the improvement was recorded. The following table shows average range of motion (ROM) observed. Active forward elevation was defined as the angle between the humerus and the upper part of the thorax in the sagittal plane. External rotation was measured with the arm at patients side. Internal rotation was recorded as the posterior body segment that could be reached by the thumb with the elbow in a flexed position.

[Table-XXII]

TABLE-XXII

ROM

S.No	Motion	Range in deg.	Average
1	Elevation	90-170	126.25
2	Abduction	70-160	123.25
3	ER	35-60	47
4	IR	T3-L4	T11
5	Extension	30-55	43
6	Flexion	80-120	93.85

Radiological Outcome:

Quality of reduction, fracture alignment, restoration of articular congruity, fracture union, PHILOS plate deviation, screw penetration, backout, implant loosening and failure were assessed radiologically during follow up. All fractures united and the average time taken for union was approximately ten weeks. One patient with three part fracture went for malunion. No cases of implant deviation, screw penetration, screw back out, impingement and failure was encountered.

Overall Results

The overall results were rated according to the following criteria:

Maximum no: of points - 100

Excellent - more than 86.

Good - 71-85

Moderate: 56-70;

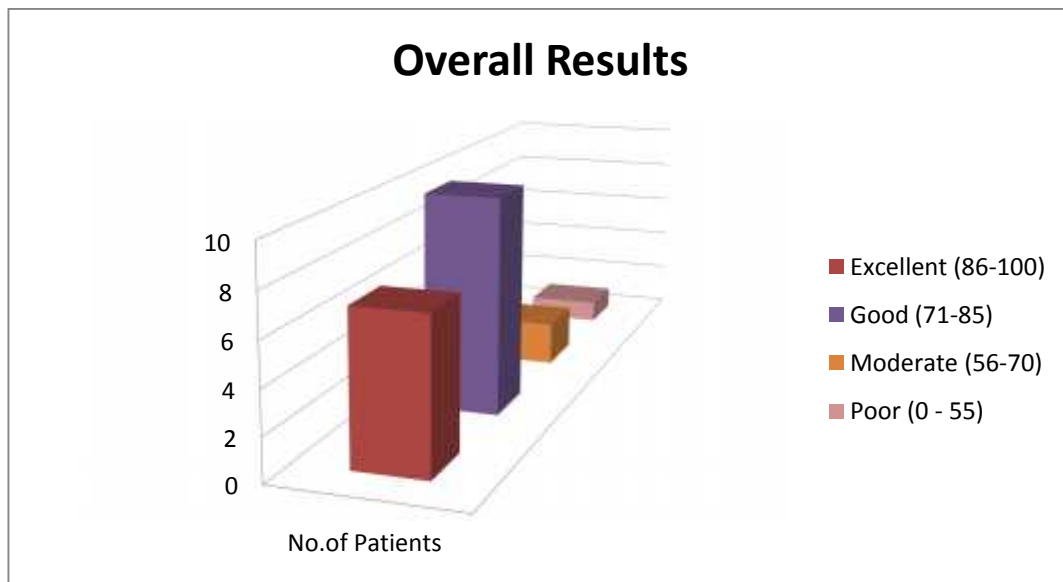
Poor : 0 – 55

Of the 20 cases 7(35%) patients had excellent result, 10(50%) good, 2(10%) moderate and 1 (5%) poor. [Table-XXIII]

TABLE-XXIII

OVERALL RESULTS

S.No	Rating	No: of Patients	Percentage
1	Excellent (86-100)	7	35
2	Good (71-85)	10	50
3	Moderate (56-70)	2	10
4	Poor (0 - 55)	1	5



DISCUSSION

In this prospective & retrospective study we have analysed 20 cases of Proximal Humerus Fractures treated surgically using PHILOS plates in our hospital. There was female preponderance in our study 12 (60%) similar to the conclusion of the study conducted by Hawkins & Bell involving fifteen (15) patients of proximal humeral fractures, there was female preponderance. In Kristiansen et al study of 565 proximal humerus fractures in 5,00,000 people, women were involved in 77% of fracture in all age groups. This is thought to be a result of advanced osteoporosis.

In our study the average age of the patients was 51 years which was corresponding to the reports by Hawkins, Bell and Gurr³⁹ and Flatow et al⁸⁷ and Cornell CN, Levine D S, Pagnani M J⁸⁸.

In our study, the most common mode and mechanism of injury was free fall at ground level and fall on an outstretched hand and average age is 51 years were much comparative to the results of the study conducted by Flatow et al⁸⁷ as fall on the outstretched arm was

the predominant mechanism of injury and average age of the patient is 53 in their study. Since our people attain menopause at an earlier age and have poor quality of bone stock, the average age is little lower.

Also in our study, unusual mode of injury like seizures was present in one patient. Neer Classification is the most widely used scheme for Proximal Humeral Fractures. It has gained universal clinical acceptance by orthopaedic surgeons and radiologists and is considered to have significant implications for both treatment options and outcomes. In our study, we also have followed the Neer's four part classification but several authors have reported low level of interobserver reliability. Sidor et al¹⁶ reported a reliability co-efficient of 0.48 for 1 viewing, 0.52 for 11 viewing and a reliability co efficient of 0.66.

In order to properly employ this classification, precise radiographic evaluation is of paramount importance⁵⁶. We have found the Neer's three view trauma series to be of greatest value in evaluating these fractures. The importance of these series has been shown by Richard J, Hawkins S and R.L. Angel⁷⁶.

Computed tomographic scans were done in patients who had equivocal findings and also to find the direction of dislocation. Flatow et al⁷⁴ believed that sole reliance on standard AP radiograph may lead to under estimation of the amount of displacement of fragments.

There was a predominance of two part fracture in our study (60%), of which greater tuberosity fractures were the most common. Associated dislocations were present in 40% of the patients. In the reduction of glenohumeral dislocation if tuberosity fragment remained displaced >1 cm or angulated more than 45°, ORIF was done. Repair in such patients restored the dynamic stability by reattachment of the muscles of the rotator cuff⁷⁴.

Flatow et al⁷⁴ in a series of 12 patients reported 50% excellent results and 50% good results in patients treated by ORIF with PHILOS plates for two part greater tuberosity fracture.

Closed treatment of three part fracture is often associated with moderate pain, poor range of motion and disability. Open Reduction and Internal Fixation (ORIF) was associated with good to

excellent results in more than 80% of patients in a report by Hawkins et al⁵⁶ and recommended surgical treatment for healthy active individuals who have three part fractures of the Proximal Humerus. Cornell and Levine⁷⁵ reported good results with screw tension band technique for 3 part fractures. Prosthetic replacement for three part fracture has been used by several authors.

In the treatment of four part fracture and fracture dislocations, less than 10% good or excellent results are obtained by open reduction and internal fixation^{100,101}. Isolated reports of revascularization of head of humerus following open reduction and internal fixation indicate satisfactory healing.

Unfortunately, many of the cases referred in the literature often have not been true four part fractures with isolation of articular fragment and follow-up is not sufficient to rule out long term osteonecrosis. Hugg and Lundberg noted 74% AVN when ORIF was used for these fractures. AVN is reported to be as high as 90% in four part fractures and 3-25% in 3 part^{4,77}.

All authors agree that pain relief has been greater than 90% with prosthetic replacement, but there has been varying results with regard to function, motion and strength. Neer and McIlveen have reported nearly 90% excellent results with an improved technique utilizing long deltopectoral approach and better rehabilitation.

From the data presented in this study we have demonstrated that majority of the patients had no pain or only mild pain (85%) which is comparable to the study by Hawkins et al^{56,102} and Flatow et al⁷⁴.

The average active elevation in our study in two part fractures was 126.25° and average external rotation was 47° which is comparable to the study by Flatow et al⁷⁴ in a study of 12 patients of two part fractures treated surgically.

The average elevation in our study with three part fracture was 124.25° and external rotation was 45.5° which is also comparable to the study by Hawkins et al⁵⁶ of 15 cases of 3 part Proximal Humerus fractures treated surgically.

Of the 8 patients with 3 and 4 part fractures, 40% regained atleast 90° abduction and elevation. About 85% of the patients had full muscle strength which is also comparable to the study by Hawkins et al⁵⁶ and Flatow et al⁷⁴.

We have seen few complications in our study. All fractures united and the average time taken for union was approximately ten weeks. One patient with three part fracture went for malunion. No cases of implant deviation, screw penetration, screw back out, impingement and failure was encountered. Malunion of greater tuberosity fragment in a patient with 2 part fracture treated with PHILOS plate resulted in restriction of abduction and impingement. In this patient poor radiological outcome lead to poor functional outcome as well. Some patients despite having malunion may have a good functional capacity reflecting the fact that radiological outcome may not imply functional outcome.

Heterotopic ossification occurred in one patient with 3 part fracture, probably because the patient had exercised native treatment in the form of many attempted reduction, massage and splinting.

Many authors have reported an incidence of upto 10% of heterotopic ossification in proximal humeral fractures⁷⁹. There was no non-union or radiographic evidence of avascular necrosis or deep infection in our study.

Finally a prolonged closely monitored and well defined program of rehabilitation was necessary to obtain the best functional results. We have followed the three phase rehabilitation protocol of Hughes and Neer in all our patients and this has provided good results.

PHILOS results: The average constant score in our study with 20 patients was 81.7 which is slightly better than the the study by Koukakis et al⁷⁸.

In summary, fractures of Proximal Humerus may be extremely demanding. There are many pitfalls for the unwary patient and surgeon to avoid during the course of treatment. Emphasis is placed on complete and accurate diagnosis and formulation of safe and simple techniques for restoration of anatomical stability, fracture union, cuff integrity, range of motion and adequate muscle strength.

CONCLUSION

- As PHILOS plate has options for more number of screws for humeral head than conventional locking plate, it will lead to more stable fixation of fracture fragments and early mobilization of the patients.
- As PHILOS plate has options of multidirectional screws, it will aid in better stability.
- Earlier the surgery is done better are the results.
- Functional outcome is better with isolated fractures than with fracture dislocations.
- Results are best when operative method results in stable fixation that allows early passive mobilization.
- Functional outcome of 2 part fractures is better than 3 part and 4 part fractures.
- Radiological outcome assessed by means of quality of reduction and union of fracture in two and three part fractures is better than in four part fractures.
- Finally, we concluded that proximal humeral fractures when treated surgically especially using PHILOS plate provided better stability and early mobilization, and hence lesser stiffness and greater ROM.

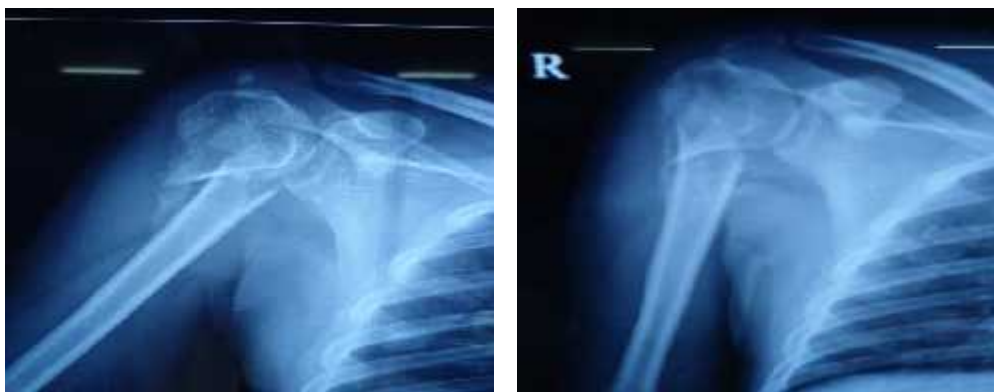ILLUSTRATIVE CASES

CASE - 1

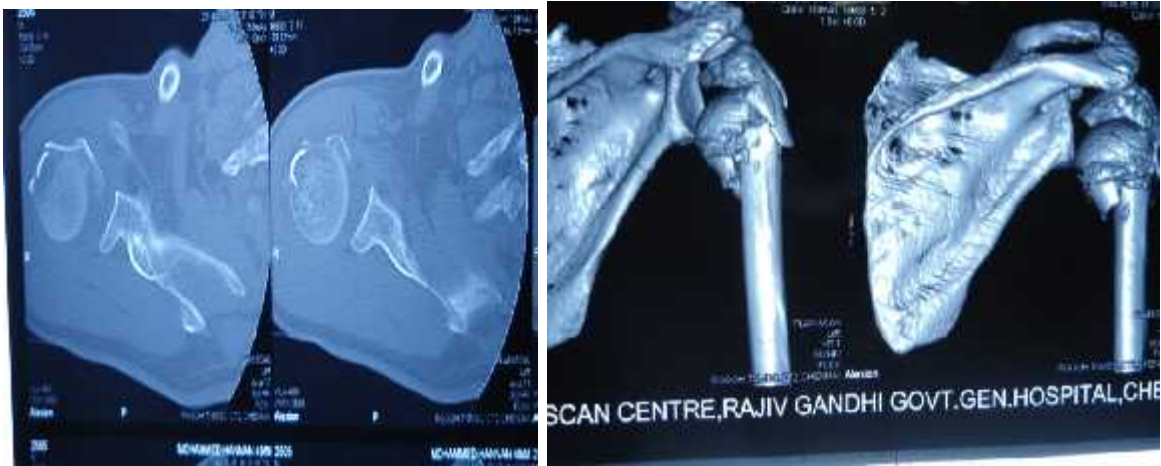Mr X, a 45 years old male who sustained a two part fracture of right proximal humerus after a fall at ground level in his residence got admitted in our hospital after three days of injury. He was a known diabetic on regular oral hypoglycaemics.s. He underwent internal fixation with PHILOS plate through deltopectoral approach.

Post-operatively, the patient was rehabilitated with 3 Phase Rehabilitation protocol of Hughes and Neer.. The patient was followed up at regular monthly intervals. He was able to perform his day to day activities without any pain and restriction and he has excellent functional outcome.

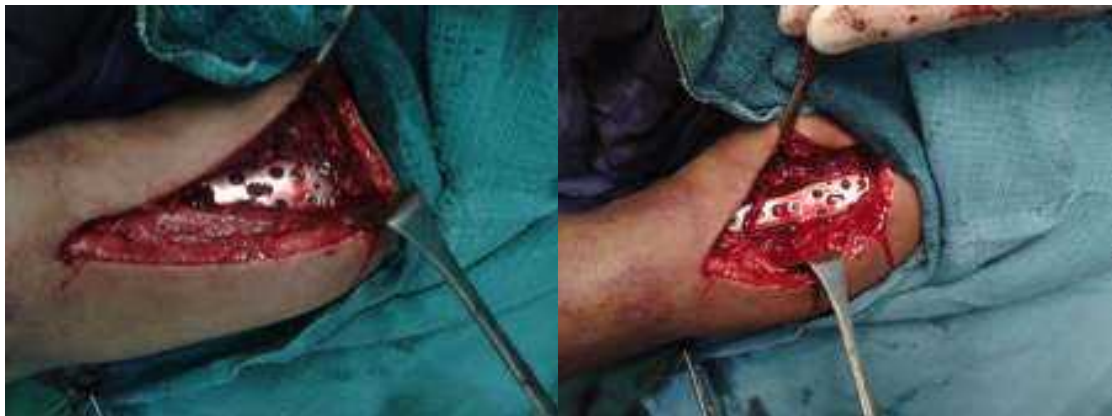Pre OP X - ray



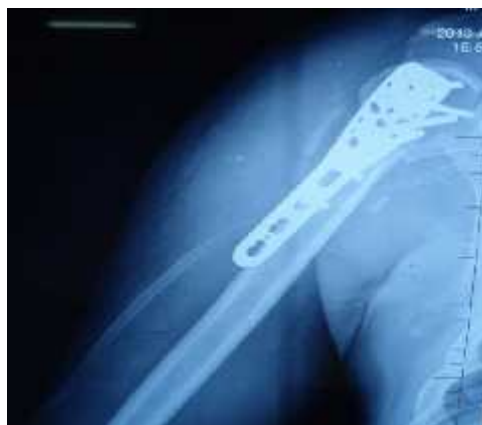Pre OP CT Scan



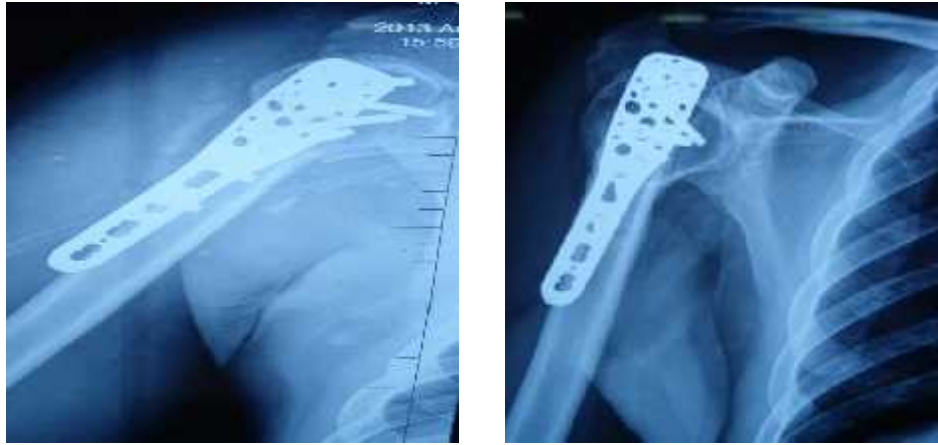Intra OP Pictures



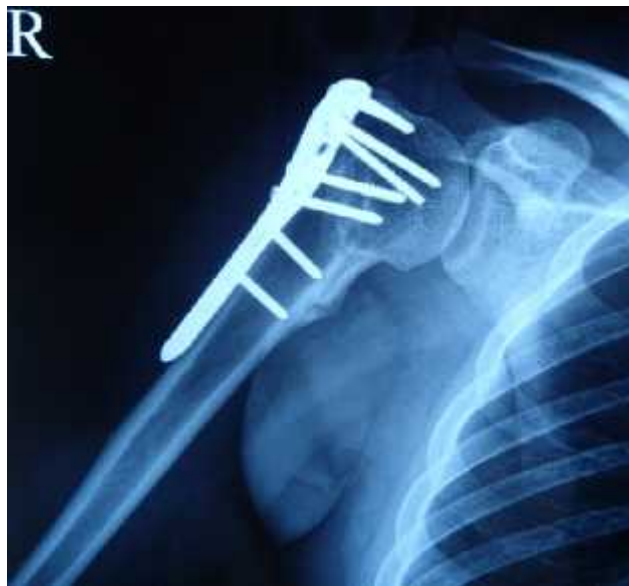Immediate Post OP X-ray



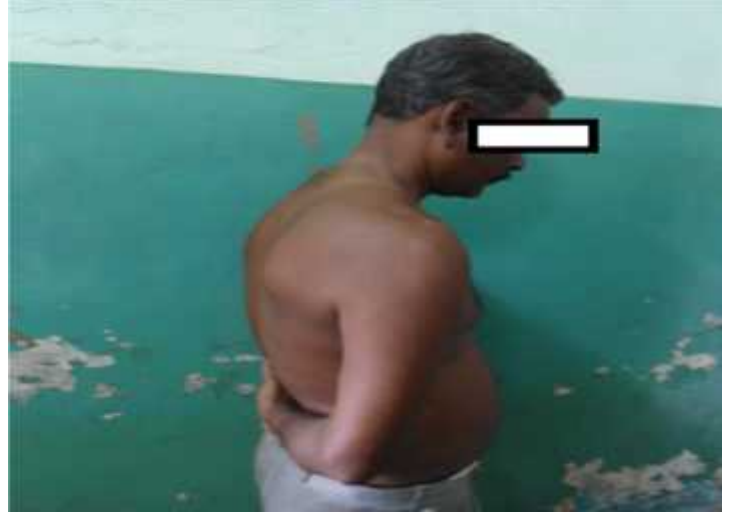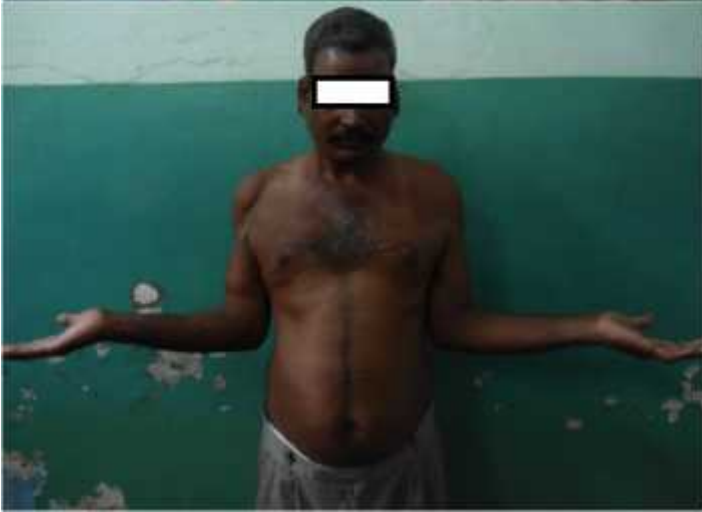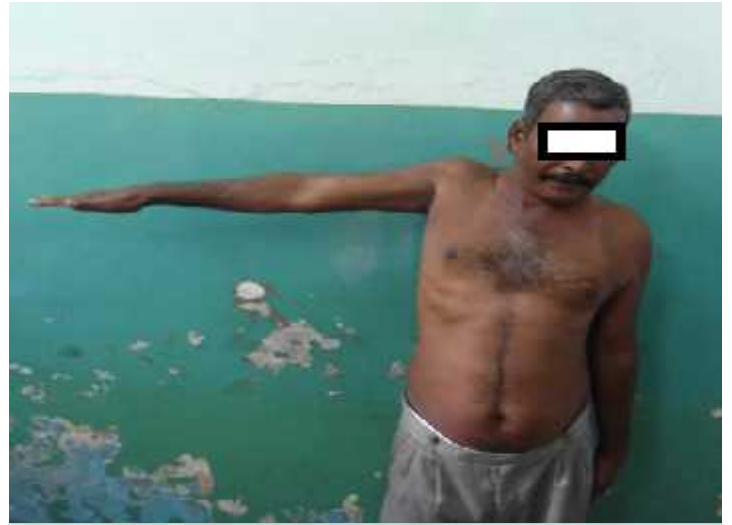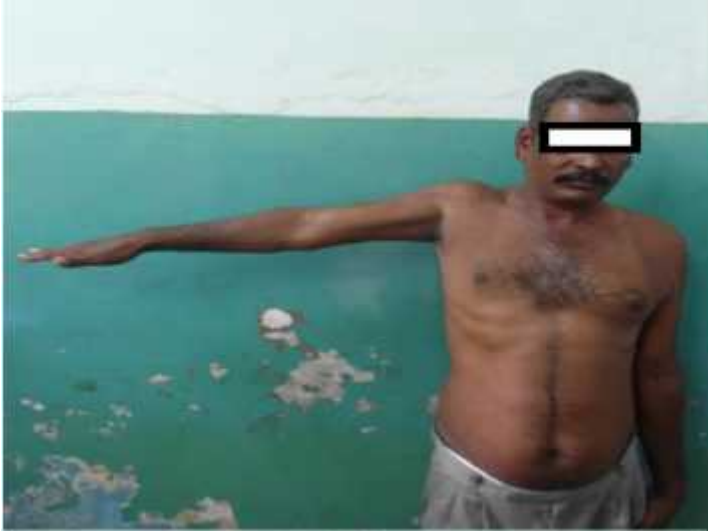3 Months follow up



6 Months follow up



CLINICAL PICTURES



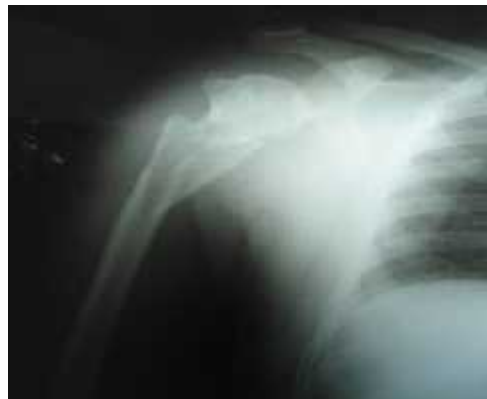CASE- 2

Mr .Y, a 28 years old male manual labourer fall from height while working and sustained a two part fracture of right proximal humerus. He also sustained fracture distal radius on the same side, got admitted on the day of injury.

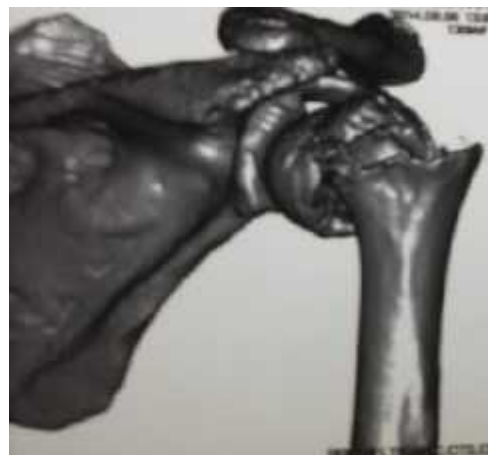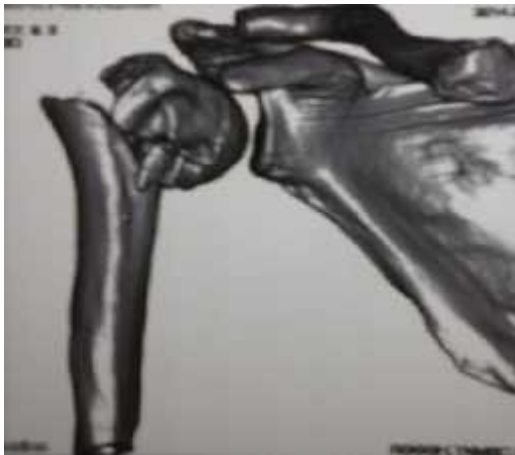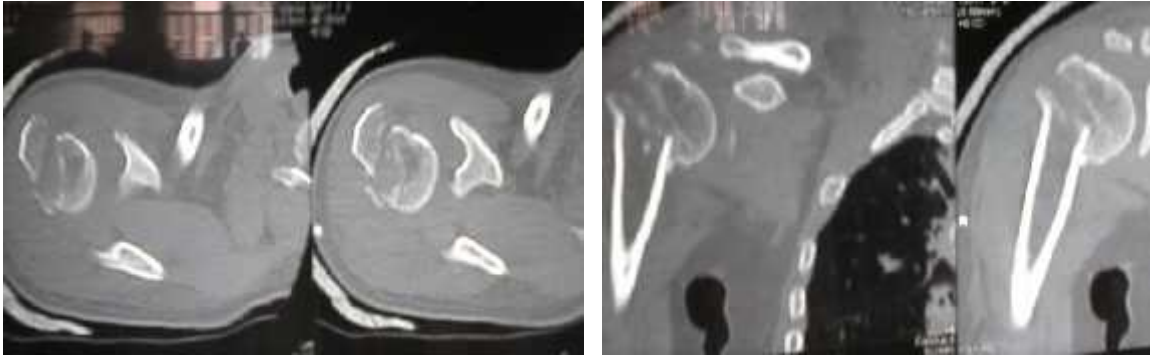
The patient underwent ORIF with Plate osteosynthesis with PHILOS plate. Postoperatively the patient had wound gaping for which he required secondary suturing. The patient was Rehabilitated with 3 Phase Rehabilitation Protocol of the Hughes and Neer.

The patient was followed up every month till 7 months and he had excellent functional result.

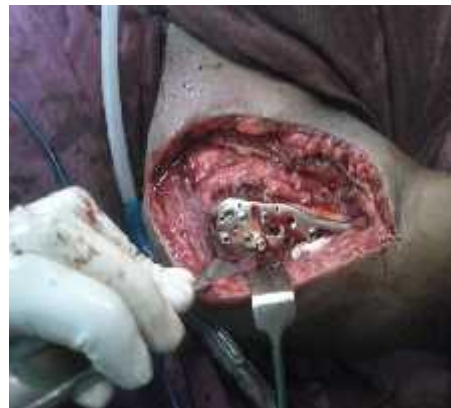Pre OP X - Ray



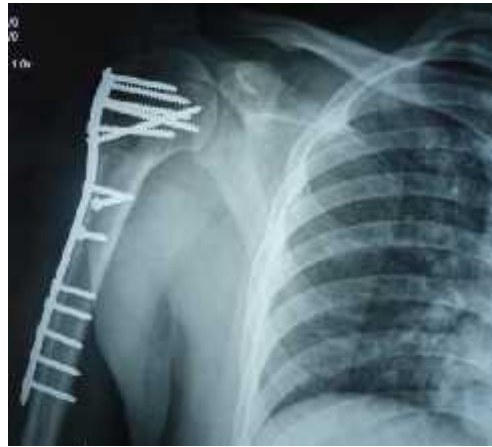Pre OP CT



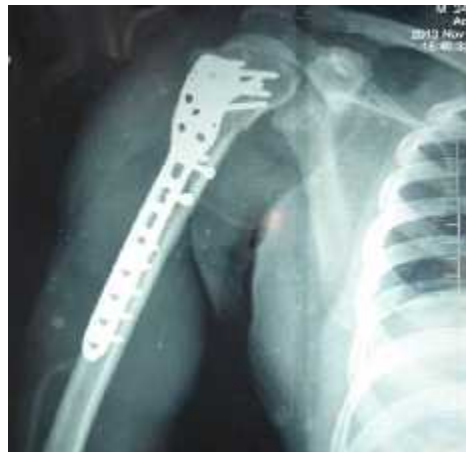Intra OP Picture



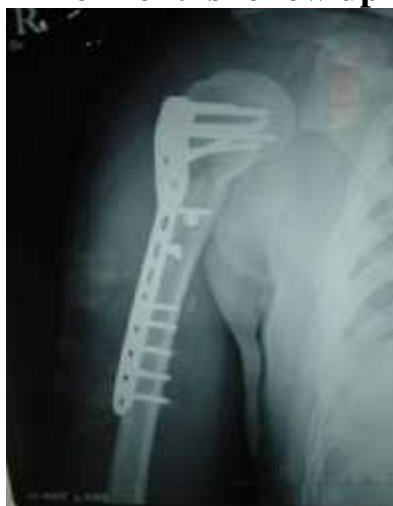Immediate Post OP X-Ray



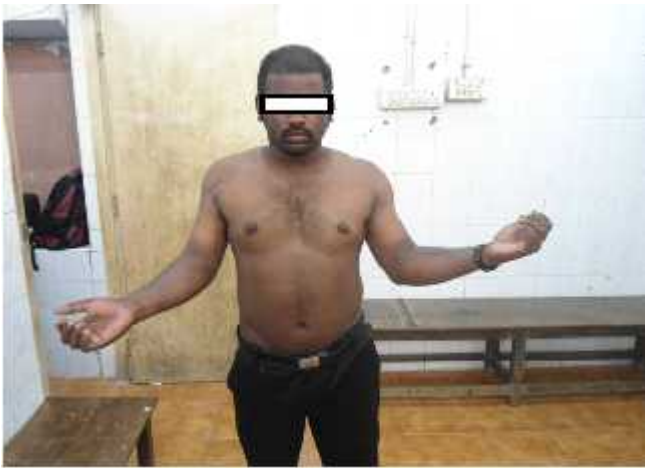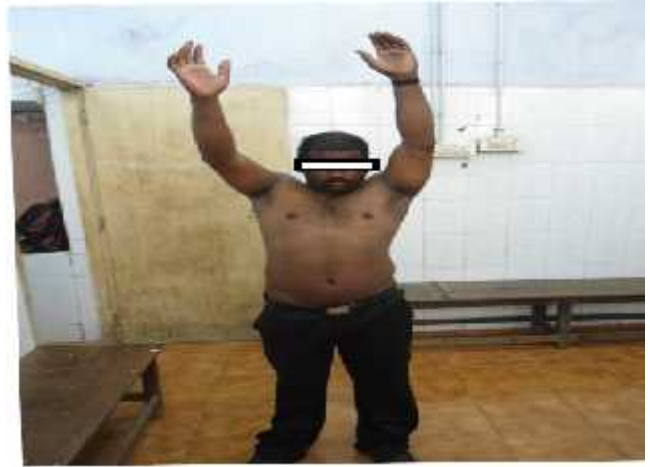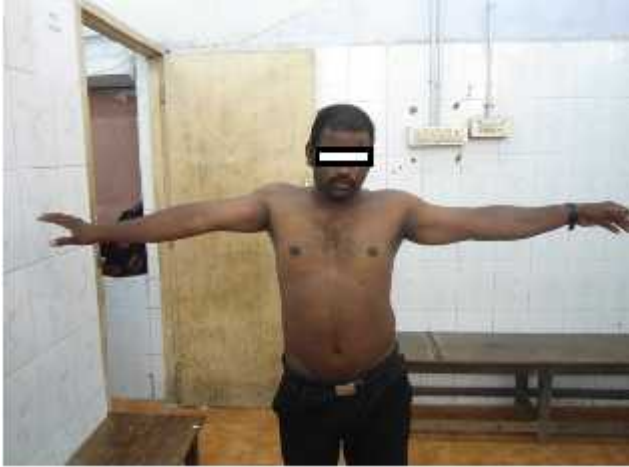2 Months follow up



6 Months follow up



CLINICAL PICTURES



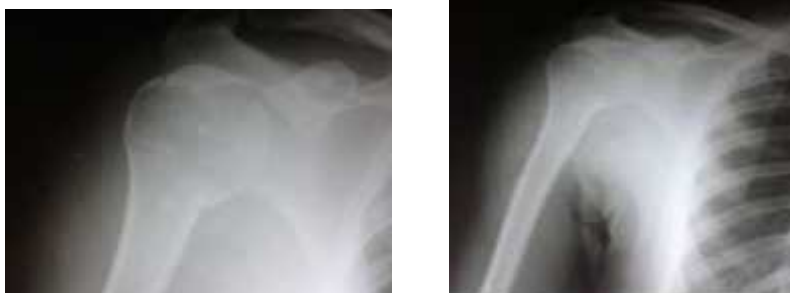CASE - 3

Mr . X, a 48 years old bank employee met with an accident while he was going to his duty in a two-wheeler and sustained two part fracture of right proximal humerus. He got admitted on the same day of injury.

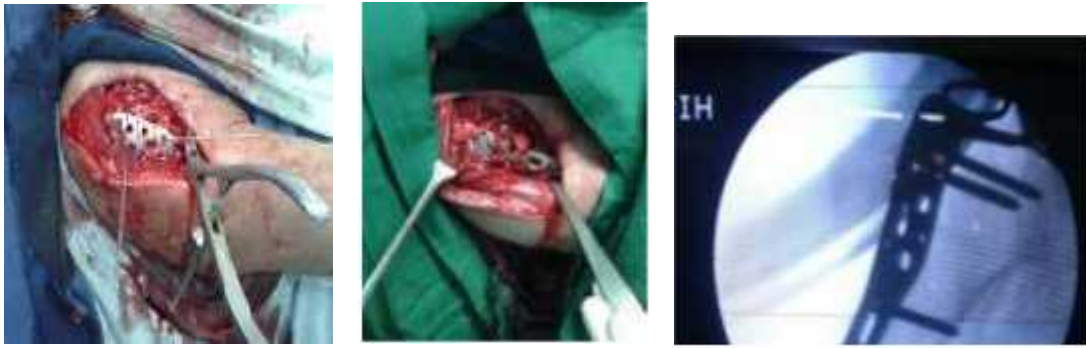The patient underwent ORIF with PHILOS plate through delto pectoral approach after three days of injury.

Postoperatively, the patient had no complications and the Rehabilitation started on from the 2nd day with pendulum exercises and continued with the Rehabilitation Protocol of Hughes and Neer. The patient was followed up regularly at monthly intervals. At the end of seven months patient had excellent functional result without any pain and he was able to perform his day to day activities efficiently.

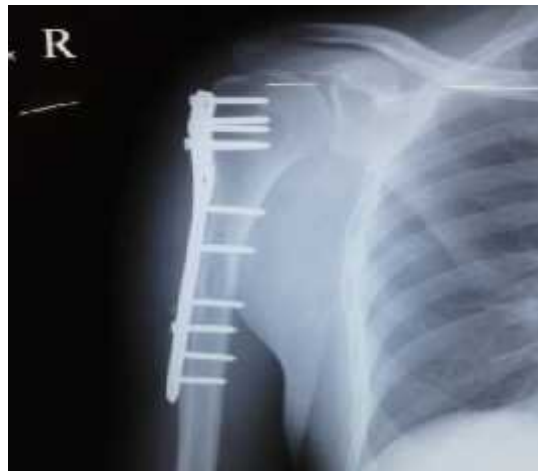Pre OP X - rays



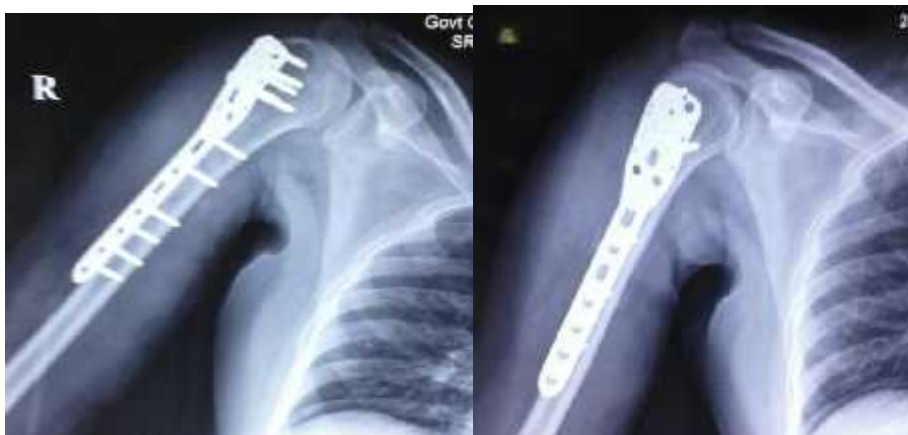Intra OP Pictures




Immediate Post OP



6 Months follow up



Clinical Pictures



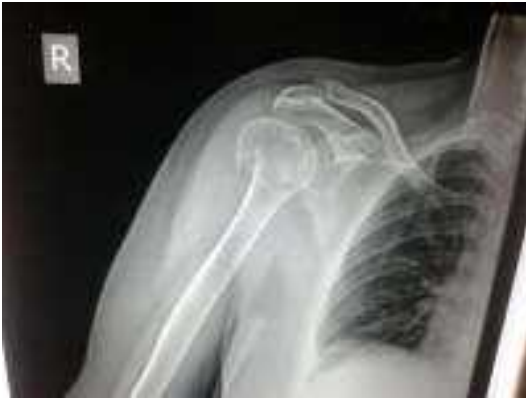CASE- 4

A 65 years old female Mrs.Y, a right handed person, (house wife) sustained a comminuted two part fracture of surgical neck of humerus after she fall at ground level, in her residence. She was a known hypertensive and diabetic on regular treatment. She was referred from a private hospital with POP after 3 days of injury.

She underwent surgery on fourth day after admission with 5 holed PHILOS plate through deltopectoral approach.

Post-operatively, the patient was started on pendulum exercise from day 2 and supine external rotation exercises from 3rd week. Periodical functional and radiological assessment shows excellent range of movements and fracture union. She was able to perform her daily activities without any pain.

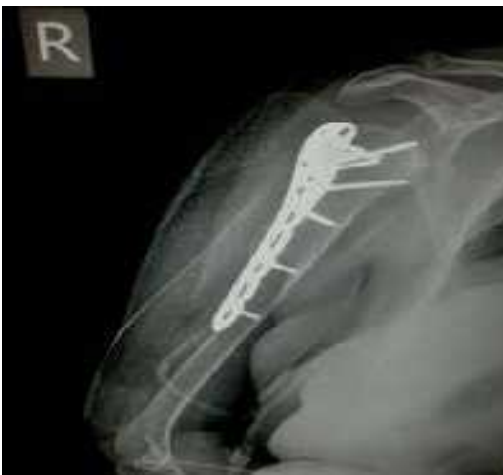Pre op X - ray AP view



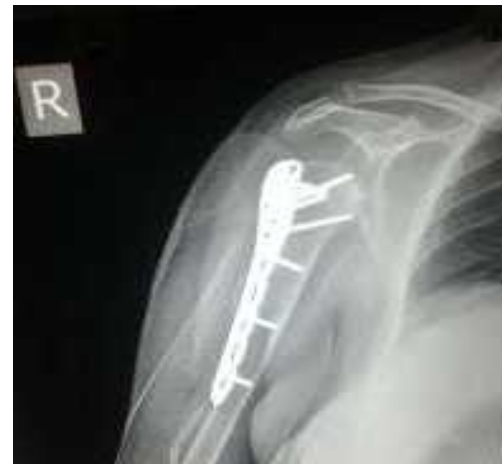Intra-OP C-arm Image



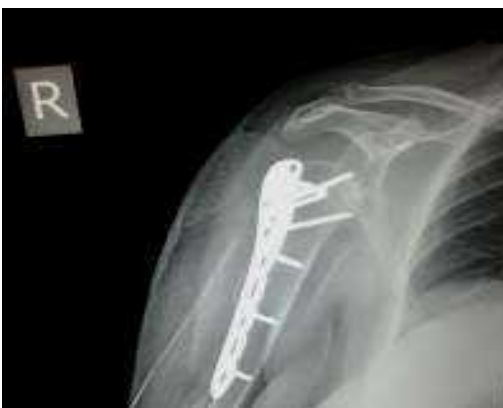Immediate Post OP X-ray



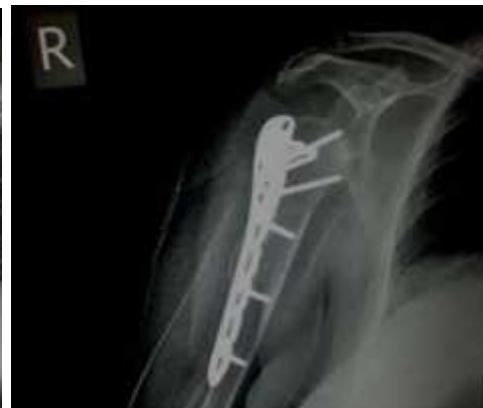2 Months Post OP X-ray



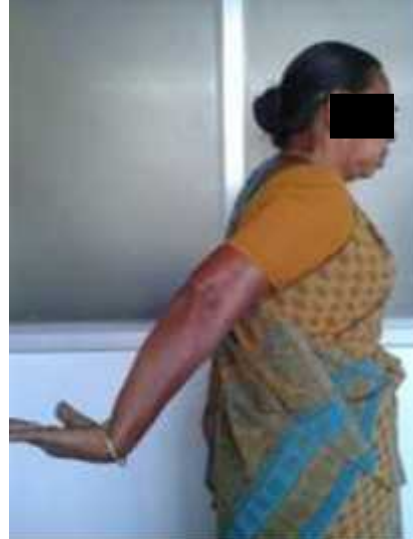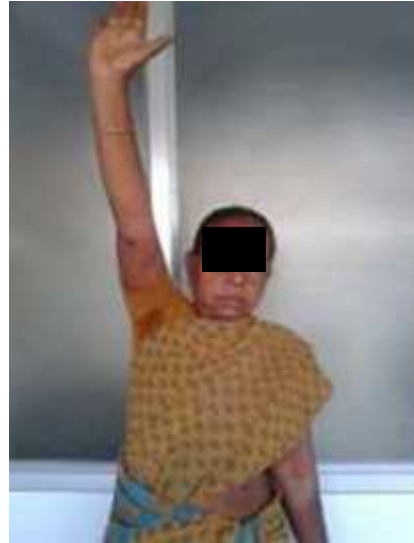4 Months Post OP X-ray



6 Months Post OP X-ray



CLINICAL PICTURES



EVALUATION FORM

CONSTANT SCORE TECHNIQUE

BACKGROUND

The European Society for Shoulder and Elbow Surgery (ESSES) adopted the scoring system of C Constant and A Murley. This scoring system consists of four variables that are used to assess the function of the shoulder.

The subjective variables are pain and Activities of Daily Living (sleep, work, recreation / sport) which give a total of 35 points. The objective variables are range of motion and strength which give a total of 65 points.

SUBJECTIVE

Pain	15
ADL (sleep, work, recreation/sport)	20

OBJECTIVE

Range of motion	40
Strength	25

PAIN

Pain	Points
None	15
Mild	10
Moderate	5
Severe	0

ACTIVITIES OF DAILY LIVING (ADL)

Activity Level	Points
Full work	4
Full recreation/ sport	4
Unaffected sleep	2

Positioning	Points
Upto waist	2
Upto xiphoid	4
Upto neck	6
Upto top of head	8
Above head	10

RANGE OF MOTION

Active range of motion should always be measured as part of the Constant and Murley Score.

ESSES recommends measuring range of motion with the patient sitting on a chair or bed, with weight even distributed between the ischial tuberosities. No rotation of the upper torso is allowed during the examination.

In the case of active motion, the patient lifts the arm to a painfree level. The range of motion is determined by noting the number of degrees at which the pain starts. If one measures the active range of motion with pain, this should be stated. The Constant score cannot then be applied beyond the initiation of pain.

The most important thing is that range of active motion is performed and measured in a standardized way.

In the Constant score system there is precise information about how the points are calculated. Bear in mind that 150 degrees of flexion give 8 points, while 151 degrees give 10 points.

Forward flexion 10 points	
0-30°	0
31-60°	2
61-90°	4
91-120°	6
121-150°	8
151-180°	10

Abduction 10 points

0-30°	0
31-60°	2
61-90°	4
91-120°	6
121-150°	8
151-180°	10

External rotation 10 points	
Not reaching the head	0
Hand behind head with elbow	
Hand behind head with elbow back	2
Hand on top of head with elbow	
Hand on top of head with elbow back	2
Full elevation from on top of head	2

INTERNAL ROTATION

End of the thumb to lateral thigh	0
End of the thumb to buttock	2
End of the thumb to lumbosacral	4
End of the thumb to L3 (waist)	6
End of the thumb to T 12	8
End of the thumb to T 7(interscapular)	10

STRENGTH

Strength is given a maximum of 25 points in the Constant Score. The significance and technique of strength measurement has been and still continues to be the subject of much discussion.

The European Society for Shoulder and Elbow Surgery measures (ESSES) strength according to the following method:

- A spring balance is attached distal on the forearm.
- Strength is measured with the arm in 90 degrees of elevation in the plane of the scapula (30 degrees in front of the coronal plane) and elbow straight.
- Palm of the hand facing the floor (pronation).
- The patient is asked to maintain this resisted elevation for 5 seconds.

- It is repeated 3 times immediately after another.
- The average in pound (lb) is noted.
- The measurement should be painfree. If pain is involved the patient gets 0 points.
- If patient is unable to achieve 90 degrees of elevation in the scapula plane the patient gets 0 points.

***FUNCTION OF MUSCLE (M)**

0 Less than 1 kg
 3 "1 kg - 2 kg"
 5 "2 kg - 3 kg"
 7 "3 kg - 4 kg"
 9 "4 kg - 5 kg"
 11 "5 kg - 6 kg"
 13 "6 kg - 7 kg"
 15 "7 kg - 8 kg"
 17 "8 kg - 9 kg"
 19 "9 kg - 10 kg"
 21 "10 kg - 11 kg"
 23 "11 kg - 12 kg"
 25 "12 kg or above"

SCORING

0-55	Poor
56-70	Moderate
71-85	Good
>86	Excellent

BIBLIOGRAPHY

1. Tom R. Norris, Fractures and Fracture Dislocations of Gleno- Humeral Complex, JB Lippincott Company- Philadelphia-1993 ,Chapter 29 : 405-421.
2. Tom R. Norris, Skeletal Trauma; Fractures of Proximal Humerus and Dislocation of shoulder: I Edition; Vol.2; Ch.39: 1201-1279.
3. Lind T, Kroner TK, and Jensen J. The Epidemiology of Fractures of the Proximal Humerus- ORTHOPAEDICS TRAUMA SURG. 108;285-87;(1989).
4. Neer CS . Displaced Proximal Humerus Fractures Part I: Classification And Evaluation:J Bone Joint Surg Am 1970;52(6);1077-89.
5. Horak J, Nilsson BE: Epidemiology of fractures of the proximal end of humerus. CORR 112: 250-253:1975.
6. Rose SH, Melton LJ, Morrey BF et al Epidemiologic features of Humeral Fractures: CORR 168;24, 1982.
7. Hippocrates. The Classic: Injuries of the shoulder dislocation, Clinical Orthopaedics and Related Research 1989: 246: 4-7.
8. Mika Palvanen, Seppo Niemi, Pekka Kannus and Jari Parkkari. Update in the Epidemiology of Proximal Humeral Fractures. Clinical Orthopaedics and Related Research, 442, 87-92.
9. Leyshon RL, Closed Treatment of Fractures of Proximal Humerus. Acta Orthopaedics Scandinavia, 55, 48-51(1984).
10. Kristiansen B and Christensen W: HF: Late Results in selection to classification and Treatment. Acta Orthop. Scandinavia,58;123-127(1987).
11. Post M, Fractures of the upper humerus. Orthop Clin North Am. Apr 1980 (Vol. 11, Issue 2, Pages 239-52).
12. Hawkins RJ, Angelo RL, Displaced proximal humeral fractures. Treatment Selection and avoiding pitfalls. Orthop Clin North Am., Jul 1987 (Vol. 18, Issue 3, Pages 421-31).
13. Neviasser RJ. Radiologic assessment of the shoulder. Plain and arthrographic. Orthopaedic Clinics North America., Jul 1987 (Vol. 18, Issue 3, Pages 343-9).
14. Joseph Bernstein, Louis M. Adler, John E. Blank, Robert M. Dalsey, Gerald R. Williams, and Joseph P. Iannotti Evaluation of the Neer System of Classification

- of Proximal Humeral Fractures with Computerized Tomographic Scans and Plain Radiographs. *J. Bone Joint Surg. Am.*, Sep 1996; 78:1371 - 5.
15. ML Sidor, JD Zuckerman, T Lyon, K Koval, F Cuomo, and N Schoenberg, The Neer classification system for proximal humeral fractures. An assessment of interobserver reliability and intraobserver reproducibility. *J. Bone Joint Surg. Am.*, Dec 1993; 75: 1745 - 1750.
 16. Terry S. Canale, Linda Jones, Kay Daughtery;Campbell Operative Orthopedics: 12th Edition; Vol.3; 2286-2296.
 17. Iannotti JP, Williams GR, Total shoulder arthroplasty. Factors influencing prosthetic design. *Orthop Clin North Am.* 1998 Jul;29(3):377-91.
 18. Post M. Constrained arthroplasty of the shoulder. *Orthop Clin North Am.*; Jul 1987;18(3):455-62.
 19. Steven J. Hattrup. Indications, Technique and Results of Shoulder Arthroplasty. *Orthop Clin North Am.*; Jul 1998;29(3):445-466.
 20. Treg D. Brown, Louis U. Bigliani, Complications with Humeral head replacement; *Orthop Clin North Am.*; Jan 2000;31(1):77-90.
 21. Lugli, Tomaso: Artificial Shoulder Joint by Pean(1893). The facts of an Exceptional intervention and the Prosthetic method. *Clinical Orthop.* 133:215-218;1978.
 22. Neer CS II: Articular Replacement for the Humeral head. *JBJS* 37A;215-228, April 1955.
 23. Letin AWF; Upelana SA; and Scales JT: The Stanmore TSR. *JBJS*: 64 B(1): 47-51. 1982.
 24. Peter L.Williams, Roger Warwick, Mary Lawrence H.Hannister, Gray's Anatomy: 3rd Edn., C. Longman Group UK Ltd.; 1992; 86-90.
 25. Jan Magus Bjorkenheim, JAKKO Pajarinen -Internal fixation of proximal humerus fractures treated with a Locking Compression Plates -*Acta Orthop Scand* (2000)4;75 (6);741-745.

26. C.P.Charalambous, I.Siddique, et al –Proximal humerus internal locking system for the treatment of Proximal humerus fractures –Arch. Of Ortho and trauma surgery (2007) 127;205-210.
27. Kenmet A.Egol et al (2008) – Early complications in Proximal humeral fractures treated with Locked plates- Journao of Orth.Trauma;March 2008- Volume 22- Issue 3 –Pages 159-164.
28. M.A.Fazal, FS Haddad; Philos Plate Fixation For Displaced Proximal Humeral Fractures- Journal of Orth.Surg. 2009;17(1) pages 8-15.
29. A A Martinez, Janenca A. Herrera, (Philos plate fixation for proximal humerus, Journal of Orth. Surg (2009); 17(1) Pages 4-10.
30. Sameer Agarwal et al, Displaced Proximal Humeral Fractures; an Indian experience with Locking plates. Journal of Ortho. Surgery and Research 2010,5:60
31. Rose PS, Adams CR, Torchia ME, Jacofsky DJ, Haidukewych GG.Steinmann SP. Locking plate fixation for proximal humeral fractures; initial results with a new implant. J Shoulder Elbow Surg.2007;16(2);202-207
32. Andrew.H.Crenshaw; Edward.A.Perez, Fractures of the shoulder,arm and forearm- chapter 54;Campbells Operative Orthopaedics by Terry.S.Canale,James.H.Beaty 12 th edition 2012;page no.3496
33. Williams PL and Warwick R; Gray s Anatomy,Philadelphia, WB Saunders,1980.
34. Moorekl; The developing human. Philadelphia, WB, Saunders 1982.
35. Hasan M and Narayan D (1964).Radiological study of the ossification of the upper e of the humerus. Journal of Anatomical Society of India,13;70-75.
36. KAPANDJI IA (1970). The Physiology of Joints, Churchill Livingstone, London.
37. MacConaill MA and Basmajian J (1977), Muscles and Movements, Kreiger Publishing Co Newyork.
38. De Palma AF; Surgery of the Shoulder. Philadelphia, JB Lippincott, 1983.
39. Iannotti JP, Gabriel JP, Schneck SL, et al;The normal glenohumaeral relationships. J Bone Joint Surg Am 74;491-500,1992.
40. Neviaser RJ, Anatomic considerations and examination of the shoulder. Orthop Clin North Am.; Apr 1980 (Vol. 11, Issue 2, Pages 187-95).

41. Saha, A. K., Das, A. K., Dutta, S. K. Mechanism of Shoulder Movements and a Plea for the Recognition of "Zero Position" of Glenohumeral Joint. *Clinical Orthopaedics & Related Research*. 173:3-10, March 19
42. Laing PG: The arterial supply of the adult humerus *JBJS*;38A:1105(1956).
43. Gerber C, Schneeberger AG, and Vinto T. The Arterial vascularisation of the humeral head *JBJS:COA*:1486-1494(1990).
44. Brooks CH, Rovell WJ, Heatley FW. Vascularity of the humeral head after PHF. An Anatomical Cadaver Study. *JBJS, Br.*1993,Jan;75(1);6-132.
45. McMinn RMH, *Regional Applied Anatomy* 8 th edition-Longman Group UK Ltd; 1990
46. Charles A. Rockwood Jr., Robert WS, Bucholz, David P. Green, James D. Heckman, *Fracture in Adults*; 4th Edition; Vol.I, pp 1055-1091.
47. Bernard F. Moorey, Eiji 1701, Kai-Narar *Biomechanics of the shoulder*, Ch-5; pp 233-272.
48. Soslowsky LJ, Carpenter JE, Bucchieri JS, Flatow EL. Biomechanics of the rotator cuff. *Orthop Clin North Am.*;Jan 1997 (Vol. 28, Issue 1, Pages 17-30).
49. Kristiansen B and Christensen S W: PHF Late results in relation to classification and treatment. *Acta. Orthop. Scand*. 58;124-127,1987.
50. Neer CS I: Displaced PHF Part I Classification,. *JBJS*; 52A: 1077-1089(1970).
51. Mills HJ and Horn G; Fractures of the Proximal Humerus in adults *J Trauma*; 25, 801-805(1985).
52. CourtBrown CM, Garg A, McQueen MM. The epidemiology of proximal humeral fractures. *Acta Orthop Scand* 2001; Court 72;365-371
53. Lee SH, Dargent-Molina P, Breart G. Risk factors for fractures of the proximal humerus: results from the EPIDOS prospective study. *J Bone Miner Res* 2002;17:817-825.
54. Reinus WR, Hatem SF. Fractures of the greater tuberosity presenting as rotator cuff abnormality: magnetic resonance demonstration. *J Trauma* 1998;44;670-675

55. Zanetti M, Weishaupt D, Jost B, et al. MR imaging for traumatic tears of the rotator cuff: high prevalence of greater tuberosity fractures and subscapularis tendon tears. *AJR Am J Roentgenol* 1999;172:463-467.
56. McKLaughlin HL Posterior dislocation of the shoulder. *JBJS*; 34A; 584-590(1952).
57. Bloom MH, and Obata WG. Diagnosis of posterior dislocation of the shoulder with use of velpeau axillary and angle-up roengengraphic view. *JBJS* 49A, 943-949(1967).
58. Horsfield D and Jones SN. A useful projection in radiography of the shoulder. *JBJS*;69B;338(1987).
59. Tietge RA and Cuiollo JV C.A.M axillary xray. Exhibit to the academy meeting of AAOS: *OrthoTrans*. 6;451(1982).
60. Bloom MH and Obata WG : Diagnosis of posterior dislocation of the shoulder with use of Velpeau Axillary and Angle-up roentgenographic views. *JBJS* : 49A; 943-949)1067).
61. SC Klasson, JL Vander Schilden, and JP Park Late effect of isolated avulsion fractures of the lesser tubercle of the humerus in children. Report of two cases. *J. Bone Joint Surg. Am.*, Nov 1993; 75: 1691 - 1694.
62. Gerber C, Werner CM, Vienne P. Internal fixation of complex fractures of the proximal humerus. *JBJS*, Br. 2005, Jun. 87(6): 84.
63. Neader Helmy, MD and Beat Hintermann, MD. New Trends in Treatment of proximal humeral fractures. *CORR* : 442, Jan.2006, pp.100-108.
64. Williams GR Jr, Wong KL. Two-part and three-part fractures: open reduction and internal fixation versus closed reduction and percutaneous pinning. *Orthop Clin North Am*. 2000 Jan;31(1):1-21.
65. Rees, J, Hens J, Ribbans W. Assessment & management of 3 and 4 part proximal humeral fractures. *CORR*, 1998, Aug, 353, 18-29.
66. Paschal, KS Hutton, and PT Weatherall Isolated avulsion fracture of the lesser tuberosity of the humerus in adolescents. A report of two cases *J. Bone Joint Surg. Am.*, Sep 1995; 77: 1427 - 1430.

67. DePalma AF and Cautilli, RA. Fractures of upper end of the humerus. CORR, 20 : 73-93 (1961).
68. Neer CS and Rockwood CA : Fractures and dislocation of the shoulder, in fractures (Eds. CA Rockwood and DP Green). JB Lippincott, Philadelphia, 1984, pp. 675-707.
69. Current treatment of complex fractures. Operative Techniques in Orthopaedics. Vol.9 (3) : July 1999, pp.130-138.
70. RJ Hawkins, RH Bell, and K Gurr The three-part fracture of the proximal part of the humerus. Operative treatment. J. Bone Joint Surg. Am., Dec 1986; 68: 1410 - 1414.
71. Habermeyer, P. Schweiberer L. Fractures of the proximal humerus. Orthopade, Jun 1989; 18(3) : 200-207.
72. Total shoulder replacement arthroplasty. Ranawat CS, Warren R, Inglis AE Orthop Clin North Am Apr 1980; Vol. 11; Issue 2; Pages 367-373.
73. RH Cofield Total shoulder arthroplasty with the Neer prosthesis J. Bone Joint Surg. Am., Jul 1984; 66: 899 - 906.
74. Cuomo F, Checroun A. Avoiding pitfalls and complications in total shoulder arthroplasty. Orthop Clin North Am., Jul 1998 (Vol. 29, Issue 3, Pages 507-18).
75. Gristina AG, Romano RL, Kammire GC, Webb LX Total shoulder replacement. Orthop Clin North Am; Jul 1987; Vol. 18; Issue 3; Pages 445-53.
76. Instructional Course Lecture. 2006; 54 : 357-62.
77. Neer CS II Displaced Proximal Humeral Fractures; Treatment of 3 part and 4 part fractures. J Bone Joint Surg Am 52A;1090;1970
78. Coumo F, Flatow EL, Miller SR et al., Open reduction and internal fixation of 2 part and 3 part proximal humeral fractures. Orthop. Trans, 14 : 588 (1990).
79. Bigliani LU, Nicholson GP., Flatow EL. The management of fractures of proximal humerus. In Arthroplasty of the shoulder (ed, RJ Friedman). Thieme, New York (1994).
80. Hughes M and Neer CSII. Glenohumeral joint replacement and post operative rehabilitation : Phys. Ther., 55, 850-58, 1975.

81. Ben kibler W, Beren Livingstone, Robin Bruce Current concepts in shoulder rehabilitation; *Advances in Operative Orthopaedics*; Vol.3; 1995: Mosby Year Book Inc.
82. Constant C R, Murley A H G. A clinical method of functional assessment of the shoulder. *Clinical Orthopaedics and Related Research* 1987; 214: 160-164.
83. Constant C R. Assessment of the shoulder. In: Watson M. *Surgical disorders of the shoulder*. Churchill Livingstone, New York. 1991; 39-45.
84. Constant C R. Constant Scoring Technique for Shoulder Function. SECEC information. 1991. Nr 3.
85. Gerber C. Integrated Scoring Systems for the Functional Assessment of the Shoulder. In: Matsen F, Fu F, Hawkins . *The Shoulder: A Balance of Mobility and Stability*. Rosemont, 1992; 531-50.
86. Circular to members of British Shoulder and Elbow Society.
87. EL Flatow, F Cuomo, MG Maday, SR Miller, SJ McIlveen, and LV Bigliani Open reduction and internal fixation of two-part displaced fractures of the greater tuberosity of the proximal part of the humerus *J. Bone Joint Surg. Am.*, Sep 1991; 73:1213 - 1218.
88. Cornell CN, Levine D, Pagnani MJ. Internal fixation of proximal humerus fractures using the screw-tension band technique. *J Orthop Trauma*. 1994;8(1):23-7.
89. WP Barrett, JL Franklin, SE Jackins, CR Wyss, and FA Matsen Total shoulder arthroplasty *J. Bone Joint Surg. Am.*, Jul 1987; 69: 865 - 872.
90. Hagg O, and Lundberg B, Aspects of prognostic factors of communitied and dislocated proximal humeral fractures. In *surgery of the should* (eds JE Bateman & RP Welsh) BC Decker, Philadelphia (1984).
91. Athanasios Koukakis, Constantinos D. Apostolou, Tarun Taneja, Dimitrios S. Korres and Alexander Amini. Fixation of proximal humerus fractures using the Philos Plate. *CORR*, 2006, 442, pp.115-120.
92. Frederick A. Matsen, Kevin L. Smith. Effectiveness evaluation and the shoulder; Chapter 28; pp 1313-1339.

93. Hintermann B, Trouillier HH, Schafer D. Rigid internal fixation of fractures of the proximal humerus in older patients. *JBJS, Br. Nov.* 2000, 82(8) : 1107-1112.
94. Brems JJ. Shoulder arthroplasty in the face of Acromioclavicular fracture : Puzzle pieces. *J. Arthroplasty*, Jun. 2002; 17 (Suppl. 4); 32-35.
95. Hente R, Kampshoft J, Kinner B, Fuchtmeier B, Nerlich M. Treatment of dislocated 3 part and 4 part fractures of the proximal humerus with an angle stabilizing fixation plate. *Unfallchirurg*, Sep. 2004, 107(9) : 769-82.
96. Hertel R. Fractures of the proximal humerus in osteoporotic bone. *Osteoporos. Int.* Mar. 2005, 16 (Suppl. 2) : 365-72.
97. Lungershaun W, Bach O, Lorent CO. Locking plate Osteosynthesis for fractures of the proximal humerus. *Zentralbl. Chir*, Jan. 2003; 128(1) : 28-33.
98. Leesa M. Galatz; Joseph P. Iannotti, Management of Surgical Neck Non-Union *Orthop Clin North Am.*; Vol.31; No.1, Jan. 2000; 51-76.
99. Loebenberg MI, Cuomo F. The treatment of chronic anterior and posterior dislocations of the glenohumeral joint and associated articular surface defects. *Orthop Clin North Am.*; Jan 2000;31(1):23-34.
100. Scott E. Powell, Joseph D. Zuckermann, Frances Cuomo, Debra Newmann, Maureen Gallagter. 1 Part Proximal Humeral Fractures: A Prospective study of Functional Outcome: AAOS 1992; Annual Meeting; Scientific Program; Paper No.330; Feb 24 1992.
101. Stephen K. Benirschke, Louis U. Bigliani, Christian Gerber, Clayton R. Perry, Timothy Weber Symposium Proximal Humeral Fracture - An Unsolved Fracture; Feb 8, 1992.
102. Fleiss JL: *Statistical methods for Rates and Proportions* Ed2, p217, New York, John Wiley and sons 1981.

PROFORMA

Name :
Age / Sex :
IP number :
Address :

Contact Number :
Date of Admission :
Date of Surgery :
Date of Discharge :
Occupation :
Education :
Socioeconomic Status :

HISTORY:

1. Mode of injury : Road traffic accident / Fall at home / Fall from height / Assault
2. Presenting complaints :
 - a. Pain – site / duration
 - b. Swelling – site / extent
 - c. Deformity
 - d. Disturbances in function of shoulder and hand – movements / sensations
 - e. Other associated injuries – head injury / limb injuries / spine injuries

3. Comorbid illnesses :

Diabetes mellitus	Hypertension	Coronary heart disease
Renal disorder	Seizures /Neurological disorder	Hepatic disorder
Dyslipidemia	Endocrine disorder	Tuberculosis
Bronchial Asthma	Chronic Obstructive lung diseases	Neoplastic disorders

4. Drug history : Steroids / Disease modifying anti-rheumatoid drugs / Immunosuppressants

PAST HISTORY:

- Any similar injuries
- Previous surgeries or hospitalisations
- Any major illnesses

PERSONAL HISTORY:

Diet	Vegetarian / Mixed
Marital Status	Married / Single
Bowel and Bladder habits	Regular / Altered
Habits	Smoking / Alcohol / Tobacco / Drug Addictions / Others

OBSTETRIC & GYNAECOLOGY HISTORY:

TREATMENT HISTORY:

FAMILY HISTORY:

CLINICAL EXAMINATION:

GENERAL EXAMINATION:

- | | | | |
|--------------------------------------|---|--|---|
| <input type="checkbox"/> Appearance | : | <input type="checkbox"/> Built | : |
| <input type="checkbox"/> Pallor | : | <input type="checkbox"/> Icterus | : |
| <input type="checkbox"/> Cyanosis | : | <input type="checkbox"/> Clubbing | : |
| <input type="checkbox"/> Pedal Edema | : | <input type="checkbox"/> Lymphadenopathy | : |

VITALS:

1. Pulse :
2. BP :
3. Respiratory rate :
4. Temperature :

SYSTEMIC EXAMINATION :

- Cardiovascular system :
- Respiratory system :
- Abdomen :
- Central Nervous System :

REGIONAL EXAMINATION

RIGHT / LEFT ARM

OTHER INJURIES

X – RAY FINDINGS

3D CT RIGHT/LEFT SHOULDER JOINT (if needed)

INVESTIGATIONS

Hb%		TC		DC	P L B E M
ESR		BT/CT		RBS	
UREA		S.CREATININE		ELECTROLYTES	Na ⁺ K ⁺
HBsAg		HIV		VDRL	
CXR		ECG		URINE ROUTINE	
Blood G & T				ALBUMIN	
				SUGAR	
				DEPOSITS	

FINAL DIAGNOSIS:

INITIAL TREATMENT GIVEN:

PLANNED SURGERY :

PROCEDURE NOTES

POST OP PERIOD

FOLLOW UP (After discharge)	CLINICAL FINDINGS	X-RAY FINDINGS	ADVICE
FIRST WEEK			
SECOND WEEK			
FIRST MONTH			
SECOND MONTH			
THIRD MONTH			
SIXTH MONTH			
SEVENTH MONTH			

OUTCOME:

LIST OF ABBREVIATIONS

#BB FA	-	Fracture Both Bones Fore Arm
#DR	-	Fracture Distal Radius
#MC	-	Fracture Metacarpal
#NOF	-	Fracture Neck of Femur
#SOH	-	Fracture Shaft of Humerus
'K' wire	-	Kirschner Wire
ARS	-	Attempted Reduction & Splinting
DOA	-	Date of Admission
DOI	-	Date of Injury
DOS	-	Date of Surgery
DP	-	Delto Pectoral
DS	-	Deltoid Splitting
ER	-	External Rotation
FAG	-	Fall at Ground Level
FFH	-	Fall From Height
IR	-	Internal Rotation -Spine Level
LCP	-	Locking Compression Plate

MILD	-	Mild Pain
MOI	-	Mode of Injury
PHILOS	-	Proximal Humerus Internal Locking Osteosynthesis System
POP	-	Plaster of Paris
PR	-	Pain at Rest
PUA	-	Pain with Unusual Activity
RTA	-	Road Traffic Accident
TBW	-	Tension Band Wiring

ETHICAL COMMITTEE APPROVAL FORM

**INSTITUTIONAL ETHICS COMMITTEE
MADRAS MEDICAL COLLEGE, CHENNAI-3**

EC Reg No.ECR/270/Inst./TN/2013
Telephone No. 044 25305301
Fax : 044 25363970

CERTIFICATE OF APPROVAL

To
Dr. D.Praveen Kumar,
Post Graduate, MS (Orthopaedics),
Institute of Orthopaedics & Traumatology,
Madras Medical College,
Chennai - 600 008.

Dr. D. Praveen Kumar,

The Institutional Ethics Committee has considered your request and approved your study titled **"A prospective and retrospective analysis of functional outcome of proximal humeral fractures treated with Proximal Humerus Internal Locking Osteosynthesis System (PHILOS)"** No.10072014.

The following members of Ethics Committee were present in the meeting held on 01.07.2014 conducted at Madras Medical College, Chennai-3.


- | | |
|--|----------------------|
| 1. Dr.C.Rajendran, M.D., | : Chairperson |
| 2. Dr.R.Vimala, M.D., Dean, MMC, Ch-3 | : Deputy Chairperson |
| 3. Prof.B.Kalaiselvi, M.D., Vice-Principal, MMC, Ch-3 | : Member Secretary |
| 4. Prof.R.Nandhini, M.D., Inst.of Pharmacology, MMC | : Member |
| 5. Dr.G.Muralidharan, Director Incharge, Inst.of Surgery | : Member |
| 6. Prof.McLAli, M.D., D.M., Prof & HOD of MGR, MMC | : Member |
| 7. Prof.K.Ramadevi, Director i/c, Inst.of Biochemistry, MMC | : Member |
| 8. Prof.Saraswathy, M.D., Director, Pathology, MMC, Ch-3 | : Member |
| 9. Prof.Tito, M.D., Director i/c, Inst.of Internal Medicine, MMC | : Member |
| 10.Thiru S.Rameshkumar, Administrative Officer | : Lay Person |
| 11.Thiru S.Govindassamy, B.A., B.L., | : Lawyer |
| 12.Tmt.Arnoold Saulina, M.A., MSW., | : Social Scientist |

We approve the proposal to be conducted in its presented form.

Sd/ Chairman & Other Members

The Institutional Ethics Committee expects to be informed about the progress of the study and SAE occurring in the course of the study, any changes in the protocol and patients information/informed consent and asks to be provided a copy of the final report.

Member Secretary, Ethics Committee


MEMBER SECRETARY
INSTITUTIONAL ETHICS COMMITTEE
MADRAS MEDICAL COLLEGE
CHENNAI-600 003

TURNITIN DIGITAL RECEIPT



Digital Receipt

This receipt acknowledges that Turnitin received your paper. Below you will find the receipt information regarding your submission.

The first page of your submissions is displayed below.

Submission author: D. PRAVEENKUMAR
Assignment title: TNMGRMU EXAMINATIONS
Submission title: PHILOS Plates
File name: Full_Thesis_29_09_2014_plg.docx
File size: 7.48M
Page count: 125
Word count: 13,026
Character count: 71,309
Submission date: 29-Sep-2014 04:04PM
Submission ID: 453303553

INTRODUCTION

Presented herewith is a report on the study of the effect of the concentration of the reactants on the rate of the reaction. The study was carried out by measuring the rate of reaction at different concentrations of the reactants. The results are given in the table below. It is observed that the rate of reaction increases with the increase in the concentration of the reactants. This is due to the fact that the number of collisions between the reactant molecules increases with the increase in the concentration of the reactants. Hence, the rate of reaction increases with the increase in the concentration of the reactants.

The reaction of Potassium Chlorate with Sulphuric acid is a reversible reaction. The reaction is given below. The reaction is carried out in a closed system. The results are given in the table below. It is observed that the reaction is reversible. This is due to the fact that the reaction can proceed in both directions. Hence, the reaction is reversible.

ANTI PLAGIARISM REPORT

Turnitin Document Viewer - Mozilla Firefox
http://turnitin.com/...
The Tamil Nadu Dr.M.G.R.Medical TNMGRMU EXAMINATIONS - DUE 15-A.1

Originality | Draft | PeerMark | PHILoS Plates | turnitin | 16% |

INTRODUCTION

Proximal humeral fractures account for about 4 to 5% of all fractures^{1,2,3,4,5,6}. It accounts for up to 45% of all humeral fractures⁷. It is the third most common fracture after hip fracture and colles fracture in elderly patients⁸. It is important to recognize these fractures early. Numerous authors have suggested that non operative treatment^{9,10,11} can be acceptable for two, three and four part fractures of proximal humerus in elderly patients but pain, stiffness, loss of function and muscle power have been described in more percentage of patients following this conservative approach.

Fractures of Proximal Humerus have gained more attention recently. Diagnosis has been facilitated with adaptation of 3-right angled trauma series X-rays^{2,12,13,14} supplemented with CT or MRI. With more standard use of Neer's 4-part Classification system for fracture and fracture dislocation, a protocol for management and comparison of

Match Overview

Match Number	Source	Percentage
1	AbouElsoud, Maged. "Publication"	2%
2	moajournal.com Internet source	1%
3	www.sportsbiomech.com Internet source	1%
4	Bohsali, Kamal I. and Publication	1%
5	www.medpreonline.com Internet source	1%
6	www.orthoteers.co.uk Internet source	1%
7	Submitted to Sultan Ga... Student paper	1%
8	Perez, Edward A. "Fra... Publication	<1%
9	"Philos plate fixation fo... Publication	<1%
10	www.hitmedica.com Internet source	<1%
11	Paksima, N. "Operativ... Publication	<1%

PAGE 1 OF 102 | Test-Only Report

INFORMATION SHEET
(for PATIENT CONSENT)

Title : **A Prospective & retrospective “Analysis of functional outcome of Proximal humeral fractures treated with PHILOS plates - A prospective cum retrospective study”**

Principal Investigator :

Name of the Participant :

Site :

We are conducting a study on “ Analysis of functional outcome of proximal humeral fractures treated with PHILOS plates – A prospective cum retrospective study” among patients attending the Institute of Orthopedics & Traumatology, Rajiv Gandhi Government General Hospital, Chennai and for that your specimen may be valuable to us.

The purpose of this study is to evaluate and analyze the functional outcome of proximal humeral fractures treated with PHILOS plates.

We are selecting certain cases and if you are found eligible, we may be using your radiographs of the spine to evaluate the outcome of surgery which in any way do not affect your final report or management .

The privacy of the patients in the research will be maintained throughout the study In the event of nay publication or presentation resulting from the research, no personally identifiable information will be shared.

Taking part in this study is voluntary, You are free to decide whether to participate in this study or to withdraw at any time: your decision will not result in any loss of benefits to which you are otherwise entitled.

The results of the special study may be intimated to you at the end of the study period or during the study if anything is found abnormal which may aid in the management or treatment.

Signature of Investigator

Signature of Participant

Date :

Place :

PATIENT CONSENT FORM

Study Detail : A Perspective & Retrospective Analysis of functional outcome of proximal humeral fractures treated with PHILOS plates. – A Prospective cum retrospective study

Study Centre : Rajiv Gandhi Government General Hospital, Chennai.

Patient's Name :

Patient's Age :

Identification Number :

Patient may check () these boxes

- a) I confirm that I have understood the purpose of procedure for the above study. I have the opportunity to ask question and all my question and doubts have been answered to my complete satisfaction.
- b) I understand that my participation in the study is voluntary and that I am free to withdraw at any time without giving reason, without my legal rights being affected.
- c) I understand that sponsor of the clinical study, others working on the sponsor's behalf, the ethical committee and the regulatory authorities will not need my permission to look at my health records, both in respect of current study and any further research that may be conducted in relation to it, even if I withdraw form the study I agree to this access. However, I understand that my identity will not be revealed in any information released to third parties or published, unless as required under the law. I agree not to restrict the use of any data or results that arise from this study.
- d) I agree to take part in the above study and to comply with the instructions given during the study and faithfully cooperate with the study team and to immediately inform the study staff if I suffer from any deterioration in my health or well being or any unexpected or unusual symptoms.
- e) I Understand that my identity will be kept confidential if my date are publicly presented
- f) I understand that my identity will be kept confidential if my date are publicly presented
- g) I hereby give permission to undergo detailed clinical examination, Radiographs & blood investigations as required.
- h) I have had my questions answered to my satisfaction.
- i) I hereby consent to participate in this study.

Signature / thumb impression

Signature of Investigator

Patient's Name and Address

Study Investigator's Name :
DR.D.PRAVEENKUMAR.

ஆய்வு தகவல் தாளீ

ஆய்வு தலைப்பு : " ஓய்யுமரஸ் எலும்பு முறிவுக்கு தட்டு வைத்து அறுவை சிகிச்சை செய்வதன் பயன்பாடு குறித்து ஓர் ஆய்வு "

ஆராய்ச்சியாளரின் பெயர்:

சென்னை மருத்துவக்கல்லூரி மற்றும் மருத்துவமனையில் " ஓய்யுமரஸ் எலும்பு முறிவுக்கு தட்டு வைத்து அறுவை சிகிச்சை செய்வதன் பயன்பாடு குறித்து ஓர் ஆய்வு "செய்து வருகிறோம். அதற்காக நோயாளிகளை தேர்வு செய்கிறோம்.

இந்த ஆய்வில் பங்கேற்க விரும்பும் நோயாளிகளுக்கு, இடைநிலை திருகுகளை பயன்படுத்தி தட்டு வைத்து அறுவை சிகிச்சை செய்து அதன் பயன்பாடு பற்றி கண்டறிவதே இந்த ஆராய்ச்சியின் நோக்கம் ஆகும்.

இந்த ஆராய்ச்சியில் பங்கேற்கும் நோயாளிகளின் விவரங்கள் ஆய்வு முடியும் வரை ரகசியமாக வைக்கப்படும். ஆராய்ச்சியின் முடிவு பற்றிய பதிப்புகள் மற்றும் வெளியீடுகளில் யாருடைய தனிப்பட்ட விவரங்களும் பகிர்ந்து கொள்ளப்பட மாட்டாது.

இந்த ஆராய்ச்சியில் பங்கேற்கும் உங்கள் முடிவு தன்னிச்சையானது. இந்த ஆராய்ச்சியில் இருந்து எந்த நேரத்திலும் விலகிக்கொள்ள உங்களுக்கு வாய்ப்பு உள்ளது. உங்களின் இந்த தீர்மானத்தினால் உங்களுக்கு இம்மருத்துவமனையில் வழங்கப்படும் பயன்களில் எவ்வித மாற்றமும் இருக்காது.

இந்த சிறப்பு ஆய்வின் முடிவுகள், ஆய்வின் முடிவில் அல்லது ஆய்வின்போது ஏற்படும் எதிர்மறையான விளைவுகளை நோயாளியின் நலன் கருதியோ அல்லது சிகிச்சை அளிக்கும் பொருட்டோ நோயாளிக்கு தெரிவிக்கப்படும்.

ஆராய்ச்சியாளரின் கையொப்பம்

நோயாளியின் கையொப்பம்

தேதி:

கய ஒப்புதல் படிவம்

ஆய்வு தலைப்பு : " ஓய்வூதியர் எலும்பு முறிவுக்கு தட்டு வைத்து அறுவை சிகிச்சை செய்வதன் பயன்பாடு குறித்து ஓர் ஆய்வு "

பெயர் : தேதி :
வயது : வெளி நோயாளி எண் :
பாலினம் : ஆராய்ச்சி சேர்க்கை எண் :
முகவரி :

நான் இந்த படிவத்தில் உள்ள தகவல்களை படித்தேன். (அல்லது எனக்கு படித்து காட்டப்பட்டது). நான் இந்த மருத்துவ ஆராய்ச்சி பற்றி எந்த தயக்கமும் இன்றி தகவல்களை கேட்டு பெற்றுக்கொண்டேன். நான் 18 வயதை கடந்தவர் என்றும், இந்த ஆராய்ச்சியில் முழு சுதந்திரத்துடன் பங்கேற்க சம்மதம் என்றும் தெரிவித்துக் கொள்கிறேன்.

1. நான் இந்த ஒப்புதல் படிவத்தை படித்து இதில் உள்ள தகவல்களை நன்கு புரிந்துகொண்டேன்.
2. எனக்கு இந்த ஒப்புதல் ஆவணம் பற்றி நன்றாக விளக்கப்பட்டது.
3. எனக்கு இந்த ஆய்வின் தன்மையை பற்றி விளக்கப்பட்டது.
4. என்னுடைய உரிமை மற்றும் பொறுப்புகள் ஆராய்ச்சியாளர்களால் விளக்கப்பட்டது.
5. நான் இந்த ஆராய்ச்சியில் இருந்து எந்த நேரமும் பின் வாங்கலாம் என்பதையும் அதனால் எந்த பாதிப்பும் ஏற்படாது என்பதையும் புரிந்து கொண்டேன்.
6. இந்த ஆய்வின் மூலம் பெறப்பட்ட என்னுடைய முடிவுகளை வெளியிட விளம்பரதாரர் கட்டுப்பாட்டு அதிகாரிகள், அரசு அதிகாரிகள், நன்னெறி குழு(IEC)க்களுக்கு அனுமதி அளிக்கிறேன்.
7. என் ஆய்வு விவரங்களை பொதுவாக வெளியிடும் பொழுது என்னை பற்றிய அடையாளங்கள் ரகசியமாக வைக்கப்படும் என்பதையும் புரிந்துகொண்டேன்.
8. என் சந்தேகத்திற்கு உரிய பதில்களை திருப்தியுடன் பெற்றுக்கொண்டேன்.
9. நான் இந்த ஆராய்ச்சியில் பங்கு பெற முடிவு செய்திருக்கிறேன்.

எனக்கு இந்த ஆய்வின் போது எழும் சந்தேகங்களை ஆராய்ச்சியாளரிடம் கேட்டு தெரிந்து கொள்ளவேண்டும் என்பதை அறிவேன். நான் இந்த படிவத்தில் கையொப்பம் இடுவதன் மூலம், இந்த ஆய்வை பற்றி எனக்கு நன்றாக விளக்கப்பட்டது எனவும் ஒப்புதல் அளிக்கிறேன். எனக்கு இந்த ஒப்புதல் ஆவணத்தின் நகல் வழங்கப்படும்.

..... நோயாளியின் பெயர் கையொப்பம் / கைரேகை தேதி
..... சாட்சியின் பெயர் கையொப்பம் / கைரேகை தேதி
..... ஆராய்ச்சியாளரின் பெயர் கையொப்பம் தேதி

MASTER CHART - 1

S.no	Age	Sex	IP NO	Occupation	MOI	Type	Dislocation	Side	Unilaterall bilateral	Asso. Injury	Previous treatment	Open/Closed
1	20	M	88499	Student	RTA	2 part	N	L	UL			C
2	39	F	5702	Labourer	RTA	2 part	N	R	UL	#MC (L)		C
3	49	M	63516	Plumber	FAG	4 part	N	R	UL	#MC (L)		C
4	65	F	122554	Housewife	FAG	2 part	N	R	UL		POP	C
5	53	F	110661	Labourer	FFH	3 part	N	R	UL	#DR	Massage	C
6	50	F	7498	Teacher	FAG	2 part	N	L	UL			C
7	56	F		Housewife	FAG	3part	N	R	UL		ARS	C
8	36	M	51184	Tailor	RTA	2 part	N	R	UL	#Patella		C
9	29	M	120483	Plumber	FFH	2 part	N	L	UL			C
10	44	F	54045	Labourer	RTA	3 part	y	R	UL		Splinting	C
11	30	M	106876	Driver	FAG	2part	N	R	UL			C
12	62	F	461	Housewife	FAG	3 part	N	R	UL	#NOF	Massage	C
13	46	F		Labourer	FFH	3 part	y	R	UL			C
14	48	F		Teacher	Epilepsy	2 part	N	L	UL	#BB FA		C
15	48	M	63516	Bank employee	RTA	2 part	N	R	UL			C
16	63	M	12001	Labourer	FAG	2 part	N	R	UL	#SOH		C
17	54	F		House-keeper	FAG	2 part	N	R	UL			C
18	58	F		Housewife	FAG	3 part	N	R	UL	# DR		C
19	55	M	71383	Business	RTA	3 part	N	L	UL			C
20	53	F		Housewife	FAG	2 part	N	R	UL			C

MASTER CHART - 2

Sl. No	Days Int. To Surger	Approach	Implant	Follow Up	Elevation	Abduction	ER	IR	Extension	Flexion	Pain	Skin Necrosis	Wound Graping	Nonunion	Malunion	Jt Stiffness	HET.Ossificat Ion	Deltoid	Instability	Constant Score
1	3	DP	PHILOS	8	160	150	55	T 3	50	110										88
2	4	DP	PHILOS	8	165	150	55	T 4	50	110										80
3	6	DS	PHILOS	8	125	120	55	L 1	45	95	MILD									70
4	6	DP	PHILOS	8	145	120	50	L 4	45	105					y					88
5	6	DP	PHILOS	7	95	100	45	L 4	35	80	PUA					y	y			82
6	7	DP	PHILOS	7	160	140	55	T 6	45	110										82
7	6	DP	PHILOS	8	125	125	40	L 1	40	90	PUA									72
8	7	DP	PHILOS	7	160	110	50	T 5	50	100										80
9	6	DP	PHILOS	7	165	140	55	T 4	50	100	MILD									88
10	5	DS	PHILOS	7	90	70	40	T12	50	85	MILD							y	y	68
11	7	DP	PHILOS	7	145	110	50	L 2	50	100	MILD									88
12	6	DS	PHILOS	6	120	125	40	L 1	45	90	MILD									82
13	11	DP	PHILOS	6	125	130	50	T10	45	90										82
14	12	DP	PHILOS	6	165	145	50	T 8	50	100		y								80
15	6	DP	PHILOS	6	155	145	50	T 6	50	100										88
16	11	DP	PHILOS	6	160	135	50	L 1	45	95	PUA									88
17	7	DP	PHILOS	6	160	140	50	T 9	50	100										80
18	1	DP	PHILOS	6	130	135	40	L 2	30	80	MILD									80
19	8	DS	PHILOS	6	90	80	35	L 3	30	80			y			y				80
20	7	DP	PHILOS	6	160	145	50	T 8	45	100										88