

# **A STUDY OF VASCULAR SURGICAL OUTCOMES IN HEMODIALYSIS ACCESS**

*Dissertation submitted in partial fulfillment of  
the requirements for the degree of*

**M.Ch.(Vascular Surgery) – Branch III**



**THE TAMIL NADU DR M.G.R. MEDICAL UNIVERSITY  
CHENNAI**

**AUGUST 2007**

## **CERTIFICATE**

This is to certify that, this dissertation titled "A Study of Vascular Surgical Outcomes in hemodialysis Access", submitted by **Dr Elancheralathan.K** appearing for M.Ch. Vascular Surgery degree examination in August 2007 is a bonafide record of work done by him under my guidance and supervision.

**Prof T Vidyasagan, M.S., DNB, M.Ch.(Vascular Surgery), F.I.C.S.**

Professor & Head of Department,

Department of Vascular Surgery,

Madras Medical College,

Chennai – 600003.

The Dean,

Madras Medical College,

Chennai- 600003.

## **ACKNOWLEDGEMENT**

I gratefully acknowledge and sincerely thank the Dean Madras Medical College, Chennai, for granting me permission to utilize the facilities of the institution for my study.

I am extremely grateful to my Prof. T Vidyasagaran, M.S., DNB, M.Ch., FICS, Professor and HOD Vascular Surgery, Madras Medical College, Chennai, who has been the guiding light at all stages of my study. I am thankful to him for his timely suggestions, unending patience, constant encouragement and scholarly guidance.

I am indebted to Dr S.R. Subramanian, Dr N Sritharan, Asst Professors of the department who guided me in this study.

I also thank Dr Kamalakannan, Dr Amolorpavanathan, Dr S Saravanan, Dr Thulasikumar, Dr Ilayakumar for their guidance and support.

I express my special thanks to Retd Prof SA Hussain and Dr Rajkumar, who with their initial effort to put me in the right track in the preparation of this dissertation.

Last but not the least I thank the patients without whose help and co-operation this study would not have been possible.

## **INDEX**

<b>Chapter No.</b>	<b>Title</b>	<b>Page No.</b>
<b>1.</b>	<b>INTRODUCTION</b>	<b>1</b>
<b>2.</b>	<b>AIM</b>	<b>2</b>
<b>3.</b>	<b>METHODOLOGY</b>	<b>3</b>
<b>4.</b>	<b>REVIEW OF LITERATURE</b>	<b>5</b>
<b>5.</b>	<b>ANALYSIS</b>	<b>33</b>
<b>6.</b>	<b>DISCUSSION</b>	<b>38</b>
<b>7.</b>	<b>CONCLUSION</b>	
	<b>MASTER CHART</b>	
	<b>BIBLIOGRAPHY</b>	



## **INTRODUCTION**

Vascular Access continues to be a leading cause for hospitalization and morbidity in patients with chronic kidney disease stage 5. An ideal access delivers a flow rate to the Dialyzer adequate for the dialysis prescription, has a large use – life and has a low rate of complications.

Studies over several decades consistently demonstrate that native fistula accesses have the best 4 to 5 years patency rates and require the fewest interventions compared with other access type.

The present study acknowledges the importance of increasing the number of fistulae in use, but believes that emphasis should be shifted from the fistula construction rate to the rate of usable fistula accesses. This study also detects vascular accesses at risk complication rates and to implement procedures that maximize access longevity.

## **A STUDY ON VASCULAR SURGICAL OUTCOMES IN HEMODIALYSIS ACCESS**

### **AIM**

- To study the effect of preoperative duplex mapping on vascular access in hemodialysis patient.
- To compare the outcome of A.V. Access in patients who were assessed pre-operatively by clinical method versus patients who were assessed pre-operatively both by clinical and duplex scan
- To study the early patency and early failure rates.
- To study the reasons for Early failure rates and the complications in A.V. Access.
- To evaluate the minor modifications in the operative technique to improve the outcome of AV Access.
- To study the correlation between early postoperative flow rate, vein size and patency based on duplex scan.

## **METHODOLOGY**

In this study, 142, cases of end-stage Renal Disease (ESRD) haemodialysis dependent patients, waiting for Renal Transplant were operated for permanent AV Access. Operated in the Department of Vascular Surgery. Govt . Gen. Hospital, Madras Medical College.

Among these 142 cases, 82 cases were operated for permanent for access based on clinical evaluation alone and 60 cases based on clinical and duplex scan.

Intra operative Minor surgical Modifications to improve the outcome were evaluated.

Post operatively sequential Duplex Scan studies were conducted in I, II and IV week to study flow rate and vein size. These values were compared with VII week values. Their correlation to patency of A.V. fistula were studied.

Early failures and reasons for such failures were analysed.

The effective use of Basilic vein for AV fistula creation and transposition surgeries were evaluated and the advantaged were studied.

### **Inclusion Criteria**

- ESRD patients for permanent AV Access included age group of 8 – 52 years.



- All the adult patients in the study were anticipated Renal transplant from Living Donors.

### **Exclusion Criteria**

ESRD patient requiring prosthetic graft.

### **Methods**

A structured proforma for clinical assessment, diagnosis, management and follow up of cases were framed to study the cases. The Data were compiled, analysed and inferences were drawn.

## REVIEW OF LITERATURE

### Historical Background

Vascular access remained the Rate – limiting step in clinical development of haemodialysis program until 1966. The first clinical Report of hamodialysis is credited to Kolff in 1944. Using hemodialysis he managed a patient with acute renal failure. His patient died after 12 hemodialysis. Access for the dialysis was a significant problem, since it required surgically exposing and ligating the arteries and veins during each dialysis session. By the time the patient died, virtually all access sites had been exhausted.

The Scribner shunt was developed in 1960. The original cannulas were made of polytetrafluoro ethylene (Teflon) and rarely could be used for more than 3 months because of problems with infection and thrombosis.

In 1960, first percutaneous Dialysis catheter was developed by Shaldon and associates. Designed as a single – lumen percutaneous catheter made of Teflon, an arterial and a venous catheter were placed at the time of each dialysis session and removed once the session was completed. Refinements brought the use of Softer materials and dual – lumen catheters.

The Introduction of the Brescia. Cimino fistula in 1966 allowed Long-term hemodialysis access, with a dramatic reduction in complication of Thrombosis, infection and Bleeding.

The Brascia – cimino fistula became the gold standard for haemodialysis access. Subsequent development of the 'bridge' fistula, initially

with saphenous vein and later with synthetic materials, particularly PTFE for bridge fistula in 1976 was a significant milestone in dialysis access surgery.

### **Dialysis Access**

The goal of Hemodialysis access is to provide a reliable means of effective dialysis. This implies the ability to remove and return a sufficient volume of Blood over a given period of time so as to allow efficient hemodialysis. A more durable access site such as proximal fistula may be deferred in favour of a more peripheral site, in order to maximize available sites. It is imperative that vascular surgeons be well versed in the full range of dialysis access options.

### **Patient preparation for permanent Hemodialysis access**

K DOQI July 2006 – guidelines

- 1.1 Patients with a glomerular filtration rate (GFR) less than 30 mL/min/1.73 m<sup>2</sup> (CKD Stage 4) should be educated on all modalities of kidney replacement therapy (KRT) options, including transplantation, so that timely referral can be made for the appropriate modality and placement of a permanent dialysis access, if necessary.
- 1.2 In patients with CKD stage 4 or 5, forearm and upper-arm veins suitable for placement of vascular access should not be used for venipuncture or for the placement of intravenous (IV) catheters,

subclavian catheters, or peripherally inserted central catheter lines (PICCs).

- 1.3 Patients should have a functional permanent access at the initiation of dialysis therapy.
  - 1.3.1 A fistula should be placed at least 6 months before the anticipated start of HD treatments. This timing allows for access evaluation and additional time for revision to ensure a working fistula is available at initiation of dialysis therapy.
  - 1.3.2 A graft should, in most cases, be placed at least 3 to 6 weeks before the anticipated start of HD therapy. Some newer graft materials may be cannulated immediately after placements.
- 1.4 Evaluations that should be performed before placement of a permanent HD access include<sup>1-5</sup> (Table 1):
  - 1.4.1 History and physical examination,
  - 1.4.2 Duplex ultrasound of the upper-extremity arteries and veins,<sup>6-8</sup>
  - 1.4.3 Central vein evaluation in the appropriate patient known to have a previous catheter or pacemaker.<sup>9-10</sup>

**Table 1 Patient Evaluation Prior to Access Placement**

<b>Consideration</b>	<b>Relevance</b>
Patient History	
History of previous CVC	Previous placement of a CVC is associated with central venous stenosis
Dominant arm	To minimize negative impact on quality of life, use of the nondominant arm is preferred
History of pacemaker use	There is a correlation between pacemaker user and central venous stenosis.
History of severe CHF	Assesses may alter hemodynamics and cardiac output.
History of arterial or venous peripheral catheter	Previous placement of an arterial or venous peripheral catheter may have damaged target vasculature.
History of diabetes mellitus	Diabetes mellitus is associated with damage to vasculature necessary for internal accesses.
History of anticoagulant therapy or any coagulation disorder	Abnormal coagulation may cause clotting or problems with hemostasis of accesses.
Presence of comorbid conditions, such as malignancy or coronary artery disease, that limit patient's life expectancy	Morbidity associated with placement and maintenance of certain accesses may not justify their use in some patients.

History of vascular access	Previously failed vascular accesses will limit available sites for accesses; the cause of a previous failure may influence planned access if the cause is still present.
History of heart valve disease or prosthesis	Rate of infection associated with specific access types should be considered .
History of previous arm, neck or chest surgery/ trauma	Vascular damage associated with previous surgery or trauma may limit viable access sites
Anticipated Kidney transplant from living donor	Catheter access may be sufficient
<b>Physical Examination</b>	
Physical Examination of Arterial System	
Character of peripheral pulses, supplemented by hand-held Doppler evaluation when indicated	An adequate arterial system is needed for access; the quality of the arterial system will influence the choice of access site.
Results of Allen test	Abnormal arterial flow pattern to the hand may contraindicate the creation of a radial- cephalic fistula
Bilateral upper extremity blood pressures	Pressures determine suitability of arterial access in upper extremities.

Physical examination of Venous System Evaluation for edema	Edema indicates venous outflow problems that may limit usefulness of the associate potential access site or extremity for access placement.
Assessment of arm size comparability	Differential arm size may indicate inadequate veins or venous obstruction which should influence choice of access site.
Examination for collateral veins	Collateral veins are indicative of venous obstruction.
Tourniquet venous palpation with vein mapping	Palpation and mapping allow selection of ideal veins for access.
Examination for evidence of previous central or peripheral venous catheterization	Use of CVCs is associated with central venous stenosis; previous placement of venous catheters may have damaged target vasculature necessary for access.
Examination for evidence of arm, chest, or neck surgery / trauma	Vascular damage associated with previous surgery or trauma may limit access sites.
Cardiovascular Evaluation Examination for evidence of heart failure	Access may alter cardiac output.

Preoperative venous imaging / mapping for AVF construction underwent systemic review. Duplex ultrasound is the preferred method for preoperative vascular mapping. Vascular mapping in preparation for the creation of a vascular access refers to the evaluation of vessels. Both arterial and venous of patients with CKD who have selected HD Therapy and it should be performed in all patients before placement of an access. Preoperative vascular mapping was shown to substantially increase the total proportion of patients dialysing with fistulae.<sup>6-8</sup>

Several studies support 2.0 to 2.5 mm vein diameter threshold for successful creation of fistula.<sup>11-12</sup> Radiocephalic fistula constructed in veins less than 2.00 mm in diameter had only a 16% primary patency at 3 months compared with 76% for those with veins greater than 2.0 mm.

The arterial evaluation should include pulse examination, differential blood pressure measurement, assessment of palmar arch for patency, arterial diameter assessed using duplex ultrasound, and presence of arterial calcification. A preoperative arterial diameter less than 1.6 mm has been associated with high failure rate in radiocephalic fistulae.<sup>13-14</sup>

The central veins may be assessed indirectly, by using duplex ultrasound.<sup>15</sup> Compared with invasive venography, Duplex ultrasound had a specificity of 97% and sensitivity of 81% for detecting central vein occlusions.<sup>16</sup> Alternatively, MRA or venography may be used.



### **Upper Extremity venous mapping with duplex ultrasonography**

Preoperative duplex imaging of the veins was used selectively in patients with poor visualization of the veins on clinical examination or patients with multiple prior access procedures or venipuncture. The deep venous system was imaged using a 7-5 MHz linear transducer while the patient was in supine, position. Brachial veins of the arm and the subclavian vein were studied to rule out thrombosis and stenosis. This was particularly relevant in patients who had previous access procedures or central lines.<sup>11</sup> For obese patients a lower frequency scanner (3 – 2 MHz phased array or 5-2 MHz curvilinear) was used to visualize the subclavian vein.

Imaging of the superficial venous system was primarily performed with a high frequency scanner (12-10 or 10-5 MHz) which affords better B-mode resolution and greater accuracy in the detection of intraluminal webs and synechiae. The superficial system was assessed for compressibility and diameter measurement of the vein in cross section at several levels. The cephalic vein was evaluated from the wrist to the cephalic subclavian junction. If the cephalic vein at the wrist was < 2 mm in diameter with outflow occlusion, it was not considered large enough to be used. The basilic vein was studied at the upper forearm, elbow, and arm. Upper arm veins greater than 3mm in diameter were considered adequate for placement of AVF./ Additionally, the length of the basilic vein from antecubital fossa to the junction with the deep venous system was measured to evaluate whether the basilic vein length was acceptable for transposition. Visualization of the superficial venous system was facilitated by application of a tourniquet at the

upper arm. Segments of poorly compressible segments of vein or veins with intraluminal webs in the antecubital fossa were not considered for creation of AVF. Preoperative skin marking was performed in obese patients, particularly for brachial – basilic or brachial – cephalic fistulae and for those with previous AVGs.

### **New Nomenclature for Arteriovenous Hemodialysis Access<sup>17</sup>**

<b>Recommended Nomenclature</b>	<b>Traditional Nomenclature</b>
<b>Autogenous</b>	
Autogenous posterior radial branch cephalic direct access	Snuff box fistula
Autogenous radial – cephalic direct wrist access	Brescia-Cimino arteriovenous fistula
Autogenous ulnar basilic forearm transposition	Superficial venous transposition in the forearm, basilic vein to ulnar artery
Autogenous radial cephalic forearm transposition	Superficial venous transposition in the forearm, cephalic vein to radial artery
Autogenous brachial cephalic forearm looped transposition	Superficial venous transposition in the forearm, cephalic vein to brachial artery, looped
Autogenous radial brachial indirect saphenous vein translocation	Greater saphenous vein reversed and translocated radial artery to brachial vein.
<b>Prosthetic</b>	
Prosthetic brachial antecubital forearm loop access	e-PTFE forearm loop graft
Prosthetic radial median cubital forearm straight access	e-PTFE forearm straight graft

Conduits	-	Autogenous Prosthetic Nonautogenous biograft– Bovine heterograft, human umbilical vein.
Location	-	The specific vascular anatomic sites of origination and termination of the access should be included in this component.

### **Order of Placement**

There are no randomized controlled trials comparing the recommended Anatomic order of distal to proximal access construction. However, good surgical practice makes it obvious that when planning permanent access placement, one should always consider the most distal site possible to permit the maximum number of future possibilities for access.<sup>2</sup>

Beginning with the 'snuff box' fistula at the base of the thumb, followed by the standard Brescia – cimino wrist fistula, followed by a forearm cephalic fistula at Dorsal Branch and finally a mid forearm cephalic fistula.

If forearm fistula is not feasible, an antecubital fistula, cephalic fistula at elbow, and finally a transposed basilic fistula should be considered.<sup>18</sup>

In cases in which fistula is not constructed initially, a graft can be used as a planned bridge to a fistula.

The preference of fistulae over all other forms of access arises from their functional advantages because of a lower rate of complications.

- Fistulae have the lowest rate of thrombosis<sup>19</sup> and require the fewest interventions<sup>19,20</sup> providing longer survival of the access. The number of access events is 3- to 7- fold greater in prosthetic bridge grafts than in native fistulae.<sup>19,20</sup>
- As a result, costs of implantation and access maintenance are the lowest.
- Fistulae have lower rates of infection than grafts, which, in turn, are less prone to infection than percutaneous catheters and subcutaneous port catheter systems<sup>21</sup>. Vascular access infections in HD patients are common, can be severe, and contribute to infection as the second leading cause of death in patients with CKD stage5.
- Fistulae are associated with increased survival and lower hospitalization. (KDOQI - 06)
  - Patients receiving catheters (RR=2,3) and grafts(RR=1,47) have a greater mortality risk than patients dialyzed with fistulae.
  - Epidemiological evidence also indicates that greater use of fistulae reduces mortality and morbidity.

Wrist (radiocephalic)<sup>61</sup> and elbow (brachiocephalic) primary fistulae are the preferred types of access because of the following characteristics: (KDOQI - 06).

- Superior patency to other accesses after they are established and matured.

- Lower complication rates compared with other access options, including lower incidence of conduit stenosis, infection, and vascular steal phenomenon.
- In most cases, flow increases early (first week), with little additional increase as the fistula matures. Failure of fistula flow to increase is a sign of access dysfunction.

The Work Group concluded that the 3 advantages of wrist and elbow primary fistulae, as listed, outweigh the following 4 potential disadvantages :

- The vein may fail to enlarge and/or increase blood flow to satisfactory levels (ie, fail to mature).
- Comparatively long maturation times(1 to 4 months) must elapse after creation of these fistulae before they can be used. Thus, the access must be created several months in advance of the anticipated need for dialysis or an alternative temporary method of vascular access must be used while the fistula matures.
- In some individuals, the vein may be more difficult to cannulate than an AVG. However, this can be addressed by mobilizing the vein superficially.
- The enlarged vein may be visible in the forearm and be perceived as cosmetically unattractive by some individuals.

The wrist fistula is the first choice of access type because of the following advantages:

- It is relatively simple to create.

- It preserves more proximal vessels for future access placement.
- It has few complications. Specifically, the incidence of vascular steal is low, and its mature fistulae, thrombosis and infection rates are low.

The only major disadvantage of the wrist (radiocephalic) fistula is a lower blood flow rate (BFR) compared with other fistula types. If adequate flow to support the HD prescription is not achieved with a radiocephalic fistula within 4 months after appropriate evaluation for correctable or modifiable factor, another type of access should be established. The major drawback of a radiocephalic fistula is the relatively high primary failure rate (15%) and only moderate secondary patency rate at 1 year (62%).

The elbow (brachiocephalic) primary fistula is the second choice for initial placement of an access. Its advantages include the following.

It has a higher blood flow compared with the wrist fistula.

- The cephalic vein in the upper arm usually is comparatively easier to cannulate and is easily covered, providing a potential cosmetic benefit.

The disadvantages of the elbow (brachiocephalic) primary fistula include the following.

- It is slightly more difficult to create surgically than a radiocephalic fistula.
- It may result in more arm swelling than a radiocephalic fistula.

- It is associated with an increased incidence of steal compared with a radiocephalic fistula.
- It is associated with a greater incidence of cephalic arch stenosis than a forearm radiocephalic fistula.

If a wrist radiocephalic or elbow brachiocephalic fistula cannot be created, the patient should be considered for a transposed basilic vein fistula. In some cases, a forearm graft can be a viable alternative to mature the venous system for an elbow fistula as a secondary access. Transposed brachiobasilic fistulae have several disadvantages compared with other fistulae.

- The transposition procedure may create significant arm swelling and patient pain.
- They have a greater incidence of steal and arm swelling than other fistula types.
- They are more technically challenging, especially in obese individuals.

A graft can be used as a "planned bridge" to a fistula and failing forearm graft can be converted to upper-arm fistulae. Similarly, fistulae at a lower level can be converted to more proximal fistulae.

**AVGs have the following advantages: (KDOQI -06)**

- A large surface area and vessel available for cannulate initially.
- They are technically easy to cannulate.

- The lag-time from insertion to maturation is short. For PTFE-derived grafts, it is recommended that not less than 14 days should elapse before cannulation to allow healing and incorporation of the graft into local tissues although ideally, 3 to 6 weeks are recommended.
- Multiple insertion sites are available.
- A variety of shapes and configurations is available to facilitate placement.
- It is easy for the surgeon to handle, implant, and construct the vascular anastomosis.
- The graft is comparatively easy to repair either surgically or endovascularly.

### **Venous Transposition in the creation of Arteriovenous Access**

In order to maximize autogenous hemodialysis access options, many institutions incorporate venous transposition procedures such as Radial Basilic and Brachial-Basilic upper arm transposition when traditional fistula options are not possible. A transposition is an access performed with transposed vein. The peripheral portion of the vein is moved from its original position. Usually through a superficial subcutaneous tunnel and connected to the artery.

The more central venous segment is a transposed access is left in its anatomic position.



### Basilic Vein – a good conduit:

The Basilic vein in the upper arm is often a good conduit for dialysis access because of its relatively large size and locations in the deeper tissue planes.

The Traumatic consequences of repeated venipunctures observed in more superficial veins are not seen in Basilic veins because of its deeper position. As with all venous transposition, only one anastomosis is required and anatomic continuity with axillary veins is maintained.

Maturation of Basilic veins can be accomplished by selective obliteration of all the venous side branches, during the mobilization of the vein.

Long term potency with translocated brachial basilica fistulae that have matured has been good, with reported primary patency rate as high as 90% at 1 year and 80% at 2 years.<sup>22</sup>

### **Superficial Venous Transposition of the Forearm**

Transposition performed	% of Total
Type A	
Artery and vein in immediate proximity	15
Single incision	
Superficial subcutaneous transposition only	

Type B	
Dorsally located vein transposed to volar surface artery Separate incisions superficial subcutaneous transposition	33
Type C	
Volar vein transposed to mid forearm volar surface Separate incisions superficial subcutaneous transposition	52

## COMPLICATIONS OF NATIVE ARTERIOVENOUS FISTULAS

Complications of autologous AV fistulas (see also Chapter 31) include the following;<sup>23</sup>

1. Thrombosis
2. Infections
3. aneurysms
4. Hand edema
5. Hand ischemia

### Fistula Thrombosis

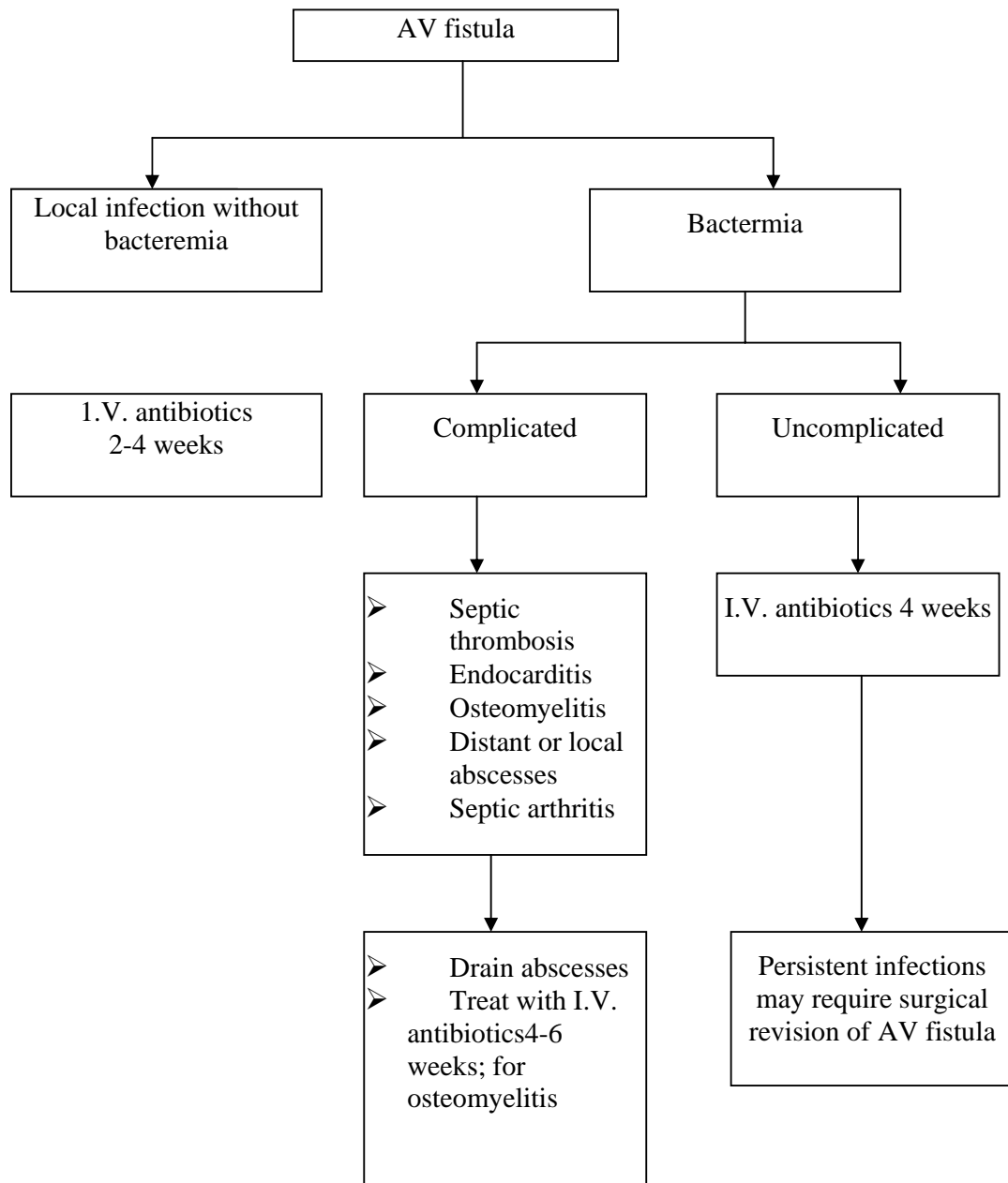
This is the most common AV fistula complication. Early thrombosis within 4 weeks after surgical construction is usually due to error in technique or judgement. Common problems are inadequate anastomosis, kinking of the vein just proximal to the anastomosis, or undetected occlusion of the venous

outflow. An inadequate arterial inflow due to proximal arterial disease can also produce early failure. Simple thrombectomy of the fistula, without correcting the primary problem that produced the failure, inevitably will result in rethrombosis. Late occlusion is most commonly due to progressive stenosis at the fibrosis of the vein in an area that has been abused by repeated traumatic needle punctures. Correction of this problem usually can be accomplished by doing a new AV fistula just proximal to the area of stenosis. This can be done as long as the proximal vein remains patent.

### **Infection<sup>24</sup>**

Primary infection of the wound is extremely rare. If it occurs, it has to be treated aggressively because it poses the potential danger of anastomotic breakdown and massive bleeding. Superficial erythema and cellulites can be treated with intravenous antibiotics. The presence of frank pus involving the anastomosis requires open drainage and ligation of the fistula (proximal and distal arterial ligation). Late infections are usually due to a break in aseptic technique during cannulation of the fistula. Because there is no foreign body, these infections usually respond well to drainage and antibiotic therapy.

**General guidelines for the management of infections of arteriovenous grafts.**



## **Hand Ischemia<sup>23</sup>**

Symptoms and signs of arterial insufficiency in the distal extremity after AV fistula are rare (about 1%). It is more common after upper arm AV fistula creation. Its clinical presentation, pathophysiology, and treatment are discussed extensively in the following section on bridge AV fistulas.

The pathophysiology of these ischemic complications has been discussed in detail by Barnes<sup>25</sup>. The lower pressure system present at the outflow side of the AV connection induces reversal of flow in the portion of the artery distal to the fistula. This alteration in the direction of flow has been labeled steal, and when it is of sufficient magnitude and cannot be compensated by collateral flow, it will result in ischemic manifestations. This is particularly likely to occur in diabetic patients, who may have diffuse arterial occlusive disease. Hemodynamic studies performed by us, directly measuring the direction of blood flow in the different components of the fistula, demonstrated that physiologic steal occurs in 73% of autologous fistulas and in 91% of prosthetic bridge AV fistulas.

If the ischemic manifestations are severe and threaten the viability of the limb, surgical treatment is required. Several techniques have been used for this purpose. The simplest and most direct means of treating the ischemic steal is ligation of the outflow of the fistula. This will instantaneously reverse the steal and improve distal perfusion. The obvious drawback of this technique is that the angioaccess is lost. Another widely used technique is banding, which consists of producing a stenosis in the outflow portion of the

AV fistula / bridge AV fistula, close to the arterial anastomosis. Many variations of banding, all intended to produce a narrowing and consequent flow reduction, have been reported. A recently described technique, presented as a solution for early steal after brachial artery to axillary vein bridge AV fistula, is the use of a branch of the axillary artery for inflow and the brachial vein for outflow. The explanation proposed for the success of this technique was that the reduced amount of flow delivered by the axillary branch prevented ischemic steal.

Some studies show that the axillary artery itself as inflow source with comparable results. The explanation for the success of this technique is that the axillary artery is very rich in collateral circulation and this overcomes the steal. A technique that consists of ligation of the artery just distal to the takeoff of the AV fistula or bridge AV fistula and an arterial bypass from the artery proximal to the takeoff of the arterial venous connection to the artery distal to the ligation. The purpose of the ligation of the artery distal to the AV fistula / bridge AV fistula is to eliminate reversal of flow. The addition of the arterial bypass provides the distal vascular bed with normal perfusion pressure and flow. This technique has given excellent results, with immediate reversal of the ischemic conditions while maintaining function of the access.

### **Evaluation of Early Arteriovenous failures**

Fistula failure has been classified as early and late. Early failure refers to those cases in which the arteriovenous fistula never develops to the point that it can be used or fails within the first 3 months of usage. It has been

common practice to abandon these early failures: however, aggressive evaluation and treatment of early fistula failures has been shown to result in salvage of a large percentage. The Reasons for failure in order of frequency are<sup>26</sup>

- (a) Technical problems at the anastomosis and positioning of the artery and vein relative to another including rotation and angulation
- b) a sclerotic vein segment in the proximal forearm
- c) Calcification of the arterial wall causing difficulty at the anastomosis, such as elevation of intimal flap, lack of distensibility or poor flow because of proximal occlusive disease.
- d) Hypotension usually associated with low blood volume from recent dialysis resulting in a poor flow through the anastomosis.

### **Surgical Management**

Technical factors are often responsible for thrombosis of the newly placed fistula. One must be careful not to narrow the lumen of the artery or vein during suturing and to avoid dissection of the radial artery. Twisting or kinking of the cephalic vein in an end of vein to side of artery anastomosis must be avoided by sufficient vein dissection and marking the vein to prevent it from rotating. Turbulent flow is a feature of AVFs, but rapid flow across the fistulas is usually adequate to prevent early thrombosis. A competent venous

valve in the caudal venous limb of a side to side AVF produces a cul-de-sac in which there is turbulence but no flow.

A side to side anastomosis may predispose to thrombosis in the proximal venous limb, resulting in a dilated plexus on the back of hand. Declotting by Fogarty thrombectomy is performed by introducing the catheter through transverse venotomy near the anastomosis or through the distal limb of a side to side fistula. Vasospasm in patients undergoing construction of AVFs is relatively common and often impairs the arterial blood supply to the cephalic vein. Prophylaxis with intravenous nicardipine may be effective in preventing vasospasm.

Otherwise gentle dilatation of the radial artery or cephalic vein proximal to the site of the anastomosis with a Fogarty catheter or coronary probes overcomes spasm and assures a wide anastomosis. Vein strictures and fibrous bands may cause narrowing and should be released. If there is any doubt about patency, the anastomosis must be taken down to look for errors; if an adequate reanastomosis is not possible, a more proximal new anastomosis can be performed. The success of surgical intervention of thrombosed radiocephalic AVFs by means of thrombectomy and revision of anastomoses varies from 14% to 90%.



## Early failure of radiocephalic AVFS: RESULTS OF SURGICAL TREATMENT

Author Ref. No.)	No. AVFs	Early Failure (%)	Successful Revision (%)
Reilly et al. (4)	145	11	33
Erasmi et al. (5)	299	14	24
Tordoir et al. (6)	129	14	55
Louridas et al. (7)	137	13	-
Wedgwood et al. (8)	71	10	14
Palder et al. (9)	99	24	66
Kherlakian et al. (10)	100	12	58
Braun and Polith (11)	277	20	57
Burger et al. (12)	208	6	27
Konner (13)	202	4	90

### Normal Hemodynamics

Accessflow and pressure are related in a permanent AV access through the relationship:

$$QA = \Delta P/R$$

The driving force for access flow, QA, is the pressure gradient,  $\Delta P$ , between the artery and Central Vein. This driving force tends to be the same for both fistulae and grafts. Within the constraints imposed by the arterial

anastomotic site, the ultimate access flow in mature accesses tends to be similar in fistula and grafts. What differs is the rate of maturation.

**Table 7 Flow Methods in dialysis Access (KDOQI -06)**

Duplex Doppler Ultrasound (quantitative color velocity imaging:[DDU]

Magnetic Resonance Angiography : [MRA]

Variable Flow Doppler Ultrasound (Specs USA): [VFDU]

Ultrasound dilution (Transonics): [UDT]

Crit-Line III (optodilution by ultrafiltration; HemaMetrics): [QABF] CritiLine

III direct transcutaneous (HemaMetrics): [TQA] Glucose pump infusion

technique [GPT]

Urea dilution [Urea D]

Differential Conductivity (GAMBRO)[GPT]

Urea dilution [UreaD]

Differential conductivity (GAMBRO): [HDM]

In Line dialysance (Fresenius): [DD]:

Duplex Doppler ultrasound requires an accurate measurement of the cross sectional diameter of the access. The method is operator dependent and subject to error caused by variation in cross sectional area and the angle of insonation.<sup>28</sup> Because turbulence in the access can limit the accuracy of the measurements, flow measurements, can be made in feeding artery (usually the Brachial) or distal part of the access. The difference between the flow in the artery and the access usually is less than 10%. Despite these operator related and equipment related limitations, sequential measurements have been used

extensively to detect and refer patients for Interventions or predict the risk for Thrombosis. In addition to flow measurements, both DDU and MRA provide anatomic assessment and direct evidence for the presence, location and severity of access stenosis.

Comparison of Diagnostic Tests for Access Surveillance and Monitoring in the HD Population:

### Duplex Doppler Ultrasound As Reference

Autho, year	N	Type of Access		Applicability	Test 1	Threshold Value for Stenosis	Results	Quality
		AVF	AVG					
May 1997	170 (220 Accessess)	22%	78%	† † †	UDT <sup>b</sup>	ND	r=0.79 p=0.0001	●
Malik 2002	193 (258 Accessess)	72%	28%	† †	Physical exam	ND	Sensitivity =36% Specificity = 93%	○

AVF=arterio- venous fistual; (AVG = arterios- venous graft; ND=no dta; 1 = correlation coefficient, UDT=ultrasound dilution technique

- a. This test is compared to the "reference standard", duplex US.
- b. Access stenosis defined by dubbing of systollic velocity in vessel narrowed more than 50%

**Summary of observational studies that evaluated the impact of a single measurement of vascular access blood flow on vascular access thrombosis**

<b>Study (Ref.No)</b>	<b>Access No.</b>	<b>Grafts (%)</b>	<b>Method</b>	<b>Follow-Up (mo)</b>	<b>Qacc (mL/min)</b>	<b>N</b>	<b>Thrombosis (%)</b>	<b>Relative Risk</b>
Sands et al. (34)	177	100	Doppler US	6	≤ 801 ≤ 1300 ≥ 1,603	14 69 38	93 42 26	
Strauch et al. (3)	57	100	Doppler US	6	< 400 ≥ 400 < 500 ≥ 500	11 46 18 39	64 13 50 11	
Bay et al (4)	2,792	69	Doppler US	≥ 6	≤ 300 300-500 500-700 7000-1000 >1000			2.0 <sup>a</sup> 1.48 1.2 1.0 1.8
Shackleton et al (2)	18	100	Doppler US	2	≤ 450 > 450	8 10	63 10	
Wrangal (5)	39	100	Doppler US	1	< 300 300–500 500-800 > 800		77 8 4 0	

In primary fistulas inadequate flow through the access is the main functional defect predictive of Thrombosis and access failure. Measurement

of recirculation becomes a more useful screening tool in fistulas, unlike grafts, can decrease to a level less than the prescribed blood pump flow (i.e < 300 to 500 ml/minute while still maintaining access patency. Thus DDU may be useful in fistula surveillance.

## ANALYSIS

Pre- operative duplex mapping on vascular access:

Prospective vascular access mapping was done for 60 patients from 2005-2007 in Govt. general hospital, Madras Medical College. Imaging of arterial, superficial venous system was primarily performed with a high frequency scanner (12-10 or 10-5 MHZ). Based on clinical as well as duplex mapping the procedures done were 60 cases.

Left Radio Cephalic fistula in	-	34 Patients
Right Radio Cephalic fistula in	-	8 Patients
Left Brachiocephalic fistula in	-	11 Patients
Right Brachiocephalic fistula in	-	5 Patients
Left Basilic vein transposition with AV access	-	2 Patients

Thirteen patients, where hemodialysis accesses were done on right upper limb, the history of right central venous catheter was present in 4 patients. These 4 patients were subjected to Duplex scanning of right central vein status. Deep venous systems were imaged using 7-5 MHZ linear transducer.

Two patients had Right IJV Thrombosis with partial recannulation.

The pre- operative diameter measurement of i) All arteries varies from 1.5 mm to 6mm ii) All veins both in forearm and upperarm varies from 1.6 mm to 4.3 mm.

**Outcome of A.V. access in patients assessed pre- operatively by clinical methods alone Vs clinical and duplex scan**

82 cases were operated based on clinical assessment alone. Clinical methods included proper clinical history and examination. Examination of these patients included character of peripheral pulses, Allen test, Evaluation for edema. Examination for collateral veins, Tourniquet venous palpation with vein mapping, evidence for central or peripheral venous catheterization and evidence of heart failure.

Out of these 82 cases.

Left Radio Cephalic fistula in	-	54 Patients
Right Radio Cephalic fistula in	-	16 Patients
Left Brachiocephalic fistula in	-	9 Patients
Right Brachiocephalic fistula in	-	1 Patients
Left Radio basilic AVF	-	1 Patients
Right brachio basilic AVF	-	1 Patients

Primary procedure failure in 14 cases

Failure rates in Clinical Vs Duplex scan based A.V. access

Primary procedure failure in A.V. access based only on clinical methods 14 cases out of 82 cases- 17%

Primary procedure failure in A.V access based only on clinical as well as Duplex- 6 cases out of 60 cases- 10%

Out of 14 cases failed in clinical method based A.V. access.

8 patients were in pediatric age group 8-12 years

4 patients were Adult females

2 patients were Adult males

### **Analyzing the early patency & early failure rates**

Outcomes of total 142 cases operated for A.V. access

A.V. access failed in primary procedure - 20 cases

All these A.V. access failed within first 3 months - (i.e.,) these cases never developed to the point that it can be used or failed.

No. of cases failed immediately after surgery - 17 cases/ 20

No. of cases failed to mature - 3 cases/ 20

Analysing the 17 cases failed immediately after surgery, the causes were,

- i) Technical problems at the anastomosis - 4 cases
- ii) Technical problems at Rotation and angulation of vein - 3 cases
- iii) Elevation of intimal flap - 2 cases
- iv) Hypotension - 4 cases
- v) Early spasm - 4 cases

Apart from these 20 cases (17+3cases),



In 9 cases primary assisted patency procedures were done. The accessory tributaries were ligated as a separate procedure which resulted in successful functioning A.V. access.

### **Analyzing the minor modifications in the operative techniques to improve the outcome of A.V. access**

End to side Anastomosis was done in all 142 cases. Minor modification was done in these anastomosis. Out of 10 vascular surgeons, 2 vascular surgeons followed perpendicular end to side Anastomosis. The suture line was begun in the middle of the posterior aspect and simply run around either edge to the corner before completion of the anterior aspect of Anastomosis in the usual fashion. 23 cases out of 142 cases were done in this fashion. 1 case failed due to infection and pseudoaneurysm.

4 cases of A.V. access with basilic vein transposition were done. All 4 cases were functioning. Basilic vein transposition with A.V. access was done as a secondary procedure and the best alternative to synthetic graft.

### **Out comes Early postoperative flow rate, vein size and patency based on Duplex scan**

In 56 cases of A.V. fistulas, postoperative Duplex scan was done at the end of I, II & IV week. Maximum venous diameter and blood flow rate were present in IV week. The blood flow rate at the end of IV week was compared with the flow rate at the end of VII week. The blood flow rates were obtained in the straight nontapering venous segment.

- i) At the end of 4 weeks the vein diameter were found to be 3.2mm-6.2 mm size
- ii) The flow rate varies from 210 ml/mt to 420 ml/mt
- iii) Number of cases that fails to mature was 2 cases. In these 2 cases the vein diameters were 2.8 mm and 3 mm. Flow rates in these 2 cases were 160 and 180 ml/mt.
- iv) Maximum flow rate were achieved in Brachiocephalic and brachio basilic fistula, with venous diameter of 4.8-6.2 mm and flow rate of 280- 420 ml/mt.

### **Complications in A.V. access procedure**

#### **Causes**

Thrombosis of A.V. access which was analyzed as the leading cause of A.V. fistula early failures.

Infections and pseudoaneurysm and ligation occurred in 3 cases.

No. of pediatric patients - 2

No of female patients - 1

In a same pediatric patients where all 3 types of fistula were performed (Left Radiocephalic & B/L Brachiocephalic fistula). Ligation of all A.V. access were done in an interval of 6 months due to infection, pseudoaneurysm and rupture. Culture results showed staphylococcus aureus in 3 cases with super added infection of pseudomonas in 1 case. Hand edema and hand Ischemia were not seen in our study.

## DISCUSSION

### Pre- operative duplex imaging

According to the recent KDOQI- 2006 recommendation the evaluation that should be performed before placement of a permanent HD access include

- History and physical Examination
- Duplex ultrasound of the upper- extremity arteries and veins
- Central vein evaluation in the appropriate patient known to have a previous catheter or pacemaker

In total number of 142 A.V access surgeries studied, 82 were evaluated on history and clinical methods. In the Remaining 60 cases evaluations were done based on clinical as well as pre- operative duplex scan.

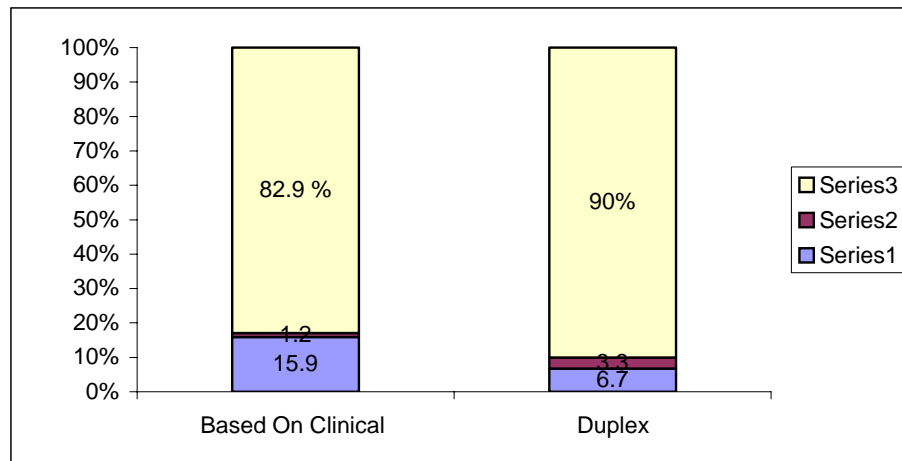
In the 82 cases done based on clinical evaluation,

The primary procedure failure were	- 13 cases	-15.9%
Fistula placed but not adequate were	- 1 case	- 1.2%
Fistula placed and adequate function	- 68 cases	- 82.9%

In the 60 cases done based on clinical and duplex evaluation

The primary procedure failure were	- 4 cases	- 6.7%
Fistula placed, but not adequate were	- 2 cases	- 3.3%
Fistula placed and adequate were	- 55 cases	- 90%

Statistical Analysis of the patients admitted to clinical Vs Duplex methods. The failure rates in the clinical method (17% failure 14/82) was compared with the Duplex method (10% - 6/60). The Duplex method seemed to have less failure with statistical significance of  $P>0.001$



### Early failures

All A.V access failed within first 3 months (ie) these cases never developed to the point that it can be used or failed. Primary failure rate were high in pediatric and female patients.

- Out comes of total 142 cases operated for A.V. access
- A.V. access failed in primary procedure- 20 cases
- (14clinical + 6 duplex cases).
- Total No of pediatric cases operated in 142 cases - 21
- In these 21 cases, 11 were operated based on clinical method and 10 cases were operated based on Clinical and duplex
- Total number of pediatric cases failed out of 21 cases - 11 cases.

- Failure in clinical group - 8 cases
- Failure in clinical and duplex - 3 cases

Out of 142 cases operated. 32 cases were female. In these 32 cases, 19 cases were operated based on clinical and 13 cases were operated based on clinical and duplex.

- No of cases failed out of 32 cases - 6 cases
- Failure in clinical group - 4 cases
- Failure in clinical and duplex - 2 cases

Statistical Analysis of Pediatric and Adult population was compared for the failures. The pediatric population had failures and were statistically significant (11/21 Vs 9/121 =  $P < 0.05$ )

Risk groups identified in our study, which requires definite pre-operative duplex mapping are.

- Pediatric patients
- Female patients
- Patients with H/O central venous catheterization
- Primary procedure failure and requiring secondary procedure

### **Early failure rates**

- Total number of cases failed immediately after surgery - 17 cases
- (i) Technical problem at the anastomosis - 4 cases -23.5%
- (ii) Technical problems at rotation and Angulation of vein - 3 cases- 17.7%

- |       |  |   |                 |
|-------|--|---|-----------------|
| (iii) | Elevation of Intimal flap and sclerotic vein | - | 2 cases - 11.8% |
| (iv)  | Hypotension                                  | - | 4 cases - 23.5% |
| (v)   | Early spasm                                  | - | 4 cases - 23.5% |

Reasons for failure were analyzed in peri- operative period, immediate post- operative and in secondary procedures.

Technical problems at the anastomosis, were due to narrowing the lumen of the artery and vein during suturing.

A posterior wall included in suturing was also a reason for thrombosis and early failure rate.

Twisting and kinking of the cephalic vein in an end of vein to side of an arterial anastomosis which leads to malrotation and Angulation of vein was found in 3 cases.

It must be avoided by sufficient vein dissection and marking the vein to prevent it from rotation.

Vein strictures and fibrous bands may cause narrowing and should be released. This type of technical problems was mostly avoided by a minor modification in surgical procedure.

The end to side anastomosis done in perpendicular fashion. Where the heel of the vein anastomosis lies at the side wall of the artery and this avoids the vein angulation and kinking.

23 cases out of 142 cases were done in this fashion and 1 case failed due to infection and pseudoaneurysm.

In our study the complication that occurred in A.V. access procedure were infections and pseudoaneurysm.

Infection and pseudoaneurysm in 3 cases and treated by ligation and culture sensitive antibiotics

In this study there was no cases of hand edema and hand ischemia due to steal.

The number of early failure rates due to elevation of intimal flap and sclerotic vein were 2 (11.8%). This less number was due to proper pre-operative and per operative assessment.

The early failure rate due to hypotension can be avoided by stopping anti-hypertensive drug from the morning of day of surgery for 24 hours, if feasible.

Vasospasm in pediatric and female patients were common and this was the reason for failure in 4 cases (23.5%). Studies showing prophylaxis with intravenous nicardipine or gentle dilatation of radial artery or cephalic vein proximal to site of the anastomosis with a Fogarty catheter or coronary probes overcomes spasm and assures a wide anastomosis. In our study we used perivenous infiltration with lignocaine or papaverine which relieved spasm.

### A.V access with Basilic vein transposition

4 cases of A.V. access with basilic vein transposition were done

Brachio basilic A.V. access with transposition of Basilic vein at arm	1
Brachio basilic A.V. access with transposition of Basilic vein at forearm	1
Radio basilic A.V access with transposition of Basilic vein at forearm	2

All four cases were functioning. The peripheral portion of vein is moved from its original position, usually through a superficial subcutaneous tunnel and connected to the artery.

The basilic vein is a good conduit

- Relatively large size
- Repeated vein punctures observed in more superficial veins are not seen in basilic veins.
- During mobilization of the vein, selective obliteration of all venous side branches so maturation is better.

### **Disadvantage**

- Extensive dissection and prolonged surgery
- Odema and infection rates are more.

Primary patency rate are as high as 90% at 1 year and 80% at 2 years.



### **Early post operative flow rate**

The blood flow rates were assessed in 56 A.V. access patients using duplex scan in I,II, IV week and VII week. Maximum flow rates were achieved at the end of IV week.

- The flow rate varies from minimum of 160 ml/mt to maximum of 420 ml/mt.
- In total number of 60 cases which were pre operatively assessed by duplex 4 cases failed immediately in post- operative period
- In the remaining 56 cases, 54 cases the blood flow rate were between 210 to 420 ml/ mt.
- 2 cases failed to mature and the flow rate were 160 and 180 ml/mt.

In 54 cases matured with functioning A.V. fistulae maximum flow rate between 330 ml/ mt to 420 ml/ mt achieved in 16 cases.

These blood flow rates were present in brachiocephalic and basilic vein transposition A.V access.

In 38 cases, (Radio cephalic fistula ) the flow rate were between 210 ml/ mt to 330 ml/mt .

Measurement of circulation becomes a more useful screening tool in fistulas, unlike grafts, can decrease to a level less than the prescribed blood flow rate (ie <300 to 500 ml/ mt) while still maintaining access patency.

Pre- operatively the vein diameter were measured in all 60 cases, and found to be in a range of 1.6 mm to 4.3 mm. Post - operatively the vein diameter were measured in 56 cases found to be in a range of 2.8 mm - 6.2 mm size

The vein diameter the arm level in case of brachiocephalic and Brachio basilic fistula were 4.8 - 6.2 mm

### T-Test

**Paired Samples Statistics**

		Mean	N	Std. Deviation	Std. Error Mean
Pair 1	VAR00003	3.5667	60	.9490	.1225
	VAR00009	3.4200	60	1.0196	.1316
Pair 2	VAR00004	3.8550	60	1.0137	.1309
	VAR00011	3.1783	60	.8222	.1061
Pair 3	VAR00006	232.1667	60	45.8861	5.9239
	VAR00008	276.7333	60	52.1250	6.7293

**Paired Samples Correlations**

		N	Correlation	Sig.
Pair 1	VAR00003 & VAR00009	60	.556	.000
Pair 2	VAR00004 & VAR00011	60	.651	.000
Pair 3	VAR00006 & VAR00008	60	.953	.000

The var009 is the initial values of the vein and the post operative vein size (var003) are compared. A paired t test is performed to see any significant change in the vein size. From the table above it is evident that the vein size has improved giving significant results (p 0.227). However the size improves dramatically during follow up period on flow rates giving statistical significance (P < 0.00).

**T-Test****Paired Samples Statistics**

		Mean	N	Std. Deviation	Std. Error Mean
Pair 1	VAR00008	282.5217	46	55.4712	8.1788
	VAR00011	3.1957	46	.8435	.1244
Pair 2	VAR00003	3.6522	46	.9991	.1473
	VAR00004	3.9457	46	1.0695	.1577

**Paired Samples Test**

	Paired Differences					t	df	Sig. (2-tailed)
	Mean	Std. Deviation	Std. Error Mean	95% Confidence Interval of the Difference				
				Lower	Upper			
Pair 1 VAR00008 - VAR00011	289.3261	54.8965	8.0941	263.0238	295.6283	34.510	45	.000
Pair 2 VAR00003 - VAR00004	-.2935	.1960	.889E-02	-.3517	-.2353	-10.157	45	.000

**Error!**

**Paired Samples Test**

		Paired Differences				t	df	Sig. (2-tailed)	
		Mean	Std. Deviation	Std. Error Mean	95% Confidence Interval of the Difference				
					Lower Bound				Upper Bound
Pair 1	VAR00003 -	.146	.930	.120	-.036	.386	1.22	.22	
Pair 2	VAR00004 -	.676	.786	.101	.473	.879	6.66	.00	
Pair 3	VAR00006 -	-	16.23	2.095	-	-	-	.00	

The flow rate and vein diameter measurement by duplex scan is operator dependent and subject to error caused by variation in cross sectional area and angle of insonation

## CONCLUSION

- 1) Analyzing the effect of preoperative duplex mapping for Arterial and Venous System
  - The preference of Arterial and Venous Segment is determined.
  - The failure rates in A.V. Access surgery is decreased.
- 2) Comparing the outcomes of A.V. Access surgery done based on clinical versus clinical and duplex method, the failure rates in clinical method – 17% failure 14/82 and 10% failure 6/60 in Duplex
  - The Duplex method seemed to have less failure with statistical significance of  $P < .001$ .
- 3) Studying the failure group, the paediatric and Adult females have more number of failures.
  - The pediatric population had failures and are statistically significant (11/21 Vs 9/121 –  $P < .05$ )
- 4) The reasons for early failure rates are analyzed and the causes, like, Technical problem at Anastomosis, Hypotension and early spasm contributes 23.5% each.

- 5) In evaluating the minor modifications in the operative technique, like End to side perpendicular anastomosis, only a small group 23 cases out of 142 are operated and statistical significance not established.

The effective use of Basilic vein for AV fistula creation and transposition surgery is a good alternative to synthetic graft. Such procedures are done only in a small group in our study.

- 6) Studying the early postoperative vein size and flow rates based on duplex scan, the increase in vein size and flow rates achieved at the end of IV week.

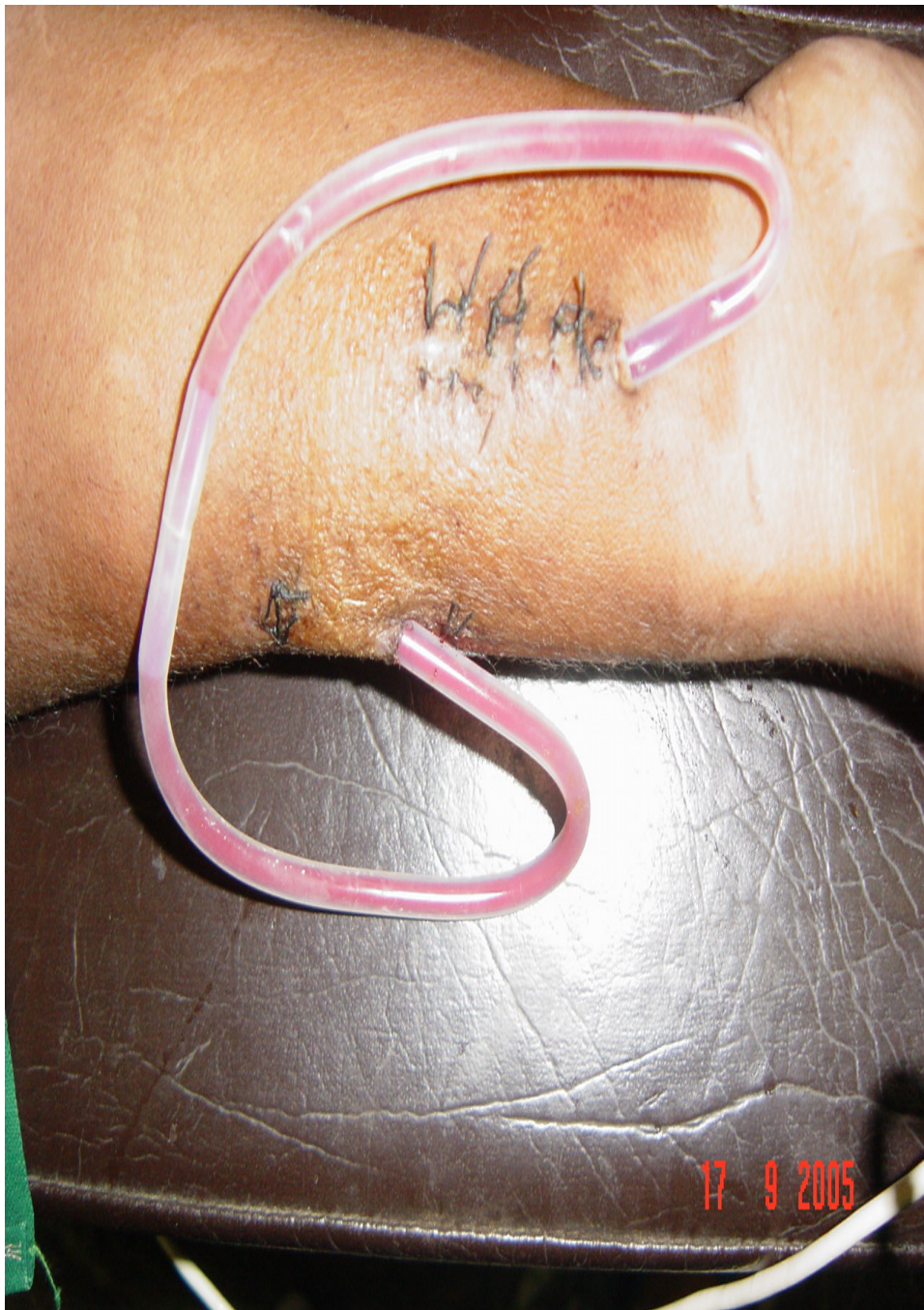However the flow rate and vein diameter measurement by duplex scan is operator dependent and subject to error in cross section area and angle of insonation.

- 7) In this study, the risk group, which requires definite preoperative duplex mapping are identified. They are –
- Pediatric Patients
  - Female patients
  - Patients with H/o Central Venous Catheterization
  - Primary procedure failure patients.

Further studies in Minor modification of Surgical Technique, Basilic Vein A.V. access with Transposition and Reducing the operator dependent

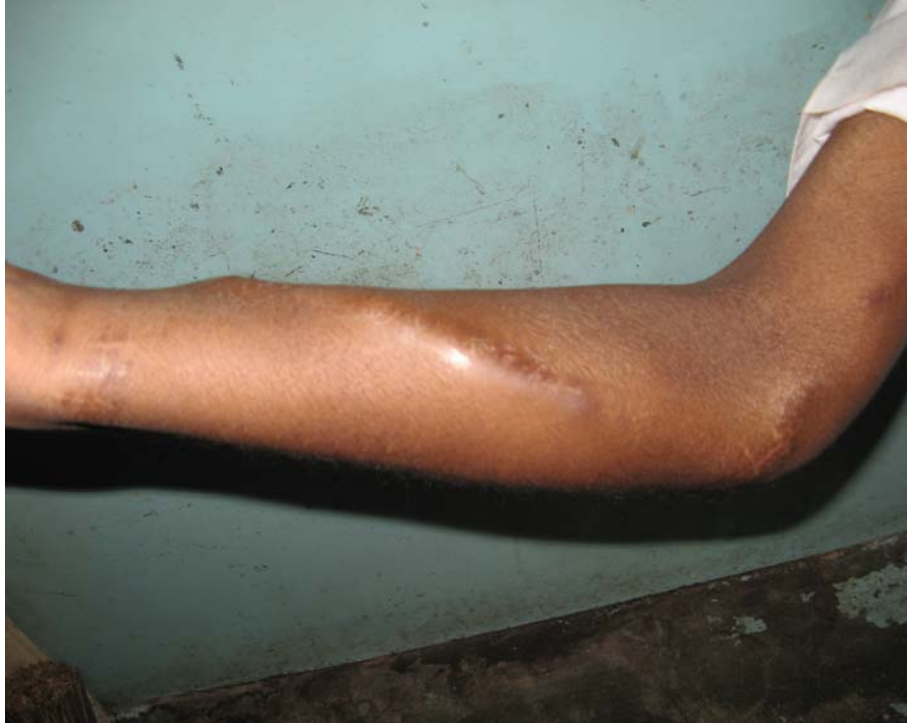errors in Duplex Scan will ensure better A.V. access. Large Series of Basilic Vein A.V. access with Transposition and end to side perpendicular anastomosis will give us adequate exposure regarding the advantages and disadvantages of these procedures.

As of now our experience in these surgeries is minimal.

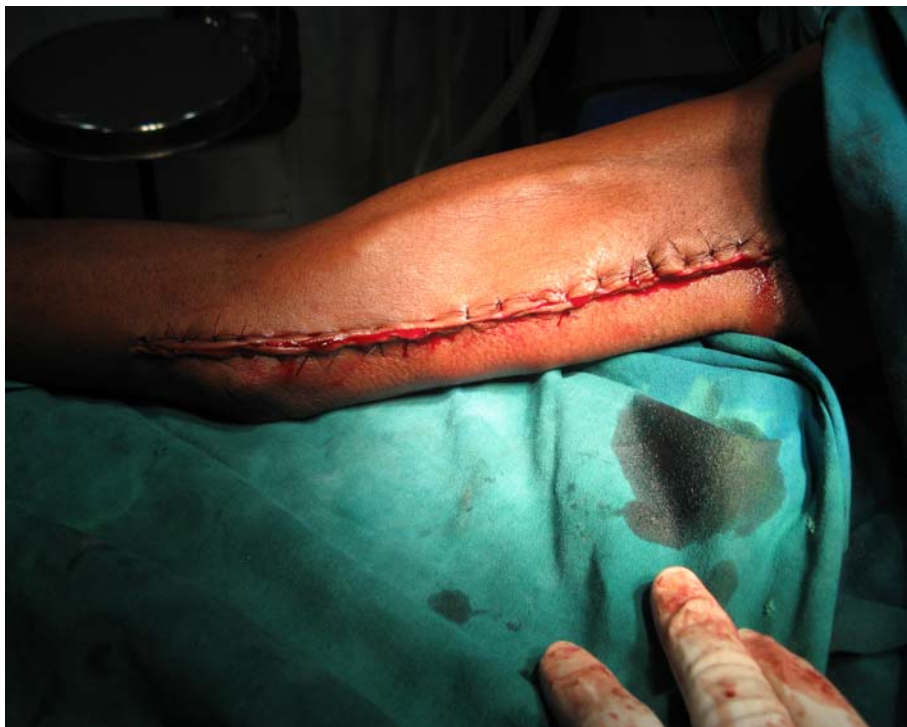

**Scribners shunt**

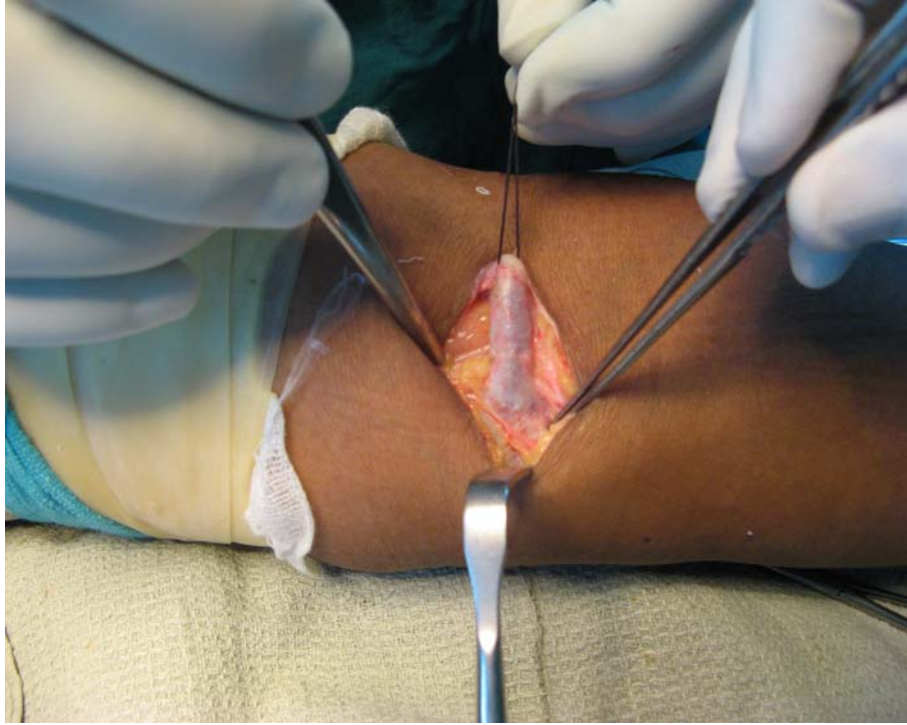




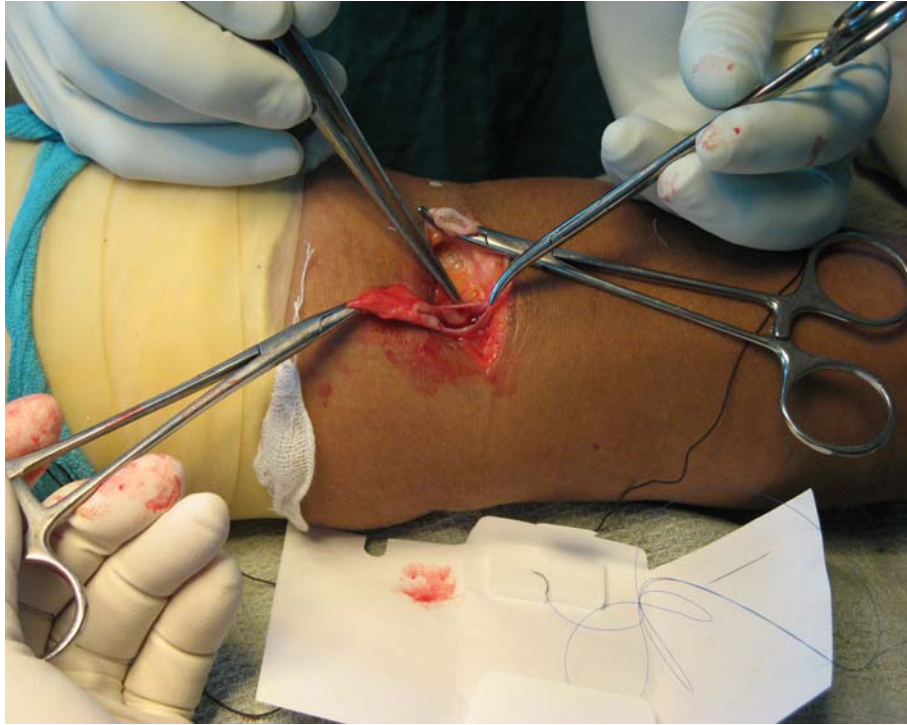**Radio Basilic AVF with Transposition of Basilic Vein at the end two months**



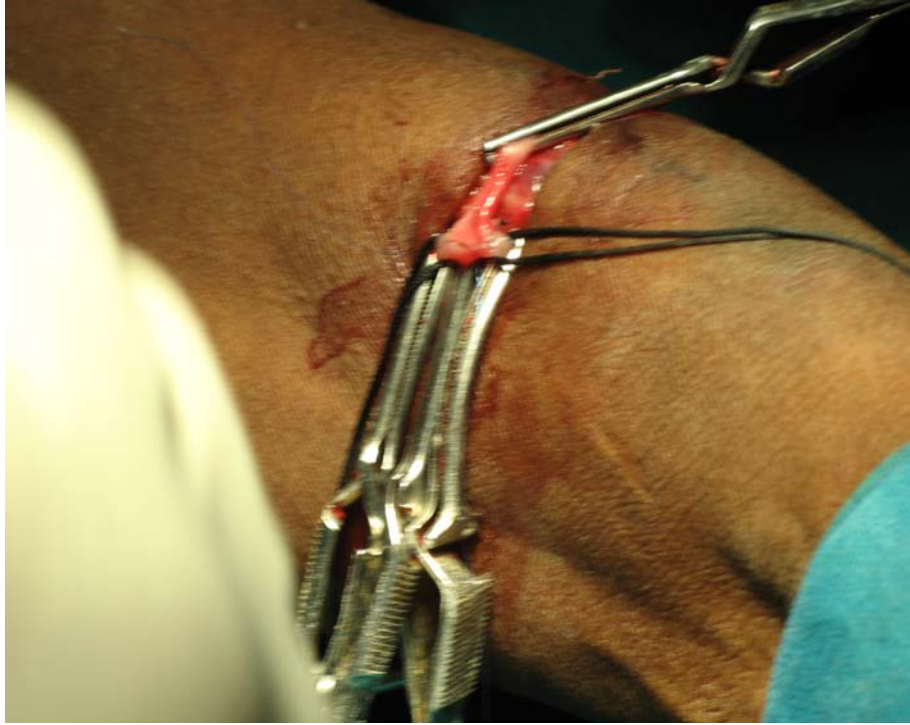**Post Brachio basilic AVF with transposition of Basilic Vein**



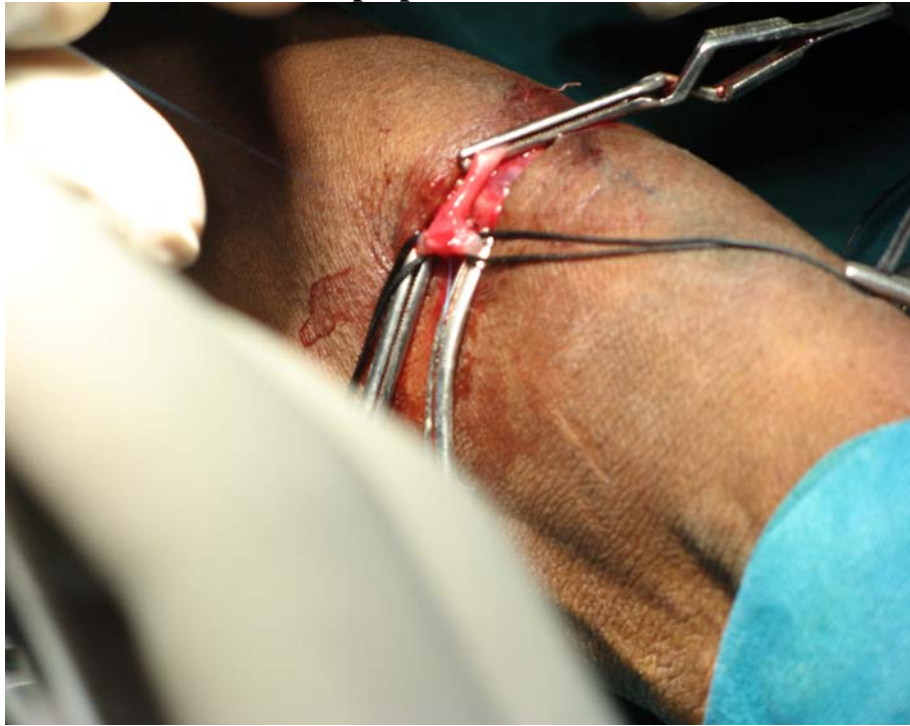
**Repair of Brachio Cephalic Pseudoaneurysm under tourniquet control**



**Pseudoaneurysm repair**

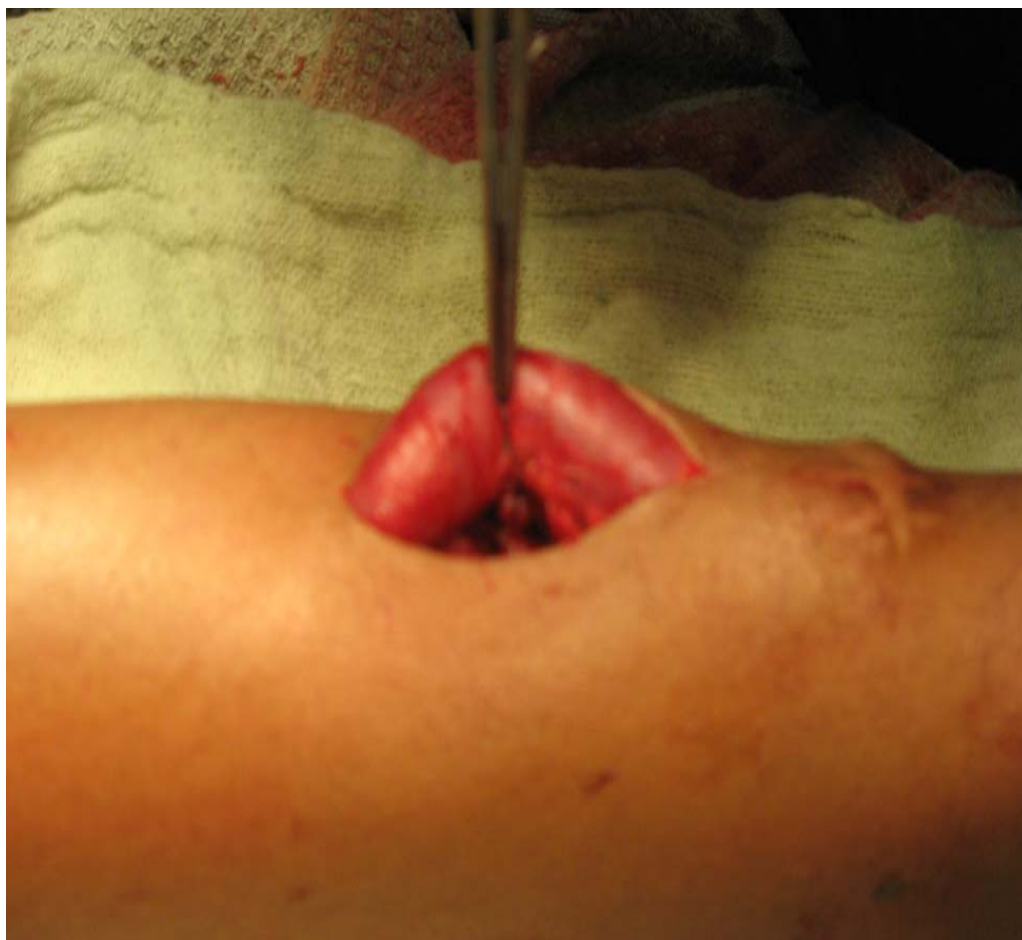

**End to side perpendicular anastomosis**

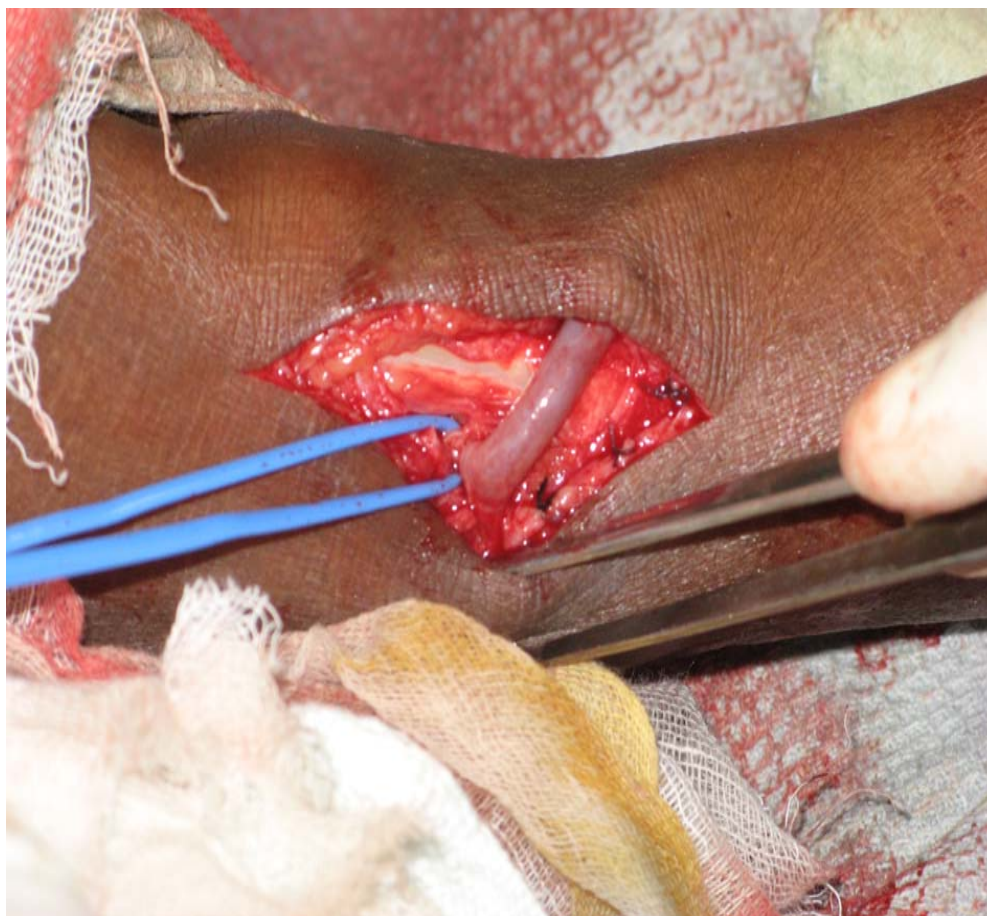


**End to Side Perpendicular Anastomosis in Radio Cephalic AVF**

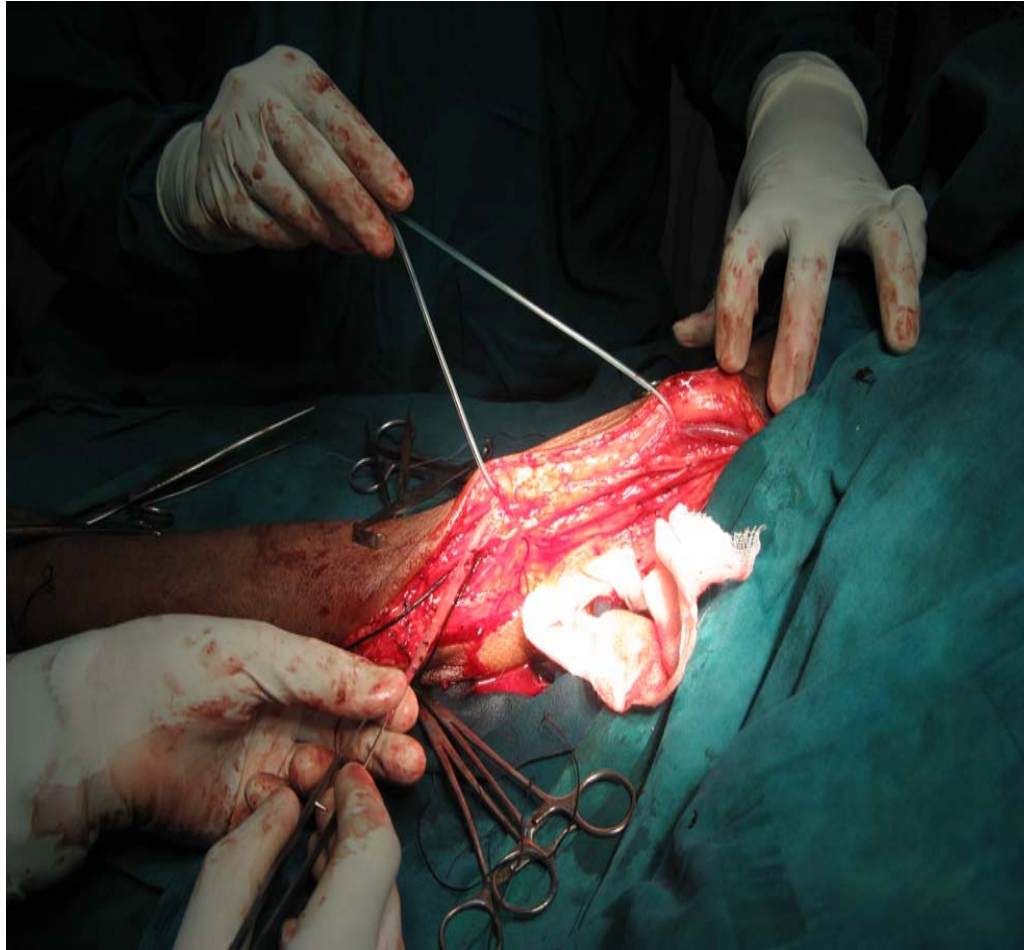




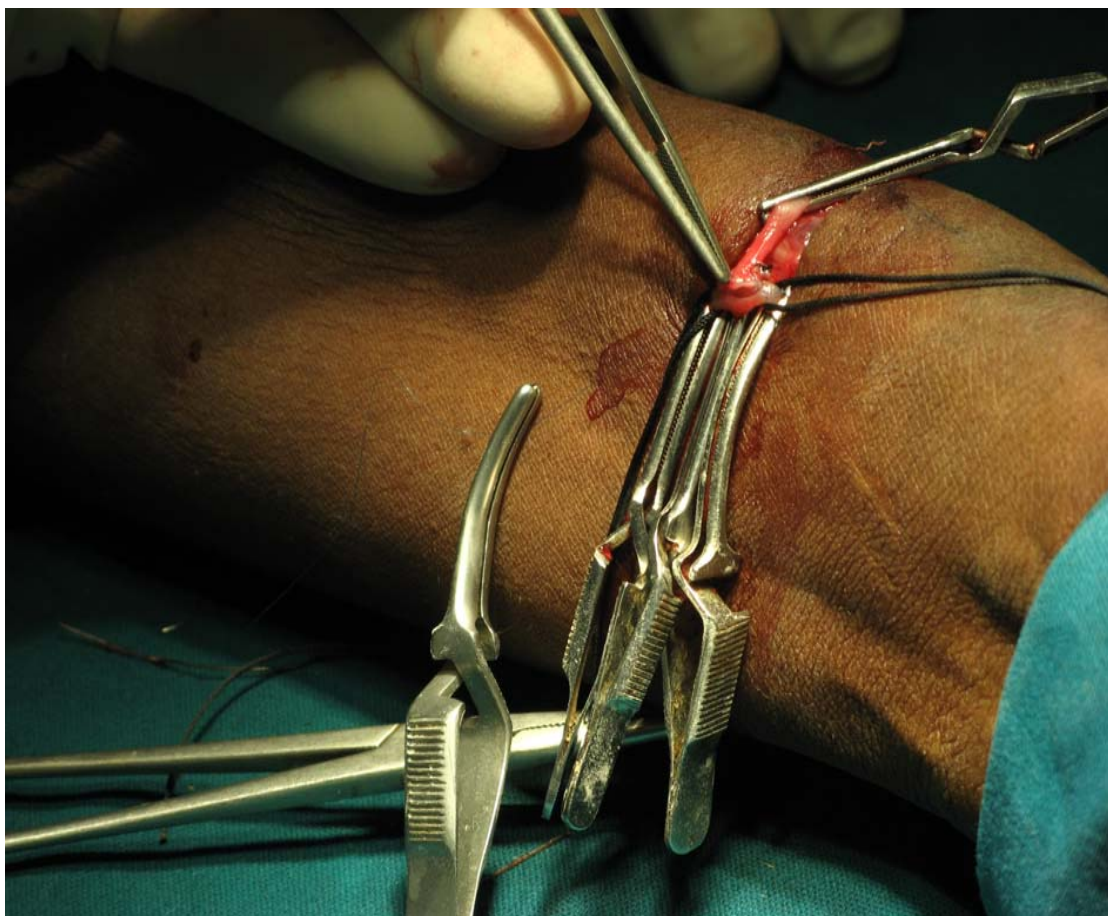
**Dialysis Puncture Pseudoaneurysm**



**Brachio Cephalic AVF**

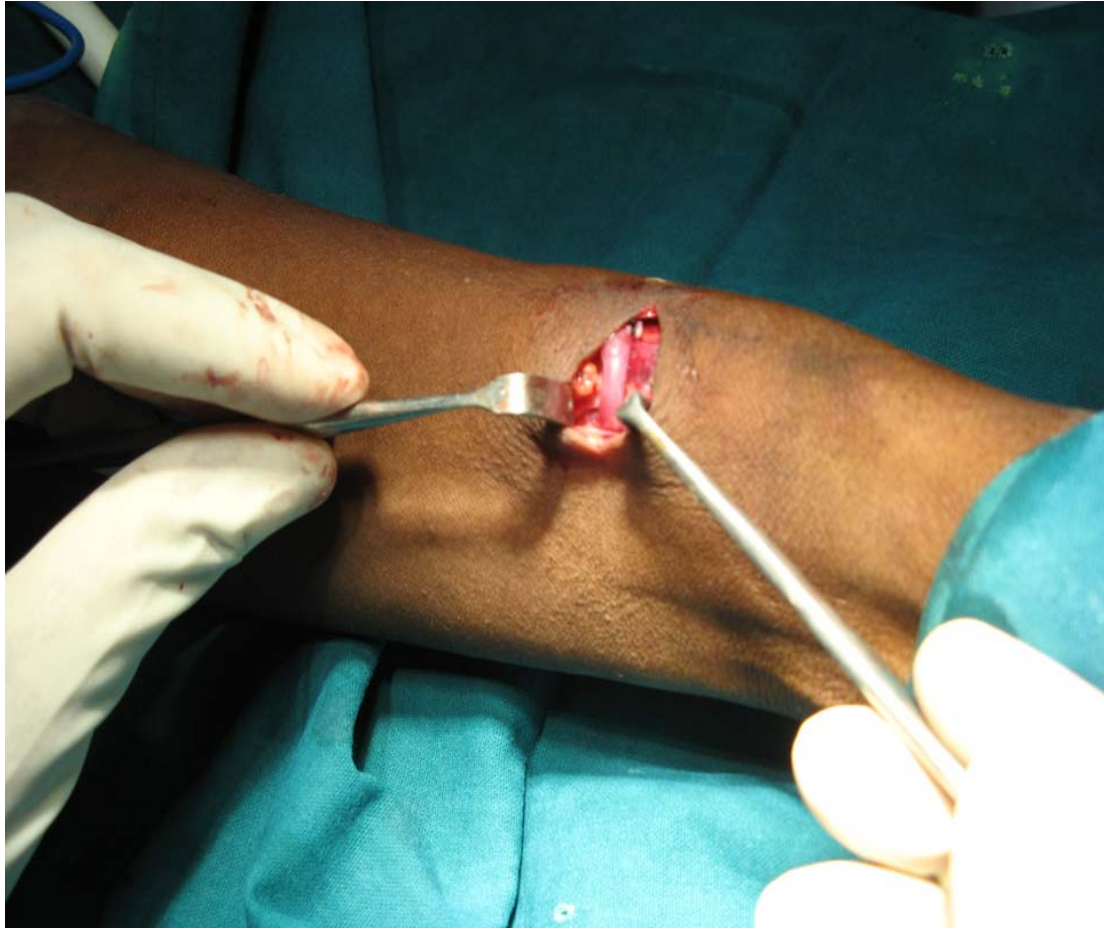


**Basilic Vein Transposition at arm level**



**Radio Cephalic AVF**

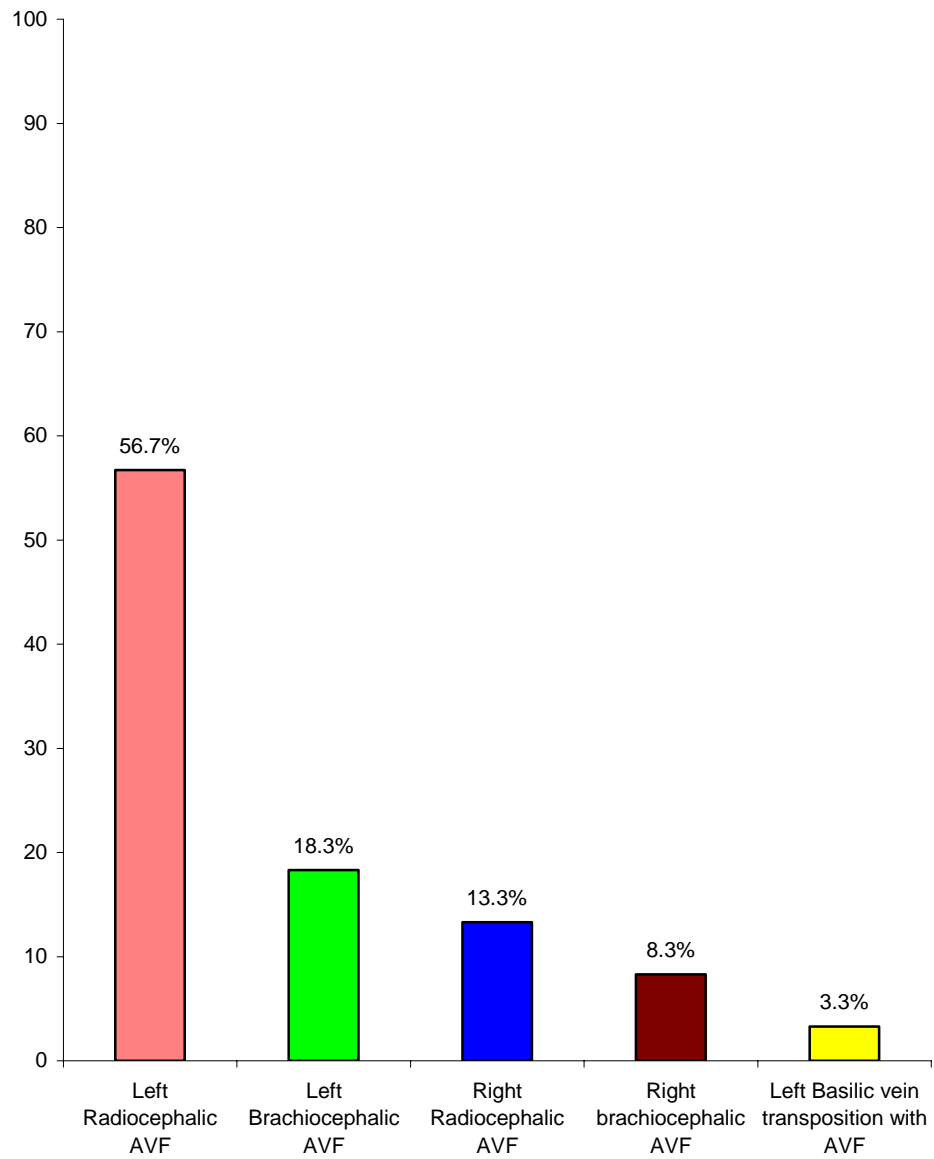




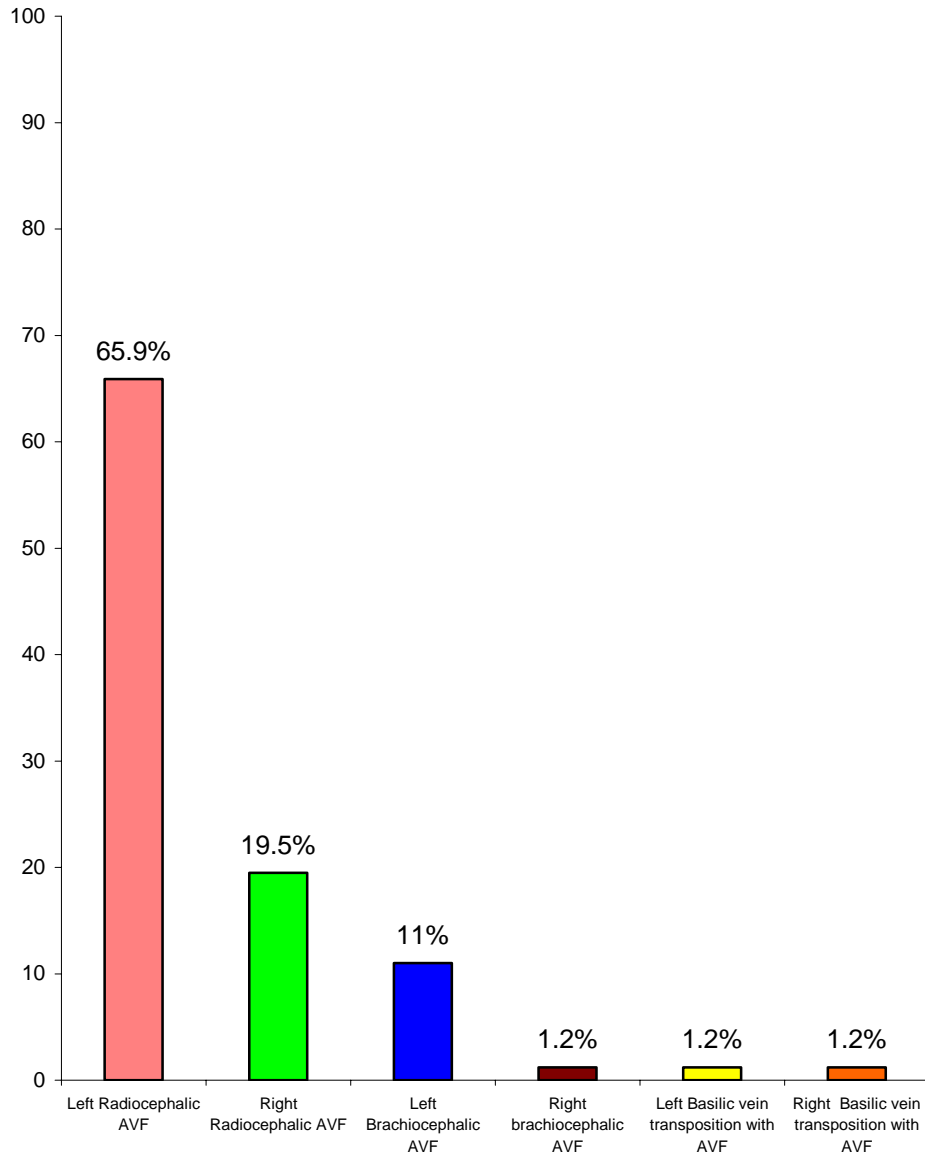
**Post operative picture with smooth angulation in end to side perpendicular anastomosis**



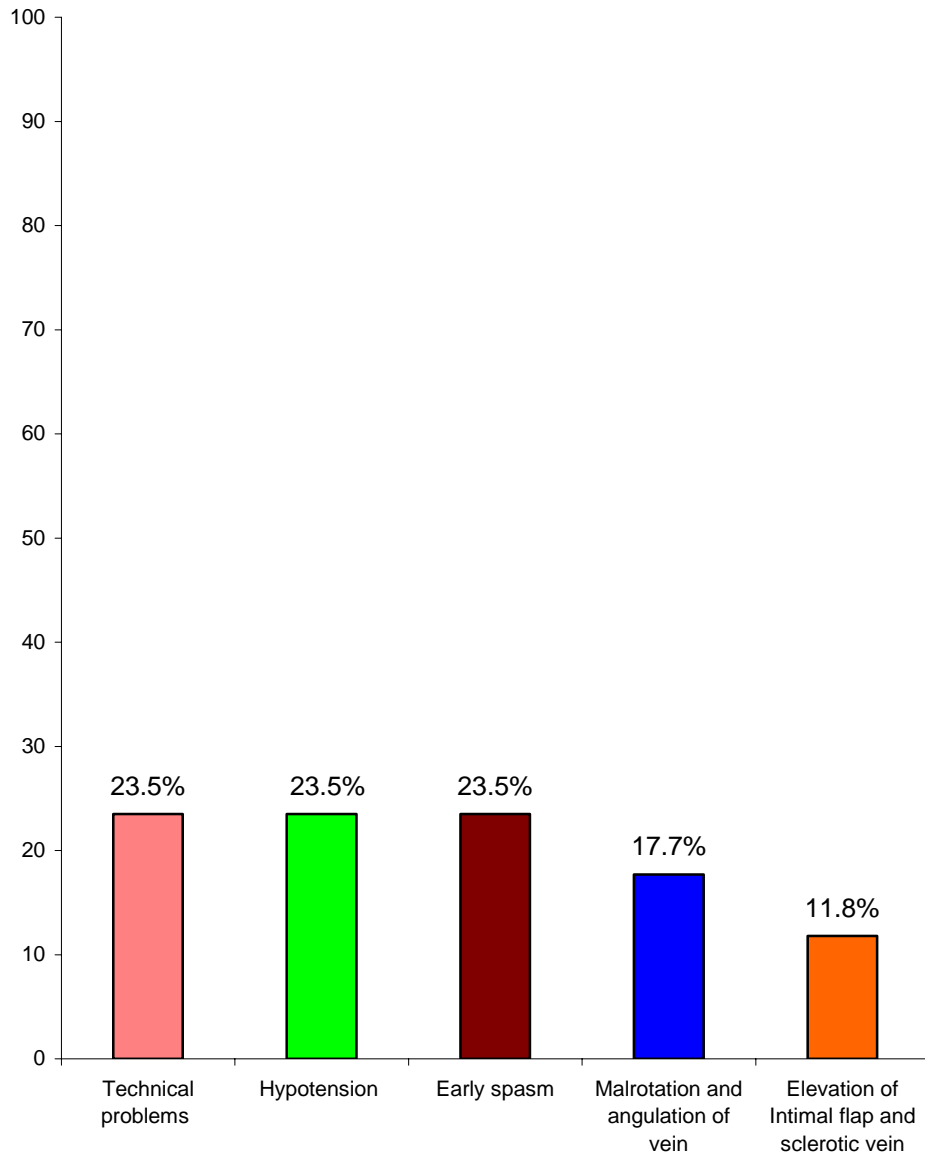
### Procedures done based on duplex method



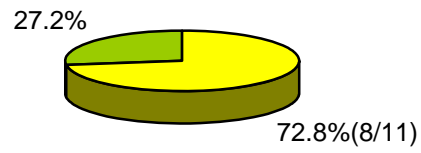
### Procedures done based on clinical evaluation



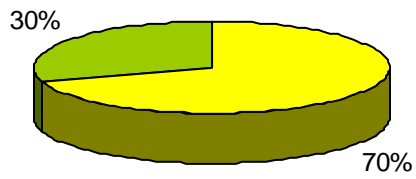
### Early failure Rates



### AVF Failure in Pediatric Age Group

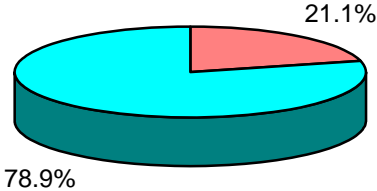


■ % of AVF failures in Pediatric Age group on clinical methods  
■ % of AVF Functioning in Pediatric Age group on clinical methods

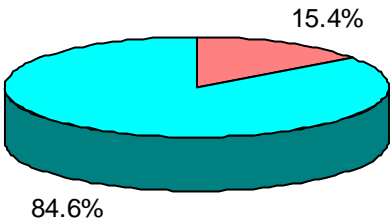


■ % of AVF functioning in Pediatric Age group on duplex methods  
■ % of AVF failures in Pediatric Age group on duplex methods

### AVF Failures in Adult Female



■ % of AVF Failure in Adult female based on clinical methods  
■ % of AVF functioning in Adult female based on clinical methods



■ % of AVF Failure in Adult female based on Duplex methods  
■ % of AVF functioning in Adult female based on Duplex methods

## **BIBLIOGRAPHY**

1. Glanz S, Gordon DH, Lipkowitz GS, Butt KM, Hong J, Scalafani SJ : Axillary and Subclavian Vein Stenosis : Percutaneous angioplasty. Radiology 168:371-373, 1988.
2. Harland RC : Placement of Permanent Vascular access devices : Surgical Considerations. Adv Ren Replace Ther 1: 99-106, 1994.
3. Palder SB, Kirkman RL, Whittemore AD, Hakim RM, Lazarus JM, Tilney NL : Vascular access for hemodialysis. Patency rates and results of Revision. Ann Surg 202 : 235-239, 1985.
4. Raju S: PTFE grafts for hemodialysis access. Techniques for insertion and Management of complications. Ann Surg. 206: 666 - 673, 1987.
5. Trerotola S: Interventional Radiology In Central Venous Stenosis and Occlusion. Semin Interv Radiol 11: 291-304, 1994.
6. Allon M, Lockhart ME, Lilly RZ, et al: Effect of preoperative Sonographic mapping on Vascular access Outcomes in hemodialysis patients. Kidney Int 60: 2013-2020, 2001.
7. Ascher E, Grade P, Hingorani A, et al: Changes in the practice of angioaccess Surgery : Impact of Dialysis Outcome and Quality Initiative Recommendations J Vas Surg 31: 84-92, 2000.
8. Silva MBJR; HobsonRW II, Pappas PJ, et al: A strategy for increasing use of autogenous hemodialysis access procedures: Impact of

preoperative noninvasive evaluation. *Jvas Surg* 27: 302-307: Discussion 307-308, 1998.

9. Barrett N, Spencer S, Mc Ivor J, Brown EA : Subclavian Stenosis : A Major Complication of Subclavian dialysis catheters *Nephrol Dial Transplant* 3: 423-425, 1988.
10. Marx AB, Landmann J, Harder FH : Surgery for Vascular access. *Curr Probe Surg* 27:1-48, 1990.
11. Silva MBJR, Hobson RWII, Pappas PJ, et al: A strategy for increasing use of autogenous hemodialysis access procedures: Impact of preoperative non invasive evaluation. *J Vas Surg* 27: 302-307 Discussion 307-308, 1998.
12. Mendes RR, Faber MA, Marston WA, Dinwiddie LC, Keagy BA, Burnham SJ . Prediction of wrist arteriovenous fistula maturation with preoperative Vein Mapping with Ultrasonography. *J Vas Surg* 36: 406-463, 2002.
13. Malovrh M : Approach to patients with End stage renal disease who need and Arterio venous fistula. *Nephrol Dial Transplant* 18 : SV 50-SV52, 2003 (Suppl 5).
14. Wong V, Ward R, Taylor J, Selva Kumar S, How TV, Bakran A: Factors associated with early failure of arteriovenous fistulae for hemodialysis access: *Eur J Vasc Endovasc Surg* 12: 207-213, 1996.

15. Patel MC, Berman LH, Moss HA, Mc Pherson SJ: Subclavian and Internal Jugular Veins at Doppler US : Abnormal Cardiac pulsality and Respiratory phasicity as a predictor of complete central occlusion. *Radiology* 211: 579-583, 1999.
16. Passman MA, Criado E, Faber MA, et al : Efficacy of Color Flow Duplex imaging for proximal upper extremely Venous Outflow obstruction in hemodialysis patients. *J Vasc Surg* 28: 869-875, 1998.
17. Sidawy AN, Gray R, Besarak A, et al. Recommended standards for reports dealing with Arteriovenous hemodialysis access. *J Vas Surg* 2002; 35: 603-610.
18. Gracz KC, Ing TS, Soung LS, Armbruster KF, Seim SK, Merkel FK: proximal forearm fistula for maintenance hemodialysis. *Kidney Int* 11: 71-75, 1972.
19. Perera G.B, Muellor MP, Kubaska SM, Wilson SE, Lawrence PF, Fujitani RM : Superiority of autogenous arteriovenous hemodialysis access: Maintenance of function with fewer secondary interventions. *Ann Vasc Surg* 18: 66-73, 2004.
20. Huber TS, Carter JW, Carter RL, Seeger JM: Patently of autogenous and PTFE upper extremity arterio venous hemodialysis access: A systematic Review. *J Vasc Surg* 38: 1005-1011, 2003
21. Nassar GM, Ayus JC : Infectious Complications of the hemodialysis access, *Kidney Int* 60:1 -13, 2001.



22. Silva MB Jr, Hobson RW II, Pappas PJ, et al: Vein Transportation in the forearm for autogenous hemodialysis access. *J Vas. Surg* 26: 981-988.
23. Harry Schanzer : Overview of complications and Management After Vascular access creation. *Dialysis Access - Chapter 15*.
24. Kurt B. Stevenson : Management of Hemodialysis Vascular Access infection. *Dialysis Access - Chapter 16*.
25. Barnes RW. Hemodynamics for the Vascular Surgeon. *Arch.Surg* 1980; 115: 216-223.
26. Jan. H.M. Tordoir : Surgical Management of Autologous Fistulae. Early and Late Thrombosis, Maturation failure and other Complications - *Dialysis Access*.
27. Owada A, Saito H, Mochizuki T, et al. Radial Artery Spasm in Uremic Patients undergoing construction of arteriovenous hemodialysis fistulas: Diagnosis and prophylaxis with intravenous Nicardipine. *Nephron* 1993; 64: 501-504.
28. Stewart SF : Effects of Transducer, Velocity, Doppler angle, and instrument settings on the accuracy of color Doppler Ultrasound. *Ultrasound Med Biol* 27: 551-564, 2001.