

# **"A STUDY ON CARDIOPULMONARY MANIFESTATIONS IN INFLAMMATORY MYOSITIS"**

*Dissertation Submitted to*  
**THE TAMIL NADU DR.M.G.R.MEDICAL UNIVERSITY,  
CHENNAI- 600 032.**

*In partial fulfillment of the regulation  
for the award of the degree of*  
**DM (RHEUMATOLOGY)  
BRANCH - IX**



**MADRAS MEDICAL COLLEGE  
RAJIV GANDHI GOVERNMENT GENERAL HOSPITAL  
CHENNAI – 600 003.**

**AUGUST 2012**

## **CERTIFICATE**

This is to certify that this dissertation entitled “**A STUDY ON CARDIOPULMONARY MANIFESTATIONS IN INFLAMMATORY MYOSITIS**” presented here is original work done by **Dr.B.SENTHIL KUMAR**, Post Graduate in the Department of Rheumatology, Madras Medical College and Rajiv Gandhi Government General Hospital, Chennai- 600 003 in partial fulfillment of the university rules and regulation for the award of D.M.Branch IX- Rheumatology, under my guidance and supervision during the academic period from 2009-2012.

**Dr.V.KANAGASABAI, MD.,**  
*Dean,*  
*Madras Medical College and*  
*Rajiv Gandhi Govt. General*  
*Hospital,*  
*Chennai – 600 003.*

**Dr.S.RUKMANGATHARAJAN, MD., DM., FMMC.,**  
*Professor and HOD,*  
*Department of Rheumatology,*  
*Madras Medical College and*  
*Rajiv Gandhi Govt. General Hospital,*  
*Chennai – 600 003.*

## **DECLARATION**

I, **Dr.B.Senthil Kumar** hereby solemnly declare that this dissertation entitled “**A STUDY ON CARDIOPULMONARY MANIFESTATIONS IN INFLAMMATORY MYOSITIS**” was done by me in the Department of Rheumatology, Madras Medical College & Rajiv Gandhi Govt. General Hospital, Chennai-3 during February 2011 to January 2012 under the guidance and supervision of Prof.Dr.S.Rukmangatharajan, MD., DM., FMMC., This dissertation is submitted to the Tamil Nadu Dr.M.G.R.Medical University towards the partial fulfillment of requirement for the award of D.M., Degree in Rheumatology.

*Signature of the Candidate*

Date :

Place :

## **ACKNOWLEDGEMENT**

I express my heartfelt gratitude to the Dean, **Dr.V.KANAGASABAI, MD.,** Madras Medical College & Rajiv Gandhi Govt. General Hospital, Chennai-3 for permitting me to do this study.

I gratefully acknowledge and sincerely thank **Prof.Dr.S.RUKMANGATHARAJAN, MD., DM., FMMC.,** Professor and Head, Department of Rheumatology, for his valuable suggestions, guidance, constant supervision and moral support without which this study would not have been possible.

I am thankful to **Dr.K.MUTHULAKSHMI, MD.,** Additional Professor for her valuable guidance in doing the Biochemical and Immunological workup of patients.

I express my gratitude to **Dr.R.RAVICHANDRAN, MD., DCH., DM.,** Asst. Professor, Department of Rheumatology for the valuable guidance, advice and suggestions during the study.

I am extremely thankful to Assistant Professors, **Dr.T.N.TAMILSELVAM, MD., DM., Dr.S.BALAMEENA, MD., DCH., DM,** and **Dr. D.THERASA MARY, MD., (Micro)** and my **FELLOW POSTGRADUATES** for their constant support and advice during my study.

I am extremely thankful to the **Laboratory Personnel** for their invaluable help in carrying out the immunological investigations without which, this work would not have been possible.

I thank **Physiotherapist, all Staff Nurses and all the Paramedical staff members** in the Department of Rheumatology, Madras Medical College, Rajiv Gandhi Government General Hospital, Chennai for their full co-operation in conducting the study.

Last but not the least, I owe my sincere gratitude to the patients and their relatives who co-operated for this study, without whom the study could not have been possible.

## INDEX

S.NO	CONTENT	PAGE NO.
1.	INTRODUCTION	1
2.	AIMS AND OBJECTIVES	2
3.	REVIEW OF LITERATURE	3-48
4.	MATERIALS AND METHODS	49
5.	OBSERVATIONS AND RESULTS OF THE DATA	50-70
6.	DISCUSSION	71-74
7.	SUMMARY & CONCLUSION	75
8.	BIBLIOGRAPHY	
9.	ANNEXURE A) PROFORMA B) MASTER CHART C) PATIENT CONSENT FORM D) ETHICAL COMMITTEE APPROVAL ORDER	

## **ABBREVIATION**

SLE	Systemic Lupus Erythematosus
IIM	Idiopathic Inflammatory Myositis
MCTD	Mixed Connective Tissue Disease
RA	Rheumatoid Arthritis
HLA	Human Leukocyte Antigen
ANA	Anti Nuclear Antibody
ENA	Extractable Nuclear Antigen
CPK	Creatine Phospho Kinase
LDH	Lactate Dehydrogenase
ELISA	Enzyme-Linked Immuno sorbent Assay
HRCT	High Resolution Computerized Tomography
PFT	Pulmonary Function Test
CXR	Chest X-Ray
EMG	Electro Myography
ILD	Interstitial Lung Disease
DM	Dermato Myositis
PM	Poly Myositis

IBM	Inclusion Body Myositis
BAL	Broncho Alveolar Lavage
LFT	Liver Function Test
RFT	Renal Function Test
AST	Aspartate Transaminase
ALT	Alanine Transaminase
MRI	Magnetic Resonance Imaging
USG	Ultrasonography
ECG	Electro Cardiogram
ECHO	Echo Cardiogram
PE	Pericardial Effusion
ESR	Erythrocyte Sedimentation Rate
CRP	C-Reactive Protein
NSIP	Non Specific Interstitial Pneumonitis
UIP	Usual Interstitial Pneumonitis
DAD	Diffuse Alveolar Damage
WNT	Wingless Integration-1
MRF-D	Myogenic Regulatory Factor D
MYF-4	Myogenic Factor
MYO	Myogenesis Determining Factor



## INTRODUCTION

The Inflammatory Myopathies encompass a group of heterogenous muscle disorders which share the clinical features of slowly progressive weakness of skeletal muscle, decreased muscle endurance and muscle fatigue. Another common feature is presence of inflammatory infiltrates, mainly composed of T cells and macrophages, in muscles tissue. Autoantibodies are also frequent in patients with inflammatory myopathies. The presence of infiltrating lymphocytes in the target organ, the muscles, and autoimmune disease but a target autoantigen has not been determined.

Although muscle symptoms predominate in myositis patients, other clinical manifestations are common. Besides skin rash, which by definition is present in dermatomyositis patients, interstitial lung disease is a frequently observed extramuscular manifestations, as are arthritis, Raynaud's phenomenon and gastrointestinal involvement. Moreover, myositis is often observed in patients with other connective tissue diseases, particularly in those with systemic sclerosis, mixed connective tissue disease (MCTD) and Sjogren's syndrome and occasionally in patients with rheumatoid arthritis (RA) or systemic lupus erythematosus (SLE). These observations suggests that the idiopathic inflammatory myopathies are systemic inflammatory connective tissue disorders and that there could be etiological factors or pathogenic mechanisms that are shared with other connective tissue diseases.

In our study we attempt to find out the incidence, prevalence of cardiopulmonary manifestations in inflammatory myositis.

## **AIM AND OBJECTIVES**

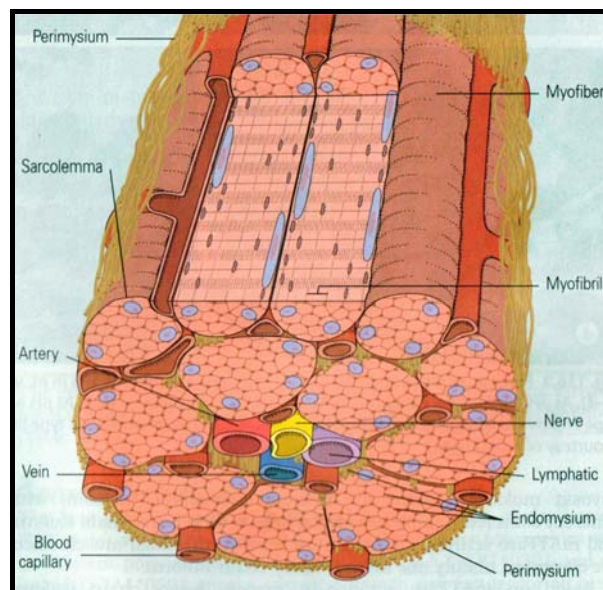
To determine the various cardiopulmonary manifestations in inflammatory myositis.

# REVIEW OF LITERATURE

## ANATOMY AND PHYSIOLOGY OF MUSCLE

### *Embryology and molecular regulation of muscle development*

The muscular system develops from the mesodermal germ layer<sup>1</sup> and consists of skeletal, smooth, and cardiac muscle. Skeletal muscle is derived from paraxial mesoderm, which forms somites from the occipital to the sacral regions and somitomeres in the head. Smooth muscle differentiates from splanchnic mesoderm surrounding the gut and its derivatives and from ectoderm (papillary, mammary gland, and sweat gland muscles). Cardiac muscle is derived from splanchnic mesoderm surrounding the heart tube.



***Schematic diagram of muscle bundle***

Somites and somitomeres form the musculature of the axial skeleton, body wall, limbs and head. From the occipital region caudally, somites form and differentiate into the sclerotome, dermatome, and two muscle-forming region. One of the regions appears at the ventrolateral edge or lip (VLL) of the prospective dermomyotome. Cells from the VLL contribute to formation

of the myotome and also provide progenitor cells for limb and body wall (Hypometric, hypaxial) musculature. The other region lies at the dorsomedial edge or lip (DML) of the dermomyotome, and dermatome. Eventually, these cells will form muscles of the back. During differentiation, precursor cells, the myoblasts, fuse and form long, multinucleated muscle fibers. Myofibrils soon appear in the cytoplasm, and by the end of the third month, cross striations, typical of skeletal muscle, appear. A similar process occurs in the seven somitomes in the head region rostral to the occipital somites. However somitomes remain loosely organized structures and never segregate into sclerotome and dermomyotome segments. Tendons for the attachment of muscles to bones are derived from sclerotome cells lying adjacent to myotomes at the anterior and posterior borders of somites. The transcription factor scleraxis regulates development of these cells.

## **GENETIC FACTORS IN MUSCLE DEVELOPMENT**

Genes regulating muscle development are bone morphogenic protein 4 (BMP4) and probably fibroblast growth factors (FGFs) from lateral plate mesoderm together with WNT proteins from adjacent ectoderm, signal ventrolateral edge or lip (VLL) cells of the dermomyotome to express the muscle-specific genes Myogenic factor-4 (MYF4) and Myogenesis determining factor (MYO-D<sup>2</sup>). BMP4 secreted by ectoderm cells induces production of WNT protein by the dorsal neural tube at the same time that low concentrations of sonic hedgehog (SHH) proteins, secreted by the notochord and floor plate of the neural tube, reach the dorsomedial edge or lip (DML) cells of the dermomyotomes. Together these proteins induce expression of MYF5 and MYO-D in these cells. Both MYO-D and MYF5 are

numbers of a family of transcription factors called myogenic regulatory factors (MRF) and it is this group of genes that activate pathways for muscle development.

Muscle is generally divided into three types, Skeletal, Cardiac and Smooth, though smooth muscle is not a homogenous single category. Skeletal muscle makes up the great mass of the somatic musculature. It has well developed cross striations, does not normally contract in the absence of nervous stimulation, lacks anatomic and functional connections between individual muscle fibers, and is generally under voluntary control. Cardiac muscle also has cross striations, but it is functionally syncytial and contracts rhythmically in the absence of external innervations owing to the presence in the myocardium of pacemaker cells that discharge spontaneously. Smooth muscle lacks cross-striations, which is found in most hollow viscera. The type found in the eye and in some other locations is not spontaneously active and resembles skeletal muscle.

## **MORPHOLOGY**

### ***Organization***

Skeletal muscles is made up of individual muscle fibers that are the “building blocks” of the muscular system<sup>2</sup> in the same sense that the neurons are the building blocks of the nervous system. Most skeletal muscle begin and end in tendons, and the muscle fibers are arranged in parallel between the tendinous ends, so that the force of contractions of the units is additive. Each muscle fiber is a single cell that is multinucleated, long, cylindrical, and surrounded by a cell membrane, the sarcolemma. There are no syncytial

bridges between cells. The muscle fibers are made up of myofibrils, which are divisible into individual filaments. The filaments are made up of the contractile proteins.

The contractile mechanism in skeletal muscle depends on the proteins myosin-II (molecular weight 40,000kda) actin (molecularweight 43,000kda) tropomyosin (Molecularweight 70,000kda) and troponin. Troponin is made up of three subunits; troponin-I, troponin T and troponin C. The three subunits have molecularweights ranging from 18,000kda to 35,000kda. Other important proteins in muscle were involved in maintaining the contractile proteins in appropriate relation to one another and connected to the external matrix.

## **STRIATIONS**

Difference in the refractive indexes of the various parts of the muscle fibers<sup>2</sup> are responsible for the characteristic cross-striations seen in skeletal muscle. The parts of the cross striations are identified by letters. The light I band is divided by the dark Z line, and the dark A band has the lighter H band in its center. A transverse M line is seen in the middle of the H band, and this line plus the narrow light areas on either side of it are sometimes called the pseudo-H zone. The area between two adjacent Z lines is called a sarcomere. The orderly arrangement of actin, myosin, and related proteins that produce this pattern. The thick filaments, which are about twice the diameter of the thin filaments are made up of actin, tropomyosin forms the less dense I bands. The lighter H bands in the centre of the A bands are the regions where, when the muscle is relaxed, the thin filaments do not overlap

the thick filaments. The Z lines transect the fibrils and connect to the thin filaments. If a transverse section through the A band is examined under the electron microscope, each thick filament is seen to be surrounded by six thin filaments in a regular hexagonal pattern.

The form of myosin found in muscle is myosin-II, with two globular heads and a long tail. The heads of the myosin molecules form cross-links to actin. Myosin contains heavy and light chains and its heads are made up of the light chains and the amino terminal portions of the heavy chains. These heads contain an actin-binding site and a catalytic site that hydrolyzes ATP. The myosin molecules are arranged symmetrically on either side of the centre of the sarcomere, and it is this arrangement that creates the light areas in the pseudo H zone. The M line is the site of the reversal of polarity of the myosin molecules in each of the thick filaments. At this point, there are slender cross-connections that hold the thick filaments in proper array. Each thick segment contains several hundred myosin molecules. The thin filaments are polymers made up of two chains of actin that form a long double helix. Tropomyosin molecules are long filaments located in the groove between the two chains in the actin. Each thin filament contains 300-400 actin molecules and 40-60 tropomyosin molecules. Troponin molecules are small globular units located at intervals along the tropomyosin molecules. Troponin T binds the other troponin components to tropomyosin, troponin I inhibits the interaction of myosin with actin, and troponin C contains the binding sites for the  $\text{Ca}^{2+}$  that initiates contractions.

Actinin, which has a molecular weight of 1,90,000kda binds actin to the Z lines. Titin, a large protein connects the Z lines to the M lines and provides the scaffolding for the sarcomere. It contains two kinds of folded domains, and these provide muscle with its elasticity. At first when the muscle is stretched there is relatively little resistance as the domains unfold, but with further stretch there is a rapid increase in resistance that protects the structure of the sarcomere. Desmin binds the Z lines to the plasma membrane.

## **SARCOTUBULAR SYSTEM**

The muscle fibrils are surrounded by structures made up of membrane that appear in electron photomicrographs as vesicles and tubules. These structures form the sarcotubular system<sup>2</sup>, which is made up of a T system and a sarcoplasmic reticulum. The T system of transversetubules, which is continuous with the membrane of the muscle fiber, forms a grid perforated by the individual muscle fibrils. The space between the two layers of the T system is an extension of the extracellular space. The sarcoplasmic reticulum, which forms an irregular curtain around each of the fibrils, has enlarged terminal cisterns in close contact with the T system with a cistern of the sarcoplasmic reticulum on either side has led to the use of the term triads to describe the system. The function of the T system, which is continuous with the sarcolemma, is the rapid transmission of the action potential from the cell membrane to all the fibrils in the muscle. The sarcoplasmic reticulum is concerned with  $Ca^{2+}$  movement and muscle metabolism.

A large protein called dystrophin (molecular weight 4,27,000kda) forms a rod that connects the thin actin filaments to the transmembrane



protein  $\beta$  dystroglycan in the sarcolemma.  $\beta$ -dystroglycan is connected to laminin in the extracellular matrix by  $\alpha$ -dystroglycan.

## **MOLECULAR BASIS OF CONTRACTION**

The process by which the shortening of the contractile elements in muscles is brought about is a sliding of the thin filaments over the thick filaments. The width of the A bands is constant, whereas the Z lines move closer together when the muscle contracts and farther apart when it is stretched.

The sliding during muscle contraction occurs when the myosin heads bind firmly to actin, bend at the junction of the head with the neck, and then detach. The “Power stroke” depends on the simultaneous hydrolysis of ATP. Myosin-II molecules are dimers that have two heads, but only one attaches to actin at a time. Many heads cycle at or near the same time, and they cycle repeatedly, producing gross muscle contraction. Each stroke shortens the sarcomere about 10nm. Each thick filament has about 500 myosin heads, and each head cycles about five times per second during a rapid contraction.

The process by which depolarization of the muscle fiber initiates contraction is called excitation contraction coupling. The action potential is transmitted to all the fibrils in the fiber via the T system. It triggers the release of  $\text{Ca}^{2+}$  which initiates contraction by binding to troponin C. In resting muscle, troponin I is tightly bound to actin and tropomyosin covers the sites where myosin heads bind to actin. Thus, the troponin- tropomyosin complex constitutes a “relaxing protein” that inhibits the interaction between actin and myosin. When the  $\text{Ca}^{2+}$  released by the action potential binds to troponin C,

the binding of troponin I to actin is presumably weakened, and this permits the tropomyosin to move laterally. This movement uncovers binding sites for the myosin heads. ATP is then split and contraction occurs. Seven myosin-binding sites are uncovered for each molecule of troponin that binds a calcium ion.

Shortly after releasing  $\text{Ca}^{2+}$ , the sarcoplasmic reticulum begins to reaccumulate it by ATP mediated active transport of it stored until released by the terminal cisterns, where it is stored until released by the next action potential. Once the  $\text{Ca}^{2+}$  concentration outside the reticulum has been lowered sufficiently, chemical interaction between myosin and actin causes and the muscle relaxes. Note that ATP provides the energy for both contractions and relaxation. If transport of  $\text{Ca}^{2+}$  into the reticulum is inhibited, relaxation does not occur even though there are no more action potentials; the resulting sustained contraction is called contracture.

Depolarization of the T tubule membrane activates the sarcoplasmic reticulum via dihydropyridine receptors, named for the drug dihydropyridine, which blocks them. They are voltage gated  $\text{Ca}^{2+}$  channels in the T tubule membrane. In cardiac muscle, influx of  $\text{Ca}^{2+}$  via these channels triggers the release of  $\text{Ca}^{2+}$  stored in the sarcoplasmic reticulum, but in skeletal muscle  $\text{Ca}^{2+}$  entry from the ECF by this route is not required for  $\text{Ca}^{2+}$  release. Instead, the dihydropyridine receptor serves as the voltage sensor and trigger that unlocks released of  $\text{Ca}^{2+}$  from the nearby sarcoplasmic reticulum. The  $\text{Ca}^{2+}$  Channel in the sarcoplasmic reticulum. The  $\text{Ca}^{2+}$  channel in the sarcoplasmic reticulum that opens to permit the outpouring of  $\text{Ca}^{2+}$  is not

voltage gated and is called the ryanodine receptors because it is called the open position by the plant alkaloid ryanodine. It is closely related to the IP<sub>3</sub> (Inosine Phosphate) receptor, a ligand-gated Ca<sup>2+</sup> channel that, when it binds IP<sub>3</sub> (Inosine Phosphate) permits Ca<sup>2+</sup> to enter the cytoplasm from the endoplasmic reticulum. The pump that moves Ca<sup>2+</sup> back into the reticulum, producing relaxation, is a Ca<sup>2+</sup>, Mg<sup>2+</sup>, ATPase.

## **FIBER TYPES<sup>2</sup>**

Skeletal muscle is a very heterogeneous tissue made up of fibers that vary in myosin ATPase activity, contractile speed and other properties. The fibers fall roughly into two types slow type-I, fast type-IIA and fast type-IIB. A fourth fiber type defined by mATPase reactivity, is an intermediate, undifferentiated type-IIC fiber. Type-IIC fibers are regarded as transition fibers which can develop into type-I or type II fibers. Type I fibers contain the slow myosin heavy chain isoform and type II fibers contain the fast myosin heavy chain isoform. Type-IIC fibers contain at least two different myosin isoforms as well as developmental fetal myosin. Fiber types can also be separated using biochemical staining for mATPase at different pH values depending on the varying pH sensitivity of different mATPase reactivity.

The different fiber types exhibit various physiological properties. Thus type I fibers, slow twitch are characterized by relatively low mATPase activity and large and numerous mitochondria, making these fibers fatigue resistant and suitable for prolonged aerobic exercise and endurance work. Type II fibers, on the other hand, have a high mATPase activity rely mainly on glycolytic systems for energy supply and are important for quick powerful

actions. The specificity of fiber type in a muscle is determined during development in the embryonic muscle and seems to be genetically determined.

Each muscle is composed of a mixture of type I and II fibers, creating a checkerboard pattern. The ratio between the fiber types determines the physiological properties of the muscle. There are large inter individual variations in fiber type composition, it is advantageous for different purposes. For example, marathon runners have a predominance of slow twitch, type-I fibers whereas athlete sprinters and ice hockey players have a predominance of fast-twitch, type-II fibers. There is a tendency to gender differences, with more type-I fibers in women than in men.

## **MUSCLE DEVELOPMENT AND REGENERATION<sup>2</sup>**

During development, muscles are composed of single nucleated myoblasts that fuse into multinucleated myotubes, which differentiate into mature muscle fiber. The phenotype of a developing muscle fiber differs from mature muscle fibers concerning, the expansion of molecules on the cell surface as well as in the cytoplasm or the sarcoplasm. One characteristic phenotype of mature, differentiated muscle fibers is the absence of major histocompatibility complex (MHC) class I molecules (human leukocyte antigen (HLA) A, B, C). MHC class I molecules are expressed on all nucleated cells in the body, with a few exceptions such as nerve cells and muscle cells. One important function of MHC class I molecules is to present endogenous antigens to the immune system via interactions with T cell receptors. The role of MHC class I molecules during development of muscle

fibers and why in nature muscle fibers lose MHC class I expression during differentiation is not known.

Muscle has a regenerating capacity depending on satellite cells, a kind of reserve cell localized under the basal lamina of the muscle fiber. Upon appropriate stimuli, these satellite cells can grow and fuse with the fiber or develop into new adult muscle cells, a process termed regeneration. Regenerating fibers are often found in muscle biopsies from patients with inflammatory myopathies.

***Classification of fiber types in skeletal muscles***

	<b>Type-I</b>	<b>Type-II</b>
Other names	Slow; oxidative; red	Fast; glycolytic; white
Myosin isoenzyme ATPase rate	Slow	Fast
Ca <sup>2+</sup> pumping capacity of sarcoplasmic reticulum	Moderate	High
Diameter	Moderate	Large
Glycolytic capacity	Moderate	High
Oxidative capacity (correlates with content of mitochondria, capillary density, myoglobin content)	High	Low

**ANATOMY AND PHYSIOLOGY OF HEART**

**EMBRYOLOGY OF HEART<sup>1</sup>**

The heart is seen to develop first as two ended, helical heart tubes in the splanchnopleuric mesoderm (cardiogenic tissue), ventral to the pericardial cavity, but dorsal to the yolk sac. The two tubes soon fuse together in a

craniocaudal direction to form a single tubular heart, the lining cells form the endocardial lining of the heart.

## **ANATOMY OF HEART**

Heart is a hollow muscular organ situated in the middle mediastinum inside the pericardium. It is conical in shape it has an apex formed by left ventricle, a base formed by posterior wall of left atrium the small part of the right atrium. Pulmonary veins enter the left atrium. The superior and inferior venae-cavae enter the right atrium above and below. It has four chambers two atria and two ventricles in the heart. Atria are above and behind the ventricles. Anterior surface is bound by a part of atrium and ventricle. Inferior surface is found by right ventricle and the left two third of the left ventricle. Pericardium is a fibrous sac which invests and protects the heart in the roots of great vessels. Heart is supplied by branches in the superficial and the deep cardiac plexuses. The blood supply of the heart is mainly by right and left coronary arteries. The venous drainage of the heart is mainly through coronary sinus and anterior cardiac veins. The lymphatic drainage of the heart is superior mediastinal nodes and right tracheobronchial nodes. The conducting system of the heart atrial node, AV node, AV bundle and Purkinje fibers.

## **MORPHOLOGY OF CARDIAC MUSCLE**

The striations in cardiac muscle are similar to those in skeletal muscle, and Z lines were present. Large numbers of elongated mitochondria are in close contact with the muscle fibrils. The muscle fibers branch and interdigitate, but each is a complete unit surrounding by a cell membrane.

Where the one muscle fiber abuts on another, the membranes of both fibers parallel each other through an extensive series of folds. These areas, which always occur at Z lines, are called intercalated disks. They provide a strong union between fibers, maintaining cell to cell cohesion, so that the pull of one contractile unit can be transmitted along its axis to the next. Along the sides of the muscle fibers next to the disks, the cell membranes of adjacent fibers fuse for considerable distances, forming gap junctions. These junctions provide low resistance bridges for the spread of excitation from one fiber to another. They permit cardiac muscle to function as if it were a syncytium, even though no protoplasmic bridges are present between cells. The T system in cardiac muscles is located at the Z lines rather than at the A-I junction, where it is located in mammalian skeletal muscle.

## **ANATOMY AND PHYSIOLOGY OF LUNG**

Lungs are paired organs of respiration. They are situated one on each side of the mediastinum within the thoracic cavity.

Shape: Each lung resembles a half cone. It has an apex, a base, 2 surfaces- medial and lateral and 3 borders- anterior, inferior and posterior.

Size: The right lung is broader than the left lung and weighs 22 ounce, whereas the left lung weighs 20 ounce.

Each lung is covered by pleural cavity. The pleura is a completely close serous sac which is invaginated from the medial side by the developing lung and as a result of this invagination it is converted into a double layered sac. There is an outer layer and an inner layer. The outer layer is called the parietal layer which lines the inner walls of the cavity in which the lung lies.

It is divided into diaphragmatic pleura, costal pleura, cervical pleura and cervical pleura depending on the region which it lines. The inner layer also called the pulmonary pleura or the visceral pleura is very closely adherent to the surface of the lung, dips into its fissures and is responsible for the shiny appearance of the surface of the lung. Pleural cavity is a space between the two pleura which is filled with a thin fluid of lymph-like fluid, it lubricates and prevents friction during movements of the lung.

Each bronchus on entering the hilum divides into branches which in turn divide repeatedly in the same manner. The tertiary branches are referred as the segmental bronchi.

The bronchus and its division are closely accompanied by the pulmonary artery and its branches. Each segmental bronchus and the accompanying division of the pulmonary artery supply a definite part of the lung and the veins are not segmental, but are intersegmental in position and functions. The bronchopulmonary segments are functionally independent units and each unit is surrounded by connective tissue which is continuous with that the visceral pleura.

Lung is supplied by pulmonary artery and bronchial artery and pulmonary and bronchial veins. The lymphatic drainage is via superficial and deep lymphatic system. Lung is supplied by anterior and posterior both sympathetic and para sympathetic pulmonary plexus.

## **HISTOLOGY AND DEVELOPMENT**

Thin alveolar septae separate the alveolar spaces. The septae are lined by thin flattened alveolar cells with a capillary network of blood vessels on



their wall. Electron microscopic studies show that the blood in the capillaries and the air in the alveoli are separated by a thin continuous layer of the alveolar epithelium and capillary endothelium with two layers of the basement membrane in between them. Many alveolar cells are phagocytic.

Each section of intrapulmonary bronchi will show (a) an outer fibrous coat with irregular plates of hyaline cartilage (b) middle bronchial muscles fibres and (c) inner mucous membrane which is headed by a layer of ciliated columnar epithelium, on its inner surface with lymphoid tissue, longitudinal elastic fibers and mucus secreting glands outer to the epithelium.

The terminal or respiratory bronchioles are about 3.2mm in diameter and have cartilages in their walls. Simple nonciliated cubical epithelium lines their lumen.

The respiratory passage first appears as a laryngotracheal groove in the floor of the primitive pharynx. The groove deepens, its margins fuse and a laryngotracheal tube is formed. Unfused cephalic end forms the inlet of the larynx. The caudal end of the tube divides and forms the lung buds. Each bud repeatedly divides dichotomously, 17 to 24 generations of divisions occur and these divisions form the alveoli respiratory bronchiole on the bronchi. The developing lung shows the four stages<sup>1</sup>. They are

- 1) Pseudoglandular stage
- 2) Canalicular stage
- 3) Terminal sac stage
- 4) Alveolar stage

The lining epithelia of the bronchi and alveoli are derived from the endoderm of the floor of pharynx. The connective tissue of the bronchi and the lung develop from the splanchnic mesoderm.

## **FUNCTIONS OF THE LUNG**

Ventilation, oxygenation, diffusion of carbon dioxide, elimination of inspired particles via mucociliary system, synthesis of pulmonary surfactant activation of angiotensin I to angiotensin II, inactivation of bradykinin, serotonin, histamine, acetylcholine, non adrenalin etc... and it act as a reservoir of blood.

## **HISTORY OF INFLAMMATORY MYOSITIS**

The characteristic 'heliotrope' rash of dermatomyositis was recognized before the disease itself in 1875, in a 17 year old waiter in Paris, France, who presented with fatigue, pain in the extremities and erythema of the eyelids. Eleven years later, in 1886, Wagner coined the term 'polymyositis' he described a women presenting with muscle weakness and diffuse muscle and joint pain who developed swelling of the extremities and forearm erythema. In 1888, the first American case of polymyositis documented by muscle biopsy was reported in New York. Because trichinosis was common at that time and could cause periorbital edema and diffuse myalgias, it was necessary that polymyositis or dermatomyositis be a diagnosis of exclusion, requiring an incompatible dietary history and a muscle biopsy lacking *Trichinella spiralis* cysts.

In 1891, Unverricht described a 39 years old pregnant women with facial erythema and tense, swollen and erythematous legs and thighs who later delivered a healthy infant. She subsequently developed myalgias with muscle weakness and atrophy and Unverricht<sup>3</sup> introduced the term 'dermatomyositis' to describe her condition. Although wagner and Unverricht are credited with the first descriptions of dermatomyositis, Unverricht noted that Virchow may have initially recognized the clinical features.

Steiner's<sup>4</sup> summary of myositis cases in 1903 made a clear distinction between idiopathic polymyositis and other forms of myositis caused by bacteria and parasites, and Stertz in 1916 first reported an association between dermatomyositis and internal malignancy. At about the same time, Batten described the first case of dermatomyositis with classic histologic features in a child.

In 1930, Gottron reported on the skin lesions of dermatomyositis that bear his name, describing rounded foci of tense atrophy over carpo-metacarpal joints.

The first published cases of dermatomyositis associated with carcinoma were independently reported in 1916 but Becezny, a Prague dermatologist, suggested a more definitive relationship between dermatomyositis and cancer on 1935.

Banker and Victor noted that dermatomyositis in children was different and involved a greater degree of vascular inflammation and thrombosis. More recently in 1967, the pathology of inclusion body myositis

was described and named in 1971. Prior to 1975 there were no generally accepted criteria for the diagnosis of myositis but Bohan and Peter proposed five criteria, in 1975 which are still used today. With the discovery of auto antibodies associated with the myositis syndromes, classification using serological features was later suggested.

## **EPIDEMIOLOGY**

The actual annual incidence of inflammatory myopathy is currently unknown. Because these disease are so rare, no large scale epidemiologic studies have been reported however several retrospective studies<sup>5</sup> have reported an annual incidence of fewer than 10 per million individuals.

These incidence, prevalence studies need to be interpreted cautiously, given that most have not reported confidence intervals for their rates.

The incidence of the various myopathies varies according to ethnicity, age and gender. Some studies have reported that the incidence of polymyositis is higher in black patients than in white patients. Idiopathic Inflammatory Myositis (IIM) can occur in any age group from early childhood to late in adult life. The onset of polymyositis is usually in the late teens or older, with the mean age at onset being 50 to 60 years; dermatomyositis shows to peaks 5 to 15 years and 45 to 65 years. Inclusion Body Myositis (IBM) is commonly seen in individuals older than 50 years and is rare in younger adults. In case of IIM (PM-DM) females are more commonly affected than males whereas in IBM the converse is true.

IIM can occur in association with other autoimmune connective tissue diseases like Systemic Sclerosis, Systemic Lupus Erythematosus (SLE),

Rheumatoid Arthritis (RA), Sjogren's Syndrome, Poly Arteritis Nodosa (PAN), and around 11% to 40% of all myositis patients have an associated connective tissue disease<sup>6</sup>.

## **CAUSE**

### ***Genetic factors***<sup>7</sup>

The occurrence of IIM in monozygotic twins and first degree relatives of cases supports a genetic predisposition, at least in some families. HLA genes implicated are HLA-DRB1\*0301, HLA-DQA1\*0501, HLA-DQB1\*0.01 which are associated with polymyositis and myositis specific auto antibodies.

In IBM, HLA B8, HLA DR3, HLA DR52, HLA DQ2 haplotype found in significant proportions. Some studies reported maternally derived chimeric cells are present in the peripheral blood and muscle tissue of juvenile dermatomyositis patients, suggesting that HLA association found in these disorders.

Non HLA genes implicated are Tumour Necrosis Factor- $\alpha$  (TNF- $\alpha$ ), interleukin-1 (IL-1), and Tumour Necrosis Factor Receptor-1 (TNFR-1), Complement Component (eg. C4, C2), immunoglobulin heavy chain allotypes and T cell receptors.

## **ENVIRONMENTAL RISK FACTORS**

### ***Infectious organisms***

Polio, coxsackie virus<sup>8</sup> type A and B, echoviruses, Retro viruses, HIV-I, HTLV-1, parvovirus B19, Hepatitis C Virus, Hepatitis C virus,

Hepatitis B virus, Staphylococci, Clostridia, Mycobacteria, Toxoplasma gondii, Trypanosoma Cruzi, Borrelia burgdogferi.

### *Non infectious agents*<sup>9</sup>

Drugs like steroids, chloroquine, statins, biological agents.

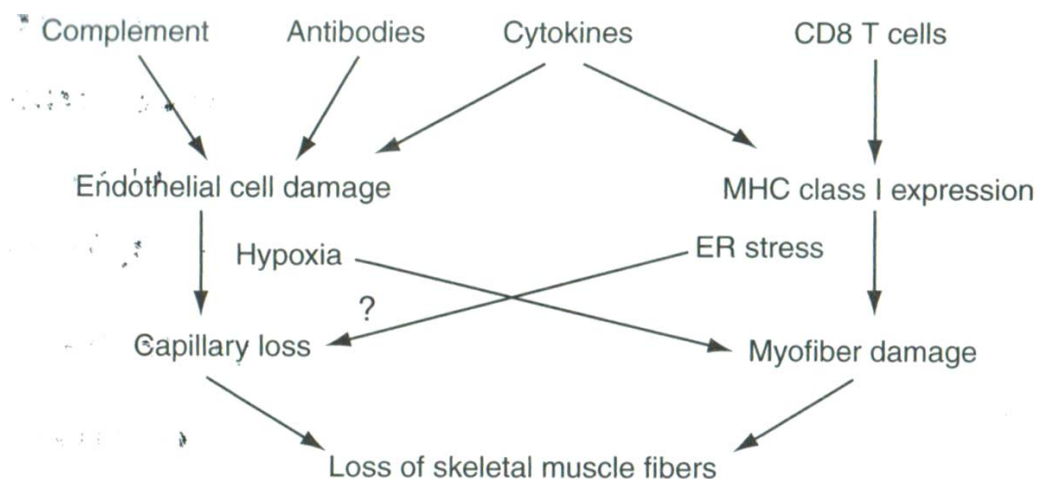
Vaccination for tetanus BCG, diphtheria, hepatitis B and A.

UV radiation exposure.

Miscellaneous agents like silicon breast implants, collagen injection, silica exposure, Chronic Graft Versus Host Disease (CVHD). Malignancy is an additional risk factor for the development of myositis and there is a strong association between dermatomyositis and malignancies.

## **PATHOGENESIS**

Immune and nonimmune pathways play a role in the disease pathogenesis. The magnitude and exact nature of the contribution of these pathways to disease initiation and progression are still unclear. Understanding the relative contribution of these pathways is important to design rational therapies for these disorder.



## *Mechanism of Muscle Fiber damage in Inflammatory Myositis*

### **ADAPTIVE IMMUNE MECHANISMS**

Inflammatory myopathies are classified as auto immune diseases<sup>10</sup> because of the following evidence.

- 1) Patient shows antibodies to specific auto antigens.
- 2) Presence of T cells in large infiltrates in muscle tissue.
- 3) Strong association with HLA DR genotypes.
- 4) Frequent association with other autoimmune diseases.
- 5) Favourable response to immunosuppressive and immunomodulatory therapies in some patients supports that these myopathies are autoimmune diseases.

### **HUMORAL IMMUNE RESPONSE**

- ❖ Up to 80% of the patients with polymyositis and dermatomyositis have positive antinuclear antibodies (ANA), some of these are specific to myositis and others not specific to but associated with myositis (anti-SnRNP, anti-Ro/SSA, Anti-Ku, and anti-PMS1).
- ❖ Some of these antibodies are associated with distinct clinical features of the disease (ex. anti-Mi-2, antibodies show very strong association with dermatomyositis with prominent features like gottron papules, heliotrophe rash, the V sign and shawl sign were as most frequent myositis specific autoantibodies the aminoacyl t-RNA synthatases associated with another distinct clinical entity named anti-synthatase

syndrome with features including mechanic hands<sup>11</sup>, Raynauds phenomenon, myositis, interstitial lung disease, non erosive arthritis. To date 8 different anti synthetase autoantibodies have been identified of which anti-histidyl-tRNA synthetase auto antibodies of the most frequent. The most common shared clinical features of these auto antibodies are occurrence of ILD.

- ❖ The role of B cells<sup>12</sup> in the pathogenesis of polymyositis and dermatomyositis is supported by the presence of B cells and plasma cell infiltrates in the muscles tissue and scripts in the muscle tissue of patients with myositis. Analysis of the variable regions gene sequences revealed clear evidence of significant somatic mutation, isotypes switching, receptor revision, codon insertion/ deletion, and oligoclonal expansion, suggesting that affinity maturation had occurred within the B-cell and plasma cell populations in the muscles tissue. Antigens localized to the muscle might drive a B-cell antigen specific response in myositis and these antigen could be autoantigens or exogenous cross reactive antigens derived from viruses or other infectious agents.
- ❖ There is a differential organ expression of these antigens were by histidyl- t-RNA synthetase has higher expression in the epithelial cells of the bronchi than in other healthy organs, which might suggest that autoimmunity to this antigen is initiated and propagated in the lung. There is an upregulation of Mi2 antigens and histidyl t-RNA synthetase in the regenerating muscle fibers which suggest that muscle fibers may become potential targets of the immune system after trauma. There is



an abnormal modulation of the muscle environment which leads to muscle dysfunction.

- ❖ Anti Jo-1 antibodies<sup>13</sup> have a type-I interferon- inducing capacity, higher expression of intercellular adhesion molecules, microvascular endothelial cells of lungs activate and facilitate homing of inflammatory cells into tissues. There is also associated high serum levels of D-cell activating factor.

## **CELL MEDIATED IMMUNE RESPONSE**

Two different pattern of distribution, location and type of lymphocyte subsets in the muscle tissue suggesting two different pathways.

- 1) CD4+ T lymphocytes, Macrophages, B-lymphocytes, Plasma cells and Dendritic cells predominantly in perivascular and perimysial areas of tissue which is mainly but not exclusively found in patient with dermatomyositis.
- 2) CD8 + T and CD4 +T lymphocytes, macrophages and dendritic cells predominantly in an endomysial distribution with inflammatory cells some times invading non necrotic muscle fibers. This pattern is found mainly in patients with myositis without skin rash and polymyositis.
- 3) Vascular involvement in patients with dermatomyositis clearly manifested in the skin can be clinically seen in the form of capillary nail fold changes. The capillary changes and damages are attributed to complement deposition. There is thickening, dropout, decrease in

number, hyperplasia and necrosis of the capillaries that could contribute to an ischaemia inturn to cause muscle fiber damage.

- 4) Endomysial inflammatory infiltrates contain high percentage of activated CD 8+ T lymphocytes, CD 4+ T lymphocytes, macrophages and CD 28 null T cells with up regulation of perforin<sup>14</sup> expressing cytotoxic T cells oriented towards the muscle fibers.

## **INNATE AND NON IMMUNE MECHANISMS**

Effector molecules that are produced by muscle fibers, inflammatory cells and endothelial cells thought to contribute to the pathogenesis of myositis. Proinflammatory cytokines such as IL-1 Alpha, IL-1 Beta, TNF Alpha, Interferon Alpha and Beta, HMGB1 and chemokines like CXCL9, CXCL10 and the beta - chemokines CCL2, CCL3, CCL4, CCL4, CCL19 and CCL21 are present in the muscle tissue of patients with polymyositis and dermatomyositis. These molecules may amplify the immune response, alter the muscle micro environment and causes direct muscle fiber dysfunction.

- ❖ IL-1 alpha and HMGB-1 cytokines consistently found in patients with persisting muscle weakness, expression of mPGES-1 and COX-1 remained unchanged, indicating a role of these enzymes in the chronicity of polymyositis and dermatomyositis.
- ❖ Type-1 Interferon system has got an ability to break tolerance, and correlates with MHC class-I expression in the muscle fibers causing muscle dysfunction.

- ❖ HMGB1<sup>15</sup> protein is an ubiquitous nonhistone molecule present in all nucleated cells. Extranuclear HMGB1 may have proinflammatory properties and may also have a function in muscle cell regeneration. HMGB1 can induce a reversible upregulation of MHC class-I in the muscle fibers, may cause an irreversible decrease in Ca<sup>2+</sup> release in the sarcoplasmic reticulum has a direct negative effect on muscle fiber contractility. Thus HMGB1 may be an early inducer of skeletal muscle dysfunction in inflammatory myositis.
- ❖ Hypoxic symptoms and muscle fatigue in patients with myositis may be due to muscle tissue hypoxia, reduced level of energy substrates, acquired metabolic disturbances producing impaired performance.
- ❖ MHC Class-1 expression and muscle fibers: MHC class-I molecules are known to play a critical role in initiating and perpetuating antigen-specific immune responses by presenting antigenic peptides to CD8+ T lymphocytes and by regulating the activities of NK cells.
- ❖ In normal differentiated skeletal muscle cells, MHC class-I is either absent or expressed at low levels; however, they can be promptly induced by proinflammatory cytokines, for example interferon alpha or TNF alpha.
- ❖ The mouse model<sup>16</sup> of myositis suggested that MHC class-I molecules themselves may potentially mediate muscle fiber damage and dysfunction through innate and nonimmune mechanisms in the absence of lymphocytes, like attenuation of muscle regeneration and

differentiation, muscle atrophy and an intrinsic decrease in force generating capacity.

- ❖ Over expression of MHC class-I muscle fibers of patients with myositis and the transgenic mouse model of myositis results in activation of the Nuclear Factor Kappa-B (NFκB) and Endoplasmic Reticulum (ER) stress response pathways.
- ❖ MHC class-I expression in the skeletal muscle links the classic immune and nonimmune mediated mechanisms of muscle impairment and damage. Altered redox state of sarcoplasmic reticulum leads to activation of unfolded protein response and myopathy in people with Hexose-6-Phosphate Dehydrogenase (H6PD) deficiency.

## **IMMUNOLOGIC ABNORMALITIES IN PATIENTS WITH INFLAMMATORY MYOPATHIES**

### *Cellular Abnormalities*

T Cell receptor restriction in inflamed muscle

Activated T and B lymphocytes expressing co-stimulatory molecules:  
CD86/ CD80 CD28/CTLA4; CD40/CD4OL in skeletal muscle

Increased peripheral mononuclear cell trafficking to muscle

Increased proportions of peripheral T and B lymphocytes bearing activation markers

Type I interferon gene expression in muscle tissue and peripheral blood of dermatomyositis and polymyositis patients

High expression of proinflammatory cytokines and chemokines in muscle tissues like IL-1a, IL-1, TNF, HMGB-1, VEGF, MIP-I alpha)

Elevated serum IL-1a, IL-2, soluble IL-2 receptors and soluble CD8 receptors

Decreased proliferative responses of peripheral mononuclear cells to T-cell mitogens

Increased proliferative responses of peripheral mononuclear cells to autologous muscle

Increased expression of cytokines and chemokines in infiltrating mononuclear cells and muscle cells

Increased expression of MHC class I (HLA-A,B,C), class II (HLA-DR), and ICAM-1 in skeletal muscle fibers.

## **HUMORAL ABNORMALITIES IN MYOSITIS ARE**

- Immunoglobulin and complement deposition in vascular endothelium of muscle.
- Myositis-specific autoantibodies
- Myositis-associated autoantibodies (anti-U1 RNP, anti-PM/Scl, anti-Ku)
- Other-autoantibodies (antithyroid, anti-Sm, anti-Ro, anti-La, etc.)
- Hyper-, hypo-, and agammaglobulinemia
- Monoclonal gammopathy

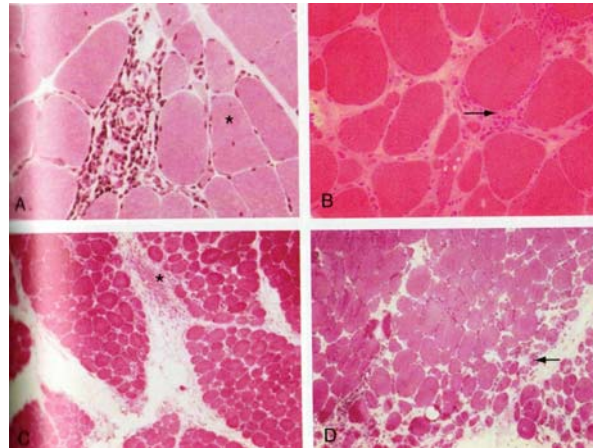
## **MUSCLE HISTOPATHOLOGY<sup>17</sup>**

Characteristic histopathologic signs in patients with inflammatory myopathies are presence of mononuclear inflammatory cell infiltrates in muscle tissue and degenerating, necrotic fibers, as well as regenerating muscle fibers. Atrophy of muscle fibers in a perifascicular fashion is mainly found in patients with dermatomyositis, often in a later phase of disease. In inclusion body myositis, rimmed vacuoles are characteristic features that can be seen in a light microscope nuclear or cytoplasmic inclusions are mainly detected by electron microscopy. None of these biopsy features is pathognomonic for myositis but may also occur in other disorders, and they are not directly linked to muscle function. Importantly, these histopathologic features are often focal and in some cases a muscle biopsy can look normal despite clinically evident muscle weakness. Furthermore, the degree of histopathologic features is not correlated with the degree of muscle weakness. The focal feature of inflammation is also observed by magnetic resonance Imaging (MRI), which can detect inflammation as a bright signal using the Short Tau Inversion Recovery (STIR) sequence. The reasons for this heterogeneity of muscle inflammation are not known, but the heterogeneity suggests that not only does immune-mediated muscle fiber damage cause impaired muscle function but that other mechanisms are also important, as discussed next.

## **IMMUNOPATHOLOGY**

Careful characterization of human muscle tissue from patients with myositis using immunohistochemistry has revealed that there is a tendency for different lymphocyte subsets to accumulate in different regions of the muscle,

suggesting that there are different targets for the immune reaction. The pattern of distribution of inflammatory cells also tends to relate to different clinical subsets of myositis.



***Hematoxylin and eosin staining of muscle biopsy showing perivascular inflammation. A, Variation in fiber size and central nucleation (star). B, Endomysial inflammation and increased fibrosis. C, Perimysial inflammation (star). D, Perifascicular atrophy (arrow).***

Basically two different patterns of inflammatory cell infiltrates are found in muscle tissue of adult inflammatory myopathies. One is predominantly localized to the endomysium, composed mainly of CD8 and CD4 T cells, macrophages, and dendritic cells. In some cases the infiltrates surround and seem to invade non-necrotic muscle fibers. This feature is predominantly seen in polymyositis and inclusion body myositis. The other pattern has a perivascular and perimysial localization and is composed mainly of CD4 T cells, macrophages, dendritic cells, and B cells. This is seen predominantly in dermatomyositis cases. These different immunohistopathologic features suggest that different pathogenic mechanism could be involved in the different subsets of myositis with a predominance of T cell-mediated muscle fiber damage in polymyositis and inclusion body myositis and a role of the microvessel damage in dermatomyositis. However, these changes are not

strictly related to presence or absence of skin rash. Moreover, in many patients the inflammatory cellular infiltrates are sparse and do not correlate to the degree of muscle symptoms, suggesting that other components of the immunopathology of inflamed muscle are also important for the disease. In contrast, the tissue distribution of signaling molecules produced in inflamed muscle tissues such as cytokines and chemokines does not seem to differ between subsets of myositis, indicating that some molecular mechanisms may be shared by different subsets of myositis.

Another feature of inflamed muscle tissue is expression of MHC class I and II molecules in muscle fibers, which normally do not express these antigens. MHC class I antigen expression is present in a majority of myositis patients both on regenerating fibers and on otherwise histopathologically normal-appearing muscle fibers. The MHC class I expression is localized to the muscle fiber membrane and often diffusely spread within the sarcoplasm. Furthermore, the MHC class I and class II expression on muscle fibers has been observed even in the absence of inflammatory cell infiltrates. The MHC class II molecules are less consistently expressed, mainly on scattered muscle fibers. The mechanisms by which MHC class I and class II expression are induced on muscle fibers *in vivo* have not been clarified, but from *in vitro* studies it has been demonstrated that proinflammatory cytokines or chemokines may induce MHC class I and class II expression on cultured muscle cells. These include cytokines that have been detected in inflamed muscle tissue such as IFN- $\alpha$  and IL-1 $\alpha$  and 3, and TNF- $\alpha$ . A possible role of the induced MHC class I on muscle fibers in the disease mechanisms of myositis is discussed previously. The MHC class I expression on muscle fibers, although not specific for myositis, could be helpful in diagnostic evaluation for distinction from normal muscle.



# **CLASSIFICATION OF INFLAMMATORY MYOSITIS**

## **DESCRIPTIONS**

- ❖ Pure polymyositis (PM)
- ❖ Pure dermatomyositis (DM)
- ❖ Overlap myositis (OM): myositis with at least one clinical overlap feature or an overlap autoantibody
- ❖ Cancer-associated myositis (CAM): clinical paraneoplastic features without an overlap autoantibody or anti-Mi-2

## **BOHAN AND PETER DEFINITION OF MYOSITIS<sup>18</sup>**

- 1) Symmetric proximal muscle weakness
  - 2) Elevation of serum skeletal muscle enzymes
  - 3) Electromyographic triad of short, small, polyphasic motor unit potentials; fibrillations, positive sharp waves, and insertional irritability; and bizarre, high-frequency repetitive discharges
  - 4) Muscle biopsy abnormalities of degeneration, regeneration, necrosis, phagocytosis, and interstitial mononuclear infiltrate
  - 5) Typical skin rash of DM, including heliotrope rash, Gottron's sign, and Gottron's papules
- Definite myositis: 4 criteria (without the rash) for PM; 3 or 4 criteria (plus the rash) for DM  
Probable myositis: 3 criteria (without the rash) for PM; 2 criteria (plus the rash) for DM  
Possible

myositis: 2 criteria (without the rash) for PM; 1 criteria (plus the rash)  
for DM

## **DEFINITION OF CLINICAL OVERLAP FEATURES**

Inflammatory myopathy plus at least one or more of the following clinical findings: polyarthritis, Raynaud's phenomenon, sclerodactyly, scleroderma proximal to metacarpophalangeal joints, typical SSc-type calcinosis in the fingers, lower esophageal or small-bowel hypomotility, DLCO lower than 70% of normal predicted value, interstitial lung disease on chest radiograph or computed tomography scan, discoid lupus, anti-native DNA antibodies plus hypocomplementenemia, 4 or more of if American College of Rheumatology criteria for systemic lupus erythematosus, antiphospholipid syndrome.

## **DEFINITION OF OVERLAP AUTOANTIBODIES**

Antisynthetases (Jo-1, PL-7, PL-12, OJ, EJ, KJ), scleroderma-associated autoantibodies (scleroderma-specific antibodies: centromeres, topoisomerase I, RNA polymerases I or III, Th; and antibodies associated with scleroderma overlap: U1 -RNP, U2-RNP, U3-RNP, U5-RNP, Pm-SCL, Ku, and other autoantibodies (signal recognition particle, nucleoporins)

## **DEFINITION OF CLINICAL PARANEOPLASTIC FEATURES**

Cancer within 3yrs of myositis diagnosis, plus absence of multiple clinical overlap features; plus, if cancer was cured, myositis was cured as well.

# **CLINICAL FEATURES OF INFLAMMATORY MYOSITIS**

## **PRESENTATION**

The most frequent symptom is insidious progressive and painless symmetric proximal muscle weakness over the course of 3-6 months before the first visit to a physician. The present features of the different myositis symptoms vary considerably from patient to patient.

## **CONSTITUTIONAL**

Fever, weight loss, fatigue, loss of appetite.

## **SKIN**

Gottron papules – violaceous flat-topped papules and plaques located over the dorsal aspect of interphalangeal or metacarpophalangeal joints. Over time, these papules may evolve and develop atrophic, depressed, white centers with prominent telangiectasias.

Heliotrope rash<sup>19</sup>, periorbital edema, V sign, Shawl sign, Gottron sign, mechanic hands, nail fold telangiectasias, cuticular overgrowth, periungual erythema, pleuritis, calcinosis. Rare findings like nonscarring alopecia, erythroderma, vesiculobullous lesion, leukocytoclastic vasculitis, and livedoreticularis, flagellate erythema, poikiloderma, digital ulcers, palpable purpura, urticaria like lesions, livedoreticularis, hyperkeratotic follicular erythematous papules (pityriasis rubra pilaris), cutaneous vasculitis.

## CARDIAC MANIFESTATIONS

Cardiac involvement in myositis was first described by Oppenheim<sup>20</sup> in 1899. Historically, it was believed that myositis spared the heart. However, based on autopsy studies, it has become evident that cardiac involvement, although usually asymptomatic, is more common than previously believed<sup>21</sup>. Cardiac involvement is a major cause of mortality in patients with myositis. In a long-term follow-up study, cardiovascular involvement was found to be the most common cause of death in patients with myositis.

The myocardium has been reported to be affected in patients with DM with varying frequencies. Up to 50% of patients with DM evaluated by noninvasive studies have asymptomatic cardiac manifestations. Noninvasive studies have shown that up to 85% of patients have abnormal findings on electrocardiography, 77% on ambulatory monitoring, 42% on echocardiography, and 15% on radionucleotide ventriculography.

Cardiac manifestations included arrhythmia, conduction abnormalities, cardiac arrest, Congestive Heart Failure (CHF), myocarditis, pericarditis, angina, and secondary fibrosis.

The frequency of cardiac involvement in myositis has been reported between 6% and 75%<sup>22</sup>. Cardiac involvement as a cause of death in PM has been reported between 10% and 20%, although this number is uncertain because large studies are unavailable.

Conduction abnormalities are the most common asymptomatic cardiac manifestation, which are observed in 32% to 72% of patients. These abnormalities include ST-T changes, bundle branch block, atrioventricular

blocks, PR prolongation, Q-wave abnormalities, and arrhythmias. In some cases, patients require pacemaker placement.

Arrhythmias and Congestive Heart Failure (CHF) secondary to myocarditis rarely occur in patients with acute disease. In chronic DM, heart failure is seen more frequently and is the most common symptomatic manifestation. The frequency of CHF has been reported to be 3% to 45% in patients with myositis. In chronic DM, heart failure has been attributed to the effects of long-standing hypertension secondary to steroid use. It has also been theorized that the cause of CHF is secondary to myocarditis, leading to left ventricular dysfunction and restrictive cardiomyopathy, or possibly because of fibrosis, resulting in chamber stiffness. It is thought that myocardial involvement resulting in myocarditis occurs by the same mechanism that results in skeletal muscle involvement. Mononuclear inflammatory cells infiltrate into the endomysium and peri-vascular areas, resulting in degeneration of cardiac myocytes. Histopathologic changes similar to those in the myocardium were also observed in the conduction system, which could explain the cause of heart block.

Angina secondary to Raynaud phenomenon, Prinzmetal angina, and small vessel disease has also been reported in patients with DM. Pericardial tamponade is very rare, with a frequency reported at about 10%. However, because tamponade can be fatal, electrocardiography of every case is recommended. Clinically symptomatic cardiac involvement is uncommon, and when present, it is associated with a poor prognosis.

There have also been reported associations between cardiac involvement and anti - signal recognition particle (SRP) antibodies. However, more recent evidence suggests that anti-SRP antibodies may not contribute to cardiac involvement to the degree that was once suspected.

## **PULMONARY MANIFESTATIONS**

Pulmonary complications are a major cause of morbidity and mortality in patients with PM and DM. These complications occur primarily or secondarily due to muscle weakness. Three distinct pulmonary complications of PM and DM have been described: hypoventilation, aspiration pneumonia, and ILD.

Respiratory failure due to hypoventilation has been historically thought to be a rare complication reported in less than 5% of patients with myositis. However, a more recent, larger, retrospective study of patients with DM and PM reported a higher prevalence of Hypoventilation occurs in patients with severe muscle weakness and inflammation, involving respiratory muscles. As a result, restrictive lung function impairment is noted on pulmonary function tests (PFTs). Patients are noted to have reduced lung volumes and maximal inspiratory and expiratory pressures, along with increased residual volumes and normal forced expiratory volume in the end of the first second of forced expiration to forced vital capacity (FVC) ratio. Chest radiographs reveal small lung volumes and basal atelectasis.

Aspiration pneumonia is a frequent complication of PM and DM, occurring in approximately 17% of patients. Patients suffering from aspiration pneumonia also frequently complain of dysphagia, which results from disease involvement of the striated muscles of the pharynx and upper esophagus.

Aspiration pneumonia is more likely to occur in patients with more extensive muscle and skin disease.

ILD is an inflammatory lung disorder of unknown cause, characterized by infiltrates of monocytes, lymphocytes, and neutrophils, as well as interstitial fibrosis. ILD is a common complication in PM and DM. The incidence of ILD has been reported between 5% and 46% in cross-sectional studies<sup>23</sup>. No significant difference in the prevalence of ILD exists between patients with PM and DM. ILD associated with myositis may occur before, concomitantly, or after the onset of skin or muscle symptoms. ILD associated with Amyopathic Dermatomyositis (ADM) is a distinct subset in which the lung disease is rapidly progressive.

Myositis-associated ILD occurs in 3 different patterns: (1) acute onset of symptoms, in which patients develop apparent progressive hypoxemia within a month of lung involvement; (2) chronic slowly progressive symptoms; and (3) asymptomatic progression, in which ILD is demonstrated only by abnormal results of chest imaging or PFT.

Cough and dyspnea are the most frequently reported symptoms in ILD, although patients can be asymptomatic. In one study, 27% of patients with ILD were asymptomatic<sup>24</sup>. Pulmonary Function Tests (PFT) demonstrate a restrictive ventilatory impairment and can show decreased total lung capacity, functional residual capacity, residual volume, FEV1, and FVC, with a normal or elevated FEV1/FVC ratio and reduced diffusing capacity of lung for carbon monoxide.

Although chest radiography is a useful screening test, High-Resolution Computed Tomography (HRCT) of the lungs is the standard technique for detecting ILD. HRCT is thought to be useful in distinguishing fibrotic disease from active inflammation, with the former presenting as a reticular pattern and the latter as ground-glass pattern.

Bronchoalveolar Lavage (BAL) is not specific for the diagnosis of Interstitial Lung Disease (ILD), although it is useful in differentiating pulmonary symptoms, such as evaluating for infection, drug-induced reaction, and malignancy<sup>25</sup>. However, similar to idiopathic pulmonary fibrosis, neutrophil-predominant alveolitis and increased eosinophil counts may indicate more progressive disease. Lung biopsy is not routinely performed for diagnosis because of the increased morbidity associated with the procedure.

Most frequently seen HRCT changes are those of idiopathic nonspecific interstitial pneumonia (NSIP), with irregular linear opacities and with areas of consolidation and ground-glass pattern. However, other patterns such as usual interstitial pneumonia, bronchiolitis obliterans with organizing pneumonia, and diffuse alveolar damage (DAD) are also seen.

The presence of anti-aminoacyl-transfer RNA (tRNA) synthetase antibodies, of which anti-histidyl-tRNA synthetase antibody (anti-Jo-1) is most frequently found, is the strongest predictive marker for ILD.” The prevalence of ILD with anti-Jo-1 antibodies is more than 70%. There are also other markers for ILD, including PM-Scl autoantibodies, Krebsvonden Lungen 6, a glycoprotein expressed on type 2 alveolar pneumocytes and bronchiolar epithelial cells, and serum surfactant protein D have been



suggested as useful markers for ILD in patients with myositis. However, these markers are not routinely used in clinical practice. Serum cytokeratin (CK) 19 fragment, a component of bronchoepithelial cells, is also associated with ILD in myositis. Patients with DAD have higher levels of CK-19 than patients with NSIP.

ILD is considered a major risk factor for premature death. It is unclear if the prognosis of ILD in patients with PM is different from those with DM. However, one study showed that patients with DM-associated ILD were less responsive to steroid therapy than those with PM-associated ILD.

Spontaneous pneumomediastinum has also been reported as a rare complication of myositis-associated ILD, occurring with a prevalence of 8.3% in patients with PM and DM. Pneumomediastinum usually results from rupture of subpleural or paracardial blebs in ILD. In a recent retrospective study, most cases of pneumomediastinum occurred in patients with DM or ADM. Poor survival was associated with an absence of muscle weakness and severe pulmonary involvement before the onset of pneumomediastinum.

Because of the concomitant use of immunosuppressive drugs in the treatment of inflammatory myopathies infections are another complication to be considered, particularly opportunistic infections. Bronchoalveolar lavage is a useful tool in making the diagnosis.

## **SKELETAL MUSCLE**

The myositis patient complain of difficulty in performing activities requiring normal upper or lower limb strength. The onset is insidious, bilateral, symmetrical and patients, with involvement of proximal more than

distal muscles. An exception is IBM, in which asymmetric distal weakness and atrophy are as prominent as proximal muscle findings. Lower extremity is often affected initially, followed by upper extremity, neck flexor weakness. Patient may have proximal dysphagia with nasal regurgitation of liquids and pulmonary aspiration is a poor prognostic sign seen with severe disease. There will be reduction in aerobic and anaerobic capacity of muscle. Ocular or facial muscle weakness is uncommon.

## **JOINTS**

Polyarthralgia, polyarthritis are relatively mild. Joint findings are more common with overlap and anti-synthetase syndrome.

## **GASTROINTESTINAL TRACT**

Patient will have pharyngeal muscle weakness which result in dysphonia, difficulty in initiation of deglutition<sup>26</sup> or nasal regurgitation of liquids. If severe, aspiration of oral contents will occur. Patient may have retrosternal sticking sensation on swallowing bread or meat and heartburn. Patient may have small bowel involvement in the form of bloating, distension, watery diarrhea. GI ulceration can occur. Other manifestations are ascitis, total gut failure, pneumatosis cystoides intestinalis.

## **VASCULAR SYSTEM INVOLVEMENT**

Patient may have Raynauds phenomenon, tender dermal subcutaneous nodules, periungual infarcts and digital ulcerations.

## **RENAL INVOLVEMENT**

Renal disease is unusual in myositis, but there are reports of (IgA) nephropathy, membranous nephropathy, rhabdomyolysis with renal failure, Acute Tubular Necrosis (ATN) with renal failure due to myoglobinuria is also reported.

## **MISCELLANEOUS**

People may have macroglossia, dental caries, hyposalivation, retinopathy or retinal vasculitis, subcutaneous edema, hemophagocytic syndrome, it is rarely associated with thyroid disorders, CNS vasculitis, progressive multifocal leukoencephalopathy.

## **OVERLAP SYNDROMES**

Overlap syndromes associated with idiopathic inflammatory myositis are SLE, systemic sclerosis, MCTD, Rheumatoid arthritis etc...

## **INVESTIGATIONS**

- ❖ Complete blood count (Hb, TC, DC, ESR)
- ❖ Liver function test (SGOT, SGPT, Bilirubin)
- ❖ Renal Function Test (Blood Urea, Serum Creatinine)
- ❖ Urine routine examination
- ❖ Serum muscle enzymes (CPK, Aldolase, aspartrate, alanine amino transferases and lactate dehydrogenase)
  - Muscle Enzymes: Enzymes that leak from the injured muscle into the serum are valuable aids in detecting ongoing muscle injury.

Elevated CK and ALT provide evidence that ALT elevation may be of muscle origin than hepatic origin.

- Serum CK is the most reliable enzyme test to use in routine patients care and predicts clinical events. During a flare of disease, the serum CK will usually increase weeks before over muscle weakness develops. There is an ethnic difference in the rise of serum muscle enzymes following myositis.
- Measurement of urinary levels of muscle damage markers like creatine, betain and citrate, may be useful.

## **ELECTROMYOGRAPHY (EMG)**

Electrical testing<sup>27</sup> is a sensitive but non specific method of evaluating muscle inflammation. EMG may be helpful to diagnose myositis in the circumstance of normal serum enzyme concentration and the physical examination of muscle strength that is difficult to interpret.

EMG findings suggestive of myopathic pattern are irritability of myofibrils at rest, positive sharp waves, short, low amplitude, polyphasic, potentials, complex repetitive discharges, loss of spontaneous activity, fibrillary waves etc.

## **MUSCLE BIOPSY**

Biopsy remains the gold standard for confirmation of the diagnosis of inflammatory myopathy. Some patients with active myositis have a normal biopsy for several reasons like wrong muscle, patchy disease and wrong technique. Various techniques available are open surgical biopsy,

percutaneous needle muscle biopsy. Open muscle biopsy is preferred over the needle biopsy because it provides a larger sample. Ideally we have to select a moderately weak muscle which is often best located by EMG testing of the contralateral side in combination with magnetic resonance imaging guided biopsy to provide the highest degree of accuracy. The characteristic findings are regeneration and degeneration of myofibrils, chronic inflammatory cells in the perivascular and interstitial areas surrounding myofibrils are present in 80% of cases, but lymphocytic invasion of non necrotic fibers is considered pathognomonic of polymyositis. Besides lymphocytes, other cells may be present, including histiocytes, plasma cells, eosinophils, and polymorphonuclear leukocytes. In chronic myositis, macrophages are seen phagocytosing necrotic fibers and muscle is replaced by fibrous connective tissue or fat.

In dermatomyositis B cells, T cells mostly CD8+ predominate in the perivascular area. CD4+T cells are also found. Perifascicular myofibril atrophy, endothelial cell hyperplasia of blood vessels, deposition of immune complexes in the vasculature, muscle capillary depletion and dropout may be seen. In contrast, the polymyositis T cell invasion of myofibrils with relative sparing of the perimysial areas but unlike DM, B cells are rarely observed.

## **SERUM ANTIBODIES**

- 1) ENA Profile, ANA by ELISA, ANA by Hep 2
- 2) Autoantibodies in IIM

## AUTO ANTIBODIES IN IIM

Antibody	Antigen	Clinical Manifestation
<i>Myositis-specific autoantibodies</i>		
<i>Antisynthetase autoantibodies</i>		
Anti-Jo-1	Histidyl-tRNA synthetase	PM, DM + ILD
Anti-PL-7	Threonyl-tRNA synthetase	PM, DM + ILD
Anti-PL-12	Alanyl-tRNA synthetase	ILD>myositis <sup>a</sup>
Anti-EJ	Glycyl-tRNA synthetase	PM>DM + ILD
Anti-OJ	Isoleucyl-tRNA synthetase	ILD + PM/DM
Anti-KS	Asparaginyl-tRNA synthetase	ILD>myositis <sup>a</sup>
Anti-Zo	Phenylalanyl-tRNA synthetase	ILD + myositis <sup>a</sup>
Anti-Ha	Tyrosyl-tRNA synthetase	ILD + myositis <sup>a</sup>
<i>Nonsynthetase autoantibodies</i>		
Anti-SRP	SRP	Severe, acute, resistant necrotizing myopathy
Anti-Mi-2	DNA helicase	DM with rash > muscle symptoms, treatment responsive
Anti-HMGCR (anti-200/100)	HMGCR	Necrotizing myopathy related to statin use in majority; most patients are statin exposed, but myopathy also reported in a minority of statin-naive patients
Anti-MDA5 (anti-CADM 140)	MDA5	DM: CAM, DM with rapidly progressive lung disease, pneumomediastinum
Anti-155/140	Transcriptional intermediary factor 1 $\gamma$	CAM
Anti-140	Nuclear matrix protein (NXP-2)	JDM
Anti-SAE	SAE	DM: CAM, DM with rapidly progressive lung disease, pneumomediastinum
<i>Myositis-associated autoantibodies</i>		
PM-Scl	Unidentified	PM or DM/SSc overlap
U1RNP	U1 small RNP	Mixed connective tissue disease (overlap syndrome)
Non-U1 snRNPs	U2, U4/6, U5, U3 snRNPs	PM or DM/SSc or SSc overlap
Ku	DNA-binding proteins	Myositis <sup>a</sup> /SSc/SLE overlap
Ro (SS-A), includes Ro60 and Ro52	RNA protein	Myositis often with SS or SLE, may be associated with ILD (especially Ro52)
56 kDa	RNP particle	Myositis, often with Jo-1
KJ	Unidentified translation factor	PM, ILD, RP
Fer	Elongation factor 1a	Myositis
Mas	tRNA <sup>Ser</sup> -related antigen	Myositis, rhabdomyolysis, chronic hepatitis
MJ	Unidentified nuclear pore	JDM
hPMS1	Protein related to DNA repair	Myositis

## **HRCT LUNG**

The chest radiograph is insensitive in the diagnosis of ILD. HRCT scan using 1mm slices will have a better resolution and will assist in the early diagnosis of lung changes in IIM. HRCT findings consist with the inflammation include ground glass opacities, nodules and consolidation while features more consistent with fibrosis and damage include traction bronchiectasis and honeycombing. Subpleural lines or bands and linear opacities are not definitely associated with either inflammation or fibrosis.

## **PULMONARY FUNCTION TEST**

### ***Broncho Alveolar Lavage***

Instillation of 120ml of saline into distal airspaces through the wedged bronchoscope and then aspirated through the instrument's suction channel. Fluid collected is subjected to microbiology testing, specific cytologic analysis and cell counts and other parameters. BAL is not specific for the diagnosis of ILD, although it is useful in differentiating pulmonary symptoms, such as evaluating for infection, drug-induced reaction, and malignancy. In inflammatory myositis with ILD contains predominantly lymphocytes, neutrophils and eosinophils are high in severe progressive disease.

## **PULMONARY FUNCTION TEST**

Pulmonary function tests are used to assess the disorders of lung. Cough and dyspnea are the most frequently reported symptoms in ILD, although patients can be asymptomatic. In one study, 27% of patients with ILD were asymptomatic PFTs demonstrate a restrictive ventilatory impairment and can

show decreased total lung capacity, functional residual capacity, residual volume, FEV1, and FVC, with a normal or elevated FEV1/FVC ratio and reduced diffusing capacity of lung for carbon monoxide.

## **ELECTROCARDIOGRAM**

In inflammatory myositis common ECG abnormalities are non specified ST T wave changes, conduction abnormalities etc...

## **ECHOCARDIOGRAM**

To diagnose cardiac involvement like valvular abnormalities, serositis, LV dysfunction etc.,

Other imaging modalities are Doppler, MRI Imaging of muscles to look for muscle inflammation.



## **MATERIALS AND METHODS**

The study was conducted in the Department of Rheumatology, Madras Medical College, Chennai-3 from February 2011 to January 2012, after ethical committee clearance. Total number of patients included in the study is 50 who fulfill inclusion criteria. All these patients were subjected to clinical examination, CBC, RFT, LFT, CRP, RF, Muscle enzymes (CPK, LDH, SGOT, SGPT) ECG, ECHO, PFT, HRCT Lung, CXR, Broncho Alveolar Lavage (BAL), auto antibody profile (ANA, ENA Profile), muscle biopsy, ultra sound abdomen and EMG studies.

### **STUDY DESIGN: CROSS SECTIONAL STUDY**

#### **INCLUSION CRITERIA**

- 1) Patients fulfilling Bohan & Peter criteria for idiopathic inflammatory myositis.
- 2) Patients with overlap syndromes presenting with inflammatory myositis.

#### **EXCLUSION CRITERIA**

- 1) Features of congenital myopathy
- 2) Features of metabolic myopathy
- 3) Features of Drug induced myopathy
- 4) Features of Endocrine myopathy
- 5) Features of muscular dystrophy
- 6) H/o. Pulmonary TB in the past
- 7) H/o. Diabetes Mellitus
- 8) H/o. Exposure to irradiation to body

**CONFLICT OF INTEREST:** Nil

**STATISTICAL METHOD USED:** SPSS V-19 (Statistical Package for Social Sciences) & Manual

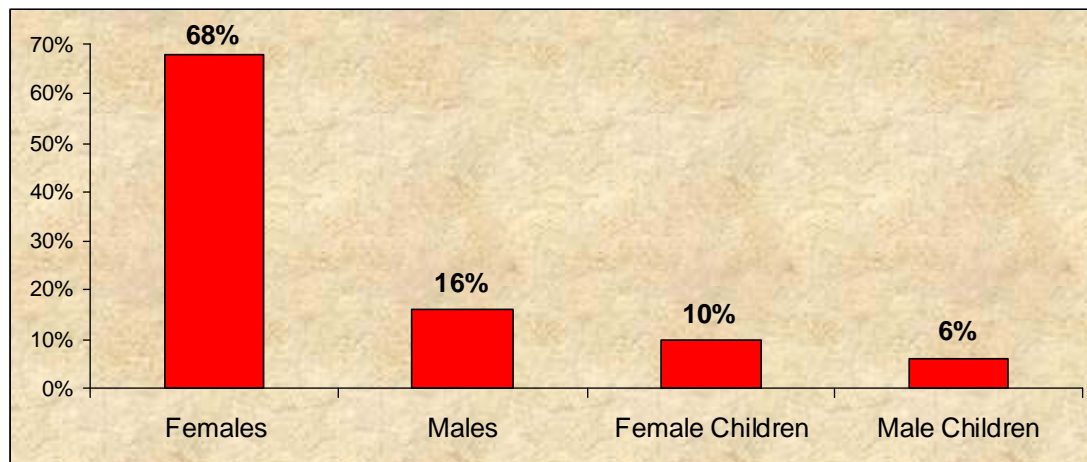
**FUNDING AGENCY** : Nil

## OBSERVATION AND RESULTS OF THE DATA

*Table-1: Sex wise distribution of the Patients*

Sex	No. of Patients (n=50)	Percentage (%)
Females	34	68
Males	8	16
Female Children	5	10
Male Children	3	6

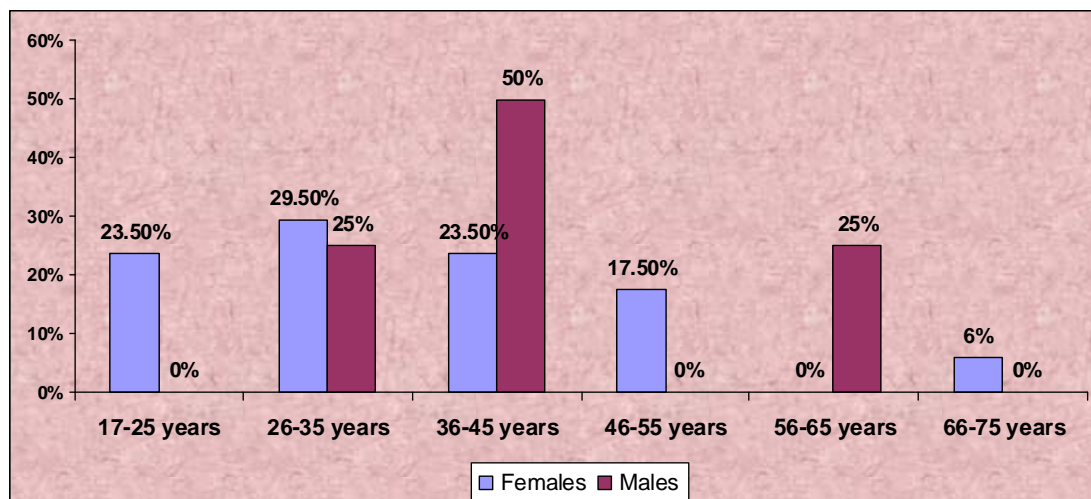
*Fig-1: Sex wise distribution of the Patients*



**Table-2: Age wise distribution of Adult cases**

Age in years	Female		Male	
	No. of Patients (n=34)	Percentage (%)	No. of Patients (n=8)	Percentage (%)
17-25 years	8	23.5	0	0
26-35 years	10	29.5	2	25
36-45 years	8	23.5	4	50
46-55 years	6	17.5	0	0
56-65 years	0	0	2	25
66-75 years	2	6	0	0

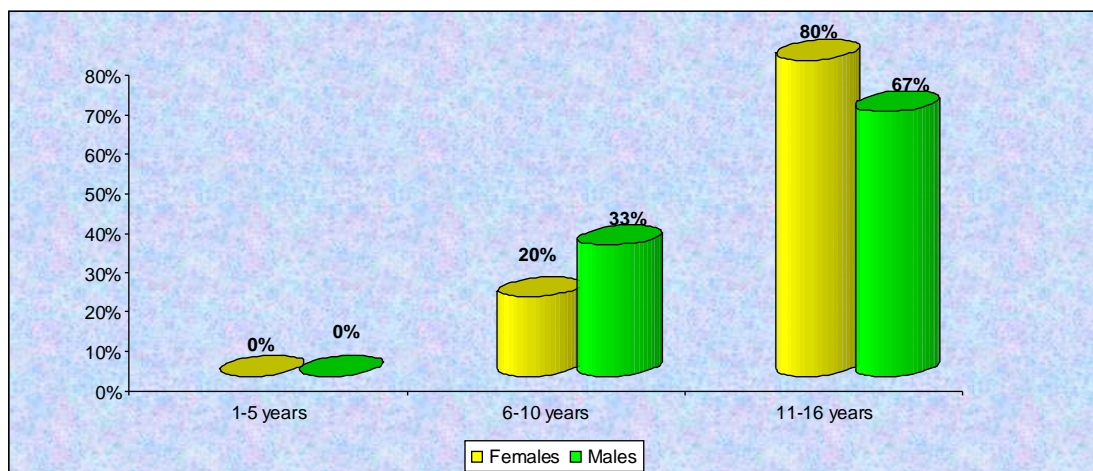
**Fig-2: Age wise distribution of Adult cases**



**Table-3: Age wise distribution of Paediatric cases**

Age in years	Female		Male	
	No. of Patients (n=5)	Percentage (%)	No. of Patients (n=3)	Percentage (%)
1-5 years	0	0	0	0
6-10 years	1	20	1	33
11-16 years	4	80	2	67

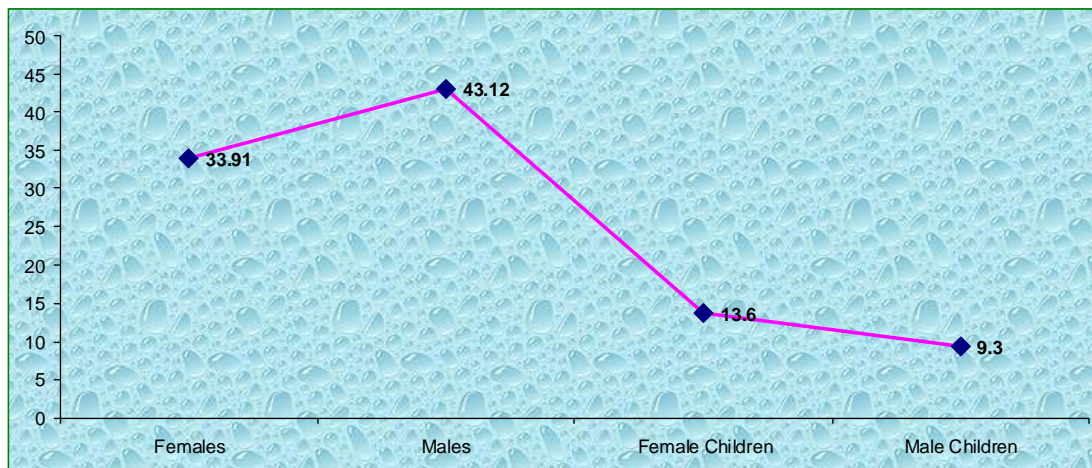
**Fig-3: Age wise distribution of Paediatric cases**



**Table-4: Mean age of the patients at the time of presentation**

Sex	No. of Patients (n=50)	Mean age in Years
Females	34	33.91
Males	8	43.12
Female Children	5	13.6
Male Children	3	9.3

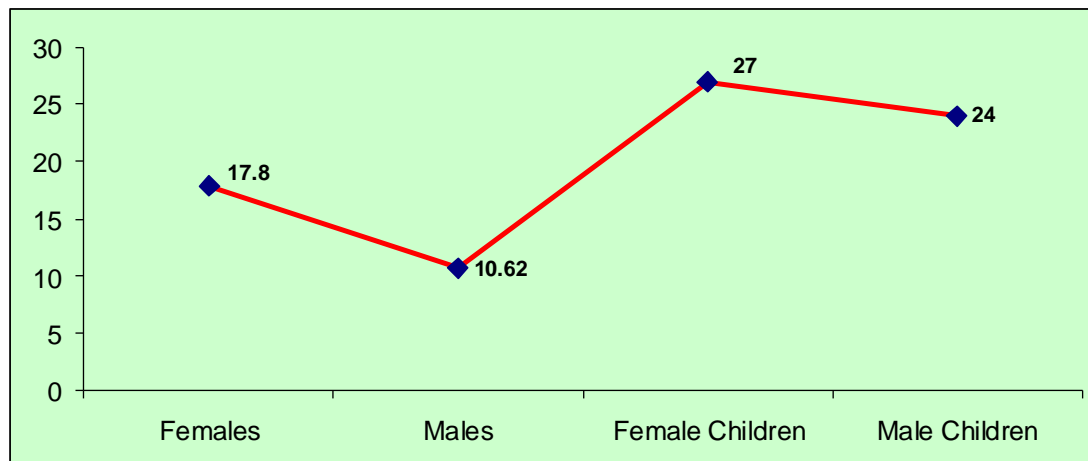
**Fig -4: Mean age of the patients at the time of presentation**



**Table-5: Mean duration of illness at the time of presentation in months**

<b>Sex</b>	<b>No. of Patients (n=50)</b>	<b>Mean duration of illness in months</b>
Females	34	17.8
Males	8	10.62
Female Children	5	27
Male Children	3	24

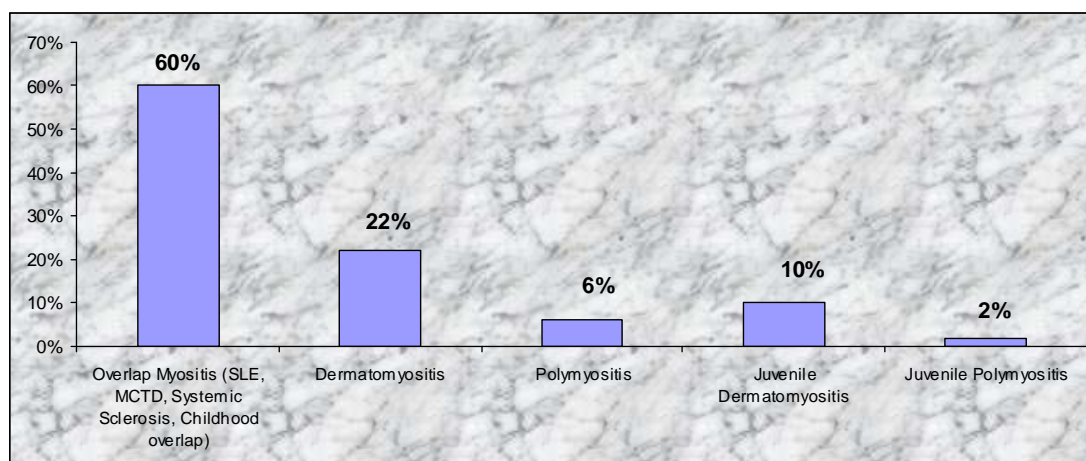
**Fig-5: Mean duration of illness at the time of presentation in months**



**Table-6: Disease Distribution among the study subjects**

<b>Diseases</b>	<b>No. of Patients (n=50)</b>	<b>Percentage (%)</b>
Overlap Myositis (SLE, MCTD, Systemic Sclerosis, Childhood overlap)	30	60
Dermatomyositis	11	22
Polymyositis	3	6
Juvenile Dermatomyositis	5	10
Juvenile Polymyositis	1	2

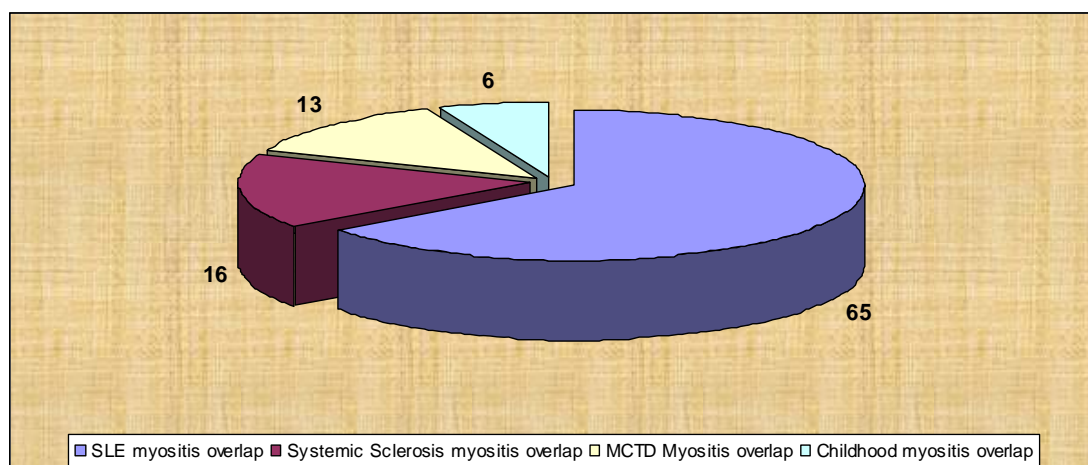
**Fig-6: Disease Distribution among the study subjects**



**Table-7: Frequency of myositis in overlap syndromes**

<b>Overlap syndromes</b>	<b>No. of Patients (n=31)</b>	<b>Percentage (%)</b>
SLE myositis overlap	20	65
Systemic Sclerosis myositis overlap	5	16
MCTD Myositis overlap	4	13
Childhood myositis overlap	2	6

**Fig-7: In overlap myositis frequency of various overlap syndromes**





**Table-8: ANA positivity in patients with inflammatory myositis**

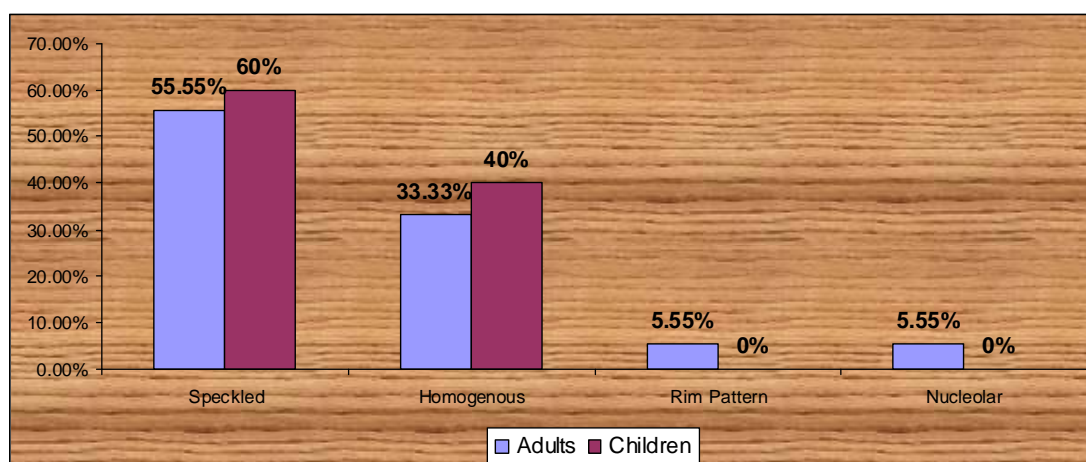
ANA by ELISA and Hep 2 IIF was done to all the 50 patients.

ANA positivity by	Adults		Children	
	No. of Patients (n=42)	Percentage (%)	No. of Patients (n=8)	Percentage (%)
ELISA	35	83.33	5	62.5
Hep-2 IIF	36	85.71	5	62.5

**Table-9: ANA pattern by IIF in adults and children**

ANA pattern	Adults		Children	
	No. of Patients (n=36)	Percentage (%)	No. of Patients (n=5)	Percentage (%)
Speckled	20	55.55	3	60
Homogenous	12	33.33	2	40
Rim Pattern	2	5.55	0	0
Nucleolar	2	5.55	0	0

**Fig -8: ANA pattern by IIF in adults and children**

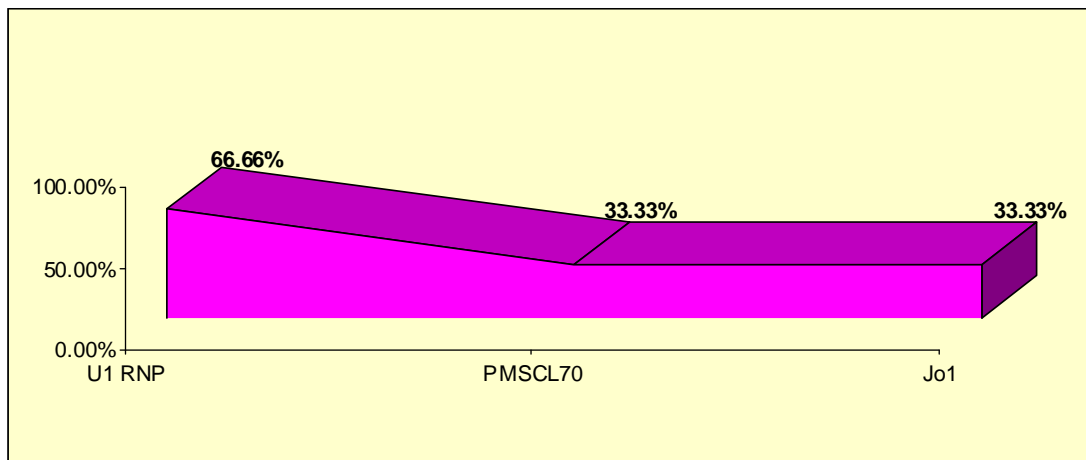


**Table-10: ENA Profile**

It was done to 50 patients out of which 6 (12%) are positive for antibodies and no children is positive for ENA profile.

<i>Antibodies</i>	<i>No. of patients (n=6)</i>	<i>Percentage (%)</i>
U1 RNP	4	66.66
PMSCL70	1	33.33
Jo1	1	33.33

**Fig-9: ENA Profile**

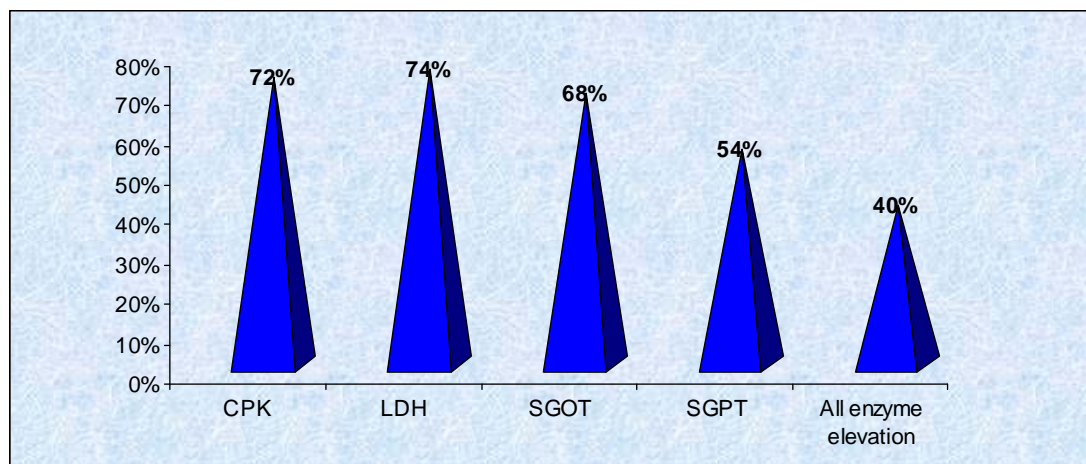


## SERUM MUSCLE ENZYMES ABNORMALITIES IN INFLAMMATORY MYOSITIS

*Table-11: Muscle Enzyme Elevation*

<i>Enzymes</i>	<i>No. of Patients Elevated (n=50)</i>	<i>Percentage (%)</i>
CPK	36	72
LDH	37	74
SGOT	34	68
SGPT	27	54
All enzyme elevation	20	40

*Fig-10: Muscle Enzyme Elevation*

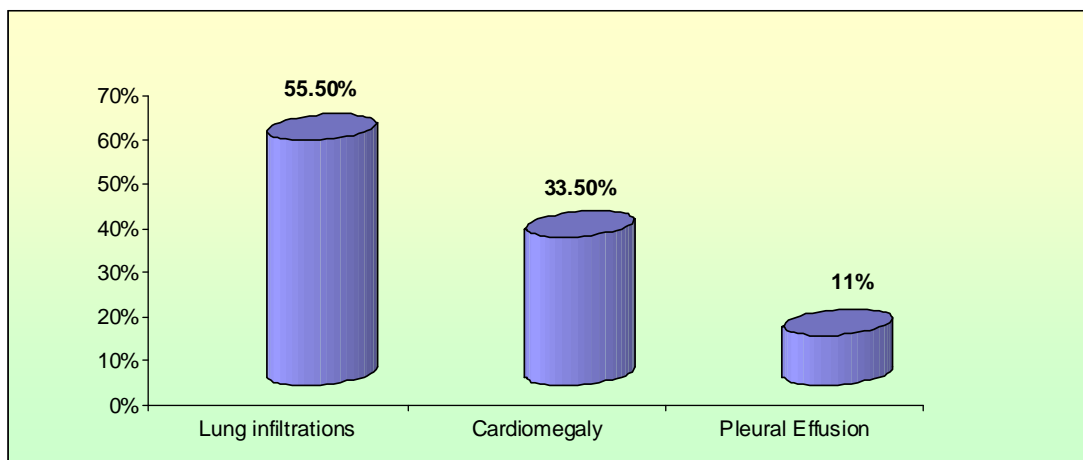


**Table-12: Chest X-Ray abnormalities**

We have done to all the 50 patients Chest X-Ray PA view. Out of 50 patients, 9(18%) showed radiological abnormalities.

<i>Chest X-ray findings</i>	<i>No. of patients (n=9)</i>	<i>Percentage</i>
Lung infiltrations	5	55.5
Cardiomegaly	3	33.5
Pleural Effusion	1	11

**Fig-11: Chest X-Ray abnormalities**



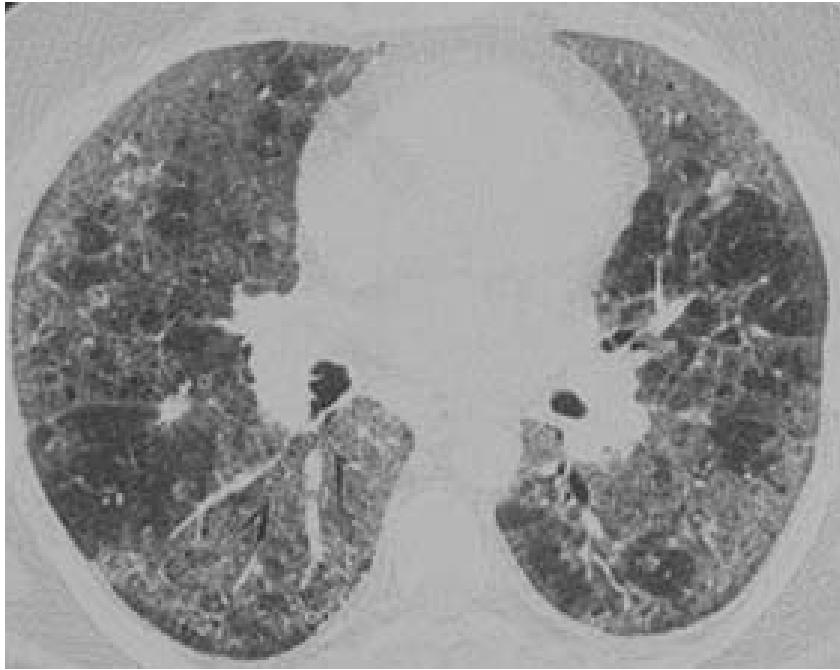## **LUNG ABNORMALITIES**

### ***HRCT lung***

HRCT lung was done in 42 cases. HRCT lung involvement in the form of interstitial infiltrates, Non Specific Interstitial Pneumonitis (NSIP), Usual Interstitial Pneumonitis (UIP), nodular, reticular patterns, ground glass opacities and traction bronchiectasis were seen in 21(50%) out of 42 patients.

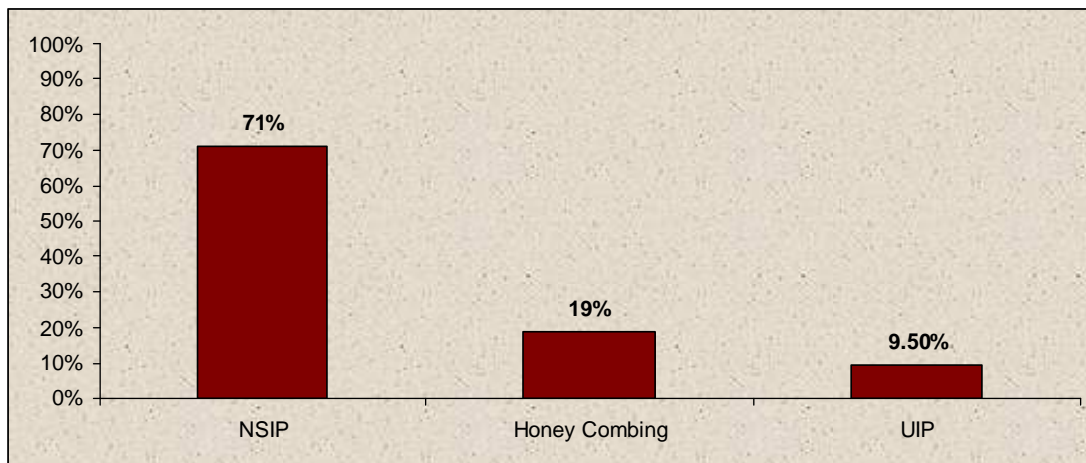
In our study, various patterns of lung involvement in inflammatory myositis are

- 1) NSIP (Non specific interstitial Pneumonitis) characterized by reticular and or ground glass opacities with or without consolidation are seen in 15 (71%) out of 21 patients.
- 2) Honey combing, bronchiectatic changes with fibrosis seen in 4 (19%) patients out of 21.
- 3) UIP (Usual Interstitial Pneumonia) 2 (9.5%) patients out of 21.
- 4) Cryptogenic organizing pneumonia, diffuse alveolar damage were not seen in our study.
- 5) Pleural effusion with consolidation was seen in 1 case of SLE myositis overlap.



*HRCT Lung showing ground glass opacity in ILD  
-A case of dermatomyositis*

*Fig-12: HRCT Lung*



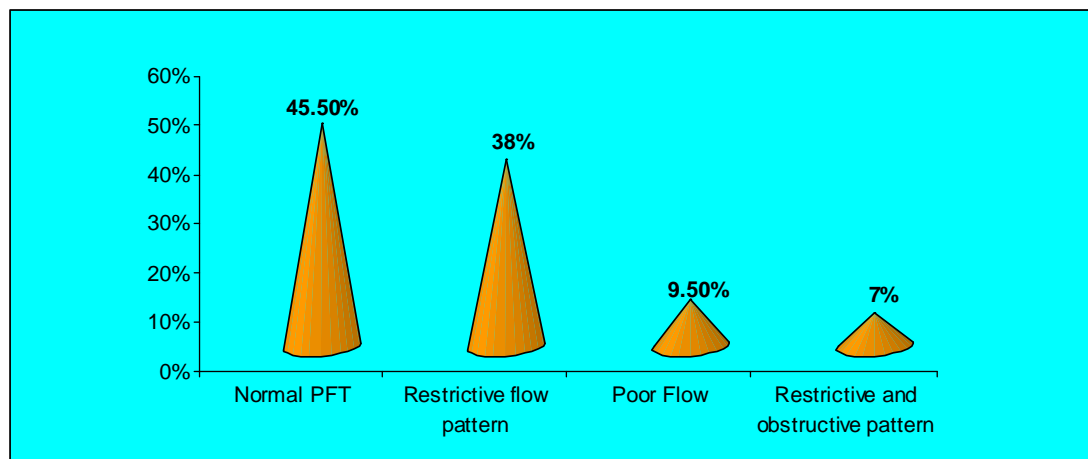
**Table-13: Pulmonary function test abnormalities in inflammatory myositis**

Pulmonary function test were done in 42 (84%) patients out of 50.

<i>Pattern</i>	<i>No. of patients (n=42)</i>	<i>Percentage (%)</i>
Restrictive flow pattern (FEV1/FVC Normal or increased)	16	38
Restrictive and obstructive pattern (reduced FEV1, FVC, FEV1/FVC)	3	7
Poor Flow	4	9.5
Normal PFT	19	45.5

OP- Obstructive Pattern (Reduced FEV1/ FVC <0.7).

**Fig-13: Pulmonary function test abnormalities in inflammatory myositis**



***Broncho Alveolar Lavage (BAL) abnormalities in inflammatory myositis***

BAL was done in 40 cases, children were excluded from the BAL and 2 patients are not willing for BAL. The BAL was done under local anaesthesia with instillation of 100ml of normal saline via flexible bronchoscope and subsequently aspirated via cannula. The aspirated fluid was subjected to cell count, grams stain, AFB smear and culture. In our study, inflammatory cells predominantly lymphocytes, neutrophils and eosinophils are seen in the smear around 23 cases. 2 cases of normal HRCT lung showed inflammatory cells.



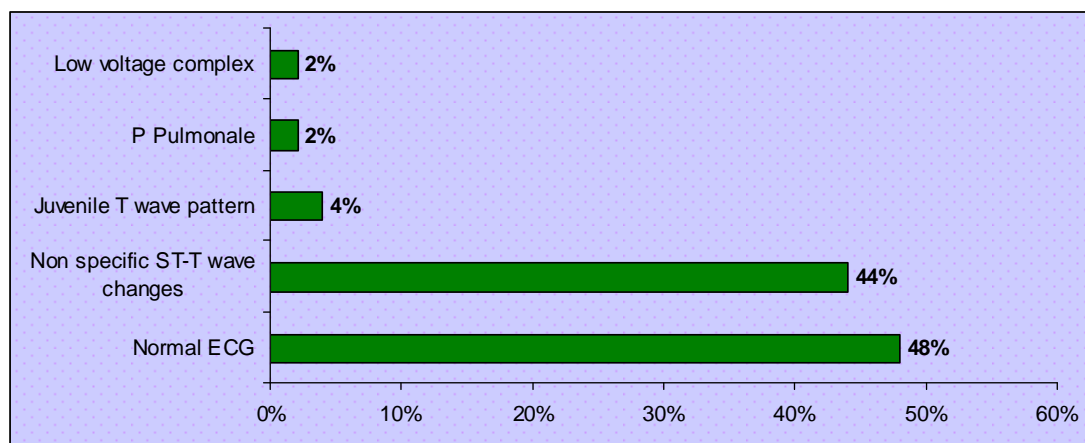
### *Cardiac manifestations in inflammatory myositis*

Clinically significant cardiac dysfunction is uncommon in idiopathic inflammatory myositis. But it is common in overlap myositis.

**Table-14: ECG changes in inflammatory myositis**

<i>ECG Changes</i>	<i>No. of patients (n=50)</i>	<i>Percentage (%)</i>
Normal ECG	24	48
Non specific ST-T wave changes	22	44
Juvenile T wave pattern	2	4
P Pulmonale	1	2
Low voltage complex	1	2

**Fig-14: ECG changes in inflammatory myositis**



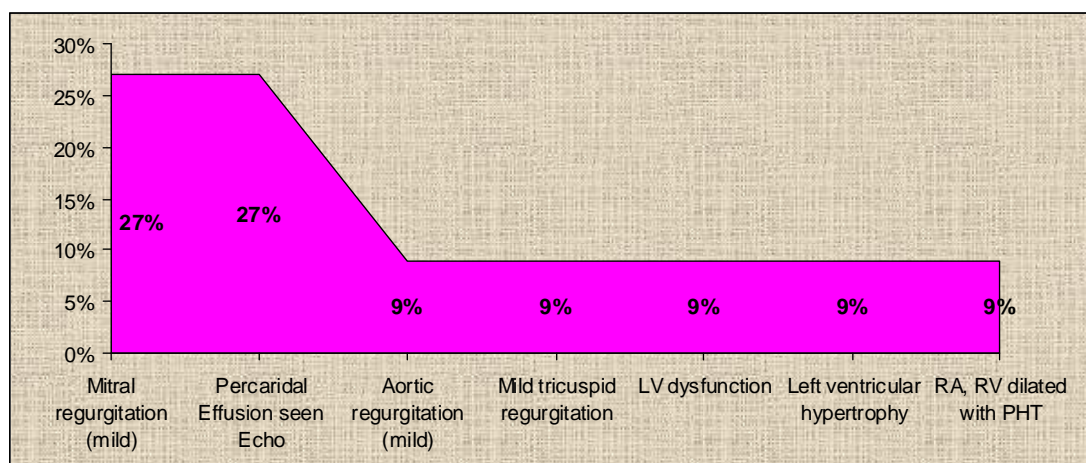
**Table-15: Echo Cardiogram**

Out of 50 patients, cardiac manifestations were seen in 11 (22%) cases.

These are the following abnormalities seen in our study

<b>Abnormalities</b>	<b>No. of Patients (N=11)</b>	<b>Percentage (%)</b>
Mitral regurgitation (mild)	3	27
Percaridal Effusion seen Echo	3	27
Aortic regurgitation (mild)	1	9
Mild tricuspid regurgitation	1	9
LV dysfunction	1	9
Left ventricular hypertrophy	1	9
RA, RV dilated with PHT	1	9

**Fig-15: Echo Cardiogram**

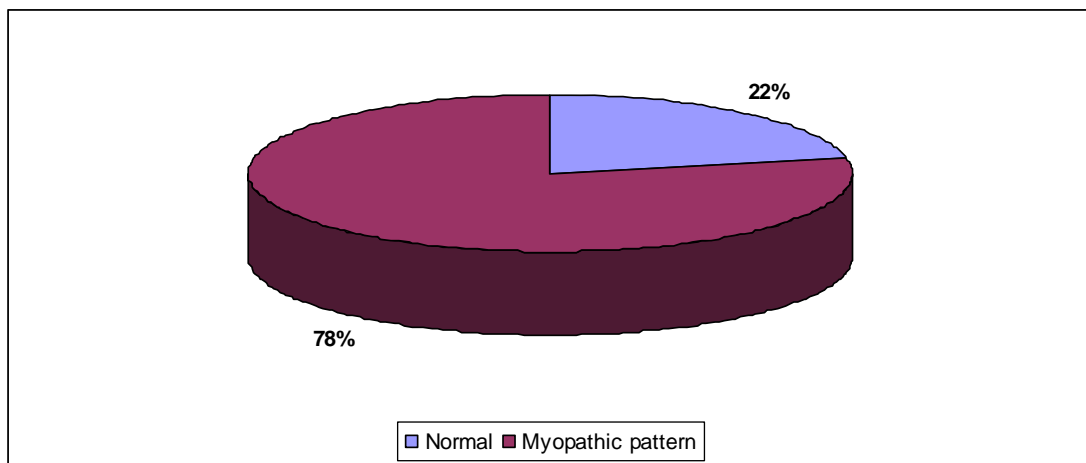


### ***Electromyographic Abnormalities***

EMG was done to all the 50 cases in our study, patients showing myopathic pattern (Short, sharp, low amplitude, positive, polyphasic, fibrillary waves, insertional irritability and spontaneous activity seen in 39 (78%) out of 50 patients).

Out of 50 patients, 78.57% were adults and 75% were children.

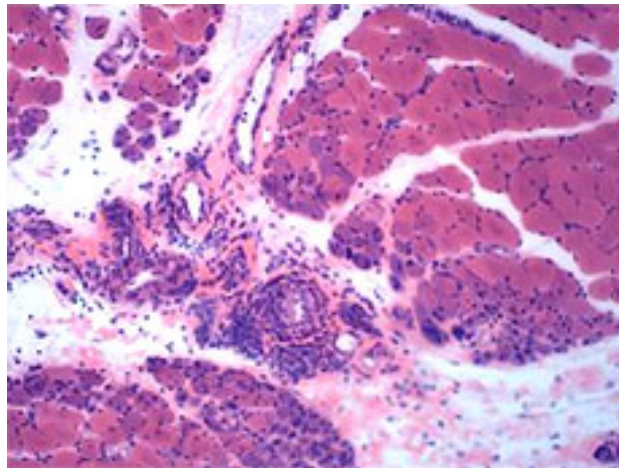
***Fig -16: Electromyographic Abnormalities***



### ***Muscle Biopsy***

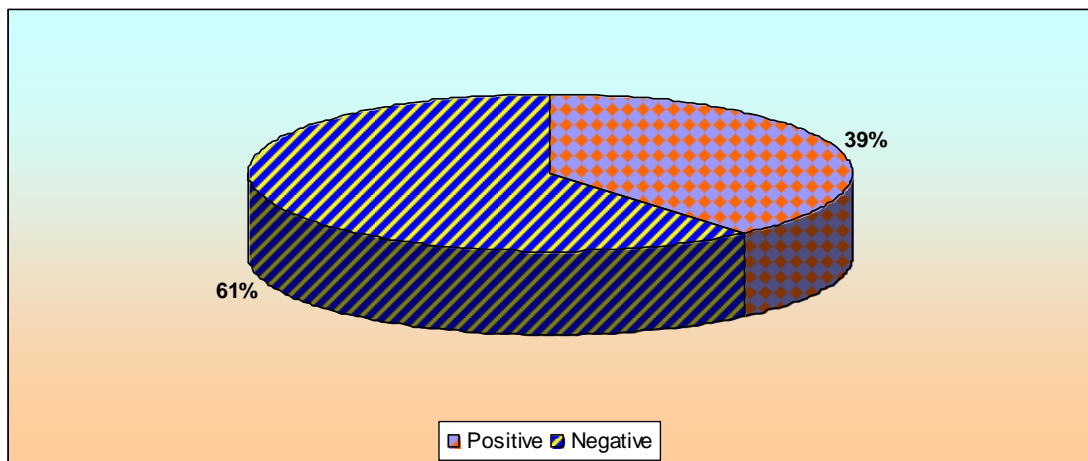
In our study we have done open surgical biopsy of the vastus lateralis of thigh muscles and subjected to histopathological examination. Muscle biopsy done in 46 (92%) out of 50 patients.

Our study shows 18 (39%) cases having histopathological evidence of myositis like inflammatory cell infiltration, focal areas of degeneration and regeneration, muscle fiber atrophy as well as perimysial inflammation.



***A case of dermatomyositis muscle biopsy report showing inflammatory cell infiltration by light microscopy using eosin and haematoxylin stain***

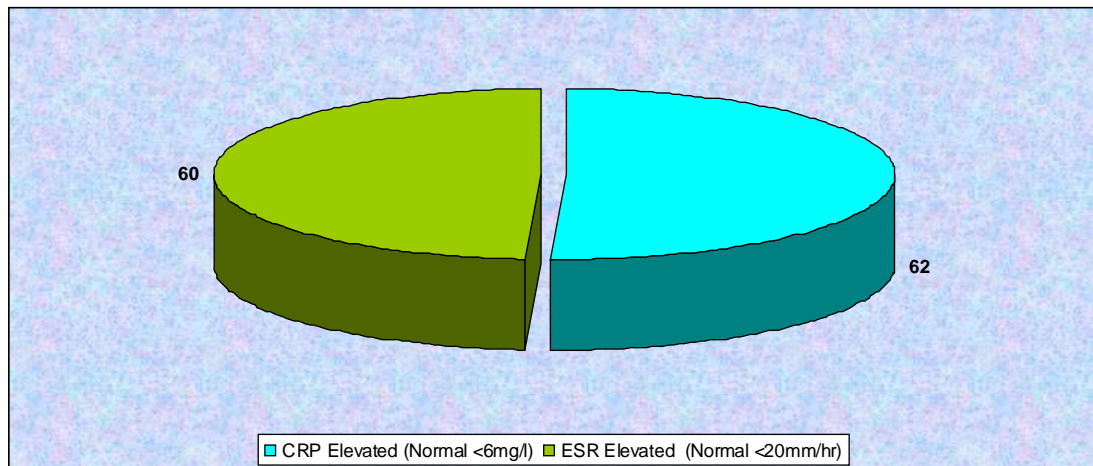
***Fig-17: Muscle Biopsy Abnormalities***



**Table-16: Inflammatory Markers**

<b>Inflammatory Markers</b>	<b>No. of Patients (n=50)</b>	<b>Percentage (%)</b>
CRP Elevated (Normal <6mg/dl)	31	62
ESR Elevated (Normal <20mm/hr)	30	60

**Fig-18: Inflammatory Markers**



**Table-17: Cutaneous features of dermatomyositis**

<b><i>Cutaneous Features</i></b>	<b><i>Adults</i></b>		<b><i>Children</i></b>	
	<b><i>No. of Patients (n=11)</i></b>	<b><i>Percentage (%)</i></b>	<b><i>No. of Patients (n=5)</i></b>	<b><i>Percentage (%)</i></b>
Periorbital edema	8	72.7	5	100
Heliotrophe Rash	6	54.5	4	70
Malar Rash	3	27.2	0	0
V Sign	1	9	0	0
Shawl Sign	2	18.1	0	0
Mechanic Hands	1	9	0	0
Calcinosis	1	9	4	80
Diffuse Erythema	1	9	1	20
Raynaud's Phenomenon	3	27.2	0	0
Vasculitis Lesions	1	9	2	40

## DISCUSSION

Inflammatory myopathies are a heterogeneous group of autoimmune disorders predominantly affecting skeletal muscles resulting in muscle inflammation and weakness. Along with musculoskeletal manifestations, involvement of other organ systems like skin, cardiac, gastrointestinal and pulmonary are common. In inflammatory myositis cardiac and pulmonary involvement results in significant morbidity and mortality.

A South Indian study<sup>30</sup> showed ILD in 9.2%, conduction disturbances 1.15%, myocarditis 4.6%, muscle enzymes elevation 85.1%, myopathic pattern EMG 66.6%, muscle biopsy suggestive of myositis 85.29%, ANA positivity 67.24%.

In our study, we aimed to study the various cardio-pulmonary manifestation in inflammatory myositis. In our study we included 50 patient who fulfilled inclusion criteria for inflammatory myositis after written consent and ethical committee approval for the period of one year (February 2011 to February 2012). We subjected these patients to clinical examination, CBC, LFT, RFT, CXR, HRCT Lung, PFT, BAL, ECG, ECHO, Muscle Biopsy and EMG.

In our study, total number of patients are 50. Out of 50 patients 34 (68%) were females, 8(16%) were males, 5 (10%) were female children, and 3(6%) were male children.

In our study, mean age was for females (33.9 years), males (43.12 years), male children (9.3 years), female children (15.6 years) with mean

disease duration in females (17.84 months), males (10.62 months), male children (24 months) and female children (24 months).

Compared to Western studies, the most common type of inflammatory myositis is overlap (60-70%). In our study, the prevalence of overlap myositis is around 60%. Like other previous studies in our study polymyositis is rare. There are variations in age at presentations. Inflammatory myositis is most common in females and polymyositis is rare in children.

In our study, among the overlap myositis, the SLE myositis overlap is most common (65%). In the decreasing order of frequencies systemic sclerosis myositis overlap (16%) MCTD myositis overlap (13%) and childhood myositis overlap (6%).

Serum autoantibodies are commonly found in inflammatory myositis and useful in defining a subject of patients phenotypically. It may be myositis specific autoantibodies (5% to 30%) and myositis associated auto antibodies (10% to 40%). ANA positivity in our adult patients are around by ELISA (83.33%) and HEP2 (85.71%). Predominant pattern is speckled (55%) in adults. Other autoantibodies positive in our study are anti-U1 RNP, anti-PMSCl, anti-Jo1.

Enzymes that release from injured skeletal muscle into the serum is valuable in detecting ongoing muscle inflammation response to therapy to certain extent and flare of the disease. In our study CPK (72%), Lactate dehydrogenase (74%), SGOT (68%), SGPT (54%) were measured in all patients and found to be elevated in (67%) and helped in the classification and diagnosis of myositis.



## **PULMONARY ABNORMALITIES**

Pulmonary involvement is a major cause of morbidity and mortality in patients with inflammatory myositis. We have done clinical examination, CXR, HRCT Lung, PFT and BAL to find out the frequency of pulmonary abnormalities in our study. In our study, we have done chest X ray PA view to all patients. Out of 50 patients 9 showed abnormalities, in which 5 (55.5%) patients showed lung infiltration and 1 (11%) patients showed pleural effusion.

We have done HRCT lung to 42 patients since ILD is uncommon in JDM. We have excluded childhood myositis cases from HRCT Lung. In our study, we found out 21 (50%) patients, out of 42 patients shown various forms of ILD, the most common pattern being NSIP in 71%, Honey combing, bronchiectatic changes with fibrosis in 19%, least being UIP pattern. Compared to Western studies we have only 50% of ILD in myositis patients. It may be due to more overlap myositis especially SLE myositis overlap (65%), usually in SLE around (14% to 43%) have lung involvement. In our study we find out again that HRCT lung is more sensitive in the diagnosis of pulmonary complications than Chest X-ray.

We have done PFT to 42 patients, children were excluded due to technical difficulties in performing PFT in children. We have found out abnormalities in around 54.5% in which predominant abnormalities are restrictive flow pattern with (normal or increased FEV1/ FVC) and poor flow in 9.5% due to severe muscle weakness.

In our study we have done BAL in 40 (80%) patients out of 50, 10 were excluded from the BAL study in which 57.5% of the patients showed

inflammatory cells in the BAL fluid. In 21 patients with HRCT proven ILD showed inflammatory changes. So there is no need to do routine BAL in all cases of inflammatory myositis to diagnose pulmonary involvement.

## **CARDIAC ABNORMALITIES IN INFLAMMATORY MYOSITIS**

Clinically significant cardiac dysfunction is uncommon in idiopathic inflammatory myositis. But it is common in overlap myositis. We have done ECG and Echo cardiogram to all patients. Like other Western study<sup>22</sup>, the most common abnormality detected was non specific ST T-wave changes in around 44% in ECG. In Chest X ray around 33.5% had cardiomegaly.

By echocardiogram 27% of patients, have Mitral Regurgitation (Mild) and Pericardial Effusion and other lesions diagnosed by echo are Aortic Regurgitation, Tricuspid Regurgitation, LV dysfunction, Left Ventricular Hypertrophy, RA, RV dilated with pulmonary hypertension. We have to do radionucleotide imaging to find out myocardial inflammation early.

Electromyography (EMG) was done to all the 50 cases in our study. EMG is a sensitive indicator of muscle involvement even though muscle enzymes, biopsy were normal. In our study around 78% showed myopathic pattern compared to western study of 80%.

We did muscle biopsy in 92% of patients in our study. Only 39% showed inflammatory changes consistent with inflammatory myositis. It may be due to patchy inflammation of muscle in Inflammatory Myositis.

In our study inflammatory markers like CRP, ESR are elevated in around 62% and 60% respectively.

## CONCLUSION

In our study, inflammatory myositis is more common in females than in males.

In our study, myositis is more common in overlap syndromes compared to Idiopathic Inflammatory Myositis.

In our study, among the overlap syndromes SLE with myositis overlap is more common.

In our study, ILD was seen in 50% of the adult patients with NSIP being the most common.

In our study, a symptomatic ECG abnormalities was common (48%).

In our study, 58% of the patients showed inflammatory cells in the BAL study, out of which 52% of the patient had ILD changes by HRCT Lung

In patients with myositis, routine use of HRCT Lung and ECG evaluation is more useful.

## **BIBLIOGRAPHY**

- 1) Dr.T.S.R., Text Book of Anatomy, 6<sup>th</sup> Edition: 417, 420, 425, 426, 430, 436, 444.
- 2) Ganong, Text Book of Physiology, 20<sup>th</sup> Edition: 65,67, 70,73, 78.
- 3) Unverricht H: Polymyositis acuta progressive. Z Klin Med: 12: 533, 1887.
- 4) Steiner W.R: Dermatomyositis, with report of a case which presented a rare muscle anomaly but once described in man. J Exp. Med. 6: 407, 1903.
- 5) Oddis C, Conte C, Steen V: Incidence of polymyositis-dermatomyositis.: A 20 year study of hospital diagnosed cases in Allegheny Country, PA 1963-1982, J Rheumatol 17: 1329-1334, 1990.
- 6) Foote R, Kimbrough S, Stevens J: Lupus myositis. Muscle Nerve 5: 65-68, 1982.
- 7) Reed AM, Ytterberg SR: Genetic and environmental risk factors for idiopathic inflammatory myopathies, Rheum Dis Clin North Am 28: 891-916, 2002.
- 8) Leff RL, Love LA, Miller FW, et al: Viruses in idiopathic inflammatory myopathies: Absence of candidate viral genomes in muscle Lancet 339; 1992.

- 9) Love LA, Miller FW: Noninfectious environmental agents associated with myopathies. *Curr Opin Rheumatol* 5: 712-718; 1993.
- 10) Nagaraju K. Update on immunopathogenesis in inflammatory myopathies. *Curr opin Rheumatol* 2001; 13: 461-8.
- 11) Love LA, Leff RL, Fraser DD, et al. A new approach to the classification of idiopathic inflammatory myopathy; myositis-specific autoantibodies define useful homogeneous patient group. *Medicine (Baltimore)* 1991; 70: 360-74.
- 12) Bradshaw EM, Orihuela A, McArde SL, et al. A local antigen- driven humoral response is present in the inflammatory myopathies. *J Immunol* 2007; 178: 547-56.
- 13) Levine SM, Raben N, Xie D et al. Novel conformation of histidyl-transfer RNA synthetase in the lung; the target issue in Jo-1 autoantibody- associated myositis *Arthritis Rheum* 2007; 56: 2729-39.
- 14) Goebels N, Michaelis D, Engelhardt M, et al. Differential expression of perforin in muscle-infiltrating T cells in polymyositis and dermatomyositis. *J Clin invest* 1996; 97: 2905-10.
- 15) Ulfgren AK, Grundtman C, Borg K, et al. Down- regulation of the aberrant expression of the inflammation mediator high mobility group box chromosomal protein 1 in muscle tissue of patients with polymyositis and dermatomyositis treated with corticosteroids. *Arthritis Rheum* 2004; 50: 1586-94.

- 16) Salmonsson S, Grundtman C, Zhang SJ, et al. Upregulation of MHC class I in transgenic mice result in reduced force-generating capacity in show- twitch muscle. *Muscle Nerve* 2009; 39: 674-82.
- 17) Dalakas MC. Muscle Biopsy findings in inflammatory myopathies. *Rheum Dis Clin North AM* 2002; 28 (4): 779-98, vi.
- 18) Bohan A, Peter JB, Polymyositis and dermatomyositis I. *N Engl J Med* 1975; 292: 344-7, 403-7.
- 19) Santmyire- Rosenberger B, Dugan EM. Skin involvement in dermatomyositis. *Curr Opin Rheumatol* 2003; 15 (6): 714-22.
- 20) Oppenheim H. Zur dermatomyositis. *Berl Klin Wochenschr* 1899; 36: 805-7.
- 21) Gottdiener JS, Sherber HS, Hawley RJ, et al. Cardiac manifestations in polymyositis. *Am J Cardiol* 1978; 41 (7): 1141-9.
- 22) Gonzalez- Lopez L, Gamez- Nava JI, Sanchez L et al. Cardiac manifestation in dermato-polymyositis. *Clin Rheumatol* 1996; 14 (4) 373-9.
- 23) Fathi M, Lundberg IE, Tornling G. Pulmonary complications of polymyositis and dermatomyositis. *Semin Respir Crit Care Med* 2007; 28 (4): 451-8.
- 24) Fathi M, Dastmalchi M, Rasmussen E, et al. Interstitial lung disease, a common manifestation of newly diagnosed polymyositis and dermatomyositis. *Ann Rheum Dis* 2004; 63: 297-301.

- 25) Ascherman DP. Pulmonary complications of inflammatory myopathy. *Curr Rheumatol Rep.* 2002; 4: 409-14.
- 26) Ebert EC. Review article: the gastrointestinal complications of myositis. *Aliment pharmacol Ther* 2010; 31 (3): 359-65.
- 27) Nishikai M, Homma M. Circulatory autoantibody against human myoglobin in polymyositis, *JAMA* 1977, 237: 1842-70.
- 28) Gregory P. Cosgrove, Marvin I Schwarz, Fishman Text book of Pulmonary Medicine: 634.
- 29) Adapted from Troyanov Y, Targoff IN, Tremblay JL, et al: Novel classification of idiopathic inflammatory myopathies based on overlap syndrome features and autoantibodies: Analysis of 100 French Canadian patients. *Medicine (Baltimore)* 84:231-249, 2005.
- 30) R Porkodi, K.E.Shanmuganandan, M.Parthiban, Radhamadhavan, C.P.Rajendran, Clinical Spectrum of Inflammatory Myositis in South India- A 10 year study, *JAPI*, 2002; 50: 1255-1258.





## **General Examination**

Height:

Weight:

BMI:

Pallor:

Icterus:

Lymphadenopathy:

Pedal Edema:

Clubbing:

Skin:

Nails:

Hair:

## **Vital Signs**

PR:

BP:

RR:

Temp:

Cardiovascular System:

Respiratory System:

Abdomen:

Central Nervous System:

Musculocellular System:

## **INVESTIGATION**

### ***Haemogram***

Hb:

TC:

DC:

PLT:

RBC:

ESR:

### ***Immunological***

ANA: ELISA/Hep-2 IIF

ENA Profile:

CRP:

RF:

### ***Bio-Chemistry***

Sugar:

Urea:

Creatinine:

Bilirubin:

SGOT:

SGPT:

ALP:

Total Protein:

Albumin:

TGL:

Cholesterol:

CPK:

LDH:

### ***Radiography***

1. Chest X-Rays:

2. HRCT Lung

3. Echo Cardiogram

### ***Other investigations***

ECG:

PFT:

Bronchoalveolar Lavage

Muscle Biopsy

EMG Studies

## ஆராய்ச்சி ஒப்புதல் படிவம்

ஆராய்ச்சி தலைப்பு

தசை அழற்சி நோயினால் இருதயம் மற்றும் நுரையீரல் பாதிப்பு குறித்த ஆய்வு

ஆராய்ச்சி நிலையம் : மூட்டு, தசை மற்றும் இணைப்புத்திசு  
நோய்களியல் துறை,  
சென்னை மருத்துவக் கல்லூரி மற்றும்  
ராஜீவ் காந்தி அரசு பொது மருத்துவமனை, சென்னை.

பங்கு பெறுவரின் பெயர் :  
பாலினம் :  
பங்கு பெறபவரின் எண் :

பங்கு பெறுபவர் இதனை (✓) குறிக்கவும்

மேலே குறிப்பிட்டுள்ள மருத்துவ ஆய்வின் விவரங்கள் எனக்கு விளக்கப்பட்டது. என்னுடைய சந்தேகங்களை கேட்கவும், அதற்கான தகுந்த விளக்கங்களை பெறவும் வாய்ப்பளிக்கப்பட்டது.

நான் இவ்வாய்வில் தன்னிச்சையாகதான் பங்கேற்கிறேன். எந்த காரணத்தினாலோ எந்த கட்டத்திலும் எந்த சட்ட சிக்கலுக்கும் உட்படாமல் நான் இவ்வாய்வில் இருந்து விலகி கொள்ளலாம் என்றும் அறிந்து கொண்டேன்.

இந்த ஆய்வு சம்பந்தமாகவோ, இதை சார்ந்த மேலும் ஆய்வு மேற்கொள்ளும் போதும் இந்த ஆய்வில் பங்குபெறும் மருத்துவர் என்னுடைய மருத்துவ அறிக்கைகளை பார்ப்பதற்கு என் அனுமதி தேவையில்லை என அறிந்து கொள்கிறேன். நான் ஆய்வில் இருந்து விலகிக் கொண்டாலும் இது பொருந்தும் என அறிகிறேன்.

இந்த ஆய்வின் மூலம் கிடைக்கும் தகவல்களையும், பரிசோதனை முடிவுகளையும் மற்றும் சிகிச்சை தொடர்பான தகவல்களையும் மருத்துவர் மேற்கொள்ளும் ஆய்வில் பயன்படுத்திக்கொள்ளவும் அதை பிரசுரிக்கவும் என் முழு மனதுடன் சம்மதிக்கின்றேன்.

இந்த ஆய்வில் பங்கு கொள்ள ஒப்புக்கொள்கிறேன். எனக்கு கொடுக்கப்பட்ட அறிவுரைகளின்படி நடந்து கொள்வதுடன் இந்த ஆய்வை மேற்கொள்ளும் மருத்துவ அணிக்கு உண்மையுடன் இருப்பேன் என்று உறுதியளிக்கிறேன். எனது உடல் நலம்பாதிக்கப்பட்டாலோ அல்லது எதிர்பாராத வழக்கிற்கு மாறான நோய்க்குறி தென்பட்டாலோ உடனே அதை மருத்து அணியிடம் தெரிவிப்பேன் என உறுதி அளிக்கிறேன்.

இந்த ஆய்வில் எனக்கு இரத்தம், சிறுநீர், எக்ஸ்ரே, ஸ்கேன் மற்றும் தசை பரிசோதனை செய்துகொள்ள நான் முழு மனதுடன் சம்மதிக்கிறேன்.

பங்கேற்பவரின் கையொப்பம் ..... இடம்..... தேதி.....

கட்டைவிரல் ரேகை

பங்கேற்பவரின் பெயர் மற்றும் விலாசம் .....

ஆய்வாளரின் கையொப்பம் ..... இடம்..... தேதி.....

ஆய்வாளரின் பெயர் .....

## PATIENT CONSENT FORM

Study Title : **“A study on Cardiopulmonary manifestations in Inflammatory Myositis”**

Participant Name: \_\_\_\_\_ Date : \_\_\_\_\_

Age: \_\_\_\_\_ RCC No : \_\_\_\_\_

Sex: \_\_\_\_\_

The details of the study have been provided to me in writing and explained to me in my own language.

I confirm that I have understood the above study and had the opportunity to ask questions.

I understand that my participation in the study is voluntary and that I am free to withdraw at any time, without giving any reason, without the medical care that will normally be provided by the hospital being affected.

I agree not to restrict the use of any data or results that arise from this study provided such a use is only for scientific purpose(s).

I have been given an information sheet giving details of the study.

I fully consent to participate in the above study.

Signature of the participant

**INSTITUTIONAL ETHICS COMMITTEE**  
**MADRAS MEDICAL COLLEGE, CHENNAI -3**

Telephone No: 04425305301  
Fax : 044 25363970

**CERTIFICATE OF APPROVAL**

To  
Dr. B. Senthil Kumar  
PG in DM Rheumatology  
Madras Medical College , Chennai -3.

Dear Dr. B. Senthil Kumar

The Institutional Ethics Committee of Madras Medical College reviewed and discussed your application for approval of the proposal entitled "A study on Cardiopulmonary manifestations in Inflammatory Myositis" No. 21012011.

The following members of Ethics Committee were present in the meeting held on 28.01.2011 conducted at Madras Medical College, Chennai -3.

- |   |                    |
|---|--------------------|
| 1. Prof. S.K. Rajan, MD   | - Chairperson      |
| 2. Prof. A. Sundaram, MD<br>Dean i/c , Madras Medical College, Chennai -3           | - Member Secretary |
| 3. Prof R. Sathianathan<br>Director , Institute of Psychiatry, MMC,Ch-3             | - Member           |
| 4. Prof R. Nandhini, MD<br>Director, Institute of Pharmacology, MMC, Ch-3           | - Member           |
| 5. Prof. Geetha Subramanian, MD,DM<br>Prof. & Head , Dept. of Cardiology, MMC, Ch-3 | - Member           |
| 6. Prof. Md. Ali, MD, DM<br>Professor & Head ,,Dept. of MGE, MMC, Ch-3              | - Member           |
| 7. Thiru. T.S. Bharathidasan<br>Administrative Officer, MMC, Chennai -3             | - Layperson        |
| 8. Thiru. S. Govindasamy . BA.BL  | - Lawyer           |
| 9. Tmt. Arnold Soulina  | - Social Scientist |

We approve the Proposal to be conducted in its presented form.

Sd / . Chairman & Other Members

The Institutional Ethics Committee expects to be informed about the progress of the study, any SAE occurring in the course of the study, any changes in the protocol and patient information / informed consent and asks to be provided a copy of the final report

  
Member Secretary, Ethics Committee

S. No	Name	Age/ Sex	RCC No	Duration of Illness (months)	Diagnosis	Complete Blood Count					ANA/ ELISA	ANA by HEP2	ENA Profile						LFT			RFT Urea/Cr(mg/dl)	Mus CPK
						Hb (gm/dl)	TC (Cells/cu mm)	DC (P/ L/ E)	ESR (mm/hr)	Platelet (Cells/Cumm)			Anti-SM Ab	Anti-SM/U1 RNP Ab	Anti-ro Ab	Anti-la Ab	Anti-SCL70	Anti Jo1 Ab	OT	PT	Sr.Br		
1	Vijaya	44/F	55039	8	Dermatomyositis with ILD	8.2	9300	52/42/6	130	1.3	+	-	-	-	-	-	-	286	196	0.6	25/0.8	28	
2	Girija	19/F	54361	6	MCTD with ILD with PHT	9.4	9800	70/29/1	30	1.2	+	-	-	+	+	-	-	35	46	0.9	30/1	60	
3	Amutha	30/F	50604	18	Systemic Sclerosis/ ILD/ Myositis overlap	10.6	7800	64/32/4	30	1.8	+	-	-	-	-	-	-	27	33	0.9	30/1.	953	
4	Shoba	27/F	54266	18	MCTD with myositis overlap	10.3	7600	62/34/5	20	1.68	+	-	-	+	-	-	-	119	200	1	28/1.2	992	
5	Premila	48/F	47660	60	SLE with myositis overlap	10.8	8010	59/32/3	16	1.64	+	-	-	-	-	-	-	168	122	0.7	24/9	90	
6	Usha	27/F	53366	8	SLE with myositis overlap	7.6	3400	67/29/4	100	1.4	+	-	-	-	-	-	-	182	130	0.9	20/9	200	
7	Ilayanathi	16/F	53238	24	SLE with myositis overlap	11	7600	50/35/3	48	1.9	+	Homogenous	-	-	-	-	-	23	21	1	20/9	43	
8	Noor Ayisha	13/F	53793	1 1/2	Polymyositis	10.4	7200	67/29/4	5	1.8	-	-	-	-	-	-	-	18	20	1	36/8	484	
9	Nazeema	22/F	53795	2	Dermatomyositis	10	920	80/18/2	40	1.72	-	-	-	-	-	-	-	33	18	0.8	17/6	2635	
10	Sahayaraj	28/M	53656	8	Dermatomyositis	11.8	6000	60/38/2	65	1.7	+	-	-	-	-	-	-	54	76	0.6	15/1.1	950	
11	Pitchayammal	48/F	53638	2	Dermatomyositis	9.8	6200	60/32/8	75	1.6	+	-	-	-	-	-	-	156	256	1	30/1.0	200	
12	Malliga	44/F	52945	3	Systemic Sclerosis Myositis Overlap	9.8	7500	57/35/8	50	1.7	+	-	-	-	-	+	-	130	83	0.5	24/5	80	
13	Sasikala	35/F	54226	3	Dermatomyositis ILD	11	8300	56/42/2	86	2.15	+	Homogenous	-	-	-	-	-	118	27	0.8	18/1.0	65	
14	Leena	13/F	53766	3	SLE with myositis overlap	6.4	10600	68/28/4	160	1.54	+	-	ND	ND	ND	ND	ND	17	21	0.3	21/9	932	
15	Engamma	24/F	53796	3	SLE with myositis overlap	9.5	8400	60/38/2	25	1.5	+	-	-	-	-	-	-	26	30	1	29/9	110	
16	Kaleema	54/F	52365	2	Dermatomyositis	10	10500	63/32/5	25	1.8	+	-	-	-	-	-	-	124	30	1	25/8	85	
17	Maharani	23/F	53884	6	SLE with myositis overlap	10.2	8300	65/31/4	103	1.8	+	-	-	-	-	-	-	114	60	0.6	29/8	114	
18	Kumar	33/M	52282	3	Polymyositis	13.4	8700	63/34/3	14	2.7	-	-	-	-	-	-	-	161	191	0.5	28/5	130	
19	Nazeema Banu	24/F	54232	6	SLE with myositis overlap	9.8	7500	66/30/4	110	2.5	+	-	-	-	-	-	-	72	26	0.7	27/1.0	48	
20	Nalini	39/F	53524	12	SLE with myositis overlap	9	5200	63/33/4	100	1.76	+	-	-	-	-	-	-	231	74	0.9	30/7	278	
21	Anandan	36/M	53450	30	Dermatomyositis with ILD	13.6	8000	54/42/4	110	1.4	+	Speckled	-	-	-	-	-	25	15	0.8	26/8	315	
22	Vanitha	37/F	53404	12	MCTD Myositis Overlap	10.4	8200	63/32/5	30	2.6	+	Speckled	-	+	-	-	-	24	19	1	24/6	300	
23	Selvi	17/F	53358	48	JDM/SLE overlap	9.6	7200	66/30/4	130	2.4	+	Speckled	-	-	-	-	-	198	38	0.9	22/8	300	
24	Shoba Rani	20/F	53368	3	SLE with myositis overlap	9.8	7800	63/34/3	100	1.7	+	Homogenous	-	-	-	-	-	88	20	0.9	20/9	40	
25	Sujatha	40/F	53168	7 year	SLE with myositis overlap	10.4	6200	65/31/4	30	1.8	+	Speckled	-	-	-	-	-	13	30	0.7	30/9	300	
26	Bhavani	9/F	55066	9	JDM	10.4	6500	79/18/3	26	1.5	+	Speckled	-	-	-	-	-	91	51	0.5	25/6	776	
27	Guru Moorthy	39/M	53181	18	Dermatomyositis with ILD	13	7200	67/33/6	32	2.7	+	Speckled	-	-	-	-	-	38	30	0.9	30/1.1	130	
28	Pratap	60/M	522121	12	Dermatomyositis with ILD	9	6500	65/30/2	50	1.2	+	Speckled	-	-	-	-	+	110	100	0.5	22/0.7	750	

(+)- Positive  
(RSTV) Non specific T Wave Abnormalities

(-) Negative  
(CXZ) Complexes

(ND) Not Done

S. No	Name	Age/ Sex	RCC No	Duration of Illness (months)	Diagnosis	Complete Blood Count					ANA/ ELISA	ANA by HEP2	ENA Profile						LFT			RFT Urea/Cr(mg/dl)	Mus CPK
						Hb (gm/dl)	TC (Cells/cu mm)	DC (P/ L/ E)	ESR (mm/hr)	Platelet (Cells/ Cumm)			Anti-SM Ab	Anti-SM/U1 RNP Ab	Anti-ro Ab	Anti-la Ab	Anti-SCL70	Anti Jo1 Ab	OT	PT	Sr.Br		
29	Gandhimathi	32/F	53109	10	SLE with myositis overlap	8.7	5900	81/18/1	40	1.06	+	Homogenous	-	-	-	-	-	-	77	72	0.5	25/6	70
30	Sugamathi	27/F	53088	6	MCTD Myositis Overlap	10.2	6100	57/42/1	110	2.6	+	Speckled	+	+	-	-	-	-	245	873	0.8	26/8	220
31	Thara Bhai	63/F	42392	10 years	Polymyositis	9.6	9200	63/33/4	80	2.66	-	-	-	-	-	-	-	22	41	0.8	30/1.1	402	
32	Annakkodi	13/F	53054	6 years	JDM	11.9	6700	66/30/4	75	1.6	-	-	-	-	-	-	-	16	16	0.6	20/9	60	
33	Rekha	24/F	53077	3	SLE with myositis overlap	5.3	7100	51/45/4	70	2.39	+	Homogenous	-	-	-	-	-	-	61	148	0.5	25/8	350
34	Sundari	42/F	53003	18	SLE with myositis overlap	8	8200	54/41/5	46	2.01	+	Homogenous	-	-	-	-	-	-	124	90	1.1	30/1.2	550
35	Nadhiya	23/F	53396	5 years	SLE with myositis overlap with ILD	9.2	7300	66/30/4	96	2.01	+	Homogenous	-	-	-	-	-	-	23	44	0.9	30/7	30
36	Murugan	8/MCH	53528	2	JDM	10.6	7800	62/33/5	34	1.85	-	Speckled	-	-	-	-	-	-	82	293	0.8	25/5	2192
37	Lakshmi	50/F	53604	9	SLE with Myositis Overlap	8.9	5300	56/34/7	50	1.7	-	RIM	-	-	-	-	-	-	99	88	0.9	30/8	300
38	Thilagavathy	40/F	53932	5 Years	Systemic Sclerosis with myositis overlap with ILD	9	7700	50/35/5	72	1.79	-	Speckled	-	+	-	-	-	-	60	25	0.8	32/1	30
39	Stella Rani	50/F	52966	6	Dermatomyositis with ILD	9.4	7800	60/35/5	20	1.78	+	Homogenous	-	-	-	-	-	-	316	106	0.6	36/9	750
40	Raja	39/M	54944	3	SLE myositis overlap	10.8	8500	68/30/2	15	1.54	+	Homogenous	-	-	-	-	-	-	159	74	0.5	15/7	1536
41	Poulia	40/F	51248	7	Systemic Sclerosis myositis Overlap with ILD	10.4	7600	67/29/4	17	1.7	+	Speckled	+	-	-	-	-	-	123	144	0.9	26/8	2117
42	Padma	22/F	51214	2 years	SLE myositis overlap	10.6	6200	60/30/6	15	1.7	+	RIM	-	-	-	-	-	-	220	90	0.3	20/1.0	15
43	Sekar	45/M	53781	6	Polymyositis	9	5500	60/36/2	35	1.5	+	Speckled	-	-	-	-	-	-	140	110	0.6	30/1.0	750
44	Sathya	13/MCH	53784	3 years	JDM	11	7500	52/30/3	40	1.7	+	Speckled	-	-	-	-	-	-	110	78	0.8	20/1.1	950
45	Kalaimani	33/F	54937	2 years	Systemic Sclerosis with Myositis Overlap with ILD	9.5	6700	56/42/2	106	1.49	+	Speckled	-	-	-	-	+	-	109	15	0.6	20/9	318
46	Govindammal	32/F	53975	8	Dermatomyositis with ILD	12	9000	45/30/6	60	2.2	+	-	-	-	-	-	-	+	140	130	0.5	26/1.0	770
47	Periyasamy	65/M	53280	5	Dermatomyositis	8	11000	70/28/2	70	1.2	+	-	-	-	-	-	-	-	116	178	0.9	34/1.2	900
48	Chandran	7/MCH	53270	1 year	JDM	9	7200	56/34/1	30	1.3	+	Speckled	-	-	-	-	-	-	100	92	0.2	20/1.0	750
49	Rama Lakshmi	30/F	53672	3	SLE myositis overlap	9	5000	72/28/1	25	68000	+	RIM	-	-	-	-	-	-	112	120	0.8	25/9	130
50	Loganayagi	72/F	56524	3	SLE myositis overlap	6.8	4100	85/10/5	42	2.36	+	Speckled	-	-	-	-	-	-	56	54	0.7	18/1.8	550

(+)- Positive  
(RSTV) Non specific T Wave Abnormalities

(-) Negative  
(CXZ) Complexes

(ND) Not Done

scale
LDH
499
150
450
2125
475
350
623
112
3814
574
156
2105
1058
650
1189
1885
950
1684
779
541
705
344
664
1052
787
1738
110
110

(+)- Positive  
(RSTV) Non specific T Wave Abnormalities

(-) Negative  
(CXZ) Complexes

(ND) Not Done



scale
LDH
566
1691
230
278
2016
900
463
631
655
56
2461
90
750
850
1100
730
131
1102
950
1300
950
850

(+)- Positive  
(RSTV) Non specific T Wave Abnormalities

(-) Negative  
(CXZ) Complexes

(ND) Not Done

CXR	HRCT Lung	BAL				ECG	ECHO	EMG	Muscle Biopsy	CRP (Normal <6mg/l)	PFT	Urine Routine
		Inflammatory Cells (Lymphocytosis, Neutrophils)	AFB	Gram Stain	Culture							
N	Lower Zone, Ground glass opacity present	+	-	-	-	NSTW	Mild AR +	Myopathic Pattern +	Perifascicular atrophy perivascular inflammatory infiltrates +	>6	RP	N
N	Bilateral ground glass opacity with bronchiectatic changes +	+	-	-	-	P Pulmonale +	RA, RV Dilated	N	N	N	RP	N
N	Bilateral lower zone opacity +	+	-	-	-	N	N	N	N	>6	RP	N
N	N	-	-	-	-	NSTW	N	Myopathic Pattern +	N	N	Poor Flow	N
N	N	+	-	-	-	NSTW	N	Myopathic Pattern +	N	N	N	N
N	N	-	-	-	-	NSTW	N	Myopathic Pattern +	N	N	N	Alb 1+, 1-2 Deposits
N	N	ND	ND	ND	ND	Juvenile Twave inversion	N	Myopathic Pattern +	ND	>6	ND	N
N	N	ND	ND	ND	ND	N	N	Myopathic Pattern +	N	>6	ND	N
N	N	-	-	-	-	N	-	Myopathic Pattern +	Muscle Degeneration +/- regeneration/ perivascular inflammatory infiltrates +	>6	N	N
N	Sub pleural down class opacity noted in the Lt lower lobe posterolateral segment	Inflammatory cells +	-	-	-	N	-	Myopathic Pattern +	N	>6	RP	N
N	N	+	-	-	-	N	N	Myopathic Pattern +	Focal perifascicular atrophy and lymphocytic infiltration +	>6	N	N
N	N	-	-	-	-	Non specific ST/T wave changes +	N	Myopathic Pattern +	N	>6	Poor Flow	N
N	Ground glass opacity in both postero basal segment +	+	-	-	-	N	N	N	Mild atrophy minimal inflammatory cells present	>6	RP+OP	N
N	ND	ND	ND	ND	ND	N	N	N	N	N	ND	N
N	Rt pleural effusion Lt upper low ? Consolidation	Lymphocytosis +	-	-	-	N	Moderate MR present	Myopathic Pattern +	Inflammatory infiltrates +	N	RP+OP	N
N	N	+	ND	ND	ND	N	N	N	N	>6	N	N
Cardiomegaly +	N	-	-	-	-	Low Voltage Cxs	Mild PE + Global hypokinesia +, EF34%	N	N	N	N	N
Lowerzone opacity +	N	-	-	-	-	NSTW	N	N	N	N	N	N
Bilateral pleural effusion +	Bilateral pleural effusion +	-	-	-	-	NSTW	N	Myopathic Pattern +	N	>6	RP	10-15 Puscells
N	N	-	-	-	-	N	TR Mild	Myopathic Pattern +	N	>6	N	Alb 1+, 1-2 Deposits
N	Lt Lower lobe ground glass opacity with bronchiectatic changes +	+	-	-	-	N	N	Myopathic Pattern +	Myophagocytosis perifascicular, interstitial inflammation +, Regenerating fibers +	>6	RP+OP	N
Bilateral upper zone haziness +	Bilateral apical fibrosis, ground glass opacity in basal segment both lower lobes with bronchiectatic changes	+	-	-	-	N	N	Myopathic Pattern +	Inflammatory cells +, regenerating muscle fibers seen, EMG myopathic pattern	>6	RP	N
N	Reticulo nodular pattern in Rt lower lobe basal segment	ND	ND	ND	ND	N	N	Myopathic Pattern +	Inflammatory cells with perifascicular atrophy, perivascular infiltration +	N	RP	N
Cardiomegaly +	N	-	-	-	-	N	MR Mild	Myopathic Pattern +	ND	>6	N	Alb 2+
N	N	N	N	N	N	N	N	N	N	>6	N	Alb 2+
N	ND	ND	ND	ND	ND	N	N	Myopathic Pattern +	ND	>6	ND	N
N	Bilateral honey combing	Inflammatory Cells Present	-	-	-	N	N	N	N	>6	N	N
N	Bilateral lower zone opacity +	Inflammatory Cells Present	-	-	-	N	N	Myopathic Pattern +	Inflammatory cells with perifascicular atrophy, perivascular infiltration +	>6	N	N

(+)- Positive  
(RSTV) Non specific T Wave Abnormalities

(-) Negative  
(CXZ) Complexes

(ND) Not Done

CXR	HRCT Lung	BAL				ECG	ECHO	EMG	Muscle Biopsy	CRP (Normal <6mg/l)	PFT	Urine Routine
		Inflammatory Cells (Lymphocytosis, Neutrophils)	AFB	Gram Stain	Culture							
N	N	N	-	-	-	N	N	Myopathic Pattern +	ND	N	N	N
Bilateral increased BVM +	Lt lung ground glass opacity +	Present	-	-	-	N	N	Myopathic Pattern +	Inflammatory cells present diffuse	N	Poor Flow	N
Increased BVM	Bilateral reticulo nodular pattern +	Present	-	-	-	N	Mild MR TR	Myopathic Pattern +	Inflammatory cell, Muscle atrophy +	>6	RP	Alb 2+
N	ND	ND	ND	ND	ND	N	N	Myopathic Pattern +	Inflammatory cells +, with perivascular atrophy, perivascular infiltration +	>6	N	N
N	Lt. upper lobe nodular opacity +, ground glass opacity + on Rt side, Thickened septum +	Present	-	-	-	N	Mild PE +	Myopathic Pattern +	N	N	RP	N
CT ratio >0.5	N	N	-	-	-	N	Mild PE +, Mild MR +	Myopathic Pattern +, No spontaneous activity	N	N	N	N
Bilateral mid zone infiltrates +	Honey combing in basal segment of Both lower lobes, reticular opacity in Rt upper lobe	Present	-	-	-	N	Main pulmonary artery dilated, Atrial septal aneurysm with intact IAS	Myopathic Pattern +	Inflammatory cells +	>6	RP	N
N	ND	ND	-	-	-	N	N	Myopathic Pattern +	Myophagocytosis perivascular, interstitial inflammation +, Regenerating fibers +	>6	ND	N
N	N	ND	-	-	-	N	N	Myopathic Pattern +	Inflammatory cells +	N	RP	Alb 2+
CT ratio >0.5	Bilateral honey combing +	Present	-	-	-	NSTW	N	N	N	>6	RP	N
CT ratio >0.5	Lt lower zone ground glass opacity +, Rt. Lung fibrotic strands +	Present	-	-	-	NSTW	N	Myopathic Pattern +	Perivascular atrophy perivascular inflammatory infiltrates +	>6	RP	N
N	N	N	-	-	-	NSTW	N	Myopathic Pattern +	N	Neg	N	N
N	Bilateral sub pleural opacity +, Suggestive of early ILD	Present	-	-	-	NSTW	N	Myopathic Pattern +	N	>6	N	N
N	N	-	-	-	-	NSTW	N	Myopathic Pattern +	N	Neg	N	N
N	N	N	-	-	-	NSTW	N	Myopathic Pattern +	N	>6	N	N
N	ND	ND	ND	ND	ND	NSTW	N	Myopathic Pattern +	N	>6	ND	N
N	Bilateral ground glass opacity noted in the medial segment Rt. Middle lobe	Present	-	-	-	N	N	Myopathic Pattern +	N	>6	RP	N
N	Bilateral lower zone opacity +	Present	-	-	-	N	N	Myopathic Pattern +	Inflammatory cells +, perivascular region, Muscle fibres, regeneration, degeneration +, perivascular atrophy +	>6	RP	N
N	N	N	-	-	-	LVH +	LVH	Myopathic Pattern +	N	>6	RP	N
N	ND	ND	ND	ND	ND	N	N	Myopathic Pattern +	N	>6	ND	N
N	Effusion Rt side fibrosis of 6th basal segment Rt lower lobe	Present	-	-	-	N	N	Myopathic Pattern +	N	Neg	Poor Flow	Alb 3+ Dep+
N	Rt. Lower lobe postero basal segment nodular opacity +, suggestive of interstitial pneumonitis	Present	-	-	-	N	N	N	N	>6	N	Alb 2+ Dep+

(+) Positive  
(RSTV) Non specific T Wave Abnormalities

(-) Negative  
(CXZ) Complexes

(ND) Not Done



RF
-
+
-
-
-
-
-
-
-
-
-
-
-
+
-
-
-
+
-
-
-
-
-

(+)- Positive  
(RSTV) Non specific T Wave Abnormalities

(-) Negative  
(CXZ) Complexes

(ND) Not Done

## **ABSTRACT**

### **BACK GROUND:**

Inflammatory Myopathies are a group of auto immune hetrogenous muscle disorders with prominent system involvement. The Cardio pulmonary complication of inflammatory myopathies usually results in increased morbidity and mortality.

### **AIM**

To find out the various cardio pulmonary manifestation in inflammatory myositis

### **MATERIALS AND METHODS**

The cross sectional study was conducted from February 2011 to January 2012 in the Department of Rheumatology, Madras Medical College, Chennai-3. 50 Patients fulfilled inclusion criteria, Bohan & Peter criteria for idiopathic inflammatory myositis and myositis overlap syndromes. All the Patients are subjected to clinical examination, CBC, RFT, LFT, CRP, RF, Muscle enzymes (CPK, LDH, SGOT, SGPT) ECG, ECHO, PFT, HRCT Lung, CXR, Broncho Alveolar Lavage (BAL), auto antibody profile (ANA, ENA Profile), muscle biopsy, ultra sound abdomen and EMG studies.

### **RESULTS:**

In our study 68% were Female, 16% were Male, 10% were Female children and 6% were Male children. Mean age for females (33.9 years), males (43.12 years), Male children (9.3 years), Female children (15.6 years). The prevalence of overlap myositis 60%, SLE myositis overlap 65%, ANA

positivity 83%, ANA speckled 55%, muscle enzymes elevated 67% , HRCT Lung 50% showed ILD, PFT abnormal in 54.5%, BAL 57.5% abnormal, nonspecific ST T-wave changes 44%, EMG 78% myopathic pattern, CRP (62%) and ESR (60%) elevated.

### **CONCLUSION:**

Inflammatory myositis is more common in females, myositis is more common in overlap syndromes, ILD was seen in 50% of the adult patients, a symptomatic ECG abnormalities was common. BAL Showed inflammatory cells in 57.5% .

### **KEY WORDS:**

Inflammatory myositis, Overlap syndromes, SLE, ILD,