

Is Celiac disease associated with Cryptogenic Chronic Liver Disease and Non-cirrhotic Intra- hepatic Portal Hypertension

**A dissertation submitted in partial fulfilment of the requirements
for DM (Branch IV, Gastroenterology) examination of the Tamil
Nadu Dr. M.G.R. Medical University, Chennai to be held in
August 2011.**

CERTIFICATE

This is to certify that this dissertation entitled 'Is Celiac disease associated with Cryptogenic chronic liver disease and Non-cirrhotic Intra-hepatic Portal Hypertension' is a bonafide work done by Dr. Rakhi Maiwall in partial fulfilment of rules and regulations for DM (Branch IV- Gastroenterology) examination of the Tamil Nadu Dr. MGR Medical University, to be held in August 2011.

Dr. Ashok Chacko MD,DM ,MNAMS,FRCP,FIMSA

Professor and Head

Department of Gastrointestinal Sciences

Christian Medical College, Vellore

Place:Vellore

Date:

CERTIFICATE

This is to certify that this dissertation entitled 'Is Celiac disease associated with Cryptogenic chronic liver disease and Non-cirrhotic Intra-hepatic Portal Hypertension' is a bonafide work done by Dr. Rakhi Maiwall in partial fulfilment of rules and regulations for DM (Branch IV-Gastroenterology) examination of the Tamil Nadu Dr. MGR Medical University, to be held in August 2011.

Dr George Chandy MD,DM,PhD,FRCP,PGDHA

Retired Professor and Head of Hepatology unit,

Department of Gastrointestinal Sciences,

Christian Medical College, Vellore

Place: Vellore

Date:

ACKNOWLEDGEMENT

I wish to place on record my sincere gratitude to Dr. George Chandy, Retired Head, Department of Hepatology for guiding me in this thesis.

I sincerely thank Dr. C. E. Eapen, Professor of Gastroenterology and Hepatology, for his continuous support and inspiration during this work.

I sincerely thank Dr. Banumathi Ramakrishna, Professor of Pathology for her valuable expert opinion in the diagnosis of NCIPH cases.

I sincerely thank Dr Anna Pulimood for her meticulous analysis of histo-pathology of duodenal biopsies study samples and in the diagnosis of celiac disease.

I also sincerely thank Dr Gagandeep Kang for her valuable support for helping me to conduct analysis of gut permeability in this group of patients.

My sincere thanks to Dr Ashish Goel for his continuous support and help in my work all throughout.

Special thanks to Dr. Sudhir babji in helping me to do the special tests, Dr L. Jayseelan for his advice and assistance for statistical analysis, Miss Sophiya for her kind laboratory assistance.

INDEX

Topic	Page No
• INTRODUCTION -----	6-7
• AIMS -----	8
• REVIEW OF LITERATURE -----	9-28
• METHODOLOGY -----	29-35
• RESULTS -----	36-49
• DISCUSSION -----	50-54
• CONCLUSIONS -----	55-56
• BIBLIOGRAPHY -----	57-66
• APPENDIX – PROFORMA -----	67-69
• CONSENT FORM -----	70-71

INTRODUCTION

Celiac disease is both a food intolerance and autoimmune disorder. Celiac disease is a kind of permanent intolerance to the storage protein “gluten” in wheat, rye and barley.⁷

It is a chronic inflammatory state of predominantly the proximal small intestinal mucosa which resolves after gluten containing food are excluded from the diet and usually returns back when gluten is reintroduced.⁷ There are complex mechanisms of both adaptive and innate immune system involved, which result in atrophy of the small intestinal villi, deepening of the crypts, and infiltration of the lamina propria with intra-epithelial lymphocytes.

Idiopathic Non-Cirrhotic Intra-hepatic Portal Hypertension (NCIPH) defines one or more entities characterized by intra-hepatic portal hypertension and preserved liver function.^{18,19,20} This definition encompasses a number of entities including Non-Cirrhotic Portal Fibrosis(NCPF), Idiopathic Portal Hypertension (IPH), Nodular Regenerative Hyperplasia(NRH), partial nodular transformation, incomplete septal cirrhosis, hepato-portal sclerosis and benign intra-hepatic portal hypertension and is sometimes difficult to differentiate from well-compensated cirrhosis. This excludes causes like extra-hepatic portal vein obstruction and Budd Chiari Syndrome.

The etio-pathogenesis of NCIPH is still poorly understood. A number of hypotheses have been proposed in the past. Arsenic toxicosis from contaminated drinking water has also been proposed as an etiological factor for NCIPH in India.²⁰ Infective hypothesis has also been put forward with the possibility of umbilical sepsis, bacterial infection and diarrheal episodes in infancy and early childhood leading to portal pyemia, pylephlebitis resulting in thrombosis, sclerosis and obstruction of small and medium sized portal vein radicals.²¹

A few reports have documented the association of celiac disease and idiopathic NCIPH.³ The hypothesis of gut derived prothrombotic factors causing prothrombotic state was suggested of which IgA Anticardiolipin antibody was a potential candidate.³

In a retrospective analysis of prognostic indicators in 34 NCIPH patients, which was done to postulate that gut-derived prothrombotic factors may contribute to the pathogenesis of the disease in which five of 31 (16%) patients tested, had celiac disease.¹

We aimed to study the spectrum of celiac disease in patients with idiopathic non-cirrhotic intrahepatic portal hypertension (NCIPH)/cryptogenic chronic liver disease and to compare them with patients of chronic liver disease of known cause (Hepatitis B and Hepatitis C related).

We also aimed to see the effects of gluten free diet in patients who have chronic liver disease.

AIMS AND OBJECTIVES

The hypothesis is that gut disorders predispose to NCIPH. Celiac disease is reported to be associated with NCIPH. In our centre, 50% of pts labelled as cryptogenic CLD are found to have NCIPH, after complete evaluation.²

Our aim was to study the spectrum of celiac disease in patients with idiopathic non-cirrhotic intrahepatic portal hypertension (NCIPH)/cryptogenic chronic liver disease, and to see the effects of gluten free diet in patients with celiac disease and chronic liver disease.

REVIEW OF LITERATURE

NON-CIRRHOTIC INTRAHEPATIC PORTAL HYPERTENSION:

Historical Background:

During 1884 to 1910, Banti in Italy proposed the disorder *morbus banti*, which is characterized by primary cryptogenic splenomegaly and anemia not associated with any known hematologic disease.¹⁰ In 1954, Tisdale et al described four patients with portal hypertension and massive bleeding from esophageal varices in whom neither intra hepatic nor extra hepatic portal obstruction was found.²²

Later Ramalingaswami et al in India (in 1962) noticed a similar disease while studying autopsy materials and characterized the histological lesion as obliterative portal venopathy.²³ In 1969, the title “non-cirrhotic portal fibrosis’ was officially adopted at a workshop organized by the Indian Council of Medical Research. Mikkelsen et al in Los Angeles described 35 patients with splenomegaly and non-cirrhotic portal hypertension, in whom phlebosclerotic processes were apparent in the intra and extra hepatic portal venous system and called the disease as “ hepato portal sclerosis.”²⁴

With similar publications coming from various countries it is established that this entity (called with different names) does exist throughout the world, being more common in developing countries. The various names that are synonymously used are Hepatoportal sclerosis, NCPF, obliterative portal venopathy, Non-cirrhotic intra hepatic portal hypertension and idiopathic pre-sinusoidal portal hypertension.

Epidemiology:

NCIPH has been reported to be common in socioeconomically disadvantaged people in India. The incidence of NCIPH has not been prospectively studied in India. Most of the

services from different parts of India show a male predominance of 2:1 to 4:1.^{12,15,16} In Japan, IPH was more common in older females with a female to male ratio of 3:1 and an average age of 40.6 years.²³

In a study from North India it was reported that NCPF is on decline in India.²⁵ But a recent study from our centre documented NCIPH as a common cause of cryptogenic intrahepatic portal hypertension.² In a retrospective analysis from June 2005- June 2007, of 517 patients who underwent liver biopsies at our centre, 227 had portal hypertension and 62 of these patients had no documented cause of liver disease prior to biopsy. Causes identified after liver biopsy in these 62 patients were: idiopathic NCIPH (30 patients - 48%), cirrhosis (14), fatty liver disease (7) and other causes (11).

Etiology:

Etiopathogenesis of NCIPH is poorly understood and a number of hypotheses have been proposed.

Infective hypothesis:

Abdominal infection have been considered as a cause which can lead to portal pyemia and pylephlebitis, resulting in sclerosis, obstruction and thrombosis of small and medium sized portal vein radicals.^{26,27}

Experimental studies

Changes of NCIPH have been reported after injection of dead non-pathogenic colon bacilli into the portal vein of rabbits and dogs and after repeated injections of *Escherichia coli*.²⁷

Exposure to Chemicals:

Histological features of NCPF have been observed following chronic exposure to arsenic, vinyl chloride monomers, copper sulfate, protracted treatment with methotrexate, hyper-vitaminosis A and in recipients of renal allografts who received treatment with 6-mercaptopurine, azathioprine.²⁸

Immunological and immunogenetic hypotheses:

A reduction in the suppressor/cytotoxic T lymphocytes in NCPF patients has been proposed.²⁹ Genetic predisposition to NCPF has not been reported.

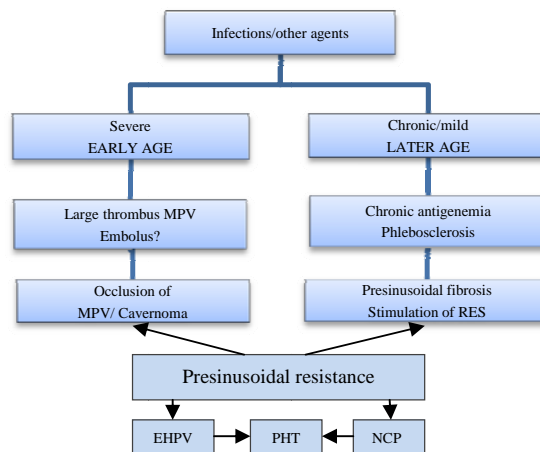


Figure 1: Etiopathogenesis of NCIIPH

Prothrombotic disorder:

In a retrospective study of 28 NCIIPH patients, prothrombotic disorders were detected in 12(48%) patients.⁸ The disorders found were protein C and S deficiency, myeloproliferative disorder and APLA syndrome.

There were two case reports of NRH (Nodular regenerative hyperplasia) associated with IgA aCL and evidence of poorly compliant celiac disease.³ There was a suggestion that T cell help from gluten specific T cells is responsible for driving the IgA autoantibody response to both transglutaminase and protein/phospholipid complexes, leading to the formation of IgA aCL. IgA aCL then can initiate thrombosis in small portal vein radicles, which drain the small intestine which is inflamed.

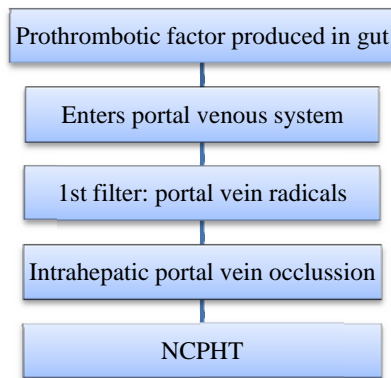


Figure 2: Pathogenesis of prothrombotic risk factors leading to NCPHT

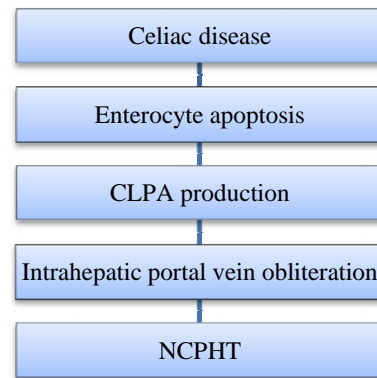


Figure 3: NRH of the liver and celiac disease: potential role of CLPA(IgA anticardiolipin antibody)

An association between celiac disease, NCIPH and IgA–anticardiolipin antibodies was first reported by Austin et al in a report of 2 cases. The above hypothesis was proposed.

In another study, which was a retrospective analysis of 34 patients followed up for 88 months (2-271 months) to look at the associated gut diseases and prothrombotic factors in patients of NCIPH, celiac disease was diagnosed in 5 of 31 NCIPH patients (16% of tested) and ulcerative colitis in 3 of 34 (9% patients) supporting the previous hypothesis of Austin et al of gluten induced enterocyte apoptosis causing obliteration of small portal venous radicles.¹ It was also seen that there was a significantly higher prevalence of elevated serum CLPA antibody (36%) and higher titres of serum CLPA antibodies, when elevated, seen in NCIPH patients as compared to controls i.e. Budd Chiari Syndrome (1/16) and patients of celiac disease without liver disease(0%).¹

In the same study, it was also noted that, of 34 patients of NCIPH 18 developed liver failure of which 13 either died or underwent liver transplantation, demonstrating that NCIPH is not a benign condition. Hepatic encephalopathy, older age at first presentation with NCIPH, portal vein thrombosis and celiac disease were predictors of reduced transplant-free survival.¹

Natural history of NCIPH:

The survival curve for patients with NCIPH is somewhat between that for those with cirrhosis and for a healthy population of comparable age.³⁰ Good prognostic features in patients with NCIPH, a 2 and 5 year survival of nearly 100% after successful eradication of esophagogastric varices, have been described.³¹

Hillaire et al⁸ reported death in 4 out of 28 patients with NCIPH owing to terminal liver failure. Development of PVT in a patient with NCIPH may be a significant factor for poor prognosis, and ascites may indicate a deterioration of the condition in patients with NCIPH. Furthermore, PVT and ascites may be mutually related in this disease.

Histopathology of NCPF/IPH

Laboratory features:

Patients usually have preserved hepatic function. The tests of liver function are normal. Pancytopenia is found in the majority of patients. Anemia may be microcytic, hypochromic (due to GI blood loss) or normocytic, normochromic (due to hypersplenism).³² Leucopenia(<4000/cumm) and thrombocytopenia (platelets <50,000/cumm) may also be present due to hypersplenism.

Imaging:

Ultrasonography shows a dilated and patent splenoportal axis with significantly thickened walls of the portal vein and the main branches. Doppler studies are helpful in identifying an occasional patient who has a thrombus in the intrahepatic branch of the portal vein.³³

Endoscopy:

Esophagogastric varices are seen in 85-95% of patients who have NCIPH. Furthermore, patients with NCIPH have large varices more often (90%) compared with cirrhotic patients (79%).

Hemodynamics in NCPF/IPH:

The portal vein pressures are elevated markedly in patients who have NCIPH. Two pathoanatomic sites of obstruction have been identified. A pressure gradient exists between the spleen and the liver (intrasplenic pressure – intrahepatic pressure [IHP]) and another exists between the IHP and the wedge hepatic venous pressure (WHVP) [IHP – WHVP].

Generally, the WHVP is normal or only slightly elevated in NCPF. Variceal pressure also has been studied in these patients and is comparable to that in cirrhotic portal hypertension.³⁴ Intravariceal pressure measurement is considered as the indicator of portal pressures in these patients.

HISTOPATHOLOGICAL FEATURES OF NCIPH

Autopsy liver- Gross examination may reveal a normal, enlarged, or even shrunken liver. Subcapsular septation is seen with normal architecture of deep parenchyma. Sclerosis of large

to small intrahepatic portal vein branches and approximation of portal tracts to surface has been documented.^{78,79,80} Histological features noted in autopsies include increased portal collagenous connective tissue and sclerosis and obliteration of small branches of portal veins in most cases.³² This histological hallmark of NCPF was termed *obliterative portal venopathy* by Nayak and Ramalingaswami. Intimal fibrosis and elastosis can also occur, leading to subendothelial thickening of the walls of large- and medium-sized portal vein branches causing luminal compromise. Veins may be thickened to the extent that they resemble an artery. Mild inflammation is seen in a few cases.

Needle biopsies-Biopsy material may show only mild and subtle changes from normal. These changes include obliterated and fibrosed portal tracts and obliterated veins, or fibrous expansion of portal tracts.³² Alternatively there may be dilatation of vessels in or near portal tracts, with vessel-like dilatation of sinusoids. Ludwig et al studied the changes in 25 liver biopsies. Changes in the portal tract included capillary dilatation, phlebosclerosis, and fibroelastosis of the stroma. Portal vein dilatation is also seen.^{78,79,80}

Wedge biopsies- Wedge biopsies show changes similar to autopsy material, but changes in medium and large portal vein branches may not be seen if not sampled adequately.³² A deep-core wedge biopsy (not broad-based wedge) along with a needle biopsy should be taken, as they would complement each other.

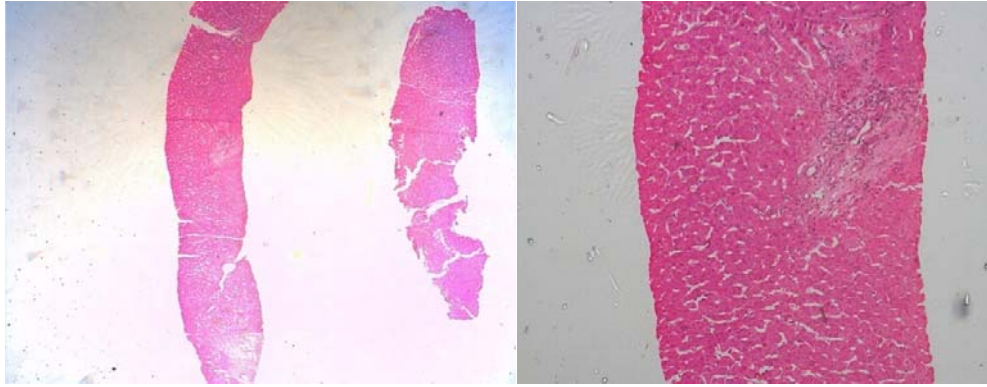


Figure 4: Long core showing fibrotic septa without cirrhosis

Figure 5: Fibrosis around the portal tract plastic venule

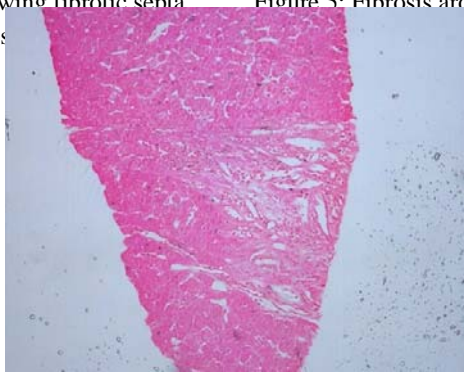


Figure 6: Angiomatosis

CELIAC DISEASE:

It is characterized by a chronic inflammation of the proximal small intestinal mucosa that improves when foods containing gluten are excluded from the diet and returns when these foods are reintroduced. There are complex adaptive and innate immune reactions which result in chronic inflammation. There is diffuse atrophy of the small intestinal villi, (varying from mild to complete atrophy) deepening of the crypts and infiltration of the lamina propria and intraepithelial compartments with chronic inflammatory cells.

Pathology:

There are varying degrees of inflammation and histological changes that occur in patients with celiac disease on a gluten containing diet. A progression in the mucosal injury was

described by Marsh et al which has evolved into a grading of histologic damage that reflects the varying degrees of villous atrophy and inflammatory changes seen in duodenal biopsies of these patients. The presence of increased intraepithelial lymphocytes only (Marsh grade 1), is not specific for celiac disease.^{35,36} Many of these patients are asymptomatic but some of these patients may have diarrhea that resolves with a gluten-free diet.³⁷

Pathogenesis:

Gluten

Celiac disease is an autoimmune disease secondary to dietary ingestion of gluten. Gluten encompasses the proteins derived from wheat, barley and rye. These proteins contain glutamines and prolines that undergo only partial digestion in the upper gastrointestinal tract, resulting in peptide derivatives. It is a 33–amino acid peptide sequence from a gliadin that survives digestion and contains several motifs that are especially immunogenic to the celiac intestine.³⁸ It is the persistence of highly immunogenic peptides and their passage through the epithelial barrier which reach antigen-presenting cell in the lamina propria of the intestine.

Mucosal Immune Response

Both innate and adaptive immune responses are seen. The adaptive response is mediated by gluten-reactive CD4₊ T cells in the lamina propria that recognize certain gluten derived peptides when they are presented by the HLA class II molecules DQ2 or DQ8. These cells then produce proinflammatory cytokines. Glutamine residues in the gluten peptides undergo deamidation with the formation of a negatively charged glutamic acid residue, the resulting peptide can bind in the binding groove of the DQ2 or DQ8 molecules with a higher affinity. Tissue transglutaminase (tTG) in the intestine performs targeted deamidation. T cells which

are activated by gluten henceforth produce interferon gamma and other proinflammatory cytokines causing inflammatory response and damage the intestinal mucosa.

SPECTRUM OF CELIAC DISEASE :

Table 1: Clinico-pathologic spectrum of Celiac Disease⁷

Type	Spectrum
Classic	It is the most commonly described form. These are the patients with classic features of intestinal malabsorption and have fully developed gluten-induced villous atrophy and other classic histologic features. They present because of GI symptoms.
Atypical	It appears to be the most common form. They generally have little or no GI symptoms but come because of other reasons such as iron deficiency, osteoporosis, short stature or infertility. They have fully developed villous atrophy. Because these are ‘asymptomatic’ from the GI perspective, majority go undiagnosed.
Silent	It refers to asymptomatic patients who are discovered to have gluten induced villous atrophy. They are found after serologic screening or perhaps during endoscopy and biopsy for other reasons. They are clinically silent because in that they do not manifest any clear GI symptoms or associated atypical features of celiac disease such as iron deficiency or osteoporosis.
Latent	It represents patients with a previous diagnosis of celiac disease that responded to GFD and who retain a normal mucosal histology or manifest only an increase in intra-epithelial lymphocytes. It can also represent patients with currently normal mucosa on a gluten-containing diet who will subsequently develop celiac disease.

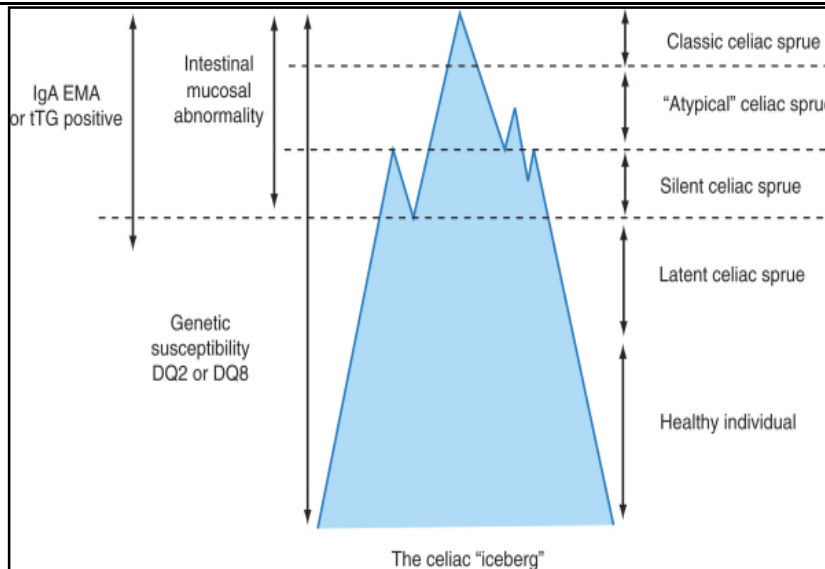


Figure 4: The Celiac Disease iceberg model

Diagnosis:

ESPGHAN CRITERIA:

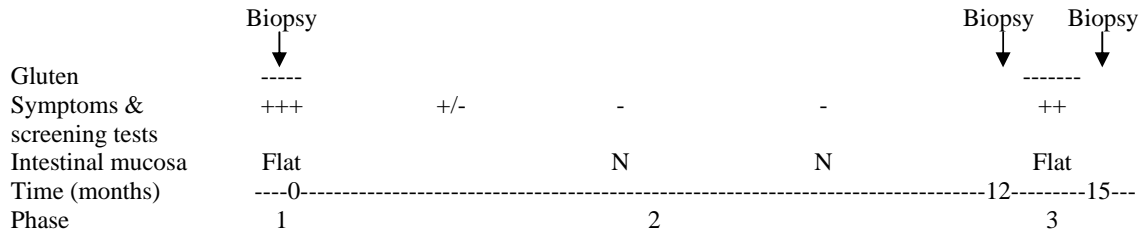


Figure 5: Celiac Disease diagnostic protocol proposed by ESPGHAN in 1970.

REVISED ESPGHAN CRITERIA:

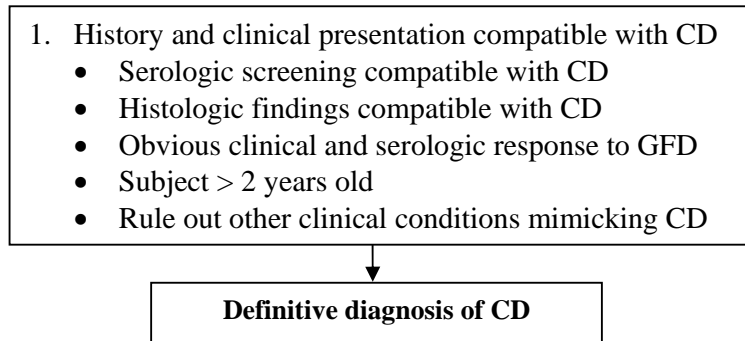


Figure 6: Revised criteria for the diagnosis of Celiac Disease.

SEROLOGY :

The various serologic tests used for detecting celiac disease include antigliadin antibodies (AGA), EMA and Anti-tTG antibodies (tTGA).

EMA. EMA is measured using an immunofluorescence technique with monkey esophagus or human umbilical cord as the tissue substrate. The pooled sensitivity of the test is 97.4% (95% confidence interval [CI]- 95.7–98.5), and the pooled specificity is 99.6% (95% CI, 98.8 – 99.9) using monkey esophagus as substrate.^{38,39}

The specificity of the IgA EMA using human umbilical cord (HU) as substrate in adults has been reported as 100% in nearly all the studies with sensitivity, ranging from 87% to

100%. The pooled sensitivity and specificity of this test were 90.2% (95% CI, 86.3–92.5) and 99.6% (95% CI, 98.4 –99.9), respectively.

tTGA. tTGA is measured by quantitative enzyme linked immunosorbent assay (ELISA) with guinea pig liver (GP) or human recombinant or red cell–derived tTG as the substrate.

IgA tTGA-GP. Studies have revealed variable results with the overall sensitivity close to 90%³⁸ and specificity was 95.3% (95% CI, 92.5%– 98.1%)

.IgA tTGA-HU. Most commercial tests use human recombinant or red blood cell– derived tTG as substrate. The pooled sensitivity and specificity of IgA tTGA-HU were 95.1% (95% CI, 91.8%–98.1%) and 98.3% (95% CI, 97.1%–99.6%), respectively in adults. There does not appear to be a major difference between tests that use recombinant tTG and those that use tTG derived from red blood cells.³⁸ Overall, the specificity of IgA tTGA is greater than 95% with a sensitivity in the range of 90%–96%. False-positive results of the IgA tTG-HU (e.g., in patients with liver disease, congestive heart failure, arthritis and inflammatory bowel disease) are less commonly seen now.

IgA AGA. The bulk of the data suggest that the specificity of the IgA AGA approximates 90%.

Disadvantages of the Serological Diagnosis of Celiac Disease in Patients with Chronic Liver Disorders.

The accuracy of serological tests which are used commonly for the diagnosis of celiac disease is decreased in patients with chronic liver disease.¹³ The interpretation of the results has to be done carefully in these patients.

Anti-Tissue Transglutaminase Antibody and Endomysial Antibodies:

With the first-generation tTGA tests which used tTG derived from guinea, pig there were many false positives in patients with chronic liver diseases. This was due to the antigens present in the crude extract of pig liver and probably secondary to immune dysregulation (hypergammaglobulinemia) associated with the underlying disease per se. The specificity and number of false positives could be reduced by use of human tTG sequences.^{13,14,65} However, false positives are rare with these assays but can be seen, in patients with advanced chronic liver disease due to the formation of antibodies directed against tTG in the diseased liver.^{13,14,65} The endomysial antibody indirect immunofluorescence assay has a very high specificity and is a useful test for patients with chronic liver disease.

HISTOLOGY:

A small intestinal mucosal biopsy is currently considered as the gold standard for the diagnosis of celiac disease.^{38,41} The changes in the small intestinal mucosa are usually graded as per the Marsh grading from 0-IV as described below.^{41,42}

Table 2: Marsh grading mucosal biopsy in Celiac Disease⁷

Grade	Histologic feature
Marsh 0	Normal villous and mucosal architecture
Marsh I	Infiltrative Normal villous and mucosal architecture Increased numbers of intraepithelial lymphocytes
Marsh II	Hyperplastic Enlarged crypts and with increased crypt cell division
Marsh III	a. Partial villous atrophy Shortened blunt villi Mild lymphocyte infiltration Enlarged hyperplastic crypts b. Subtotal villous atrophy Clearly atrophic villi, but still recognizable Enlarged crypts c. Total villous atrophy Complete loss of villi Severe crypt hyperplasia, and infiltrative inflammatory lesion
Marsh IV	Hypoplastic Total villous atrophy Normal crypt depth, but hypoplasia Normal intraepithelial lymphocyte count

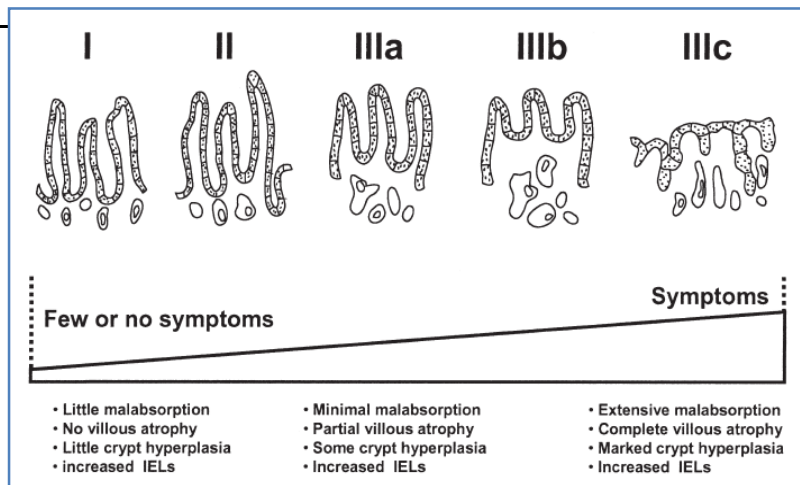


Figure 7: Spectrum of malabsorption and symptoms in celiac disease. The magnitude of malabsorption and symptoms often correlates with extent of mucosal injury.

Mucosal changes can be patchy and hence it is important to take multiple endoscopic biopsy specimens from the proximal small intestine. Many other diseases resemble celiac disease histologically need consideration before a diagnosis of celiac is made.

Treatment:

The treatment of the disease is a gluten-free diet viz. wheat, barley and rye, which could be advised with the help of an experienced dietician. Improvement is noted within few weeks after gluten exclusion. On follow up on GFD after 6 months to 1 year the serologic tests results usually normalize with symptomatic improvement also. Repeat histology is not required in those who have a response to GFD.

Follow up on a Gluten Free Diet(GFD):

Patients should be regularly assessed on GFD by history regarding patient's compliance with the diet and to reinforce for the same by an expert team involving the dietician and clinician. Symptomatic improvement on GFD may not give an accurate assessment of compliance. Repeat serologic testing with monitoring for titres after 6 months or more on a GFD can help in assessing any histologic improvement and compliance with a GFD. It has been seen that the sensitivity of the serologic tests decreases with lower Marsh grades i.e. Marsh grades I and II and serologic tests usually become negative and the titres usually decrease as the findings on histology improve but may not revert to normal.⁴²⁻⁴⁵ Monitoring serologies (i.e., tTGA or EMA) can distinguish between those who are complaint with the noncompliers with diet.⁴⁶⁻⁵¹ In adults the improvement is usually slow as compared to children, which can take more than 2 years and frequently also is incomplete which cannot be explained only with dietary non-compliance.⁵²⁻⁵⁵ In adults, negative serologic test results do not necessarily reflect improvement in histology.⁴⁴

MILD ENTEROPATHY:

In a study by Kurppa et al there was a suggestion that mucosal damage develops gradually and patients may experience clinical symptoms before histologic changes appear. They studied 70 consecutive adults with positive EMA, and of these, 23 had only mild enteropathy (Marsh I–II) and they were randomized either to continue on a gluten-containing diet or start GFD. Forty seven patients (disease controls) had mucosal lesions on duodenal histology compatible with celiac disease (Marsh III). It was further noted that in the gluten-containing diet group (Marsh I–II) the small-bowel mucosal deterioration was seen in all patients, and the symptoms and abnormal antibody titres persisted. In the GFD group (Marsh

I–II) the symptoms were alleviated, antibody titres decreased and mucosal inflammation diminished equally to celiac controls (Marsh III).⁶

In a recent study by Adrian Cummins et al the authors described morphometric changes in duodenal biopsies in untreated and treated subjects with celiac disease with follow-up of 4 years.⁷¹ They looked at the relationship of changes in morphometry to histologic assessment using Marsh criteria, self-reported compliance to a GFD, and changes in celiac serology. The described morphometric changes in duodenal biopsies in untreated and treated subjects with celiac disease after 6, 24, and 48 months of a GFD were 26.3, 52.4, and 63.1, respectively. Further the relationship of Marsh grades to intestinal morphometry was assessed in a subset of subjects who had both Marsh grades and duodenal morphometry. Patients with Marsh grades 0, 1, and 2 showed a reduction in villous area as compared to controls.⁷¹

INTESTINAL PERMEABILITY:

Patients with celiac disease have an increased gut permeability.¹¹ It has been hypothesized that this in genetically predisposed individuals cause an immune response against antigens sharing common epitopes to self liver proteins or cryptic antigens unmasked by dietary gliadin. The mucosal damage which occurs in patients with CD leads to exposure of tissue transglutaminase enzyme, the target antigen in these patients which is recognized by anti-endomysial antibody. The hypothesis has been shown by a study showing deposition of IgA TTG antibody in liver biopsy of two patients with active celiac disease.¹⁰

The permeability can be tested by using lactulose mannitol test. Both are water soluble molecules of which mannitol is easily absorbed while lactulose (larger molecule) is only slightly absorbed. Patients would be asked to drink a solution containing both mannitol and lactulose in fasting state. Urine would be collected for six hours and the amount present in

urine would reflect how much was absorbed by the body. In normal healthy people the test shows high levels of mannitol and low levels of lactulose. In celiac disease there is a reduction in the fractional excretion of mannitol and an increase in that of lactulose with an increase in the lactulose:mannitol ratio which reverses in majority of patients on a gluten free diet.⁵⁹ Increase in permeability is a sensitive test for the presence of gluten in the diet.⁵⁹ Evidence comes from animal studies which have shown that abnormal permeability precedes disease.

In humans there is paucity of data for altered gut permeability prior to the onset of disease.^{56,57} In some studies it has been seen that gluten removal does not totally resolve the underlying defect, reflecting some of the damage is irreversible and an existing alteration in the tight junctions.⁵⁷ In one study about one third of first degree relatives had abnormal permeability.⁵⁸ Approximately 8% of these had a positive endomysial antibody test, underwent biopsy and were demonstrated to have asymptomatic celiac disease but the reason for the abnormal permeability in the remainder was not reported.

LIVER IN CELIAC DISEASE :

The prevalence of celiac disease has been seen in patients of cryptogenic hypertransaminemia (1.5-9%), autoimmune hepatitis (2.9-6.4%), Primary Biliary Cirrhosis-PBC (0-6%) and Primary Sclerosing Chlorangitis-PSC (1.5%). It has also been associated with Non-Alcoholic Fatty Liver Disease-NAFLD (~3.4%).⁶

Table 3: Liver diseases associated with Celiac Disease⁸¹

Isolated hypertransaminemia with parenchymal damage reversible on GFD(celiac hepatitis)
Cryptogenic cirrhosis
Autoimmune liver disorders
Primary biliary cirrhosis
Autoimmune hepatitis: type 1 and type 2
Autoimmune cholangitis
Primary sclerosing cholangitis
Chronic hepatitis C infection/antiviral therapy
Hemochromatosis
Non-alcoholic fatty liver disease(NAFLD)
Acute liver failure
Regenerative nodular hyperplasia
Hepatocellular carcinoma

CELIAC DISEASE AND CRYPTOGENIC CHRONIC LIVER DISEASE /NON-CIRRHOTIC INTRAHEPATIC PORTAL HYPERTENSION:

A retrospective analysis of prognostic indicators in 34 NCIPH patients was done to postulate that gut-derived prothrombotic factors may contribute to the pathogenesis and prognosis of NCIPH. A search for associated gut diseases was also done in which five of 31 (16%) tested had celiac disease.¹

Prevalence of elevated initial serum IgA anticardiolipin antibody (CLPA) was significantly higher in NCIPH (36% of patients tested), compared to Budd–Chiari syndrome (6%) and celiac disease without concomitant liver disease.¹ An association of elevated serum cardiolipin antibodies, non-cirrhotic intrahepatic portal hypertension and celiac disease had been suggested by Austin et al.³ The hypothesis of gut derived prothrombotic factors causing prothrombotic state was suggested, of which IgA-anticardiolipin was a potential candidate.³ Cancado et al (J. of clin gastroenterol, Feb 2006) showed association of hepatopulmonary syndrome and IgA cardiolipin.⁴ A case was reported by M’saddek, who showed celiac disease in a patient of idiopathic portal hypertension (Gastroenterol Clin Biol, Oct 2007) and positive antibodies in 5 patients of celiac disease and nodular regenerative hyperplasia.

Other case reports of association of celiac with NCPIH from India have been published by *B C Sharma et al* who reported 2 cases of celiac disease associated with NCPF.⁶³

In another study of 327 consecutive patients with chronic liver disease for Gliadin antibodies (IgA and IgG). They were detected in 19 patients (6%), a prevalence six times greater than that found in healthy blood donors. In 9 of the 19 patients the etiology of the liver disease was considered as cryptogenic. The occurrence of Gliadin antibody was noted to be independent of the degree of hepatocellular impairment. Small bowel biopsy was done in 5 of the 10 patients in whom the diagnosis of celiac disease was confirmed. The authors suggested that the prevalence of CD in patients with chronic liver disease to be at least 1.5%, that is, 15 times higher than in the general population. They also suggested that the possible presence of CD should be considered in cases of chronic 'cryptogenic' liver disease.⁶⁰

Effect of gluten free diet on liver disease:

The effect of a GFD on halting progression of liver disease associated with CD is presently not clear. A response to gluten free diet with an improvement in clinical manifestations and laboratory abnormalities has been described in both adults and children with advanced liver disease.^{62,63} The general condition, jaundice, ascites, bilirubin, ALT, albumin, and INR improved after 6 months of strict adherence to a GFD in the patients with advanced liver disease and CD. Whether severe histological changes in the liver of patients with CD are reversible is still controversial, but the regression and even reversal of severe fibrosis in a liver biopsy after gluten exclusion has been reported.^{62,64}

In another study done in Finland,⁸ 185 adults who underwent liver transplantation, a dramatic improvement was seen on a gluten free diet (given in 4 untreated patients) and 3 patients were subsequently delisted from the transplant list. A similar case was reported by Ojetti et al.⁹

In a study by Lindgren et al, of the 5 patients diagnosed with celiac disease had a complete normalisation of liver functions on a gluten free diet.⁶⁰

Celiac disease in India :

The overall seroprevalence of celiac disease was 1.44% and the overall prevalence of celiac disease was 1.04% in a recent study from north India.⁶⁷ In another study by Sood et al, amongst school children the prevalence of celiac disease was reported as 0.3 to 1% in 310.⁶⁶

In another study by Lal et al the seroprevalence amongst school children in northern india was reported.

METHODOLOGY

AIM 1: To Study the spectrum of celiac disease in patients of cryptogenic chronic liver disease.

This was a case-control study in which the spectrum of celiac disease was studied in cases i.e. consecutive patients of cryptogenic chronic liver disease or non-cirrhotic intrahepatic portal hypertension and in control group which included patients of chronic liver disease of known etiology i.e. hepatitis B or C related. The period of recruitment was over a period of 2 years (Jan, 2009 to Jan, 2011). The study was approved by Research and Ethics committee (IRB-Institutional Review Board) of the Christian Medical College, Vellore. Patients who did not provide consent or had hepatocellular carcinoma and Budd-chiari syndrome were excluded.

Diagnosis of Celiac disease: In all enrolled patients the evaluation of disease included :

1. Symptoms: i.e. diarrhea, bloating, flatulence, steatorrhea etc using symptom score as per Kurppa et al⁶
 - 0: none
 - 1: slight(occasionally 1 or more of: abdominal pain, diarrhea, tiredness or joint pain)
 - 2: moderate (more persistent, disturbing normal life)
 - 3: severe (severe daily symptoms significant restricting normal life or excess weight loss).

Serology: IgA-TTG antibody with titres at the time of diagnosis. The evaluation of IgA antibody against neo-epitopes of tissue transglutaminase (tTG) in human serum was performed using the commercially available solid-phase enzyme immunoassay kit (ELISA) (AESKULISA Celichek, Germany and AIDA, Germany). The assay employed recombinant

human transglutaminase. Serum samples diluted to 1:101 were incubated in the microplates coated with human recombinant tissue transglutaminase. Patient's antibodies, if present in the specimen, would bind to the antigen. Subsequently the unbound fraction was washed off. Afterwards, anti-human immunoglobulins conjugated to horse radish peroxidase (conjugate) was incubated in the microplates and reacted with the antigen-antibody complex of the samples. Unbound conjugate was washed off. Addition of TMB-substrate generated an enzymatic colorimetric (blue) reaction, which was stopped by diluted acid (color change to yellow). The rate of color formation from the chromogen is a function of the amount of conjugate bound to the antigen-antibody complex and is proportional to the initial concentration of the respective antibodies in the patient sample. The absorbance of resulting product at 450 nm was read within 30 min to determine the optical density (OD). A standard curve was obtained by plotting the OD of each calibrator (y axis) against corresponding concentrations in U/ml(x-axis). From this standard curve, quantitative interpretation of patient's sample in U/ml was obtained for their respective optical densities. The test would be interpreted as titres <15 U/ml as negative, 15-20 U/ml as borderline positive and >20 U/ml as positive.

Anti-cardiolipin antibodies (IgG, IgM and IgA) : Similarly anti-cardiolipin antibodies were detected using the ELISA (Varelisa kit)

Varelisa Cardiolipin (IgM, IgG and IgA) antibodies is an indirect noncompetitive enzyme immunoassay for the semiquantitative and qualitative determination of cardiolipin antibodies in human serum or plasma. The wells of a microplate are coated with bovine cardiolipin antigen. Antibodies (IgM, IgG and IgA) specific for cardiolipin present in the patient sample bind to the antigen. In a second step the enzyme labeled second antibody (conjugate) binds to the antigen-antibody complex which leads to the formation of an enzyme labeled conjugate-

antibody-antigen complex. The enzyme labeled antigen-antibody complex converts the added substrate to form a colored solution. The rate of color formation from the chromogen is a function of the amount of conjugate complexed with the bound antibody and thus is proportional to the initial concentration of the respective antibodies in the patient sample. A standard curve was obtained by plotting the OD of each calibrator (y axis) against corresponding concentrations in U/ml(x-axis). From this standard curve, quantitative interpretation of patient's sample in U/ml was obtained for their respective optical densities. The test would be interpreted as titres <10 U/ml as negative, 10-15 U/ml as equivocal and >15 U/ml as positive.

Duodenal biopsy: The biopsy grading was done according to the Marsh criteria as described above.

Spectrum of disease: It was assessed as follows based on biopsy and serology.

Table 4: Spectrum of disease based on biopsy and serology

Duodenal biopsy (Marsh grade)	IgA-TTG antibody	Spectrum
III/IV	+	Celiac disease
I/II	+	Celiac enteropathy
0	+	Latent celiac disease

Gut permeability: Celiac disease also causes a “leaky gut” with increase in intestinal permeability. The standard test for leaky gut syndrome is the mannitol and lactulose test by HPLC technique. Both are water soluble molecules that the body can't use. Mannitol is easily absorbed by people with healthy intestinal linings. Lactulose is a larger molecule and is only

slightly absorbed. Patients would be asked to drink a solution containing both mannitol and lactulose in fasting state. Urine would be collected for six hours and the amount present in urine would reflect how much was absorbed by the body. A healthy test shows high levels of mannitol and low levels of lactulose. If high levels of both molecules are found, it indicates a leaky gut condition. If low levels of both molecules are found, it indicates general malabsorption of all nutrients. The test would be interpreted as a ratio greater than 0.072 as positive and indicative of increased permeability⁸³

Other tests: For all cases at diagnosis in

CBC

Serum Ferritin/iron studies

Serum Vit. B12 /folate

A/G ratio

This was followed by subjecting these patients on a gluten free diet which would be done by the principal investigator. The patient was asked to avoid wheat made products and all packed items containing “gluten” as ingredient to be avoided.

Evaluation for Chronic liver disease:

Etiological work up of chronic liver disease [Liver profile (AMA, SLA, LKM, SMA), ANA], Wilsons (serum ceruloplasmin), 24-hr urine copper, viral serology, Iron studies.

CTP Score

Liver biopsy with measurement of HVPG where clinically indicated for diagnosis. Patients having a normal HVPG and no evidence of cirrhosis in liver biopsy were considered as non-cirrhotic intrahepatic portal hypertension.

USG Abdomen with colour Doppler

Serum AFP

Gastroscopy: For assessment of varices

AIM 2: To see the effects of gluten-free diet in patients with chronic liver disease. This was a before and after intervention study in which we looked at the effects of gluten-free diet on all patients diagnosed with celiac disease.

Assessment of liver functions at baseline and after a minimum of 3 months of gluten free diet

Liver functions

CTP score

Complications

Ascites

Hepatic encephalopathy

Variceal bleed

Spontaneous bacterial peritonitis

Intestinal functions: At baseline and follow up

Clinical symptoms graded using scoring as per Kurppa et al.

Compliance with gluten free diet⁷⁰

Body Weight

Hemoglobin

Serum Albumin

Intestinal permeability test using lactulose-mannitol test

Titres of Anti-TTG antibody on follow up

Repeat gastroscopy with duodenal biopsy where possible.

The diet was explained by the principal investigator verbally to the patient and was monitored by a detail history on follow up. The patients were asked to avoid all wheat and wheat based products and all packed items containing gluten as ingredient. Compliance to gluten-free diet was defined as follows: (3) = more than one serve of gluten-containing food/week; (2) = up to one serve of gluten-containing food/week; (1) = one serve of gluten in a month; (0) no gluten-containing food/week.⁷⁰

Consent: written informed consent was taken from all enrolled patients for the study.

STATISTICAL ANALYSIS :

Sample size:

Based on the objective to study the association between celiac disease (CD) and cryptogenic chronic liver disease, the study design has been Case Control Study. As the prevalence has been reported to be 30% in the,⁵ cryptogenic chronic liver disease while this has been ~5% in the control group(HBV and HCV related chronic liver disease)¹⁵ and keeping Alpha and Beta errors at 5% and 20%, and expecting 6 times

more association in the group, the cryptogenic chronic liver disease sample size needed is 50 cases and 100 controls. However, looking at recent data and due to financial constraints the sample size was calculated to be kept as 50 cases and controls.

Statistical Methods:

In order to study the association, bivariate analyses were done and the associations were studied using chi-square test (Fisher exact test). A p value of less than or equal to 0.05 was considered statistically significant.

RESULTS

Age and sex distribution:

The mean age of the cases was 43 years and in controls it was 45 years. 77% of the cases and 89% of the controls were males.

Table 5: Age and sex distribution

	CASES Cryptogenic CLD (n=60)	CONTROLS HBV/HCV related CLD (n=59)	p value
Age(yrs)mean(SD)	43 (10)	45(11)	0.27
Sex (M:F)	46:14	53:6	0.08

Geographic distribution:

The majority of patients in cases and controls were from Eastern India. 45 (75%) cases and 46 (78%) controls were from eastern India, 9 (15%) cases and 12 (20%) controls from southern India, 5 (8%) of cases and 0 (0%) controls from northern India, 1 (2%) cases and 1 (2%) control was from western India.

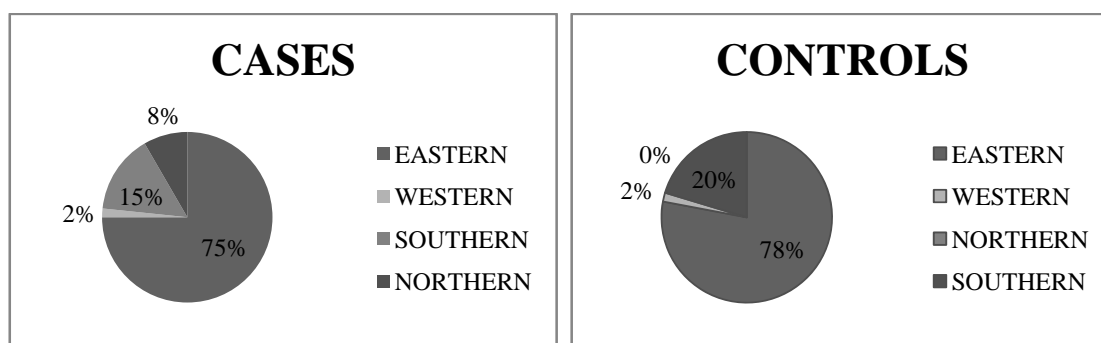


Figure 8: Geographic distribution of cases and controls.

Baseline parameters:

Table 6: Baseline clinical parameters in cases and controls

	CASES Cryptogenic CLD (n=60)	CONTROLS Hep B/C related CLD (n=59)	p value
Past/present Jaundice	14	11	0.66
Ascites	25	30	0.26
Encephalopathy	9	6	0.58
Variceal bleed	18	19	0.69
CTP (A:B:C)	41:12:7	28:20:11	
CTP score- mean(SD)	6(1.9)	7(2.3)	0.01

Table 7: Baseline clinical parameters in cases and controls

	CASES Cryptogenic CLD (n=60)	CONTROLS Hep B/C related CLD (n=59)	p value
Bilirubin (gm/dl)	1.9(4)	2(2.7)	0.89
Protein (gm/dl)	7.5(0.8)	7.6 (0.9)	0.53
Albumin(gm/dl)	3.5 (0.9)	3.2 (0.8)	0.06
Prothrombin time	15 (4.3)	16 (4.4)	0.40
INR	1.2(0.4)	1.3(0.4)	0.10
Creatinine	0.9(0.2)	1.2(0.9)	0.02
Haemoglobin(gm%)	11 (2)	11 (2)	0.74

Evaluation for celiac disease in cases and controls:

IgA-TTG Antibody: In the cases IgA-TTG antibody was positive in 40/58 (69%) of cases however it was positive in 16/59 (27%) controls (p=0.00).

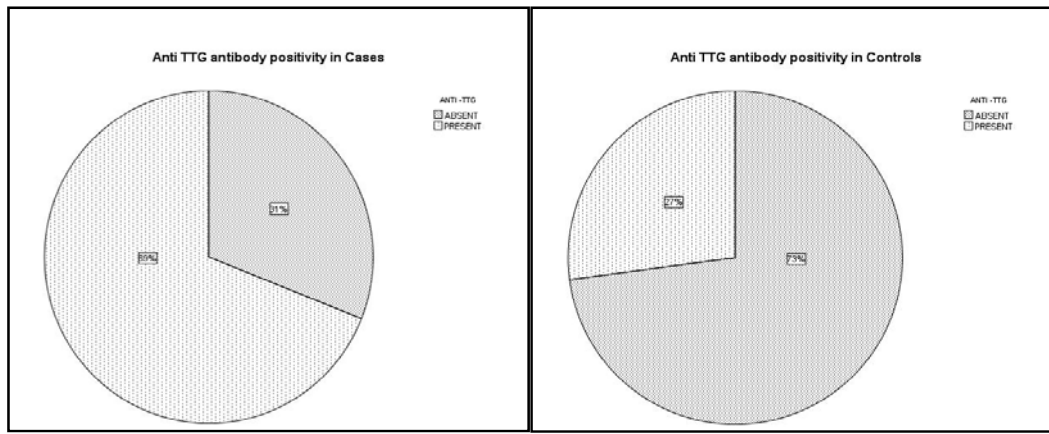


Figure 9: Anti TTG positivity in cases and controls

Duodenal biopsies:

Duodenal biopsies were done in 51 cases and 28 controls. Marsh 0 (normal) were seen in 19/51(37%) cases and 19/28 (68%) of controls. Marsh I seen in 19/51(37%) cases and 8/28 (29%) controls. Marsh II seen in 1/51 in cases and 1/28 of controls. Marsh III changes on duodenal biopsies were seen in 12/51 (24%) of cases and 0/28 (0%) of controls (p =0.002) as depicted in figure 10.

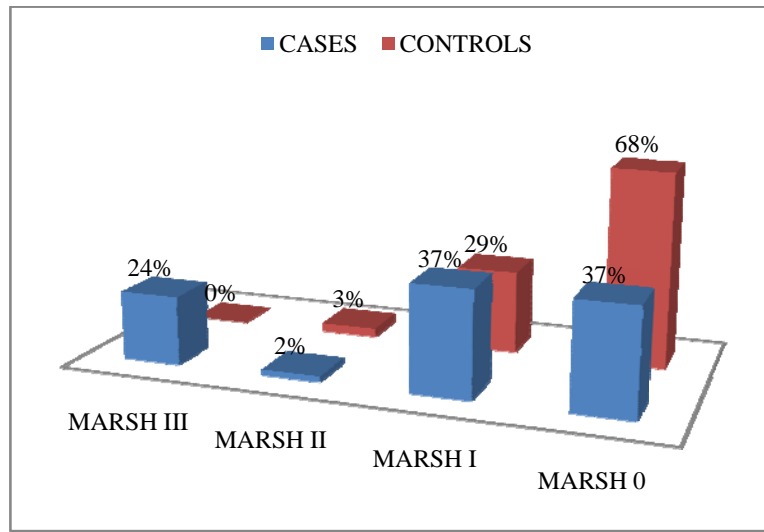


Figure 10: Duodenal histology in cases and controls

IgA-TTG antibody titres were significantly higher in cases as compared to controls, 70 IU/ML(60) and 43 IU/ML(21) respectively($p=0.03$).

There was no correlation seen between the TTG antibody titres and duodenal histology i.e. many patients with normal duodenal biopsies had higher titres as compared to patients who had villous atrophy on duodenal biopsies in both cases and controls (fig 11).

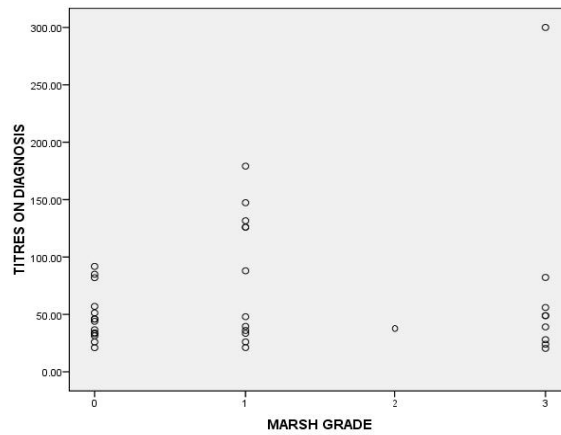


Figure 11: Correlation of Duodenal histology with Anti-TTG titres in cases and controls

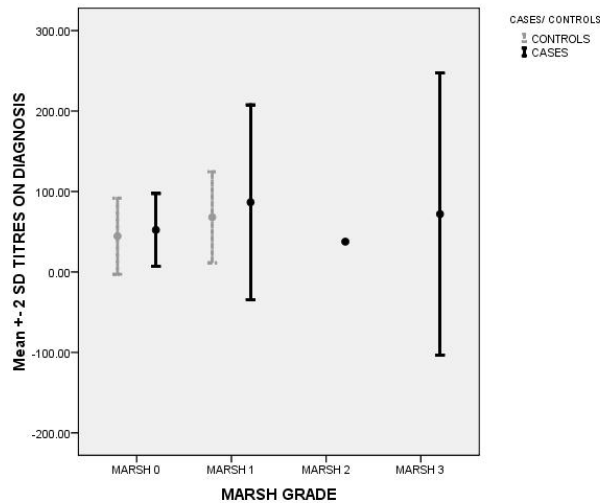


Figure 12: TTG Ab titres (mean +/- 2 SD) vs Marsh grade in cases and controls

Table 8: Celiac serology and duodenal histology in cases and controls

	CASES Crypto. CLD (n=60)		CONTROLS HepB/C rel. CLD (n=59)		p value
	+ve	-ve	+ve	-ve	
IgA-TTG Ab	40/58	18/58	16/59	43/59	0.00
Titres at diagnosis (IU/ML)	70		43		0.03
Duodenal biopsy	Cases (n=51)		Controls (n=28)		
Marsh 0	19	0	7	12	
Marsh I/II	13	7	3	6	
MARSH III	11	1	0	0	0.006
	p value 0.002				

Table 9: Spectrum of Celiac Disease

	CASES Crypto. CLD (n=60)	CONTROLS Hep B/C rel. CLD (n=59)
	Cases who underwent duodenal biopsy (n=51)	Controls who underwent duodenal biopsy (n=28)
Celiac disease	11	0
Celiac enteropathy	13	3
Latent Celiac Disease	19	7

Anticardiolipin antibodies in cases: None of the cases had positive cardiolipin antibodies (IgA, IgG and IgM). The IgA Cardiolipin antibodies were borderline positive in 4 patients. Of these 4 patients , 1 had celiac disease, 2 had celiac enteropathy and 1 had latent celiac disease.(table 10)

Table 10: Anticardiolipin antibodies (IgA, IgG and IgM) in cases (n=28)

Case no.	IgA-TTG Ab (1-> positive 0->negative)	Duodenal biopsy (Marsh grade)	IgA (U/ml)	IgM(U/ml)	IgG(U/ml)
1	1	1	6.76	ND#	ND
2	1	3	8.89	ND	4.38
3	1	1	5.10	ND	ND
4	1	1	13.7	ND	3.73
5	1	3	9.6	ND	ND
6	1	0	9.9	ND	ND
7	1	3	10.09	ND	ND
8	1	1	7.33	ND	5.35
9	1	3	ND	ND	ND
10	1	0	4.89	ND	ND
11	1	3	ND	ND	ND
12	1	0	7.98	ND	4.4
13	1	1	9.4	ND	ND
14	1	0	11.5	ND	4.17
15	1	1	10.98	6.61	ND
16	1	3	5.7	ND	4.76
17	1	1	6.8	ND	ND
18	1	3	8.48	ND	ND
19	1	3	ND	ND	6.32
20	1	3	6.35	6.4	ND
21	1	3	ND	ND	ND
22	0	0	4.13	ND	ND
23	0	3	ND	ND	ND
24	0	-	5.57	ND	ND
25	0	0	8.24	ND	4.03
26	0	0	4.4	ND	ND
27	0	0	ND	ND	ND
28	0	0	ND	ND	ND

ND# below detection threshold

Anticardiolipin antibodies in controls: IgA anticardiolipin antibodies were borderline positive in 4 patients of which 1 had celiac enteropathy, 1 had latent celiac disease, 1 had duodenal biopsy showing Marsh grade I changes but a negative serology and the fourth had negative serology(duodenal biopsy was not done) (table 11).

IgA anticardiolipin antibody was positive in 1 patient who had a negative serology and a normal biopsy. This same patient also had a positive IgG anticardiolipin antibody. This patient had a decompensated chronic liver disease secondary to hepatitis B.

Table 11: Anticardiolipin antibodies (IgA, IgG and IgA) in controls (n=32)

Case no	IgA-TTG Ab (1->positive 0->negative)	Duodenal biopsy (Marsh grade)	IgA(U/ml)	IgM(U/ml)	IgG(U/ml)
1	1	0	4.3	ND#	4.2
2	1	0	11.2	ND	5.18
3	1	0	ND	ND	ND
4	1		5.5	ND	7.9
5	0		6.5	ND	ND
6	0		6.6	ND	ND
7	0		5.15	14.6	4.75
8	0		5.5	ND	5.14
9	1		7.76	ND	6.67
10	1	0	7.57	ND	5.06
11	0		4.65	ND	6.1
12	1		8.89	ND	6.98
13	0		5.93	ND	4.05
14	1	0	8.7	15.7	4.08
15	0		6.63	ND	ND
16	0		6.54	ND	6.84
17	1		4.03	5.12	ND
18	1	0	8.2	ND	5.59
19	0		ND	ND	4.76
20	0		ND	ND	ND
21	0		11.04	ND	5.86
22	0		7.55	ND	ND
23	0	0	ND	ND	ND
24	0	0	18.26	ND	15.3
25	1	1	10.25	ND	4.94
26	0	0	7.56	ND	ND
27	0		ND	ND	ND
28	0	1	12.59	ND	5.6
29	0	0	ND	ND	ND
30	0		5.32	ND	ND
31	0	1	ND	ND	6.59
32	0	1	ND	ND	ND

ND# below detection threshold

NON-CIRRHOTIC INTRAHEPATIC PORTAL HYPERTENSION:

Of the 60 cases liver biopsy was done in 20 patients of which 13/20 (65%) had Non-cirrhotic intrahepatic portal hypertension (NCIPH), 7 had cirrhosis. The mean HVPG was 6 (SD = 5) mm Hg.

Spectrum of celiac disease in NCIPH pts.

Of these 6 pts had villous atrophy on duodenal biopsy and 5 of 6 also had a positive IgA-TTG antibody consistent with the diagnosis of celiac disease.

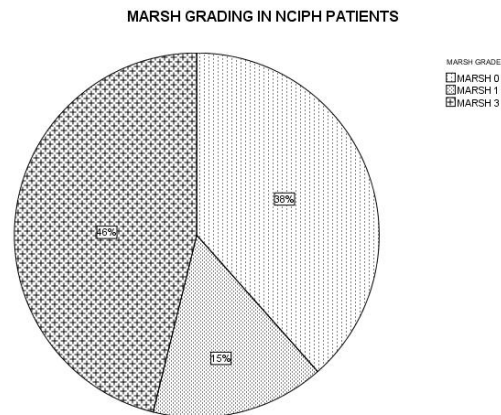


Figure 13: Spectrum of celiac disease in NCIPH patients(n=13)

CELIAC DISEASE:

There were 11 cases (cryptogenic CLD) who had celiac disease (IgA-TTG Ab positive and Marsh III changes of villous atrophy on duodenal biopsy). Of these, 8 patients had symptomatic celiac disease with symptoms of diarrhea, bloating and flatulence and 3 had

silent celiac disease (i.e. no intestinal symptoms). One patient also had associated dermatitis herpetiformis.

The mean age of these patients was 40 years. All except one patient had an adult onset celiac disease. (One patient had diarrhea from 7 years of age). 10 patients were from eastern India and 1 from southern India (Andhra Pradesh). Of these patients 7 underwent liver biopsies and 5 had NCIPH, 2 had cirrhosis.

Table 12: Baseline gut permeability in cases

Case no	IgA-TTG Ab	Ab titres (U/ml)	Duodenal biopsy(Marsh grade)	Gut permeability (inc >0.072) ⁸³
1	+	28	3	0.4468
2	+	82	3	0.1158
3	+	25	3	0.142
4	+	56	3	0.0244
5	+	49	3	0.0388
6	+	>300	3	0.50024
7	+	39	3	0.0695
8	-		3	0.0133
9	+	40	1	0.0154
10	+	21	1	0.0122
11	+	126	1	0.0238
12	+		1	0.014
13	-		1	0.009143
14	-		1	0.0487
15	+	51	0	0.625
16	+	31	0	0.0215
17	+		0	0.0074
18	+		0	0.0314
19	+	82	0	0.0044
20	+	33	0	0.0071
21	-		0	0.1703
22	-		0	0.0408
23	-		0	0.01296

Gut permeability using lactulose-mannitol was done in 23 cases (17 pts TTG Ab positive and 6 TTG Ab negative). Gut permeability was increased in 6 pts, of which 4 had celiac disease (villous atrophy on duodenal histology and a positive TTG antibody), 1 had normal biopsy and a positive serology and 1 had both negative serology and normal histology (table 12).

FOLLOW UP:The patients who had celiac disease were advised a gluten-free diet and were re-evaluated after a minimum of 3 months. The duration of follow-up was 8 (3 – 14) months,

median (range). The compliance was assessed on follow up. All patients except 2 were compliant with diet.

Parameters of patients with celiac disease at baseline and follow-up on Gluten free diet

Table 13: Parameters at baseline and follow up

Case no	Months of F-up	Compliance score	Symptom score		IgA-TTG Ab (titres U/ml)		Duodenal histology (Marsh grade)	
			Baseline	F-up	Baseline	F-up	Baseline	F-up
1	6	0	1	0	21	Neg	IIIa	I
2#*	8	3	0	0	24	44	IIIa	IIIa
3	9	0	2	1	82	Neg	IIIa	II
4	14	0	2	0	25	Neg	IIIa	I
5#	5	2	1	1	49	62	IIIa	-
6*	6	0	0	0	>300	>300	IIIb	IIIa
7*	10	0	0	1	39	Neg	III	I
8	3	0	1	0	49	Neg	III	III

* silent celiac disease

non-compliant with gluten free diet

Table 14: Parameters at baseline and follow up of patients with Celiac enteropathy/Latent disease on Gluten free diet

Case no	Months of f-up	Compliance score	Symptom score		IgA-TTG Ab (titres)		Duodenal histology (Marsh grade)	
			Baseline	F-up	Baseline	f-up	Baseline	f-up
1	10	0	2	1	21	Neg	I	I
2#	11	3	1	1	31	27	0	-
3	12	0	0	0	26	23	I	I
4	8	0	0	0	50	72	I	0
5	6	0	0	0	33	Neg	0	-

non-compliant with gluten free diet

Table 15: Lab parameters at baseline and follow up on GFD in patients with celiac disease

Case no	Hemoglobin (gm/dl)		Bilirubin (mg/dl)		Albumin (gm/dl)		Prothrombin time		Alanine aminotransferases(U/L)	
	Baseline	F-up	Baseline	F-up	Baseline	F-up	Baseline	F-up	Baseline	F-up
1	9.9	8.5	2.5	2.8	3.3	2.5	17.8	17.5	18	18
2#	12.9	13	1.1	0.9	4.2	4.3	12	13.6	26	14
3	13.8	13.3	1.1	1.4	4.6	4.4	12.1	10.4	92	50
4	10.6	11.6	1.4	0.4	4.5	4.4	14.1	13.6	35	22
5#	12.6	11.7	1	1.8	4.1	3.6	13.7	16	25	26
6	12	12.1	0.5	1	3.7	3.8	13.3	12.5	59	36
7	10.3	11.6	1.4	1.4	3.7	3.5	14.5	16	52	56
8	5.8	15	0.9	1	4.4	4.5	13	13	28	50

non compliant with gluten free diet

Table 16: Lab parameters at baseline and f-up on GFD in patients with celiac enteropathy/latent ds.

Case no	Hemoglobin (gm/dl)		Bilirubin (mg/dl)		Albumin (gm/dl)		Prothrombin time(sec)		Alanine aminotransferases(U/L)	
	Baseline	F-up	Baseline	F-up	Baseline	F-up	Baseline	F-up	Baseline	F-up
1	8.4	10.1	0.9	1.1	3.6	4	14.5	13.4	54	44
2#	6.6	13	2.2	1.1	3.7	4.3	12.4	11	46	63
3	12.6	12.3	2.4	1.5	4.2	4.3	12.3	11.4	30	22
4	12.9	10.2	0.6	2	3	2.7	14.9	15.5	42	24
5	12.6	12.8	1	1.1	3.9	3.6	14.8	14.3	25	35

non-compliant with gluten free diet

Table 17: Serial TTG antibody titres in pts who had more than 1 follow up on gluten free diet

Cases	Duodenal histology (Marsh grade) baseline	Titres at baseline	0-3mnths	3-9mnths	>9mnths
1	III	21	-	Neg	Neg
2	III*	>300	>300	>300	
3	I	25	Neg	-	Neg
4	I	31	31		27
5	I	50	>300		72
6	0	26	24	-	23

* silent celiac disease (duodenal histology done on subsequent visits at 3 and 8 mths was consistent with villous atrophy despite strict compliance with gluten free diet)

EFFECT OF GFD ON VARIOUS PARAMETERS IN 8 PTS OF CELIAC DISEASE WHO CAME FOR FOLLOW UP

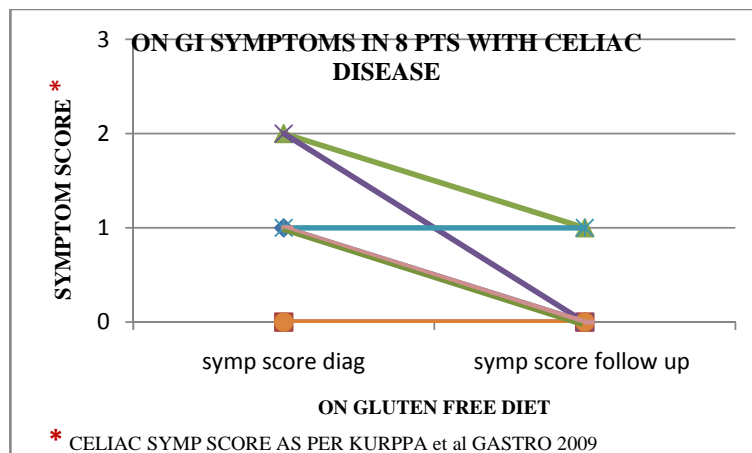


Figure 14: Effect of GFD on GI symptoms

On liver functions: 7 of 8 patients had no hepatic decompensation while on gluten-free diet on follow up. 1 of 8 patients came with worsening ascites and pedal edema despite strict compliance with gluten free diet (fig 15).

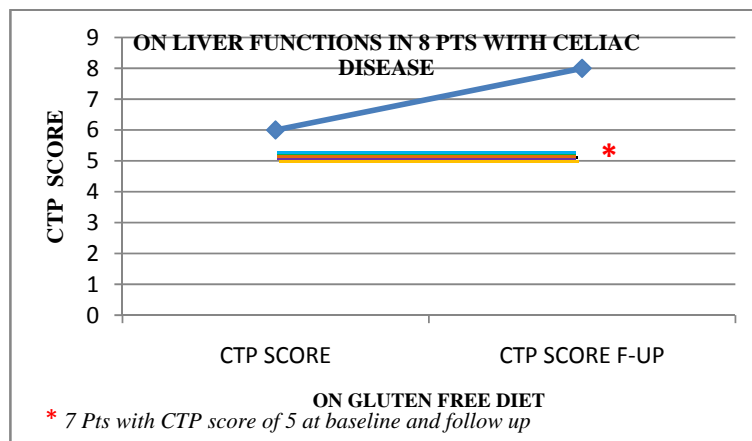


Figure 15: Effect of GFD on liver function

On transaminases: The transaminases remained the same or improved in the patients with celiac disease (figure 16).

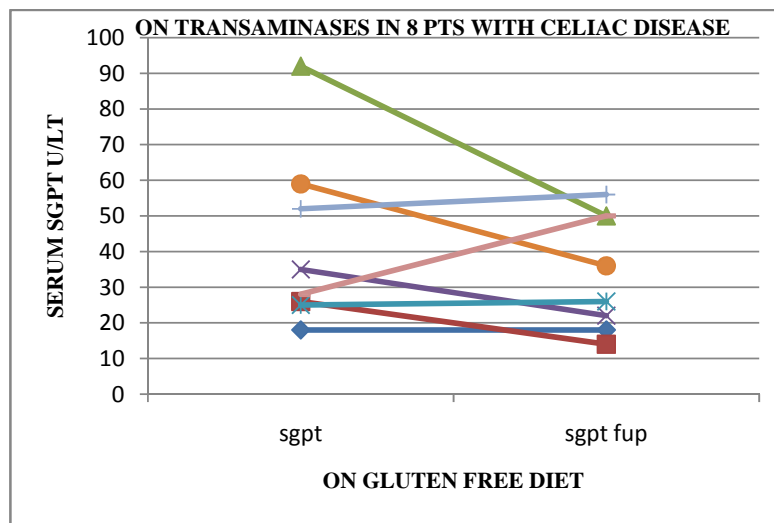


Figure 16: Effect of GFD on transaminases

On IgA-TTG antibody titres:

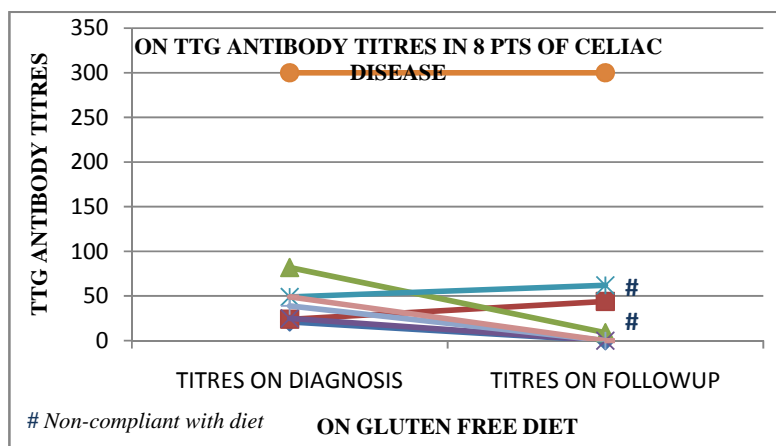


Figure 17: Effect of GFD on Anti TTG Ab titre

The titres of TTG antibody became negative in 5 of 8 patients who came for follow up on a gluten-free diet. The titres showed mild increase in 2 patients who were non-compliant with the diet. Another patient who had a silent celiac disease and titres >300 times, remained the same despite 8 months of a strict gluten-free diet.

Duodenal histology:

Duodenal biopsies were done in 7 of 8 pts on follow up. Of these, 3 patients had reversion of villous atrophy to only features of chronic atrophic gastritis (Marsn 1). However in none of the patients the biopsy returned to normal. In 1 patient there was reversion of crypt hyperplasia with preservation of crypt architecture and decrease from moderate villous atrophy to normal and mildly atrophic villi. In another patient, the villous atrophy regressed from subtotal to moderate atrophy of villi. Of the remaining 2 patients, the histology remained the same and despite a strict adherence with gluten free diet. However, in one patient who also had dermatitis herpetiformis, the skin lesions disappeared after 3 months of gluten-free diet (fig 18).




Figure 18: Effect of GFD on duodenal histology

Gut permeability using lactulose mannitol test showed reversal in 1 patient after 6 months of gluten free diet.

DISCUSSION

The present study is a prospective case-control study to look at association between celiac disease and cryptogenic chronic liver disease (including idiopathic non-cirrhotic intrahepatic portal hypertension).

We observed celiac disease to be significantly more common in the cases (cryptogenic chronic liver disease including idiopathic non-cirrhotic intrahepatic portal hypertension) as compared to the controls (pts with Hep B/C related CLD).

When these patients were followed on a gluten-free diet for 8 months (3-14) median (range) an improvement in the celiac serology was noted with a decrease in titres of IgA-TTG antibody from baseline.

However, repeat histology showed improvement in only 4 patients with a complete reversion of villous atrophy in 3 patients. The histology did not revert to normal in any patient. Further no patient showed worsening in histology. The liver functions remained stable over follow up.

Of the 11 patients of celiac disease, 6 underwent liver biopsies of which 5 (83%) had non-cirrhotic intrahepatic portal hypertension.

The prevalence of celiac disease was much higher, 11/51 ~ 22% as compared to the reported prevalence in India (0.3-1%).^{66,67}

Idiopathic non-cirrhotic intrahepatic portal hypertension has been a predominant cause of cryptogenic chronic liver disease in our population.² In the present study of the 60 patients with cryptogenic chronic liver disease, liver biopsies were done in 20 patients and 13 (65%) had evidence of non-cirrhotic intrahepatic portal hypertension and cirrhosis in 7 patients. In another retrospective analysis of the liver biopsies done from June 2005- June 2007 at our

centre, of 517 patients who underwent liver biopsies, 62 patients had no documented cause of liver disease of which idiopathic non-cirrhotic intrahepatic portal (NCIPH) was identified in 30 patients (48%).

In this study we found that celiac serology using IgA-TTG antibody was significantly more common in cases (69%) as compared to controls (27%) ($p=0.00$).

The mean titres were also significantly higher in cases 70 IU/L (SD= 60) as against controls i.e. 43 (SD=21) ($p=0.036$).

Further once these patients were subjected to duodenal biopsies for histological confirmation of the diagnosis of celiac disease we found 12/51 (24%) patients with cryptogenic chronic liver disease as against 0/ 28 (0%) had features of villous atrophy or Marsh III changes. This prevalence is much higher (approx. 24 fold) than prevalence of celiac disease which has already been reported in India^{66,67}.

Further evaluation revealed that 19 of 51 patients who underwent duodenal biopsies in cases and 8 of 28 patients in the control group had only evidence of intraepithelial lymphocytosis with crypt hyperplasia seen in 1 patient in each group. In a study by Kurppa et al⁶ there was a suggestion that mucosal damage develops gradually and patients may experience clinical symptoms before histologic changes appear. They studied 70 consecutive adults with positive EMA, and of these, 23 had only mild enteropathy (Marsh I–II) and they were randomized either to continue on a gluten-containing diet or start GFD. It was noted that in the gluten-containing diet group (Marsh I–II) the small-bowel mucosal deterioration was seen in all patients, and the symptoms and abnormal antibody titers persisted. In the GFD group (Marsh I–II) the symptoms were alleviated, antibody titers decreased, and mucosal inflammation diminished equally to celiac controls (Marsh III). In our series also of the 5 patients who came for follow up after a 9 (6-12) months mean (range) of gluten free diet

TTG antibody titres decreased in 3 patients (in 2 patients became negative) and histology reverted to normal in 1 patient.

Adult-onset celiac disease was recognised in 10 cases and in none of the controls. The mean age of the patients was 40 years and 9 patients were from the eastern India and 1 patient from south India (however there were only 9 patients of south India that were studied to begin with). 1 pt of the 11 had symptoms of diarrhea from 7 years of age. In all these patients a diagnosis of celiac disease was made after the diagnosis of liver disease.

Of these 11 patients the main presentation as diarrhea disturbing life was seen in 4 patients, 4 patients had minimal diarrhea, bloating and flatulence and 3 had silent celiac disease. In another retrospective evaluation of celiac disease and NCIPH by Eapen et al in Birmingham 5 patients were diagnosed with celiac disease of which 2 /5 had a silent disease. All these 11 patients had come to the hepatology unit for the evaluation of the liver disease and were incidentally detected with celiac disease after complete evaluation.

Austin et al hypothesized that in patients with celiac disease there occurs enterocyte apoptosis which causes production of anti-cardiolipin antibodies which further cause obliteration of the small intrahepatic portal venous system causing non-cirrhotic intrahepatic portal hypertension. Similarly celiac disease was seen to be associated with non-cirrhotic intrahepatic portal hypertension in another retrospective analysis which looked at gut derived prothrombotic factors and association with high titre IgA-anticardiolipin antibodies was reported.

However, in our series of the 28 cases who were checked for the presence of anti-cardiolipin antibodies (IgA, IgG and IgM) none had raised levels of either of these antibodies(i.e titres more than 15 U/ml). The IgA anti-Cardiolipin antibodies were borderline positive (titres between 10-15 U/ml) in 4 patients. Of these 4 patients, 1 had celiac disease, 2

had celiac enteropathy and 1 had latent celiac disease. In the control group of the 32 patients who were checked for the presence of anti-cardiolipin antibodies (IgA, IgG and IgM), IgA anticardiolipin antibodies were borderline positive in 4 patients of which 1 had celiac enteropathy, 1 had latent celiac disease, 1 had duodenal biopsy showing Marsh I changes but a negative serology and the fourth had negative serology (duodenal biopsy was not done).(table 10,11)

IgA anticardiolipin antibody was positive(titres more than 15U/ml) in only 1 patient who had a negative serology and a normal biopsy. This same patient also had a positive IgG anticardiolipin antibody. This patient had a decompensated chronic liver disease secondary to hepatitis B.

This indicates that the pathogenetic mechanisms in our patients with this entity are different as compared to the west and require further research.

All cases with a positive antibody irrespective of the duodenal histology were subjected to a gluten free diet.

Of the 11 patients with a positive TTG antibody and villous atrophy on duodenal biopsy (Marsh III), 8 came for follow up after a median 8 months, range (3-14 months).

Of these 2 patients were non-compliant with the diet who had a corresponding increase in titres at follow up. All the remaining 6 who were compliant with the diet had a decline in titres with the antibody becoming negative at follow up. This is consistent with the fact the titres of antibodies decrease in patients with celiac disease on a gluten free diet and can be used for monitoring of compliance with diet. A repeat histology to document response is presently not indicated in these patients as histological changes may take longer time to improve.⁷

The liver functions remained stable on follow up without any new decompensation noted in any of the patients, apart from worsening ascites in 1 patient. Most of these patients were with CTP score A and hence any definite improvement in liver functions could not be determined and also because of a short follow up in our study.

On follow up one patient who was diagnosed with celiac disease developed hepatocellular carcinoma and underwent radiofrequency ablation for the same. There have been only case reports on association of hepatocellular carcinoma with celiac disease.^{72,73}

Another patient who was diagnosed as a case of non-cirrhotic intrahepatic portal hypertension and silent celiac disease had very high titre TTG antibody (>300 U/ml) repeatedly at baseline, at 3 months and 8 months of strict gluten free diet and histology showing persistent villous atrophy reflecting possibility of a refractory celiac disease or an inadvertent ingestion of gluten⁸⁴.

It is already known that patients with celiac disease have an increased gut permeability which causes gut derived toxins , antigens and cytokines to reach the liver via the portal circulation and cause liver damage.^{73,74,75,76} In our series we found increased gut permeability in 4 of the 8 (50%) cases of celiac disease who were checked. In 1 patient the gut permeability reversed and normalized on follow up on gluten free diet.

CONCLUSIONS

Celiac disease was seen in 22% (11/51) of patients with cryptogenic chronic liver disease including idiopathic non-cirrhotic intrahepatic portal hypertension. This is much higher than the reported prevalence of celiac disease in India of ~1% (Makharia et al).

Of the 11 patients of celiac disease, 5 of 7 patients (71%) who underwent liver biopsy had non-cirrhotic intrahepatic portal hypertension.

Non-cirrhotic intrahepatic portal hypertension was recognised as the predominant cause of cryptogenic intrahepatic portal hypertension in our unit. Of the 20 cases (Cryptogenic CLD) who underwent liver biopsy 65% (13) had NCIPH.

Of the 11 patients of celiac disease, 8 came for follow up at 8 (3-14) months median (range).

Adult onset celiac disease was diagnosed in 10 patients.

In all patients, celiac disease was recognised after the diagnosis of the liver disease and 3 patients had silent celiac disease.

Reversion of villous atrophy was seen in 3 patients on follow up and serology became negative in 5 patients.

GI symptoms improved in all patients however an improvement in liver functions could not be determined probably because of the short follow up.

Dermatitis herpetiformis was a presentation in 1 patient which resolved with gluten-free diet. Refractory celiac disease was suspected in 1 patient with silent disease. Another patient was diagnosed with hepatocellular carcinoma on follow up.

Increased gut permeability was seen in 6 patients of which 4 had celiac disease and one had latent celiac disease. The permeability reversed in one patient on follow up after 6 months of gluten free diet.

In our series of patients none of the patients of celiac disease had high titres of IgA-anticardiolipin antibodies (apart from 1 patient with celiac disease who had borderline high levels) as against the data from the western population indicating need of further research to look at the underlying pathogenetic mechanisms in our population.

BIBLIOGRAPHY

1. Non-cirrhotic Intrahepatic Portal Hypertension: Associated Gut Diseases and Prognostic Factors. *C. E. Eapen et al Dig Dis Sci* DOI 10.1007/s10620-010-1278.
2. Madhu K, Avinash B, Ramakrishna B, Eapen CE, Shyamkumar NK, Zachariah U, Chandy G, Kurian G. Idiopathic non-cirrhotic intrahepatic portal hypertension: common cause of cryptogenic intrahepatic portal hypertension in a Southern Indian tertiary hospital. *Indian J Gastroenterol*. 2009 May-Jun; 28(3):83-7.
3. Austin A, Campbell E, Lane P, Elias E. Nodular regenerative hyperplasia of the liver and celiac disease: potential role of IgA anticardiolipin antibody. *Gut*. 2004 Jul; 53(7):1032-4.
4. Cancado EL, Medeiros DM, Deguti MM, Dos Santos MS, de Mello ES, Vendramini MB, Carrilho FJ. Celiac disease associated with nodular regenerative hyperplasia, pulmonary abnormalities, and IgA anticardiolipin antibodies. *J Clin Gastroenterol*. 2006 Feb;40(2):135-9.
5. Chundamannil E, Velisarris D, Elias E. Progression to liver failure in non-cirrhotic portal hypertension. *Gastroenterology* 2005;128 (Suppl 2):abstract W1710.
6. Kurppa K, Collin P, Viljamaa M, Haimila K, Saavalainen P, Partanen J, et al. Diagnosing mild enteropathy celiac disease: a randomized, controlled clinical study. *Gastroenterology*. 2009 Mar;136(3):816-23.
7. AGA Institute Technical review on the diagnosis and Management of Celiac Disease. *Gastroenterology* 2006; 131 :1981-2002.

8. Kaukien K, Halme L, Collin P et al. Celiac disease in patients with severe liver disease, gluten free diet may reverse hepatic failure. *Gastroenterology* 2002;122:881-888.
9. Ojetti V, Fini I, Zileri Dal Verme L. Acute cryptogenic liver failure in an untreated celiac patient, case report. *Eur.J.Gastroenterol Hepatol* 2005 ;17:1119-1121s.
10. Korponay-Szabo IR, Halttunen T, Szalai Z et al. In vivo targeting of intestinal and extraintestinal transglutaminase 2 by coeliac autoantibodies. *Gut* 2004;53:641-648.
11. Intestinal permeability in patients with coeliac disease and relatives of patients with coeliac disease. *Gut* 1993;34:354-357.
12. Harald Vogelsang, Maria Schwarzenhofer, Georg Oberhuber. Changes in Gastrointestinal Permeability in Celiac Disease. *Dig Dis* 1998;16:333-336.
13. M.Vecchi, C. Folli et al, High rate of positive anti-TTG antibodies in chronic liver disease. *Scand Jour of Gastroenterology* 2003.
14. Guinea pig transglutaminase immunolinked assay does not predict celiac disease in patients of chronic liver disease. *Carroccio et al; Gut, 2001; 49: 506-11.*
15. Celiac disease and risk of liver disease: A general population-based study. *Clinical gastroenterology and hepatology* 2007;5 63-69.
16. Celiac disease and Non-organ specific antibodies in patients with chronic hepatitis C virus infection. Caterina Rugeri et al *Dig. Dis Sci* (2008)53;2151-2155.
17. Madhu K, Ramakrishna B, Zachariah U, Eapen CE, Kurian G. Non-cirrhotic intrahepatic portal hypertension. *Gut*. 2008 Nov;57(11):1529.
18. Fiolla AD, Havelund T. [Non-cirrhotic intrahepatic portal hypertension] *Ugeskr Laeger*. 2007 Oct 15;169(42):3590-1.

19. Ibarrola C, Colina F. Clinicopathological features of nine cases of non-cirrhotic portal hypertension: current definitions and criteria are inadequate. *Histopathology*. 2003 Mar;42(3):251-64.
20. Mazumder DN, Effect of chronic intake of arsenic contaminated water on liver. *Toxicol Appl. pharmacol* 2005 Aug 7; 206 (2), 169-75.
21. Sama SK, Bhargava S, Gopinath N et al. Non Cirrhotic Portal Fibrosis, *Am J Med* 1971; 51: 160-9.
22. Tisdale WA, Klatskin G, Glenn WWL. *New England Journal Medicine*. 1959; 261:209-214.
23. Ramalingaswami B, Wig HL, Sama SK. Cirrhosis of liver in Northern India. A clinicopathologic study. *Arch Med* 1962; 11; 350-35.
24. Mikkelson WP, Edmonson HA, Peters RL, et al. Extra and intra hepatic portal hypertension without cirrhosis. *Ann Surg* 1965; 162: 602-620.
25. Chawla Y, Duseja A. Non cirrhotic portal fibrosis (NCPF) is a vanishing disease in India. *Trop Gastroenterol* 2003 Apr-June; 24(2): 45-6.
26. S K Sarin, D Kapoor. Non-Cirrhotic portal fibrosis: Current concepts and Management; *Jrnl of gastroent and hepatol* (2002) 17,526-534.
27. Sarin SK, Non-cirrhotic portal fibrosis. *GUT* 1989;5;336-51.
28. Shiv Kumar Sarin, Ashish Kumar. Non cirrhotic portal hypertension) *Clin Liver Dis* 10 (2006) 627-65.
29. S.K.Sarin, A.K. Nayyar, P.Malhotra et al, Immunological profile of patients with non-cirrhotic portal fibrosis.
30. Okuda K, Obata H. Idiopathic portal hypertension (hepatoportal sclerosis): clinical and physiological aspects. Tokyo: Springer-Verlag; 1991. p. 271–87.

31. S K Sarin, D Kapoor. Non-Cirrhotic portal fibrosis: Current concepts and Management; *Jrnl of gastroent and hepatol* (2002) 17,526-534.
32. Shiv Kumar Sarin, Ashish Kumar, Yogesh Kumar Chawla et al. Noncirrhotic portal fibrosis/idiopathic portal hypertension: APASL recommendations for diagnosis and treatment, *Hepatology International* © Asian Pacific Association for the Study of the Liver 2007 10.1007/s12072-007-9010-9.
33. Sheth SG, Deo AM, Bichile SK et al, Coagulation abnormalities in non-cirrhotic portal fibrosis and Extra hepatic portal vein obstruction, *JAPI* 1996; 44: 790-8.
34. Sarin SK, Shahi HM, Jain M et al. The natural history of portal hypertensive gastropathy; influence of variceal eradication. *Am J Gastroenterol* 2000; 95 :2888-93.
35. Mention J, Ben Ahmed M, Begue B, Barbe U, Verkarre V, Asnafi V, Colombel J, Cugnenc P, Ruemmele FM, McIntyre E, Brouss N, Cellier C, Cerf-Bensussan N. Interleukin 15: a key to disrupted intraepithelial lymphocyte homeostasis and lymphomagenesis in celiac disease. *Gastroenterology* 2003;125: 730–745.
36. Kakar S, Nehra V, Murray JA, Dayharsh GA, Burgart LJ. Significance of intraepithelial lymphocytosis in small bowel biopsy samples with normal mucosal architecture. *Am J Gastroenterol* 2003;98:2027–2033.
37. Kaukinen K, Maki M, Partanen J, Sievanen H, Collin P. Celiac disease without villous atrophy: revision of criteria called for. *DigDis Sci* 2001;46:879–887.
38. Rostom A, Dube C, Cranney A, Saloojee N, Sy R, Garritty C Sampson M, Zhang L, Yazdi F, Mamaladze V, Pan I, McNeil J, Moher D, Mack D, Patel D. Celiac disease. *Evid Rep Technol Assess (Summ)* 2004;(104):1–6.
39. R, Schreier E, Volta U, Granito A, Veronesi L, Mascart F, Ocmant A, Ivarsson A, Lagerqvist C, Burgin-Wolff A, Hadziselimovic F, Furlano RI, Sidler MA, Mulder CJ, Goerres MS, Mearin ML, Ninaber MK, Gudmand-Hoyer E, Fabiani E, Catassi C,

- Tidlund H, Alaintalo L, Maki M. Antiendomysial and antihuman recombinant tissue transglutaminase antibodies in the diagnosis of coeliac disease: a biopsy-proven European multicentre study [see comment]. *Eur J Gastroenterol Hepatol* 2005;17:85–91.
40. Rostami K, Kerckhaert J, Tiemessen R, von Blomberg BM, Meijer JW, Mulder CJ. Sensitivity of antiendomysium and antigliadin antibodies in untreated celiac disease: disappointing in clinical practice. *Am J Gastroenterol* 1999;94:888–894.
41. Marsh MN. Gluten, major histocompatibility complex, and the small intestine: a molecular and immunobiologic approach to the spectrum of gluten sensitivity ('celiac sprue'). *Gastroenterology* 1992;102:330–354.
42. Wahab PJ, Meijer JW, Mulder CJ. Histologic follow-up of people with celiac disease on a gluten-free diet: slow and incomplete recovery. *Am J Clin Pathol* 2002;118:459–463.
43. Bardella MT, Trovato C, Cesana BM, Pagliari C, Gebbia C, Peracchi M. Serological markers for coeliac disease: is it time to change? *Dig Liver Dis* 2001;33:426–431.
44. Sategna-Guidetti C, Grosso S, Bruno M, Grosso SB. Reliability of immunologic markers of celiac sprue in the assessment of mucosal recovery after gluten withdrawal. *J Clin Gastroenterol* 1996;23:101–104.
45. Valentini RA, Andreani ML, Corazza GR, Gasbarrini G. IgA endomysium antibody: a valuable tool in the screening of celiac disease but not its follow-up. *Ital J Gastroenterol* 1994;26: 279–282.
46. Dickey W, Hughes DF, McMillan SA. Disappearance of endomysial antibodies in treated celiac disease does not indicate histological recovery. *Am J Gastroenterol* 2000;95:712–714.

47. Bartholomeusz RC, Labrooy JT, Davidson GP, Hetzel P, Johnson RB, Shearman DJ. Polymeric IgA antibody to gliadin in the serum of patients with coeliac disease. *J Gastroenterol Hepatol* 1990; 5:675–681.
48. Burgin-Wolff A, Gaze H, Hadziselimovic F, Huber H, Lentze MJ, Nussle D, Reymond-Berthet C. Antigliadin and antiendomysium antibody determination for coeliac disease. *Arch Dis Child* 1991;66:941–947.
49. Fabiani E, Catassi C. The serum IgA class anti-tissue transglutaminase antibodies in the diagnosis and follow up of celiac disease. Results of an international multi-centre study. International Working Group on Eu-tTG. *Eur J Gastroenterol Hepatol* 2001;13:659–665.
50. Fabiani E, Catassi C, Villari A, Gismondi P, Pierdomenico R, Ratsch IM, Coppa G, V, Giorgi PL. Dietary compliance in screening- detected coeliac disease adolescents. *Acta Paediatr Suppl* 1996;412:65–67.
51. Scalici C, Manzoni D, Licastro G, Varia F, Di Prima L, Vitali R. Reliability of EMA assay in the evaluation of gluten-free diet compliance in celiac patients during follow-up. *Acta Med Mediterr* 2003;19:67–69.
52. Kaukinen K, Sulkanen S, Maki M, Collin P. IgA-class transglutaminase antibodies in evaluating the efficacy of gluten-free diet in coeliac disease. *Eur J Gastroenterol Hepatol* 2002;14: 311–315.
53. McNicholl B, Egan-Mitchell B, Stevens F, Keane R, Baker S, McCarthy CF, Fottrell PF. Mucosal recovery in treated childhood celiac disease (gluten-sensitive enteropathy). *J Pediatr* 1976; 89:418–424.

54. Lee SK, Lo W, Memeo L, Rotterdam H, Green Peter HR. Duodenal histology in patients with celiac disease after treatment with a gluten-free diet. *Gastrointest Endosc* 2003;57:187–191.
55. Martini S, Mengozzi G, Aimo G, Giorda L, Pagni R, Guidetti CS. Comparative evaluation of serologic tests for celiac disease diagnosis and follow-up. *Clin Chem* 2002;48:960–96.
56. Selby WS, Painter D, Collins A, Faulkner-Hogg KB, Loblay RH. Persistent mucosal abnormalities in coeliac disease are not related to the ingestion of trace amounts of gluten. *Scand J Gastroenterol* 1999;34:909–914.
57. Montalto M, Cuoco L, Ricci R, et al. Immunohistochemical analysis of ZO-1 in the duodenal mucosa of patients with untreated and treated celiac disease. *Digestion* 2002;65:227–33.
58. Schulzke JD, Bentzel CJ, Schulzke I, et al. Epithelial tight junction structure in the jejunum of children with acute and treated celiac sprue. *Pediatr Res* 1998;43:435–41.
59. Vogelsang H, Wyatt J, Penner E, et al. Screening for celiac disease in first degree relatives of patients with celiac disease by lactulose/mannitol test. *Am J Gastroenterol* 1995;90:1838–42.
60. Duerksen DR, Wilhelm-Boyles C, Parry DM. Intestinal permeability in long term follow-up of patients with celiac disease on a gluten-free diet. *Dig Dis Sci* 2005;50:785–90.
61. S. Lindgren, K. Sjoberg & S. Eriksson. Unsuspected Coeliac Disease in Chronic ‘Cryptogenic’ Liver Disease *Scand J Gastroenterol* 1994;29:661-664.

62. Cataldo F, Marino V, Ventura A, Bottaro G, Corazza GR. Prevalence and clinical features of selective immunoglobulin A deficiency in coeliac disease: an Italian multicentre study. Italian Society of Paediatric Gastroenterology and Hepatology (SIGEP) and “Club del Tenue” Working Groups on Coeliac Disease. *Gut* 1998;42:362–365.
63. Kaukinen K, Halme L, Collin P, Farkkila M, Maki M, Vehmanen P, et al. Celiac disease in patients with severe liver disease: gluten-free reverse hepatic failure. *Gastroenterology* 2002;122:881-888.
64. Sharma BC, Bhasin DK, Nada R. Association of celiac disease with noncirrhotic portal fibrosis. *J Gastroenterol Hepatol* 2006;21(pt 2):332-334.
65. Jacobsen MB, Fausa O, Elgjo K, Schrupf E. Hepatic lesions in adult celiac disease. *Scand J Gastroenterol* 1990;25:656-662.
66. Villalta D, Crovatto M, Stella S, Tonutti E, Tozzoli R, Bizzaro N. False positive reactions for IgA and IgG anti-tissue transglutaminase antibodies in liver cirrhosis are common and method-dependent. *Clin Chim Acta* 2005;356:102-109.
67. Sood A, Midha V, Sood N, Avasthi G, Sehgal A. Prevalence of celiac disease among school children in Punjab, North India. *J Gastroenterol Hepatol*. 2006;21:1622-25.
68. P Govind, K Makharia, Anil K Verma, Ritvik, Amarchand Shinjini, Bhatnagar, Prasenjit Das, Anil Goswami, Vidyut Bhatia, Vineet Ahuja, Siddhartha Datta Gupta, K Anand. Prevalence of celiac disease in the Northern part of India: A Community Based Study. *Journal of gastroenterol and hepatol* Dec 2010.

69. Lal S, Nain CK, Prasad KK, et al. Celiac disease in Chandigarh: A population survey. *Indian J Gastroenterol* 2005;24 (Suppl 1):A39.
70. Marsh MN. Gluten major histocompatibility complex and the small intestine. A molecular and immunobiologic approach to the spectrum of gluten sensitivity ('celiac sprue'). *Gastroenterology* 1992; 102: 330–54.
71. Long-term follow-up of celiac adult on gluten-free diet: prevalence and correlates of intestinal damage Carolina Ciaccia et al *Digestion*. 2002;66:178–185.
72. Morphometric evaluation of duodenal biopsies in Celiac disease Adrian Cummins et al *Am J Gastroenterol* 2011; 106:145–15
73. Pollock DJ. The liver in coeliac disease. *Histopathology* 1977; 1: 421–30
74. Hagander B, Berg NO, Brandt L, Norden A, Sjolund K, Stenstam M. Hepatic injury in adult coeliac disease. *Lancet* 1977;2: 270–2.
75. Volta U, De Franceschi L, Lari F, Molinaro N, Zoli M, Bianchi F. Celiac disease hidden by cryptogenic hypertransaminasemia. *Lancet* 1998; 352: 26-29.
76. Volta U, Granito A, De Franceschi L, Petrolini N, Bianchi FB. Anti tissue transglutaminase antibodies as predictors of silent celiac disease in patients with hypertransaminasemia of unknown origin. *Dig Liver Dis* 2001;33: 420-425.
77. Pelaez-Luna M, Schmulson M, Robles-Diaz G. Intestinal involvement is not sufficient to explain hypertransaminasemia in celiac disease? *Med Hypotheses* 2005;65:937-941.

78. L. Pasta, C Marrone, M.D 'Amico et al letter to the editor, MTHFR C677T mutations in liver cirrhosis with and without portal vein thrombosis *Liver international* 2006; 26:269-270.
79. Angeline T, Jeyaraj N, Granito S et al. *Mol Pathol*. 2004 Oct; 77(2): 85-8.
80. Okudaira M, Ohbu M, Okuda K. Idiopathic portal hypertension and its pathology. *Semin Liver Dis* 2002;22:59–72.
81. Ludwig J, Hashimoto E, Obata H, Baldus WP. Idiopathic portal hypertension; a histopathological study of 26 Japanese cases. *Histopathology* 1993;22:227–34.
82. Alberto Rubio-Tapia and Joseph A. Murray The Liver in Celiac Disease *HEPATOLOGY*, Vol. 46, No. 5, 2007.
83. Simultaneous HPLC determination with light scattering detection of lactulose and mannitol in studies of intestinal permeability in paediatrics Renzo Marsilio,* Lorenzo D'Antiga, Lucia Zancan, Noemi Dussini, and Franco Zacchello. *Clinical Chemistry* 44:81685–1691 (1998)
84. Alberto Rubio-Tapia and Joseph A. Murray Classification and management of refractory coeliac disease. *Gut* 2010 59: 547-557

PROFORMA

NAME:

HOSPITAL NO:

AGE:

SEX:

ADDRESS:

TEL NO:

MODIFIED KUPPUSWAMY SCORE

CLD: ETIOLOGY

ALCOHOL		AUTOIMMUNE		VIRUS		NAFLD				Wilson
Qty.	Dur.	ANA	Liver profile	HBV	HCV	DM	HTN	Lipids	BMI	

CRYPTOGENIC/NCIPH:

LIVER BIOPSY:

HVPG:

VARICES:

Symptoms	Duodenal biopsy (Marsh grade)	TTG	EMA	SPECTRUM				
				Silent	Symptomatic	Enteropathy	Latent	FP TTG

Date of start of gluten free diet:

Assessment of liver functions:

Decompensation/liver functional status	At entry point	After 3-6 months of GFD
CTP		
MELD		
Ascites		
Encephalopathy		
Variceal bleed/Grade		
Jaundice		
SBP		
Renal failure		

CELIAC DISEASE:

	At entry point	After 3-6 months of GFD	
IgA TTG Ab (titres)			
IgA EMA			
Duodenal biopsy (Marsh Grade)			
Intestinal permeability			

Quantitative variables:

Variable	At entry point	After 3-6 months of GFD
Hb		
Platelet		
Iron/TIBC		
Ferritin		
Vit. B12/Folate		
Bilirubin		
PT/INR		
Prot/Alb		
Creatinine		
AC/PC		
Lipids		
D-Xylose		

OTHER FACTORS:

HYPERSPLENISM(+/-):

EHPVO(+/-):

PATIENT INFORMATION SHEET AND CONSENT

Study title: Study of spectrum of celiac disease in patients of chronic liver disease

To see the effect of gluten free diet on the outcome of the liver disease

Information sheet (to be read by or explained to the patient)

Celiac disease is an intestinal disease that is associated with allergy to wheat. It has also been shown to affect the liver causing chronic liver disease.

This study is being done to find out what is the connection between celiac disease and liver disease especially in patients in whom the cause of liver damage is not known despite detail workup. She would also like to see that in all such patients how a simple gluten free diet can help improving both the intestinal and liver functions in the course of time by doing certain tests.

The study would involve a duodenal biopsy and a serology for TTG antibody including a detail clinical examination. If this is positive the patient would be given a wheat- free diet i.e avoidance of wheat and all packed items containing wheat as ingredient and a re-evaluation would be done after 3-6 months of the same.

All other tests are only done for your clinical care.

The results of the tests done in connection with the study may directly benefit you. They are likely to indirectly benefit other patients with the disease.

The results of the tests will be kept confidential and there will be no direct link of the test report with your hospital records.

You are free to not participate in this study if you do not wish so.

CONSENT

I hereby provide my consent for the above research study and to give the necessary information and samples.

I also provide my consent for the blood sample to be preserved for additional research for a period of five years without my further approval, under the condition that the results will be kept anonymous and not linked to me.

Name:

Hosp. No:

Study No:

Date:

Signature:

Witnessed by:

(Name :)

Title: Is Celiac disease (CD) associated with Cryptogenic Chronic Liver Disease and Non-cirrhotic Intra-hepatic Portal Hypertension(NCIPH).

Department:Department of Gastrointestinal Sciences ,Christian Medical College , Vellore

Name of the candidate: Dr. Rakhi Maiwall

Degree and subject :DM Branch IV (Gastroenterology)

Guide: Dr George Chandy

Abstract:

Background and Aims: To study the spectrum of CD in patients with NCIPH /cryptogenic chronic liver disease (CLD) and to see the effects of gluten free diet in these patients.

Methods : Prospective case-control study looked at CD in cryptogenic CLD including NCIPH (cases) and hepatitis B/C related CLD (controls). IgA–TTG antibody (using recombinant human transglutaminase , ELISA (AESKULISA Celichek) and anticardiolipin antibodies (IgG,IgA and IgM) (ELISA Varelista kit) with titres at the time of diagnosis and duodenal biopsy with grading according to Marsh criteria was done.This was followed by subjecting the patients on gluten free diet and reassessing after minimum of 3 months. To study the association, bivariate analyses were done and the associations were studied using chi-square test (Fisher exact test).

Results :60 cases (age 43 (10) years, (mean (SD)), males 46) and 59 controls (age 45 (11) years; males 53) were studied. Majority were from eastern India.

Liver biopsy done in 20 cryptogenic CLD patients showed NCIPH (13) and cirrhosis (7).

IgA TTG Ab was significantly positive in 40/58 cases (69%) with higher mean titres (70 U/ml) as compared to controls 16/59 (27%) (p = 0.00) mean titres (43 U/ml) (p 0.002).

Marsh III, II/I and 0 were seen in 24%, 39% and 34% of cases and 0%, 32% and 68% of controls (p=0.002).

Of 11 pts. with CD (mean age 43 yrs, 3 with silent disease) 5 of 7 who underwent liver biopsy had NCIPH. Follow up on GFD duration median 8 (3 – 14) months, TTG Antibody became negative in 5 patients and villous atrophy reversed in 3 patients.

IgA anticardiolipin antibodies were not positive in any of the patients with CD. Gut permeability was increased in 4 of 8 (50%) pts of CD

Conclusion: CD was seen in 24% pts. of cryptogenic cld which is much higher than reported prevalence in India. Of these 5 of 7 pts (71%) who underwent liver biopsy had NCIPH. NCIPH was recognised as the predominant cause of cryptogenic intrahepatic portal hypertension in our unit. Adult onset celiac disease was diagnosed in 10 patients. GI symptoms improved in all patients however an improvement in liver functions could not be determined probably because of the short follow up.