

EVALUATION OF PATIENTS WITH SWALLOWING DIFFICULTIES BY MODIFIED BARIUM SWALLOW

**DISSERTATION
SUBMITTED FOR M.S(ENT)
BRANCH IV
APRIL – 2014**



**THE TAMILNADU DR. M.G.R. MEDICAL UNIVERSITY
CHENNAI – TAMILNADU**

CERTIFICATE

This is to certify that this dissertation titled **“EVALUATION OF PATIENTS WITH SWALLOWING DIFFICULTIES BY MODIFIED BARIUM SWALLOW”** is the original andbonafide work done by **Dr.B.MUTHUKUMAR** under the guidance of **Prof.Dr.T.RAMANATHAN,M.S,DLO**, HOD and Professor, Department of Oto rhino laryngology at the Thanjavur medical college and Hospital, Thanjavur,during the tenure of his course in M.S(ENT) from May-11 to April-14 held under the regulation ofthe TamilnaduDr.M.G.R. Medical University,Guindy, Chennai- 600032.

PROF.,Dr.T.RAMANATHAN,M.S,DLO **PROF.Dr.K.MAHADEVAN,M.S**

Professor and Head

DEAN

Department of Otorhinolaryngology,

Thanjavur Medical college

Thanjavur Medical college

Thanjavur- 613 004

Thanjavur- 613004.

Place: Thanjavur

Place: Thanjavur

Date: .12. 2013

Date: .12.2013

CERTIFICATE BY THE GUIDE

This is to certify that this dissertation titled **“EVALUATION OF PATIENTS WITH SWALLOWING DIFFICULTIES BY MODIFIED BARIUM SWALLOW ”** is the original and bonafide work done by **Dr.B.MUTHUKUMAR** under my guidance and supervision at the Thanjavur Medical college & Hospital, Thanjavur- 613 004, during the tenure of his course in M.S(ENT) from May-2011 to April 2014 held under the regulation of the Tamilnadu Dr.M.G.R. Medical University, Guindy, Chennai-600032.

PROF.Dr.T.RAMANATHAN,M.S,DLO

Professor and Head

**Department of Otorhinolaryngology,
Thanjavur Medical college
Thanjavur- 613 004.**

Place: Thanjavur

Date :

ACKNOWLEDGEMENT

I would like to express my most sincere thanks to the following beloved and respected persons who went the extra mile to help me in completing this dissertation. First of all, I thank our **DEAN**, for granting me the permission to carry out this work.

I wish to express my sincere and profound gratitude to our **PROF .DR. T. RAMANATHAN, M.S, DLO**, HOD, Dept. of otorhinolaryngology, Thanjavur Medical College Hospital, for his valuable guidance, constant encouragement, words of advice and judicious help during the course of this project.

I take immense pleasure in thanking our **Prof.DR.A.RAVINDRAN,M.S,DLO, DR.SEENIVASAN,M.D(Radiology)** for their valuable suggestions, encouragement and guidance throughout my study.

I would also like to express my sincere thanks to my Assistant Professors **DR. B. GANESH KUMAR,M.S,DLO,& DR.K.RAMESH BABU, M.S(ENT),DR.M. KAVITHA,M.S(ENT),DGO DR.D.PRINCE PETER DHAS ,M.S(ENT)**, and **Speech language pathologist Mrs.SajeeSridhar**, for their help and cooperation throughout my study.

I am highly indebted to all technicians , all staffs of ENT and Radiology Department and Librarians for their timely help throughout my study. I thank my colleagues & friends who helped me in this work. I wish to record my sincere respect & to all those patients who despite their agony and suffering have helped in moulding this study.

ABSTRACT

EVALUATION OF PATIENTS WITH SWALLOWING DIFFICULTIES BY MODIFIED BARIUM SWALLOW TECHNIQUE

Patients with swallowing difficulties are commonly encountered in the ENT OPD. Swallowing disorders can occur at any age but it is more common in the elderly patients. Neurological causes and malignancy account for the main reason in most of the cases. The modified barium swallow provides information about the complex split second events underlying the swallowing process. We can evaluate the effectiveness of swallowing manouveres by which we can prevent aspiration in patients with pharyngeal retention.

AIMS

1. To study the various phases of swallowing in patients with dysphagia by modified barium swallow
2. To identify the patients with risk of aspiration during swallowing
3. To study the effectiveness of swallowing manouveres by the modified barium swallow technique

Materials and methods:

200 patients who attended ear, nose, and throat out patient department with history of swallowing difficulties for more than

3 months were included in the study. Modified barium swallow was done in all these patients.

Patients with risk of aspiration were detected by the amount of pharyngeal retention in the pyriform sinuses and vallecula after swallowing. The patients with grade 3 severe form of pharyngeal coating were given training for postural technique and swallowing manoeuvres to prevent aspiration.

Results:

Out of the 200 patients, 92 patients were found to have abnormal findings during the study. Other 108 patients had normal findings on videofluoroscopy. Out of the 92 patients with the abnormal videofluoroscopic findings, 28 patients have pharyngeal retention alone with no other structural abnormalities. We focussed mainly on the patients with pharyngeal retention. 16 of them were found to have grade 3 severe pharyngeal retention. These patients had history of stroke in the past. They were given training on swallowing manoeuvres to prevent aspiration. We found that these manoeuvres are effective in doing so. Another 12 patients had pharyngeal retention with no aspiration risk and they were in between the 61-80 yrs.

Keywords: Swallowing difficulty, modified barium swallow, pharyngeal retention, aspiration, swallowing manoeuvres

TABLE OF CONTENTS

S.NO	CONTENTS	PAGE NO
1.	INTRODUCTION	1
2.	AIMS	6
3.	MATERIALS AND METHODS	7
4.	ANATOMY OF SWALLOWING APPARATUS	15
5.	PHYSIOLOGY OF SWALLOWING	20
6.	EVALUATION OF DYSPHAGIA	46
7.	REVIEW OF LITERATURE	53
8.	RESULTS AND ANALYSIS	66
9.	DISCUSSION	76
10.	SUMMARY	90
11.	CONCLUSION	93
12.	BIBILIOGRAPHY	94
13.	ANNEXURES	98

EVALUATION OF PATIENTS

WITH

SWALLOWING DIFFICULTIES

BY

MODIFIED BARIUM

SWALLOW TECHNIQUE

INTRODUCTION

INTRODUCTION :

The very purpose of living beings in this earth is to live and to transfer the genes to the next generation. All invertebrates and vertebrates take in nutrition in one or other ways such as diffusion, absorption, and eating depending on their evolutionary level for their fittest survival in this earth. All vertebrates without any exception eat and swallow their foods. As a well evolved species among the vertebrates we humans face with difficulties in swallowing, coined as a term “dysphagia”, derived from greek word “dys” meaning “with difficulty” and “phagia” meaning “to eat”.

DEFINITION :

It is the subjective sensation of swallowing difficulty during the passage of a solid or liquid bolus from mouth to stomach.

HISTORICAL ASPECTS:

Generally, a healthy adult swallows between 800 and 2400 times a day. Exploration into the physiology of swallowing were tried very well before the invention of the modern investigations and the muscles and nerves responsible for the act of swallowing were defined. *Magendie* was the physiologist who first studied the phases of swallowing and the anatomic regions traversed by the “bolus” to be swallowed.

EPIDEMIOLOGY :

Swallowing disorders can occur at any age resulting from congenital abnormalities or structural problems. It is common among the older age group, especially among the elders. Patients with stroke, acute and chronic illnesses suffer the most.

A careful history and clinical examination can point to the phase and site of dysphagia.

CLASSIFICATION :

Depending on the phase of difficulty, it is classified into

1. Oropharyngeal dysphagia and
2. Esophageal Dysphagia

OROPHARYNGEAL DYSPHAGIA:

The main complaints of patient with oropharyngeal dysphagia are difficulty in swallowing especially in the initial phase, cough, choking and regurgitation through the nose. Local anatomical defects like diverticulum or pathological lesions like web or tumour and CNS disorders like cerebrovascular accident, Parkinson's disease, Myasthenia gravis, Alzheimer's disease and muscular dystrophy may be the cause.

ESOPHAGEAL DYSPHAGIA:

Here the main complaints of the patients will be sensation of blockage and a feeling that food "sticks" after swallowing. However, the patient's subjective assessment of the site of dysphagia does not always correlate with the site of the actual pathology. The abnormalities of the middle

one third or distal one third of esophagus can cause dysphagia which may be referred to the pharynx or superior part of the thorax.

OTHERS:

Mechanical obstruction of the esophagus is classically with difficulty in swallowing for solids rather than liquids. Peptic stricture, carcinoma and a lower esophageal ring (Schatzki's ring) are the common obstructive causes. In patients with on and off difficulty in swallowing for solids, the cause will be an esophageal mucosal ring in most of the occasions. In eosinophilic esophagitis, the complaints will be difficulty in swallowing for solids only and the patient will be young in age. In patients with a progressive nature of difficulty in swallowing and weight loss in the narrow period of time suggests dysphagia due to malignancy.

Patients with motility disorders commonly presents with difficulty in swallowing for both solid foods and liquids which is gradually progressive.

Mechanical changes to swallowing related anatomical structures following surgery, cancer, inflammation, trauma are possible causes of dysphagia. Any anatomical abnormalities in the oral or nasal cavity, pharynx, larynx, trachea or oesophagus that one is born with can also lead to dysphagia. Moreover, a variety of neurological impairments such as stroke, cerebral palsy, Parkinson's disease, general brain injury, trauma and insult commonly disrupt the neurophysiology of normal swallowing.

MODIFIED BARIUM SWALLOW TECHNIQUE:

It is also known as video deglutition study or videofluoroscopic study. Other names are cine swallow study, cookie swallow study, oropharyngeal motility study and video fluoroscopic oropharyngeal swallow study.

'*Logemann*' is the pioneer of this study and he has done several studies in the field of this investigation. It is the 'gold standard investigation' for the patients with any disorders of swallowing for the assessment of swallowing mechanism because we can visualize the bolus flow in real time starting from the mouth to the lower oesophageal sphincter. We can also visualize the presence and timing of aspiration and we can identify the causative factor for aspiration. The effects of various bolus volumes and bolus textures can also be studied. Based on these findings, we can plan the treatment strategies by which aspiration can be prevented. Recommendations regarding diet type, advice on oral or non oral intake can also be made.

POSTURAL TECHNIQUES AND SWALLOWING MANOUVERES:

Changing the positioning of body, head and neck before the onset of pharyngeal phase of deglutition while maintaining that position till the entire swallow is completed is defined as postures. Manual movements of oral, pharyngeal or laryngeal structures which are under voluntary control before the onset or during the pharyngeal phase of deglutition which is capable of increasing the force of swallowing and protecting the airway also are called as manouveres. Postural techniques like chin tuck or

headflexion, head rotation and swallowing manouveres like Mendelsohn's manouvere, supraglottic swallow technique and super supraglottic swallowing technique can influence the swallowing physiology. So, these techniques and manouveres can be used as therapeutic methods in patients with risk of aspiration during swallowing.

AIMS

- 1.To study the various phases of swallowing in patients with dysphagia by modified barium swallow**
- 2.To identify the patients with risk of aspiration during swallowing**
- 3.To study the effectiveness of swallowing manouveres by the modified barium swallow technique**

MATERIALS AND METHODS

PATIENTS:

200 patients who attended ear, nose, and throat out patient department of our hospital with history of difficulty in swallowing ,feeling of lump in the throat , foreign body sensation of throat and patients with history of cough during swallowing for more than 3 months were included in the study.Critically ill and unco-operative patients were excluded from the study. The study period was from August 2011 to August 2013.Out of these 200 patients, 109 were males and 91 were females. The age range of patients were 20 to 80 yrs.The Chief complaints of patients for difficulty in swallowing for solids only in 128 patients,solids and liquids in 68 patients and liquids only in 4 patients. Co-existing illnesses which are known to cause swallowing difficulties like stroke were noticed in 16 individuals of our study population.

Inclusion criteria

Patients in the age between 20-80 yrs with the chief complaints of difficulty in swallowing,feeling of lump in the throat,foreign body sensation in throat and patients with history of cough during swallowing

Exclusion criteria

Critically ill patients

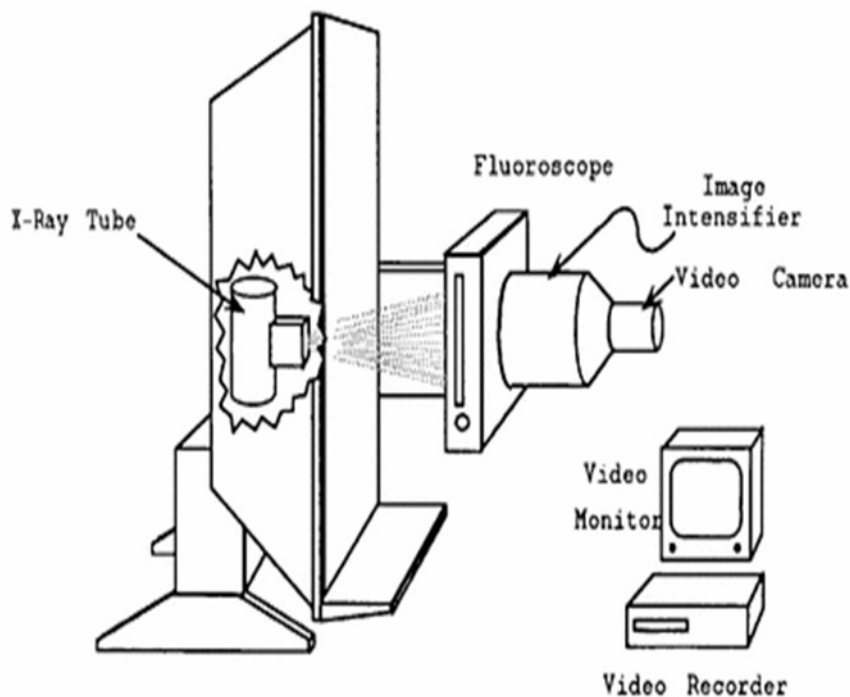
Un co-operative patients

CLINICAL EVALUATION:

Prior to modified barium swallow examination, a detailed medical history obtained.History on limitations of certain type of diet,manner

with which the food is swallowed, and history of any choking or coughing during swallowing was enquired. Detailed clinical examination of oral cavity and throat was carried out. Bed side evaluation of swallowing was done with various consistencies of foods.

MODIFIED BARIUM SWALLOW TECHNIQUE:



It is defined as dynamic X-ray images of swallowing that combine traditional fluoroscopy with video technology to capture the motion and record it. Using this video, the swallowing process is reviewed in realtime, frame-by-frame, or in slow motion. To capture a fluoroscopic video of the swallowing process, the subject sits upright in front of an X-ray machine while the camera records a lateral view of the head and neck. The X-ray machine is turned on only during the swallow to limit the radiation dose. Modified barium swallow techniques is done with patient in erect position. Lateral and antero posterior directions

viewed in real time as the patients swallows the radio opaque barium suspension. Initially patients are given with 15ml of barium suspension in the lateral view. Oral cavity and pharynx are concentrated in the centre of view.If there is no difficulty in swallowing with 15 ml of barium ,patient is given another 30 ml of barium and the centre of view is concentrated over the pharynx and oesophagus.Then another 15 ml of barium is given to view the pharynx in antero posterior direction. If we expect patients with possible aspiration during swallowing,initially 3ml of water soluble non- ionic thin barium is given.Then it is gradually increased to 5ml,10ml and 15ml.The recorded images are then reviewed with the help of the Radiologist and Speech language pathologist of our hospital. Pharyngeal mucosal coating is a finding which was taken as the predictor of aspiration.It is graded as grade1 ,2 and 3

Grade 1 – mild form – residue of barium is below 25% of the height of the vallecula or pyriform sinuses

Grade 2 – moderate form - residue of barium is below 50% of the height of the vallecula or pyriform sinuses

Grade 3 – severe form - residue of barium is below 75% of the height of the vallecula or pyriform sinuses.

The patients with grade 3 severe form of pharyngeal coating were given training for postural technique and swallowing manoeuvres to prevent

aspiration. Patients with grade 1 and 2 of pharyngeal mucosal coating were given advice on diet modification as suggested by the videofluoroscopic images recorded with various consistencies of boluses.

RADIOLOGICAL FINDINGS DURING ORAL PHASE AND THEIR INFERENCE

Unable to hold barium in mouth anteriorly	Reduced lip closure
Unable to chew	Reduced tongue lateralisation
Hesitation initiating swallow	Neurological disorders
Forward movement of tongue at onset of swallow	Forward tongue thrust
Stasis in bucco labial sulci	Reduced labial or buccal tension
Stasis in floor of mouth	Reduced tongue shaping
Reduced tongue to palate contact	Reduced tongue elevation

RADIOLOGICAL FINDINGS DURING THE PHARYNGEAL PHASE AND THEIR INFERENCE

Absent or decreased hyoid movement	Weakness of suprahyoid muscles
Residue in vallecula or pyriform sinus	Impairment of pharyngeal peristalsis
Laryngeal penetration or aspiration	Premature spill, grade 3 pharyngeal retention
Abnormal opening of upper oesophageal sphincter	Impaired relaxation of upper oesophageal sphincter

VIDEOFLUOROSCOPIC SWALLOWING STUDY REPORT

Findings during oral phase

- Oral drooling : yes/no
- Oral stasis : yes/no
- Premature oral leakage : yes/no
- Tongue – palate contact : normal/abnormal
- Bolus holding : normal/abnormal
- Piecemeal swallowing : yes/no

Findings during pharyngeal phase:

Vallecular stasis	: yes/no
Velar elevation	: normal/abnormal
Hyoid bone elevation	: complete/not
Pharyngeal mucosal coating	: normal/abnormal
\Pharyngeal nasal reflux	: yes/no
Pyramidal sinus stasis	: yes/no
Pharyngeal contraction	: normal/decreased
Epiglottic movement	: normal/fixed
Pharyngeal oral reflux	: yes/no
Retropharyngeal soft tissue	: normal/abnormal

MODIFIED BARIUM SWALLOW MEASUREMENT TOOL FOR SWALLOW IMPAIRMENT(MBSIMP)

1. LIP CLOSURE

2. HOLD POSITION/TONGUE CONTROL

3. BOLUS PREPARATION/LINGUAL MOTION

4. BOLUS TRANSPORT/LINGUAL MOTION

5. ORAL RESIDUE

6. INITIATION OF THE PHARYNGEAL SWALLOW

7. SOFT PALATE ELEVATION

8. LARYNGEAL ELEVATION

9. ANTERIOR HYOID MOTION

10. EPIGLOTTIC MOVEMENT

11. LARYNGEAL CLOSURE

12. PHARYNGEAL STRIPPING WAVE

13. PHARYNGEAL CONTRACTION

14. PHARYNGOESOPHEAL SEGMENT OPENING

15. TONGUE BASE RETRACTION

16. PHARYNGEAL RESIDUE

17. OESOPHAGEAL CLEARANCE IN THE UPRIGHT POSITION

ANATOMY
OF
SWALLOWING APPARATUS

ANATOMY:

The anatomic components of the swallowing apparatus in head and neck includes

- (1) cartilages, bones
- (2) muscles,
- (3) cranial nerves and its branches.

The hard palate opposes the tongue during the oral phase. The temporomandibular joint permits grinding and chewing in the initial preparatory phase and the joint will be in a closed position when the patient swallows. The anchor of the pharynx to the skull base is pharyngobasilar fascia which originates from the basiocciput. The cervical spine is a flexible posterior support for the pharynx. Membranous planes ensheathing the pharynx allow free axial movements. The hyoid bone is an intermediate support for larynx and platform of the tongue. It is suspended by the suprahyoid musculature. The larynx and the hyoid bone are interconnected by strap muscles and thyrohyoid membrane.

The anterior wall of the hypopharynx is formed by laryngeal structures and the anterior wall of the oropharynx is formed by the base of the tongue.

MUSCLES AND CRANIAL NERVES:

A total of 31 paired striated muscles are involved during the first phases of swallowing. The muscles of mastication are supplied by the mandibular branch (V3) of the CN V. The facial muscle movement, supplied by the CN (VII), has an important role during chewing. Movements of the tongue is the main event in first two phases of deglutition. Tongue movements is by the four intrinsic and extrinsic muscles. All the muscles of tongue are supplied by the hypoglossal nerve CN(XII), and except palatoglossus which is supplied by the Vagus nerve CN(X). All the muscles of the soft palate are supplied by vagus nerve CN (X) , except tensor velipalatini, which is supplied by mandibular branch of Trigeminal nerve(V3). All the pharyngeal muscles are innervated by the Vagus nerve CN (X) except the stylopharyngeus, which is supplied by the Glossopharyngeal nerve CN (IX). The muscles of larynx are supplied by the recurrent laryngeal nerves except the cricothyroids which is innervated by the superior laryngeal nerves through its external branch.

Suprahyoid and infrahyoid muscle groups are innervated by CN V3, CN VII, and the ansacervicalis (C1-C2).

NEURAL CONTROL:

The regulation of the swallowing is controlled by the following components of the nervous system:

- (1) Motor fibers from centres (efferent) and the C1, C2 (ansacervicalis)
- (2) sensory fibres from periphery to centres (afferent)
- (3) cerebral, midbrain, and cerebellar fibers synapsing within the midbrain swallowing centers
- (4) Brain stem swallowing centers .

The swallowing centres in the brainstem receive the signals from the sensory fibres and processing the information. From the CNS, output signals are sent to the muscles of swallowing.

AFFERENT PATHWAY:

Sensory CN pathway goes directly to the brainstem swallowing centres and is provided mainly by Glossopharyngeal (CN IX) and Vagus (X) nerves, along with some part by the branch of trigeminal CN (V2) and facial (VII) nerves. Taste sensation is carried from the anterior two thirds of tongue by facial (CN

VII)nerve. Coarse touch sensation from the lips and face is also carried by the facial nerve which also contains sensory fibers from the posterior part of the larynx, tongue base, and hypopharynx get the sensory supply from the superior laryngeal branch of the Vagus(CN X)nerve. Optimal stimuli has regional variations. Even light touch at the anterior pillars, liquids in hypopharynx and the laryngeal inlet are most sensitive. Touch sensations from the oral cavity, tongue and pharynx is a main stimulus for swallowing whereas taste is the poor one for the same. Sensory fibers from the pharynx are responsible for gag reflex, cough or other protective reflexes .

BRAINSTEM SWALLOWING CENTERS:

Broad areas of nucleus tractussolitarius and reticular formation which are poorly defined form the paired swallowing centers in the hindbrain . Sensory signals from the centers transmitted within the reticular formation or nucleus tractussolitarius. The network of interneurons in the swallowing centres which processes input signals thereby triggering the swallowing response and sends appropriate signal to CNS motor nuclei ,their axons and then the signals to the muscles involved in swallowing.

Two major hypotheses for execution of first 2 phases

(1) reflex-chain hypothesis

According to this hypothesis, sensory receptors are stimulated by the bolus passing through the mouth and pharynx thereby triggering the next phase of the swallowing. The posterior movement of the tongue is believed to stimulate the swallowing in the absence of the bolus.

(2) central pattern generator hypothesis.

As per this theory, the independently functioning brainstem swallowing centers act in a stereotyped manner when the swallowing is initiated. Both the hypotheses are supported by several studies now. The initial two phases of swallowing are under voluntary control and it is a basic medullary process that can be modified by volume and consistency of the boluses.

PHYSIOLOGY
OF
NORMAL SWALLOWING

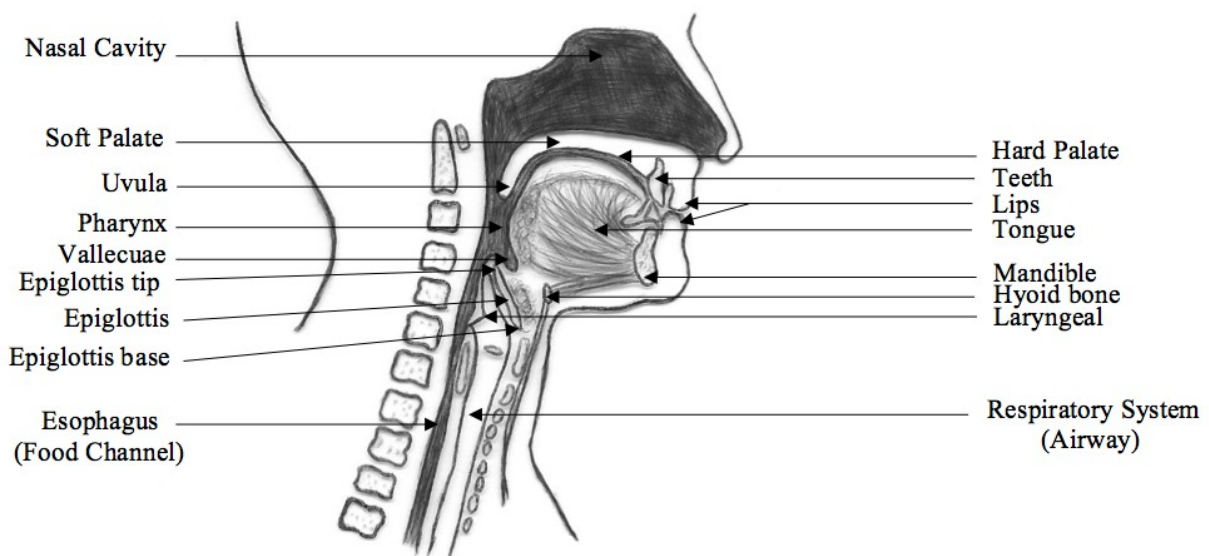
PHYSIOLOGY OF NORMAL SWALLOWING

Swallowing is a complex pattern that involves different levels of brain control and sequential activation and deactivation of various muscle groups (oral, pharyngeal, laryngeal, and esophageal) .

This complex pattern is divided into 4 phases

- 1) oral preparatory,
- 2) oral transit,
- 3) pharyngeal, and
- 4) esophageal phases.

Figure 1: Body parts involved in the swallowing process



ORAL PREPARATORY PHASE:

In oral preparatory phase, food is chewed and mixed with the saliva and formed into a bolus. The bolus is kept inside the mouth, as seen in Figure 2, under the hard palate between the front of the tongue, which is elevated to the lip and the back of the tongue which is elevated against the depressed soft palate.

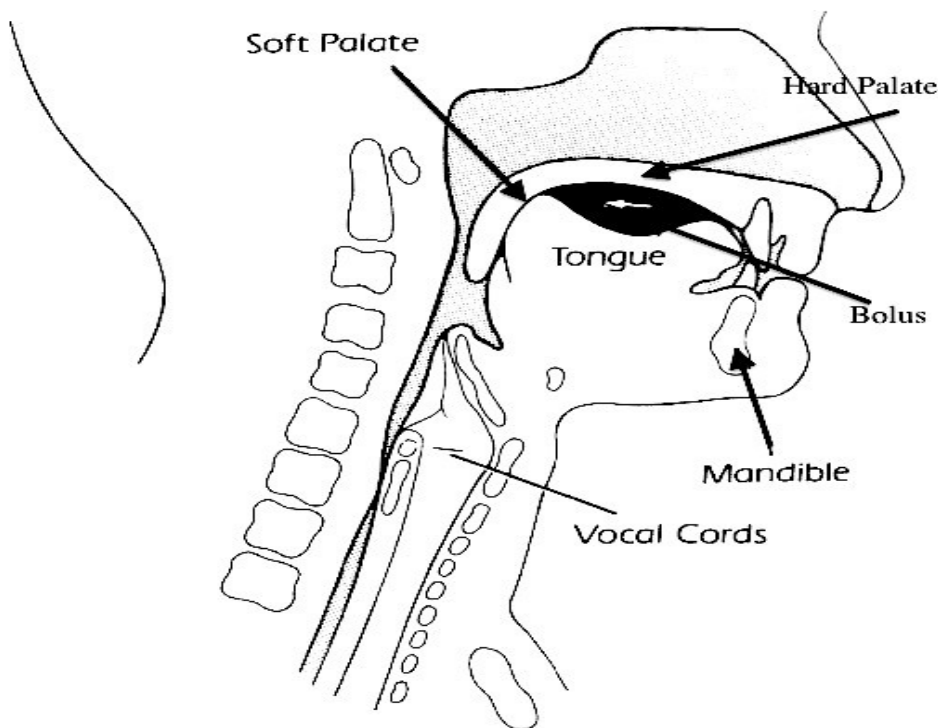


Figure 2: Oral Preparatory phase

ORAL TRANSIT PHASE:

During this phase, the bolus is propelled by the tongue by backward rolling motion. The back of the tongue is depressed as the front is elevated against the hard palate as shown in Figure 3. The oral transit phase

ends when the bolus passes the anterior of the throat and touches the posterior wall of the pharynx.

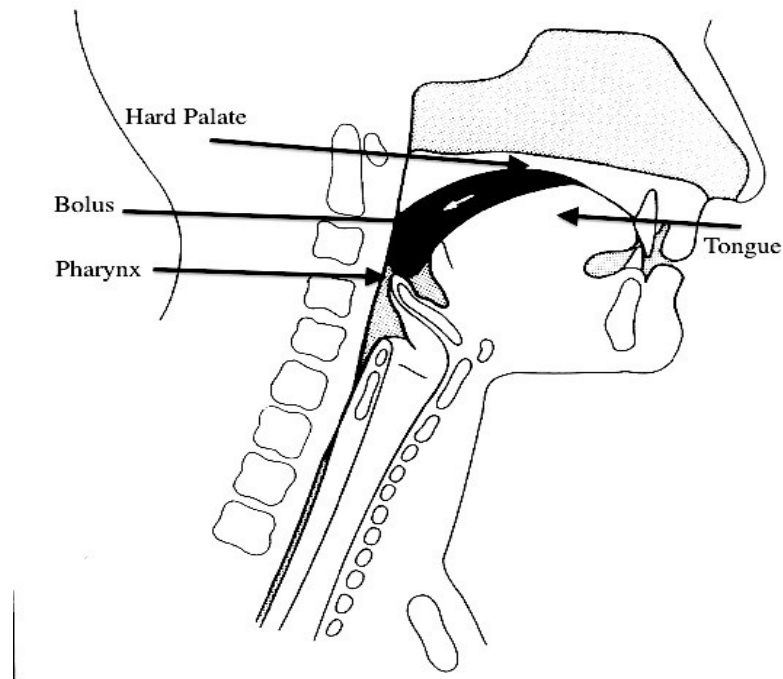


Figure3 : Oral phase

PHARYNGEAL PHASE:

During the pharyngeal phase, the airway is closed to prevent aspiration. The soft palate is elevated to open the upper pharynx. The nasal aperture is closed as a result of the elevation of the soft palate to prevent the bolus from entering into the nasopharynx region. In addition, laryngeal aperture is closed by

the epiglottis to prevent the food from entering into the airway, as shown in Figure 4.

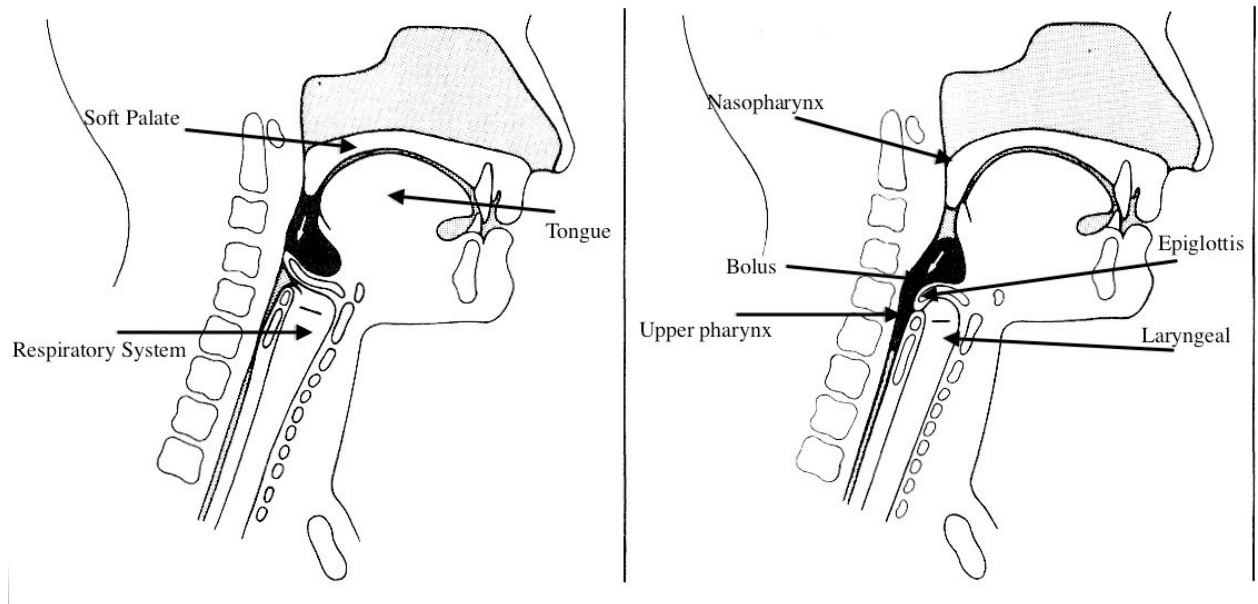


Figure 4. Pharyngeal phase

LARYNGEAL SUB-PHASE:

The pharyngeal phase has a sub-phase called the laryngeal sub-phase. First, the larynx is pulled upward and forward to enlarge the pharynx, which creates a vacuum and pulls the bolus down. Second, the vocal folds adduct. Third, the epiglottis closes the top of the larynx to force the bolus to enter the esophagus.

ESOPHAGEAL PHASE:

Finally, during the *esophageal phase*, the bolus travels down the esophagus to the stomach, propelled by a squeezing action of the throat muscles, as shown in below.

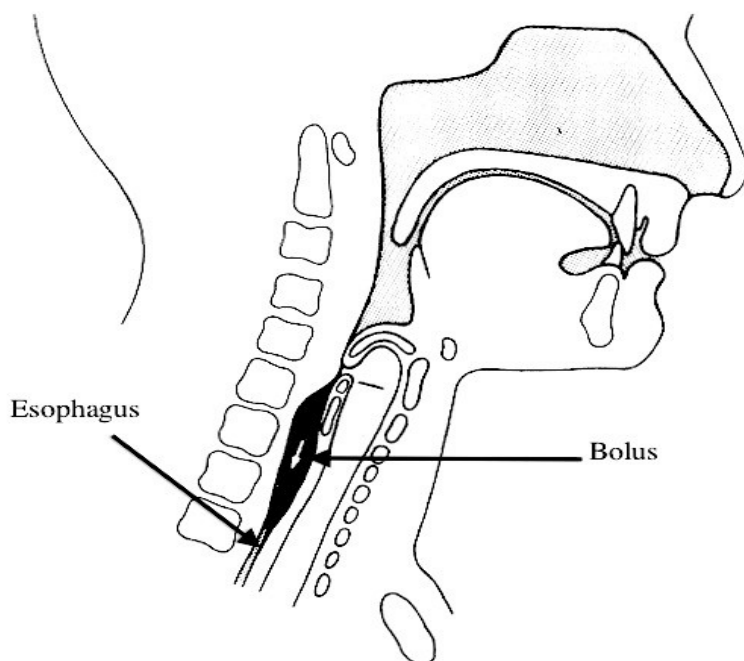


Figure 5

The upper digestive tract, made up of the oral cavity, pharynx, and larynx, supports the physiology of deglutition in addition to respiration, phonation, and articulation. The area is well vascularized and has a consistent architecture of

lymphatic vessels and consistent drainage into regional lymph nodes . To accomplish each of these functions and the rapid transitions between them, the upper aerodigestive tract contains a series of valves that are adjusted differently for each function. During deglutition, the valves in the oral cavity and pharynx are adjusted to direct the flow of food safely and efficiently from the mouth through the pharynx and into the esophagus. At the same time, pressure is exerted on the food or liquid to move it rapidly and cleanly, leaving minimal residue in the mouth or pharynx when the swallow is completed. Thus, valve operation and pressure generation are the critical components of normal, efficient, and safe operation of the upper aerodigestive tract during deglutition. Valves may function differently for swallow, speech, and respiration.

VALVE FUNCTION FOR DEGLUTITION:

There are six valves that operate during swallow within the upper digestive tract: lips, tongue, velum to back of tongue (the glossopalatal valve), velopharynx (velum to posterior pharyngeal wall), larynx, and upper esophageal (cricopharyngeal) sphincter.

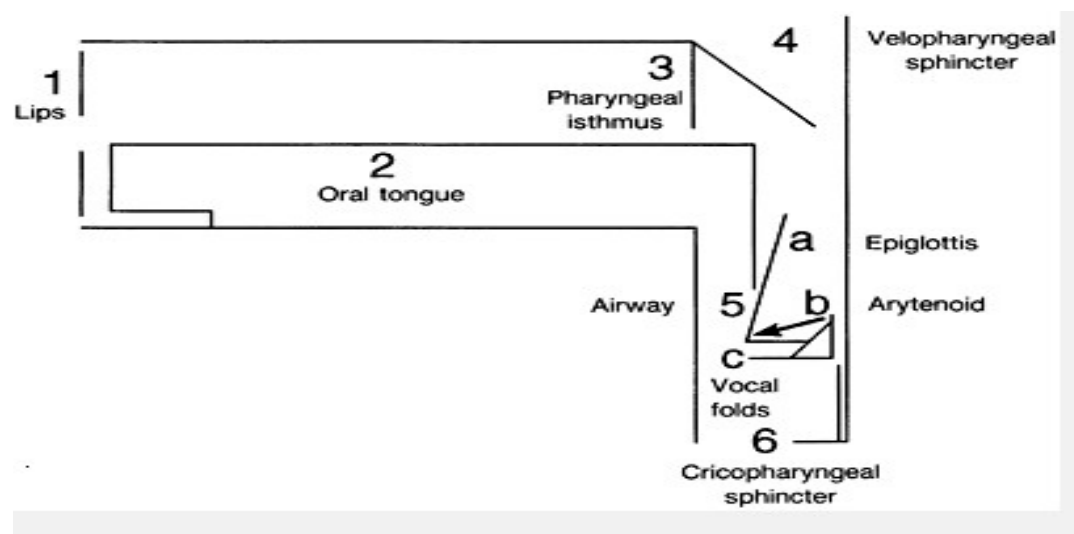
The lips (orbicularis oris muscle) form the first and most anterior valve, closing around a spoon, fork, cup, or straw to capture food and liquid in the oral cavity, preventing drooling. Lip closure is maintained throughout the oropharyngeal stages of swallow. Lip closure permits mastication without loss of food from the mouth and the generation of pressure in the oral cavity to propel the bolus

posteriorly during the oral stage of swallow. Reduction in lip closure results in loss of food or saliva from the mouth anteriorly.

The tongue is the second and most mobile valve within the upper digestive tract and is involved in very different ways in oral preparation and the oral and pharyngeal phases of deglutition. The tongue is composed almost entirely of muscle fibers going in all directions. The oral portion of the tongue is under volitional cortical control and is largely responsible for movement of the food during chewing and oral preparation. During mastication, the tongue positions food on the teeth, picks it up as it is crushed by the teeth, mixes the food with saliva, and replaces it onto the teeth in a rotary lateral action. Facial tone prevents food from falling into the lateral sulci during chewing. At the end of oral preparation, the tongue rapidly brings the food particles together into a cohesive ball or bolus, in preparation for initiation of the oral stage of swallow. If a large amount of food is placed in the mouth after chewing, the tongue subdivides the material, forming a bolus that is the right volume in relation to the food's viscosity. The thicker the food viscosity, the smaller the bolus. Excess food is put to the side by the tongue for later swallowing.

The edges of the tongue then begin the oral stage by making anterior and lateral contact with the anterior and lateral alveolar ridge. Vertical midline tongue-to-palate contact progresses antero-posteriorly, propelling the bolus ahead of it toward the pharynx . The pressure of the tongue against the palate increases as the bolus viscosity increases. All of this lingual control during oral preparation

and the oral stage of swallow is thought to be under voluntary cortical control. When there is no peripheral seal of the sides of the tongue to the alveolar ridge or reduced range of tongue motion or damage to fine motor control of the tongue, the person may experience difficulty in chewing, controlling food in the mouth, forming a bolus, or propelling the bolus posteriorly.



Lateral schematic view of the oral cavity and pharynx with the six valves identified: 1, lips; 2, tongue; 3, soft palate to tongue; 4, velopharynx; 5, larynx, including the true vocal folds (c), the false vocal folds and the arytenoid to epiglottic base (b), and the epiglottis (a); and 6, the cricopharyngeal (upper esophageal) sphincter.

As the bolus passes the faucial arches, back of the tongue, or the point where the ramus of the mandible crosses the base of tongue, the pharyngeal swallow should trigger. This is accomplished by peripheral afferent input to the cortex and the brainstem swallowing centers (the nucleus solitarius and the nucleus ambiguus) and a motor program output. As we age, the pharyngeal stage triggers later. The later triggering of the pharyngeal stage with age is thought to result from slowing in neural processing.

When the pharyngeal swallow triggers, a number of physiologic events occur in the pharynx. When the bolus tail reaches the valleculae during the pharyngeal swallow, the base or pharyngeal portion of the tongue moves rapidly backward to contact the inward moving posterior and lateral pharyngeal walls. This base of tongue action applies pressure to the tail of the bolus, propelling it cleanly through the pharynx. Neurologically, this base of tongue retraction during the pharyngeal swallow is under brainstem (medullary) control. If there is reduced base of tongue retraction, such that the tongue base does not contact the pharyngeal walls, there will be residue in the valleculae after the swallow, which may ultimately fall into the airway and be aspirated. The soft palate contact to the back of the tongue makes up the third or glossopalatal valve, which is operative while holding a bolus in the mouth before beginning the oral stage of swallow. As food is held in the mouth or gently manipulated before swallow, the soft palate is actively pulled down and forward by the palatoglossus muscle to contact the back of the tongue, which is elevated slightly. Closure of this posterior glossopharyngeal valve prevents premature loss of food or liquid into the pharynx and widens the nasal airway to ensure easy nasal breathing during chewing and oral manipulation of food. During active chewing, this valve does not operate so that premature spillage of food into the pharynx while chewing is quite normal in individuals of all ages. While sucking liquid into the mouth from a straw, the soft palate is also normally pulled down in contact with the back of the tongue so that suction is created

intraorally. After the liquid bolus is drawn into the mouth through the straw, the oral swallow is initiated, and the soft palate elevates away from the back of the tongue. It is also possible to suck liquid from a straw using an inhalation with an open airway and an elevated and retracted palate. Sucking in this manner can increase the risk of inhaling food into the airway. The fourth valve, the velopharyngeal port, closes during the pharyngeal phase of swallow to prevent the entry of food or liquid into the nasal cavity. Velopharyngeal closure may be accomplished using velar elevation (levator muscle) and retraction (palatopharyngeal muscle) alone or in combination with anterior movement of the posterior pharyngeal wall (Passavant's ridge) or medial movement of the lateral pharyngeal walls (superior constrictor). The adenoid pad may also contribute to velopharyngeal closure. If complete velopharyngeal closure is not attained during swallow, nasal regurgitation may occur. The fifth valve, the larynx, closes at three different levels during swallow to prevent the entry of food or liquid into the airway. The true vocal folds close first, followed by the false vocal folds with anterior tilting of the arytenoid cartilage to contact the base of the epiglottis and close the laryngeal entrance. Finally, the epiglottis is folded over the top of the airway biomechanically. The larynx, including the cricoid cartilage, is suspended in the neck by muscles (thyrohyoid) and ligaments attached to the hyoid bone. The hyoid, in turn, is suspended in the neck by the suprahyoid muscles (anterior digastric, mylohyoid, and geniohyoid anteriorly and the stylohyoid and posterior belly of digastric posteriorly).

Contraction of these muscles can move the hyoid in various directions depending on the function underway.

During the normal pharyngeal swallow, the hyoid and larynx elevate and move forward together. As the larynx and hyoid elevate, the epiglottis is folded to a horizontal position. Tongue base retraction brings the tip of the epiglottis backward and continues to squeeze the epiglottis down against the posterior pharyngeal wall, bringing the epiglottis to its most inferior position. As the bolus envelops the epiglottis, the downward pressure of the bolus contributes to this epiglottal descent. As the bolus passes through the pharynx and the tongue base moves anteriorly toward its rest position, the epiglottis elevates and moves anteriorly with the tongue base. When the tip of the epiglottis is no longer in contact with the posterior pharyngeal wall, the elasticity in the cartilage causes it to spring back to its vertical position within 0.03 to 0.06 second.

If the airway fails to lift well during the swallow, part of the bolus is usually captured at the entrance to the airway as it passes through the pharynx. This residual food at the top of the airway may be aspirated after the swallow. If the laryngeal entrance (arytenoid tilting anteriorly to contact the epiglottic base and contracted false vocal folds) fails to close, food can penetrate into the airway entrance and may be aspirated after the swallow. If the entire larynx fails to close, food or liquid passes through the larynx into the trachea during the pharyngeal swallow.

The cricopharyngeal valve or upper esophageal sphincter (UES) is the sixth valve and serves to prevent the entry of air into the esophagus during respiration. During swallow, the UES opens to allow bolus passage into the esophagus. The cricopharyngeal muscle is attached to the lateral aspects of the cricoid cartilage. Therefore, the cricopharyngeal muscle is comprised of the posterior and lateral walls of the UES. The anterior wall of the sphincter is the cricoid lamina. The cricopharyngeal sphincter, then, is a musculoskeletal sphincter, that is, the cricopharyngeal muscle and the cricoid cartilage. The cricopharyngeal muscle varies in its degree of contraction at rest. When stressed (such as when a nasogastric or manometric tube passes through the UES), the degree of muscle contraction is greater. At other times, the level of contraction may be minimal. In sleep, the cricopharyngeal muscle is completely relaxed. During the pharyngeal swallow, as the bolus head (leading edge) leaves the valleculae, the UES opens.

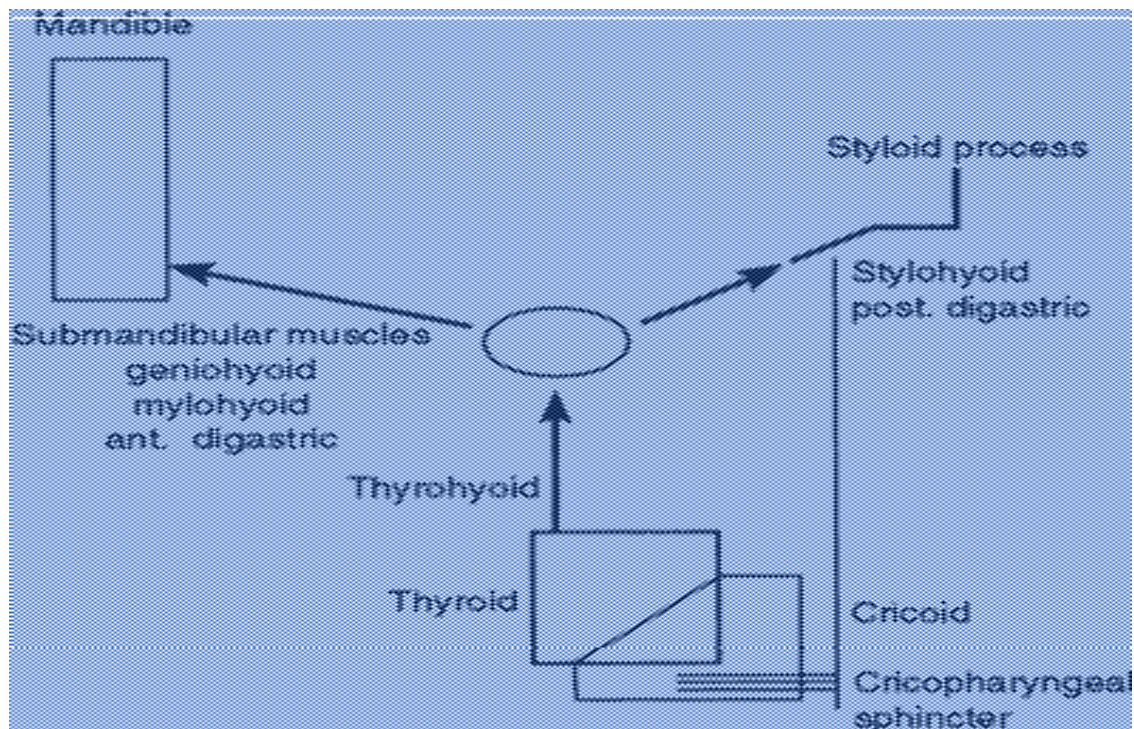


Fig.No.6 Lateral view diagram of the hyolaryngeal suspension system and its relationship to the cricopharyngeal sphincter.

Opening of the UES is a complex event. First, the cricopharyngeal muscle relaxes. However, this muscle relaxation does not open the sphincter. Rather, muscle relaxation is considered to be an enabling event, allowing the larynx to move up and forward. One tenth of a second after the cricopharyngeal muscle relaxes, opening of the UES is observed radiographically. Opening occurs as the larynx and hyoid move anteriorly and the cricoid lamina is jerked anteriorly away from the posterior pharyngeal wall. Thus, the UES is opened by anterior movement of the hyolaryngeal complex. As the bolus passes through the sphincter, the pressure of the bolus increases the width of UES opening . If the cricopharyngeal sphincter (UES) fails to open long or wide enough, there will be residue remaining in the piriform sinus after the swallow. Most often, failure

of the UES to open long or wide enough is caused by disorders of hyolaryngeal elevation and anterior movement or bolus pressure.

PRESSURE GENERATION:

The second major component of deglutition is the generation of pressure on the bolus to drive it from the mouth, through the pharynx, and into the esophagus. Figure 7 present the major sources of pressure generation during the oral and pharyngeal phases of swallow. The oral portion of the tongue propels the bolus posteriorly during the oral phase of swallow, lifting the bolus and exerting pressure against the palate as it rolls the bolus towards the oropharynx. As the bolus passes from the mouth and the pharyngeal swallow is triggered, the pharyngeal pressure generators are activated. The larynx elevates approximately 2 cm and the pharynx is shortened by approximately 2 cm, or one third of its total length during the pharyngeal swallow in younger adults (under age 65). In older adults, this movement may be reduced by 0.5 cm. The pharynx lifts with the larynx as it elevates. The pharyngeal constrictors contract, moving the posterior pharyngeal wall anteriorly and the lateral pharyngeal walls medially and narrowing the pharyngeal diameter sequentially from top to bottom. As the pharynx becomes physically smaller in length and width, the bolus tail has reached the valleculae at the base of the tongue. The tongue base then retracts over the bolus to contact the posterior pharyngeal wall as it contracts and bulges anteriorly. Tongue base retraction acts like a piston during the swallow, moving the bolus through a chamber (the pharynx) of decreasing size and into the

esophagus. If the tongue base fails to retract sufficiently to make complete contact to the inward moving pharyngeal walls, residual food or liquid will remain in the valleculae after the swallow. If there is a unilateral pharyngeal weakness, food will remain in the piriform sinus on the damaged side of the pharynx after the swallow. If both sides of the pharynx fail to contract, food will be left on both sides of the pharynx in the piriform sinuses and the chances of aspiration increases.

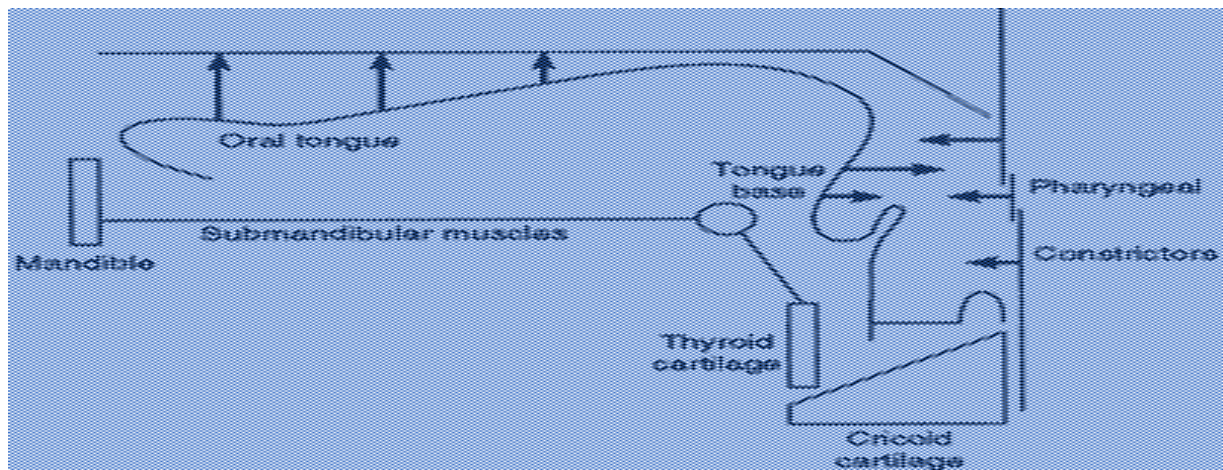


Fig.No8 Lateral schematic view of the pressure generators

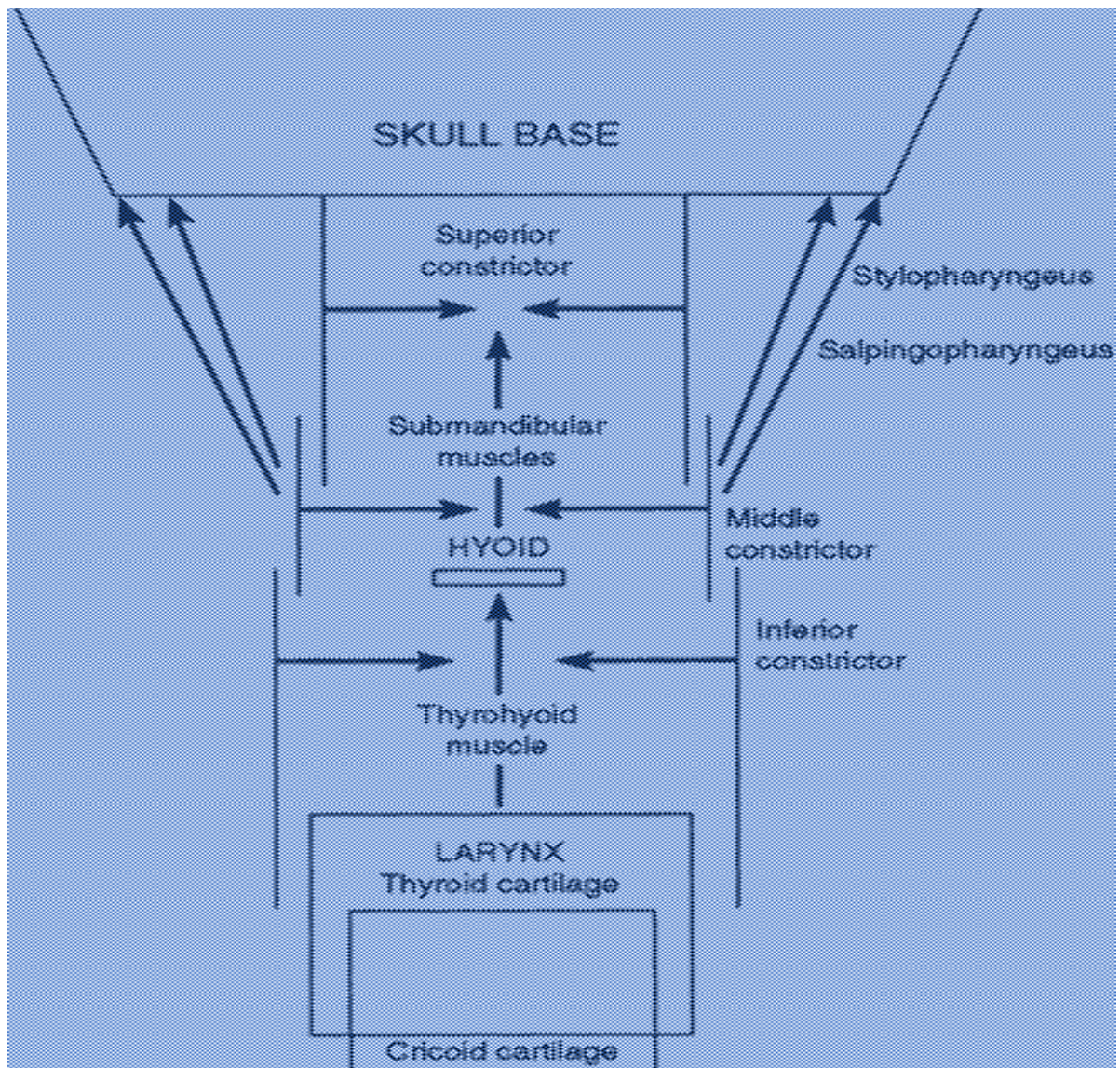


Fig.No9anterior view of pharyngeal elevators and the directions of pharyngeal contraction
COORDINATION OF OROPHARYNGEAL SWALLOW

A normal oropharyngeal swallow requires that all valves and pressure generators operate normally and that these physiologic elements occur in the correct sequence. Oral preparation precedes the oral stage of swallow. Oral preparation involves lip closure and lingual manipulation of the bolus to break it down to a consistency ready for swallow. During mastication, the mandible moves in a lateral rotatory motion in coordination with lateral rolling tongue

movements that bring the bolus onto the biting surfaces of the teeth. During the act of chewing, the velopharynx is open to facilitate nasal breathing, the larynx is open, and the cricopharyngeal region is closed. At the termination of oral preparation, the food or liquid is brought together into a cohesive bolus by rapid and finely coordinated tongue movements. Most of the pleasure of eating occurs during oral preparation.

Before the onset of the oral stage of deglutition, the bolus is held on the floor of the mouth or between the tongue and the palate. If the bolus is held on the floor of the mouth, the front tongue lifts the bolus into the superior position at the onset of the oral swallow. At the initiation of the oral phase, the tongue elevates the bolus against the palate, rolling and squeezing it posteriorly toward the oropharynx. As the bolus passes the faucial arches and the back of the tongue and enters the pharynx, the pharyngeal stage of swallow is triggered. The exact sensory stimulus needed to elicit the onset of pharyngeal swallow events has not been clearly identified. Both the bolus and tongue movement appear to be important components of the sensory stimulus. The region stimulated by the bolus and tongue movement is innervated by the glossopharyngeal cranial nerve (IX), which sends afferent input to the medullary swallow center. As the leading edge of the bolus reaches the pit of the valleculae and the oropharynx, sensory input is carried to the medullary swallow center by the vagus nerve (cranial nerve X). In normal swallowing, the pharyngeal swallow is triggered as the head of the bolus passes the point where the ramus of the mandible crosses the

base of the tongue. If the bolus head (leading edge) passes into the valleculae and the pharyngeal swallow has not been elicited, the pharyngeal swallow is described as delayed. As long as the pharyngeal swallow is delayed, the airway is open. The patient is at risk for aspirating the bolus before the pharyngeal swallow is triggered, especially with thin liquids, which move quickly by gravity.

When the pharyngeal swallow triggers, the hyoid and larynx begin to elevate and move anteriorly, the pharynx shortens, and the velopharyngeal valve closes. The airway closes as the larynx achieves approximately 50% of its elevation. The bolus is propelled by oral tongue movement into the pharynx. When the tail of the bolus reaches the valleculae, the tongue base retracts and the pharyngeal walls contract, applying pressure to the bolus in the pharynx. The cricopharyngeal valve opens as the bolus is moving under pressure from the valleculae to the piriform sinuses. Airway closure and cricopharyngeal opening always occur within 0.03 second of each other unless the airway is closed voluntarily at an earlier time. Thus, the airway is closed and protected as the esophagus is opened to receive the bolus that is being driven through the pharynx under pressure. This entire sequence of pharyngeal events takes place in less than 1 second.

EFFECTS OF BOLUS CHARACTERISTICS ON THE OROPHARYNGEAL SWALLOW:

Recent investigations of swallow physiology with calibrated boluses of various volumes and viscosities have revealed systematic changes in duration of pharyngeal swallow events and their temporal relationships as these bolus variables are changed . Airway closure duration and cricopharyngeal opening duration increase systematically as bolus volume increases and as bolus viscosity increases. However, these two events generally occur within 0.03 second of each other, regardless of bolus volume. Lingual palatal pressures, electromyographic activity, and intrabolus pressures in the pharynx increase as bolus viscosity increases. Oral and pharyngeal transit times of the bolus increase as bolus volume increases and viscosity increases. The temporal relationship of the oral and pharyngeal stages of swallow also changes systematically with bolus volume. On swallows of small volumes (1 to 5 mL), the oral stage proceeds first, followed by the pharyngeal stage. On swallows of larger volumes (10 to 20 mL), the oral and pharyngeal stages occur essentially simultaneously. The neural control underlying these systematic changes in the oropharyngeal swallow has still not been clearly defined. It has been hypothesized that afferent input from the oral cavity, particularly from the tongue as it manipulates the food or liquid and shapes around it to initiate the oral stage of swallow, to the cortex and medullary swallow center modulates these physiologic changes, because many of these systematic changes in the swallow begin while the bolus is still in the oral cavity.

Understanding these systematic changes in normal pharyngeal swallow physiology with various bolus types helps to explain the difficulties of dysphagic patients with various types of boluses. Some bolus characteristics such as taste and texture have not been well studied and may have significant effects on normal and abnormal swallow.

EFFECTS OF VOLUNTARY CONTROL:

Voluntary control can be exerted over many components of the pharyngeal swallow. The airway can be closed voluntarily at the vocal folds (supraglottic swallow) or at the entrance to the airway (super-supra glottic swallow). The duration of laryngeal elevation can be prolonged voluntarily, thereby prolonging the duration of cricopharyngeal opening (Mendelsohn's manoeuvre). The muscle effort used during the oral and pharyngeal phases of swallow can be modified (the effortful swallow). These voluntary modifications are used as therapy strategies for specific pharyngeal swallowing disorders and are sometimes used spontaneously in the course of normal swallows. For example, before taking a large swallow of liquid from a glass or cup, many normal individuals inhale and hold their breath, thus closing their airway before swallowing as an added protection. This action is essentially the supraglottic swallow.

EFFECTS OF POSTURE:

Changing head position changes pharyngeal dimensions and the direction of food flow. With the chin tucked, the entire anterior wall of the pharynx (the

tongue base and epiglottis) is pushed posteriorly and the airway entrance is narrowed. With the head rotated, one side of the pharynx (the side rotated toward) is closed off from the passage of the bolus. Tilting the head to one side directs food down that side of the oral cavity and pharynx. Lifting the chin decreases oral transit time by using gravity to empty food from the mouth. Lying the patient down changes the direction of gravity on any residual food left after the swallow. When the patient is lying down, any residual food simply adheres to the pharyngeal walls rather than falling down the airway after the swallow when the patient returns to breathing. Postural changes are often used as compensatory strategies in the management of swallowing disorders .

EFFECTS OF DEVELOPMENT AND AGING:

During infancy, suckle feeding is used. Suck swallow involves multiple tongue pumping of small amounts of liquid from the nipple, which are collected in the posterior oral cavity or valleculae. When an adequate amount has collected, the pharyngeal swallow triggers. Then the pharyngeal swallow proceeds as in adults. Most normal infants use a particular pattern or number of tongue pumps with some variation. Usually one to four tongue pumps are used to generate a bolus. More than eight pumps before a swallow is considered abnormal. When infants take discrete amounts of liquid, the oral swallow is similar to that of adults, with a single well co-ordinated tongue action propelling the bolus backward.

In adults older than 60 years of age, there is a slight increase (approximately 0.4 second) in the time required to trigger the pharyngeal phase of swallow. There is also a slight prolongation of oral transit time of the bolus and duration of cricopharyngeal opening. Adults older than age 60 also tend to hold the bolus on the floor of the mouth before the swallow, requiring them to pick up the bolus and bring it onto the surface of the tongue as they initiate the swallow. This added action may be the cause of the prolonged oral transit time. There is no documented increase in frequency of aspiration or in the amount of residue in the mouth or pharynx with aging. There is, however, an increase in frequency of penetration in older individuals, that is, the entry of food or liquid into the airway entrance during the swallow with the complete clearance of material from the airway before the swallow is complete. In normal men older than the age of 80, there is early evidence that the extent of hyoid and laryngeal movement is reduced. This may relate to the frequency of penetration, because reduced elevation may allow the penetration to occur.

TYPES OF SWALLOWS:

There are many different swallow types, that is, systematic variations in the oropharyngeal physiology used to move food from the mouth to the esophagus in addition to the variations described previously. This range of swallow types results from changes in bolus volume, viscosity, voluntary

control, and age. During saliva swallowing, the pharyngeal phase may be elicited without any oral activity. If liquid is chugged down in large amounts, the airway is voluntarily closed, the cricopharyngeal valve is voluntarily opened, and the liquid is literally dropped from the mouth into the pharynx and esophagus in a steady flow. Understanding the normal systematic variations in swallow physiology is important in understanding the swallowing problems.

HIGHLIGHTS OF SWALLOWING EVENTS:

- The oropharyngeal swallow comprises a series of valves that are adjusted to direct the flow of food safely and efficiently from the oral cavity through the pharynx and into the esophagus at the same time that pressure is actively exerted against the bolus by the oral tongue, tongue base, and pharyngeal walls.
- Airway closure at the vocal folds and at the airway entrance, that is, the false vocal folds and arytenoid tilting to epiglottic base, is neurologically controlled.
- Movement of the epiglottis is the biomechanical result of hyolaryngeal vertical and anterior movement, bolus pressure, and tongue base retraction.
- Opening of the UES is controlled biomechanically and involves a complex series of muscular actions, beginning with relaxation of the

cricopharyngeal muscle, followed by anterior movement of the hyolaryngeal complex and pressure of the bolus.

- Airway closure and cricopharyngeal opening are time locked so that they always occur within 0.03 second of each other as the bolus is driven into the pharynx under pressure. This relationship remains the same at all bolus volumes.
- Pressure on the bolus tail is generated by the oral tongue, the tongue base, and the pharyngeal walls.
- Many aspects of oropharyngeal swallow physiology change systematically with increases in bolus volume, bolus viscosity, and the voluntary control exerted over selected physiologic components of the swallow.
- Normal swallow physiology also differs in infants as compared to young adults, older adults (older than age 60), and the oldest old (80+ years of age).
- Head posture affects the dimensions of the pharynx and the direction of food flow.

RESPIRATION DURING SWALLOWING IN NORMAL PERSONS:

Respiration and swallowing must be co-ordinated precisely so as to avoid airway invasion. The cessation of breathing during swallowing is known as swallowing apnoea. The onset and offset timings as well as duration of

swallowing apnoea are very critical in airway penetration during swallowing. Swallowing is preceded and followed by expiration. Respiratory pattern depends on number of factors such as age, gender, volume, and viscosity of the bolus. As the size of the bolus increases, the onset of swallowing apnoea occurs earlier. Respiratory pattern during swallowing in patients with neurogenic dysphagia is distinct from those in healthy individuals. Neurological impairments disturb the neurological co-ordination between respiration and swallowing and it may be sensory loss (afferent) or motor dysfunction (efferent). Respiratory centre receives impulses from the swallowing centres in the brain stem in this regard. Sensory impairment is suspected, if the gag reflexes are diminished in patients with dysphagia. Motor impairment is suspected if there is multiple swallowing for a small bolus volume and respiratory pattern is normal.

EVALUATION OF DYSPHAGIA

HISTORY:

1. Age: The common cause of dysphagia are foreignbody,congenital problem in children. Malignant growth,neurologicalproblems,refluxoesophagitis,hiatushernia,anemia, achalasia , globus syndrome are common in middle age. Malignant growth,stricture,pharyngealpouch,motility disorders are seen in old age.
2. History of onset and progression of the symptoms should be elicited.
3. Type of foodie,solid or liquids or both.
4. Associated symptoms such as odynophagia,change of voice,reflux of food,earpain,cough after swallowing,recurrent chest infections will give an idea to come to a provisional diagnosis.
5. Feeling of a lump while swallowing is one of the commonest complaint given by middle aged women.It will be more while swallowing saliva and not affected by the meal times.This is called Globus pharyngeus.

CLINICAL EXAMINATION:

Complete examination of oral cavity,oropharynx,hypopharynx larynx ,head and neck and cranial nerves must

be done and we have to look for any swelling or mass in neck which may be node ,tumour,thyroid mass. Laryngeal contour and laryngeal crepitus should be seen. The examination should also include general physical status,the other systems like nervous system,respiratory system and abdomen..

INVESTIGATIONS:

1.BARIUM SWALLOW:

If there is no obvious cause that could be found after a complete ENT examination, all those patients should be subjected for a barium swallow study.This is aimed at diagnosing diseases of oesophagus mainly and also hypopharynx in special view.

2.MODIFIED BARIUM SWALLOW TECHNIQUE:

It is a modification of barium swallow study for all phases of swallowing.This is specifically useful in neurological causes.

3.CHEST X RAYS:

To check for any signs of aspiration or pneumonitis

4.COMPUTED TOMOGRAPHY:

Computed tomography of neck, chest and abdomen

may be useful to detect some extraluminal causes

5. DIRECT PHARYNGOSCOPY AND OESOPHAGOSCOPY:

This will help to directly visualize certain intraluminal and mucosal lesion that may have been missed in barium swallow.

6. FLEXIBLE UPPER OESOPHAGO GASTRODUODENOSCOPY;

This is an alternative for the rigid endoscopic techniques.

7. FIBROPTIC ENDOSCOPIC EVALUATION OF SWALLOWING:

Using a fiberoptic nasendoscope, the larynx and pharynx are visualized at rest and during swallowing.

8. MANOMETRY:

The pressure within the oesophagus is measured at rest and during swallowing using a catheter with pressure transducers. This is more useful in diagnosing motility disorders.

9. 24HRS OESOPHAGEAL PH MONITORING:

This is the gold standard method for diagnosing gastro oesophageal reflux disorder.

DYSPHAGIA THERAPY:

1.Diet modification: One of the simplest ways to achieve an improved swallowing is to change the dietary composition .For most of the patients, a semisolid diet is the easiest form to swallow. It has less chance for aspiration.Another modification to add a sour taste to the bolus (50% lemon juice) .The idea of using this is to stimulate the oral phase and to reduce the delay in pharyngeal phase.

2.Postural techniques: The basic mechanism behind the postural techniques is the change in the direction of the flow of food and the dimensions of food pathway especially pharynx.

[a]Chin down:The vallecula becomes widened and epiglottis pushed posteriorly thus protecting the airway .Also the tongue base is pushed towards posterior pharyngeal wall .By extrinsic pressure the vocal cord closure will be assisted.

[b] Head back: This posture makes use of the gravity to clear oral cavity

[c]Head rotation: Here, head is rotated to the affected side.The extrinsic

pressure on thyroid cartilage increases adduction and so the damaged side gets eliminated from the food path.

[d] Head tilt: The head is tilted to the stronger side so that the food will get diverted down to that side.

3. Compensatory manoeuvres:

(a) Effortful swallow:

The tongue base motion towards posterior pharyngeal wall increased to squeeze out the residual food in vallecula.

(b) Supra glottic swallow:

The patient is asked to breath in and hold the breath both before and during the swallow. At the end of swallow, he should cough to clear any residual food around airway entrance .The aim of this technique is to minimize aspiration.

During this manoeuvre, the true vocal cords & arytenoids become well approximated and if the same is done effortfully the false cords also get approximated.

(C) super supra glottic swallow

This is a continuation of the supraglottic swallowing with an added action of bearing down. This will tilt the arytenoids forwards towards base of the epiglottis. Thus, the efficiency of laryngeal valving is further enhanced.

(d) Mendelsohn's manoeuvre:

The aim is to increase the degree of laryngeal elevation for a longer duration. The patient is asked to swallow repeatedly and he can feel the movement of laryngeal skeleton. Now he should hold the larynx in the highest position for a few seconds. The larynx should be held in the position by the action of extrinsic muscles of larynx.

(4) Surgical rehabilitation:

Various surgical techniques like epiglottoplasty, epiglottopexy, cricopharyngeal myotomy and laryngeal suspension are described to overcome the problems with swallowing.

REVIEW OF LITERATURE

REVIEW OF LITERATURE

Modified barium swallow(MBS) is the radiographic examination of choice for evaluating deglutition^[1]. Unlike a pharyngo-esophagogram, the MBS uses contrast agents of different consistencies and is performed with the direct input of a speech pathologist, so that a more complete assessment of swallowing physiology is obtained^[2].

Flexible endoscopic evaluation of swallowing (FEES) is an alternative means of assessing deglutition ^[3]. However, the MBS has several advantages over endoscopic techniques. In an MBS, there is no endoscope to interfere with swallowing function. The MBS evaluates the upper phases of swallowing in greater detail than does FEES. Portions of the mucosa that may be hidden from an endoscope are more easily evaluated radiographically.

There are three distinct phases of a swallow: the oral phase, the pharyngeal phase, and the esophageal phase. The oral phase is under voluntary control, whereas the pharyngeal and esophageal phases are involuntary reflexes. The understanding of swallowing function rests on the radiographic studies performed in the 1980s, and the terminology of swallowing reflects this historical inclination^[1].

The oral phase begins with formation of the oral bolus with the tongue, including mastication and lubrication of the bolus. The second event in the oral phase is transport of the bolus to the pharynx. This concludes the voluntary portion of the swallow, and the swallow reflex initiates.

The first event in the pharyngeal phase of swallowing is elevation of the soft palate, which, in combination with superior pharyngeal muscle constriction, occludes the nasopharynx to prevent nasopharyngeal reflux. Next, the hyoid bone elevates, raising the larynx along with it. This causes the epiglottis to retroflex and cover the vestibule of the larynx. At the same time, the vocal folds occlude, but this event is not evident radiographically. The next step in the pharyngeal phase is contraction of the pharyngeal constrictors in a peristaltic wave that forces the bolus through the pharynx, across the pyriform sinuses, and into the esophageal verge.

The esophageal phase of deglutition begins with relaxation of the cricopharyngeus muscle to allow passage of the food bolus. The peristaltic wave then progresses through the cervical and thoracic esophagus.

The first two phases of the swallow can be evaluated with MBS^[4]. Formation of the oral bolus is assessed by ensuring that contrast does not spill into the valleculae before the tongue formally transfers the bolus. Movement of the soft palate and hyoid bone can be observed even without the use of oral contrast, but their timing relative to delivery of the oral bolus is important. Epiglottic inversion is a rapid event. It is often necessary to replay the video fluorography to appreciate epiglottic inversion.

Small amounts of contrast may be seen penetrating into the laryngeal ventricle during the pharyngeal phase of the swallow. As long as this penetration clears immediately and completely, this is not considered abnormal. Contraction of the

pharynx should strip away almost all of the contrast in a normal individual. Small amounts of contrast may persist in the valleculae and pyriform sinuses.

The cricopharyngeus muscle should have completely relaxed by the time that the bolus reaches it, and it is usually not evident radiographically. However, it may occasionally be seen as a smooth posterior impression at the level of the C6 vertebra. This smooth impression is not, in itself, predictive of symptomatology

⁽⁵⁾ A study was conducted by Ekberg and Michel J. Feinberg on 56 patients of age between 72 to 93 yrs who were having no complaints of impaired swallowing using modified barium swallow. They observed that the swallowing function was normal in only 16%. In 20% of patients there was misdirected swallowing into subepiglottic segment of laryngeal vestibule. In 45% of patients a misdirected swallowing into the supraglottic segment of laryngeal vestibule was observed. In 16% of patients there was sensory motor inco-ordination of oral fluids. Pharyngeal retention was observed in 20%. Defective opening of upper esophageal sphincter was found in 23% of patients. Structural abnormalities like web were picked up only in 5% of patients. 36% of the asymptomatic elderly patients were having esophageal dysfunction. These observations lead them to conclude that non dysphagic patients of old age have altered swallowing functions. We can get two important points from this study, one is we can diagnose even a minor pathology of upper digestive tract by using MBS. Other thing is that it is difficult in elderly patients with dysphagia to differentiate whether it is due to aging or due to disease. This needs clinical

correlation.^[6] M.G .Rugin found that the sensitivity and specificity of the bedside examination in diagnosing the following disorders was 40% to 50% and 59 to 91% respectively. Based on these findings he concluded that MBS is essential in diagnosing and planning for rehabilitative treatment of dysphagia^[7]. Various studies have been conducted to compare the efficiency and usefulness of the different modalities of investigations to evaluate dysphagia. In 1997, Wu et al compared MBS and FEES and found that the sensitivity of FEES was superior to MBS. But an opposite observation was reported by Kaye in the same year^[8]. Aviv conducted a prospective study in 126 patients and his results didn't show any significant difference between FEES and MBS. From the above studies, MBS is not found to be superior to FEES. But it is complimentary and in the absence of facilities for FEES, it is not inferior to FEES^[9].

Swallowing studies by Videofluoroscopic method are the gold standard for evaluating the swallowing especially pharyngeal phase. ^[12,21,22]Videofluoroscopy can precisely assess the sequences of swallowing, especially the pharyngeal phase of it. The causative etiology for aspiration can often be identified with videofluoroscopy.

In the considerable number of elderly population ,it is common to have the finding like pharyngeal retention after swallowing during modified barium swallow examination^[29]. But, all the patients with this finding

are not having difficulty in swallowing. So, it may be considered as a normal finding in the elderly individuals unless otherwise they have any complaints of difficulty in swallowing. This abnormal finding can be attributable to the normal aging process. This is supported by one study in which the underlying mechanical events are^[30] studied in the older individuals without any swallowing difficulties. Therefore, the mild pharyngeal retention may be taken as a normal finding in the old patients who are nearing or above the age of 80 years and aspiration is not the potential risk in these patients. Videofluoroscopy is not useful in differentiating pharyngeal retention due to aging process from pharyngeal retention because of underlying pathology. So, it is hard to find the patients with underlying pathology when it is concerned with geriatric age group. When there is impaired transportation of bolus, the risk of aspiration after swallowing increases in proportion to the amount of residue in the pharynx that remains after swallowing^[31]. Aspiration during swallowing is the most serious complication, which puts the patient at high risk for developing a variety of pulmonary complications such as aspiration pneumonia^[10]. Aspiration pneumonitis is a major cause of morbidity and mortality, especially among the

older people, and an overall mortality ranging between 20% and 50% ^{19,20}.

Aspiration is often associated with other functional abnormalities of swallowing. The causes of aspiration include delayed initiation of swallowing, reduced elevation of hyoid, impaired epiglottic tilting, or defective laryngeal closure ^[32]. So, to differentiate between normal and abnormal airway protection during swallowing is important. The entry of contrast material into the airway occurs in 21% of healthy individuals (by Robbins et al with the penetration aspiration scale) ^[16] before completion of the swallow, the contrast material is almost always ejected from the airway which remains above the vocal cords ^[16].

We observed from the results that the amount of pharyngeal residue markedly more with increasing bolus size and repeated swallowing. We found that an increase in the amount of pharyngeal retention was seen during the examination after several swallows in more than 80% of patients and these findings show the importance of repeated swallowing and increasing bolus size for development of pharyngeal retention. We also learnt that the risk of aspiration increases with the amount of pharyngeal residue. The postswallowing aspiration risk is negligibly low for patients without pharyngeal retention and

very high for patients with moderate to severe pharyngeal residue. So, the risk of post swallowing aspiration is more in patients with severe pharyngeal retention than in patients without pharyngeal retention. Another factor is the consistency of the bolus which also decides the aspiration following swallowing. In patients who are likely to aspirate, the water-soluble, non ionic, low-osmolar contrast material is used^[23]. Bolus with thick volume increases the chances of pharyngeal retention and thereby the aspiration. Some patients will be comfortable with thicker consistency food while aspirating thin liquids^[24]. Hence, it is necessary to test the various consistencies of food on modified barium swallow techniques and decide on which food consistency the patient is comfortable with. This helps us to formulate a treatment regime for the particular patient. We take pharyngeal residue after swallowing as the predictive factor for aspiration. Pharyngeal retention results from defects in the mechanical events of swallowing like reduced propelling force of the tongue, decreased force of pharyngeal contraction which results in reduced shortening of the pharynx .^[25,26,30] Videomanometry is the investigation of choice for identifying the cause of pharyngeal retention due to defective mechanical

events of swallowing.^[30,25] Aspiration which is clinically apparent may not always be detected by modified fluoroscopic examination. Reduced duration of the study and inability to use the various consistencies of the material may be the reason behind this^[32]. It is frequently said that the patients are exposed to harmful radiation during the study. Any how, one study revealed that the radiation dose during videofluoroscopic study examinations is significantly lower when compared with other radiological procedures such as lumbar spine x ray. Even with all these limitations, videofluoroscopy is still considered to be the investigation of choice in evaluating dysphagia^[27,28].

Approximately about 20% of the population of the elderly individuals have dysphagia with an abnormal finding on modified barium swallow technique of pharyngeal mucosal coating or residue after swallowing is completed. According to one study, elderly individuals without any swallowing difficulties have abnormal swallowing function caused by ageing process but there is no impairment of swallowing function. Another group studied the mechanisms involved in pharyngeal residue of the swallowing in the non symptomatic elderly individuals and the conclusion of the study was

mild pharyngeal retention must be considered as normal in very old patients of mean age of 80yrs. There is no risk of aspiration in these patients. However, the risk of aspiration is more when the pharyngeal retention increases after swallowing. Study by using mechanomyography(MMG)^[39] and electromyography (EMG)^[38] stated that no significant effect of ageing on dysphagia found. Dysphagia can lead to aspiration and there by can result in grave complications, it is necessary to identify and treat this patients as early as possible. The role of compensatory strategies like change of posture and positioning, consistency of the food, size of the bolus or swallowing manoeuvres such as Mendelsohn's manoeuvre and supraglottic swallowing. According to another study, compensatory strategies are able to eliminate aspiration risks in 75 to 80% of all patients with risk of aspiration.

Evaluation of Therapeutic Manoeuvres

Videofluoroscopy is not only a useful method for the diagnostic evaluation of oral-pharyngeal swallowing disorders but can be used to search for a "safe swallow" without aspiration accompanied by satisfactory pharyngeal bolus transport ^[32]. Therapeutic manoeuvres include

- (1) manipulations of bolus variables such as volume and consistency,
- (2) variation of head position, and
- (3) use of specific therapeutic maneuveressuch as supra glottic swallow ^[24].

Some patients exhibit aspiration with a small barium bolus(e.g., 2 ml), while others require a larger bolus (e.g., 10 ml). For this reason, at least several volumes should be used during the diagnostic examination. Examination with severalbolus consistencies is critical. In some patients, aspiration occurs most commonly with thin barium (e.g., 30% wt/vol), but may not occur at all with thick barium on paste material (e.g., barium paste). Head positioncan be very important in assisting swallowing.Chin tuck otherwise called as head flexion is a postural technique followed in patients with dysphagia in which tilting of head below onto the sternum without any forward extension of the head.This postural technique significantly increases the pressure of pharyngeal contraction and its duration.Distance between larynx and hyoid bone,hyoid to mandible,the angle between the mandible and the posterior pharyngeal wall,the angle between anterior wall of trachea and epiglottis ,distance between the epiglottis and posterior pharyngeal wall and the width of airway entrance are all

decreased. These changes were supported by studies by Bullock. Evidences indicate that the changes of anatomical relationships between pharyngeal structures involved in swallowing during chin tuck. Head flexion often prevents aspiration by reducing premature spill from the mouth and also by tucking the larynx anteriorly beneath the epiglottis. Head rotation is achieved by asking the patient to simply rotate the head to left or right during swallowing. In patients with disorders of swallowing head rotated to the weak side. Rotation of the head to the left or right increases the pharyngeal contraction pressure at the level of vallecula and pyriform sinus on the side of rotation when compared with neutral head position. Tilting the head backward can enhance oral transit. Turning the head directly to the contralateral side may compensate for unilateral pharyngeal weakness. Bending the head laterally directs swallowed liquid to the ipsilateral side and may also be useful therapeutically to enhance pharyngeal bolus transport and prevent aspiration. Two special manoeuvres that may be evaluated during videofluoroscopy include the supraglottic swallow and the Mendelsohn's manoeuvre. The supraglottic swallow is done for patients with aspiration before or during a pharyngeal swallow.

RESULTS AND ANALYSIS

RESULTS AND ANALYSIS:

We conducted modified barium swallow examination for 200 patients with complaints of difficulty in swallowing of which 109 were males(54.5%) and 91 were females(45.4%).

SEX	NO. OF PATIENTS
MALE	109
FEMALE	91

These patients are then divided into age group between 20 to 40,41 to 60 and 61 to 80.

AGE	NO. OF PATIENTS	
	MALES	FEMALES
20 TO 40 YRS	31	42
41 TO 60 YRS	48	43
61 TO 80 YRS	30	6

AGE DISTRIBUTION

About 92 patients were found to have abnormal findings during the study.

Other 108 patients had normal findings on videofluoroscopy.

NORMAL VS ABNORMAL

NORMAL	108
ABNORMAL	92

Abnormal pharyngeal mucosal coating was found in 28 patients, and 16 of them had past history of stroke for which neurological causes may be attributed. Another 12 patients however have no significant illnesses.

DISEASE DISTRIBUTION:

Out of the 92 patients with the abnormal videofluoroscopic findings, 28 patients have pharyngeal retention alone with no other structural abnormalities. 10 patients were found to have growth in the hypopharynx. 8 patients were found to have growth in the larynx. 4 patients were found to have oesophageal growth. Postcricoid web was found in 30 patients. 2 patients had achalasia cardia. 4 patients had unilateral vocal cord palsy.

DISEASE	No. OF PATIENTS
PHARYNGEAL RETENTION	28
GROWTH HYPOPHARYNX	12
GROWTH LARYNX	8
GROWTH OROPHAYNX	4
GROWTH OESOPHAGUS	4
POSTCRICOID WEB	30
ACHALASIA	2
UNILATERAL VOCAL CORD PALSY	4

This pharyngeal mucosal coating after swallowing is graded as mild, moderate and severe according to the height of residue in the pyriform sinuses or valleculae seen in the videofluoroscopic images.

SEX PREDILECTION FOR DISEASE:

DISEASE	MALES	FEMALES
PHARYNGEAL RETENTION	23	5
GROWTH HYPOPHARYNX	9	3
GROWTH LARYNX	8	0
GROWTH OROPHARYNX	3	1
GROWTH OESOPHAGUS	3	1

POSTCRICOID WEB	0	30
ACHALASIA	1	1
UNILATERAL VOCAL CORD PALSY	3	1

DISEASE SEX DISTRIBUTION

DISEASE DISTRIBUTION IN 20 TO 40 YRS OF AGE:

DISEASE	MALES	FEMALES
PHARYNGEAL RETENTION	0	0
GROWTH HYPOPHARYNX	0	0
GROWTH LARYNX	0	0
GROWTH OROPHARYNX	0	0
POST CRICOID WEB	0	22
ACHALASIA	0	0
UNILATERAL VOCAL CORD PARALYSIS	0	0

DISEASE DISTRIBUTION IN AGE BETWEEN 40 TO 60 YRS:

DISEASE	MALE	FEMALE
PHARYNGEAL RETENTION	11	1
GROWTH HYPOPHARYNX	4	2
GROWTH LARYNX	4	0
GROWTH OROPHARYNX	1	1
GROWTH OESOPHAGUS	1	0

POSTCRICOID WEB	0	8
ACHALEZIA	1	1
UNILATERAL VOCAL CORD PALSY	1	1

Postericoid web was found in 30 female patients of which 22 patients fall in the age group between 20-40 yrs.8 were in between 40-60 yrs of age.

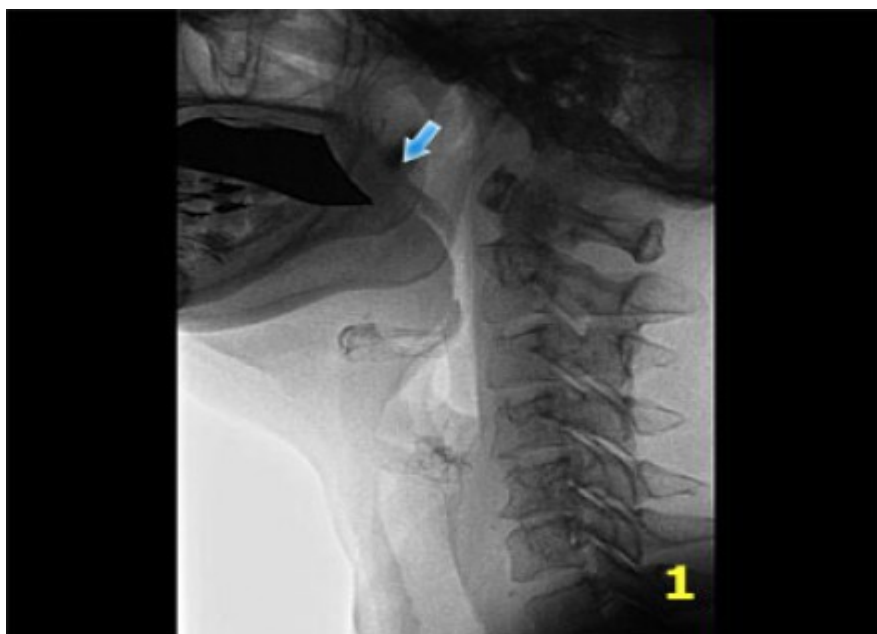
DISEASE DISTRIBUTION IN AGE GROUP 60 TO 80 YRS:

DISEASE	MALE	FEMALE
PHARYNGEAL RETENTION	12	4
GROWTH HYPOPHARYNX	3	1
GROWTH LARYNX	4	0
GROWTH OROPHAYNX	2	0
GROWTH OESOPHAGUS	2	1
POSTCRICOID WEB	0	0
ACHALASIA	0	0
UNILATERAL VOCAL CORD	2	0

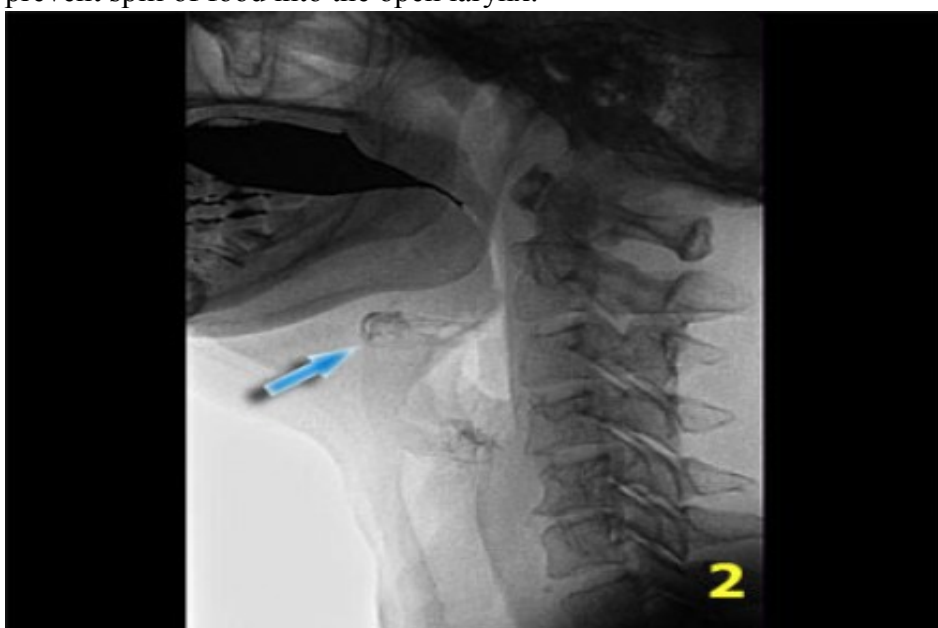AGE WISE DISEASE DISTRIBUTION

Postericoid web was found in 30 females with anaemia and no males were found to have this finding.108 patients who are radiologically and clinically normal were treated appropriately. There was a good response in the patients who were treated with proton pump inhibitors and domperidone.They were diagnosed as GERD and managed conservatively.Some patients showed improvement with placebo treatment itself.In this study, I concentrate mainly on

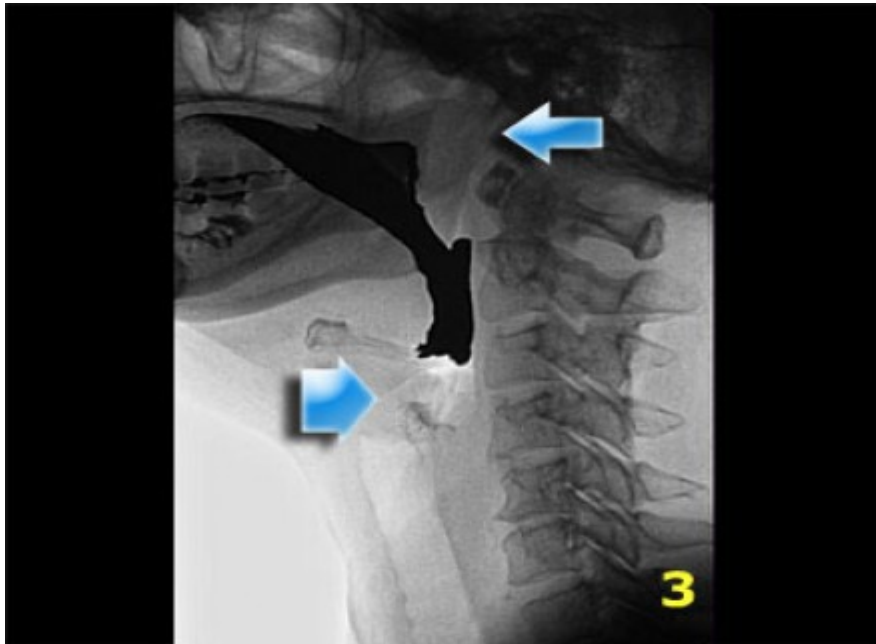the patients who were likely to aspirate while swallowing. We identified 28 patients with pharyngeal retention and 16 of the patients were given training on swallowing manouveres as they had severe pharyngeal retention. We studied the effectiveness of these manouveres again by the videofluoroscopy and we found that these are very useful in preventing aspiration.



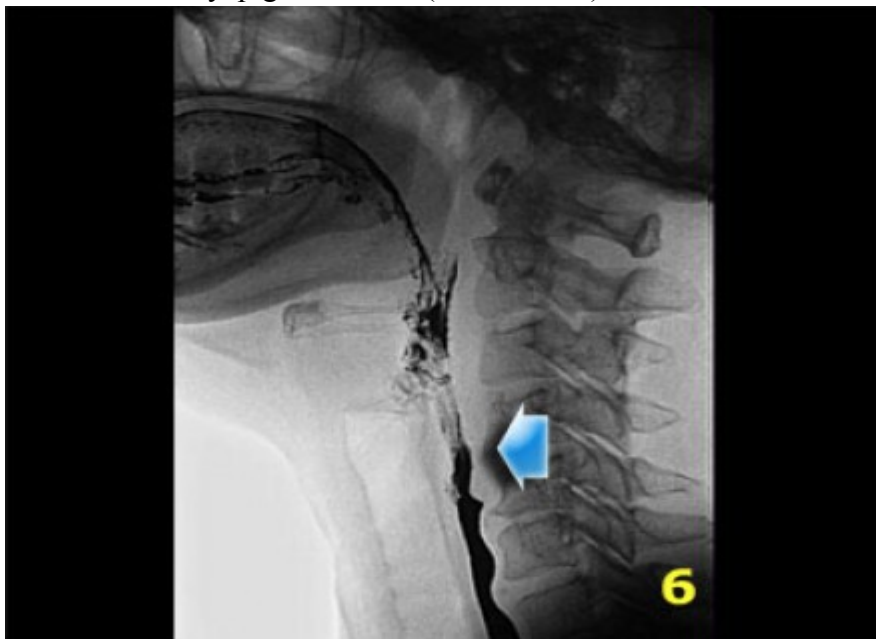The base of the tongue and the soft palate close the oral cavity posteriorly (arrow) to prevent spill of food into the open larynx.



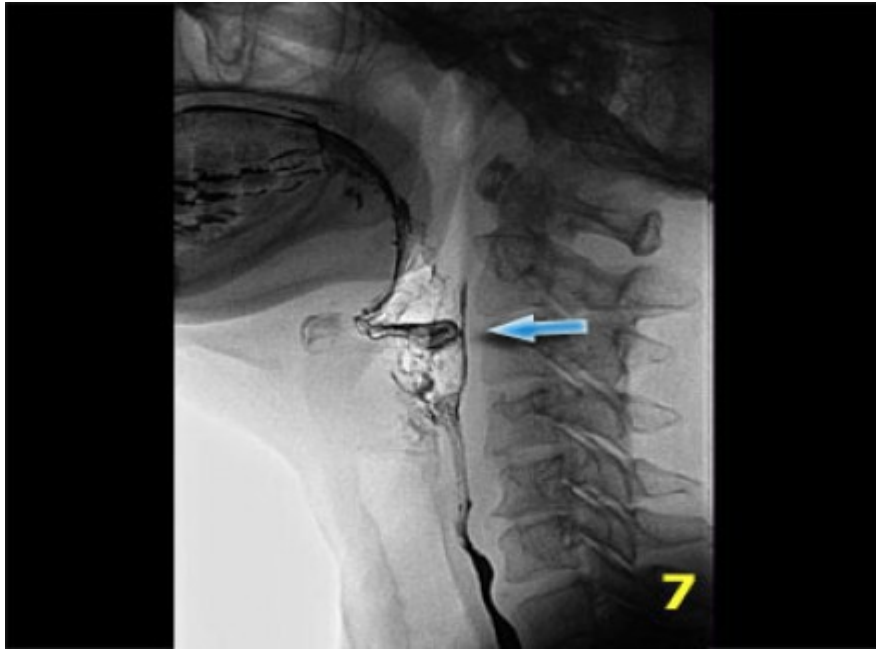
Hyoid bone and base of the tongue move in a cranial direction and lift the larynx (arrow).



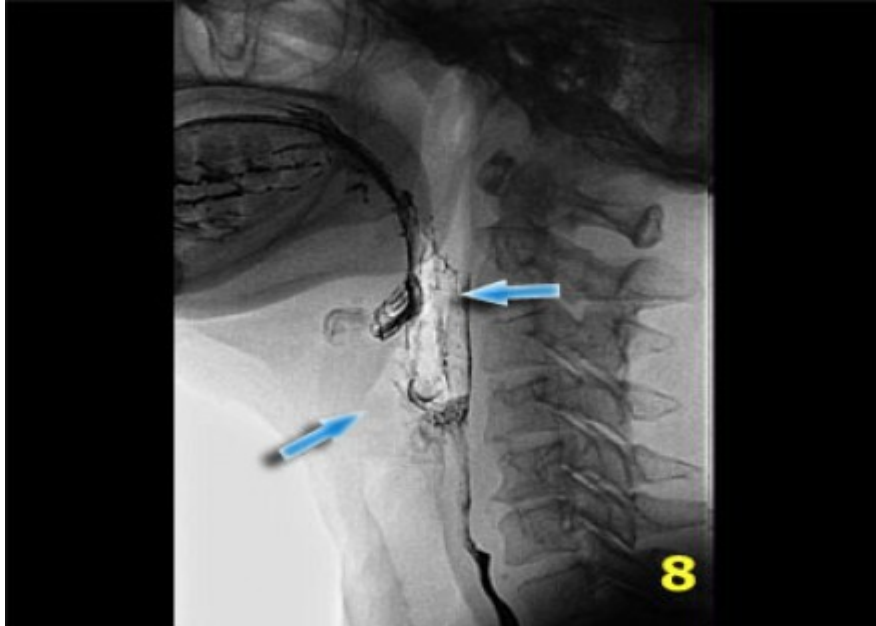
Soft palate elevates to prevent spill into the nasopharynx (thin arrow) and the larynx closes by contraction of the aryepiglottic folds (broad arrow)



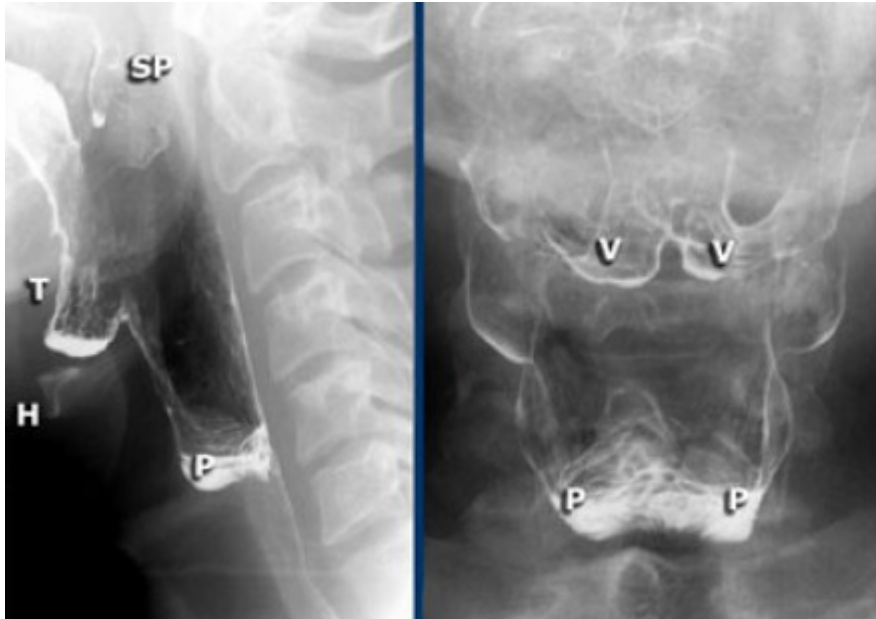
Contraction of the lower pharyngeal constrictor and relaxation of the cricopharyngeal muscle (arrow)



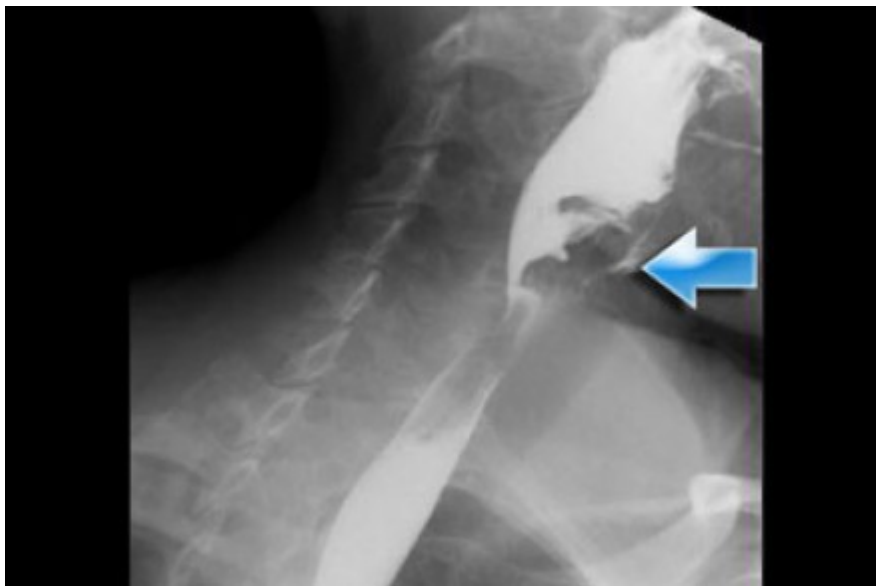Epiglottis elevates to regain its resting position and the larynx opens.



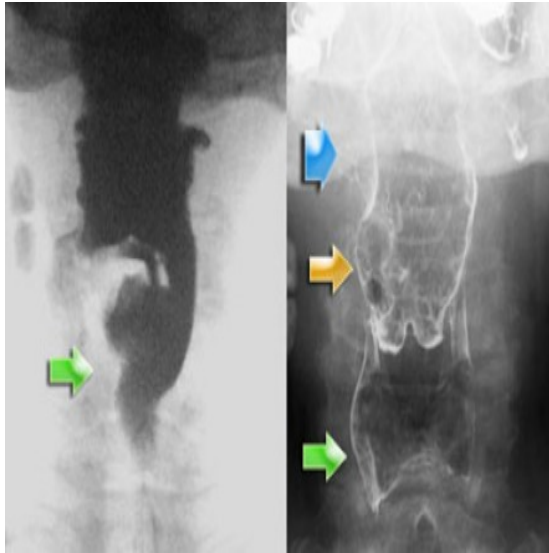
Epiglottis in resting position and larynx is open (arrow).



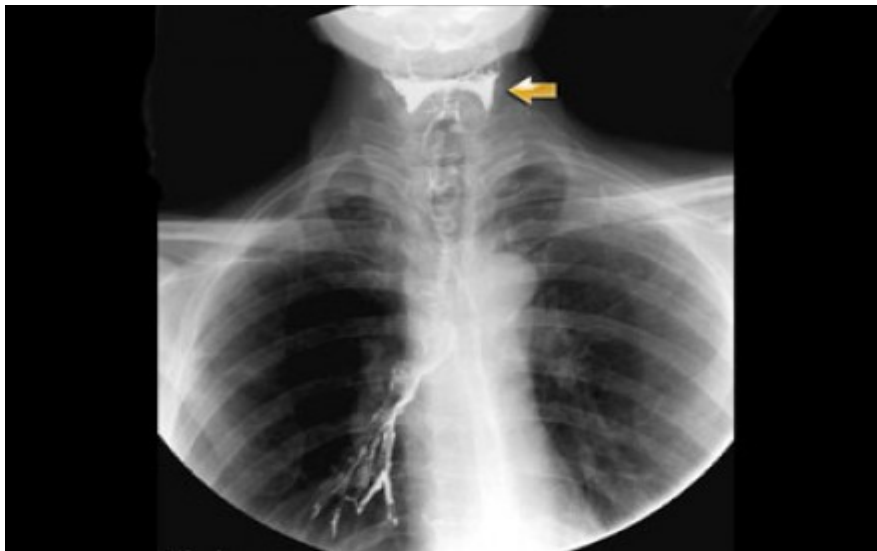
LEFT: Lateral view. Hyoid (H) and tongue base (T) move anteriorly. Left and right pyriform sinuses are projected on top of each other. Tip of soft palate (SP) is seen. RIGHT: Valleculae (V) and pyriform sinuses (P).



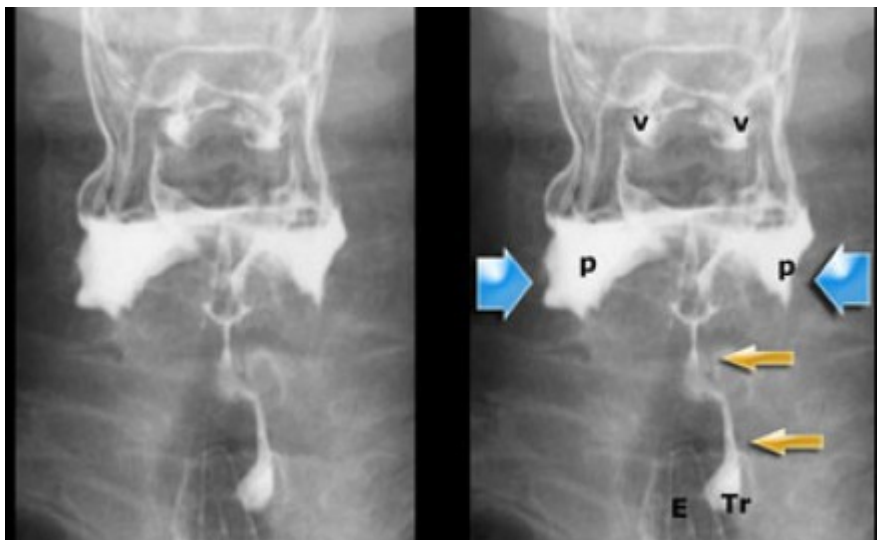
Asymmetric swallowing due to head turn. The head is turned to the left and contrast is only seen in the Rt. pyriform sinus



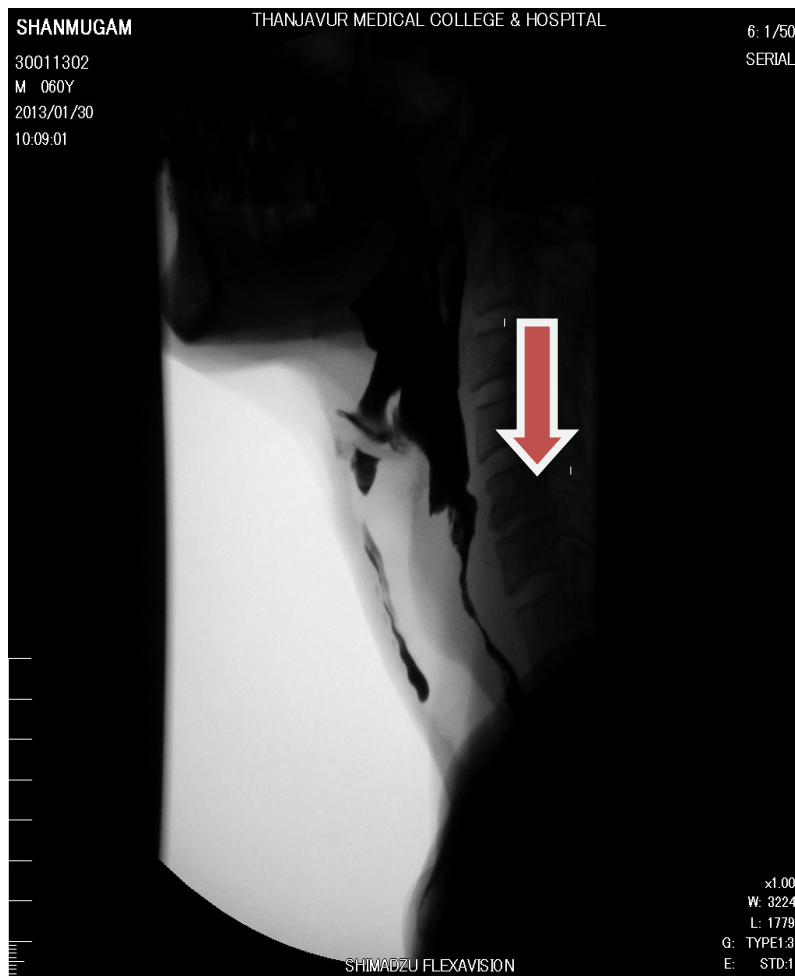left asymmetry is seen on the fluorographic study



grade 3 pharyngeal retention



*Stasis of contrast at the level of the pyriform sinuses (blue arrows)
with subsequent aspiration (yellow arrows)*

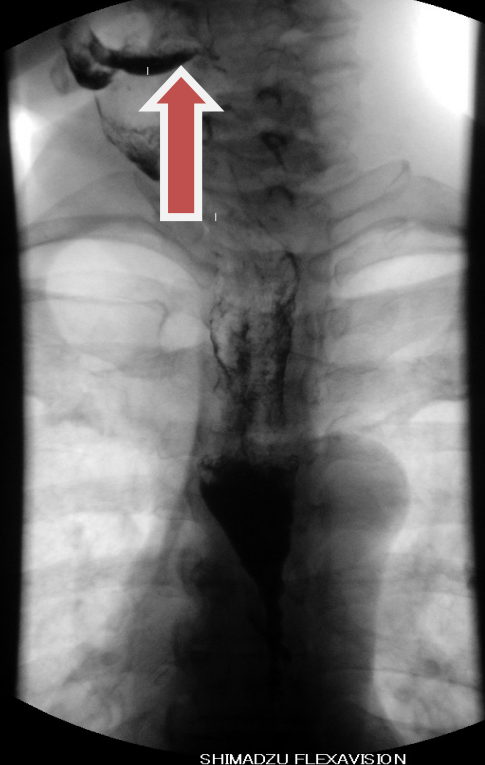


Grade 3 Pharyngeal retention with aspiration into trachea

KRISHNAMOORTHY
02071303
M 065Y
2013/07/02
10:58:01

THANJAVUR MEDICAL COLLEGE & HOSPITAL

1: 1/1
SPOT



SHIMADZU FLEXAVISION

x1.00
W: 3232
L: 1784
G: TYPE1.3
E: STD:1

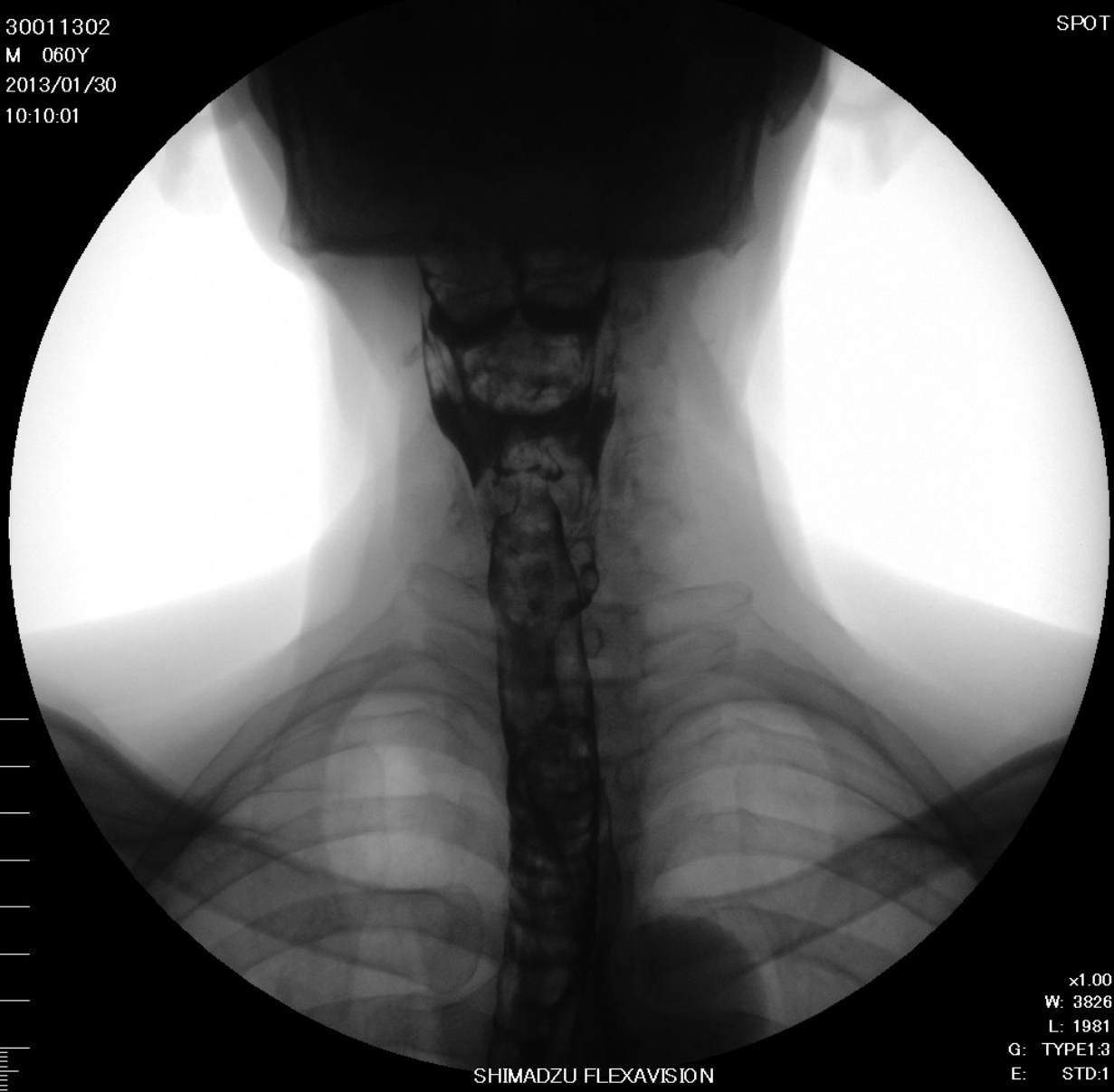mild pharyngeal retention in a case of Lt.sided hemiplegia

SHANMUGAM

THANJAVUR MEDICAL COLLEGE & HOSPITAL

8: 1/1
SPOT

30011302
M 060Y
2013/01/30
10:10:01



SHIMADZU FLEXAVISION

x1.00
W: 3826
L: 1981
G: TYPE1.3
E: STD:1

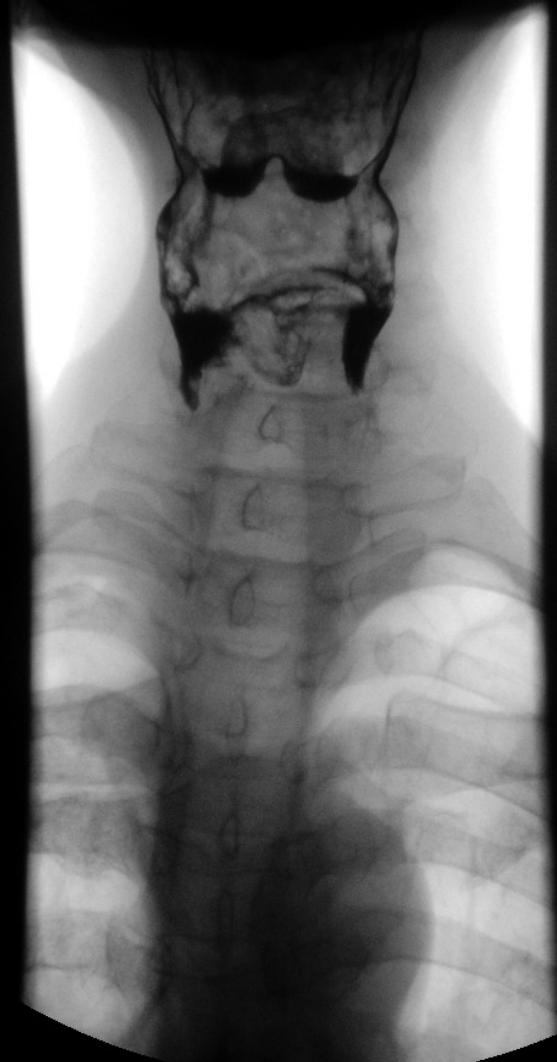Grade 2 pharyngeal retention

KALIYAMOORTHY

THANJAVUR MEDICAL COLLEGE & HOSPITAL

1: 1/50
SERIAL

31051303
M 047Y
2013/05/31
11:56:08



SHIMADZU FLEXAVISION

x1.00
W: 3194
L: 1769
G: TYPE1.3
E: STD:1

Residue in both valleculae and pyriform sinuses

SELVI

THANJAVUR MEDICAL COLLEGE & HOSPITAL

1002: 1/1

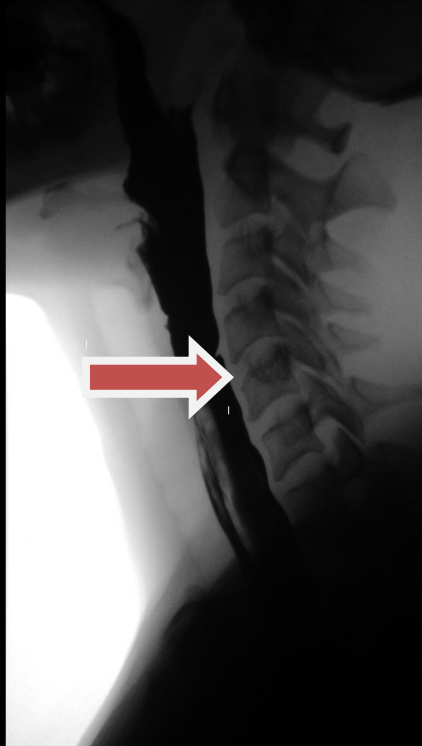
22021304

M 045Y

2013/02/22

11:19:02

SERIAL



x1.00

W: 3826

L: 1981

G: TYPE1.3

E: STD:1

SHIMADZU FLEXAVISION

oesophageal web

MARIYAMMAL

THANJAVUR MEDICAL COLLEGE & HOSPITAL

4: 1/19

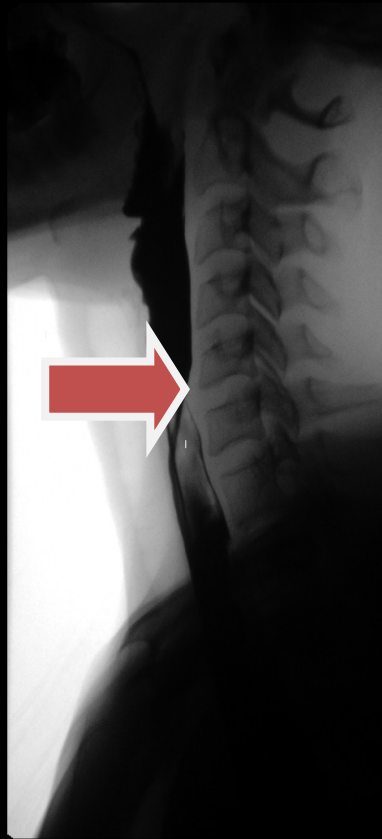
26061301

SERIAL

F 047Y

2013/06/26

10:39:30



x1.00

W: 3826

L: 1981

G: TYPE1.3

E: STD:1

SHIMADZU FLEXAVISION

oesophageal web

DISCUSSION

DISCUSSION:

In our study, we learnt the various phases of swallowing by modified barium swallow. We found 28 patients with pharyngeal retention alone. Out of these 28 patients, 16 had past history of stroke and had grade 3 pharyngeal retention. Another 12 patients had grade 1 & 2 pharyngeal retention and they fall between 61-80 yrs of age. We had given training for swallowing manoeuvres for the patients with severe pharyngeal retention so as to prevent the aspiration. Another finding we got from our study was postcricoid web which was typically found in females. Out of the 30 patients, 22 were in the age group between 20-40 and 8 were in the 41-80 yrs of age. These patients were managed with deworming, iron supplementation, and rigid oesophagoscopy. They showed significant improvement following this line of management.

Laryngeal penetration is differentiated from tracheal aspiration by the involvement of the true vocal cords. Contrast that contacts the true cords, if it is not immediately removed by a cough reflex, is considered aspiration.

When evaluating laryngeal penetration and tracheal aspiration, it is critical to assess the timing of the abnormality relative to the swallow reflex^[17]. For example, poor control of the oral bolus will lead to early vallecular spill. If the vallecula fills, contrast will spill into the laryngeal vestibule and eventually contact the vocal folds. Because this type of aspiration occurs during the oral

phase, before the initiation of the swallow reflex, it is termed as pre prandial aspiration.

If the epiglottis fails to invert, or the larynx is otherwise unprotected, the contrast bolus may enter the laryngeal vestibule during the pharyngeal phase of the swallow. This type of aspiration is termed prandial aspiration.

If there is a failure of pharyngeal contractility, or the cricopharyngeus muscle fails to relax, contrast may be retained in the pharynx after the completion of the entire swallow. This contrast may then drip into the larynx, causing postprandial aspiration. A diagnosis of postprandial aspiration is sometimes applied presumptively, when contrast is seen in the trachea late in the examination but the patient was not seen to aspirate during the videotaped portions of the swallow.

Whenever laryngeal penetration or tracheal aspiration is identified, comment should be made about the presence or absence of a cough reflex. Patients with normal sensation will cough to remove the aspirated material. Silent aspiration (aspiration without a cough reflex) is a particularly worrisome event, but if it is identified, it can be addressed with specific swallowing manoeuvres. Silent aspiration is a radiographic diagnosis.

During the MBS, the patient attempt protective manoeuvres to determine whether aspiration can be minimized or prevented. Such manoeuvres include chin tuck and neck rotation. In general, radiographic images obtained with the patient using protective manoeuvres will not be

diagnostic because of overlapping structures, but the degree of aspiration can usually be assessed.

Because barium suspension may concrete in the lungs and form a nidus for infection, patients with copious aspiration should have their studies terminated as soon as the aspiration is identified. It is thus important for the first swallow to be properly filmed in case no further swallows are performed.

COMMON DISEASES:

Dysphagia is the most frequent symptom to merit fluoroscopic evaluation of swallowing. A pharyngo-esophagogram is the examination of choice in this setting. The most common causes of dysphagia are gastroesophageal reflux disease (GERD) and its complications, so a pharyngo-esophagogram for dysphagia must include an evaluation of lower esophageal sphincter competency. Endoscopy and pH monitoring are more reliable for this diagnosis^[33]. Fluoroscopy plays an important role in patients who present with globus. About half of these patients can be shown to have GERD on endoscopy or 24-hour pH monitoring. Although an esophagogram will usually be normal, occasionally a mucosal lesion or extrinsic mass will be identified as the source of the globus sensation. Such lesions may be overlooked if only endoscopy or pH monitoring are used to evaluate globus.

GERD traditionally causes inflammation in the thoracic esophagus, but in severe cases, the pharynx may become involved. Laryngopharyngeal reflux, in

which inflammatory changes extend into the laryngeal tissues, is better evaluated with endoscopy than with fluoroscopy. A frequent finding on swallowing studies in older individuals is a wavy configuration to the posterior pharynx caused by anterior osteophytes from the cervical spine. Although this finding is not usually associated with symptomatology, osteophytes may interfere with the inversion of the epiglottis, resulting in prandial aspiration.

Large osteophytes may displace the esophagus and simulate an extrinsic mass. Cricopharyngeal achalasia is a failure of the cricopharyngeus muscle to relax in response to a food bolus. It appears as a smooth impression on the posterior pharynx at the level of the C6 vertebral body. Unlike most retropharyngeal masses, the cricopharyngeus muscle is rarely greater than 1 cm in superoinferior dimension.

There are many causes of cricopharyngeal achalasia, including amyotrophic lateral sclerosis, poliomyelitis, pseudobulbar palsy, nasopharyngeal carcinoma, thyroid myopathy, surgical vagotomy, dermatomyositis, and hiatus hernia. However, most patients do not have an identifiable cause^[34]. Other cricopharyngeal dysfunctions can also be diagnosed radiographically. Cricopharyngeal achalasia is complete incompetence of the cricopharyngeus muscle and is seen in myotonic dystrophy^[35]. Familial dysautonomia manifests as a delayed opening of the cricopharyngeus muscle .

There are several types of diverticular outpouchings that arise in the pharynx. Best known are Zenker's diverticula, which arise from the posterior wall of the pharynx just superior to the cricopharyngeus muscle. These lesions are presumed to represent pulsion diverticula resulting from cricopharyngeal achalasia. Radiographically, a Zenker's diverticulum appears as an outpouching from the posterior surface of the pharynx. The diverticulum may retain contrast between swallows, or it may completely discharge its contents. The size of the diverticulum and the caliber of its neck can be assessed on fluoroscopy. Large Zenker diverticula may compress the hypopharynx. Pharyngeal pouches are the result of chronically increased pharyngeal pressure, as in trumpet players and glass blowers. These pouches arise on the lateral surface of the oropharynx and are thus best viewed in the frontal projection^[36]. Pharyngeal pouches are generally asymptomatic, but large pouches may cause dysphagia.

Pharyngeal hypocontractility is a frequent finding in elderly patients. It is often idiopathic, but brainstem diseases (e.g., stroke, demyelination), cranial nerve dysfunction (particularly IX and X), and diseases of the neuromuscular junctions or pharyngeal musculature have been implicated.

Diseases that affect the pharyngeal constrictors include myasthenia gravis, dermatomyositis, systemic lupus erythematosus, myotonic dystrophy, systemic sclerosis, and oculopharyngeal myopathy. These diseases are usually not

distinguishable radiographically, except myasthenia gravis, which is characterized by worsening findings over consecutive swallows.

Unilateral pharyngeal hypocontractility can be a confusing radiographic finding. Asymmetry in the pyriform sinus, with preferential flow into the affected sinus, may be confused with obstruction of the contralateral pyriform sinus. The distinction can usually be made with careful analysis of multiple swallows in both frontal and lateral projections (2).

Although cross-sectional modalities (CT and magnetic resonance imaging) are the mainstays of pretreatment cancer imaging, fluoroscopy is useful in a few specific clinical settings. When there is uncertainty about invasion of the prevertebral fascia from a hypopharyngeal tumor, an esophagogram can document decreased laryngeal motion to indicate prevertebral invasion^[37]. Pharyngo-esophagography can also document the mucosal extent of tumors across the postcricoid hypopharynx.

Fluoroscopy plays a specific role in the evaluation of the treated neck. The Radiologist must be familiar with the expected appearance of the pharynx after surgery. For example, after laryngectomy, it is normal for a ridge of soft tissue to separate the anterior pouch from the remainder of the pharynx. This tissue is called a pseudo epiglottis because of its radiographic appearance. Jejunal interposition grafts can create an unusual appearance because the plicae circularis of the jejunum are identified in the neck. The interposed segment may even demonstrate peristalsis on video fluorography.

Benign strictures are a common complication of pharyngeal surgery. These strictures tend to occur at anastomotic sites and are readily evaluated with fluoroscopy. The strictures that result from radiotherapy tend to affect a longer segment of the alimentary tract. Strictures generally become symptomatic when they are less than 13 mm in cross-sectional diameter. If the precise caliber of the stricture is in question, we must administer a 13-mm barium tablet to see whether this critical threshold has been breached.

Based on the findings we got from our study, patients with dysphagia were divided into

1. patients with neurogenic dysphagia
2. patients with dysphagia due to head and neck cancer
3. patients with dysphagia due to aging.

We take the pharyngeal residue after swallowing as the risk factor for aspiration in these patients. We found this factor from 12 patients and it is observed from our study that the residue in the pharynx is common among elderly individuals and in patients with history of neurological disorders. The risk of aspiration is more and is directly proportionate to the amount of pharyngeal retention in these patients. To recommend a suitable dietary regime, these patients are tested with various consistencies of barium. Because, we learnt from several studies that aspiration is more with thickened fluids which

may also aggravate swallowing difficulties. Post swallowing aspiration is frequently seen in patients with decreased contractions or inadequate opening of lower oesophageal sphincter. So, these patients are recommended thin liquids only and the patients who cough on thin liquids may be advised thick fluids. One study disproved the role of viscosity in pharyngeal retention. They found no correlation between the viscosity and retention.

Aspiration is the most serious life threatening complication as it may lead to aspiration pneumonia. We learnt that prior full bed side examination of the patients to predict aspiration must be carried out before going for videofluoroscopic studies. It includes clinical observation of swallowing, assessment of intra oral sensibility and functional examination of the musculature involved in swallowing. One report stated that thorough clinical examination before study can reach a sensitivity for aspiration upto 80%, specificity to near 70%. Aspiration (food getting into the airway and lungs) occurs because of incomplete laryngeal closure when the bolus passes through the larynx which leads to the entry of food or fluid into the larynx before it is sufficiently closed. This type of aspiration is known as

predeglutition aspiration. It is frequently found in patients with dysphagia after stroke and patients with other neurological disorders. Thickened fluids are the option of dietary modification for these patients because more time is allowed to establish complete laryngeal closure when the speed of bolus is decreased. A large trial by Logemann et al stated that thickened fluids will cause less aspiration in patients with neurological disorders like Parkinson's disease, and dementia.

Laryngeal penetration is defined as the presence of barium contrast in the laryngeal vestibule that does not pass below the level of true vocal cords into the airway. Silent aspiration means the aspiration in the absence of reflexive patient response. An eight point penetration and aspiration scale developed by Rosenbek, Robbins, & Roecker is commonly used for diagnosing aspiration or penetration. They found that 20 % of normal individuals have contrast in the laryngeal vestibule during the swallow and on the penetration aspiration scale they received a score of 2. This implies that the further entry of the material was restricted before the completion of the swallow.

TIMING OF THE PHARYNGEAL SWALLOW ONSET:

It is important in determining the interaction of bolus flow in relation to airway protection. During the pharyngeal stage of swallowing, there is a period of apnoea in which the respiration stops providing further protection of airway. Onset of hyolaryngeal elevation is the first radiographic indication for the onset of laryngeal swallow. It occurs about 500 milliseconds after the oral bolus starts to move into the pharynx. This is followed by the onset of laryngeal closure which occurs very soon after hyoid bone began to elevate. Delayed onset of pharyngeal swallow response is usually the result of decreased pharyngeal or laryngeal sensation. It is caused by number of conditions including stroke, Parkinson's disease, amyotrophic lateral sclerosis, prior radiotherapy, post endotracheal intubation or tracheostomy. If there is more delay in the pharyngeal swallow initiation response after the bolus is in the pharynx, the risk of aspiration into the airway will be more. Volume, texture and viscosity of the bolus alter the timing of pharyngeal swallow onset with the

beginning of vocal cord adduction. Research in normal adults has revealed that when large liquid boluses are placed in the oral cavity, vocal cord adduction with the onset of hyolaryngeal elevation begins. Average normal pharyngeal delay time for oral liquid bolus was 0.6 seconds in adults of age between 18 to 80 yrs. Pharyngeal delays in relation to bolus flow is calculated by various anatomical landmarks by various researches. The onset of pharyngeal swallow is defined as the time when head of the bolus passes the ramus of mandible and the tongue base. Due to the reduced sensory awareness of the bolus, pharyngeal delay time is increased in the old age. Before the closure of the airway closure and the elevation of hyolarynx, the vallecula is occupied by the bolus.

ORAL AND PHARYNGEAL TRANSIT:

The consistency of food or liquid being swallowed, the age and sex of the patient as well as the variation in the propulsive forces decide this duration. Swallowing efficiency is generally calculated by the duration of bolus transportation through the oral cavity and pharynx, the number of swallows needed to clean the bolus whether it is solid or liquid. It gives a rough guide for efficiency of swallow. Normally, a 5 to 30ml of bolus can be cleaned in a single

swallow and may be done by a second cleaning swallow. Several swallows are required to clean boluses with hard textures. Rademaker et al developed a measure that depicts the interaction between the speed of flow of bolus and efficiency with which the bolus is swallowed from the oropharynx taking aspiration into account. This precisely assesses the oropharyngeal swallow efficiency.

THERAPEUTIC STRATEGY:

Major advantage of videofluoroscopic study is that the effectiveness of the therapeutic strategies which could be either rehabilitative or compensatory can be assessed. The aim of compensatory strategies is to correct the disorder of swallowing by altering the flow of bolus. Head position changes can alter the axis of oral, pharyngeal and laryngeal subsites and it can reduce the angle of opening of laryngeal inlet. Hyolaryngeal excursion and propulsive forces of the muscles of the pharynx can be increased by chin down (chin tuck) position. Anyhow, the risk of aspiration is increased when the pyriform sinuses are filled with barium before the onset of pharyngeal swallow. Because, the emptying of pyriform sinuses and elevation of larynx

coincides. Testing with various consistencies of boluses permits one to formulate a treatment plan. The effectiveness of these trials were tested by modified barium technique in 12 patients of our study. During the study, we trained the patients on how to accurately perform the manoeuvres and postural techniques. We found as disadvantages of this manoeuvres are it requires full co operation of the patient who must have the mental and cognitive ability to understand the importance and method of procedures.

Summary:

In a normal modified barium swallow technique, the images are viewed in the lateral aspect first. There should be co ordinated tongue movements for manipulation of liquid and semisolid boluses. The bolus

should be in contact with dorsum of the tongue. The base of the tongue and the soft palate must be ready for action before the onset of pharyngeal swallow. When the tongue moves upwards and backwards, the soft palate contacts the posterior pharyngeal wall and shuts off the nasopharynx. Once the bolus reaches the tongue base, it will contact the posterior pharyngeal wall and the pharyngeal phase of swallowing is initiated. Downward and forward movement of the hyolaryngeal complex followed by downward tilting of epiglottis and adduction of arytenoids will close the laryngeal vestibule. When the bolus reaches the hypopharynx, cricopharynx will open and there should be no indentation in the posterior part of it. It will be closed once the peristalsis in the cervical oesophagus started. There should be no pharyngeal residue after this event. Solid residue if present, should be cleaned on subsequent swallowing of saliva. Residue in the pharynx is usually seen when there is limited motion of hyoid with limited forward and upward movement of pharynx with swallowing. As a result, the suprahyoid portion of the epiglottis does not move forward against the base of tongue and any residual material in the vallecula cannot be squeezed out. This can occur in neurological disorders like Parkinson's disease

or after surgery or radiotherapy . Residue in pyriform sinus can also occur when there is decreased pharyngeal motion as seen in vagal neuropathies. The decreased constrictions which limits the pharyngeal pressure which normally helps to push the bolus past the cricopharyngeal spasm can also lead to pyriform residue. These type of residue can lead to secondary aspiration or penetration. The bolus should occupy the lateral pharyngeal walls symmetrically which can be seen in the anteroposterior view of modified barium swallow images. The bolus then passes into the cervical oesophagus. Epiglottic deflection may be viewed as an arc shaped as its dense folding displaces the barium . The fully adducted vocal folds may be seen when the barium eventually enters into the cervical oesophagus. In our study, retention of the barium in the pharynx was a single factor that was taken into account for predicting aspiration and planning for compensatory therapeutic strategies.

CONCLUSION:

From my study ,I came to the conclusion of understanding the normal and abnormal biomechanical events of the swallowing that drive the bolus from the oral cavity to the pharynx and into the oesophagus is necessary for the accurate

diagnosis of oropharyngeal swallowing disorders. Modified Barium Swallow plays a critical role in the evaluation of swallowing and it provides extensive information about the swallowing events. Mild and moderate pharyngeal retention should be considered as normal in older individuals provided other causes are ruled out. Swallowing maneuvers are effective in preventing aspiration in patients with severe pharyngeal retention. Help of expertise of the Radiologist and Speech language pathologist permit the better evaluation of therapeutic strategies aimed at improving the chance that the patient with dysphagia can eat safely and effectively.

BIBLIOGRAPHY:

1. Gustafson-Yoshida N, Maglente DD, Hamaker RC, et al. Evaluation of swallowing disorders: the modified barium swallow. *Indiana Med* 1990;83:892-895.
2. Ekberg O, Olsson R. Dynamic radiology of swallowing disorders. *Endoscopy* 1997;29:439-446.

3. Aviv JE. Prospective, randomized outcome study of endoscopy versus modified barium swallow in patients with dysphagia. *Laryngoscope* 2000;110:563-574.
4. Jones B, Donner MW. Normal and abnormal swallowing: imaging in diagnosis and therapy. New York: Springer-Verlag, 1991:xvi, 235.
5. Leonard R, Kendall K, McKenzie S. UES opening and cricopharyngeal bar in nondysphagic elderly and nonelderly adults. *Dysphagia* 2004;19:182
6. Olle Ekberg, Feinberg MJ, Cheryl K. Chamberlain, John E. Cornell, Michèle J. Saunders, John P. Hatch, Rosemary S. Shinkai, Chih-Ko Yeh. 2007.
7. Intra-oral tactile sensation and aging in a community-based population. *Aging Clinical and Experimental Research* 19:2, 85-90. [[CrossRef](#)]
8. Karen Kost, Richard Payne. Laryngopharyngeal Reflux in the Elderly 383-394. [[CrossRef](#)]
9. Bernhard L. Partik, Martina Scharitzer, Gerd Schueller, Martin Voracek, Wolfgang Schima, Ewald Schober, Michael R. Mueller, Ann N. Leung, Doris-Maria Denk, Peter Pokieser. 2003. Videofluoroscopy of Swallowing Abnormalities in elderly
10. Langmore SE, Terpenning MS, Schork A, et al. Predictors of aspiration pneumonia: how important is dysphagia? *Dysphagia* 1998; 13:69-81
11. Feinberg MJ, Ekberg O. Videofluoroscopy in elderly patients with aspiration: importance of evaluating both oral and pharyngeal stages of deglutition. *AJR* 1991; 156:293-296
12. Dodds WJ, Stewart ET, Logemann JA. Physiology and radiology of the normal oral and pharyngeal phases of swallowing. *AJR* 1990; 154:953-963
13. Olsson R, Nilsson H, Ekberg O. Simultaneous videoradiography and computerized pharyngeal manometry: videomanometry. *Acta Radiol* 1994; 35:30-34
14. Ekberg O. The normal movements of the hyoid bone during swallow. *Invest Radiol* 1986; 21:408-410
15. Ekberg O, Nylander G. Cineradiography of the pharyngeal stage of deglutition in

- 150 individuals without dysphagia. *Br J Radiol* 1982; 55:253-257
16. Robbins J, Coyle J, Rosenbek J, Roecker E, Wood J. Differentiation of normal and abnormal airway protection during swallowing using the penetration—aspiration scale. *Dysphagia* 1999; 14:228-232
17. Friedman B, Frazier JB. Deep laryngeal penetration as a predictor of aspiration. *Dysphagia* 2000; 15:153-158
18. Frederick MG, Ott DJ, Grishaw EK, Gelfand DW, Chen MYM. Functional abnormalities of the pharynx: a prospective analysis of radiographic abnormalities relative to age and symptoms. *AJR* 1996; 166:353-357
19. Pick N, McDonald A, Bennett N, et al. Pulmonary aspiration in a long-term care setting: clinical and laboratory observations and an analysis of risk factors. *J Am Geriatr Soc* 1996; 44:763-768
20. Bryan CS, Reynolds KL. Bacteremic nosocomial pneumonia: analysis of 172 episodes from a single metropolitan area. *Am Rev Respir Dis* 1984; 129:668-671
21. Jones B, Donner MW. Examination of the patient with dysphagia. *Radiology* 1988; 167:319-326
22. Levine MS, Rubesin SE. Radiologic investigation of dysphagia. *AJR* 1990; 154:1157-1163
23. Auffermann W, Geisel T, Wohltmann D, Gunther RW. Tissue reaction following endobronchial application of iopamidol and ioxithalamate in rats. *Eur J Radiol* 1988; 8:13-17
24. Jones B, Donner M. The tailored examination. In: Jones B, Donner M, eds. *Normal and abnormal swallowing*. New York: Springer, 1991: 33-50
25. Kahrilas PJ, Logemann JA, Lin S, Ergun GA. Pharyngeal clearance during swallowing: a combined manometric and videofluoroscopic study. *Gastroenterology* 1992; 103:128-136
26. Olsson R, Castell J, Johnston B, Ekberg O, Castell DO. Combined videomanometric identification of abnormalities related to pharyngeal retention. *Acad Radiol* 1997; 4:349-354

27. Groher ME. The detection of aspiration and videofluoroscopy.
(editorial) *Dysphagia* 1994; 9:147-148
28. Langmore SE, Schatz K, Olson N. Endoscopic and videofluoroscopic evaluations of swallowing and aspiration. *AnnOtolRhinolLaryngol* 1991; 100:678-681
29. Ekberg O, Feinberg MJ. Altered swallowing function in elderly patients without dysphagia: radiologic findings in 56 cases. *AJR* 1991; 156:1181-1184
30. Dejaeger E, Pelemans W, Ponette E, Joosten E. Mechanisms involved in postdeglutition retention in the elderly. *Dysphagia* 1997; 12:63-67
31. Dodds WJ, Logemann JA, Stewart ET. Radiologic assessment of abnormal oral and pharyngeal phases of swallowing. *AJR* 1990; 154:965-974
32. Perlman AL, Booth BM, Grayhack JP. Videofluoroscopic predictors of aspiration in patient with oropharyngeal dysphagia. *Dysphagia* 1994; 9:90-95
33. Richter JE. Typical and atypical presentations of gastroesophageal reflux disease. The role of esophageal testing in diagnosis and management. *GastroenterolClin North America* 1996;25:75
34. Eisenberg RL. *Gastrointestinal radiology: a pattern approach* Philadelphia: Lippincott-Raven Publishers, 1996:xiv, 1194.
35. Marcon M, Briani C, Ermani M, et al. Positive correlation of CTG expansion and pharyngoesophageal alterations in myotonic dystrophy patients. *Ital J NeurolSci* 1998;19:75-80.
36. Rubesin SE, Yousem DM. Structural abnormalities of the pharynx. In: Levine MS, Gore RM, eds. *Textbook of gastrointestinal radiology* Philadelphia: W.B. Saunders, 2000
37. Ekberg O. Functional abnormalities of the pharynx. In: Freeny PC, Stevenson GW, Margulis and Burhenne's *alimentary tract radiology* St. Louis: Mosby-Year Book, 1994.
- 38 M. Klahn and A. Perlman, "Temporal and durational patterns associating respiration and swallowing," *Dysphagia*, vol. 13, pp. 131-138, 1999.

39. Investigation of Accelerometry, Mechanomyography, and

Nasal Airflow Signals for Abnormal Swallow Detection

by Joonwu tspace.library.utoronto.ca/bitstream/1807/26467/3/
Lee_Joonwu_200911

S.NO	NAME	AGE/SEX	I.P.NO	Radiological diagnosis
1	THAYAMMA	45/F	1462348	POST CRICOID WEB
2	DANIEL	66/M	016483	GROWTH LARYNX
3	GOVINDARAJ	24/M	16327	NORMAL STUDY
4	REVATHY	49/F	1462328	GROWTH HYPOPHARYNX
5	RAJENDRAN	34/M	16417	NORMAL STUDY
6	BANUMATHY	45/F	16180	UNILATERAL VOCAL CORD PALSY
7	MANORAMMAL	29/F	1459182	POST CRICOID WEB
8	SATHIYAPPAN	33/M	12097	NORMAL STUDY
9	SUNDRAMBAL	28/F	1458716	POST CRICOID WEB
10	MOORTHY	34/M	1458121	NORMAL STUDY
11	KRISHNAMOORTHY	39/M	13847	NORMAL STUDY
12	MOHAMMED HANIFA	65/F	1456369	PHARYNGEAL RETENTION
13	MARIMUTHU	25/M	12634	NORMAL STUDY
14	KALIYAPERUMAL	28/M	11157	NORMAL STUDY
15	JEYAPRATHA	49/F	12499	POST CRICOID WEB
16	TAMILSELVAN	70/M	14372	GROWTH LARYNX
17	MANIKKAM	33/M	3575	NORMAL STUDY
18	MURUGESAN	32/M	3578	NORMAL STUDY
19	MUTHUSELVI	55/F	4677	GROWTH HYPOPHARYNX
20	THIYAGARAJAN	34/M	2605	NORMAL STUDY
21	PONNAMMAL	33/F	4773	POST CRICOID WEB
22	RAJENDRAN	28/M	6030	NORMAL STUDY
23	KALIYAMOORTHY	44/M	5075	GROWTH HYPOPHARYNX
24	CHINNACHI	36/F	4209	POST CRICOID WEB
25	ABDUL	23/M	4341	NORMAL STUDY
26	GANESAN	35/M	5222	NORMAL STUDY
27	SELVAM	36/M	6113	NORMAL STUDY
28	IRUDHYAMARY	72/F	5395	PHARYNGEAL RETENTION
29	SHANMUGAM	23/M	30759	NORMAL STUDY
30	RAJENDRAN	36/M	1440195	NORMAL STUDY
31	INDIRANI	38/F	29672	POST CRICOID WEB
32	MOHAMMED RAFIQ	39/M	14372	NORMAL STUDY
33	PERIYASAMY	54/M	12499	PHARYNGEAL RETENTION
34	SURESH	40/M	11157	NORMAL STUDY
35	PARIMALAM	50/F	12634	POST CRICOID WEB
36	BALAGANESH	31/M	1456369	NORMAL STUDY
37	SELVI	66/f	013847	GROWTH HYPOPHARYNX
38	BATCHARFEVI	39/F	145871	POST CRICOID WEB

LIST OF ABBREVIATIONS

- CN - Cranial Nerve
- MBS - Modified Barium Swallow
- FEES - Fibreoptic endoscopic evaluation of swallowing
- MMG - MechanoMyoGraphy
- EMG - Electro MyoGraphy