

# STUDY OF POSTERIOR TIBIAL ARTERY, ITS BRANCHING PATTERN AND VARIATIONS WITH ITS CLINICAL APPLICATIONS

*Dissertation submitted for*

**M.S.ANATOMY – BRANCH –V  
DEGREE EXAMINATION**



**THE TAMIL NADU DR. M.G.R. MEDICAL UNIVERSITY  
CHENNAI**

**MARCH – 2008**

## **ACKNOWLEDGEMENT**

It is an overwhelming experience of getting the support and guidance from large number of people in completing this study and I would like to take this opportunity to thank each one of them.

I wish to acknowledge my sincere and great thankfulness to my teacher and guide **Dr. CHRISTILDA FELICIA JEBAKANI, M.B.B.S., M.S.**, Director and Professor, Institute of Anatomy, Madras Medical College for her valuable guidance, persistent support and suggestion in conducting and completing this dissertation work. Without her valuable guidance, this work would not have been possible.

I acknowledge my thanks to **Dr.T.P.KALANITHI M.D., Dean**, Madras Medical College, Chennai for permitting me to avail the facilities in this College during the course of this study.

I wish to acknowledge my thankfulness to **Mrs. M.S. Thenmozhi** for their appreciation and encouragement to my study.

My sincere thanks to **Dr.I.Jayaraj, Dr.B.Chezian, Dr.V.Lokanayagi, Dr.V.Sathialakshmi, Dr.M.Vijayalakshmi, Dr.Murugasen** for their encouragement, guidance and support throughout my dissections.

I wish to acknowledge my thanks to **Dr. T. VIDYASAGARAN M.S., M.Ch.**, Professor and Head of Department of vascular surgery, Madras Medical College, Chennai, for guiding me through the clinical study and helping me to collect materials for the study.

I wish to acknowledge my sincere thankfulness to **Dr.T.S.SWAMINATHAN, M.D., D.M.R.D.**, Director and Professor of Bernard Institute of Radiology, Madras Medical College, Chennai, **Dr.Sundaresan** and other faculty members for extending their support in angiographic studies.

I acknowledge my thanks to **Dr.M.P.NAMASIVAYAM, M.S., M.Ch**, Department of Plastic Surgery, Madras Medical College, Chennai, for providing valuable materials and suggestions regarding this study.

I acknowledge my thanks to **Dr.K.SARASWATHY, M.D.** The Director, Institute of Obstetrics and Gynaecology, Chennai, for permitting me to make use of the dead born foetuses with the consent of the parents.

I would like to extend my thanks to **Dr. M. Jayanthi, Dr.Preethi** and **Dr.Anitha** for being supportive and encouraging throughout this study.

I acknowledge my thanks to **Dr.Ananthi, Dr.Rajeswari, Dr.Mukundhan** and **Dr.Sudha**, for being supportive and encouraging throughout the study.

I would like to thank Mrs. Usha Rani who helped me in preparing the histology slides. I sincerely thank Mr. A. Abdul Jabbar, Mrs. Selen Mary, Mr.G.Ankiah, and Mr. Sugendran who helped with making arrangement for dissections.

I thank my husband **Dr. R. Deivanayagam**, my daughter **D.Sushma** who have been tolerant throughout and gave all their suggestions and their support in carrying out search on the internet and in the preparation of the manuscript.

Above all, I thank my **Almighty Lord** who blessed me with good health and knowledge for conducting and completing this study.

## ***CERTIFICATE***

This is to certify that the dissertation work on “**POSTERIOR TIBIAL ARTERY, ITS BRANCHING PATTERN AND VARIATIONS WITH ITS CLINICAL APPLICATIONS**” is the bonafide work done by **Dr.C.JEYANTHI GNANADEEPAM** in the Institute of Anatomy, Madras Medical College, Chennai – 600 003, during 2005-2008 under my supervision and guidance in partial fulfillment of the regulation laid down by the Tamil Nadu Dr.M.G.R. Medical University, for the M.S.Anatomy Branch V examination to be held in March 2008.

**Dr.T.P.KALANITHI M.D.,**  
Dean  
Madras Medical College  
Chennai – 600 003.

**Dr. CHRISTILDA FELICIA, M.S.,**  
Director  
Institute of Anatomy  
Madras Medical College,  
Chennai – 600 003.

Date :

Date :

Station :

Station :

# ***CONTENTS***

|                                 | <b>Page No.</b> |
|---------------------------------|-----------------|
| <b>1. INTRODUCTION</b>          | <b>1</b>        |
| <b>2. AIM OF THE STUDY</b>      | <b>3</b>        |
| <b>3. REVIEW OF LITERATURE</b>  | <b>5</b>        |
| <b>4. DEVELOPMENTAL ANATOMY</b> | <b>31</b>       |
| <b>5. MATERIALS AND METHODS</b> | <b>34</b>       |
| <b>6. OBSERVATION</b>           | <b>40</b>       |
| <b>7. DISCUSSION</b>            | <b>52</b>       |
| <b>8. CONCLUSION</b>            | <b>69</b>       |
| <b>9. BIBLIOGRAPHY</b>          |                 |

# **POSTERIOR TIBIAL ARTERY, ITS BRANCHING PATTERN AND VARIATIONS WITH ITS CLINICAL APPLICATIONS**

## **INTRODUCTION**

The descriptions of the arterial trunks of the limbs and of the arrangement of their main branches found in anatomy text books represent the patterns encountered in a majority of subjects and such patterns are then accepted as the normal or average arrangement. Striking variations in the origin and course of the principal arteries are termed as abnormalities and this have received considerable alterations in the anatomical literature. Accurate knowledge of the relationships and course of these major arterial conducts and particularly of their variable pattern is of considerable importance in the conduct of vascular surgery and plastic surgery.

In the modern world, people are exposed to many toxic substances and thereby suffer from many diseases. Incidence of vascular diseases affecting lower limb vessels are more common in diabetics and smokers. Diabetes is a contributing factor in half of all lower extremity amputations. Arterial revascularization is essential for successful wound healing and avoidance of amputations.

After trauma to the lower extremity a wide spread change occurs in the walls and perivascular tissues of the major vessels of the limb. These vessels are easily prone to intractable constriction and infection. A fasciocutaneous flap secures the viability of tissues exposed to trauma or surgery. The flap brings additional blood supply to the site of a previously infected wound, that promotes and secures the permanent healing of a wound.

The knowledge about the posterior tibial artery as well as its variations are very much important for vascular surgeons, plastic surgeons and Radiologists according to which they can modify the surgical procedure in a more satisfactory way. This study of variations in posterior tibial artery and its branching pattern will help them to prevent most of the common post operative complications.

## **AIM OF THE STUDY**

Variations in origin and course of the principal arteries of the lower extremities have long received the attention of anatomists and surgeons. The incidence of vascular diseases are more common and diabetes and smoking are main contributing factors in lower extremity amputations . Now a days arterial reconstructions are performed in lower extremity which rely on the tibial and peroneal arteries to serve as the inflow and outflow vessel.

The peroneal artery is an important vessel to consider for use in limb revascularization and salvage in the absence of suitable popliteal or tibial artery. The main principle of arterial reconstruction in the diabetic foot is to obtain maximal perfusion to the foot and to restore normal arterial pressure to the target area. In the past, the gangrene was usually associated with the need for a higher amputations level. As enthusiasm for femoral –popliteal and femoral-tibial arterial bypass for limb salvage grew, the rates of limb loss correspondingly decreased.

The fasciocutaneous skin flap in treating any infected wound is now very common. Flap refers to any tissue used for reconstruction or wound closure that retains part or all of its original blood supply after the tissue has been raised and moved to a new location. This fasciocutaneous skin flap is based on the cutaneous perforators of the main artery. Posterior tibial artery perforators flap is successfully used in clinical practice.

In chronic lower limb ischaemia the widely accepted and routinely employed procedure is tibial and peroneal angioplasty. All these things have kindled my interest to do a detailed study of the posterior tibial artery under the following parameters.



1. Origin of posterior tibial artery in relation to popliteus muscle.
  2. Course and mode of termination of the posterior tibial artery .
  3. Level of bifurcation of posterior tibial artery into medial and lateral planter arteries.
  4. Relation of posterior tibial artery to tibial nerve.
  5. Branches of posterior tibial artery and the variations.
    - a) Circumflex fibular artery.
    - b) Nutrient Artery of the tibia.
    - c) Muscular branches.
    - d) Perforating branches.
    - e) Peroneal Artery.
1. Origin of peroneal artery
  2. Distance of origin of peroneal artery from the commencement of posterior tibial artery.
  3. Course and termination of peroneal artery.
    - f) Communicating branch.
    - g) Medial malleolar branches.
    - h) Medial calcaneal branches.
    - i) Terminal branches – medial and lateral planter arteries.

This study may help to add more information to guide the vascular and plastic surgeons and radiologists.

## **REVIEW OF LITERATURE**

### **Quain R (1844)**

He described various arterial anomalies of the leg. These are as follows;

1. High division of the popliteal artery into the posterior tibial and peroneal, the latter giving off the anterior tibial.

The peroneal artery, instead of arising from the posterior tibial artery takes origin from the popliteal artery while the anterior tibial artery arises from the peroneal artery.

2. High origin of peroneal artery, the popliteal artery being normal.
3. High division of the popliteal artery into posterior and anterior tibial arteries.
4. Division of the popliteal artery into anterior tibial and great peroneal or an artery derived from kindred antecedents, the posterior tibial being absent.
5. The peroneal artery is smaller than usual, the posterior tibial being present.
6. The peroneal artery is larger than usual and supplies the sole, the posterior tibial artery being absent.

### **Henry Gray (1858)**

He has described in Text book of Gray's Anatomy that the posterior tibial artery begins at the lower border of the popliteus, opposite the interval between the tibia and fibula and passes downwards and medially on the back of the leg. In the lower part of its course it is situated midway between the medial malleolus and the medial process of the tubercalcanei. It divides under cover of origin of the abductor hallucis into the medial and lateral plantar arteries.

He also described that the posterior tibial artery lies successively upon the tibialis posterior, the flexor digitorum longus, the tibia and the back of the ankle joint. Its upper part is covered by the gastrocnemius and soleus, and the deep transverse fascia of the leg. Its lower part is covered only by the skin and fascia and runs parallel with, and about 2.5 cm in front of the medial border of tendocalcaneus. Its terminal part is deep in flexor retinaculum and abductor hallucis. It is accompanied by two veins and by the tibial nerve which lies at first on its medial side, but soon crosses it posteriorly and is in the greater part of its course on its lateral side. Under the flexor retinaculum, it lies between tibialis posterior and flexor digitorum longus tendons medially and flexor hallucis longus tendon laterally.

It gives out the circumflex fibular artery, peroneal artery, nutrient artery of the tibia, muscular branches, communicating branch, medial malleolar branches, and medial calcaneal branches. Its terminal branches are medial and lateral plantar arteries.

He also describes that the peroneal artery arises from the posterior tibial, about 2.5cm below the lower border of the popliteus. It passes obliquely towards the fibula and descends along the medial crest of the bone, contained in a fibrous canal between the tibialis posterior and flexor hallucis longus, or in the substance of the latter muscle. It then runs behind the tibio-fibular syndesmosis and divides into calcaneal branches. Its upper part is covered by the soleus and the deep transverse fascia of the leg. Its lower part by the flexor hallucis longus. (Fig. 1,2)

Variations quoted by him are,

The posterior tibial artery may be much reduced in length or caliber. The peroneal artery then takes over its distal territory and may consequently be increased in size.

The peroneal artery may branch high from the posterior tibial artery or may even branch from popliteal artery separately, giving a true trifurcation.

The peroneal artery may also branch more distally from the posterior tibial artery sometimes 7 to 8 cm distal to popliteus . Its size may be reduced but is more often enlarged, when it may join, reinforce or replace the posterior tibial artery in the distal leg and foot.

The circumflex fibular artery, which sometimes arise from anterior tibial artery.

In the latest editions of Gray's Anatomy by Susan Standring, the anatomical basis of clinical practice (2005), it is said about that the posterior tibial artery gives perforating branches also. These are approximately five fascio cutaneous perforators which emerge between flexor digitorum longus and soleus and pass through the deep fascia often accompanying the perforating veins that connect the deep and superficial venous systems. The arterial perforators then divide into anterior and posterior branches to supply periosteum and skin. These vessels are utilized in raising medial fasciocutaneous perforator flaps in the leg.

### **Hyrtil .J (1864)**

He reported in his studies about various arterial anomalies of leg and foot that

- 1) the posterior tibial artery arises from popliteal artery in a high level.
- 2) popliteal artery divides into anterior tibial artery and great peroneal artery, the posterior tibial artery being absent.
- 3) the peroneal artery is larger than usual and supplies the sole, the posterior tibial artery being absent.

**Mr. Craver (1869)**

He dissected the cadaver of an idiot in the dissecting room and reported the absence of peroneal artery on the left side. The posterior tibial inclined outwards, entering the substance of the flexor longus pollicis about its middle. Having perforated that muscle it passed between it and tendoachillis and appeared at inner ankle. A little above the ankle it gave off a large branch which was distributed about inner malleolus and another branch taking the place occupied by the terminal branch of the peroneal, passed through the interosseous membrane to the front of the leg. On the right side the distribution of the arteries in the leg and foot was normal.

**Parsons, F.G., and Robinson, A. (1898)**

They collected reports on the level of ending of the popliteal artery in 106 specimens and said that in 82 percent of these the division of the artery was either at or within 0.25 inch (0.6cm) of the lower border of the popliteus, but that in 8.2% it divided more than 0.5 inch (1.3cm) above this border. They also found that high division of the popliteal artery is often associated with origin of the peroneal artery from the anterior rather than the posterior tibial artery. They also reported that in 5% of 106 cases, peroneal artery arose at the level of division of the popliteal artery into anterior and posterior tibial artery. So that the popliteal artery actually ended in a trifurcation.

**E.A. Schafer (1912)**

He described the posterior tibial artery as a medium sized artery when examined under a high power microscope a transverse section of a posterior tibial artery shows from within outwards, a fine transparent colourless

membrane that is tunica intima which consist of three different structures namely,

- an endothelial layer which is a simple layer of thin elliptical cells.
- a sub endothelial layer which is composed of finely fibrillated connective tissue with a number of branched corpuscles lying in the cell spaces of the tissue.
- an elastic layer which represented by a dark sinuous line that represents the internal elastic lamina. It is not a continuous membrane but is a fenestrated membrane .

Then a broad pale band, representing the middle coat or tunica media, composed of non-stripped muscular fibres arranged concentrically broken up on its outer side into more or less distinct fasciculi by the elastic fibres of the middle coat.

Outside the muscular coat is a broad, deeply stained band, containing a large number of elastic fibres held together by white fibrous tissue. This is called the tunica adventitia. Still further outwards is the loose connective tissue. (Fig.3,4)

### **Adachi, B. (1928)**

Adachi has reported in his studies that any terminal division of the popliteal artery which takes place at a level above the middle of the posterior surface of the popliteus muscle must be considered as a high division and he gave the incidence as 2.8% in 770 limbs be studied. He also refers about trifurcation another variant of popliteal artery pattern where all 3 terminal branches arise together at the level of lower border of popliteus muscle.

He gives the mean length of posterior tibial artery above the origin of the peroneal as 26-30mm. As regards the termination of posterior tibial artery, he gives 7 types of bifurcation of the posterior tibial artery, but the variations refer to differing anatomical relationships between the two plantar arteries and the corresponding nerves.

**H.D. Senior, (1929)**

He mentioned that true absence of the peroneal artery has never been reported, when it replaces the posterior tibial artery on the foot, it typically passes superficial to the flexor hallucis longus tendon to assume the position of the posterior tibial artery at the ankle, and usually continues into the foot as the lateral plantar artery. The medial plantar is then usually absent.

**George A.Piersol (1930)**

He has written in his text book of Human Anatomy that the posterior tibial artery is the direct continuation of popliteal artery. It begins at the bifurcation of the popliteal artery at the lower border of the popliteus muscle and passes vertically downward. In its course it rests upon the tibialis posterior, the flexor digitorum longus and the posterior surface of the lower part of the tibia, but deep to the more superficial muscles of the calf, to the groove between the medial malleolus and the calcaneus, opposite the tip of the malleolus, it terminates by dividing into medial and lateral plantar arteries. Its course may be indicated by a line drawn from the centre of the popliteal space to a point midway between medial malleolus and the calcaneus .

The nutrient artery to the tibia may arise from the posterior tibial, either above or below the origin of the peroneal artery, or it sometimes arises from that vessel. The peroneal artery is exceedingly subject to variation. It is

rarely absent, but frequently it terminates over the lateral malleolus, its lower portion being given off from a branch which passes across from the posterior tibial and represents the enlarged anastomosis of the posterior tibial and peroneal communicating branches.

He says numerous variations in the posterior tibial artery are,

- The posterior tibial artery may arise above the upper border of the popliteus muscle or it begins a point almost half way down the leg.
- There may be no posterior tibial or it may be represented by a small vessel whose distribution is confined to the upper part of the leg.
- Sometimes the posterior tibial artery has been observed to perforate the lower part of the interosseous membrane and to be continued down the dorsum of the foot as the dorsalis pedis artery, the plantar arteries, arising from the peroneal.
- Occasionally, the posterior tibial artery may terminate by inosculating with the peroneal, probably by the enlargement of the communicating branch, the peroneal in this case also giving rise to the plantar arteries.

### **Thomas Walmsley (1934)**

He had written that posterior tibial artery is the direct continuation of the popliteal artery and is larger of its terminal divisions. It begins at the lower border of the popliteus muscle. It is accompanied by two venae comites. The peroneal artery sometimes even larger than the parent vessel, arises about 2 inches below the popliteus muscle. Peroneal artery terminates by dividing into perforating and posterior malleolar branches. A medial calcaneal branch arises beneath the flexor retinaculum and then it perforates that band and supplies the superficial structures on the medial side of the heel.



### **J.E. Frazer (1937)**

He describes that the posterior tibial artery commences at the lower border of the popliteus muscle on a level with the lower limit of the tubercle of the tibia, and usually ends deeply to the flexor retinaculum by dividing into medial and lateral plantar arteries. The artery is accompanied by two venae comites which are connected together by numerous transverse communications lying superficial to the artery. Above, the posterior tibial nerve is medial to the artery, but crossing the vessel superficially just below the origin of peroneal artery, the nerve lies on its outer side for the rest of its course. The peroneal artery is the largest branch which arises about 1 inch below the bifurcation of the popliteal artery. The communicating branch arises from the posterior terminal branch a short distance above the ankle joint.

Variations quoted by him are,

- The level at which the posterior tibial artery divides into the two plantar arteries is variable.
- This vessel may be much diminished in size.
- In such cases the peroneal Artery is relatively increased and by means of an enlarged communicating branch conveys blood to the distal end of the posterior tibial artery.
- In rare cases the vessel does not extend to the ankle and may be entirely absent, in which cases the deficiency is made good by an enlarged peroneal artery.
- The level at which the peroneal artery arises is subject to variation. Peroneal artery may be at a higher level in which case it may be a branch of the popliteal artery or at a lower level than normal where it arises from the anterior tibial artery.
- The peroneal artery is often enlarged and replaces the posterior tibial artery to a varying extent.

### **Y.H. Aasar (1939)**

He found a case in his dissecting room that shows the arteria genu suprema (A.G.S) arising as usual from the distal end of the second part of the femoral artery, giving off almost immediately its musculo - articular branch and continuing as a well marked saphenous artery. This descends with the saphenous nerve on the medial side of the lower part of the thigh and the upper half of the leg. It is tortuous in its lower half at the end of which it pierces the fascia enters into the posterior compartment of the leg and it ascends for a short distance and joins the posterior tibial artery. Numerous branches are given from it on the front of the leg but none of them could be followed to the dorsum of the foot.

### **C. Latimer Callander (1939)**

He reported that the posterior tibial artery originates just distal to the ring in the soleus muscle. In its upper 2/3, the artery is deep, in the rest of its course, it is superficial, near its termination, it has beneath the lancinate ligament among the tendons of the deep leg muscles. Peroneal artery arising about 2.5cm below the bifurcation of the popliteal. It follows the medial edge of the fibula within the flexor hallucis longus and remains in close relation with the posterior aspect of the bone and with the interosseous membrane throughout the rest of its course.

### **Trotter, M. (1940)**

He found a high ending of the popliteal artery, with the division occurring on the posterior surface of or above the upper border of the popliteus muscle, in 4.9% of 246 extremities from white persons and 6.2% of 338 extremities from Negro persons. He also found the anterior tibial artery

passing distally on the anterior surface of the popliteus muscle in about 1/3<sup>rd</sup> of instances in which there was high division of the artery. He reported that high division of the popliteal artery is often associated with the origin of the peroneal artery from the anterior rather than posterior tibial artery. He gives the average level of origin of the peroneal artery as 2.5cm below the commencement of the posterior tibial artery.

**Huber, J.F. (1941)**

He found 6 cases in 200 dissections (3%) where the dorsalis pedis artery began as a continuation of the perforating branch of the peroneal artery. There were 7 instances where the peroneal artery replaced or reinforced the posterior tibial (2.5%) among these were two subjects in which the posterior tibial artery was absent on both sides. In each case the vessel was replaced by a strong peroneal artery which turned medially at the ankle joint level, and then assumed the functions of a posterior tibial artery .

**J.C.B. Grant (1951)**

In the book “ The Anatomy of the Respiratory, Blood Vascular and Lymphatic systems”, they had written that posterior tibial artery is the larger terminal branch of the popliteal artery, begins at the distal border of the popliteus and ends at the distal border of the flexor retinaculum. Posterior tibial artery may be small or altogether absent, its place being taken by branches of the peroneal artery. Peroneal artery is large, if either the anterior or the posterior tibial artery is small. In some cases the perforating branch of the peroneal artery replaces the whole dorsalis pedis artery. Peroneal artery sometimes arises from a stem common to posterior and anterior tibial artery. From posterior tibial artery cutaneous branches are distributed to the skin of the medial and posterior part of the leg. Communicating branch from posterior

tibial artery unites it to peroneal artery about an inch above the inferior tibio-fibular joint.

The circumflex fibular branch passes laterally round the neck of the fibula through the fibres of the soleus. Occasionally it springs from the lower end of the popliteal artery, or from the anterior tibial. The nutrient branch of the tibia springs from the proximal part of posterior tibial, pierces the tibialis posterior muscle and enters into the nutrient foramen on the posterior surface of the bone.

**J. Parsons Schaeffer (1953)**

He described that posterior tibial artery is the one of the largest terminal branch of popliteal artery at the distal border of the popliteus muscle. Under cover of the origin of abductor hallucis it divides into medial and lateral plantar arteries. First it is situated midway between the tibia and fibula, and is deeply placed beneath the muscles of the calf. As it passes distally it inclines to the medial side and at the distal third of the leg is superficial being covered by the skin and fasciae.

The fibular branch usually arises from the beginning of anterior tibial or from posterior tibial artery. The peroneal artery arises from the posterior tibial artery about 2.5 cm below the distal border of the popliteus muscle. It passes laterally and reaches fibula, then dips beneath flexor hallucis longus. It terminates on the lateral surface of the tuber calcanei by breaking up into lateral calcaneal branches.

**F.H.Poteete JR, Robert.C.Lynch, New Ordeans LA (1956) .**

They described 2 cases of histologically proved thrombo angitis obliterans in woman. In this cases, the posterior tibial arterial wall showing of pronounced tortuosity of elastica interna , perivascular fibrosis and prominent vasa vasorum in tunica media of artery. (Fig.5)

**J.D. Boyd et al (1956)**

He described that the posterior tibial artery is accompanied by the posterior tibial nerve. Its pulsation can usually be felt at its termination, midway between medial malleolus and the medial tubercle of the calcaneum where it divides into medial and lateral plantar arteries. The peroneal artery, arising from the posterior tibial artery about 1 inch below its commencement, descends along the fibula to the back of the lateral malleolus .

**R.D. Lockhart, G.F. Hamilton, F.W. Fyee (1959)**

They described that the posterior tibial artery the larger and more direct terminal branch of the popliteal artery gives origin to the most important branch the peroneal artery, an inch below popliteus as it is descending between tibialis posterior and soleus deep to the fascial layer between the muscles. It divides into medial and lateral plantar arteries deep to the abductor hallucis . It also gives circumflex fibular , muscular branches, nutrient branch, communication branch, medial malleolar and calcaneal branches.

**J.A. Keen (1961)**

He reported the variations of the arterial patterns in two lower limbs of 140 subjects (280 dissections). High division of the popliteal artery was found 14 times in 250 limbs (5%). Trifurcation of the popliteal artery was seen 12

times in his series (4.3%) There were 7 instances where the peroneal artery replaced or reinforced the posterior tibial artery (2.5%). Among these were 2 subjects in which the posterior tibial artery was absent on both sides, in each case the vessel was replaced by a strong peroneal artery which turned medially at the ankle joint level, and then assumed the functions of a posterior tibial artery.

### **Russell .T. Woodburne (1961)**

He has described that the posterior tibial artery is the direct continuation of the popliteal artery. It runs at first diagonally toward the fibula, then after giving off the peroneal artery, it inclines medialward and passes behind the medial malleolus. The artery divides beneath the origin of the abductor hallucis into medial and lateral plantar arteries. The peroneal artery is the largest branch of the posterior tibial artery and developmentally is the major artery of the leg which arises 2 to 3 cm below the lower border of popliteus muscle. The larger nutrient branch from its upper part of posterior tibial artery, enters the nutrient foramen in the proximal one third of the posterior surface of the tibia. The communicating branch unites posterior tibial artery and peroneal artery a centimeter or more above the tibio-fibular syndesmosis. Posterior medial malleolar branch of posterior tibial artery anastomoses with the anterior medial malleolar branch of the anterior tibial artery. Medial calcaneal branches anastomoses with the lateral calcaneal branches of the peroneal artery.

### **Sir Solly Zuckerman. C.B. (1961)**

In his text book quoted that posterior tibial artery arises from popliteal artery just above the lower border of popliteus muscle. In the distal half of the leg the artery having moved medial to the tendocalcaneus becomes superficial and that it is covered by skin and fascia only. It gives small muscular branches

through out its course. Just below the popliteal fossa, it gives off a large peroneal artery which enters the belly of flexor hallucis longus muscle.

**Roger Warwick (1963)**

He has stated that the posterior tibial artery begins at the lower border of the popliteus muscle under cover of the contiguous borders of the two heads of the gastrocnemius and tendinous arch of the soleus. The peroneal artery is the largest and most important branch which arises a short distance below the termination of the popliteal artery. The muscular and cutaneous branches are numerous.

**Sir John Bruce, Robert Walmsley, James A Ross (1964)**

They have mentioned that the posterior tibial artery begins at the level of the tibial tuberosity and at first lies on the tibialis posterior, but near the ankle joint, it lies between the flexor hallucis longus and the flexor digitorum longus tendons. The peroneal artery arises from the posterior tibial artery soon after its origin and runs downwards in relation to fibula.

**G.J. Romanes (1964)**

He has written in his “Cunningham’s Text book of Anatomy” that the posterior tibial artery sometimes arises at a higher level than usual. The popliteal artery may divide at a more proximal or more distal level than usual and the division may be into either two or three branches. If three, they are the anterior and posterior tibial and peroneal arteries and if only two, either the two tibials or the anterior tibial and peroneal arteries. The posterior tibial artery is crossed by the tibial nerve about an inch distal to its origin. A circumflex fibular branch may arise from the anterior tibial artery. The communicating

branch unites the posterior tibial artery to the peroneal artery 2.5 cm above the tibio fibular syndesmosis. The peroneal artery arises about 2.5cm below the distal border of the popliteus.

**Ben Pansky, Earl Lawrence House (1964)**

They described that it is the direct continuation of the popliteal artery. It gives peroneal, posterior medial malleolar, communicating, medial calcaneal, muscular branches and nutrient branch to tibia. The peroneal artery approaches fibula and lies in a fibrous canal between tibialis posterior and flexor hallucis longus muscles.

**Ernest Gardner, Donald J. Gray, RonanO' Rahilly (1967)**

They have described that the first portion of posterior tibial artery is sometimes termed the tibioperoneal trunk, which is then dividing into the posterior tibial and peroneal arteries. Distally the posterior tibial artery becomes more superficial but, at its division into medial and lateral plantar arteries, it lies deep to flexor retinaculum and abductor hallucis. The tibial nerve is successively medial, posterior and lateral to the artery. The peroneal artery which is as large as posterior tibial, arises a few centimeters below the lower border of popliteus from posterior tibial artery. Medial malleolar branch of posterior tibial artery gives off calcaneal branches or these may arise separately from the posterior tibial artery just before its division.

**Maurice Arnold (1968)**

He has reported in his studies that the posterior tibial artery is the larger branch of popliteal artery. It is separated from the capsule of the ankle joint by connective tissue. Its pulse can be felt midway between medial malleolus and



calcaneus. Peroneal artery arises about 1 inch below the beginning of the parent trunk.

**W. Henry Hollinshead (1969)**

He has described in his book “Anatomy for surgeons” that the posterior tibial artery occasionally small in the leg after giving off the peroneal but attains its usual size at the ankle after being joined by the communicating branch of the peroneal. Rarely the posterior tibial artery is absent, it and the peroneal being replaced in the leg by an artery, the great peroneal that contributes to the peroneal and otherwise normally disappears during later development.

One of the upper muscular branches of posterior tibial artery is the fibular circumflex artery. This branch may arise from the lower end of the popliteal artery or occasionally from the anterior rather than posterior tibial artery. The peroneal artery may arise from anterior tibial artery rather than from the posterior tibial artery. Branches of the peroneal artery may partially replace those of posterior tibial artery and if the latter is small or missing the lower end of the peroneal is typically continued into the foot to form the lateral plantar artery.

**Barry J. Anson, Chester B. McVay (1971)**

They have written that the posterior tibial artery originates just distal to the ring in the soleus muscle. In its upper 2/3, the artery is deep, then it is superficial. So the incision for ligation of the artery in its upper 2/3 is not made exactly in the course of the artery. The peroneal artery arising about 2.5 cm below the bifurcation of the popliteal, is the largest branch of posterior tibial artery.

### **Samarendra Mitra (1973)**

He has described that the popliteal artery bifurcation may be opposite the knee joint. Sometimes it may terminate into anterior and posterior tibial and peroneal arteries or anterior tibial and peroneal arteries.

In the lower part of the leg, the posterior tibial artery runs parallel to and 2.5cm in front of the medial border of the tendocalcaneus. The tibial nerve just lies medial to the posterior tibial artery and then the nerve crosses the artery superficially in the middle of the back of the leg, then the nerve descends lateral to the artery.

### **John V. Basmajian (1980)**

He has described in his book "Grants method of Anatomy" that the posterior tibial artery begins at the upper border of soleus and ends deep to flexor retinaculum. Near the ankle, 2 layers of fascia cover it. When this fascia is relaxed by inverting the foot, the pulsations of the artery can be felt behind the medial malleolus.

### **Keith L. Moore (1980)**

He reported in his book clinically oriented Anatomy that the posterior tibial artery begins at the distal border of the popliteus muscle between the tibia and fibula, as the larger terminal branch of popliteal artery. Deep to flexor retinaculum and the origin of abductor hallucis, the posterior tibial artery divides into medial and lateral plantar arteries. Peroneal artery is the most important collateral branch of posterior tibial artery. It begins 2-3cm inferior to the distal border of the popliteus and tendinous arch of the soleus. The nutrient artery of the tibia arises from posterior tibial artery near its origin. It

passes through the nutrient foramen just distal to the soleal line on the posterior surface of the tibia.

**Harold Ellis (1980)**

He has described that the posterior tibial artery can be exposed by splitting gastrocnemius and soleus in the midline. In the lower third of the leg, it passes behind the medial malleolus between the tendons of flexor digitorum longus and flexor hallucis longus. It is accompanied by its corresponding vein and by the tibial nerve. Posterior Tibial Artery gives off the peroneal artery about 1.5 inch (4cm) from its origin.

**M. Prives, N. Lysenkov, V. Bushkovich (1985)**

They have described that the posterior tibial artery can be regarded as a continuation of the popliteal artery. Descending along the canalis cruro-popliteus, it emerges from under the medial edge of soleus muscle and comes near the surface. It divides on the sole into two of its terminal branches. The pulse of posterior tibial artery is palpated by pressing it against the medial malleolus. The biggest branch of posterior tibial artery is peroneal artery which originates in the upper one third of posterior tibial artery, passing downwards and laterally into the canalis musculo peroneus inferior and ending at the calcaneus.

**Ronan O'Rahilly (1986)**

He has stated that the posterior tibial artery begins at the lower border of popliteus. At its division into medial and lateral plantar arteries, it lies deep to flexor retinaculum and abductor hallucis. Tibial nerve is successively medial, posterior and lateral to the artery. If the anterior tibial is small or absent, the peroneal is large and may, by means of its perforating branch, replace the

dorsalis pedis artery. A medial malleolar branch ramifies on the medial malleolus and it gives off calcaneal branches to the calcaneal network.

**Sanders RJ., Alston GK (1986)**

They performed a review of the anatomical characteristics of the popliteal artery and its tibial branches in 147 patients. The anterior tibial artery arose 6-8 cm below the knee joint in 91% of limbs. The posterior tibio-peroneal trunk was 2 to 5 cm in length in 87% of the patients. In 3%, the posterior tibial artery originated directly from popliteal artery proximal to anterior tibial origin. It was located either at knee joint or within 5cm of it. In 75%, the anomalies were bilateral.

**R. Kanagasuntheram, P. Sivanandasingham, A Krishnamurti. (1987)**

They have reported that a number of muscular and cutaneous branches arise from the posterior tibial artery. Peroneal artery arises about 2.5 cm distal to the bifurcation of the popliteal artery and there is only one artery (popliteal) at about 2.5cm below the knee joint, two arteries (anterior and posterior tibial) about 5cm below the knee joint, and three arteries (the two tibial and peroneal) about 7.5 cm below the knee joint.

**David Harvey (1990)**

He has described that the popliteal artery bifurcates into the tibioperoneal trunk and the anterior tibial artery. The tibioperoneal trunk in turn bifurcates into the peroneal and posterior tibial artery. On the plantar surface of the foot, the arterial circulation is provided by the medial and lateral plantar branches from the posterior tibial artery. The lateral plantar artery is larger than the medial plantar vessels in 80 percent of cases.

**Voboril . R (1990)**

The organization of the arterial bed was evaluated in the arteriograms of 253 lower extremities of subjects of a known sex and age. The crural segment was the most variable part of the arterial bed of the lower limbs. Most frequently, in 21.7 % of the subjects, anomalies of the crural arteries were unilateral, in 4.6 % they were bilateral. In 2.3%, bilaterally different anomalies were present. The tibialis posterior artery is the most variable crural artery and the peroneal artery is the most stable.

**Koshima I, Moriguchi T, Ohta S, Hamanaka T.**

They have studied the vascular anatomy of the posterior tibial artery in 20 legs of 10 cadavers. The number and size and distribution of the direct cutaneous and direct muscular branches of posterior tibial artery were recorded. For analysis, the leg was divided into four equal segments. Zone-I being the most distal and Zone IV the most proximal. The direct cutaneous branches were found to cluster mainly around Zone II. The direct muscular branches to the soleus and flexor digitorum longus muscles arose chiefly in Zone II & III. Based on this knowledge, they performed fascio cutaneous flaps based on the posterior tibial vessels in 12 patients.

**Hallock GG, Anous MM, Sheridan BC. (1993)**

They pointed out that the origin of the nutrient artery of the tibia may be from the popliteal bifurcation or anterior or posterior tibial vessels. In every dissection a single artery and vein were discovered entering a nutrient foramen, usually at the upper third of the tibia.

### **Rodriguaz JI. (1993)**

He gave a report on 4 patients with the campomelic Syndrome (CS) in whom postmortem angiography of the lower limbs was performed. Of the 4 patients, 3 were phenotypic females and one was a male with a normal 46, XY karyotype . The results of the angiographic study are compared with 46 postmortem angiographics of normal foetuses and new born infants at different gestational ages. In the first 3CS patients the posterior tibial arteries had greater diameters than age matched controls. The most striking abnormality was the absence or marked deficiency of the anterior tibial artery. Its terminal branch, the dorsalis pedis artery was also absent and the plantar arch was abnormally formed by the posterior tibial artery either alone or in conjunction with the peroneal artery.

### **Robert B. Rutherford (1993)**

He has pointed out that in the middle segment of the leg, the posterior tibial artery should be obtained just below the mid point where the soleus is thin or absent. At this point, the great saphenous vein is even closer to an incision over the artery rather than just above the medial malleolus. So that insitu by pass is easily performed here. At the ankle, the posterior tibial artery usually lies more anterior and deeper than the vein with the more posterior and venae comitantes are usually numerous.

### **Wu WC, Chang YP, So YC, Yip SF , Lam YL (1993)**

Studied the perforators from the posterior tibial artery in 25 cadaveric legs. Based on this study considered the cutaneous perforators to be distributed from the distal to the proximal sides of the lower leg through the medial border of the tibia and they were classified into three types.

- Septocutaneous perforators – mainly located in the distal third of the leg.

- Muscle perforators – located in the proximal half.
- Periosteal perforators in the proximal third of the leg.

**Berish Strauch, Han-Liang Yu (1993)**

They have described that the posterior tibial artery in its course gives off about four or more septocutaneous branches along the medial border of the tibia. These branches emerge to the subcutaneous layer. He made a study of the peroneal artery and stated that it arises from the posterior tibial artery about 3cm below the lower border of the popliteus muscle, at a level of 7 cm below the head of the fibula.

He also gave a report of the variations of the peroneal artery. (Fig.6)

- Type A. The peroneal artery arises from the posterior tibial artery in 90% of cases.
- Type B. It arises from the anterior tibial artery in 1% cases.
- Type C. It arises from the popliteal artery in 1% of cases.
- Type D. It takes the place of the posterior tibial artery in 8% cases.

**Poratt D, Tilley GE (1994)**

They presented a case, in which the arteriograms showed that the peroneal artery had replaced the absent posterior tibial artery. The peroneal artery coursed medially below the ankle joint to become the plantar arteries of the foot.

**Richard S. Snell (1995)**

He has stated that the posterior tibial artery passes behind the medial malleolus beneath the flexor retinaculum and lies between the tendons of flexor digitorum longus and flexor hallucis longus . The peroneal artery may be larger than normal and replace the posterior tibial artery in the lower part of the leg.

**Saadeh FA, el-Karagy SA, Haikal FA (1995)**

They reported in a combined radiographic anatomic study, the anterior tibial artery in a still born male was a branch of the posterior tibial artery at about its midpoint.

**Piral T, Germain M, Princ G. (1996)**

They reported a well documented case of absence of the posterior tibial artery . They have studied 40 personal case – records of dissection of the arteries of the leg in fresh corpses. This study allowed classification of the origins of the leg arteries from the popliteal artery into 7 groups.

Several findings emerged,

- 1) The peroneal artery is constant for phylogenetic and embryologic reasons.
- 2) The posterior tibial artery is absent in 1 to 5% of cases. Other anatomic variations may be trifurcation of popliteal artery. Origin of the anterior tibial artery from the peroneal artery, and aplasia of the terminal portions of both anterior and posterior tibial arteries.



**Hung LK, Lao J, Ho PC. (1996)**

They made a study of the anatomy of cutaneous perforators of the posterior tibial artery in 20 limbs of 10 cadavers. The majority of the perforators were (61%) located in the middle two quarters of the leg at an average of 18.6 cm from medial malleolus and usually 3 or 4 perforators in this region.

The posterior tibial flap enables the surgeon to retain the posterior tibial artery when the skin of the medial aspect of the leg is chosen to be used as a skin flap donor .

**Renan Uflacker(1997)**

He has described that the segment of posterior tibial artery before giving off the peroneal artery is commonly called the tibial peroneal trunk positioned in between tibia and fibula. The circumflex fibular artery may arise from the anterior tibial artery. Peroneal artery originates from the first centimeter of the posterior tibial artery and may arise directly from popliteal artery. The nutrient artery of the tibia arises from the proximal posterior tibial artery. The arteries of the foot are distal branches of the posterior tibial artery. Medial plantar is smaller and lateral plantar is the largest terminal branch of posterior tibial artery.

**Chummy S. Sinnatamby (1999)**

He has stated that the posterior tibial artery is accompanied throughout its course by a pair of venae comitantes which frequently communicate with each other around the artery. The pulsation can be palpated behind the medial malleolus, 2.5 cm in front of the medial border of the tendo calcaneus. It can

be exposed here for making an arterio – venous shunt with the great saphenous vein for haemodialysis. In arteriograms the popliteal artery may appear to have trifurcated into anterior and posterior tibial and peroneal arteries.

**William J. Zuiebel, John S. Pellerito (2000)**

They have given the percentage frequency of occurrence of the anatomical arterial variants of the lower extremity as,

- High bifurcation of the popliteal artery – 4%
- High bifurcation of the popliteal artery with peroneal arising from the anterior tibial artery - 2%
- Absence of posterior tibial artery – 1-5% may have distal reconstitution at the level of the ankle by the way of peroneal artery.

They have listed the normal level of bifurcation of the popliteal artery, with the peroneal arising from the anterior tibial artery as a rare variation.

**Robert J. Baker, Josef E. Fischer (2001)**

They have described that the popliteal artery ends at the upper border of the soleus muscle and divides into anterior tibial and tibio-peroneal trunk at the inferior border of the popliteus muscle. The tibio-peroneal trunk is the direct extension of popliteal artery which then becomes the posterior tibial artery after giving off the peroneal artery. Posterior tibial artery becomes superficial just above and posterior to medial malleolus. To gain access to the upper and middle portions of the posterior tibial artery, a skin incision is made 1-2cm postero – medially to the medial edge of the tibia just anterior to the saphenous vein.

**Jindarak S, Khobunsongserm S, Tansatit T. (2001)**

They said that the skin of the medial aspect of the leg is supplied by the cutaneous perforating branches of the posterior tibial artery and can be raised as a flap based on the main artery or perforating branches. They conducted a study in 20 cadaveric legs about the perforating branches of the posterior tibial artery and reported that the average location of the first branch was 7.35 cm from the tibial tubercle while the last branch resided 2.31cm from medial malleolus.

**Wesley S. Moore (2002)**

He has pointed out that the posterior tibial vessels are medial to the peroneal artery and veins, but also above the intermuscular septum and in the deep posterior compartment of the leg. The peroneal artery is adjacent to the medial margin of the fibula in the deep posterior compartment, lies in close proximity to the transverse crural intermuscular septum.

## **DEVELOPMENTAL ANATOMY OF LOWER LIMB VASCULATURE**

The early limb bud receives blood via intersegmental arteries that contribute to a primitive capillary plexus. At the tip of the limb bud, there is a terminal plexus which is constantly renewed in a distal direction as the limb grows. Later one main vessel, the axial artery supplies the limb and the terminal plexus. (Fig.7)

The axial artery of the lower limb arises from the dorsal root of the umbilical artery and courses along the dorsal surface of the thigh, knee and leg. Below the knee, it lies between the tibia and popliteus and in the leg it lies between the crural interosseous membrane and tibialis posterior. It gives off a perforating artery that traverses the tarsus to form a dorsal network and ends distally in a plantar network. The femoral artery passes along the ventral surface of the thigh, opening a new channel to the lower limb. It arises from a capillary plexus that is connected proximally with the femoral branches of the external iliac artery and distally with the axis artery. At the proximal border of popliteus the axis artery splits into primitive posterior tibial and peroneal branches. These run distally on the dorsal surface of the popliteus and tibialis posterior to gain the sole of the foot. At the distal border of popliteus the axis artery gives off a perforating branch that passes ventrally between the tibia and the fibula and then courses to the dorsum of the foot forming anterior tibial artery and dorsalis pedis artery. The primitive peroneal artery communicates with the axis artery at the distal border of popliteus and in its course in the leg.

The femoral artery gradually increases in size. Coincidentally, most of the axis artery disappears. However proximal to its communication with the femoral artery the root of axis artery persists as the inferior gluteal artery and the arteria comitans nervi ischiadici.

The proximal parts of the primitive posterior tibial and peroneal arteries fuse; they remain separate distally. Ultimately, much of the primitive peroneal artery disappears; however, a part of axis artery is incorporated in the permanent peroneal artery.

## **EMBRYOLOGICAL JUSTIFICATION OF THE EXISTENCE OF ARTERIAL VARIATIONS IN THE ADULT LOWER LIMB**

**H.D.Senior (1919)**

Based on the results of analysing studies of H.D senior, the anomaly depends upon the absence of one of the embryonic arteries it has been assumed, unless there is evidence to the contrary, that the absence is primary, and not due to the disappearance of a vessel once present. The a poplitea superficialis is absent, the embryonic a tibialis posterior superficialis and a peronea posterior superficialis having failed to unite in the normal manner.

Failure in the union of the roots of these tibialis posterior superficialis and peroneal posterior superficialis arteries has produced a further anomaly which affects the aa. tibialis posterior, peronea, and tibialis anterior. The a. peronea, instead of arising from the a. tibialis posterior, takes origin from the a. poplitea, while the a. tibialis anterior arises from the a. peronea.

In the absence of the a. tibialis posterior, the artery which performs the function of the missing vessel is invariably derived from the embryonic arteries which take part in the formation of the normal adult a. peronea. The persisting elements of the embryonic vessels in question are identical with those entering in to the composition of the a. peronea, and arranged in a similar order, the main artery of the posterior crural region takes the form of a large peroneal artery which, instead of ending in the leg, is continued into the sole.

The distinctive relations taken by the adult a. peronea in the successive stages of its course through the leg provide a basis for the division of this vessel into four parts. The parts are derived respectively from the four distinct embryonic elements from which the adult artery has arisen.(Fig.8a, 8b)

The parts of the adult a.peronea, and the embryonic elements which precede them are as follows:

Part I -extend from the origin of the artery to the proximal margin of the m. flexor hallucis longus. It is derived from a persisting section of the embryonic a. peronea posterior superficialis.

Part II - lies between the mm. flexor hallucis longus and tibialis posterior. It corresponds to the whole of embryonic r. communicans inferius.

Part III- lies upon the interosseous membrane and gives origin to the rr. communicans and perforans. It is derived from a short persisting section of the embryonic a. interossea.

Part IV-passes behind the lateral malleolus to the calcaneus.With the exception of a short section derived from the trunk of the embryonic a. peronea posterior superficialis , it consists of the r. calcaneus lateralis of that embryonic artery.

# **MATERIALS AND METHODS**

## **STUDY MATERIALS**

The study material consists of

- a) 40 lower limb specimens from 20 adult cadavers ( 14 males, 6 females)
- b) 10 lower limb specimens from 5 full term foetuses.
- c) 3 clinical cases.

## **METHODS OF STUDY**

### **A. Cadaveric Study**

I. Conventional dissection method.

- a) In adult specimens
- b) Foetal Specimens

II. Adult Cadaveric Angiographic study

### **B) Clinical Study**

### **C) Histological Study**

#### **A. Cadaveric study:**

##### **1. Conventional dissection method**

###### **a. Adult Specimens**

Twenty adult human cadavers were selected from the cadavers allotted to the first MBBS students and first BDS students at the Institute of Anatomy, Madras medical college, Chennai-3.

In 38 lower limbs, the redoxide with melten bull's fat was injected as a method for better identification of the branches of the posterior tibial artery.

This injecting medium was prepared by mixing the bull's fat, turpentine oil and vegetable oil in the proportion of 2:1:1. Redoxide powder was added for colouring. This mixture was loaded in a metal syringe when it was hot and in liquid form and injected into the femoral artery quickly with force. The femoral artery was exposed by making a linear, four inches length skin incision from midinguinal point, vertically downward on the thigh. A small caliber metal canula was introduced into the femoral artery. About 20 to 30ml of this injecting medium was injected into the canula and the specimen was allowed to settle down for atleast six hours before carrying out the dissection on it.

The dissection was carried out as follows:-

A longitudinal incision on the back of the leg from the heel to the popliteal fossa was made. Skin and superficial fascia were reflected. Then the deep fascia was also reflected. The flexor retinaculum was exposed postero – inferior to the medial malleolus. The two bellies of gastrocnemius were identified and separated from their attachment to the femur. Both bellies of the gastrocnemius were reflected downwards. The lower part of the popliteal vessels and tibial nerve in the popliteal fossa were exposed. The soleus was separated from its tibial attachment. It was reflected laterally along with intermuscular septum. The lower border of the popliteus was identified. The fascia was removed from the lower part of popliteal vessels and the terminal branches of popliteal artery namely the anterior tibial artery and posterior tibial artery were cleaned. Anterior tibial artery gives off at this level from popliteal artery and extended into the anterior compartment of leg. The posterior tibial artery was traced upto the flexor retinaculum. The branches of the posterior tibial artery- circumflex fibular artery, nutrient artery of the tibia, muscular branches, perforating branches, peroneal artery, medial malleolar branches, calcaneal branches and communicating branch were dissected.



During the above procedure the tibial nerve was medial to the artery in the upper part, then the nerve crossed the posterior tibial artery superficially and was on the lateral side of the artery in the middle and the lower part of the leg.

The first branch from the posterior tibial artery, circumflex fibular artery was traced from its origin laterally around the neck of the fibula and the level of its origin was noted. The nutrient artery of the tibia was dissected from the posterior tibial artery till it entered into nutrient foramen in the tibia immediately distal to the soleal line. Its origin in relation to peroneal artery was noted. Muscular branches were identified to the soleus and deep flexors of the leg. 3 to 5 perforating branches which emerged between flexor digitorum longus and soleus and passed through deep fascia were also cleaned.

The peroneal artery was identified which arose from the posterior tibial artery and traced along the back of the fibula under cover of flexor hallucis longus and the variations in its origin, course and termination were noted.

The communicating branch of posterior tibial artery which ran posteriorly across the tibia above the distal end of tibia deep to flexor hallucis longus to join with the communicating branch of peroneal artery was also dissected. Medial malleolar branches were also traced from their origin from posterior tibial artery and their numbers noted down. Just proximal to the termination of posterior tibial artery, calcaneal branches were found and was cleaned. Their origin from posterior tibial artery and from medial malleolar artery were observed and the variations were recorded.

The posterior tibial artery was dissected upto the point of bifurcation under the flexor retinaculum and the origin of medial and lateral plantar arteries, their size were also noted.

During the above dissection, the posterior tibial artery and its branches were photographed for documentation.

### **b. Foetal Specimens**

Five full term foetuses were obtained from the Institute of Obstetrics and Gynaecology, Egmore and were embalmed with 10% formalin solution. The thorax was opened by a midline incision to reach the pericardium. The metal cannula was introduced into the aorta through the left ventricle and 200 to 300 ml of embalming fluid was injected. After embalming, the foetuses were preserved in formalin solution.

In the foetus, the skin was reflected over the back of the leg from heel to the popliteal fossa. The neuro vascular bundle was identified in the popliteal fossa. The muscle mass was separated. The posterior tibial artery with its venae comitantes were identified. The relation of the tibial nerve to the posterior tibial artery was studied. The branching pattern of the posterior tibial artery was noted. During the above procedure the branches of posterior tibial artery were identified and photographed.

The findings of the observation were noted down as per the parameter taken for this study.

## **II. Adult Cadaveric Angiographic Study**

Two lower limb adult specimens were taken to radiology department Government General Hospital, Chennai -3 from institute of Anatomy, Madras Medical College, Chennai -3.

The popliteal artery was exposed at popliteal fossa. A 18 guage needle was introduced into the distal part of the artery. The popliteal artery was

ligated proximally, the urograffin solution (contrast) was injected into the artery to identify the origin, course and termination of posterior tibial artery . The entire procedure was done under fluoroscopic guidance and serial radiological pictures were taken. After angiographic study, dissection was carried out in the same specimens.

## **B. Clinical Study**

3 cases belonging to vascular surgery department, Government General Hospital, Chennai – 3, have been selected for the study with the following provisional diagnosis.

| <b>Case No.</b> | <b>Sex</b> | <b>Age</b> | <b>Diagnosis</b>  |
|-----------------|------------|------------|---|
| 1.              | Male       | 45         | Foot ulceration with peripheral vascular disease.               |
| 2.              | Male       | 37         | Thrombosis of popliteal artery with limb threatening ischaemia. |
| 3.              | Male       | 28         | Aneurysm of tibial artery due to benign bone tumour.            |

In all the above 3 cases the branching pattern of posterior tibial artery was observed by the angiographic method.

### **Angiographic Procedure:**

#### **Retrograde Femoral Artery Catheterisation:**

First the patient was put in supine position. After selecting a skin entry site with fluoroscopy and applying local anaesthesia, a small superficial skin nick was made with a No.11 blade directly over the arterial pulse. The course

of the artery was palpated while an 18 gauge needle stylet was rapidly thrust down the artery. The needle was gently advanced, when arterial blood was seen exiting from stylet hub, the hub was removed and a 0.035 inch guide wire was carefully inserted into the artery. The wire should not be forced. Now, the urograffin solution (contrast ) was injected to identify the course of the vessel and to find out the clinical problems like thrombosis, embolism, atheromatous plaque, stenosis and abnormal dilatations namely aneurysm.

The study was done by visualizing the pictures taken serially from 5 minutes after injecting the contrast. Then the popliteal artery, posterior tibial artery, peroneal artery and plantar arteries and presence of collateral channels were noted.

### **C. Histological Study**

Three bits of posterior tibial artery measuring 2 to 3 cm were taken from the lower part of the leg of the fresh cadavers and processed for histological study. The tissue section was stained with haematoxylin and eosin and was studied under a light microscope.

## **OBSERVATION**

The posterior tibial artery and its branching pattern was studied by,

- A** Conventional dissection method both in adult and foetal cadavers and adult cadaveric lower limb Angiogram.
- B** Clinical study was done by angiography.
- C** Microstructure of posterior tibial artery was also studied.

### **A. Conventional dissection method and adult cadaveric lower limb Angiogram**

40 lower limbs from adult cadaver and 10 lower limbs from foetuses were taken for study. The findings were noted and summarized as follows under the following headings.

#### **1) Origin of posterior tibial artery in relation to popliteus muscle.**

In 40 adult specimens, only in 34 specimens, the posterior tibial artery arose at the lower border of the popliteus muscle on level with the lower limit of the tubercle of tibia from popliteal artery. In 3 specimens, the origin was above the lower border of popliteus muscle.

In one specimen, the origin of posterior tibial artery was just below the lower border of popliteus muscle.

In 2 specimens, the popliteal artery at the lower border of popliteus muscle had given of 2 branches. One of the branch passed through a gap above the interosseous membrane and appeared in the anterior compartment of leg.

Another branch from its origin from popliteal artery coursed more laterally and entered deep to flexor hallucis longus.

In 9 foetal limbs, the posterior tibial artery arose from the popliteal artery at the level of lower border of popliteus muscle. In one specimen, the popliteal artery at the lower border of popliteus had given two branches. One anterior tibial artery passed through a gap above the interosseous membrane and appeared in the anterior compartment of leg. Another branch from its origin from the popliteal artery course more laterally and entered deep to flexor hallucis longus. (Table-I)

## **2) Course and mode of termination of the posterior tibial artery**

The posterior tibial artery after its origin, entered under cover of the tendinous arch of the origin of soleus and passed downward upon the tibialis posterior, flexor digitorum longus in 34 adult specimens. It was accompanied throughout its course by a pair of venae comitantes.

In the upper 2/3, the artery was superficially covered by the soleus, deep to it was the tibialis posterior, flexor digitorum longus and posterior surface of tibia. In the lower 1/3 of the leg, the artery was superficial, related to the medial border of tendo calcaneus. Then it passed deep to flexor retinaculum where it terminated by dividing into medial and lateral plantar arteries.

In other 6 specimens, the course of posterior tibial artery was different. Out of this 6, in 2 specimens after giving peroneal artery, the posterior tibial artery was very small in size and passed more medially and after giving a communicating branch to peroneal artery, the posterior tibial artery ended by giving smaller branches to muscles and skin.

In 2 specimens, the posterior tibial artery was very smaller in size, after giving the peroneal artery and passed downwards between tibialis posterior and flexor digitorum longus and finally joined with the peroneal artery.

In 2 specimens, the only artery present in the posterior compartment of leg, extended downwards and laterally and descended along the medial crest of fibula within the flexor hallucis longus. Just above the ankle joint, it deviated to medial side and passed beneath the flexor retinaculum and then terminated into two plantar arteries. This should be considered as a peroneal artery with the absence of posterior tibial artery.

In 9 foetal limbs, the posterior tibial artery after its origin passed medially under cover of the tendinous arch in the origin of soleus and extended downwards between tibialis posterior and flexor digitorum longus. Throughout its course, accompanied by a pair of vanae comitantes. In the lower part of the leg, it was related to the medial border of the tendocalcaneus. Then it passed deep to flexor retinaculum where it terminated by dividing into medial and lateral plantar arteries.

In one case, one of the terminal branches of popliteal artery which entered deep to flexor hallucis longus muscle and travelled along the medial crest of fibula deep to flexor hallucis longus. Then this artery deviated to medial side and passed deep to flexor retinaculum, where it divided into plantar arteries. Since this artery related to the crest of fibula and had a more lateral course, this was considered as peroneal artery and in this case the posterior tibial artery was absent. (Table -II)

### **3) Level of bifurcation of posterior tibial artery into medial and lateral plantar arteries.**

In 40 adult specimens, only in 34 specimens, the posterior tibial artery bifurcated into medial and lateral plantar arteries. Out of this 34 specimens, in 32 specimens the posterior tibial artery bifurcated into medial and lateral plantar arteries beneath the flexor retinaculum midway between medial malleolus and medial tubercle of calcaneum.

In 2 specimens, the posterior tibial artery bifurcated into medial and lateral plantar arteries at a lower level under abductor hallucis muscle in the sole.

In the remaining 6 cases, in 2 specimens the posterior tibial artery terminated at a higher level by giving small muscular branches. In 2 cases, the posterior tibial artery terminated by joining with the peroneal artery. In another 2 cases the posterior tibial artery was replaced by peroneal artery.

In 9 foetal limbs, the posterior tibial artery bifurcated into medial and lateral plantar arteries under the flexor retinaculum. In one foetal specimen, the posterior tibial artery was absent and was replaced by peroneal artery which divided into medial and lateral plantar arteries. (Table –III)

### **4) Relation of posterior tibial artery to tibial nerve**

In 38 specimens, the tibial nerve was on the medial side of posterior tibial artery in the upper part of the leg, then it crossed superficially to the posterior tibial artery and descended along the lateral side of the posterior tibial artery in the middle and the lower part of the leg. In 2 cases, where the



posterior tibial artery was absent and was replaced by peroneal artery, so the tibial nerve was medial to the peroneal artery .

In 9 foetal specimens dissected the tibial nerve was on the medial side of the upper part of the posterior tibial artery, then it crossed the artery from medial to lateral side superficially. Then it descended along the lateral side of posterior tibial artery in the middle and the lower part of the leg. In one foetal specimen, the posterior tibial artery was absent, the peroneal artery was present in the posterior compartment. The tibial nerve was medial to the peroneal artery.

## **5) Branches**

In 40 specimens, the circumflex fibular artery, nutrient artery of the tibia, muscular branches, perforating branches, peroneal artery, communicating branch, medial malleolar branches, calcaneal branches and the terminal branches- medial and lateral plantar arteries were studied.

### **a) Circumflex Fibular Artery**

In 38 adult specimens, the circumflex fibular artery arose from posterior tibial artery near its origin. Then it runs laterally around the neck of the fibula through the fibres of soleus and anastomoses with the lateral inferior genicular artery .(Table-IV)

In 2 specimens, the circumflex fibular artery arose from the peroneal artery.

In 9 foetal specimens, it arose from the posterior tibial artery, near its commencement. In one specimen the posterior tibial artery was absent, circumflex fibular artery was found to arise from the peroneal artery.

#### **b) Nutrient branch of tibia**

In 35 adult specimens, the nutrient artery of the tibia arose from posterior tibial artery from 1.5 to 3.5 cm distance below the lower border of popliteus in the upper third of the tibia. Then it passed through the substance of the tibialis posterior and entered into the nutrient foramen on the posterior surface of tibia. (Table –V)

In 3 specimens, the nutrient branch arose from the posterior tibial artery below the origin of peroneal artery in the middle third of tibia.

In 2 specimens, the nutrient artery arose from the peroneal artery in the middle part of the tibia.

In 9 foetal specimens, the nutrient artery arose from the posterior tibial artery below the lower border of popliteus in the upper third of tibia, then it passed through the tibialis posterior and entered into the nutrient foramen on the posterior surface of tibia. In one case, the nutrient artery arose directly from the peroneal artery.

#### **c. Muscular branches**

In 38 adult specimens, the posterior tibial artery gave muscular branches to soleus and deep flexors of the leg. i.e tibialis posterior, flexor digitorum longus and flexor hallucis longus.

In 2 specimens, muscular branches were given off from the peroneal artery.

In 9 foetal specimens muscular branches to soleus and deep flexors of the leg arose from the posterior tibial artery. In one specimen, muscular branches arose from peroneal artery in the absence of posterior tibial artery.

**d) Perforating branches**

In 35 adult specimens, (92.5%) 3 to 5 perforating fasciocutaneous branches arose from posterior tibial artery which pierced soleus, deep fascia and supplied the skin. Mostly these were located in the middle two quarters of the leg. The distance of the last perforating branch in the middle two quarters of the leg from medial malleolus was measured and recorded in Table VI. The last branch was located at an average of 18.9 cm from the medial malleolus.

In 3 cases (7.5%) five and more perforating branches arose from the posterior tibial artery and these were located in the proximal, middle and distal third of the leg. The distance of the last perforating branch in the distal third of the leg from the medial malleolus was measured and tabulated in Table VII. The last branch was located at an average of 2.4 cm from the medial malleolus. In 2 cases (5%), the perforating branches (3-5) arose from the peroneal artery. In foetus, very slender perforating branches were observed.

**5) e) Peroneal artery**

**i) Origin of peroneal artery**

In 2 adult specimens, the peroneal artery was directly arising from the popliteal artery with the absence of posterior tibial artery. In 38 adult specimens, the peroneal artery was directly from the posterior tibial artery.

In 9 foetal specimens, the peroneal artery arose from the posterior tibial artery. In one case, the peroneal artery replaced the posterior tibial artery, directly arose from the popliteal artery.(Table – VIII)

**ii) Distance of origin of peroneal artery from the commencement of posterior tibial artery.**

Usually the peroneal artery arises from the posterior tibial artery 2.5 cm below the lower border of popliteus. The distance of origin of peroneal artery was measured and recorded in Table IX. The distance varied from 2cms to 7.2cms. The average distance was 3.4cms.

Out of 38 adult specimens, the distance varied from 2-3cm in 19 specimens(50%), varied from 3-4cm in 10 specimens(26.3%), varied from 4-5 cm in 8 specimens(21.1%), from 7-8 cm in one specimen(2.6%). (Table-X)

In 9 foetal specimens, the peroneal artery arose from posterior tibial artery with the distance varied from 1-1.7cm from the commencement of posterior tibial artery. The distance of origin of peroneal artery was measured. All the measurements were recorded in Table XI. In one specimen, the peroneal artery was the direct continuation of the popliteal artery where the posterior tibial artery was absent.

**iii) Course and termination of peroneal artery**

Usually peroneal artery inclines downwards and laterally, then descends along the medial crest of the fibula, lying between flexor hallucis longus and tibialis posterior or within the flexor hallucis longus. At the inferior tibio fibular syndesmosis, it terminates by dividing into perforating and lateral calcaneal branches.

In 34 adult specimens, the peroneal artery descended laterally and terminated by dividing into perforating and lateral calcaneal branches.

In 4 specimens, the peroneal artery was enlarged in size and replaced the posterior tibial artery in the distal leg and foot. Out of these cases, the

posterior tibial artery took more medial course and terminated at a higher level by giving small muscular branches in 2 cases and posterior tibial artery was smaller in size and ended by communicating with peroneal artery in 2 cases.

In 2 specimens, the peroneal artery was present as the direct continuation of popliteal artery along the medial crest of the fibula. After giving perforating branch it deviated to medial side, then passed behind the flexor retinaculum and finally divided into medial and lateral plantar arteries.

In 9 foetal specimens, the peroneal artery descended laterally and terminated into calcaneal branches. In one specimen, it was enlarged in size and deviated from lateral to medial side and passed behind the flexor retinaculum and divided into medial and lateral plantar arteries. (Table –XII)

#### **5)f) Communicating Branch**

Normally, the communicating branch arises proximal to the ankle joint, usually 5cm above the medial malleolus. It passes laterally deep to the tendon of flexor hallucis longus and anastomoses with a corresponding branch of the peroneal artery.

In 34 adult specimens, the communicating branch arose from posterior tibial artery. In 6 specimens, the peroneal artery replaced the posterior tibial artery. The distance of origin of communicating branch from posterior tibial artery was measured from medial malleolus and recorded in Table XIII. The distance varied from 2.5 to 5.5 cm. The average distance was 4.4cm.

In 9 foetal specimens, communicating branch arose from the posterior tibial artery just above the medial malleolus. In one specimen, the posterior tibial artery was replaced by peroneal artery.

#### **g) Medial malleolar branches**

In 20 adult specimens, two medial malleolar branches were found to be arising from posterior tibial artery. In 14 specimens, it was single. In 4 cases in which the peroneal artery replaced the posterior tibial artery in the distal part of leg and foot, medial malleolar branch arose from the peroneal artery. In 2 specimens in which the posterior tibial artery was replaced by peroneal artery, medial malleolar branches arose from peroneal artery. (Table XIV)

In 9 foetal specimens, the medial malleolar branch was very slender and arose from posterior tibial artery. In one specimen, this slender branch arose from peroneal artery.

#### **h) Calcaneal branches**

In 34 adult specimens, calcaneal branches arose just proximal to the terminal division of the posterior tibial artery. They pierced the flexor retinaculum and passed to the calcaneal network.

In 4 specimens, in which the posterior tibial artery was replaced distally by peroneal artery, calcaneal branches arose from the peroneal artery. In 2 specimens in which the posterior tibial artery was absent and replaced by peroneal artery, calcaneal branches arose from peroneal artery.

In 9 foetal specimens, the calcaneal branches arose from posterior tibial artery just proximal to the terminal division of the posterior tibial artery. In one specimen, calcaneal branches arose from peroneal artery .

**j) Terminal branches – medial and lateral plantar arteries**

In 32 adult specimens, the medial plantar artery was smaller in size than the lateral plantar artery. In 2 specimens, the medial and lateral plantar arteries were equal in size.

In 4 specimens in which the peroneal artery replaced the posterior tibial artery distally, the medial plantar artery was smaller in size than the lateral plantar artery.

In 2 specimens, in which the peroneal artery replaced the posterior tibial artery, the medial plantar artery was smaller in size than the lateral plantar artery.

In 9 foetal specimens, the posterior tibial artery was terminated by dividing into medial and lateral plantar arteries. In this cases medial plantar artery was smaller in size than the lateral plantar artery. In one case in which the posterior tibial artery was replaced by peroneal artery, medial plantar and lateral plantar arteries are equal in size.(Table XV)

**B. Clinical Study**

For clinical study, three clinical cases were selected from vascular surgery department, Government General Hospital, Chennai -3 between the age group of 25-45 years with the history of chain smoking and diabetes for the past 10 years.

| <b>S.No</b> | <b>Sex</b> | <b>Age</b> | <b>Diagnosis</b>  |
|-------------|------------|------------|---|
| 1           | Male       | 45         | Foot ulceration with peripheral vascular disease.               |
| 2           | Male       | 37         | Thrombosis of popliteal artery with limb threatening ischaemia. |
| 3           | Male       | 28         | Aneurysm of tibial artery due to benign bone tumour.            |

For the above cases an investigative procedure femoral arteriogram was done. In case no.1. popliteal artery and patent origin of anterior and posterior tibial and peroneal arteries were observed. In case no.2, thrombosis of popliteal artery with limb threatening ischaemia was observed. In case no.3, aneurysm of tibial artery caused by benign bone tumour was made out. (Fig.9,10, &11)

### **C. Histological Study**

Three bits of posterior tibial artery measuring 2 to 3 cm were taken from the lower part of the leg. They were processed, sectioned and stained with haematoxylin and eosin and studied under a light microscope.

It was observed that the posterior tibial artery was surrounded on all sides by connective tissue. In the arterial wall an inner dark sinuous line was seen which represents the internal elastic lamina and inner to that endothelial layer was thin and endothelial cells were irregular and polygonal. Outer to the internal elastic lamina, a broad pale band was seen which consists of plain muscular tissue, disposed circularly around the artery and few circular elastic fibres running parallel to the lumen of the vessel. Outer to this muscular coat, a broad deeply stained band, largely composed of elastic tissue.



## DISCUSSION

The branching pattern and the variations of posterior tibial artery was studied.

### **A.Cadaveric Study**

#### **1. Origin of posterior tibial artery in relation to popliteus muscle.**

In the present study, posterior tibial artery was present in 94% of cases and it was absent in 6% of cases.

**Henry Gray (1858), George.A. Piersol (1930), Thomas Walmsley(1934), J.E. Frazer (1937), J.C.B. Grant (1951), J. Parsons schaffer(1953), Russell T. Woodburne(1961), Roger warwick (1963), G.J.Romanes (1964), Keith.L.Moore(1980), Ronan O' Rahilly (1986) and Robert J.Baker,Josef E.Fischer (2001)** have quoted that the posterior tibial artery arose from the popliteal artery at the lower border of the popliteus muscle.

In the present study, the posterior tibial artery arose from the popliteal artery at the lower border of popliteus in 86% which coincides with the statement of above scientists. But they have not mentioned any statistical data about the incidence.

**Trotter, M. (1940)** found the origin of posterior tibial artery above the upper border of popliteus muscle in 4.9% of 246 extremities from white persons and 6.2% of 338 extremities from Negro persons. In the present study, the origin of posterior tibial artery above the upper border of popliteus was not observed.

**Barry J.Anson, Chester B. Mcvay (1971), C.Latimer Callender (1939)** have said that the posterior tibial artery arose from the popliteal artery

distal to the ring in the soleus muscle. But the incidence was not mentioned. In the present study, in 2% of cases the posterior tibial artery was below the lower border of popliteus.

**Quain,R. (1844), Hyrtl J (1864), George A. Piersol (1930), Sir Solly Zuckerman (1961), G.J. Romanes (1964)** have observed that the origin of the posterior tibial artery from the popliteal artery was above the lower border of popliteus muscle.

**Parsons,F.G. and Robinson,A. (1898 )**reported that in 8.2% of cases, the posterior tibial artery divided more than 0.5 inch ((1.3cm) above the lower border of the popliteus muscle.

**Adachi, B. (1928)** gave the incidence of high level origin of posterior tibial artery in 2.8% of his study in 770 limbs.

**J.A.Keen (1961)** reported that the high division of popliteal artery into posterior tibial artery and anterior tibial artery in 5% of his study in 280 limbs.

**William J. Zwiebel , John S.Pellerito (2000)** gave a report that 4% of high bifurcation of the popliteal artery into posterior tibial artery and anterior tibial artery.

In the present study, in 6% of cases, the posterior tibial artery arose from the popliteal artery above the lower border of popliteus muscle (high origin). This observation almost coincides with that of J. A. Keen (1961) and less than the incidence of 8.2% mentioned by Parsons,F.G. and Robinson,A. (1898) and higher than the incidence of 4% and 2.8% mentioned by William J. Zwiebel, John S. Pellerito (2000) and Adachi B (1928) respectively (Table- 1D).

## 2. Course and mode of termination of posterior tibial artery.

**Henry Gray (1858), George A. Piersol (1930), J.E. Frazer(1937), J. Parsons schaffer (1953), J.D.Boyd et al (1956), Russell T.Woodburne(1961)** have mentioned that the posterior tibial artery ran downward and medially and terminated by dividing into medial and lateral plantar arteries under flexor retinaculum.

In the present study, 86% of posterior tibial artery passed downward and medially and terminated by dividing into medial and lateral plantar arteries under flexor retinaculum. This observation coincides with the statement of the above scientist but they have not mentioned the incidence.

**Henry Gray (1858)** said that the posterior tibial artery was much reduced in length and in caliber . The peroneal artery then took over its distal territory and was consequently increased in size.

**J.E. Frazer (1937)** said that the posterior tibial artery does not extend to the ankle and may be entirely absent, in which cases the deficiency is made good by an enlarged peroneal artery.

In the present study, in 4% of cases the posterior tibial artery was very smaller in size and divided into small muscular branches at a high level and did not extend upto ankle joint. The peroneal artery took over its distal territory . Hence regarding this course of posterior tibial artery, this study coincides with Henry Gray andJ.E.Frazer.

**George A. Piersol (1930)** observed that the posterior tibial artery may terminate by inosculating with the peroneal artery by the enlargement of the communicating branch and he also reported that it may be represented by a small vessel whose distribution is confined to the upper part of the leg.

**J.E.Frazer (1937)** said that the posterior tibial artery may be much diminished in size and in such cases the peroneal artery is relatively increased and by means of an enlarged communicating branch conveys blood to the distal end of the posterior tibial artery.

In the present study, in 4% of cases the posterior tibial artery was very smaller in size after giving peroneal artery and joined with the peroneal artery as a communicating branch. This observation coincides with that of George A Piersol and J.E. Frazar.

**Huber, J.F. (1941)** reported that in 2.5% of cases the posterior tibial artery was replaced by peroneal artery.

**J.A.Keen (1961)** observed that in 2.5% of cases the posterior tibial artery was replaced by peroneal artery.

**Berish Strauch et al (1993)** reported that in 8% of cases the peroneal artery takes the place of the posterior tibial artery.

**Piral T.et al (1996)** reported that the absence of posterior tibial artery in 1 to 5% of cases.

**William J. Zwibel , John S. Pellerito (2000)** observed that the absence of posterior tibial artery in 1-5% cases.

In the present study, in 6% of cases the posterior tibial artery was absent and the only artery in the posterior compartment of leg was peroneal artery which replaced the posterior tibial artery. This study coincides with the study of Piral T. et al and William J. Zwibel , John S. Pellerito and less than the

incidence of 8% mentioned by Berish strauch et al and higher than the incidence of 2.5% mentioned by Huber J.F. and J.A. Keen (Table- 2D).

### **3. Level of bifurcation of posterior tibial artery into medial and lateral plantar arteries.**

**Ronan O' Rahilly (1986), Earnest Gardner et al (1967), Samerendra mitra (1973)** said that the posterior tibial artery terminated deep to flexor retinaculum and abductor hallucis.

**J.E.Frazer (1937)** said that the level at which the posterior tibial artery divided into two plantar arteries was variable.

**J.C.B.Grant (1951), John V. Basmajian (1980), Keith L.Moore (1980), Richard S. Snell (1995)** have reported that the posterior tibial artery terminated under the flexor retinaculum into medial and lateral plantar arteries.

In the present study, in 82 % of cases the posterior tibial artery bifurcated into medial and lateral plantar arteries under flexor retinaculum. This observation coincides with J.C.B.Grant, John.V. Basmajian, Keith L. Moore and Richard S. Snell.

**R.D. Lockhart et al (1959)** said that the posterior tibial artery bifurcated into medial and lateral plantar arteries deep to abductor hallucis muscle.

In the present study, in 4% of cases, the posterior tibial artery bifurcated into medial and lateral plantar arteries deep to abductor hallucis muscle which coincides with the study of R.D. Lockhart et al.

#### **4. Relation of posterior tibial artery to tibial nerve**

**Henry Gray (1858)** said that the tibial nerve was at first medial to the artery but soon crossed behind the posterior tibial artery and subsequently become largely posterolateral.

**George A. Piersol (1930), Thomas Walmsley (1934), J.C.B. Grant (1951), W. Henry Hollinshead (1969), Ronan O' Rahilly (1986)** have reported that the tibial nerve at first was medial to the posterior tibial artery, then crossed the artery and was on its lateral side throughout the length of the leg.

**J.E. Frazer (1937), F. Wood Jones (1953)** said that the posterior tibial nerve crossed the vessel superficially just below the origin of the peroneal artery and was on its outer side for the rest of its course.

**G.J. Romanes (1964)** said that the posterior tibial artery was crossed by the tibial nerve about an inch distal to its origin.

In the present study, the tibial nerve superficially crossed the posterior tibial artery and was related to the lateral side of the posterior tibial artery in 94% of cases which is similar to the relation described by Henry Gray, George A. Piersol, Thomas Walmsley, J.C.B. Grant, Donald J. Gray, W. Henry Hollinshead and Ronan O' Rahilly.

In 6% of cases, the posterior tibial artery was replaced by the peroneal artery and the tibial nerve was related to the medial side of peroneal artery.

#### **5. Branches**

##### **a) Circumflex Fibular artery**

**R.D. Lockhart et al (1959), Earnest Gardner et al (1967), Keith L. Moore (1980), Ronan O' Rahilly (1986), Chummy S. Sinnatamby (1999)**

said that the circumflex fibular artery arose from the posterior tibial artery near its origin and passed laterally over the neck of the fibula to join the arterial anastomosis around the knee joint.

In the present study, in 94% of cases, the circumflex fibular artery arose from the posterior tibial artery near its origin. This finding coincides with the above authors. In 6% of cases, the circumflex fibular artery arose from the peroneal artery which was not reported by any of the authors.

**Henry Gray (1858), J.C.B. Grant (1951), Parsons Schaffer (1953), G.J. Romanes (1964), W. Henry Hollinshead (1969), Ronan Uflacker (1997)** reported that in some cases the circumflex fibular artery may arise from the anterior tibial artery.

**J.C.B. Grant (1951), W. Henry Hollinshead (1969)** reported that the origin of circumflex fibular artery was from the popliteal artery.

In the present study, the origin of circumflex fibular artery from the anterior tibial artery or popliteal artery was not observed.

#### **b) Nutrient artery of the tibia**

**Henry Gray (1858), Thomas Walmsley (1934), J.C.B. Grant (1951), G.J. Romanes (1964), W. Henry Hollinshead (1969), Keith L. Moore (1980), Ronan Uflacker (1997) and Chummy S. Sinnatamby (1999)**, reported that the nutrient artery of the tibia arose from the proximal part of the posterior tibial artery and pierced the tibialis posterior and entered into the nutrient foramen on the posterior surface of the bone.

**Hallock GG et al (1993)** observed that the nutrient artery of the tibia may be from the posterior tibial artery or anterior tibial artery or popliteal bifurcation. He also mentioned that in 85% of cases, the nutrient artery was discovered in the upper 3<sup>rd</sup> of tibia.

In the present study, in 88% of cases the nutrient artery of the tibia arose from the proximal part of the posterior tibial artery in the upper part of tibia. This findings coincide with the above authors. This observation is similar to the observation made by Hallock GG et al (Table - 3D).

**George A. Piersol (1930)** said that the nutrient artery arose from the posterior tibial artery either above or below the origin of the peroneal artery and sometimes it arose from the peroneal artery.

In the present study, in 6% of cases, the nutrient artery of the tibia arose from the posterior tibial artery below the origin of the peroneal artery. In 6% of cases, the nutrient artery of the tibia arose from the peroneal artery in the absence of posterior tibial artery. This study coincides with the study of George A. Piersol.

#### **c) Muscular branches.**

**Henry Gray (1858), George .A. Piersol (1930), J.E. Frazer (1937), J.C.B. Grant (1951), F. Wood Jones (1953), Henry Hollinshead (1969)** reported that the posterior tibial artery gave muscular branches to soleus, tibialis posterior, flexor digitorum longus and flexor hallucis longus muscle.

In the present study, muscular branches from the posterior tibial artery were observed in 94% of cases . In 6% of cases, the muscular branches arose from the peroneal artery.

#### **d)Perforating branches**

**J.C.B. Grant (1951), R. Kanagasuntheram et al (1987), Henry Gray (2005)** reported that approximately five fasciocutaneous perforators emerge between flexor digitorum longus and soleus and supply the skin of posterior part of leg.



**Roger Warwick (1963)** said that the posterior tibial artery gave numerous cutaneous branches.

**Berish Strauch et al (1993)** have mentioned that the posterior tibial artery gave about four or more septocutaneous branches along the medial border of tibia.

In the present study, in 92.5% of cases 3-5 fasciocutaneous perforators from posterior tibial artery present in the upper and middle third of the leg and supplied the skin of posterior part of the leg which coincides with the study of J.C.B. Grant, R. Kanagasuntheram et al, Henry Gray and Berish Strauch et al.

**Hung LK et al (1996)** reported that cutaneous perforators of posterior tibial artery were located in the middle two quarters of the leg. The last branch located at an average of 18.6 cm from the medial malleolus.

In the present study, the last branch in the middle third of leg located at an average of 18.9cm from the medial malleolus. This observation coincides with the observation made by Hung LK et al (Table - 4D).

**Wu WC, Chang YP et al (1994)** described that the cutaneous perforators were distributed from the distal to the proximal sides of the lower leg through the medial border of the tibia.

**Jindarak. S et al (2001)** reported that the perforating branches of posterior tibial artery were located from proximal to the distal third of legs and last branch was located 2.3 cm from the medial malleolus. .

In the present study, in 7.5% of cases more than 5 fasciocutaneous perforators were present in the upper, middle and lower third of the leg which is similar to the observation of Wu,WC,Chang YP et al, and Jindarak. S et al. The last branch was located at an average of 2.4cm from medial malleolus in

the present study and this coincides with the observation made by Jindarak.S et al (Table- 5D).

#### **e) Peroneal Artery**

##### **1) Origin of Peroneal artery.**

**J.E.Frazer (1937), J. Parsons Schaffer (1953), Russell T. Woodburne (1961) and Sir John Bruce et al (1964)** said that the peroneal artery arises from the posterior tibial artery.

**Berish Strauch et al (1993)** reported that the peroneal artery arises from posterior tibial artery in 90% of cases.

In the present study, in 94% of cases the peroneal artery arose from the posterior tibial artery which coincides with the study of the above authors. The incidence of origin of peroneal artery from posterior tibial artery is almost same as the observation of Berish Strauch et al (Table - 6D).

**Hyrtil.J.(1864)** said that the peroneal artery arises from the popliteal artery with the absence of posterior tibial artery .

**J.E.Frazer (1937)** observed that the peroneal artery may be at a higher level in which case it may be a branch of popliteal artery.

**G.J. Romanes (1964)** said that the popliteal artery may divide into anterior tibial and peroneal arteries.

**Berish Strauch et al (1993)** reported that the peroneal artery takes the place of the posterior tibial artery in 8% of cases.

**Renan Uflacker (1997)** said that the peroneal artery may arise directly from the popliteal artery.

In the present study, in 6% of cases the peroneal artery was found to be directly coming from the popliteal artery with the absence of posterior tibial artery. This study coincides with the study of above scientists. The incidence of occurrence is little less than the observation made by Berish Strauch et al (Table - 7D).

**Henry Gray (1858)** said that the peroneal artery may branch from popliteal artery separately, giving a true trifurcation .

**J.A.Keen(1961)** reported that trifurcation of the popliteal artery was seen 12 times in his studies (5%).

**G.J. Romanes (1964), Samarendra mitra (1973)** said that the popliteal artery may divide into anterior and posterior tibial and peroneal arteries.

In the present study, the origin of peroneal artery directly from the popliteal artery with anterior tibial artery and posterior tibial artery (trifurcation of popliteal artery) was not observed in any case.

## **2) Distance of origin of peroneal artery from the commencement of posterior tibial artery**

**J.E.Frazer (1937), C.Latimer Callander (1939), Trotter, M. (1940), G.J.Romanes (1964), Maurice Arnold (1968), Berry J. Anson, Chester B.McVay (1971)** said that the peroneal artery arises from the posterior tibial artery 2.5 cm (1 inch) distal to the commencement of posterior tibial artery.

**Russel T. Woodburne (1961), Keith L. Moore (1980)** observed that the distance of origin of peroneal artery was 2-3cm.

**Berish Strauch et al (1993)** reported that the peroneal artery arises from the posterior tibial artery about 3cm below the lower border of popliteus.

In the present study, in (50%) 19 adult specimens the distance of origin of peroneal artery from posterior tibial artery was 2-3cm. This observation coincides with the above authors observation . This observed value exactly coincides with the observation made by Russel T. Wood burne, Keith L Moore, and Berish Strauch et al.

**Harold Ellis (1980)** reported that the posterior tibial artery gives off the peroneal artery about 1.5 inch (4cm) from its origin.

In the present study, in (26.3%) 10 adult specimens the distance of origin of peroneal artery from posterior tibial artery was 3-4 cm. This observation coincides with Harold Ellis observation.

**Thomas Walmsley(1934)** said that the peroneal artery sometimes arises from the posterior tibial artery about 2 inches (5cm) below the popliteus muscle.

In the present study, in (21.1%) 8 adult specimens the distance of origin of peroneal artery from posterior tibial artery was 4-5 cm. This finding coincides with Thomas Walmsley.

**Henry Gray (1858)** said that the peroneal artery may branch more distally from the posterior tibial artery, 7-8 cm distal to popliteus.

In the present study, in (2.6%) one adult specimen the distance of origin of peroneal artery from posterior tibial artery was 7.2 cm, This observation coincides with the observation made by Henry Gray (Table- 8D).

In 2 adult specimens, the posterior tibial artery was absent

In 10 foetal specimens studied, the posterior tibial artery was absent in one specimen and in 9 specimens the distance of origin of peroneal artery ranges from 1 – 1.7 cm from the commencement of posterior tibial artery.

### **3) Course and termination of peroneal artery**

**Thomas Walmsley (1934), J. Parson Schaffer (1953), Sir John Bruce et al (1964), Ben pansky et al (1964), M. prives et al (1985) and Wesley S. Moore (2002)** said that the peroneal artery descended along the medial crest of fibula within the flexor hallucis longus and terminated by dividing into lateral calcaneal branches.

In the present study, in 86% of cases peroneal artery descended laterally and terminated by dividing into lateral calcaneal branches. This study coincides with the study of above authors.

**Henry Gray (1858), Hyrtl.T (1864), H.D. Senior (1929), J.E. Frazer (1937), Henry Hollinshead (1969) , Poratt D. et al (1994), and Richard S. Snell (1995)** described that the peroneal artery was enlarged sometimes and continued into the sole and replaced the posterior tibial artery in the distal leg and foot.

In the present study, in 8% of cases the peroneal artery was enlarged in size and replaced the posterior tibial artery in the distal leg and foot which coincides with the above authors work.

**Huber (1941), J.A. Keen (1961)** reported that the peroneal artery replaced the posterior tibial artery in 2.5% cases.

**Piral T et al (1996), J. Zwiabel (2000)** observed that the posterior tibial artery is absent in 1-5% cases .

**Berish strauch et al (1993)** reported that in 8% of cases peroneal artery takes the place of posterior tibial artery.

In the present study, in 6% of cases the peroneal artery was larger and terminated by dividing into medial and lateral plantar arteries in the absence of

posterior tibial artery. Regarding this, the present study coincides with Piral T et al and J. Zwiabel and higher than the incidence of 2.5% mentioned by Huber and J.A. Keen and lesser than the incidence of 8% mentioned by Berish Strauch et al. (Table - 2D)

#### **f) Communicating branch**

**Henry Gray (1858), J. Parsons Schaffer (1953)** said that the communicating branch to peroneal artery arose from posterior tibial artery 5 cm above the medial malleolus.

**J.C.B. Grant (1951), G.J. Romanes (1964)** observed that the communicating branch united the posterior tibial artery to peroneal artery about 2.5cm above the inferior tibio-fibular syndesmosis.

In the present study, in 34 adult specimens, the distance of origin of communicating branch from posterior tibial artery varied from 2.5 to 5.5 cm from medial malleolus, the average being 4.4 cm which coincides with the observation made by Henry Gray and J. Parsons Schaffer, but higher than the distance of 2.5cm mentioned by J.C.B. Grant and G.J. Romanes.(Table - 9D)

In 6 adult specimens, peroneal artery replaced the posterior tibial artery .

In 9 foetal specimens, the communicating branch from posterior tibial artery arose just above the medial malleolus. In one specimen, posterior tibial artery was replaced by peroneal artery.

#### **g) Medial malleolar branches**

**George A.. Piersol (1930), J.C. B.Grant (1951), J. Parsons Schaffer (1953), Russell T. Wood burne (1961), G.J. Romanes (1964)** said that the posterior tibial artery gave single medial malleolar branch.

In the present study, in 66% of cases the posterior tibial artery gave off single medial malleolar branch near the ankle joint, which coincides with the above scientists.

**Henry Gray (1858), J.E. Frazer (1937), F.wood Jones (1953), Renan Uflacker (1997)** said that the medial malleolar branches from posterior tibial artery passed around the tibial malleolus to the medial malleolar network.

**Earnest Gardner et al (1967), W. Henry Hollinshead (1969), Ronan O' Rahilly (1986)** said that the posterior tibial artery gave off one or more medial malleolar branches.

In the present study , in 20% of cases, the posterior tibial artery gave off more than one medial malleolar branch . This observation coincides with Earnest Gardner et al, W. Henry Hollinshead and Ronan O' Rahilly.

In the present study, in 14% of cases the medial malleolar branches also arose from peroneal artery which replaced the posterior tibial artery.

#### **h) Medial calcaneal branches**

**Henry Gray (1858), George A. Piersol (1930), J.C.B.Grant (1951), Parsons Schaffer ( 1953), Russell T. Woodburne (1961), G.J. Romanes (1964), W. Henry Hollinshead (1969)** said that the posterior tibial artery gave off one or more medial calcaneal branches just proximal to the terminal division of the posterior tibial artery.

In the present study, in 86% of cases (43 specimens) the medial calcaneal branches arose just proximal to the terminal division of the posterior tibial artery. This is similar to the findings of above scientists.

In the present study, in 7 specimens the medial calcaneal branches arose from peroneal artery. Out of this 7 specimens, in 3 specimens the posterior

tibial artery was absent, in 2 specimens there is high level termination of posterior tibial artery and in 2 specimens the posterior tibial artery joined with peroneal artery by a communicating branch above medial malleolus.

**Earnest Gardner et al (1967), Ronan O' Rahilly (1986)** said that the medial calcaneal branches arose from the medial malleolar branch which was from posterior tibial artery.

In the present study, this observation was not found in any of the specimens.

**i) Terminal branches of posterior tibial artery - medial and lateral plantar arteries.**

**Henry Gray (1858), George A. Piersol (1930), J.C.B. Grant (1951), G.J. Romanes (1964)** said that the medial plantar artery was smaller than the lateral plantar artery.

**David Harvey (1990)** observed that the lateral plantar artery was significantly larger than the medial plantar artery in 80% cases.

In the present study, in 82% of cases, the medial plantar artery was smaller in size than the lateral plantar artery. This study is similar to the study of above authors. This observation coincides with the observation made by David Harvey. (Table 10D)

In 4% of cases, bulk of lateral and medial plantar arteries were equal in size which was not reported by any of the authors.

In 14% of cases, the medial and lateral plantar arteries were from the peroneal artery.



## **B. Clinical Study**

3 clinical cases were studied in which along the general investigative procedures, specific investigation, the femoral arteriogram (Angiogram) was done. With the help of angiograms, it was observed that the posterior tibial artery arose from popliteal artery in all 3 cases and peroneal artery arising from the posterior tibial artery and other branches of posterior tibial artery were also visualised.

## **C. Histological Study**

**E.A. Schafer (1912)** observed that the posterior tibial artery which consist of a dark sinuous internal elastic lamina. Outer to that, broad pale muscular coat composed of concentrically arranged muscular fibres with few elastic fibres. Outside this, a deeply stained broad tunica adventitia contain elastic fibres. External to that loose connective tissue surrounds the artery.

In the present study, it was observed that the posterior tibial artery was surrounded by loose connective tissue and composed of from inner to outer a dark sinuous internal elastic lamina, broad pale muscular coat and outermost deeply stained broad tunica adventitia. This observation coincides with the observation made by E.A.Schafer.

## CONCLUSION

The present study about the posterior tibial artery was carried out in both adult and foetal cadaveric specimens and clinical cases. The results of the study are based on the routine dissection method, radiological method, clinical studies and histological studies.

Origin of posterior tibial artery from popliteal artery at the lower border of popliteus was observed in 86% and above the lower border of popliteus in 6%, below the lower border of popliteus muscle in 2% and absence of posterior tibial artery in 6%. The knowledge of variations in the level of origin of posterior tibial artery will help the Radiologists for interventional management of tibial and peroneal diseases.

The branches of posterior tibial artery - the circumflex fibular artery, nutrient artery of tibia, peroneal artery, muscular branches, perforating branches, communicating branch, medial malleolar branches, calcaneal branches and terminal branches were observed in the present study.

The posterior tibial artery terminated by dividing into medial lateral plantar arteries was observed in 86% , terminated at a higher level by giving smaller branches to the skin and muscles in 4% and terminated by joining with peroneal artery in 4% of cases. The posterior tibial artery was completely replaced by peroneal artery in 6% cases. Observations about the occurrence of rare and abnormal termination of posterior tibial artery and replacement of posterior tibial artery by peroneal artery will definitely serve the vascular surgeons in the field of revascularization surgery for foot salvage. Through more aggressive use of tibial bypass, limb preservation has improved greatly.

The perforating branches from posterior tibial artery were located only in the middle two quarters of leg in 92.5% of cases and these branches were located in the proximal, middle and distal third of the leg in 7.5% of cases. The observations about the perforating branches of posterior tibial artery will help the plastic surgeons in refinements in lower extremity free flap reconstructive surgery.

The peroneal artery arose from the posterior tibial artery in 94% and directly from the popliteal artery in the absence of posterior tibial artery in 6%. The distance of origin of peroneal artery from the commencement of posterior tibial artery was varied from 2cms to 7.2 cms. In 8% of cases, the peroneal artery was enlarged in size and replaced the posterior tibial artery in the distal part of the leg. The information about the distance of origin of peroneal artery and its termination, replacement of posterior tibial artery by peroneal artery in the entire leg will alert the general and vascular surgeons because the peroneal artery is an important vessel to consider for use in limb revascularization and salvage in the absence of a suitable popliteal artery.

Accessibility to the leg arteries is a critical factor in achieving successful revascularization. So, this study of posterior tibial artery, its branching pattern and variations will definitely be of use to the anatomists, and clinicians of the respective fields in the future.

## **BIBLIOGRAPHY**

1. **Aasar.Y.H. (1939)**, Journal of Anatomy, Vol. LXXIII, Oct 1938 – July 1939, Page No: 194.
2. **Adachi. B (1928)**, Das Arterien System der Japaner, Kyoto, Vol.II, Pages: 206,227,242,262,269.
3. **Ben Pansky, Earl Lawrence House (1964)** , Review of Gross Anatomy, pages: 388,389.
4. **Berish strauch , Han – Liang Yu (1993)** ,Atlas of Micro vascular surgery, pages: 218,219,264.
5. **Berry J. Anson, Chester B. McVay (1971)** , Anatomy, Fifth Edition: pages :1190, 1191.
6. **J.D.Boyd et al (1956)** , text book of Human Anatomy, Page No: 365.
7. **Chummy S. Sinnatamby (1999)**,Last's Anatomy, 10<sup>th</sup> Edition, Pages : 143,144.
8. **Craver (1869)**, Irregularities in the arteries and muscles of an Idiot- Journal of Anatomy and Physiology; Vol –III, Pages: 257-260.
9. **David Harvey (1990)** , Plastic Surgery, Vol.6 - The Trunk and lower extremity , Pages : 4034, 4035.
10. **Earnest Gardener, Donald J.Gray, Ronan O' Rahilly (1967)** ,Anatomy A Regional study of Human structure, second edition, Pages : 296, 297.
11. **J.E.Frazer (1937)** , Buchanan's manual of Anatomy, 6<sup>th</sup> Edition : Pages 624-627

12. **George A. Piersol (1930)** , Human anatomy, Pages: 834-840.
13. **J.C.B.Grant (1951)**, The Anatomy of the respiratory, blood-vascular and lymphatic systems; Pages: 1322-1324.
14. **Hallock GG, Anous MM, Sheridan BC (1993)**,The surgical Anatomy of the principal nutrient vessel of the tibia- Plastic Reconstr Surgery; Jul . 92 (1): 49-54.
15. **Harold Ellis (1980)** , Clinical Anatomy, Tenth Edition; Pages: 265-266
16. **Henry Gray (1858)** , Gray's Anatomy – 38<sup>th</sup> Edition – Pages :1547,1548; 39<sup>th</sup> Edition – Pages: 1502,1503.
17. **Henry Hollinshead . W.(1969)** ,Anatomy for surgeons, Vol. 3 ; Second Edition, Pages: 804-808.
18. **Huber J.F.(1941)** , The arterial network supplying the dorsum of the foot – Anat. Rec. 80:373-391.
19. **Hung LK, Lao J, Ho PC (1996)**, Free posterior tibial perforator flap: anatomy and a report of 6 cases – Micro surgery 17 (9) : 503 -11.
20. **Hyrthl. J (1864)** ,“Ueber normal and abnorme verhaltnisse der schlagadern des unterschenkels”. Denkschriften der Mathematische Naturwissenschaftliche classe der K. Akademie der Wissenschaften.
21. **Jindarak S, Khobunsongserm S, Tansatit T (2001)**, The anatomic basis of fascio – cutaneous flap based on the posterior tibial vessels- Journal med Assoc. Thai. 2001 June : 84 suppl. 1: S283-8.

22. **John. V Basmajian (1980)** , Grant's method of Anatomy, Tenth Edition,  
Page No: 280.
23. **Kanagasuntheram. R, Sivanandasingham. P, Krishnamurti.A (1987)**,  
Anatomy- Regional, Functional and Clinical; Pages :374,375.
24. **J.A.Keen (1961)** , A study of the Arterial variations in the Limbs –  
American Journal of Anatomy, vol. 108, Jan, March, May 1961, Pages :  
254-256.
25. **Keith L. Moore (1980)** , Clinically Oriented Anatomy, Pages: 528,529
26. **Koshima I, Moriguchi T,Ohta S, Hamanaka T (1992)** , The vasculature  
and clinical application of the posterior tibial perforator- based flap- Plast  
Reconstr. Surg 1992 Oct : 90 (4) : 643-9.
27. **Latimer Callander .C (1939)** ,Surgical Anatomy, second edition, pages :  
769-771.
28. **Lockhart R.D., Hamilton G.F, Fyee F.W. (1959)** , Anatomy of the human  
body, Pages : 632,633.
29. **Maurice Arnold (1968)** , Reconstructive surgery, Page No: 446.
30. **Parsons F.G., and Robinson, A (1898)**, Eight report of the committee of  
collective investigation of the Anatomical society of Great Britain and  
Ireland – Journal of Anatomy and Physiology 33:189.
31. **Parsons schaffer.J (1953)** , Morris Human Anatomy, Eleventh Edition,  
Pages: 736-740.

32. **Piral T, Germain M, Prinic G (1996)** , Absence of the Posterior tibial artery – Surg Radial Anatomy 1996 ; 18 (2) : 155-8.
33. **Poratt D, Tilley GE (1994)** , Absence of the posterior tibial artery – Journal Am Podiatr Med Assoc. 1994 Jul: 84(7) : 363-4.
34. **F.H.Poteete JR, Robert C. Lynch, New Orleans LA (1956)** , Thromboangitis obliterans in women- Journal Devoted to the Art and Science of Surgery; vol.39, page no: 345.
35. **Prives . M, Ly sankov . N, Bushkovich. V. (1985)**, Vol. II , The science of the vessels, the science of the nervous system, the science of sensory organs; Pages: 90,91.
36. **Quain .R. (1844)** ,The anatomy of the arteries of the Human body.
37. **Renan Uflacker (1997)** ,Atlas of Vascular Anatomy- An Angiographic Approach; Pages: 745-746.
38. **Richard S. Snell (1995)** , clinical Anatomy for medical students, fifth Edition; Pages : 563,564,606.
39. **Robert J. Baker, Josef E. Fischer (2001)**, Mastery of Surgery, Fourth Edition, Vol.II ; pages : 2148,2149.
40. **Robert B. Rutherford (1993)** , Atlas of vascular surgery – Basic Techniques and Exposures; Pages : 152,154.
41. **Rodriguaz JI (1993)** , Vascular Anomalies in Campomelic syndrome – American Journal Med. Genet. 1993 Apr.15 : 46 (2) : 185-92.

42. **Roger Warwick (1963)** , Johnston's Synopsis of Regional Anatomy, Ninth Edition; Page No: 78.
43. **Romanes G.J. (1964)** , Cunningham's Text book of Anatomy, Tenth Edition; Pages: 910,911.
44. **Ronan O' Rahilly (1986)** , Anatomy -A Regional study of Human structure, Fifth Edition; Page No: 231.
45. **Russell .T. Woodburne (1961)** , Essentials of Human Anatomy, Second Edition; Pages : 566,567.
46. **Saadeh FA, el-karagy SA, Haikal FA(1995)** , Anterior Tibial Artery : Variation in Origin and branching- Surgical Radiological Anatomy 17 (1) : 83-4.
47. **Samarendra Mitra (1973)** , Anatomy, Vol.I; Pages: 3.35, 3.46.
48. **Sanders R.J, Alston GK (1986)** , variations and anomalies of the popliteal and tibial arteries- American Journal of Surgery 1986 Nov; 152 (5) : 531-4.
49. **E.A.Schafer (1912)** , Quain's Elements of Anatomy, Eleventh Edition, Vol.II, Part I; pages : 330-333.
50. **H.D.Senior (1919)**, An interpretation of the Recorded Arterial Anomalies of the Human leg and foot – Journal of Anatomy, Vol .LIII Oct 1918 – July 1919; Pages : 136,146,149,150
51. **H.D.Senior(1929)** , Abnormal branching of the human popliteal artery, American Journal of Anatomy 44; 111,1929.



52. **Sir John Bruce, Robert Walmsley, James A Ross ( 1964)** , Manual of Surgical Anatomy, Pages : 521,522
53. **Sir Solly Zuckerman(1961)** , A new system of Anatomy ; pages :162,163.
54. **Thomas walmsley (1934)** ,A manual of practical Anatomy; Pages: 320,322.
55. **Trotter, M (1940)** , The level of termination of the popliteal artery in the White and Negro, American Journal of Anthropology., 27: 109-118.
56. **Vaboril.R (1990)** , Note on variability of the arteries of the lower extremities in man – Folia morphol 1990; 38 (3) : 265-72.
57. **Wesley S. Moore (2002)** , Vascular and Endovascular surgery ; Pages : 64,65.
58. **William J. Zwiebel, John S. Pellerito (2000)** , Introduction to vascular ultra sonography, fifth edition; Pages : 265,266.
59. **Wu WC, Chang YP,So YC, Yip SF, Lam YL (1993)** , The anatomic basis and clinical applications of flaps based on the posterior tibial vessels – Br. Journal plast surg 1993 sep;46 (6) : 470-9.

**Staining Procedure for Formalin Fixed Specimen.**

**Dehydration with graded alcohol**



**Cleaning with xylol**



**Impregnation with wax**



**Embedding**



**Sectioning**



**Mounting of sections**



**Staining**

**Staining**



**Deparaffinization**



**Hydration with graded alcohol**



**Haematoxylin and Eosin staining**



**Dehydration**



**Cleaning**



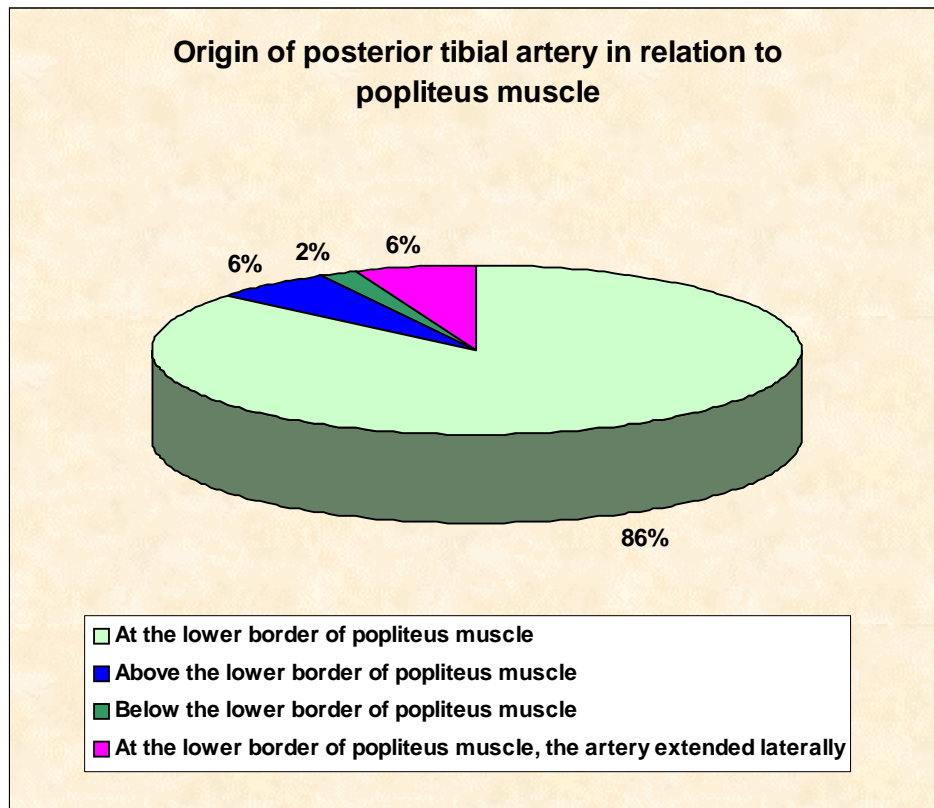
**Mounting the slide with DPX**

( Cytoplasm – Pink)  
( Nucleus - Purple)

**Table I**

**Origin of posterior tibial artery in relation to popliteus muscle**

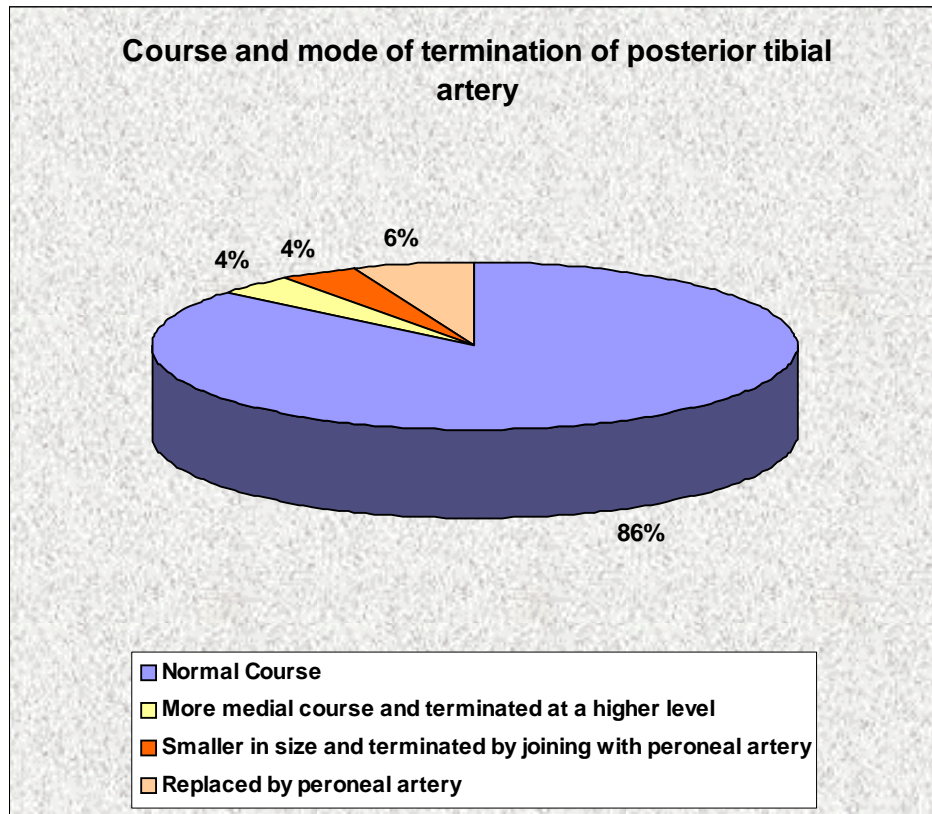
| Type   | Adult<br>(40) | Foetus<br>(10) | Total<br>(50) | Percentage<br>% |
|--|---------------|----------------|---------------|-----------------|
| 1. At the lower border of popliteus muscle.                                | 34            | 9              | 43            | 86%             |
| 2. Above the lower border of popliteus muscle                              | 3             | -              | 3             | 6%              |
| 3. Below the lower border of popliteus muscle.                             | 1             | -              | 1             | 2%              |
| 4. At the lower border of popliteus muscle, the artery extended laterally. | 2             | 1              | 3             | 6%              |



**Table II**

**Course and mode of termination of posterior tibial artery**

| <b>Course of posterior tibial artery</b>                         | <b>Adult (40)</b> | <b>Foetus (10)</b> | <b>Total (50)</b> | <b>Percentage %</b> |
|--|-------------------|--------------------|-------------------|---------------------|
| 1. Normal Course   | 34                | 9                  | 43                | 86%                 |
| 2. More medial course and terminated at a higher level           | 2                 | -                  | 2                 | 4%                  |
| 3 Smaller in size and terminated by joining with peroneal artery | 2                 | -                  | 2                 | 4%                  |
| 4. Replaced by peroneal artery                                   | 2                 | 1                  | 3                 | 6%                  |



**Table III**

**Level of bifurcation of posterior tibial artery**

| <b>Level of bifurcation</b>                   | <b>Adult</b> | <b>Foetus</b> | <b>Total</b> | <b>Percentage %</b> |
|---|--------------|---------------|--------------|---------------------|
| 1. Under flexor Retinaculum                   | 32           | 9             | 41           | 82%                 |
| 2. Under abductor hallucis                    | 2            | -             |              | 4%                  |
| 3. Terminated at a higher level               | 2            | -             |              |                     |
| 4. Terminated by joining with peroneal artery | 2            | -             |              |                     |
| 5. Replaced by peroneal artery.               | 2            | -             |              |                     |

**Table IV**

**Origin of circumflex fibular artery**

| <b>Circumflex Fibular artery</b>       | <b>Adult</b> | <b>Foetus</b> | <b>Total</b> | <b>Percentage<br/>%</b> |
|--|--------------|---------------|--------------|-------------------------|
| 1. Origin from posterior tibial artery | 38           | 9             | 47           | 94                      |
| 2. From peroneal artery                | 2            | 1             | 3            | 6                       |

**Table V**

**Nutrient Artery**

| <b>Nutrient Artery of the tibia</b>  | <b>Adult Specimens</b> | <b>Foetal Specimens</b> | <b>Total</b> | <b>Percentage %</b> |
|--|------------------------|-------------------------|--------------|---------------------|
| 1. Origin from posterior tibial artery above the origin of peroneal artery in the upper part of tibia. | 35                     | 9                       | 44           | 88                  |
| 2. From posterior tibial artery below the origin of peroneal artery in the middle part of tibia.       | 3                      | -                       | 3            | 6                   |
| 3. From peroneal artery, in the absence of posterior tibial artery.                                    | 2                      | -                       | 3            | 6                   |

**Table VII**

**Distance of the last perforating branch in the distal third of the leg  
from the medial malleolus**

| Specimen No. | Distance in cm |
|--------------|----------------|
| 1            | 2.4            |
| 2            | 2.2            |
| 3            | 2.8            |

Average = 2.4cm



**Table VI**

**Distance of the last perforating branch in the middle two quarters of the leg from the medial malleolus**

| <b>Specimen No.</b> | <b>Distance in cm from medial malleolus</b> | <b>Specimen No</b> | <b>Distance in cm</b> |
|---------------------|---|--------------------|-----------------------|
| 1                   | 14.8  | 18                 | 18.8                  |
| 2                   | 20.6  | 19                 | 21.4                  |
| 3                   | 18.6  | 20                 | 20.6                  |
| 4                   | 17.8  | 21                 | 21.4                  |
| 5                   | 17.6  | 22                 | 15.7                  |
| 6                   | 19.8  | 23                 | 17.6                  |
| 7                   | 17.6  | 24                 | 18.8                  |
| 8                   | 18.7  | 25                 | 20.7                  |
| 9                   | 19.3  | 26                 | 16.4                  |
| 10                  | 17.5  | 27                 | 20.8                  |
| 11                  | 19.8  | 28                 | 16.6                  |
| 12                  | 19.5  | 29                 | 19.7                  |
| 13                  | 21.8  | 30                 | 18.8                  |
| 14                  | 20.7  | 31                 | 20.8                  |
| 15                  | 16.6  | 32                 | 16.7                  |
| 16                  | 17.8  | 33                 | 19.6                  |
| 17                  | 20.8  | 34                 | 20.4                  |
|                     |   | 35                 | 18.6                  |

Average = 18.9cm

**Table VIII**  
**Origin of peroneal artery**

| <b>Origin of Peroneal artery</b>  | <b>Adult Specimens</b> | <b>Foetal Specimens</b> | <b>Total</b> | <b>Percentage %</b> |
|---|------------------------|-------------------------|--------------|---------------------|
| 1. From Posterior tibial artery   | 38                     | 9                       | 47           | 94                  |
| 2. Directly from the popliteal artery, in the absence of posterior tibial artery. | 2                      | 1                       | 3            | 6                   |

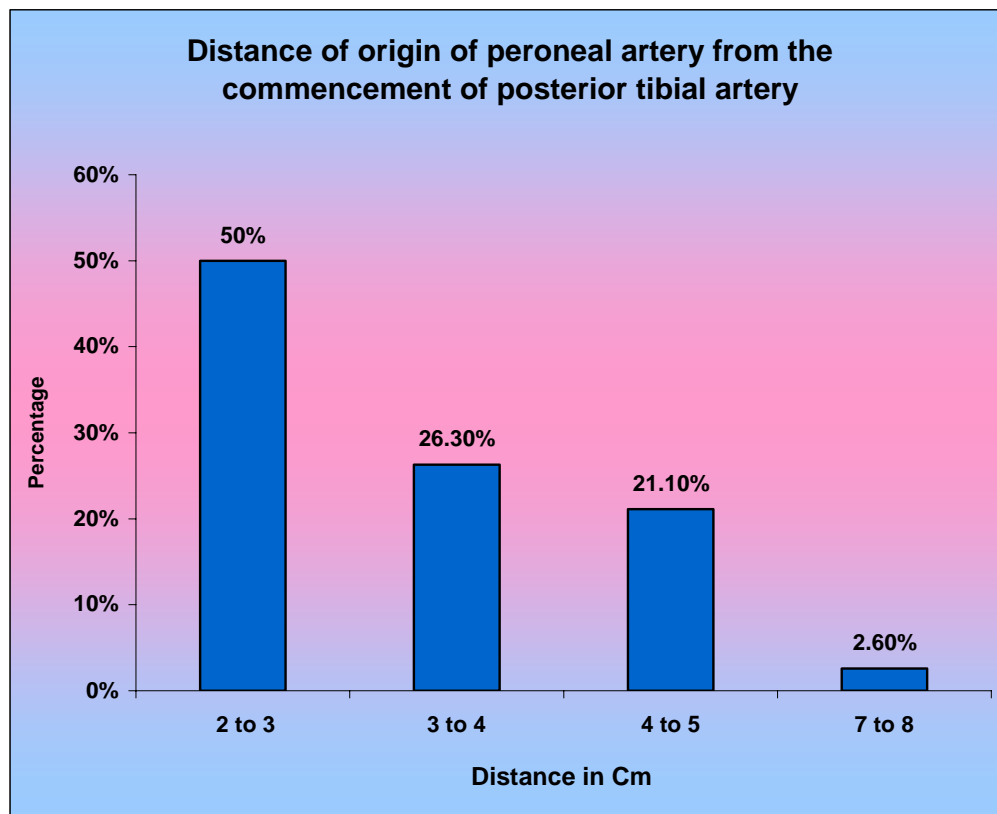
**Table IX**  
**Distance of origin of peroneal artery from the commencement**  
**of posterior tibial artery in adults**

| Specimen<br>No. | Distance in cm | Specimen<br>No | Distance in<br>cm |
|-----------------|----------------|----------------|-------------------|
| 1               | 2.8            | 20             | 2.4               |
| 2.              | 3.4            | 21             | 2.0               |
| 3.              | 2.4            | 22             | 3.8               |
| 4.              | 3.6            | 23             | 2.8               |
| 5.              | 2.8            | 24             | 2.4               |
| 6.              | 2.5            | 25             | 3.0               |
| 7.              | 2.8            | 26             | 5.0               |
| 8.              | 4.2            | 27             | 4.2               |
| 9.              | 2.6            | 28             | 2.8               |
| 10              | 2.8            | 29             | 3.6               |
| 11              | 4.4            | 30             | 4.4               |
| 12              | 3.4            | 31             | 2.6               |
| 13              | 2.6            | 32             | 2.4               |
| 14              | 3.6            | 33             | 3.2               |
| 15              | 4.6            | 34             | 4.8               |
| 16              | 3.4            | 35             | 2.8               |
| 17              | 2.2            | 36             | 2.4               |
| 18              | 3.4            | 37             | 3.2               |
| 19              | 7.2            | 38             | 5.0               |

**Average - 3.4 cm**

**Table X**  
**Distance of origin of peroneal artery**

| <b>Total no. of adult specimens (38)</b> | <b>Distance in cm.</b> | <b>Percentage %</b> |
|--|------------------------|---------------------|
| 19                                       | 2-3                    | 50                  |
| 10                                       | 3-4                    | 26.3                |
| 8  | 4-5                    | 21.1                |
| 1  | 7-8                    | 2.6                 |



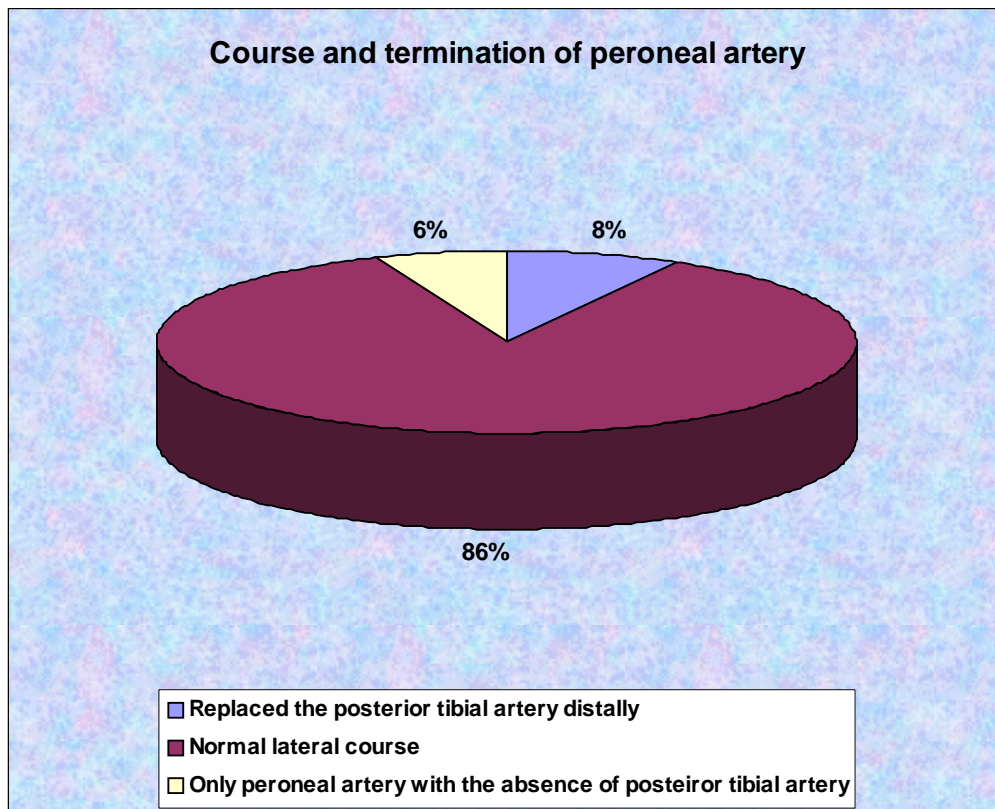
**Table XI**  
**Distance of origin of peroneal artery from the commencement**  
**of posterior tibial artery (in foetus)**

| <b>Specimen No.</b> | <b>Distance in cm</b> | <b>Specimen no.</b> | <b>Distance in cm</b> |
|---------------------|-----------------------|---------------------|-----------------------|
| 1.                  | 1.7 cm                | 6                   | 1.7 cm                |
| 2.                  | 1.5 cm                | 7                   | 1.2 cm                |
| 3.                  | 1.4 cm                | 8                   | 1.0 cm                |
| 4                   | 1.5 cm                | 9                   | 1.5 cm                |
| 5.                  | 1.2 cm                |                     |                       |

**Average – 1.5 cm**

**Table XII**  
**Course and termination of peroneal artery**

| <b>Course of peroneal artery</b>   | <b>Adult Specimens</b> | <b>Foetal Specimens</b> | <b>Total</b> | <b>Percentage %</b> |
|--|------------------------|-------------------------|--------------|---------------------|
| 1. Normal lateral course.  | 34                     | 9                       | 43           | 86                  |
| 2. Enlarged in size and replaced the posterior tibial artery distally.                                       | 4                      | -                       | 4            | 8                   |
| 3. Only peroneal artery, directly arising from popliteal artery with the absence of posterior tibial artery. | 2                      | 1                       | 3            | 6                   |



**Table XIII**

**Communicating Branch of posterior tibial artery**

| <b>Specimen No.</b> | <b>Distance in cm<br/>from medial<br/>malleolus</b> | <b>Specimen no.</b> | <b>Distance in cm</b> |
|---------------------|---|---------------------|-----------------------|
| 1                   | 4.8   | 19                  | 3.8                   |
| 2                   | 5.5   | 20                  | 3.5                   |
| 3                   | 5.2   | 21                  | 4.6                   |
| 4                   | 4.6   | 22                  | 4.8                   |
| 5                   | 4.2   | 23                  | 3.4                   |
| 6                   | 4.4   | 24                  | 5.2                   |
| 7                   | 5.2   | 25                  | 2.8                   |
| 8                   | 4.6   | 26                  | 4.6                   |
| 9                   | 4.8   | 27                  | 5.0                   |
| 10                  | 2.6   | 28                  | 4.6                   |
| 11                  | 4.6   | 29                  | 2.6                   |
| 12                  | 3.8   | 30                  | 5.4                   |
| 13                  | 5.2   | 31                  | 4.6                   |
| 14                  | 4.8   | 32                  | 4.4                   |
| 15                  | 5.2   | 33                  | 5.4                   |
| 16                  | 4.2   | 34                  | 4.8                   |
| 17                  | 4.4   |                     |                       |
| 18                  | 2.8   |                     |                       |

**Average – 4.4 cm**

**Table XIV**  
**Medial malleolar branch**

| <b>Medial malleolar branch</b>               | <b>Adult Specimens</b> | <b>Foetal Specimens</b> | <b>Total</b> | <b>Percentage %</b> |
|--|------------------------|-------------------------|--------------|---------------------|
| <b>I. Arose from posterior tibial artery</b> |                        |                         |              |                     |
| <b>a. Two in number</b>                      | 20                     | -                       | 20           | 40                  |
| <b>b. one in number</b>                      | 14                     | 9                       | 23           | 46                  |
| <b>II. Arose from peroneal artery</b>        |                        |                         |              |                     |
| - One in number                              | 6                      | 1                       | 7            | 14                  |



**Table XV**

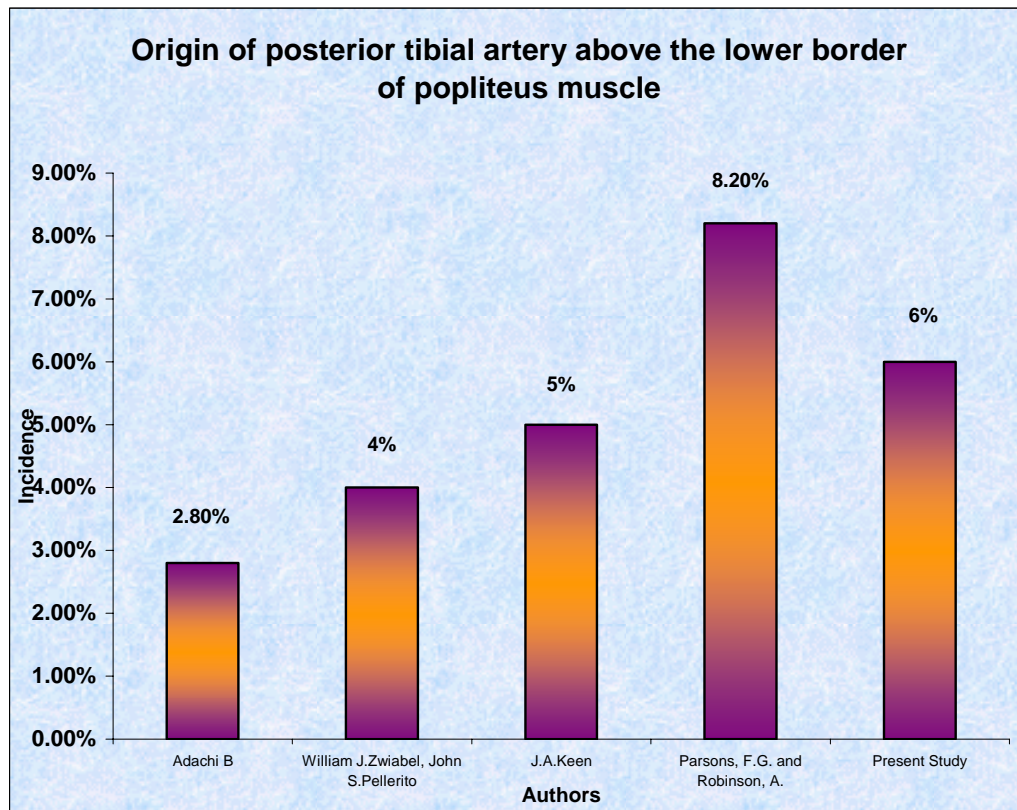
**Terminal branches – medial and lateral plantar arteries**

| <b>Terminal branches</b>  | <b>Adult Specimens</b> | <b>Foetal Specimens</b> | <b>Total</b> | <b>Percentage %</b> |
|---|------------------------|-------------------------|--------------|---------------------|
| <b><u>From Posterior tibial artery</u></b>                              | 32                     | 9                       | 41           | 82                  |
| - Medial plantar artery was smaller in size than lateral plantar artery | 2                      | -                       | 2            | 4                   |
| - Both were equal in size   |                        |                         |              |                     |
| <b><u>From peroneal artery</u></b>                                      |                        |                         |              |                     |
| -Medial plantar artery was smaller in size than lateral plantar artery  | 6                      | -                       | 6            | 12                  |
| -Both were equal in size  | -                      | 1                       | 1            | 2                   |

**Table - ID**

**Origin of posterior tibial artery above the lower border of popliteus muscle**

| <b>Serial No.</b> | <b>Author</b>                         | <b>Incidence</b> |
|-------------------|---------------------------------------|------------------|
| 1.                | Adachi B                              | 2.8 %            |
| 2.                | William J. Zwiabel, John S. Pellerito | 4%               |
| 3.                |                                       | 5%               |
| 4.                | J.A. Keen                             |                  |
| 5.                | Parsons, F.G.and Robinson,A.          | 8.2%             |
|                   | Present study                         | 6%               |



**Table – 2D**

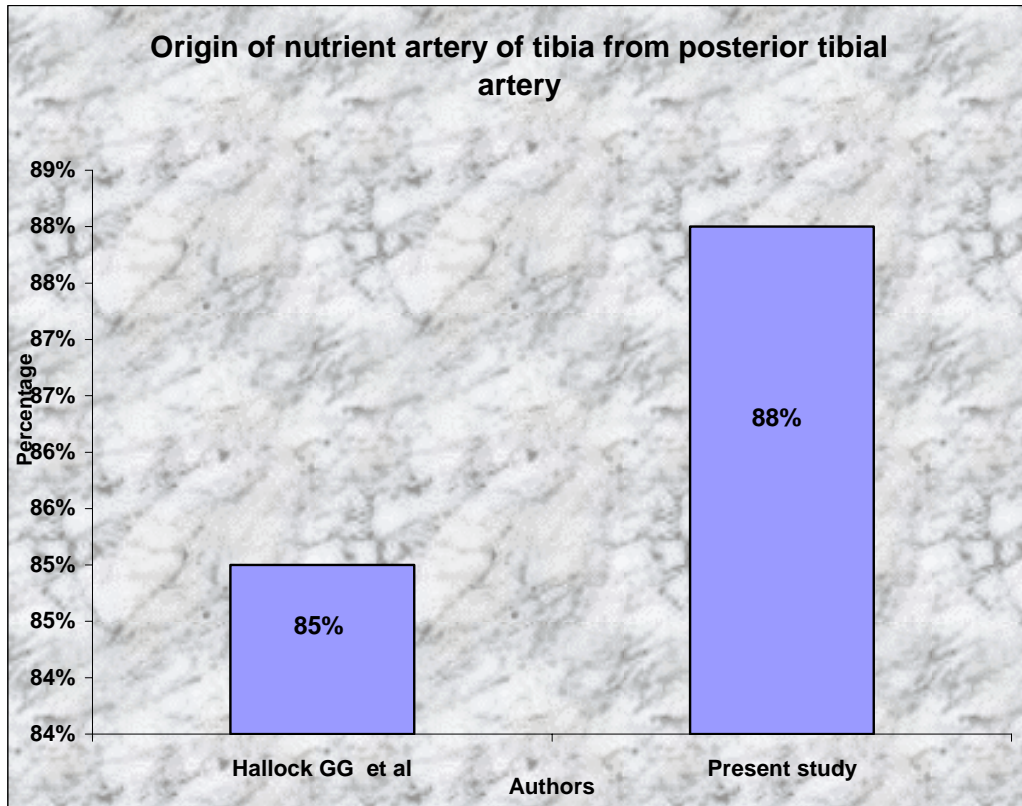
**Replacement of posterior tibial artery by peroneal Artery**

| <b>Serial No.</b> | <b>Author</b>                          | <b>Percentage</b> |
|-------------------|--|-------------------|
| 1.                | Huber, J.F.                            | 2.5%              |
| 2.                | J.A.Keen                               | 2.5%              |
| 3.                | Piral T. et al                         | 1-5%              |
| 4.                | William J. Zwiebel,John<br>S.Pellerito | 1-5%              |
| 5.                | Berish Strauch et al                   | 8%                |
| 6.                | Present study                          | 6%                |

**Table – 3D**

**Origin of Nutrient Artery of Tibia from posterior tibial artery**

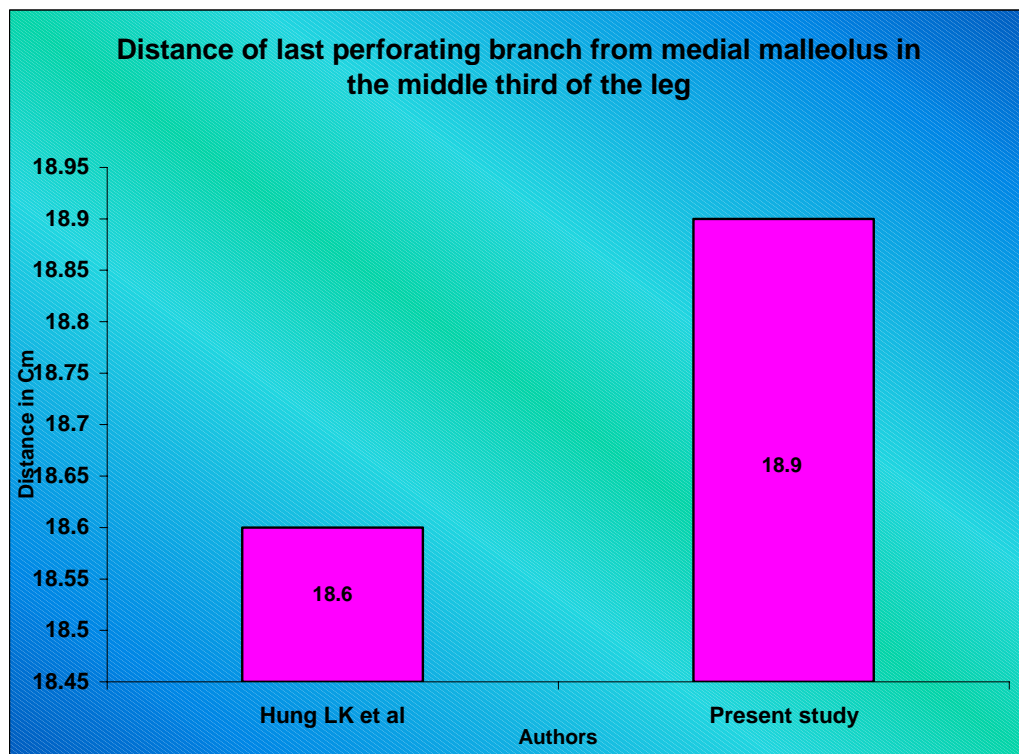
| <b>S.No</b> | <b>Author</b>    | <b>Incidence</b> |
|-------------|------------------|------------------|
| <b>1</b>    | Hallock GG et al | 85%              |
| <b>2</b>    | Present study    | 88%              |



**Table – 4D**

**Distance of last perforating branch from medial malleolus in the middle third of the leg**

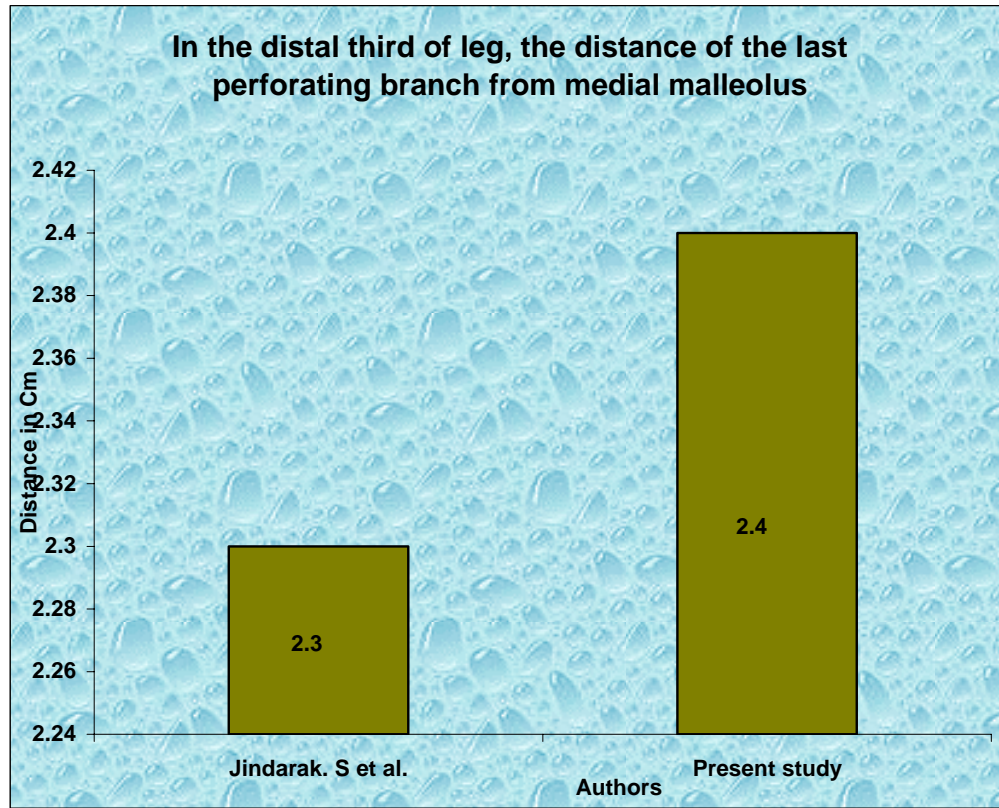
| <b>Author</b> | <b>Distance</b> |
|---------------|-----------------|
| Hung LK et al | 18.6 cm         |
| Present study | 18.9 cm         |



**Table – 5D**

**In the distal third of the leg, the distance of the last perforating branch from medial malleolus**

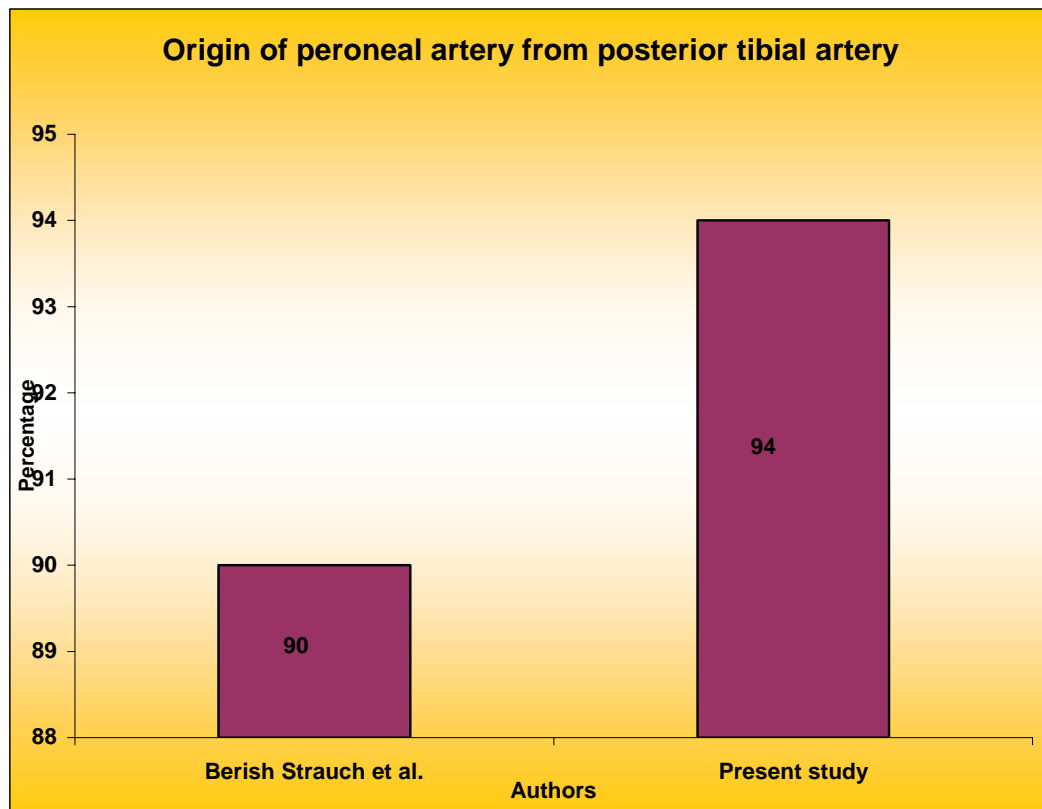
| <b>Author</b>      | <b>Distance</b> |
|--------------------|-----------------|
| Jindarak . S et al | 2.3 cm          |
| Present Study      | 2.4 cm          |



**Table – 6D**

**Origin of peroneal artery from posterior tibial artery.**

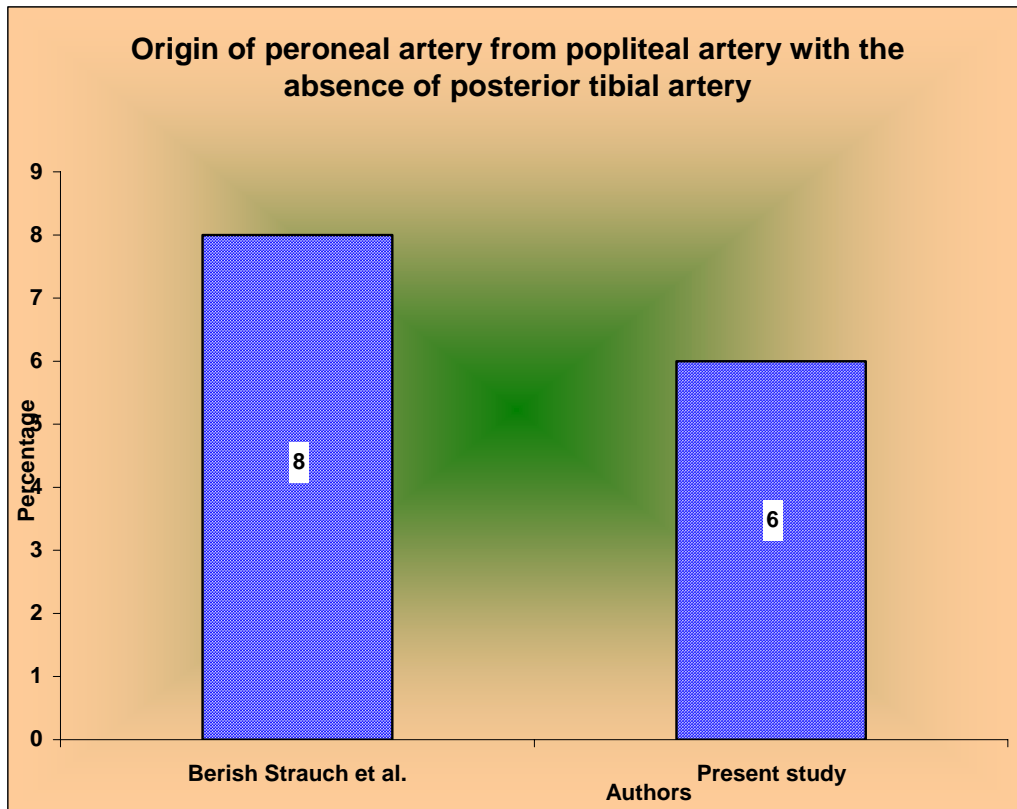
| <b>S.No.</b> | <b>Author</b>        | <b>Incidence</b> |
|--------------|----------------------|------------------|
| 1.           | Berish Strauch et al | 90%              |
| 2.           | Present study        | 94%              |



**Table – 7D**

**Origin of peroneal artery from popliteal artery with the absence of posterior tibial artery.**

| <b>S.No.</b> | <b>Author</b>        | <b>Incidence</b> |
|--------------|----------------------|------------------|
| 1.           | Berish Strauch et al | 8%               |
| 2.           | Present study        | 6%               |





**Table -8D**

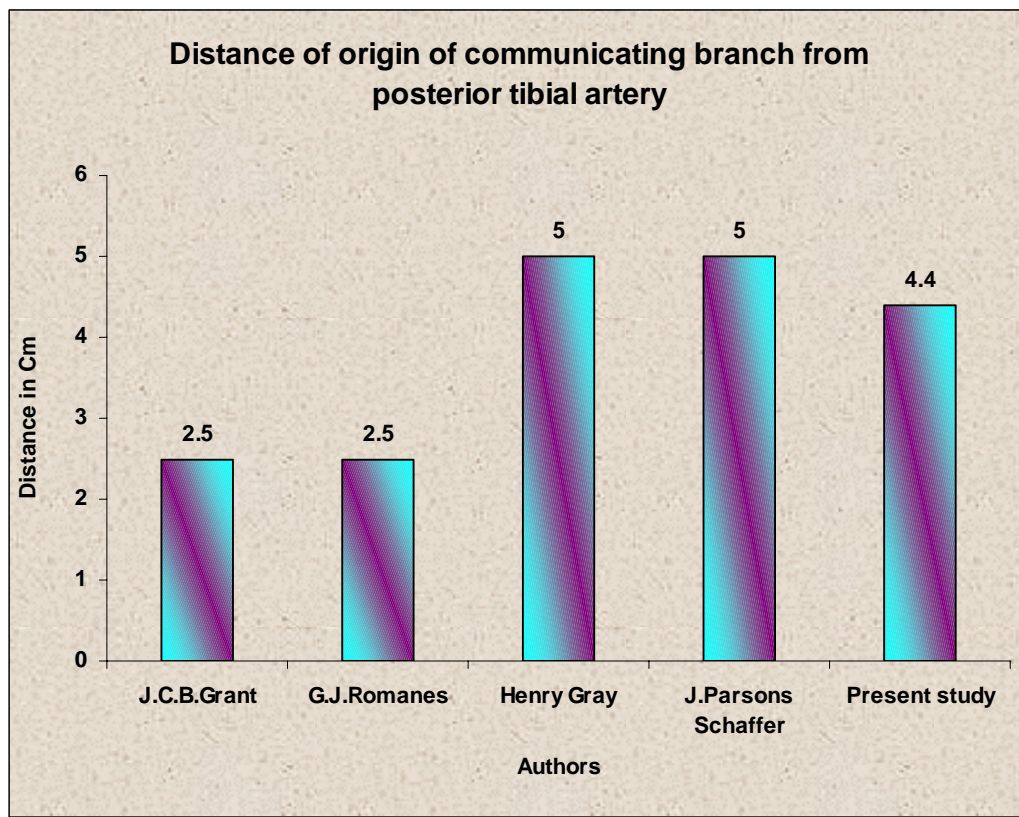
**Distance of origin of peroneal artery from posterior tibial artery**

| S.No. | Authors                      | Distance  |
|-------|------------------------------|-----------|
| 1.    | Russell T. Wood burne (1961) | 2-3 cm    |
| 2.    | Keith L. Moore (1980)        | 2-3 cm    |
| 3.    | Berish Strauch et al (1993)  | 3 cm      |
| 4.    | Harold Ellis (1980)          | 4 cm      |
| 5.    | Thomas walmsley (1934)       | 5cm       |
| 6.    | Henry Gray (1858)            | 7-8cm     |
| 7.    | Present study in adult       | 2-7.2 cm  |
|       | in foetus                    | 1 – 1.5cm |

**Table – 9D**

**Distance of origin of communicating branch from  
posterior tibial artery to peroneal artery**

| <b>S.No</b> | <b>Author</b>       | <b>Distance</b> |
|-------------|---------------------|-----------------|
| 1           | J.C.B. Grant        | 2.5 cm          |
| 2           | G.J. Romanes        | 2.5 cm          |
| 3.          | Henry Gray          | 5 cm            |
| 4           | J. Parsons Schaffer | 5 cm            |
| 5           | Present Study       | 4.4 cm          |



**Table – 10D**

**Large Lateral Plantar Artery**

| <b>S.No.</b> | <b>Authors</b> |  |
|--------------|----------------|--|
| 1            | David Harvey   |  |
| 2            | Present Study  |  |

