



W&M ScholarWorks

VIMS Articles

1999

Isolation of *Aphanomyces* sp(p). associated with skin lesions and mortalities in the striped (*Mugil cephalus*) and the thin lip (*Liza ramada*) grey mullets

AA Shaheen

E Elsayed

M Faisal

Virginia Institute of Marine Science

Follow this and additional works at: <https://scholarworks.wm.edu/vimsarticles>

 Part of the [Aquaculture and Fisheries Commons](#), and the [Marine Biology Commons](#)

Recommended Citation

Shaheen, AA; Elsayed, E; and Faisal, M, "Isolation of *Aphanomyces* sp(p). associated with skin lesions and mortalities in the striped (*Mugil cephalus*) and the thin lip (*Liza ramada*) grey mullets" (1999). *VIMS Articles*. 1726.

<https://scholarworks.wm.edu/vimsarticles/1726>

This Article is brought to you for free and open access by W&M ScholarWorks. It has been accepted for inclusion in VIMS Articles by an authorized administrator of W&M ScholarWorks. For more information, please contact scholarworks@wm.edu.

ISOLATION OF *APHANOMYCES* SP(P). ASSOCIATED WITH SKIN LESIONS AND MORTALITIES IN THE STRIPED (*MUGIL CEPHALUS*) AND THE THIN LIP (*LIZA RAMADA*) GREY MULLET

ADEL A. SHAHEEN^{***}, EHAB ELSAYED^{***} AND MOHAMED FAISAL^{**}

^{*}Faculty of Veterinary Medicine at Moshtohor, Zagazig University, Moshtohor, Egypt.

^{**}Virginia Institute of Marine Science, School of Marine Science, The College of William and Mary, Gloucester Point, VA 23062

^{***}Faculty of Veterinary Medicine, Cairo University, Guiza, Egypt

Abstract

Aphanomyces spp. were isolated from skin erosions and ulcers of cultured Striped and thin lip grey mullets. Fungi with non-septated hyphae were found in wet mount preparations of skin. Samples inoculated on glucose peptone liquid medium for three successive steps then mycelial growths were transferred into glucose peptone yeast extract agar medium. *Aphanomyces* spp. were successfully isolated, in axenic cultures, from seven out of 35 fish samples. The cultures were maintained on glucose peptone yeast extract liquid media. Formation of sporangia in tap water that contained hemp seeds confirmed that the grey mullet isolates are members of the genus *Aphanomyces*. All isolates grew progressively at salinities that ranged from 2-8 ppt, however, only one isolate survived at 37°C.

Introduction

Members of genus *Aphanomyces* (Oomycetes fungi) have been implicated as the cause of serious outbreaks among freshwater and estuarine fish species worldwide (Fraser *et al.*, 1992; Willoughby and Roberts 1994). The disease has been described as Mycotic Granulomatosis in freshwater fish from Japan (Hatai *et al.*, 1977), Ulcerative Mycosis in the Atlantic menhaden from North America (Dykstra *et al.*, 1989), Epizootic Ulcerative Syndrome in freshwater fish species from southeastern Asia, and Red Spot Disease in mullets from Australia (Callinan *et al.*, 1989; Fraser *et al.*, 1992).

Aphanomyces have been identified in the skin of affected fish exhibiting a wide range of lesions varying from necrotic dermatitis to deep ulceration on different parts of skin (Dykstra *et al.*, 1989; Noga *et al.*, 1988; Callinan *et al.*, 1989). There is a controversy, however, whether *Aphanomyces* is a primary pathogen or a secondary invader in this syndrome. In the present study, we report the association of *Aphanomyces* spp. with skin lesions and mortalities from two grey mullet species; *Mugil cephalus* and *Liza ramada*.

Materials and Methods

Fish:

A total of 20 *Mugil cephalus* and 15 *Liza ramada* showing skin lesions were collected from an excavated earthen pond at the western shore of the Suez Canal, Suez Governorate, Egypt during winter of 1997. The fish were transported alive to the Fish Diseases and Management Laboratory, Faculty of Veterinary Medicine at Moshtohor, in plastic bags supplied with pumped oxygen. Fish were kept in four glass aquaria (100 X 40 X 30 cm each) that contained dechlorinated tap water and supplied with aerators and filters. Fish were then sacrificed by a blow on the head and then examined for the presence of gross skin lesions. Skin scrapings were obtained from different skin ulcers and examined microscopically for the presence of fungal elements.

Isolation of *Aphanomyces* spp.:

Isolation of *Aphanomyces* was carried out using the five step culture procedure as detailed by Willoughby and Roberts (1994). Briefly, three subcultures were carried out on glucose-peptone broth supplemented with penicillin G sodium (100 mg/l) and oxolinic acid (100 mg/l). The growth was then transferred on glucose peptone yeast extract agar

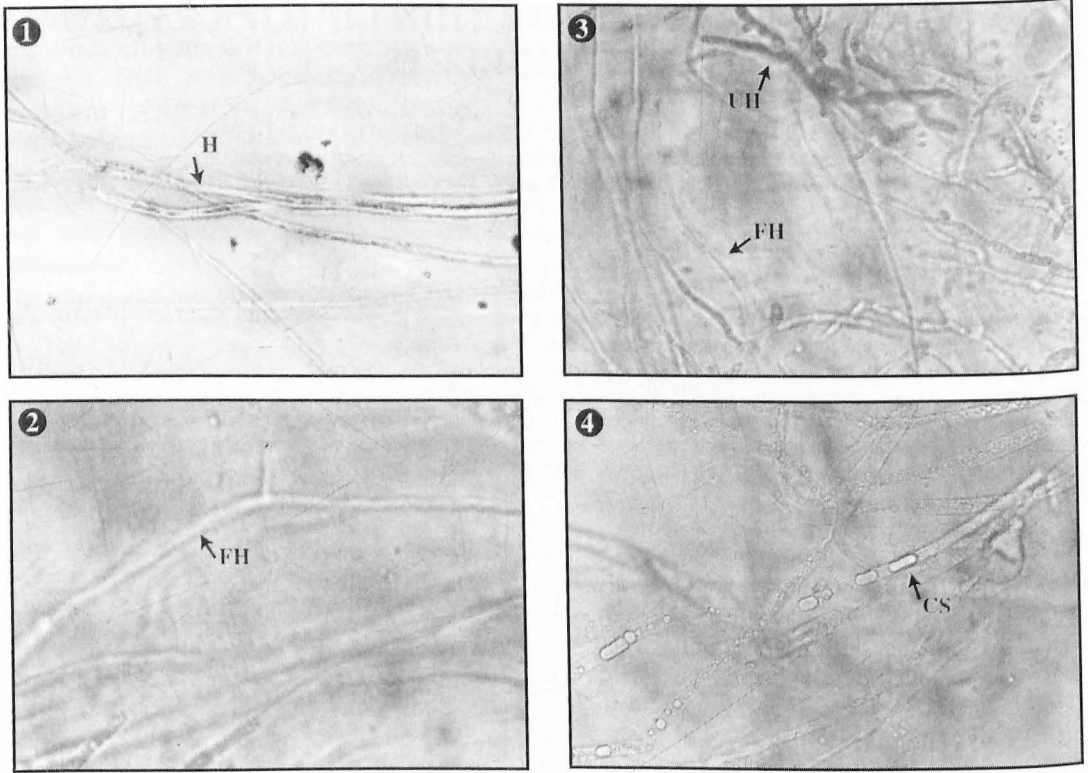


Figure 1: Mount preparation of an ulcer scrapping showing non-septated hyphae (H) of *Aphanomyces* sp. (1000 X).

Figure 2: Mount preparation from the periphery of *Aphanomyces* sp. culture on glucose peptone yeast extract agar showing fine non-septated hyphae (FH) (1000 X).

Figure 3: Mount preparation from the center of *Aphanomyces* growth on glucose peptone yeast extract agar showing undulating hyphae (UH) and viable (FH) hyphae (400 X).

Figure 4: Mount preparation of *Aphanomyces* spp on glucose peptone yeast extract broth showing clamydospore (CS) like structures inside the hyphae (500 X).

supplemented with penicillin G sodium (100 mg/l) and streptomycin sulphate (100 mg/l) and was incubated at room temperature. Subcultures on glucose-peptone-yeast extract broth were performed every 4-5 weeks. The isolated fungi were identified by their morphological characters as listed by Scott (1961). Ability of *Aphanomyces* isolates to grow at different temperatures (20, 22, 24, 26, 28, 30 and 37°C) was tested using glucose peptone yeast extract agar media for six days. The ability of *Aphanomyces* to grow at

different salinities was attempted 0, 2, 4, 8, 12, 16 and 20 ppt using sodium chloride. Cultures were incubated for six days at room temperature and mycelial growth rates were checked daily (Fraser *et al.*, 1992). Zoospore germination was induced by transferring mycelial mass from the glucose peptone yeast extract broth, washing twice with sterile distilled water, and then resuspended in sterile tap water supplied with hemp seed halves (obtained by permission from the Egyptian Security Authority, Qalubia) as described by Fraser *et al.* (1992) and Wada *et al.* (1996).

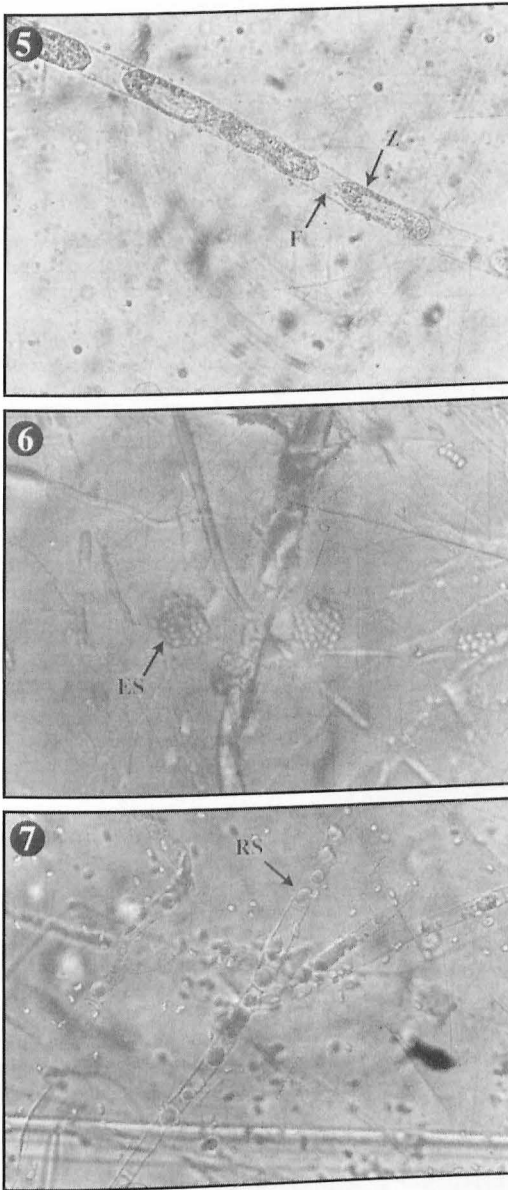


Figure 5: Mount preparation of *Aphanomyces* spp. in hemp seed containing tap water showing primary spores (Z) as a single row linked by thin cytoplasmic strand (F). (1250 X).

Figure 6: Mount preparation of *Aphanomyces* spp. in hemp seed containing tap water showing clusters of primary encysted zoospores (ES) at the tip of terminal hyphae (1250 X).

Figure 7: Mount preparation of *Aphanomyces* spp on sterile tap water showing retained encysted mature zoospores (RS) failed to evacuate from the sporangia (1250X).

All chemicals were purchased from DIFCO Lab.(Detroit, MI) except penicillin, strepto-

mycin, and oxolinic acid were from CID Chemical Co. (Guiza, Egypt).

Results and Discussion

Ulcers were found most commonly on the dorsal surface and caudal peduncles of affected fish from both species. Most fish had a single lesion, though some had multiple (2-4) discrete ulcers. The ulcers were usually circumscribed shallow (2-5 mm size) with whitish center and hemorrhagic rims.

Wet mount preparations demonstrated the presence of relatively wide sparsely branched, non-septated hyphae in all samples examined (Figure 1). On glucose peptone agar, white flat mycelia grew progressively to occupy the entire growth surface of the plate within 10 days post-inoculation. Growth was primarily of non-septated hyphae that were thinner than those observed in skin scrapings mount preparations specially at the periphery of the culture (Figure 2). Hyphae in the culture centre appeared undulated and coarser than those at the periphery, although some thin actively growing fungal hyphae could also be observed (Figure 3). Clamydospore like structures were observed

inside aged mycelia on glucose peptone yeast extract broth (Figure 4).

Seven *Aphanomyces* spp. isolates were obtained and designated as MC1, MC2, MC3, MC4, LR1, LR2 and LR3. The success in recovery of *Aphanomyces* spp. isolates were relatively poor (7 out of 35, 20%). This poor recovery has also been reported by in several studies (Dykstra *et al.*, 1989; Callinan *et al.*, 1995).

Fungal sporulation was induced by growing the fungus isolates on hemp seed halves containing tap water. Asexual reproduction was detected at the terminal end of the hyphae. Sporangia were formed with septa at their bases. Primary spores were produced within the sporangium arranged in a row, linked together by thin strands (Figure 5). Primary zoospores were then released at the tip of the terminal hyphae and encysted in clusters around the tip of the hyphae (Figure 6). Spores that failed to emerge encysted and appears as a refractile bodies within the sporangia (Figure 7). Motile secondary zoospores were observed within 12 hrs of sporangia development. In conclusion, all the developmental stages obtained with isolates of this study are similar to those described as *Aphanomyces* spp. by other authors.

Growth of obtained isolates at different temperatures revealed that six out of seven isolates grew at temperatures up to 30°C. While one isolate exhibited a more rapid growth at all temperatures up to 37°C. Some investigators considered the ability of an isolate to grow at 37°C as an indicator of its saprophyte nature (Fraser *et al.*, 1992; Willoughby *et al.*, 1995; Lilley *et al.*, 1997). All seven *Aphanomyces* spp. isolates of this study were able to grow at salinity range of 2-8 ppt with their growth rate slower as the salinity increased, similar findings were described by Fraser *et al.* (1992).

Cultures of *Aphanomyces* showed no sexual organs at the presence of hemp seeds. Failure of induction sexual reproduction in this study and in previous studies by other workers (Fraser *et al.*, 1992, Roberts *et al.*, 1993) leave *Aphanomyces* species identification as a puzzling question. Further studies are needed to identify the pathogenesis and biology of our *Aphanomyces* spp. isolates.

Acknowledgments

Dr. Shaheen is recipient of a scholarship from the Egyptian Ministry of Higher Education. This is the Virginia Institute of Marine Science Contribution # ~~XXXX~~ 2228

References

- Callinan, R.B., Fraser, G.C. and Virgona, J.L. (1989) Pathology of Red Spot Disease in sea mullet, *Mugil cephalus* L., from eastern Australia. *J. Fish Dis.* **12**, 467-479.
- Callinan, R.B., Paclibare, J.O., Bondad-Reantaso, M.G., Chin, J.C. and Gogolewski, R.P. (1995) *Aphanomyces* species associated with Epizootic Ulcerative Syndrome (EUS) in the Philippines and Red Spot Disease (RSD) in Australia: Preliminary comparative studies. *Dis. aquat. Org.* **21**, 233-238.
- Dykstra, M.J., Levine, J.F., Noga, E.J., Hawkins, J., Gerdes, P., Hargis Jr., W.J., Grier H.T. and Te Strake, D. (1989) Ulcerative Mycosis: a serious menhaden disease of the southeastern coastal fisheries of the United States. *J. Fish Dis.* **12**, 175-178.
- Fraser, G.C., Callinan, R.B. and Calder, L.M. (1992) *Aphanomyces* species associated with Red Spot Disease: an ulcerative disease of estuarine fish from eastern Australia. *J. Fish Dis.* **15**, 173-181.
- Hatai, K., Egusa, S., Takahashi, S. and Ooe, K. (1977) Study on the pathogenic fungus of Mycotic Granulomatosis - I. Isolation and pathogenicity of the fungus from cultured ayu infected with the disease. *Fish Pathol.* **12**, 129-133.
- Lilley, J.H. and Roberts, R.J. (1997) Pathogenicity and culture studies comparing the *Aphanomyces* involved in Epizootic Ulcerative Syndrome (EUS) with other similar fungi. *J. Fish Dis.* **20**, 135-144.
- Noga, E.J., Levine, J.F., Dykstra, M.J. and Hawkins, J.H. (1988) Pathology of ulcerative mycosis in Atlantic menhaden *Brevoortia tyrannus*. *Dis. aquat. Org.* **4**, 189-197.
- Roberts, R.J., Willoughby, L.G. and Chinabut, S. (1993) Mycotic aspects of Epizootic Ulcerative Syndrome (EUS) of Asian fishes. *J. Fish Dis.* **16**, 169-183.
- Scott, W.W. (1961) A monograph of the genus *Aphanomyces*. *Virginia Agricultural Experimental Station. Technical Bulletin* **151**, Blacksburg, VA.
- Wada, S., Rha, S., Kondoh, T., Suda, H., Hatai, K., and Ishii, H. (1996) Histopathological comparison between Ayu and Carp artificially infected with *Aphanomyces piscicida*. *Fish Pathol.* **31**, 71-80
- Willoughby, L.G. and Roberts, R.J. (1994) Improved methodology for isolation of the *Aphanomyces* fungal pathogen of Epizootic Ulcerative Syndrome (EUS) in Asian fish. *J. Fish Dis.* **17**, 541-543.
- Willoughby, L.G., Roberts, R.J. and Chinabut, S. (1995) *Aphanomyces invaderis* sp. nov., the fungal pathogen of freshwater tropical fish affected by Epizootic Ulcerative Syndrome. *J. Fish Dis.* **18**, 273-275.