
VIMS Articles

5-1996

An unidentified haplosporidian parasite of bay scallop *Argopecten irradians* cultured in the Shandong and Liaoning provinces of China

FLE Chu

Virginia Institute of Marine Science

EM Burreson

Virginia Institute of Marine Science

F Zhang

K Chew

Follow this and additional works at: <https://scholarworks.wm.edu/vimsarticles>



Part of the [Aquaculture and Fisheries Commons](#)

Recommended Citation

Chu, FLE; Burreson, EM; Zhang, F; and Chew, K, "An unidentified haplosporidian parasite of bay scallop *Argopecten irradians* cultured in the Shandong and Liaoning provinces of China" (1996). *VIMS Articles*. 1582.

<https://scholarworks.wm.edu/vimsarticles/1582>

This Article is brought to you for free and open access by W&M ScholarWorks. It has been accepted for inclusion in VIMS Articles by an authorized administrator of W&M ScholarWorks. For more information, please contact scholarworks@wm.edu.

NOTE

An unidentified haplosporidian parasite of bay scallop *Argopecten irradians* cultured in the Shandong and Liaoning provinces of China

Fu-Lin E. Chu^{1,*}, Eugene M. Burreson¹, Fusui Zhang², Kenneth K. Chew³

¹School of Marine Science, Virginia Institute of Marine Science, College of William and Mary, Gloucester Point, Virginia 23062, USA

²Institute of Oceanology, Academia Sinica, Qingdao, People's Republic of China

³School of Fisheries, University of Washington, Seattle, Washington 98195, USA

ABSTRACT: Since 1988 growers of bay scallop *Argopecten irradians* in China have been experiencing mortality in their cultured stocks. Although poorly documented, mortality apparently began near Qingdao and has since spread to other areas of Shandong and Liaoning provinces. Samples of cultured scallops were collected from several growing areas in these provinces and analyzed by histological methods for pathogens. An unidentified haplosporidian parasite was observed in a high proportion of scallops from two of the stocks examined. Most infections were of low intensity, but one heavy infection was also observed. Only plasmodia stages were observed; they occurred intercellularly in connective tissues throughout the scallops. Plasmodia were spherical to oval, varied from 4.0 to 17.0 µm in diameter and contained from 2 to 18 nuclei. Absence of spores prevented generic assignment of the parasite. The source and pathogenicity of the haplosporidian could not be assessed without additional research. No other microbial parasites (i.e. rickettsia-like, chlamydia-like or kidney coccidia) were observed in any of the scallops examined.

KEY WORDS: *Argopecten irradians* · China · Culture · Haplosporidia · Histopathology · Parasite

The bay scallop *Argopecten irradians* was first introduced to China from the east coast of the United States in December 1982. Presently, bay scallop cultivation is one of the major aquaculture activities in China, particularly along the coasts of the Bohai and Yellow Seas in Shandong and Liaoning provinces (Fig. 1). Significant production was first achieved in 1987 and was recorded as 20–25 000 t live weight; production has increased steadily and was estimated at 220 000 and near 300 000 t live weight for 1993 and 1994 respec-

tively. Bay scallop growers in recent years have experienced problems with increasing mortality in their cultured scallops. Scallop mortality was first noticed in the Yang Ma Dao hatchery in 1988. Subsequently, scallop mortalities spread into other areas of the Shandong peninsula. In 1989 mortalities occurred in Jiaozhou Bay, in 1990 in Laoshan and Haiyang, in 1991 in the Jiaonan region, and in 1992 in Jimo, Penglai and Laizhou Bay (Shandong province) and in Dalian (Liaoning province). Currently, there is no adequate documentation of the mortality rate, but scallops usually die in the spring of each year, somewhat after spawning. Although little research has been conducted on the cause of mortality, it has been attributed to energetic stress resulting from spawning, and to diseases, because large numbers of juvenile scallops often died at the same time. Moribund scallops were characterized by mantle recession, with the mantle detached from the edge of the shell.

This paper reports the results of a histopathological study of adult bay scallops collected from several of the bay scallop growing areas of Shandong and Liaoning provinces while two of the authors, Fu-Lin E. Chu and Kenneth K. Chew, visited China under the Marine and Fishery Science and Technology Protocol between the US and China. The morphology of an unidentified haplosporidian parasite is described and its source and potential pathogenicity are discussed.

Materials and methods. Most samples were collected in March 1993, but some were collected in October 1993 (Table 1). At the Jiaonan scallop hatchery samples were taken from conditioned stocks of the following growing areas: Dazhusan, Zhaili counties, the shrimp pond of Hongshiya county and Laizhou Bay. At the Penglai hatchery, samples were taken from

*E-mail: chu@vims.edu

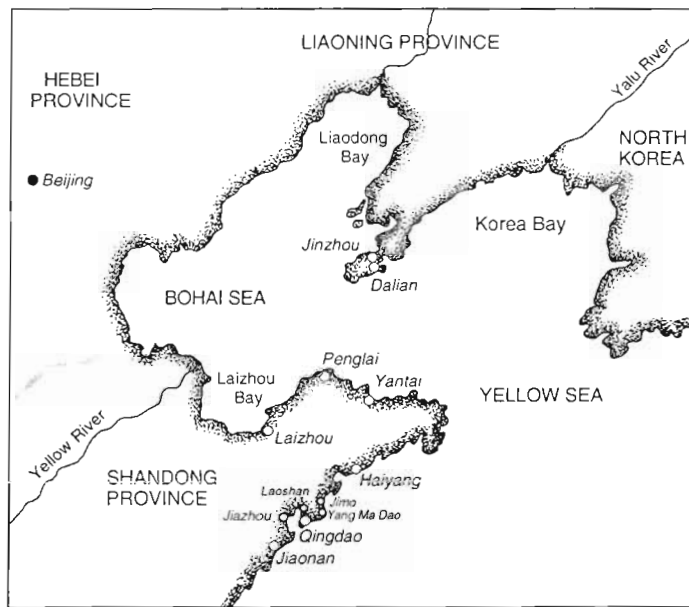


Fig. 1. Major bay scallop growing areas in the Shandong and Liaoning provinces of China

Fushan stocks. In addition, samples were collected from the growing areas in Laizhou Bay and Dalian Fisheries College. All of the scallops collected were adults ($n = 48$). Scallops were fixed whole in Davidson's fixative (Shaw & Battle 1957) for 24 to 48 h, rinsed in 70% ethanol and stored in 70% ethanol for histological processing. In October 1993, additional *Argopecten irradians* were collected at Jiaonan ($n = 12$) and Laizhou Bay ($n = 12$), and Pacific oysters *Crassostrea gigas* were collected at Qingdao ($n = 4$) and Laizhou Bay ($n = 10$).

Histological analyses were performed at the School of Marine Science, Virginia Institute of Marine Science, USA. A section of scallop tissue approximately 1 cm thick that included adductor muscle, gill, mantle,

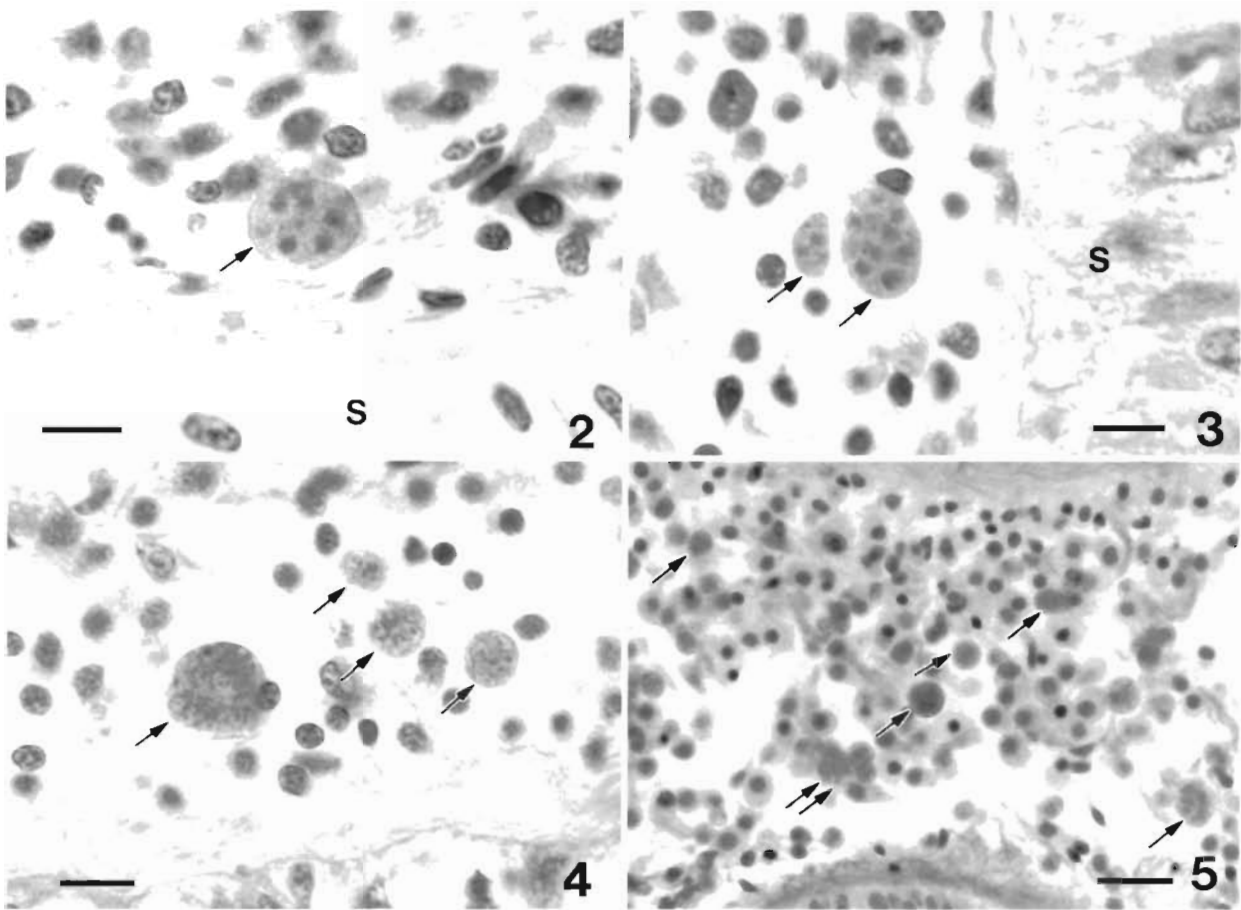
digestive gland and gonad was dehydrated and embedded in paraffin using standard histological techniques. In large scallops, the tissue section was cut into 2 pieces to facilitate embedding, sectioning and mounting on glass slides. Sections were cut at 5 μm , stained with Harris' hematoxylin and eosin and examined at 100 \times for the presence of parasites. A total of 40 haplosporidian parasites were measured with a calibrated ocular micrometer.

Results. Plasmodia of what appeared to be a haplosporidian parasite were observed in a high proportion of scallops from Fushan stock at the Penglai hatchery and from Zhaili stock at the Jiaonan hatchery (Table 1). The intensity of most infections was low (<1 plasmodium per 100 \times field), but one scallop at Penglai hatchery had a heavy infection (≥ 1 plasmodium per 400 \times field). Plasmodia were usually located intercellularly in the connective tissue adjacent to the stomach epithelium, but other sites included the connective tissue of the gonad and labial palps and hemal spaces of the adductor muscle.

Plasmodia were typically spherical to oval and contained 2 to 18 nuclei. The size of the spherical plasmodia varied from 4.0 to 17.0 μm in diameter; oval plasmodia ranged from 4.0 \times 6.0 to 15.5 \times 17.0 μm (Figs. 2 to 5). Nuclear morphology varied from uniform distribution of chromatin with a more or less central nucleolus (Fig. 4). In the scallop with the heaviest infection from Penglai hatchery, small, mostly spherical plasmodia averaging 6.0 μm in diameter were present throughout the connective tissue, but were concentrated in the labial palps (Fig. 5). From 2 to 6 nuclei were observed in these small plasmodia, but in many the internal morphology could not be discerned because of dark staining or lack of detail.

Table 1 *Argopecten irradians*. Prevalence of an unidentified haplosporidian parasite in samples of bay scallops from various growing areas in China

Location	Date collected	Mean shell height (mm) and range	No. of scallops infected/examined (%)
Jiaonan Hatchery:			
Dazhushan stock	18 Mar 1993	57.2 (49-63)	0/6 (0%)
Zhaili stock	18 Mar 1993	59.9 (54.5-66)	5/6 (83%)
Hongshiya shrimp pond stock	18 Mar 1993	58.6 (52-65)	0/6 (0%)
Laizhou Bay stock	18 Mar 1993	51.0 (42.5-61)	0/6 (0%)
Jiaonan	4 Oct 1993	47.7 (41-52)	0/6 (0%)
Laizhou Bay, Bohai Sea	19 Mar 1993	59.0 (55-67)	0/12 (0%)
	4 Oct 1993	49.0 (42-57)	0/12 (0%)
Penglai Hatchery:			
Fushan stocks	20 Mar 1993	55.7 (52-59)	6/6 (100%)
Dalian Fisheries College	23 Mar 1993	51.7 (45-57)	0/6 (0%)



Figs. 2 to 5. Unidentified haplosporidian parasite from *Argopecten irradians*. Figs. 2 & 3. Plasmodia from *A. irradians* from Zhaili stock at Jiaonan hatchery with uniform distribution of chromatin in nuclei. Fig. 2. Large plasmodium (arrow) in connective tissue adjacent to stomach epithelium (s). Scale bar = 10 μ m. Fig. 3. Large and small plasmodia (arrows) in connective tissue adjacent to stomach epithelium (s). Scale bar = 10 μ m. Figs. 4 & 5. Plasmodia from heavily infected *A. irradians* from Fushan stock at Penglai hatchery. Fig. 4. Large and small plasmodia (arrows) in connective tissue. Note nuclei with peripheral chromatin and central nucleolus. Scale bar = 10 μ m. Fig. 5. Concentration of small plasmodia (arrows) in connective tissue of labial palps; not all plasmodia are labeled. Double arrow indicates a cluster of 5 plasmodia. Scale bar = 20 μ m

The haplosporidian parasite did not stimulate widespread hemocyte infiltration in lightly infected scallops, although in some cases there was localized hemocyte infiltration adjacent to the stomach epithelium. However, there was moderate hemocyte infiltration in the scallop with a heavy infection from Penglai hatchery.

No prokaryotes or other eukaryote parasites were observed in histological sections of scallops. Noticeably absent were rickettsia-like organisms in the gills, chlamydia-like organisms in the digestive diverticula and kidney coccidia. No parasites or infectious disease agents were observed in any of the *Crassostrea gigas* examined.

Discussion. Haplosporidians were previously included along with the paramyxia in the phylum Asctospora, but recently both of these groups have been elevated to phylum rank and the Asctospora has been abandoned (Perkins 1991). The protistan parasite ob-

served during this study was determined to be a member of the phylum Haplosporidia on the basis of typical multinucleate plasmodia. The genus of the parasite cannot be determined because the spore stage was not observed. Haplosporidian parasites have not previously been reported from *Argopecten irradians* (Leibovitz et al. 1984, Karlsson 1990, Getchell 1991, Bower et al. 1994). Potential disease agents of *A. irradians* that are reported most often are chlamydia-like organisms in the digestive diverticula (Getchell 1991), rickettsia-like organisms in the gills (Getchell 1991) and coccidia in the kidney epithelium (Whyte et al. 1994), but the lesions caused by these organisms are not well studied. None of these latter organisms was observed in *A. irradians* from China. *Perkinsus karlssoni* has been implicated in mortality of juvenile *A. irradians* in Nova Scotia, Canada (McGladdery et al. 1991), but this parasite was not observed during the present study.

It is impossible to determine at this time if the haplosporidian parasite is endemic to China or was introduced with the importation of *Argopecten irradians* from the east coast of the United States. No haplosporidian parasite has been observed in *A. irradians* from the United States so it seems unlikely that the parasite was introduced. However, an undescribed species of *Marteilia*, a genus previously grouped with the haplosporidia in the phylum Ascetospora but now placed in the phylum Paramyxea, has recently been implicated in mass mortalities of calico scallops *Argopecten gibbus* in Florida, USA (Moyer et al. 1993). Cells of *Marteilia* spp. are usually restricted to the epithelium of the gut (Villalba et al. 1993) and sporulation stages are commonly observed, usually in large numbers, in the epithelium of digestive diverticula. Multinucleate plasmodia are not known from *Marteilia* spp. The presence of plasmodia in the connective tissues strongly suggests that the unidentified haplosporidian in *A. irradians* is not related to *Marteilia*.

An undescribed haplosporidian is known from *Crassostrea gigas* in Korea (Kern 1976) and has also been observed in *C. gigas* seed oysters imported from Japan (Friedman et al. 1991). Plasmodia are distributed throughout the connective tissues. The plasmodia reported in *C. gigas* are similar to those observed in *Argopecten irradians* from China and it is possible that the parasites are the same species. No similar parasites were observed in the few *C. gigas* sampled from the scallop growing areas of China, but the parasite in *C. gigas* is known to be uncommon and, in the present study, *C. gigas* was not collected from areas where the parasite was present in scallops.

The haplosporidian in *Argopecten irradians* is not similar to the 2 unidentified protistan parasites reported by Bower et al. (1992) from Japanese scallops *Patinopecten yessoensis* cultured in British Columbia, Canada. None of the observed stages of these parasites, designated SPX and SPG, was a multinucleated plasmodium. The pathogenicity of the haplosporidian parasite cannot be determined without further study. Most observed infections were light, suggesting minimal mortality at least at that sampling point. However, the presence of at least one heavy infection at Penglai hatchery suggests that the parasite is capable of developing in *A. irradians* and has the potential to cause mortality. Seasonal sampling of live scallops from all growing areas would permit documentation of the prevalence, intensity, and distribution of the infections, and, in conjunction with documented scallop mortality, would provide data for assessing pathogenicity. Sampling of dying or dead scallops that still contain

tissue would provide additional data on the relationship between the presence of the parasite and scallop mortality.

Acknowledgements. The authors thank J. Walker, S. Li, and G. Constantin for their invaluable technical assistance, Dr Q. Xue for assistance with bay scallop sampling, and Ms S. Blake and Drs J. Shield and R. Hale for reviewing of the first draft of the manuscript. Virginia Institute of Marine Science Contribution no. 1971.

LITERATURE CITED

- Bower SM, Blackbourn J, Meyer GR, Nishimura DJH (1992) Diseases of cultured Japanese scallops (*Patinopecten yessoensis*) in British Columbia, Canada. *Aquaculture* 107:201–210
- Bower SM, McGladdery SE, Price IM (1994) Synopsis of infectious diseases and parasites of commercially exploited shellfish. *A Rev Fish Dis* 4:1–199
- Friedman CS, Cloney DF, Manzer D, Hedrick RP (1991) Haplosporidiosis of the Pacific oyster, *Crassostrea gigas*. *J Invertebr Pathol* 58:367–372
- Getchell RG (1991) Diseases and parasites of scallops. In: Shumway SE (ed) *Scallops: biology, ecology and aquaculture*. Elsevier, New York, p 471–494
- Karlsson JD (1990) Parasites of the bay scallop, *Argopecten irradians* (Lamarck, 1819). In: Shumway SE, Sandifer PA (eds) *An international compendium of scallop biology and culture*. World Aquaculture Workshops, No. 1 The World Aquaculture Society, Louisiana State University, Baton Rouge, p 180–190
- Kern FG (1976) Sporulation of *Minchinia* sp. (Haplosporida, Haplosporidiidae) in the Pacific oyster *Crassostrea gigas* (Thunberg) from the Republic of Korea. *J Protozool* 23(4): 498–500
- Leibovitz L, Schott EF, Karney RC (1984) Diseases of wild, captive and cultured scallops. *J World Maricult Soc* 15: 269–283
- McGladdery SE, Cawthorn RJ, Bradford BC (1991) *Perkinsus karlssoni* n. sp. (Apicomplexa) in bay scallops *Argopecten irradians*. *Dis Aquat Org* 10:127–137
- Moyer MA, Blake NJ, Arnold WS (1993) An ascetosporan disease causing mass mortality in the Atlantic calico scallop, *Argopecten gibbus* (Linnaeus, 1758). *J Shellfish Res* 12(2): 305–310
- Perkins FO (1991) 'Sporozoa': Apicomplexa, Microsporidia, Haplosporidia, Paramyxea, Myxosporidia, and Actinosporidia. In: Harrison FW, Corliss JO (eds) *Microscopic anatomy of invertebrates*, Vol 1, Protozoa. Wiley-Liss, New York, p 261–331
- Shaw BL, Battle HI (1957) The gross and microscopic anatomy of the digestive tract of the oyster *Crassostrea virginica* (Gmelin). *Can J Zool* 35:325–347
- Villalba A, Mourelle SG, López MC, Carballal MJ, Azevedo C (1993) Marteiliasis affecting cultured mussels *Mytilus galloprovincialis* of Galicia (NW Spain). I. Etiology, phases of the infection, and temporal and spatial variability in prevalence. *Dis Aquat Org* 16:61–71
- Whyte SK, Cawthorn RJ, McGladdery SE (1994) Co-infection of bay scallops *Argopecten irradians* with *Perkinsus karlssoni* (Apicomplexa, Perkinsea) and an unidentified coccidian parasite. *Dis Aquat Org* 18:53–64