

Summer 6-21-2004

Analysis of Two Human Skeletons from Smith's Fort, Bermuda

Michael L. Blakey

College of William and Mary, mblak@wm.edu

Autumn Barrett

College of William and Mary

Follow this and additional works at: <https://scholarworks.wm.edu/ihbpub>



Part of the [Biological and Physical Anthropology Commons](#)

Recommended Citation

Blakey, Michael L. and Barrett, Autumn, Analysis of Two Human Skeletons from Smith's Fort, Bermuda (2004).

<https://scholarworks.wm.edu/ihbpub/3>

This Article is brought to you for free and open access by the Institute for Historical Biology at W&M ScholarWorks. It has been accepted for inclusion in Institute for Historical Biology Articles & Book Chapters by an authorized administrator of W&M ScholarWorks. For more information, please contact scholarworks@wm.edu.

Analysis of Two Human Skeletons from Smith's Fort, Bermuda

By:

Michael L. Blakey, Director
Autumn Barrett, Graduate Research Associate
Institute for Historical Biology
Department of Anthropology
College of William and Mary
Williamsburg, Virginia
USA

To:

Edward C. Harris, Director
Bermuda Maritime Museum
Bermuda
and
Norman F. Barka, Principal Investigator and Professor
Department of Anthropology
College of William and Mary
Williamsburg, Virginia
USA

Report No. 3, Institute for Historical Biology, 21 June 2004

Table of Contents

I.	Skeletal Analysis Report	
	Historical and Political-Economic Context	1
	Settlement and Original Fortification of Bermuda	1
	Economic and Political Transition and Refortification	3
	Smith's Fort Burials	4
	Labor and the Refortification of Bermuda	6
	Condition of the Skeletal Remains	7
	Skeletal Analysis	10
	South Burial	11
	North Burial	23
	Population Affiliation	31
	Conclusions	33
	Acknowledgements	35
	Bibliography	36
II.	Appendix A: South Burial	
	a. Inventory Recording Form for Complete Skeletons	
	b. Photographic Inventory	
	c. Photograph Log	
	d. Anthropometric Record	
	e. Dental Inventory: Visual Recording Form	
	f. Dental Measurement	
	g. Enamel Defect Measurement	
III.	Appendix B: North Burial	
	a. Inventory Recording Form for Complete Skeletons	
	b. Photographic Inventory	
	c. Photograph Log	
	d. Anthropometric Record	
	e. Dental Inventory: Visual Recording Form	
	f. Dental Measurement	
	g. Enamel Defect Measurement	

The excavation of a portion of Smith's Fort, Bermuda, was led by Norman Barka of the College of William and Mary during the summers of 2000 and 2001. Excavation revealed two burials located within the merlons of the Fort's upper battery. The remains of the two individuals were kept in the Bermuda Maritime Museum before they were transferred to the Institute for Historical Biology by the Museum's director, Edward C. Harris. The remains of both individuals were inventoried and cleaned with deionized water and soft brushes prior to analysis by the Institute's staff. This is the first report of their analysis.

Historical and Political-Economic Context

Settlement and Original Fortification of Bermuda

Juan Bermudéz encountered Bermuda in the early sixteenth century and found the island to be empty of inhabitants. There is no archaeological evidence to indicate human habitation on the Bermuda islands prior to European encounter (Harris 1997: 37). The *Sea Venture*, bound for Jamestown, came upon a storm that caused them to go off course and take shelter in Bermuda. The crew lived for ten months off of fish and the wild hogs found on the island while building the *Patience* and the *Deliverance* from Bermuda cedar wood in order to make their intended journey to James Fort, Virginia.¹ However, a permanent settlement was not established in Bermuda until 1612, with Richard Moore as the first governor, becoming England's second American colony.

Bermuda's earliest fortification took place between 1612 and 1622, during which time eleven forts were constructed primarily under governors Richard Moore (1612 – 1616) and

¹ Edward C. Harris, *Bermuda Forts* (1997), 45.

Nathaniel Butler (1619 – 1622)². The eastern coast of Bermuda was more vulnerable to attack because it lacked the reefs as protection against entering St. George’s Harbor. Prior to the 1920s, the channel through Governor’s Island and Paget Island was the only access to the

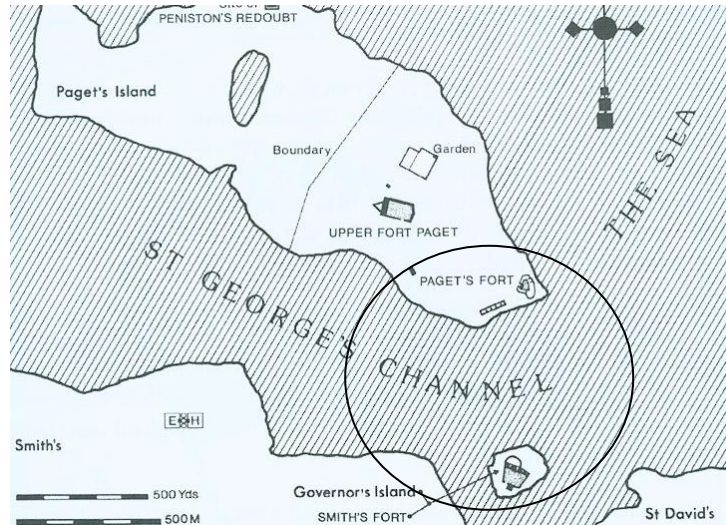


Figure 1: Map illustrating the strategic locations of Paget’s Fort and Smith’s Fort in defending the entrance into St. George’s Harbor³

Town of St. George by sea.⁴ Therefore the fortification of this passage through the construction of Paget fort to the north of the channel (1612) and Smith’s fort to the south of the channel (1613) were strategically crucial to safeguarding the Islands. Fortification of Bermuda’s western and southern coasts continued into the eighteenth century, so that by 1783, approximately fifty forts protected Bermuda’s periphery.⁵

² Ibid., 48 – 79.

³ Modified from Harris, 1997: 135.

⁴ Ibid., 55.

⁵ Ibid., 126.

Economic and Political Transition and Refortification

Bermuda underwent what Michael Jarvis has referred to as a “Maritime Revolution” after the dissolution of the Somers Island Company in 1684. Bermuda was transformed from an agricultural economy, primarily growing tobacco, to an economy based on Atlantic trade and constructing ships.⁶ Enslaved labor was increasingly employed in building ships as well as providing the majority of crew members for merchant fleets by the late 1700’s.⁷ During the seventeenth and eighteenth centuries, enslaved Pequot and Mohawk Indians and enslaved Africans were transported to Bermuda.⁸

The American Revolution and the Declaration of Independence in 1776 drastically changed the commercial relationships that Bermuda held with North America. Although Bermuda engaged in smuggling activities with the North American colonies throughout the conflict, the Bermuda colony remained loyal to the Crown.⁹ Following the end of the Revolutionary War in 1783, Bermuda became a focal point in English military interest. England forfeited valuable naval bases along the eastern coast to the nascent United States and sought to recuperate losses through increased fortification in Bermuda.¹⁰ The 1780s and 1790s, involved an intense period of refortification to increase British military bases and to ensure defense in the case of an American attack.¹¹ British military officers and members of the Royal Corps of Engineers were sent to Bermuda during this refortification period.

⁶ Michael Jarvis, *“In the Eye of All Trade”: Maritime Revolution and the Transformation of Bermudian Society, 1612 – 1800* (1998), xi.

⁷ Ibid.

⁸ Kathleen Bragdon, “Native Americans in Bermuda.” *Bermuda Journal of Archaeology and Maritime History*.

⁹ Harris, *Bermuda Forts*, 129. Jarvis, *“In the Eye of All Trade,”* xi.

¹⁰ Harris, *Bermuda Forts*, 129.

¹¹ Jarvis, *“In the Eye of All Trade,”* xi.

Financial interests of the British Crown shifted from commercial activity in the Atlantic to “toward meeting the domestic needs of the island’s garrison.”¹² Another transition occurred in Bermudian economy so that by the middle of the nineteenth century, Bermuda had returned to an agriculturally based economy and the “shipbuilding industry and merchant fleet had been almost completely abandoned.”¹³

Andrew Durnford, a member of the Royal Corps of Engineers, was commissioned to refortify Bermuda in 1788. Durnford ordered a survey of Bermuda, which was the first to be completed since Richard Norwood’s in 1663 and required five years to complete.¹⁴ Smith’s fort on Governor’s island was refortified in 1793 by strengthening the original lower battery constructing an upper battery that included four merlons approximately fifteen feet thick and four emplacements through which four guns were mounted (in addition to the eight mounted in the lower battery).¹⁵

Smith’s Fort Burials

During excavations of Smith’s fort in the summers of 2000 and 2001 conducted by archaeological teams from the College of William and Mary under the direction of Dr. Norman F. Barka, two burials were excavated from within the merlons of the upper battery. The individuals were buried within wooden coffins with possible indications of shrouding.¹⁶ The burials are oriented in a Southwest, Northeast position, with their heads facing the Southwest. Careful placement of the burials located each individual within the center of the second and third merlons of the upper battery. Burial goods were associated with the South

¹² Ibid.

¹³ Ibid.

¹⁴ Harris, *Bermuda Forts*, 131.

¹⁵ Ibid., 136-7.

¹⁶ Barka, personal communication, 2003.

Burial, including five buttons, an iron ring and a coin. The stratigraphy indicates that the individuals were buried during the construction of the merlons, rather than having been interred.

While the military presence of the Royal Navy as well as enslaved militia men in the 1790s may indicate that these individuals were in the military, the absence of artifacts identified as military in association, coupled with the stratigraphic context and lack of grave markers suggests that these graves are not military.¹⁷ As C. Adinolfi's 1995 study of the Royal Naval Cemetery in Bermuda demonstrates, graves for seamen as well as admirals were marked, whether by headstones or elaborate monuments.¹⁸ Adinolfi also notes that monuments were erected for those who died at sea, from disease such as yellow fever, and commemorating children.¹⁹ However, Adinolfi's study places the Royal Naval Cemetery within the "rural cemetery movement" studied by Edmund Gillon. According to Gillon, European cemeteries underwent a transition from burials on personal property, to burial within church cemeteries and then pastoral settings for cemeteries by the beginning of the nineteenth century.²⁰ Grave markers in the form of headstones and monuments commemorating the lives of the deceased within burial grounds for the free, enslaved and military existed in Bermuda in the late eighteenth century. The burial of these two individuals within the fort reflect a burial pattern inconsistent with the Victorian tradition and the "rural movement" discussed by Adinolfi.

The stratigraphic context and burial within the fort during the construction of the upper battery under Andrew Durnford, suggests that the two individuals may have been

¹⁷ Future analysis of the buttons, coin and iron ring may provide alternative interpretations.

¹⁸ Christina Adinolfi, *The Symbolic Nature of Mortuary Art in the Royal Naval Cemetery on Ireland Island, Bermuda 1800 – 1899*, (1995) 26.

¹⁹ Ibid.

²⁰ Ibid., 21.

laborers in the reconstruction process that took place in Bermuda during the late eighteenth century.

Labor and the Refortification of Bermuda

On June 13, 1793, the same year during which refortification of Smith's fort was occurring, Governor Henry Hamilton "ordered that each parish was to provide a quota of six 'stout Negroes' to complete some of the batteries and other works on the coast."²¹ An increased reliance on enslaved labor for the economic success of Bermuda during the seventeenth hundreds included the refortification efforts under Durnford.²² The Hamilton Parrish vestry records indicate that enslaved Bermudians were to work "for a period of four months and to be sent to different parts of the island to finish the work" of rebuilding the forts.²³

Each being provided with a Hoe, Pick or Shovel, they shall receive during their employ a full ration of Corn, Pork & Rum, and should the Legislature at their next meeting decline paying the proprietors the usual price of labor, I promise to make it good on the part of the Govt. The Engineer having reviewed the South, S. West and Northern Parts of the Coast has determined to raise batteries in diff. parts for the protection of the several bays and landings (on which the Negroes will chiefly be employed).²⁴

During the 1700s and early 1800s, enslaved labor was employed in a wide range of occupations including local fishing, whaling and sailing, salt production, Atlantic trade, merchant crews, masonry, stone cutters, carpentry, and shipbuilding.²⁵ Free laborers also

²¹ James E. Smith, *Slavery in Bermuda*, (1976), 121.

²² James E. Smith, *Slavery in Bermuda*, (1976), 121; Cyril Outerbridge Packwood, *Chained on the Rock*, (1975), 18-19; Jarvis, "In the Eye of All Trade," 374.

²³ Smith, *Slavery in Bermuda*, 121.

²⁴ *Ibid.*

²⁵ See James Smith, *Slavery in Bermuda* (1976), Cyril O. Outbridge, *Chained on the Rock* (1975), Virginia Bernhard, *Slaves and Slaveholders in Bermuda: 1616 – 1782* (1999), Jarvis, "In the Eye of All Trade." vols. 1 and 2.

engaged in these occupations, but as Jarvis discusses, enslaved labor was increasingly used within each of these categories and enslaved people would likely have engaged in more than one occupation during a lifetime.²⁶

Condition of the Skeletal Remains

Postmortem changes to the remains of the two individuals were evident primarily in postmortem fractures, exfoliation and rodent gnawing. The north burial had evidence of exposure to wet/ dry conditions. The remains of this individual were more fragile than the skeleton from the south burial and exfoliation occurred throughout the entire skeleton. Postmortem fractures were present in the left humerus, right femur, left tibia, both fibula and several of the ribs. The scapulae had slight fractures on the superior angles and the right scapula was fractured in the body near the medial border. The vertebrae were slightly fractured, primarily along the spinous processes. The left first metacarpal and several metatarsals and foot phalanges had evidence of rodent gnawing. The foramen magnum was damaged circumferentially due to rodent activity or trowel damage.

²⁶ Jarvis, *"In the Eye of All Trade."* vol 2.



Figure 2: First metacarpal on the left hand (north burial) displaying evidence of rodent gnawing




Figure 3: Damage to the foramen magnum, possibly rodent or trowel damage (north burial)

The south burial was in much better condition, with very little exfoliation and only slight fracturing, and no complete fractures of the long bones. The remains of the south burial were nearly complete as well. The right tibia displayed evidence of damage with iron embedded in

the anterior diaphysis. However, the cause is most likely a postmortem reaction to the iron ring indicated by the archaeologists to have been in contact with the anterior of the right tibia. Green staining, similar in appearance to copper staining, was noted on the left ribs and the left humerus. The stains on the ribs may correspond to the presence of buttons and a coin noted by the archaeologists, but there is no indication at this time as to the cause of staining on the left humerus. Iron stains on the leg, arm, feet and hands may be a result of coffin nail contact.

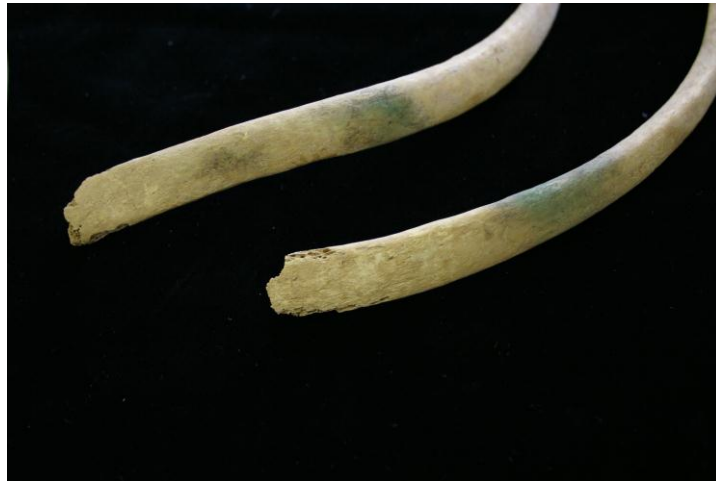

Figure 4: Staining on the left ribs (south burial)

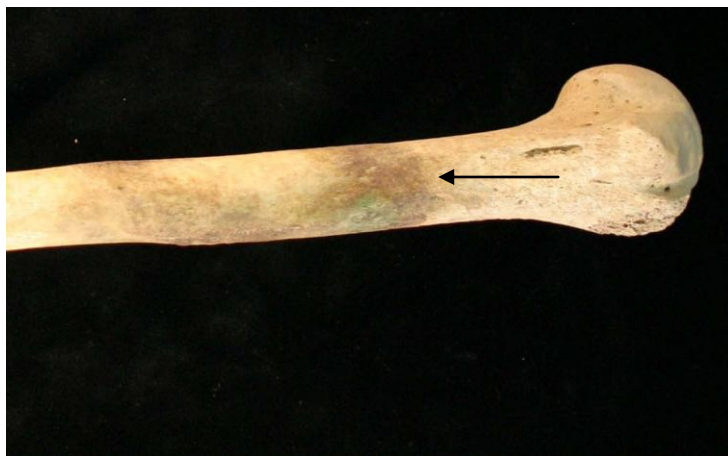

Figure 5: Proximal half of the left humerus (south burial)

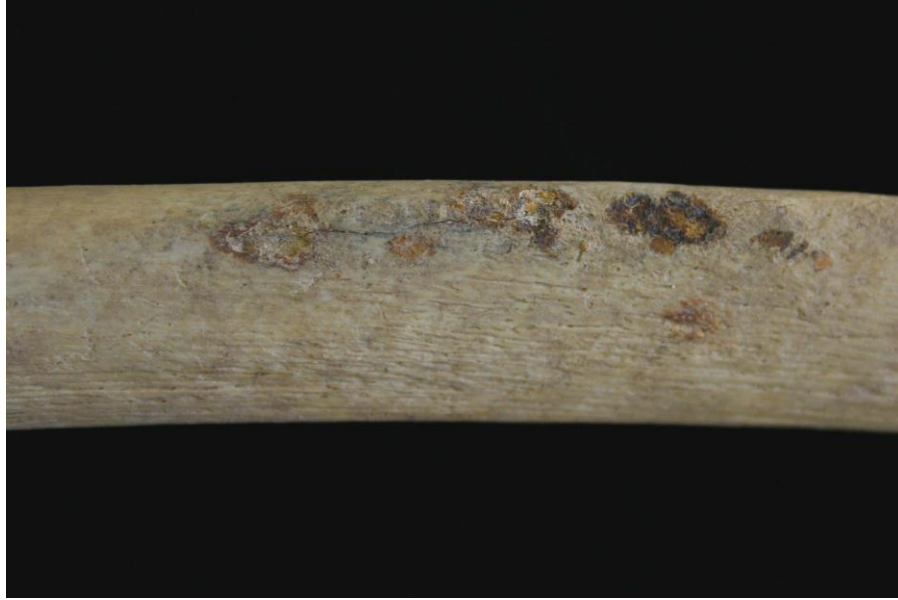

Figure 6: Damage and staining on the anterior of the right tibia due to contact with an iron ring (south burial)

Skeletal Analysis

Age, sex, stature, pathologies and occupational markers were assessed for each individual. The individual excavated from the south burial, with associated grave goods, was determined to be male. Sex was assessed by observing subpubic concavity, ventral arc, the ischiopubic ramus, the greater sciatic notch and preauricular sulcus on the pelvis as well as cranial morphology of the nuchal crest, the mastoid process, the supra-orbital margin, supra-orbital ridge and the mandibular mental eminence.

South Burial

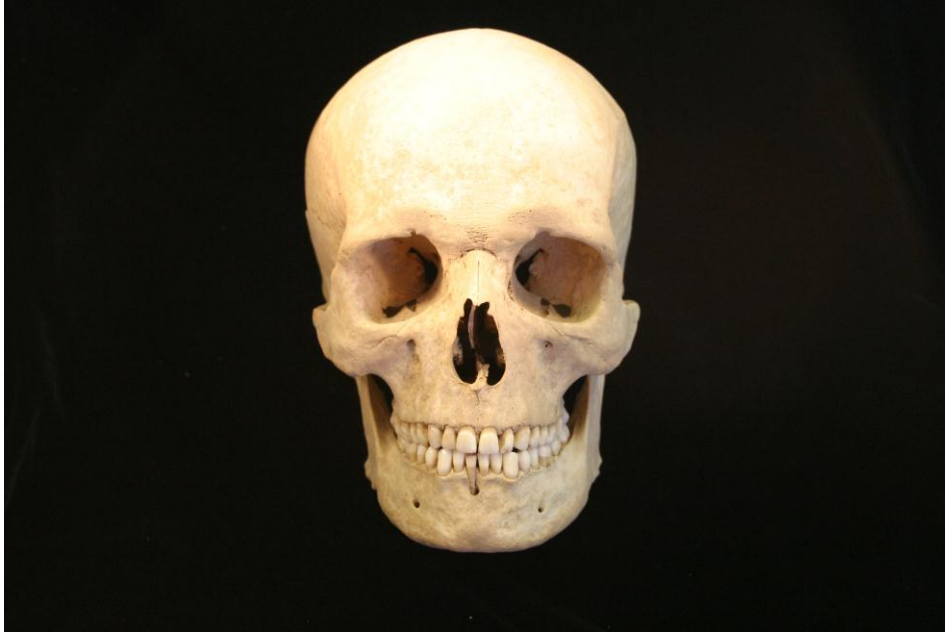

Figure 7: Anterior view of the skull (south burial)

Table 1: Sex Assessment (south burial)

Sex Assessment	
Technique	Scale 1 (female) to 3 or 5 (male)
Pelvis: subpubic concavity (1-3)	3
ventral arc (1-3)	3
ischiopubic ramus ridge (1-3)	3
greater Sciatic Notch (1-5)	4
preauricular Sulcus (0-4)	3
Skull: nuchal crest (1-5)	2
mastoid process (1-5)	5
supraorbital margin (1-5)	5
Glabella (1-5)	3
Mental eminence (1-5)	4

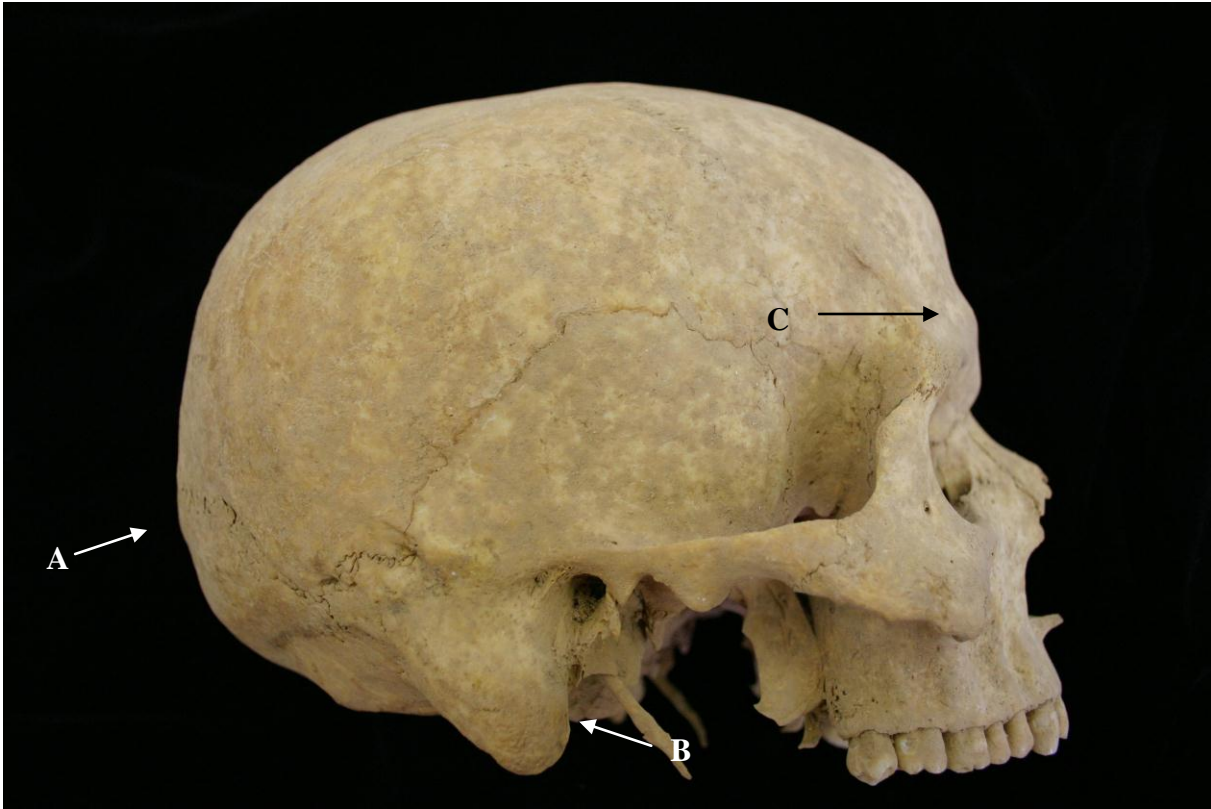

Figure 8: Cranium of the south burial adult male indicating the nuchal crest (A), mastoid process (B) and glabella (C) assessed for sexing.

Sex indicators were assessed as male according to the guidelines set forward by the *Standards* (Buikstra and Ubelaker 1994).²⁷

²⁷ Jane Buikstra and Douglas Ubelaker, *Standards*, (1994), 16-21.

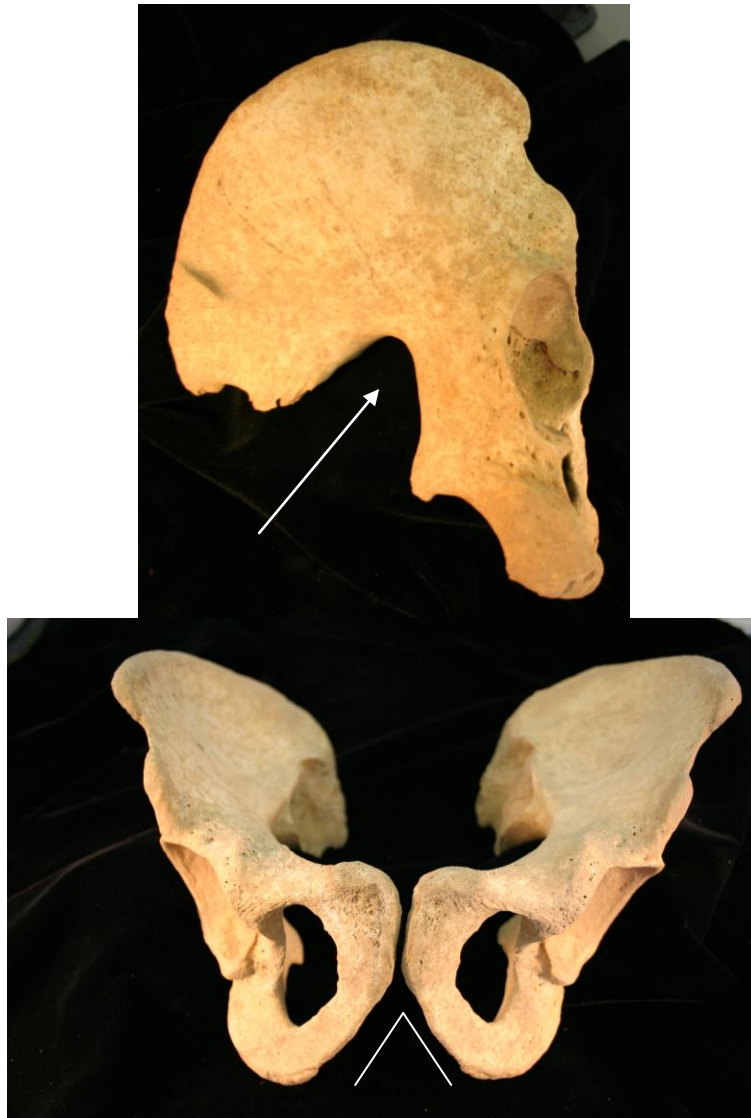

Figure 9: Innominate with an arrow pointing to the greater sciatic notch angle (top) and the subpubic angle (bottom) assessed for sexing (south burial)

Once the human skeleton reaches adulthood, developmental changes are more difficult to age beyond larger age ranges. Depending on factors such as diet, health and mechanical stressors, the adult skeleton may provide indicators for ages younger or older than their age in years at the time of death. The Suchey-Brooks pubic symphysis,²⁸ Todd pubic symphysis,²⁹

²⁸ See Buikstra and Ubelaker, *Standards*, 1994; Bass, *Human Osteology*, 1995 and White, *Human Osteology* 2000.

²⁹ *Ibid.*

Lovejoy et al. 1985 auricular surface,³⁰ *Standards* auricular surface,³¹ Brothwell 1965 tooth wear to age correlation,³² fusion of the cranial sutures, and epiphyses of the sacrum and sternum, as well as the Isçan et. Al 1984 sternal end of the fourth rib³³ aging techniques were employed. The following chart summarizes the findings of these combined aging techniques for adult remains.

Table 2: Age Assessment (south burial)

Age Assessment		
Technique	Assessment	Age Range Indicated
Suchey-Brooks pubic symphysis	Phase 4	23 – 57 years
Todd pubic symphysis	Phases 7 – 9	35 - 49 years
Isçan et al, 1984 sternal end of the fourth rib	Phase 5	34.4 – 42.3 years
<i>Standards</i> auricular surface	Phases 4 - 5	35 – 44 years
Lovejoy et al. Auricular Surface	Upper Phase 5, lower Phase 6	44 – 45 years
Brothwell, 1965 tooth wear pattern and age correlation	Age category 1	17 – 25 years
Sacral vertebrae epiphyseal fusion	Almost completely fused	Fusion begins at age 17 and continues into the 30s, age of the individual is in the 30s
Sternal end of clavicle epiphyseal fusion	Completely fused	Fusion is complete by 30 years of age, age of the individual is over 30
Standards composite suture closure age ranges after Meindle and Lovejoy 1985	Composite score for cranial vault and lateral-anterior sutures = S3	27 – 44 years

This individual’s age at death was assessed with a low age of 27 years and a high age of 57 years, with the probable age range between 34 and 49 years. While most age assessment methods indicate that this individual was between 34 and 49 years of age at death, his tooth wear pattern falls within a much younger age pattern. These wear patterns most likely reflect

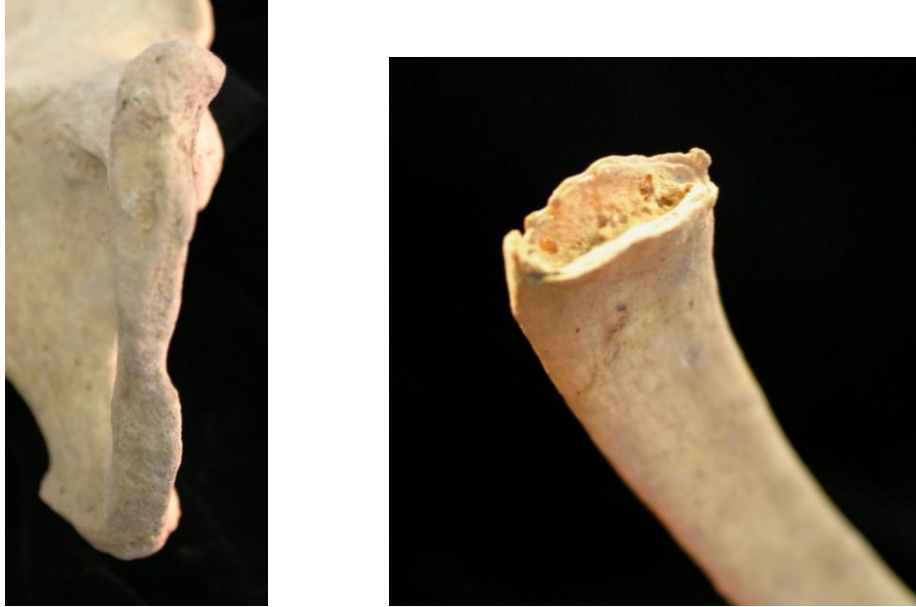³⁰ David White, *Human Osteology* (2000), 358.

³¹ Jane Buikstra and Douglas Ubelaker, *Standards*, (1994), 27-28.

³² William Bass, *Human Osteology: A field manual* (1995), 301.

³³ William Bass, *Human Osteology: A field manual* (1995), 143.

diet rather than chronological age at death. The Todd pubic symphysis aging technique provided a more precise age range and was, therefore, favored in the final analysis over the Suchey-Brooks method, though the age assessed using the Todd method fell within the range assessed using the Suchey-Brooks method.



**Figure 10: Pubic symphysis (left) and the sternal end of the fourth rib (right)
(south burial)**



Figure 11: Auricular surface (south burial)

Stature was assessed using the method of Trotter and Gleser (1952) in Bass (1995).

The Trotter and Gleser method estimates stature based on the maximum length of the Humerus, Radius, Ulna, Femur, Tibia and Fibula. This individual's height was assessed to be between 5 feet 4 inches and 5 feet 6 inches.

Table 3: Stature Assessment (south burial)

Element	Length (mm)	Stature Estimate (cm)
Humerus	310	166
Radius	225	164
Ulna	241	163
Femur	447	167.5
Tibia	357	168.5
Fibula	350	165.5

This individual had very few enamel defects or pathologies within his dentition, with the exception of one abscess located below the right mandibular central incisor. The

pathology assessment indicated active and healed porotic hyperostosis on the cranium, as well as active cribra orbitalia in both eye orbits. Porotic hyperostosis is the operational term for pitting in the cranium and cribra orbitalia refers to pitting within the eye orbits. Porotic hyperostosis indicates an anemic reaction due to dietary deficiency, parasitic infection or diseases, including treponemal disease, thalassemia, nonspherocytic hemolytic anemia and cycle cell anemia. Pitting is caused by the expansion of the bone marrow to facilitate transportation of iron through the blood stream via increased red blood cell production.³⁴ The pervasiveness of the pitting beyond the parietal, occipital, frontal bones and eye orbits, including the nasal bones, the tori, and the palate bones indicates a reaction to disease rather than a dietary source of anemia.



Figure 12: Active and healed periostitis on the anterior-medial aspect of the right tibia. The arrows point to reactive woven lamellar reaction indicating active infection at the time of death (south burial)

The adult male also exhibited reactive woven and sclerotic inflammatory bone responses to infection, also termed periostitis. The adult had active infection at the time of death in the right humerus and the right tibia. Reactive woven bone displays sharp edges and is indicative of active infection at the time of death. Sclerotic periostitis displays more rounded edges and indicates past infection that has healed.

³⁴ See Angel, 1966.

This individual had evidence of osteoarthritis and mechanical stress in the lumbar, thoracic and cervical vertebrae as indicated by the presence of Schmorl's nodes. Schmorl's nodes are depressions in the centrum of the vertebrae and indicate pathology due to age and heavy labor including heavy lifting. Heavy mechanical stress is also indicated by a unilateral spondylolysis or fracture in the fifth lumbar vertebra of this individual, which is only slightly healed and occurred within a few weeks prior to death.

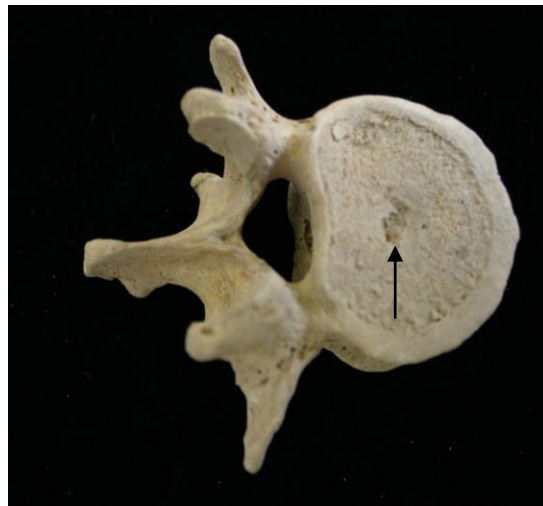


Figure 13: Schmorl's Node depression on the second lumbar vertebrae (south burial)

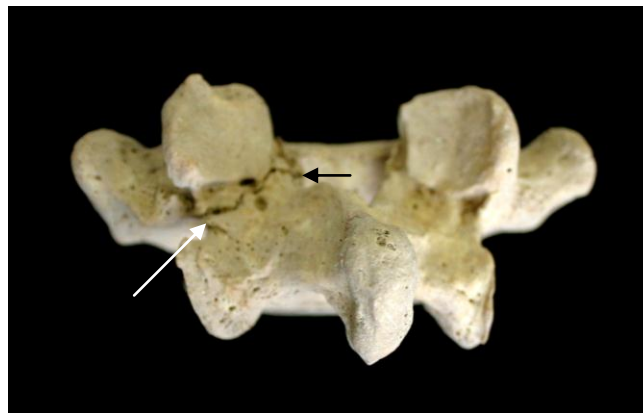


Figure 14: Unilateral spondylolysis of the fifth lumbar vertebra

The upper body, including the clavicles, humeri, radii and ulnae exhibit hypertrophied muscle and ligament attachments that result from repetitive heavy labor using the muscles of the

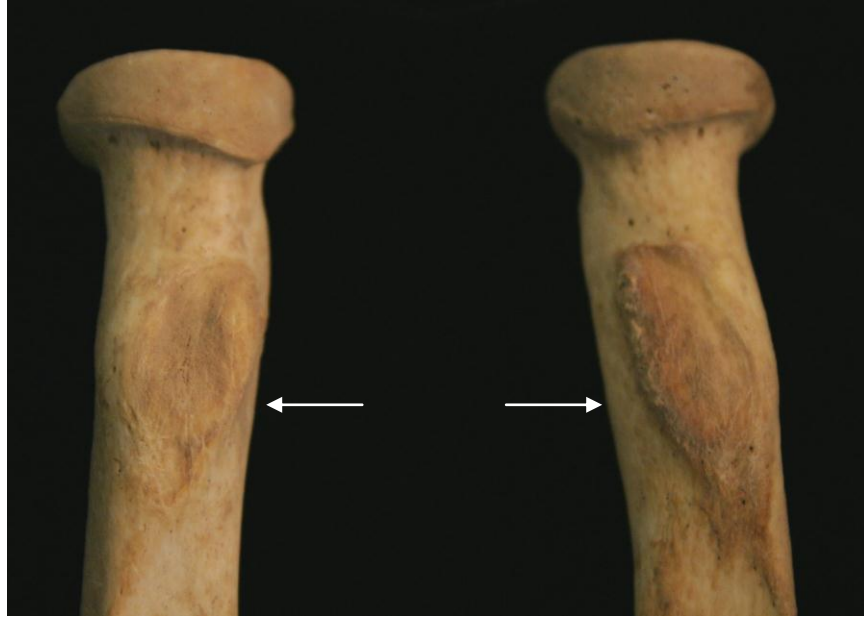

Figure 15: Hypertrophic biceps brachii attachments on the radii (south burial)

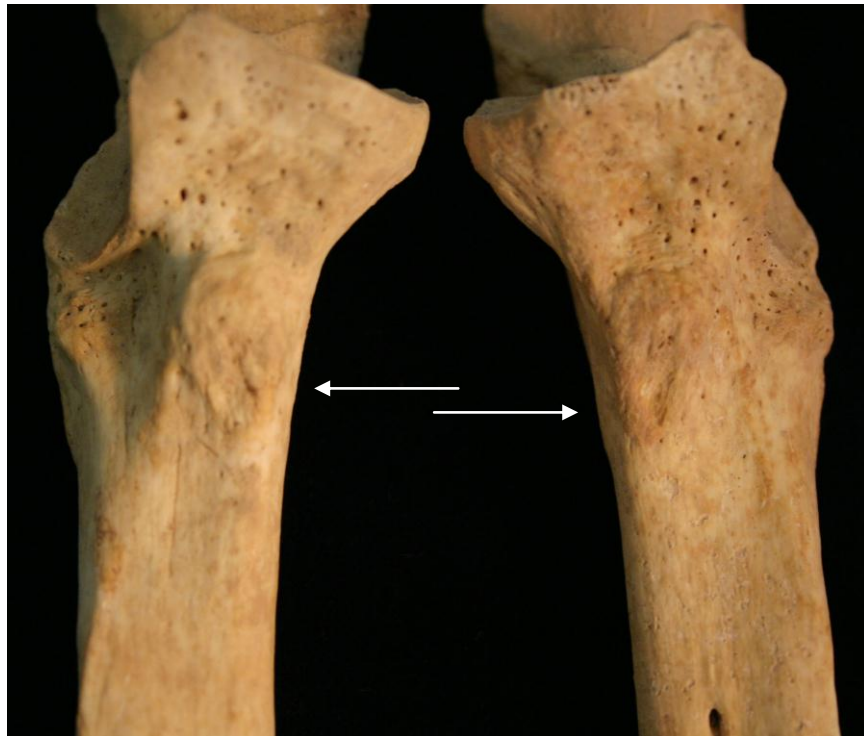

Figure 16: Hypertrophic brachialis insertions on the ulna (south burial)

upper body including the upper back, chest muscles and arm muscles. The sternal ends of the clavicles exhibit costoclavicular syndesmosis, which are lesions on the costal tuberosity.

Capasso et al. (1999) describe the movement related to these indicators as “generalized stress of the pectoral girdle” which “results in this lesion, particularly when the shoulders are bent forward while bending and moving heavy loads.”³⁵

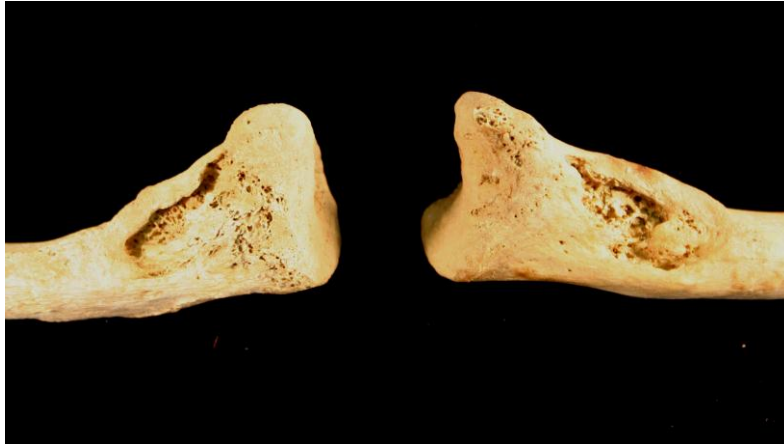


Figure 17: Costo-clavicular syndesmosis of the clavicles (Adult Male, South Burial)

Occupations associated with this costo-clavicular syndesmosis, as observed in past populations, include ploughing and agricultural work, “carrying heavy weights hanging from the shoulders, stone-house building, and hunting.”³⁶ The scapular borders of this individual display “lateral extension” associated with the teres major and minor muscle attachments and indicate movement involving “scapular rotation when the arms are raised above shoulder height and then pushed down against an outside force, or when extended arms are being used to support body weight.”³⁷ Kayaking is a movement that caused this skeletal indicator in past populations,³⁸ but may be related to occupational activities such as rowing, sailing, piloting or perhaps stone cutting and tree felling. This individual engaged in heavy labor during his

³⁵ Luigi Capasso, Kenneth Kennedy and Cynthia Wilczak, *Atlas* (1999), 52.

³⁶ *Ibid.*

³⁷ *Ibid.*, 62.

³⁸ Capasso et al., 52.




Figure 18: Bermudian stone cutter in the early 1900s. Bermuda soft limestone is able to be cut with a handsaw and hardens when exposed. This limestone was used in Bermuda fortifications.³⁹

lifetime and the high levels of hypertrophic muscle and ligament attachments indicate that he used his upper body extensively and, while he did display prominent hypertrophy of the gluteus maximus attachment in the posterior femur (Figure 19), overall he experienced much greater mechanical stress in the upper rather than lower body.

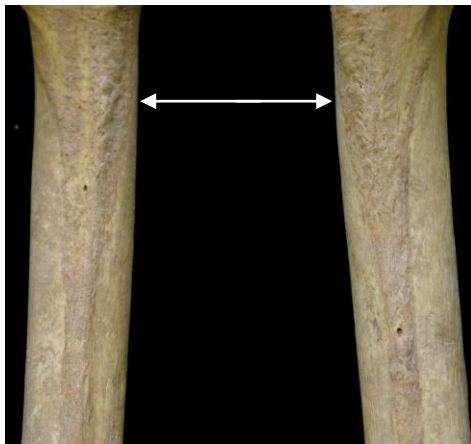

Figure 19: Hypertrophic gluteus maximus attachments on the posterior of the femur (south burial)

³⁹ Ibid, 40-41.

Exostoses of the external auditory meatus were observed bilaterally and may be associated with inflammation and infections of the ear, which are often associated with swimming and exposure to cold water (see Hutchinson et al. 1997).

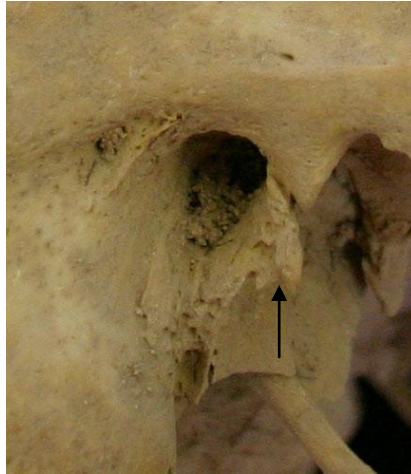


Figure 20: Exostoses of the external auditory meatus (south burial)

The exostoses are not isolated to the external auditory meatus, however, and occur on the inferior aspect of the temporals as well.

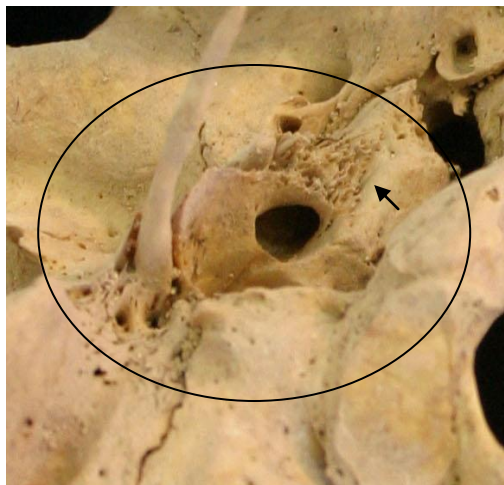


Figure 21: Exostoses of the inferior aspect on the right temporal bone (south burial)

North Burial

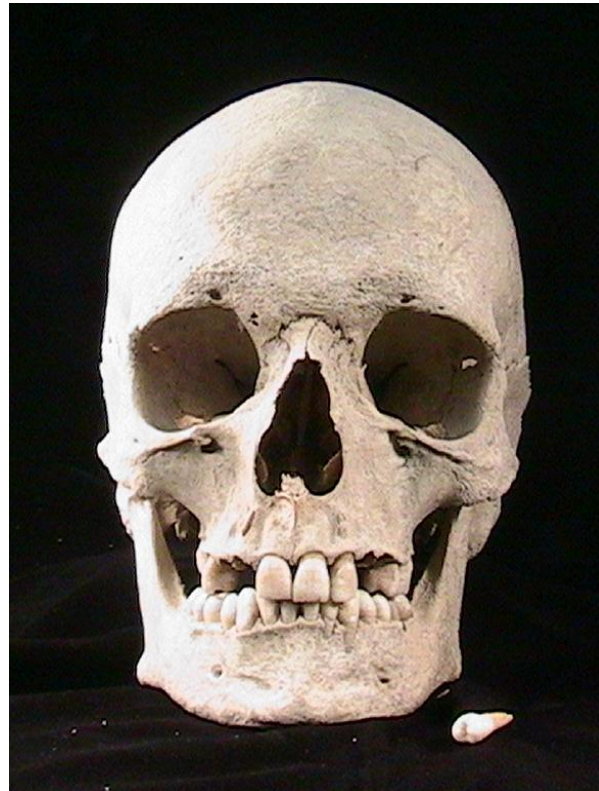


Figure 22: Anterior view of the skull (north burial)

The individual identified as the north burial was assessed as probably male, employing the pelvis and skull, as summarized in the table below.

Table 4: Sex Assessment (north burial)

Sex Assessment	
Technique	Scale 1 (female) to 3 or 5 (male)
Pelvis: subpubic concavity (1-3)	3
ventral arc	unobservable
ischiopubic ramus ridge	unobservable
greater Sciatic Notch (1-5)	3.5
preauricular Sulcus (0-4)	3
Skull: nuchal crest (1-5)	5
mastoid process (1-5)	3.5
supraorbital margin (1-5)	2
Glabella (1-5)	3
Mental eminence (1-5)	3.5

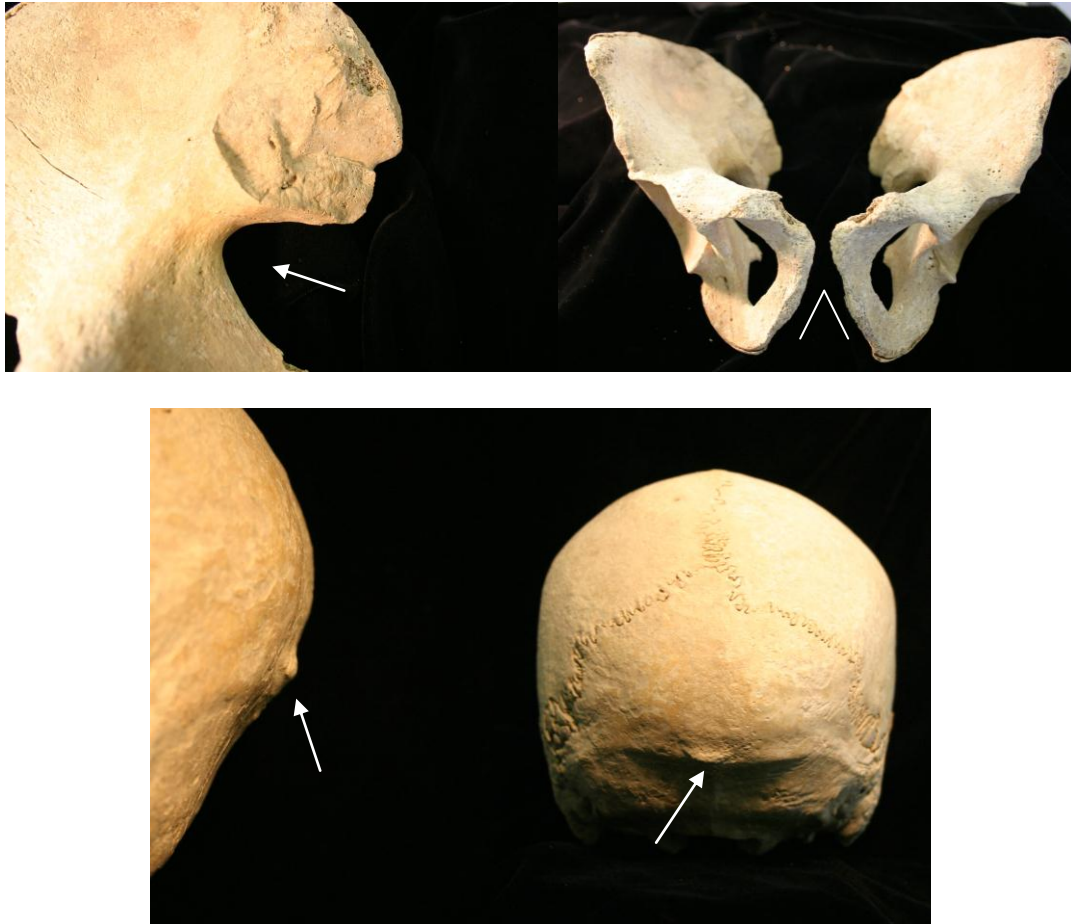

Figure 23: Greater sciatic notch, (top, left) subpubic angle (top right) and the nuchal crest (bottom left and right) employed in sexing (north burial)

The age assessment, for this immature individual was based on developmental indicators that give more precise age ranges than are possible for the south burial. The age of the individual from the north burial was assessed using epiphyseal closure,⁴⁰ stage of dental development, and tooth wear (Brothwell 1965).⁴¹ The low end of the age range was assessed to be 17 years and the high age to be 25 years, however, this individual most likely died within the age range of 17 to 19 years. The following chart summarizes the age indicators and their corresponding age ranges.

⁴⁰ Buikstra and Ubelaker, *Standards*, 43.

⁴¹ William Bass, *Human Osteology*, 301, 304.

Table 5: Age Assessment (north burial)

Technique	Bone	Assessment	Age range indicated
Brothwell, 1965 tooth wear pattern and age correlation	Dental – first and second molars	Age category 1	17 – 25 years
Epiphyseal Fusion	Distal Humerus	Fully fused	at least 13 years
Epiphyseal Fusion	Head of the Humerus	Partially fused	14.5 – 19.5
Epiphyseal Fusion	Proximal Ulna and Radius	Fully fused	Fused by 19 years
Epiphyseal Fusion	Distal Ulna and Radius	Partially fused	Fuses between 17 – 22 years
Epiphyseal Fusion	Proximal Fibula	Partially fused	Fuses between 13 and 21 years
Epiphyseal Fusion	Distal Fibula	Partially fused	Fuses between 14.5 and 19.5 years
Epiphyseal Fusion	Iliac crest, anterior-inferior iliac spine, ischial tuberosity	Partially fused	Fuses between 16 - 23
Epiphyseal Fusion	Sternal extremity of the clavicle	Unfused	Fusion begins at 19 years of age
Epiphyseal Fusion	Proximal Tibia	Partially Fused	Fuses between 15.5 and 22 years
Epiphyseal Fusion	Distal Tibia	Partially Fused	Fuses 14.5 -19.5 yrs.
Epiphyseal Fusion	Femoral head	Partially Fused	Fuses between 14.5 and 23 years
Epiphyseal Fusion	Iliac Crest	Partially Fused	Fuses between 14.5 and 21.5 years
Epiphyseal Fusion	Vertebral centra	Partially Fused	Fuses between 17 – 25 years
Epiphyseal Fusion	Sacrum S1 – S2	Partially Fused	Fusion begins at 17, continues into the 30s
Epiphyseal Fusion	Sacrum S2 – S3	Partially Fused	Fuses between 18 – 24 years
Epiphyseal Fusion	Sacrum S3 – S4 and S4 – S5	Partially Fused	Fuses between 16 and 23
Dental Development	Molars	Second Molar fully erupt, third molar not in occlusion	Approximately 15 –18 years. Third Molar is fully erupt by 21, but is not usually erupt at age 15 –18.

The most definitive indicators were the unfused epiphyseal plates of the sternal end of the clavicles and the fully erupted second molar without the third molar in occlusion.

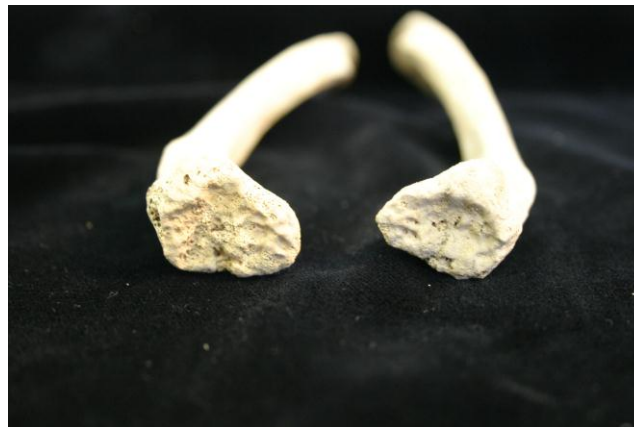

Figure 24: Unfused medial/sternal epiphyses (north burial)

Stature was assessed using the Trotter and Gleser (1952) estimates published in Bass (1995). This individual was assessed to be between 5 feet 4 inches and 5 feet seven inches in height.

Table 6: Stature Assessment (north burial)

Element	Length (mm)	Stature Estimate (cm)
Humerus	307	165
Radius	234	167.5
Ulna	246	172
Femur	430	163.5
Tibia	336	163.5
Fibula	330	160.5 (based on estimate of maximum length)

Pathologies indicated within the remains of the younger probable male, similar to the older male, indicate active porotic hyperostosis evidenced as pitting in the cranial bones and as cribra orbitalia. Also corresponding to the pattern observed in the older male, the younger probable male exhibited pitting in the nasal and palate bones, indicating responses to systemic infection.

Dental pathologies within this individual included enamel hypoplasia, hypocalcification and caries. Dental enamel hypoplasia are transverse bands or pits within the enamel that occur during tooth development. When the ameloblastic (enamel producing) activity is disrupted due to physiological stress (including nutritional and disease stresses), a groove or pit results on the tooth. Dental enamel is acellular and, therefore, does not remodel. Thus, dental enamel provides a record of childhood health. Within this individual, hypoplasia were present primarily within the anterior teeth – the canines and incisors- and represent the health status of the individual during the developmental years of birth to six and a half years of age. This individual experienced childhood stress during those early years of his life. A chronology was calculated for hypoplasia occurring on the mandibular canines to assess the age at which physiological disruption occurred. The canine crown height was used to determine a yearly increment of growth for this individual and the measurement of each defect was then used to determine ages represented by each defect. The canine enamel record indicates that this individual experienced stress episodes during ages 1.7 to 1.9 years, 2.1 to 2.4 years and 4.3 to 5.5 years.

Dental caries and carious lesions were present in the posterior teeth and demonstrate dental damage related to diet and possible predisposition toward caries due to the presence of hypoplasia that weaken the enamel at fissures where dental decay accelerates.

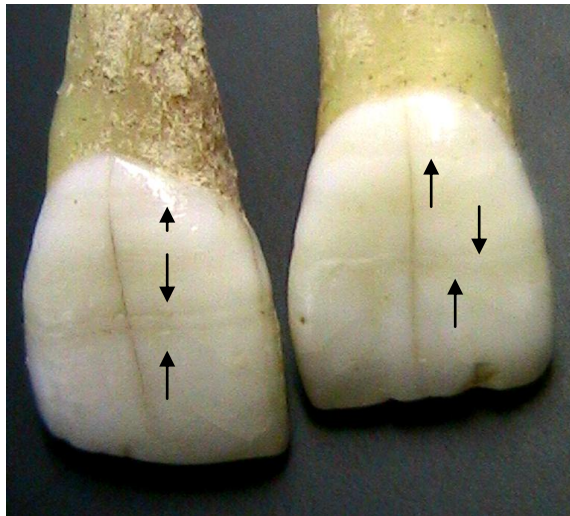


Figure 25: Upper central incisors with arrows pointing to linear hypoplasia



Figure 26: Porotic Hyperostosis in the nasal and maxilla (north burial)

The remains of the younger probable male were more fragile and fractured than was the south burial. However, the fractures appear to be post-mortem rather than peri-mortem. Iron staining was evident on the long bones and, again, may be associated with coffin nail contact. The young male exhibited active infection (reactive woven bone – periostitis) in both tibiae, pointing again to generalized, systemic infection. His cervical, thoracic and lumbar vertebrae

indicate early formation of Schmorl's nodes depressions. Due to the age indicators, these depressions most likely correspond to mechanical stress rather than aging. One would not expect the observed extent of schmorlization otherwise in such a young individual.

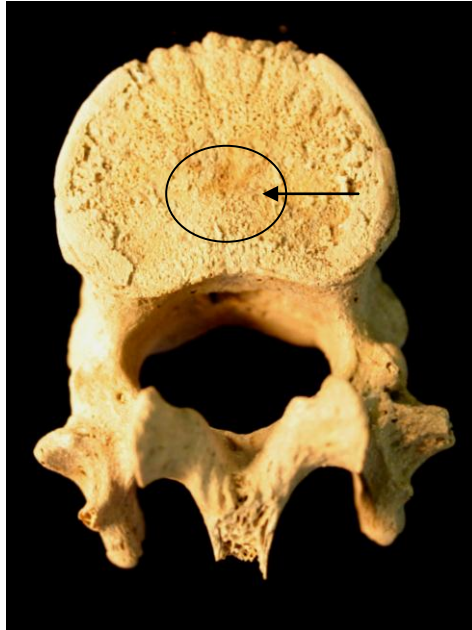


Figure 27: Twelfth thoracic vertebra with early stages of Schmorl's node depression.

This individual's thoracic vertebrae are slightly curved and his spinous processes are not in alignment.

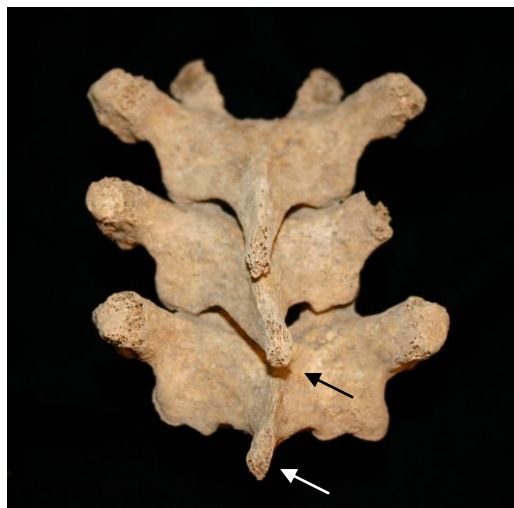

Figure 28: Thoracic vertebrae T7 – T9 illustrating misalignment of spinous processes (north burial)

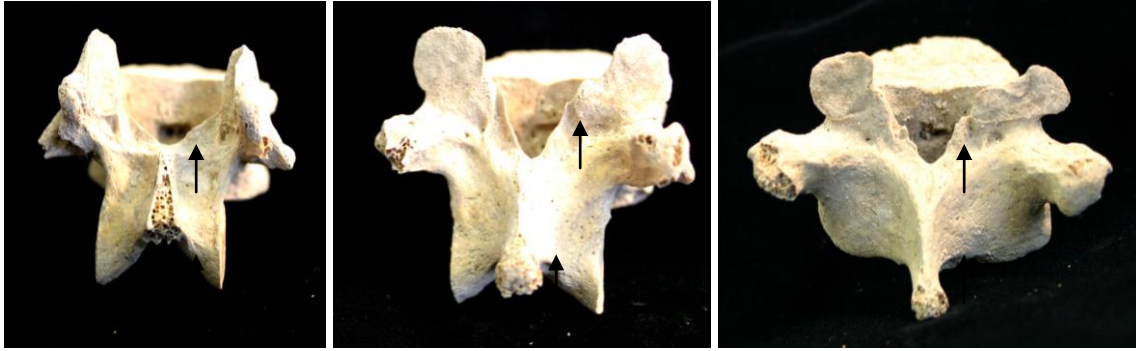


Figure 29: Thoracic vertebrae 10-12 with early formation of spicules or exostoses on the vertebral arch (north burial)

The lower thoracic vertebrae displayed spicules or exostoses on the posterior vertebral arch which may represent early osteoarthritic formations due to mechanical stressors.

Hypertrophic muscle attachments and enthesopathies of the upper body are similar to the upper body stressors observed within the older male. Early formation of syndesmosis within the clavicles was observed to be of much less severity than the lesions observed in the

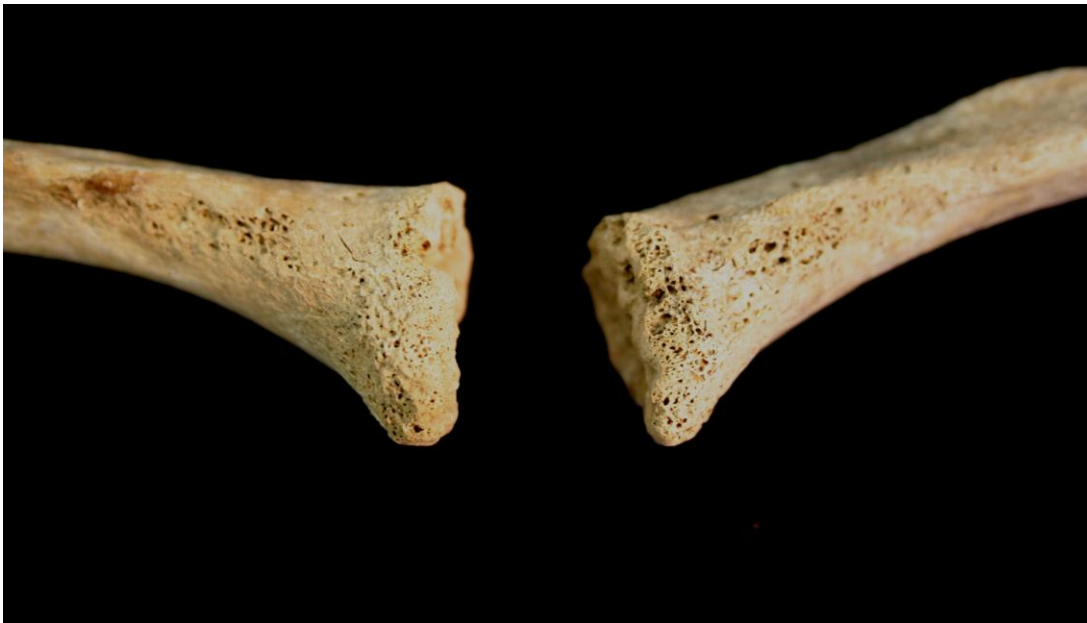

Figure 30: Early stages of costo-clavicular syndesmosis in the clavicles (north burial)




Figure 31: Enthesopathy of latissimus dorsi attachment on the anterior of the left humerus (north burial)

older male. The younger male, however, also displays enthesopathies of the lower leg in the right Tibia. This individual, died at a young age with active infection and evidence of anemic reaction. Skeletal indicators of mechanical stress reflect heavy labor, especially for a young individual.

Both individuals buried within Smith's fort experienced disease and infection as well as hard and repetitive labor during their lifetime.

Population Affiliation

An estimate of population affiliation was made based on skull morphology in the skeletons of the north and south burials. The assessment was similar in each case. Skeletons of both the north and south burials lack the prognathism usually associated with West and Central African populations. These relatively orthognathic faces are most consistent with those of Europeans. The inferior border of the nasal apertures have a slight sill in the north burial and a very well developed sill in the south burial, a discrete trait that is relatively

infrequent in African populations but common in Western Europeans. The south burial has an apparent occlusal overbite consistent with European and African jaws, while the north burial has a edge-to edge bit consistent with Native American jaws. The zygomatics and malars (cheek bones) do not project as far forward as is common among Native Americans and are consistent with Europeans. Yet the maxillary central incisors are shoveled in both skeletons, as is very common among Native Americans.

Cranial morphology cannot provide definite affiliations in these cases. Tentatively, however, the most likely affiliations, given the historically relevant populations can be ranked as Western European or mixed heritage (most probable), Native American (probable) and West or Central Africans (possible). Further analysis should rely upon evidence of childhood environmental exposures using dental chemistry that might discern the part of the world were these individuals were born. DNA analysis might also be useful (the sixth right rib for each individual was sealed and separated in preparation for potential DNA analysis). Craniometric techniques on a less than a statistically adequate sample, as in this case, are problematic and cannot be recommended. Further development of archaeological and historical context for these individuals might also provide more crucial information for cultural affiliation of these individuals.

Conclusions

The archaeological context of the two burials excavated at Smith's Fort in 2000 and 2001 indicates that the two males were buried during the refortification period that took place in the late 1700s under Andrew Durnford. The economic, political and historical context provided by the documentary record provides evidence that free and enslaved laboring men in the late 1700s engaged in sailing, whaling, shipbuilding, carpentry, stone masonry, and fishing. Furthermore, the documentary record demonstrates that many men engaged in more than one of these occupations during their lifetimes. The governor's decree for 6 slaves from each parish in 1793 for construction of the fortifications was in the same year in which the Smith's Fort refortification occurred.

While the burial context does not indicate who these individuals may have been, future analysis of the artifacts associated with the south burial may provide further information. The skeletal analysis supports that these two males were engaged in heavy, arduous and repetitive labor during their lifetimes. The patterning of muscle and ligament attachment hypertrophies and lesions corresponds with the upper body intensive movements required of sailors, stone cutters, masonry, fishing and whaling. Patterns of osteoarthritis, while indicators of age are, particularly in younger individuals, also indicators of heavy lifting and load-bearing in the back. The lack of molar wear in the older man's teeth offers intriguing evidence of a highly processed menu, low in grit.

The infection and disease indicators demonstrated within the remains of these two males may indicate increased exposure to disease through extensive travel as part of the commercial trade engaged by Bermudians during the latter portion of the eighteenth century. The combined historical, archaeological and skeletal records strongly support that these two

individuals were free or enslaved laborers, who may have been working on the refortification of Smith's fort at the time of their death.

Acknowledgements

We would like to thank Stephanie Lau for her assistance in cleaning and preparing an inventory of the Smith's Fort skeletal remains and Dr. Lesley Rankin-Hill for providing advice on biomechanical spinal anomalies.

Bibliography

- Adinolfi, Christina. *The Symbolic Nature of Mortuary Art in the Royal Naval Cemetery on Ireland Island, Bermuda: 1800 – 1899*. Master's Thesis, Department of Anthropology, College of William and Mary, 1995.
- Angel, J. Lawrence. "Porotic Hyperostosis, anemias, Malaras, and Marshes in the Prehistoric Eastern Mediterranean." In *Science*, 1966, vol. 153:760 – 3.
- Bass, William M. *Human Osteology: A Laboratory and Field Manual*, fourth edition. Special Publication No. 2, Columbia, MO: Missouri Archaeological Society, 1995.
- Bernhard, Virginia. *Slaves and Slaveholders in Bermuda: 1616 – 1782*. Columbia: University of Missouri Press, 1999.
- Bragdon, Kathleen. "Native Americans in Bermuda." In *The Bermuda Journal of Archaeology and Maritime History* v. 10, 1998: 53-68.
- Buikstra, Jane E. and Douglas H. Ubelaker, eds. *Standards for Data Collection from Human Skeletal Remains*. Arkansas Archaeological Survey Research Series, No. 44, 1994.
- Capasso, Luigi, Kenneth A.R. Kennedy and Cynthia A Wilczak. *Atlas of Occupational Markers on Human Remains*. Teramo, Italy: Edigrafital SpA., 1999.
- Harris, Edward Cecil, F.S.A. *Bermuda Forts 1612 – 1957*. Bermuda: The Bermuda Maritime Museum, 1997.
- Hutchinson, D.L., C.B. Denise, H.J. Daniel, and G.W.Kalmus. "A Reevaluation of the Cold Water Etiology of External Auditory Exostoses" In *American Journal of Physical Anthropology* 1997, vol. 103:417-422.
- Jarvis, Michael J. "*In the Eye of All Trade*": *Maritime Revolution and the Transformation of Bermudian Society, 1612 – 1800*. Ph.D. Dissertation, Department of History, College of William and Mary, 1998, volumes 1 and 2.
- Packwood, Cyril Outerbridge. *Chained on the Rock*. New York: Eliseo Torres and Sons, 1975.
- Smith, James E. *Slavery in Bermuda*. New York: Vantage Press, 1976.
- White, Tim D. *Human Osteology, Second Edition*. San Diego: Academic Press, 2000.