

Spring 5-12-2011

## **Analysis of Human Remains Recovered from James Anderson's Public Armoury, Colonial Williamsburg**

Michael L. Blakey  
*College of William and Mary, mblak@wm.edu*

Christopher Crain  
*College of William and Mary*

Follow this and additional works at: <https://scholarworks.wm.edu/ihbpub>



Part of the [Biological and Physical Anthropology Commons](#)

---

### **Recommended Citation**

Blakey, Michael L. and Crain, Christopher, Analysis of Human Remains Recovered from James Anderson's Public Armoury, Colonial Williamsburg (2011).  
<https://scholarworks.wm.edu/ihbpub/5>

This Other is brought to you for free and open access by the Institute for Historical Biology at W&M ScholarWorks. It has been accepted for inclusion in Institute for Historical Biology Articles & Book Chapters by an authorized administrator of W&M ScholarWorks. For more information, please contact [scholarworks@wm.edu](mailto:scholarworks@wm.edu).

# Analysis of Human Remains Recovered from James Anderson's Public Armoury, Colonial Williamsburg

By:

Michael L. Blakey, Director  
Christopher Crain, Graduate Research Associate  
Institute for Historical Biology  
Department of Anthropology  
College of William and Mary  
Williamsburg, Virginia  
USA

To:

Edward Chappell, Director  
Department of Architectural and Archaeological Research  
Colonial Williamsburg Foundation  
Williamsburg, Virginia  
USA

Report No. 5, Institute for Historical Biology, 12 May 2011

## Table of Contents

I.	Skeletal Analysis Report	
	Background	1
	Methodology	1
	Condition of the Remains	2
	Skeletal Analysis	3
	Individual #1	3
	Individual #2	7
	Conclusion	20
	Acknowledgements	21
	References Cited	22
II.	Appendix A: Skeletal Inventories	
	a. Inventory for Individual #1	
	b. Inventory for Individual #2	
III.	Appendix B: Anthropometric Records	
	a. Anthropometric Record for Individual #1	
	b. Anthropometric Record for Individual #2	
IV.	Appendix C: Markers of Pathological and Occupational Stress, Individual #2 (Table Seven)	
V.	Appendix D: Photographic Inventory	

## **Background**

In November of 2010, Dr. Michael Blakey, director of the Institute for Historical Biology, was contacted by archaeologist Andrew Edwards of the Colonial Williamsburg Foundation notifying him of the discovery of human remains during an excavation of the James Anderson's Public Armoury, located near Francis Street in Colonial Williamsburg. After consultation, it was decided that the remains of the two individuals would be transferred to the Institute for Historical Biology for inventory and analysis. The first individual was transferred on January 5<sup>th</sup>, 2011 from the Colonial Williamsburg Foundation's collections facility, where it had been cleaned by conservator, Emily Williams, and the second individual was transferred directly from the archaeological site March 17<sup>th</sup>, 2011.

## **Methodology**

The Human Remains were brought to the Institute for Historical Biology on the College of William & Mary campus where the laboratory studies were conducted by Christopher Crain, assisting Dr. Blakey. Upon completion of the cleaning of the remains, an inventory for each individual was conducted using a modified version of the "Inventory Recording Form for Complete Skeletons" from *Standards* (Buikstra and Ubelaker 1994). After this, each individual was analyzed to determine their sex, age, stature, and to identify any evidence of pathological or occupational stress. Each skeletal element, or group of elements when appropriate, were placed within a plastic bag and labeled. All of the soil removed from the remains was also placed in such bags and were identified by the element with which the soil was associated.

## Condition of Skeletal Remains

Both individuals excavated from the site exhibited a number of taphonomic changes caused by the environment of their interment. In general, both individuals exhibited cortical and trabecular bone erosion, post-mortem fracturing, and destruction of various elements of the skeleton.

Individual #1, the first individual excavated and analyzed, proved to be highly fragmentary. After the removal of adhering soil, only a small amount of skeletal material remained. Only portions of the calvarium, mandible, left innominate, left femur, and left tibia maintained enough of their structural integrity to be analyzed. All other skeletal elements were highly fractured, or were completely missing.



Figure One: Postmortem damage caused by a sharp edged tool.

Individual # 2 suffered from much less post-mortem damage. After the completion of the cleaning of this individual most of the long bones were found to be either mostly intact or only partially fragmented. Both the innominates, as well as most of the mandible were also preserved

with this individual. Unfortunately large portions of the calvarium, vertebra, ribs, scapulae, and sacrum were either highly fractured or completely missing. None of the face remained observable.

### **Skeletal Analysis**

Analyses of both individuals were conducted to gather any information concerning their sex, age, and stature. In addition, to this, an examination of all available skeletal elements was completed to identify any evidence for pathological or occupational stress.

#### *Individual #1*

##### *Sex*

As mentioned before, the preservation of individual # 1 was minimal at best. Most of the elements and morphological traits used for the determination of both sex and age at time-of-death were unavailable. Of the various cranial features used for the assessment of sex, only the right temporal bone, with its broken mastoid process, and the mental eminence of the mandible were helpful. While the body of the mastoid process is missing, an estimation was calculated for its length, which was observed to be 19.65 mm. When this is compared to the length of Individual #2's, calculated to 35.52 mm, a dimorphic difference can be deferred for this trait. This, along with the lack of any pronouncement of a mental eminence of the individual's mandible, suggests the individual is female, but due to its edentulous condition, such an assessment is problematic at best. Therefore, we consider the sex of Individual #1 to be indeterminate (Buikstra and Ubelaker 1994).



Figure Two: Right portion of the temporal bone showing the area of the missing mastoid process

### *Age*

The assessment of age suffered from the same conditions of poor preservation. Only two ectocranial points were observable for suture closure. Both the bregma and anterior sagittal points manifested significant closure. While this is usually an indicator of a medium aged adult, the lack of other observable suture points makes it impossible to create a composite score for the assessment of age with this technique (Buikstra and Ubelaker 1994). The other element used to assess the age of this individual was the left acetabulum. Following the criteria developed by Rouge-Maillart, et al. (2004), observations of the surface changes for the rim, fossa, and lunate were conducted. These changes indicate that this individual was between 22-and 80 years of age at the time of their death. So, in conjunction with the mandible's edentulous condition, and the

apparent completion of alveolar resorption, it is probable that this individual was an older adult (50+ years in age).

Table One: Age Assessment (Acetabulum)

Characteristic	Stage	Criteria	Age Range
Rim	4	localized destruction	54-76 years
Fossa	4	bone destruction with macroporosity	58-80 years
Lunate surface	2	extensive microporosity or macroporosity	22-60 years




Figure Three: Left acetabulum showing evidence of bone destruction and macroporosity

### *Stature, Pathological Lesions, and Indicators of Occupational Stress*

Though fragmentary, the left femur was measured in an attempt to assess the stature of this individual. Using the stature formulas developed by Trotter and Gleser (1952, 1958) for females,



as presented in Bass (1995), a rough estimate of stature was obtained. A composite measurement, from the both *in situ* and laboratory assessments, for this element, was calculated to be 438.5 mm. This measurement suggests that this individual stood between 5' 1" and 5' 5". As for indicators of pathological conditions and/or markers of occupational stress, three conditions were observable upon the surviving skeletal elements. The edentulous condition of the mandible and arthritic changes involving the acetabulum have been mentioned previously, but in addition to these, the left femur also exhibited a hypertrophic *linea aspera*. The *linea aspera* is the primary origin for the *vastus* muscles, and main insertion points for the abductor muscles, *longis*, *brevis*, and *magnus* (White 2000), muscles of the hip which function in the extension of the knee and the rotation, extension, and flexion of the thigh (McKinley and O'Loughlin 2006).

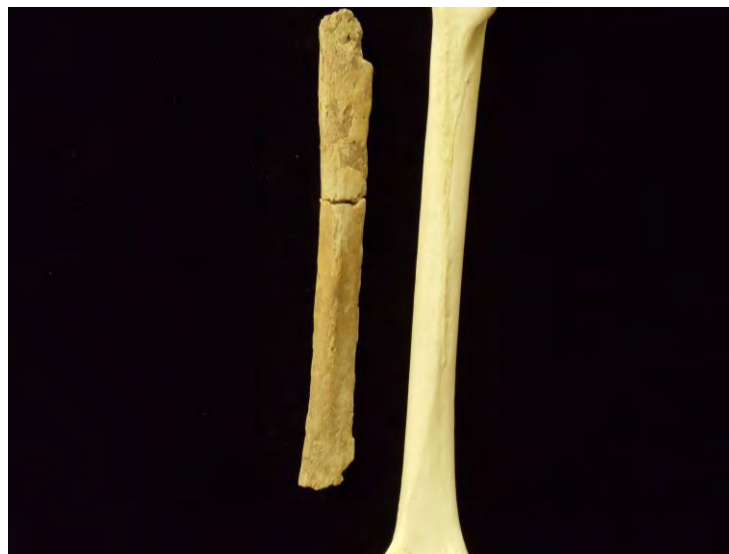

Figure Four: The posterior view of Individual #1's left femur in comparison to an anatomical specimen

### *Population Affiliation*

No osteological or odontological data were available appropriate to morphological assessment of population origins or affiliation.

### *Summary of Individual One*

In summary, individual #1 is consistent with an adult who was at least fifty years in age, stood around 5' 1'' - 5' 5'', and was involved with some kind of labor involving significant bending and loading of the lower extremities.

### *Individual #2*

#### *Sex*

Due to better preservation, a number of characteristics were available for the assessment of sex for this individual. Various morphological traits of the pelvis were used including the ventral arc, subpubic concavity, ischiopubic ramus, greater sciatic notch, and preauricular sulcus. In conjunction observations of the calvarium and its nuchal crest, mastoid processes, and the mental eminence of the mandible were available.

With these indicators, this individual can be confidently assigned to the “probable male” category set forth in *Standards* (Buikstra and Ubelaker 1994). This determination is also supported by the measurements for the left humerus and femora heads, which according to Stewart’s (1979) research, indicates an individual that is most likely male (Bass 1995).

Table Two: Sex Assessment for Individual #2

Technique	Scale 1(female) to 3 or 5 (male)
Pelvis:	
Ventral Arc	3
Subpubic Concavity	3
Ischiopubic Ramus	3
Greater Sciatic Notch	5
Preauricular Sulcus	3
Skull:	
Nuchal Crest	4
Mastoid Process	4
Mental Eminence	3

Table Three: Sex Assessment, Individual #2 (part two)

Technique	Measurement	Classification
Left Humeral Head	47.88 mm	Male
Left Femoral Head	46.95 mm	Probable Male
Right Femoral head	47.33 mm	Probable Male



Figure Five: Posterior view of Individual #2's calvarium and its nuchal development

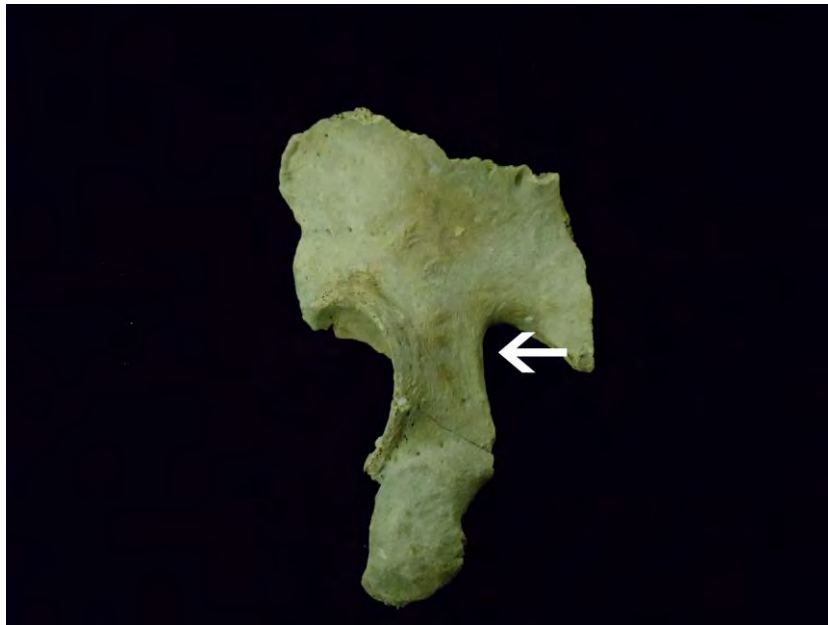


Figure Six: Lateral view of Individual #2's left innominate showing the narrow sciatic notch used in the assessment of sex

## Age

Again, the better preservation of this individual allowed for a more complete assessment of age. Observations of the surviving cranial sutures, the pubic symphyses, and the auricular surfaces were the primary traits used for this portion of the analysis.

While all of the cranial suture points were not observable due to the incompleteness of the calvarium, the midlambdoid, lambda, anterior sagittal, inferior sphenotemporal, and sagittal were present. All of these points exhibited complete closure, except the midlambdoid and the inferior sphenotemporal, which had significant closure. While a true composite score could not be generated, these points suggest an age of 30 to 45 years at the time of death.

Table Four: Age Assessment, Individual #2 (Suture Closure)

Suture Point	Score	Score
External Cranial Vault:	Score	0= Open
Midlambdoid	2	1= Minimal Closure
Lambda	3	2= Significant Closure
Bregma	3	3= Complete Obliteration
Inferior Sphenotemporal	2	
Internal Cranial Vault:		
Sagittal	3	
Left Lambdoid	3	

In the assessment of the pubic symphyses, enough remained of both faces to use the techniques developed by Todd (1921a, 1921b) and Suchey- Brooks (1990). Using Todd's scoring method the left pubic symphysis was rated a phase seven and the right a phase eight, generating an age range of 35 to 45 years. By comparison, the Suchey-Brooks scoring system established phases four and five for the same symphyseal faces, indicating a range of 25 to 60 years or greater for this individual. Enough of the auricular surfaces were also preserved for the use of Meindl and Lovejoy's (1989) aging system. Both auricular surfaces were found to correspond to phase seven, which indicate an individual whose age was between 50 to 59 years.

It was noted that the sternal epiphyses of the left clavicle was fused. Therefore, this individual was at least a medium aged adult (30-59 years) or 45 years +/- 15 years at his time of death.

Table Five: Age Assessment, Individual #2 (part two)

Technique	Assessment	Age Range
Todd Pubic Symphysis (Right Side)	Phase 8	40-45 years
Todd Pubic Symphysis (Left Side)	Phase 7	35-39 years
Suchey- Brooks Symphysis (Right Side)	Phase 5	25-60+ years
Suchey- Brooks Symphysis (Left Side)	Phase 4	25-55 years
Auricular Surface (Right and Left Side)	Phase 7	50-59 years
Sternal end of the clavicle epiphyseal fusion	Completely Fused	Fusion is complete by the age of 30

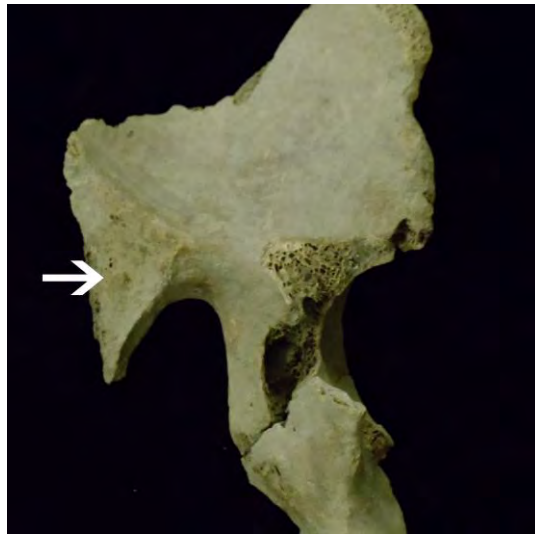


Figure Seven: Auricular Surface of Individual #2's left innominate used in the assessment of age

*Stature*

Three long bone measurements were available for the estimation of stature for this individual. These include the left humerus (343 mm), the left femur (458 mm), and the right tibia (393 mm) which when used with the formulae generated by Trotter and Gleser (1952, 1958), indicate that this individual stood between 5' 5" and 5' 9" when alive (Bass 1995).

Table Six: Stature, Individual #2

Skeletal Element	Measurement of the Element in mm	Measurement of Height Range in cm
Left Humerus	343	173
Left Femur	458	172
Right Tibia	393	176

*Pathological Lesions and Indicators of Occupational Stress*

Due to the good preservation of diverse elements of Individual #2, several indicators were observed to reveal environmental conditions in which he had lived (see Appendix C).

### *The Axial Skeleton*

While much of the axial skeleton was highly fragmented, both the mandible and several vertebral bodies exhibited conditions of stress. The mandible was completely edentulous. Alveolar bone in the region of the incisors, canines, and premolars showed significant remodeling, and the areas of the left first and second molar, the right second premolar, first molar, and second molar, were completely remodeled. Only the area of the right third molar was partially exposed, with no evidence of remodeling.

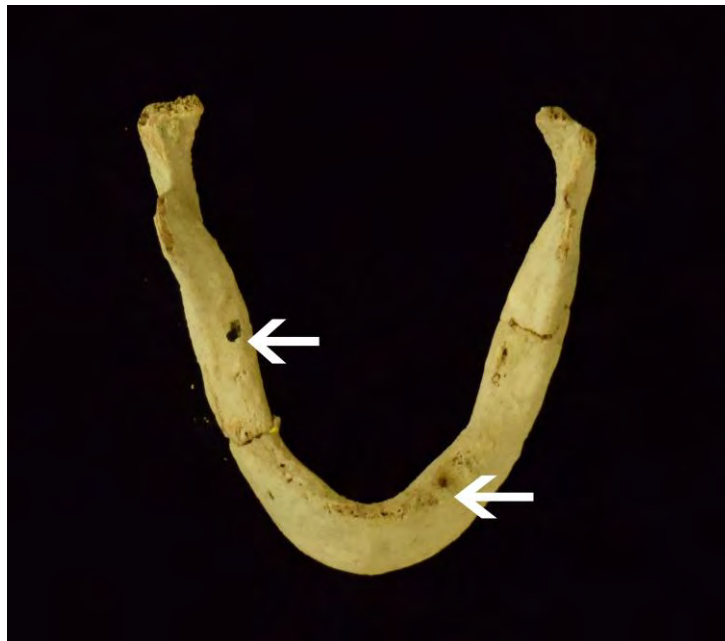

Figure Eight: Superior view of Individual #2's mandible with various stages of alveolar bone remodeling

As for manifestations in the vertebrae, both a lower thoracic and upper lumbar exhibit evidence of Schmorl's node depressions. Both depressions extend into the trabecular bone, and are the result of the protruding cartilage from a corresponding intervertebral disc. In addition, one of the persevered lower lumbar has osteophytic lipping with slight curvature of the spicules. Both of



these conditions are associated with mechanical stress and the age related degeneration of the vertebral column over time (Buikstra and Ubelaker 1994, Larsen 1997, Ubelaker 1999).



Figure Nine: Superior view of a thoracic vertebra with a Schmorl's node that has perforated the cortical bone




Figure Ten: Superior view of a lumbar vertebra with osteophytic lipping on the edge of the vertebral body

### *The Appendicular Skeleton*

Besides the general robustness of this individual's skeleton, every element of the upper body, the clavicles, scapulae, humeri, ulnae, and radii, exhibit hypertrophic attachment points for their muscles and ligaments. In addition, the costal tuberosity of the right clavicle, exhibited a lesion associated with costoclavicular syndesmosis, which is a condition involving stress of the pectoral girdle (Capasso et al. 1999). The superior and axillary borders of the scapulae, which are associated with the supraspinatus and teres muscle, also show a marked thickening. These muscles are important for both the function and stability of the shoulder joint (McKinley and O'Loughlin 2006). The development of these areas is associated with the extensive use of the upper body muscle groups of the arm, chest, and back for hard physical labor involving both lifting and pushing of heavy objects, often in a rowing motion (Hawkey and Merbs 1995).

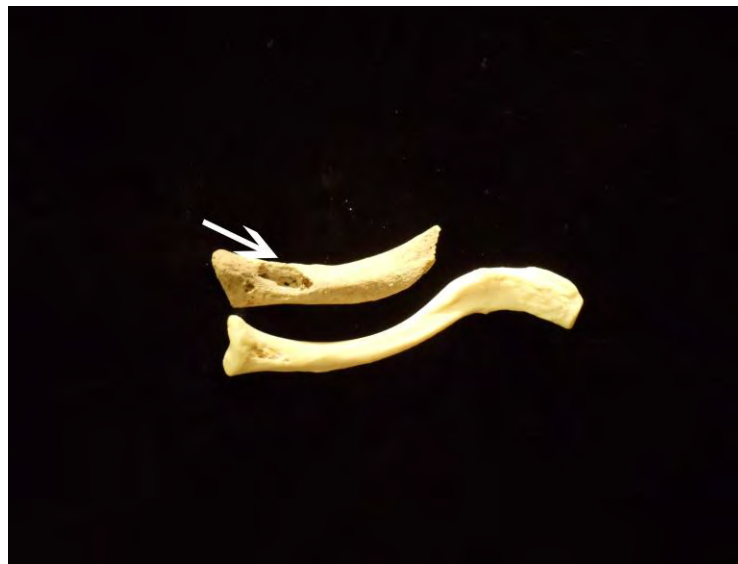

Figure Eleven: Inferior view of the right clavicle's costal tuberosity with a lesion associated with costoclavicular syndesmosis, compared with an anatomical specimen, below

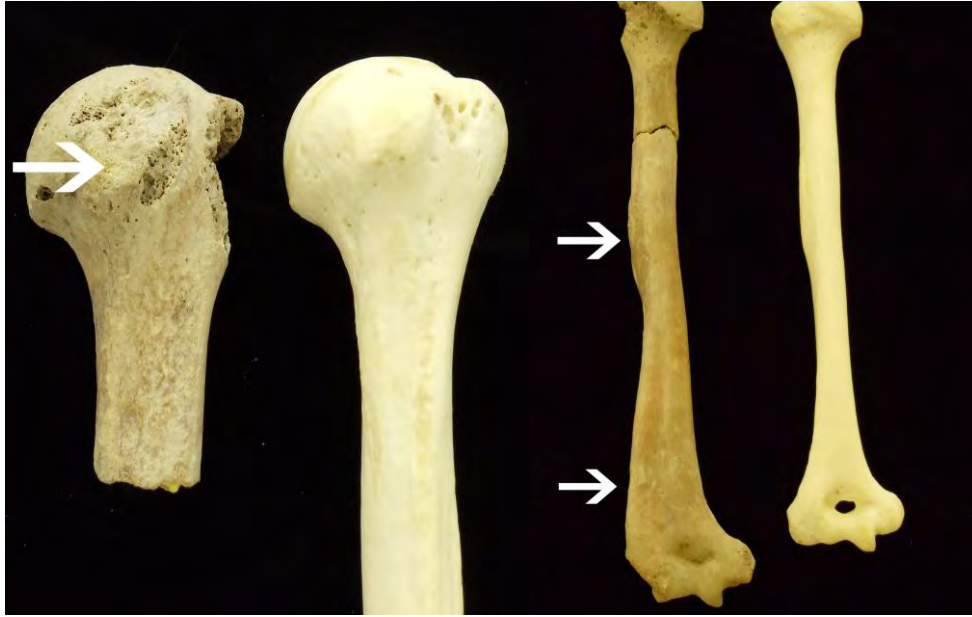

Figure Twelve: Anterior and Posterior views of the left humerus with its hypertrophic lesser tubercle, intertubercular sulcus, deltoid tuberosity, and lateral supracondylar crest



Figure Thirteen: Anterior view of the left radius with its hypertrophic radial tuberosity and general robustness, compared with an anatomical specimen, above

The lower body also showed evidence of hard physical labor, as well as indications of pathological stress. The greater and lesser trochanters, trochanteric fossae, gluteal tuberosities, and linea asperae of the femora, all have a roughened or hypertrophic appearance. These areas act as attachment points for such muscles groups as the *gluteal*, *gemeli*, *vastus*, and other individual muscles such as the *obturator internus*, *piriformis*, *iliacus*, *psaos major*, *gluteus maximus*, *longis*, *brevis*, and *magnus*. These muscles are important for the stabilization, as well as the rotation of the hip, and the flexing of the knee (McKinley and O'Loughlin 2006). Their increased sizes, like those associated with the upper body are evidence of substantial mechanical stress involving the lifting and pushing of objects of significant mass.

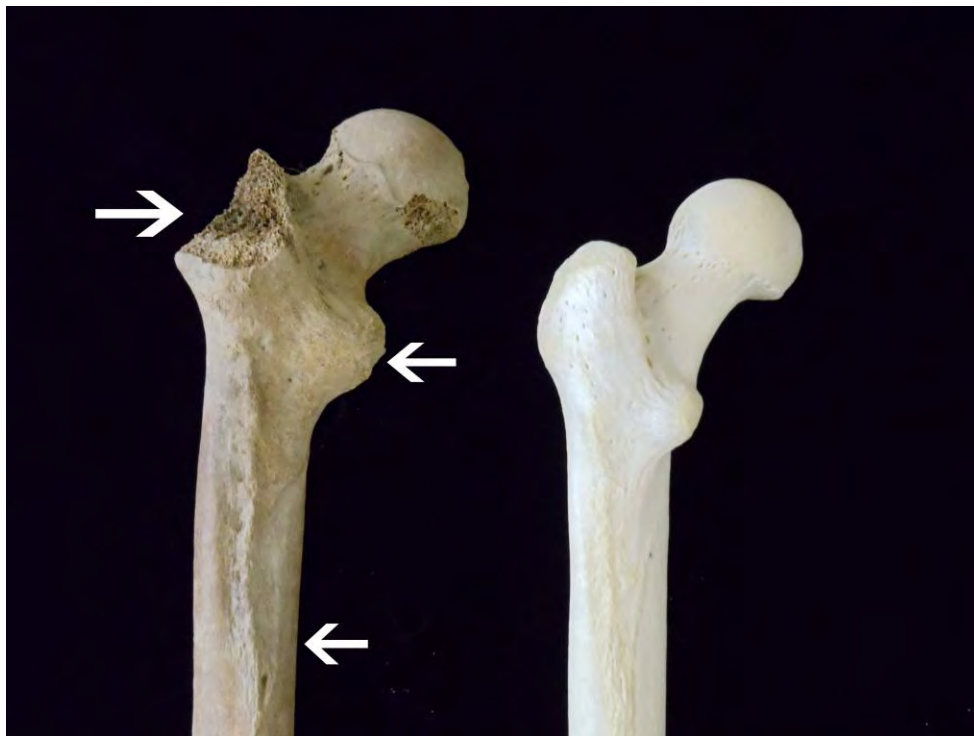

Figure Fourteen: Posterior-proximal view of the left femur (left) showing the hypertrophic trochanters and linea aspera

The tibiae also show hypertrophy along their soleal lines which are insertion points for the *popliteus* muscle, a flexor and rotator of the tibia. This area also gives rise to the *popliteus fascia* and *soleus muscle* which allows for the flexing of the foot (McKinley and O'Loughlin 2006, and White 2000). In addition, both tibiae revealed evidence of periostitis along their diaphyses. The right tibia's manifestation is along the anterior-lateral edge of distal third of the diaphyses, which shows marked elevation with healing. The left tibia has three areas of periosteal reaction. The first involves sclerotic activity along the proximal-lateral side of the first two-thirds of the diaphyses, the second involves another area of raised elevation with healing along the lateral edge of the distal third of the diaphyses, and the last is located along the distal third of the posterior diaphyses, and is almost completely remodeled. All of these indicators show evidence of a past bacterial infection or traumatic event. The sclerotic reaction is along the origination of the *tibialis anterior*, *tibialis posterior*, and the *interosseous membrane*, which are key muscles and ligaments for the function and stabilization of the leg. A substantial injury involving any of these components may very well have been the cause for this reaction (Larsen 1997, McKinley and O'Loughlin 2006).

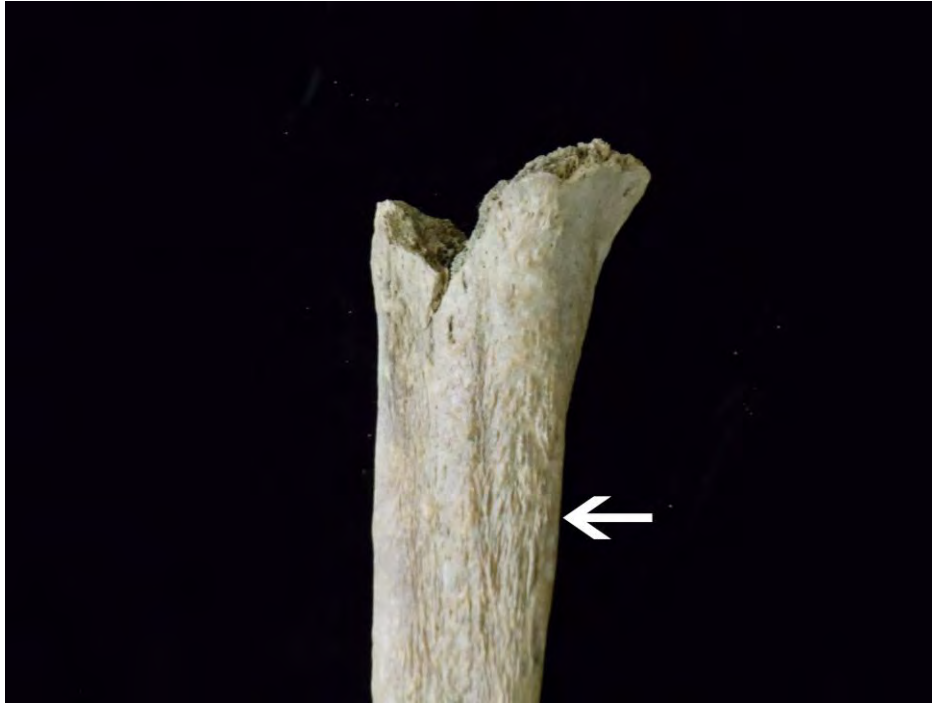

Figure Fifteen: The lateral side of the proximal tibia with sclerotic periostitis

Other evidence of osteoarthritis was identified. Several of the long bones, such as the radii, femora, and the tibiae, all revealed the development of osteophytes along their articular facets. In addition, the superior-proximal edge of the left patella, which is the insertion point for the *rectus femoris*, has an enthesophyte.

#### *Population Affiliation*

No osteological or odontological data were observable appropriate for estimating population origins or affiliation.

### *Summary of Individual #2*

In summary, individual #2 was a probable male adult, who stood between 5'5" and 5'9", and was between the ages of 30-59 years when he died. He also was involved in some type of heavy labor, in which both his upper and lower body was involved. This type of labor may have very well involved the opportunity for injury, as indicated by the pathological lesions found upon the tibiae.

### **Conclusion**

The archaeological and historical contexts for these burials are continuing to be developed at Colonial Williamsburg, and most conclusions await the incorporation of the skeletal data within context. We do know that both of the individuals examined lived well into adulthood, and from observations of the skeletal remains were involved in some kinds of physically demanding labor. In fact, Individual #2 has exceedingly robust muscle attachments associated with a long lifetime of arduous labor, industrial, agricultural, or other.

## **Acknowledgements**

We would like to thank Lucie Vinciguerra and Kathryn Sikes for excavation of the remains, and Mark Kostro for his field measurements. In addition, we would like to give our thanks to Ellen Chapman and Luran Kellam for their lab assistance in the cleaning and inventory of the James Anderson's Armoury skeletal remains.



## References Cited

Bass, W. (1995) Human Osteology: A Laboratory and Field Manual. Special Publication No.2. Columbia: Missouri Archaeological Society. Columbia, Mo.

Brooks, S. and J. Suchey (1990) Skeletal Age Determination Based on the Os Pubis: A Comparison of the Acsadi-Nemeskeri and Suchey-Brooks Methods. Human Evolution, 5:227-238.

Buikstra, J, and D. Ubelaker (1994) Standards for Data Collection from Human Skeletal Remains. Arkansas Archeological Survey Research Series NO. 44. Fayetteville: Arkansas Archeological Survey.

Capasso, L, Kennedy, K and C. Wilczak (1999) Atlas of Occupational Markers on Human Remains. Teramo, Italy: Edigrafital SpA.

Hawkey, D. and C. Merbs (1995) Activity-induced Musculoskeletal Stress Markers (MSM) and Subsistence Changes among Ancient Hudson Bay Eskimos. International Journal of Osteoarchaeology, 5: 324-338.

Larsen, C. (1997) Bioarchaeology: Interpreting Behavior from the human skeleton. Cambridge: Cambridge University Press.

McKinley, M. and V. O'Loughlin (2006) Human Anatomy, McGraw Hill Higher Education.

Meindl, R. and O. Lovejoy (1989) Age Changes in the Pelvis: Implications for Paleodemography. In Age Markers in the Human Skeleton, edited by M.Y. Iscan. Springfield: Charles C. Thomas, pp137-168.

Rouge-Maillart, C, Telmon, N, Rissech, C, Malgosa, A. and D. Rouge (2004) The Determination of Male Adult Age at Death by Central and Posterior Coxal Analysis-A Preliminary Study. Journal of Forensic Sciences, 49: 208-214.

Stewart, T. (1979) Essentials of forensic anthropology: Especially as developed in the United States, Springfield: Charles C. Thomas.

Todd, T. (1921a) Age Changes in the Pubic Bone, I: The Male White Pubis. American Journal of Physical anthropology, 3: 285-334.

(1921b) Age Changes in the Pubic Bone, III: The Pubis of the White Female, IV: The Pubis of the White-Negro Hybrid. American Journal of Physical Anthropology, 4:1-70.

Trotter, M. and G. Gleser (1952) Estimation of Stature from Long Bones of American Whites and Negroes. American Journal of Physical Anthropology,10:463-514.

(1958) A Re-evaluation of Stature Based on Measurements Taken During Life and of Long Bones after Death. American Journal of Physical Anthropology,16:79-123.

Ubelaker, D. (1999) Human Skeletal Remains: Excavation, Analysis, Interpretation. 3rd Edition, Washington D.C.: Taraxacum Publishing.

White, T. (2000) Human Osteology. 2nd Edition, San Diego: Academic Press.

## **Appendix A**

**INVENTORY RECORDING FORM FOR COMPLETE SKELETONS**

Site Name/ Number	Armoury	Observer	Crain
Feature/ Burial Number	10AR-00238	Date	3/23/2011
Burial/ Skeleton Number	Individual #1		
	Colonial		
Present Location of Collection	Williamsburg		

**CRANIAL BONES AND JOINT SURFACES**

	<u>L (left)</u>	<u>R(right)</u>		<u>L(left)</u>	<u>R(right)</u>
Frontal	3	3	Sphenoid		
Parietal	3	2	Zygomatic		
Occipital			Maxilla		
Temporal		3	Palatine		
TMJ	3	3	Mandible	3	3

**POSTCRANIAL BONES AND JOINT SURFACES**

Clavicle			Os Coxae		
Scapula			Ilium	3	
Body			Ischium		
Glenoid f.			Pubis		
Patella			Acetabulum	2	
Sacrum			Auric. Surface		
Cocryx					

**VERTEBRA (individual)**

Centrum Neural Arch

**VERTEBRAE (group)**

#Present/ #Complete

	Centrum	Neural Arch		Centra	Neural Arches
C1					
C2			C3-6		
C7			T1-T9		
T10					
T11			<b>Sternum:</b>	<b>Manubrium</b>	<b>Body</b>
T12					
L1					
L2					
L3					
L4					
L5					

**RIBS (individual)**

**RIBS (grouped)**

#Present/ #Complete

1st  
2nd  
11th  
12th


3--10

--	--

Series/ Burial/ Skeleton  
Observer/Date

Armoury Individual  
#1  
Crain 03/23/2011

**LONG BONES**  
Diaphysis

	Proximal Epiphysis	Proximal Third	Middle Third		Distal Third	Distal Epiphysis
Left Humerus						
Right Humerus						
Left Radius						
Right Radius						
Left Ulna						
Right Ulna						
Left Femur	3	2	2		3	3
Right Femur		2				3
Left Tibia	3	2	1			
Right Tibia	3	2	3			
Left Fibula						
Right Fibula						
Left Talus						
Right Talus						
Left Calcaneus						
Right Calcaneus						

**HAND (#Present/ #Complete)**

	<u>L</u>	<u>R</u>
# Carpals	1	
# Metacarpals		
# Phalanges		

Unsided

**FOOT (# Present/# Complete)**

	<u>L</u>	<u>R</u>	<u>Unsided</u>
# Tarsals	1		
#Metatarsals			
#Phalanges			

**INVENTORY RECORDING FORM FOR COMPLETE SKELETONS**

Site Name/  
 Number Armoury Observer Crain  
 Feature/ Burial Number 10AR-00250 Date 4/17/2011  
 Burial/ Skeleton Number Individual #2  
 Present Location of Colonial  
 Collection Williamsburg

**CRANIAL BONES AND JOINT SURFACES**

	L (left)	R(right)		L(left)	R(right)
Frontal			Sphenoid		
Parietal	3	2	Zygomatic		3
Occipital	2	2	Maxilla		
Temporal	3	2	Palatine		
TMJ	2	1	Mandible	1	1

**POSTCRANIAL BONES AND JOINT SURFACES**

Clavicle	1	3	Os Coxae		
Scapula			Ilium	2	2
Body	3	3	Ischium	1	1
Glenoid f.	2	2	Pubis	2	2
Patella	1	1	Acetabulum	2	2
Sacrum	3	3	Auric. Surface	3	3
Cocryx					

**VERTEBRA (individual)**

	Centrum	Neural Arch
C1	2	3
C2	2	
C7		
T10		
T11		
T12		
L1		
L2		
L3		
L4		
L5		

**VERTEBRAE (group)**

	#Present/	#Complete
C3-6		
T1-T9		

	Centra	Neural Arches
	2	1
	4	9

**Sternum:**

	Manubrium	Body

**RIBS (individual)**

1st	3
2nd	
11th	
12th	

**RIBS (grouped)**

	#Present/	#Complete
3--10	131 Fragments	

Series/ Burial/ Skeleton  
Observer/Date

Armoury Individual  
#2  
Crain 04/17/2011

**LONG BONES**  
Diaphysis

	Proximal Epiphysis	Proximal Third	Middle Third		Distal Third	Distal Epiphysis
Left Humerus	1	1	1		1	2
Right Humerus	2	3	1		1	2
Left Radius	1	1	1		1	1
Right Radius	2	3	1		1	1
Left Ulna	1	1	1		1	
Right Ulna	3	1	1		1	3
Left Femur	1	1	1		1	1
Right Femur	1	1	1		1	1
Left Tibia	1	1	1		1	1
Right Tibia	1	1	1		1	1
Left Fibula		2	2		1	
Right Fibula		1	1		1	1
Left Talus	1	1	1		1	1
Right Talus	2	1	1		1	1
Left Calcaneus	1	1	1		1	1
Right Calcaneus	3	3	2		2	1

**HAND (#Present/ #Complete)**

	<u>L</u>	<u>R</u>	<u>Unsided</u>
# Carpals	7	8	
# Metacarpals	5	5	
# Phalanges	4	14	

**FOOT (# Present/# Complete)**

	<u>L</u>	<u>R</u>	<u>Unsided</u>
# Tarsals	7	7	
#Metatarsals	5	5	
#Phalanges	5	6	

## **Appendix B**



<b>Institute for Historical Biology ANTHROPOMETERIC RECORD</b>				
Burial Number: Armoury Individual #1 10AR-00238				
Recorder: Crain				
Date: 3/23/2011				
<b>CRANIAL MEASUREMENTS (Pages 53-62)</b>				
<b>ALL MEASUREMENTS IN mm</b>				
			<u>Left</u>	<u>Right</u>
1.) MAXIMUM LENGTH (g-op):		13.) NASAL HEIGHT (n-ns):		
2.) MAXIMUM BREADTH (eu-eu):		14.) NASAL Breadth (al-al):		
3.) BIZYGOMATIC BREADTH (zy-zy):		15.) ORBITAL BREADTH (mf-ec):		
4.) BASION-BREGMA (ba-b):		16.) ORBITAL HEIGHT:		
5.) CRANIAL BASE LENGTH (ba-n):		17.) BIORBITAL BR. (ec-ec):		
6.) BASION-PROSTHION L. (ba-pr):		18.) INTEROBITAL BR. (mf-mf):		
7.) MAX. -ALVEOLAR BR. (ecm-ecm):		19.) FRONTAL CHORD (n-b):		
8.) MAX. -ALVEOLAR L. (pr-alv):		20.) PARIETAL CHORD (b-l):		
9.) BIAURICULAR BREADTH (au-aw):		21.) OCCIPITAL CHORD (l-o):		
10.) UPPER FACIAL HGT. (n-pr):		22.) FORAMEN MAGNUM L. (ba-o):		
11.) MIN. FRONTAL BR. (ft-ft):		23.) FORAMEN MAGNUM BR.:		
12.) UPPER FACIAL BR. (fmt-fmt):		24.) MASTOID LENGTH:		(19.65 mm)
<b>MANDIBULAR MEASUREMENTS (Pages 62-65)</b>				
	<u>Left</u>	<u>Right</u>	<u>Left</u>	<u>Right</u>
25.) CHIN HEIGHT (gn-id):		30.) MIN. RAMUS BREADTH:		
26.) BODY HEIGHT at MENTAL FOR:		31.) MAX. RAMUS BREADTH H:		
27.) BODY THICKNESS at M. FOR:		32.) MAX. RAMUS HEIGHT:		
28.) BIGONIAL DIAMETER (go-go):		33.) MAND. LENGTH:		
29.) BICONDYLAR BR. (cdl-cdl):		34.) MAND. ANGLE:		
<b>POSTCRANIAL MEASUREMENTS (Pages 65-79)</b>				
	<u>Left</u>	<u>Right</u>	<u>Left</u>	<u>Right</u>
<b>CLAVICLE: Epiph. P/A:</b>		<b>INNOMINATE: Epiph. P/A:</b>		
35.) MAXIMUM LENGTH:		57.) HEIGHT:		
36.) SAGITTAL DIAM. At MIDSH:		58.) ILIAC BREADTH:		
37.) VERTICAL DIAM. At MIDSH:		59.) PUBIS LENGTH:		
		60.) ISCHIUM LENGTH:		
<b>SCAPULA: Epiph. P/A:</b>		<b>FEMUR: Epiph. P/A:</b>		
38.) ANATOMICAL BREADTH (HGT):		61.) MAXIMUM LENGTH:		(447 mm)
39.) ANATOMICAL LENGTH (BR):		62.) BICONDYLAR LENGTH:		
40.) GLENOID CAV. LENGTH :		63.) EPICONDYLAR BREADTH:		
		64.) MAX. DIAM. Of HEAD:		
<b>HUMERUS: Epiph P/A:</b>		65.) A/P SUBTROCH. DIAMETER:		31.89 mm
41.) MAXIMUM LENGTH:		66.) TRANSV. SUBTROCH. DIAM:		22.45 mm
42.) EPICONDYLAR BREADTH:		67.) SAGITTAL DIAM. MIDSH:		25.41 mm
43.) MAX. VERT. DIAM. Of HEAD:		68.) TRANVS. DIAM. MIDSH:		24.41 mm
44.) MAX. DIAM. At MIDSHAFT:		69.) CIRCUMFERENCE AT MIDSH:		85 mm
45.) MIN. DIAM. At MIDSHAFT:				
<b>RADIUS: Epiph P/A:</b>		<b>TIBIA: Epiph P/A:</b>		
46.) MAXIMUM LENGTH:		70.) CONDYLO-MALLEOLAR LENGTH:		
47.) SAGITTAL DIAM. At MIDSH:		71.) MAX. PROX. EPIPH. BR:		
48.) TRANSV. DIAM. At MIDSH:		72.) MAX. DIST. EPIPH. BR:		
		73.) MAX. DIAM. NUTRIENT FOR:		
<b>ULNA: Epiph P/A:</b>		74.) TRANSV. DIAM. NUTR. FOR:		
49.) MAXIMUM LENGTH:		75.) CIRCUM. AT NUTR. FOR:		
50.) DORSO-VOLAR DIAMETER:				
51.) TRANVERSE DIAMETER:		<b>FIBULA: Epiph. P/A:</b>		
52.) PHYSIOLOGICAL LENGTH:		76.) MAXIMUM LENGTH:		
53.) MIN. CIRCUMFERENCE:		77.) MAX. DIAM. At MIDSHAFT:		
<b>SACRUM: No. Segments:</b>		<b>CALCANEUS: Epiph. P/A</b>		
54.) ANTERIOR LENGTH:		78.) MAXIMUM LENGTH:		
55.) ANTERIOR-SURFACE BR:		79.) MIDDLE BREADTH:		
56.) MAX. BREADTH (S-1):				

<b>Institute for Historical Biology ANTHROPOMETERIC RECORD</b>					
Burial Number: Armoury Burial individual #2 10AR-00250					
Recorder: Crain					
Date: 04/17/2011					
<b>CRANIAL MEASUREMENTS (Pages 53-62)</b>					
<b>ALL MEASUREMENTS IN mm</b>					
				<u>Left</u>	<u>Right</u>
1.) MAXIMUM LENGTH (g-op):			13.) NASAL HEIGHT (n-ns):		
2.) MAXIMUM BREADTH (eu-eu):	145.67 mm		14.) NASAL Breadth (al-al):		
3.) BIZYGOMATIC BREADTH (zy-zy):			15.) ORBITAL BREADTH (mf-ec):		
4.) BASION-BREGMA (ba-b):			16.) ORBITAL HEIGHT:		
5.) CRANIAL BASE LENGTH (ba-n):			17.) BIORBITAL BR. (ec-ec):		
6.) BASION-PROSTHION L. (ba-pr):			18.) INTEROBITAL BR. (mf-mf):		
7.) MAX. -ALVEOLAR BR. (ecm-ecm):			19.) FRONTAL CHORD (n-b):		
8.) MAX. -ALVEOLAR L. (pr-alv):			20.) PARIETAL CHORD (b-l):		
9.) BIAURICULAR BREADTH (au-aw):	164 mm		21.) OCCIPITAL CHORD (l-o):		
10.) UPPER FACIAL HGT. (n-pr):			22.) FORAMEN MAGNUM L. (ba-o):		
11.) MIN. FRONTAL BR. (ft-ft):			23.) FORAMEN MAGNUM BR.:		
12.) UPPER FACIAL BR. (fmt-fmt):			24.) MASTOID LENGTH:	37.1 mm	35.52 mm
<b>MANDIBULAR MEASUREMENTS (Pages 62-65)</b>					
	<u>Left</u>	<u>Right</u>		<u>Left</u>	<u>Right</u>
25.) CHIN HEIGHT (gn-id):			30.) MIN. RAMUS BREADTH:	34.92 mm	34.27 mm
26.) BODY HEIGHT at MENTAL FOR:	21.96 mm	21.26 mm	31.) MAX. RAMUS BREADTH H:		
27.) BODY THICKNESS at M. FOR:	11.07 mm	9.66 mm	32.) MAX. RAMUS HEIGHT:		
28.) BIGONIAL DIAMETER (go-go):			33.) MAND. LENGTH:		
29.) BICONDYLAR BR. (cdl-cdl):			34.) MAND. ANGLE:		
<b>POSTCRANIAL MEASUREMENTS (Pages 65-79)</b>					
	<u>Left</u>	<u>Right</u>		<u>Left</u>	<u>Right</u>
<b>CLAVICLE: Epiph. P/A:</b>			<b>INNOMINATE: Epiph. P/A:</b>		
35.) MAXIMUM LENGTH:			57.) HEIGHT:		195.33 mm
36.) SAGITTAL DIAM. At MIDSH:			58.) ILIAC BREADTH:		
37.) VERTICAL DIAM. At MIDSH:			59.) PUBIS LENGTH:		
<b>SCAPULA: Epiph. P/A:</b>			60.) ISCHIUM LENGTH:	61.52 mm	
38.) ANATOMICAL BREADTH (HGT):			<b>FEMUR: Epiph. P/A:</b>		
39.) ANATOMICAL LENGTH (BR):			61.) MAXIMUM LENGTH:	458 mm	
40.) GLENOID CAV. LENGTH :			62.) BICONDYLAR LENGTH:	452 mm	444 mm
<b>HUMERUS: Epiph P/A:</b>			63.) EPICONDYLAR BREADTH:		
41.) MAXIMUM LENGTH:	343 mm		64.) MAX. DIAM. Of HEAD:	46.95 mm	47.33 mm
42.) EPICONDYLAR BREADTH:			65.) A/P SUBTROCH. DIAMETER:	26.58 mm	27.37 mm
43.) MAX. VERT. DIAM. Of HEAD:	47.88 mm		66.) TRANSV. SUBTROCH. DIAM:	32.33 mm	33.15 mm
44.) MAX. DIAM. At MIDSHAFT:	24.38 mm		67.) SAGITTAL DIAM. MIDSH:	33.28 mm	33.66 mm
45.) MIN. DIAM. At MIDSHAFT:	24.3 mm		68.) TRANVS. DIAM. MIDSH:	27.31 mm	27.60 mm
			69.) CIRCUMFERENCE AT MIDSH:	97 mm	97.33 mm
<b>RADIUS: Epiph P/A:</b>			<b>TIBIA: Epiph P/A:</b>		
46.) MAXIMUM LENGTH:	260.6 mm		70.) CONDYLO-MALLEOLAR LENGTH:		393.33 mm
47.) SAGITTAL DIAM. At MIDSH:	15.46 mm		71.) MAX. PROX. EPIPH. BR:	75.33 mm	74 mm
48.) TRANSV. DIAM. At MIDSH:	13 mm		72.) MAX. DIST. EPIPH. BR:		
<b>ULNA: Epiph P/A:</b>			73.) MAX. DIAM. NUTRIENT FOR:	36.86 mm	36.8 mm
49.) MAXIMUM LENGTH:			74.) TRANSV. DIAM. NUTR. FOR:	23.26 mm	27.72 mm
50.) DORSO-VOLAR DIAMETER:	21.98 mm	19.62 mm	75.) CIRCUM. AT NUTR. FOR:	100.33	102.67
51.) TRANVERSE DIAMETER:	17.38 mm	17.25 mm	<b>FIBULA: Epiph. P/A:</b>		
52.) PHYSIOLOGICAL LENGTH:			76.) MAXIMUM LENGTH:		
53.) MIN. CIRCUMFERENCE:	46.7 mm		77.) MAX. DIAM. At MIDSHAFT:		
<b>SACRUM: No. Segments:</b>			<b>CALCANEUS: Epiph. P/A</b>		
54.) ANTERIOR LENGTH:			78.) MAXIMUM LENGTH:	85.11 mm	
55.) ANTERIOR-SURFACE BR:			79.) MIDDLE BREADTH:	40.1 mm	
56.) MAX. BREADTH (S-1):					

## **Appendix C**

Table Seven: Markers of Pathological and Occupational Stress, Individual #2

Element	Side	Condition	Notes
Mandible	n/a	Edentulous	active and complete remodeling of the alveolar bone
Clavicle	left	Hypertrophy	conoid tubercle, trapezoid line, costal impression, subclavian sulcus
Clavicle	right	Hypertrophy	costal impression (enthesopathy), subclavian sulcus
Scapula	left	Hypertrophy	medial, lateral and axillary borders
Scapula	right	Hypertrophy	medial, lateral, and axillary borders
Humerus	left	Hypertrophy	greater tubercle, lesser tubercle, intertubercular sulcus, deltoid tuberosity, lateral supracondylar crest
Humerus	right	Hypertrophy	deltoid tuberosity, lateral supracondylar crest
ulna	left	Hypertrophy	ulnar tuberosity
ulna	left	Arthritis	radial notch
radius	left	Hypertrophy	radial tuberosity, pronator teres insertion
radius	left	Arthritis	distal articular surface
radius	right	Arthritis	distal articular surface
Thoracic Vertebra	n/a	Schmorl's Node	vertebral body, marked expression
Lumbar Vertebra	n/a	Schmorl's Node	vertebral body, marked expression
Lumbar Vertebra	n/a	Arthritis	osteophytic lipping with curved spicules
Os Coxae	left	Hypertrophy	attachment point for the <i>straight head rectus femoris</i> , gluteal lines
Os Coxae	right	Hypertrophy	attachment point for the <i>straight head rectus femoris</i> , gluteal lines

Table Seven: Markers of Pathological and Occupational Stress, Individual #2 (part two)

Element	Side	Condition	Notes
Femur	left	Hypertrophy	intertrochanteric line, greater trochanter, lesser trochanter, trochanteric fossa, trochanteric fossa, pectineal line, gluteal line, linea aspera, medial supracondylar line, popliteal surface
Femur	right	Hypertrophy	intertrochanteric line, greater trochanter, lesser trochanter, trochanteric fossa, trochanteric fossa, pectineal line, gluteal line, linea aspera, medial supracondylar line, popliteal surface
Femur	right	Arthritis	chipping of the lateral condyle, inferior of the popliteal surface
Patella	left	Arthritis	enthesophyte at the attachment of the <i>straight head rectus femoris</i>
Fibula	left	Hypertrophy	attachment areas for the <i>peroneus longus and soleus</i> muscles, peroneus groove
Fibula	right	Hypertrophy	attachment areas for the <i>soleus, hallucis longus, peroneus longus, peroneus tertius</i>
Fibula	right	Arthritis	malleolar fossa

Table Seven: Markers of Pathological and Occupational Stress, Individual #2 (part three)

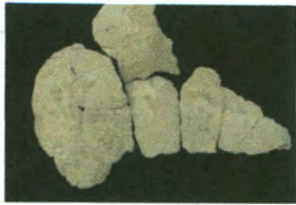Element	Side	Condition	Notes
Tibia	left	Arthritis	osteophytic lipping along the anterior portion of the lateral condyle, bone spur located on the lateral intercondylar tubercle
Tibia	left	Periostitis	sclerotic and healed, elevated lesions
Tibia	right	Hypertrophy	Insertion points for the <i>vastus medialis</i> , <i>sartorius</i> , <i>gracilis</i> , <i>semitendinosus</i> , <i>tibia posterior</i> , soleal line, and malleolar groove,
Tibia	right	Arthritis	osteophytic lipping along the anterior section of the lateral condyle, osteological reaction at the medial portion of the tibia plateau, interior portion of the intercondylar eminence, and anterior ridge of the superior and inferior facets
Tibia	right	Periostitis	healed elevated lesions
First meta carpal	left	Arthritis	osteophyte development along the proximal palmar area and articular facet with the trapezoid
First meta carpal	right	Arthritis	osteophyte development along the proximal palmar area

Table Seven: Markers of Pathological and Occupational Stress, Individual #2 (part four)

Element	Side	Condition	Notes
Tarsals	left	Arthritis	osteophytic lipping along the articular facets of the calcaneus and talus
Tarsals	right	Arthritis	osteophytic lipping along the articular facets of the calcaneus and talus

## Appendix D





10AR-00238-01.JPG



10AR-00238-02.JPG



10AR-00238-03.JPG




10AR-00238-04.JPG



10AR-00238-05.JPG



10AR-00238-06.JPG



10AR-00238-07.JPG



10AR-00238-08.JPG




10AR-00238-09.JPG



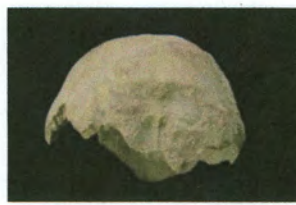10AR-00238-10.JPG



10AR-00238-11.JPG



10AR-00238-12.JPG



10AR-00250-01.JPG



10AR-00250-02.JPG



10AR-00250-03.JPG



10AR-00250-04.JPG



10AR-00250-05.JPG



10AR-00250-06.JPG



10AR-00250-07.JPG



10AR-00250-08.jpg



10AR-00250-09.JPG



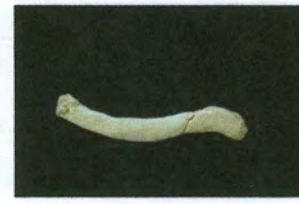
10AR-00250-10.JPG



10AR-00250-11.JPG



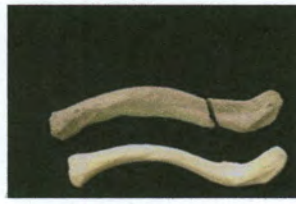10AR-00250-12.JPG



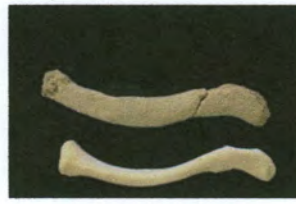10AR-00250-13.JPG



10AR-00250-14.JPG



10AR-00250-15.JPG



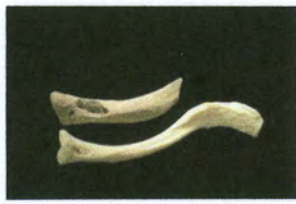10AR-00250-16.JPG



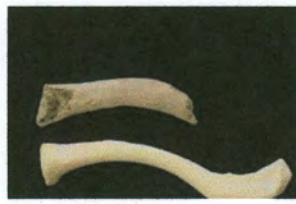10AR-00250-17.JPG



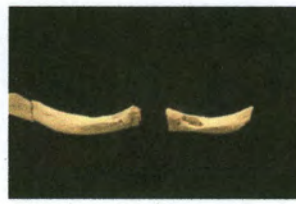10AR-00250-18.JPG



10AR-00250-19.JPG



10AR-00250-20.JPG



10AR-00250-21.JPG



10AR-00250-22.JPG



10AR-00250-23.JPG



10AR-00250-24.JPG



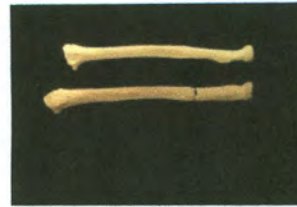10AR-00250-25.JPG



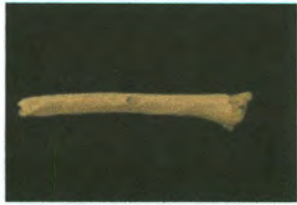10AR-00250-26.JPG



10AR-00250-27.JPG



10AR-00250-28.JPG



10AR-00250-29.JPG



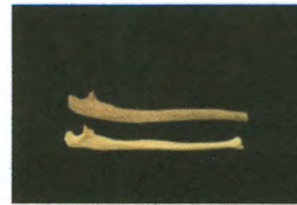10AR-00250-30.JPG



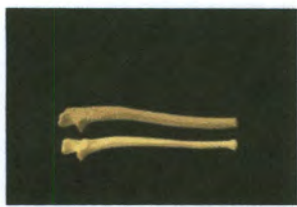10AR-00250-31.JPG



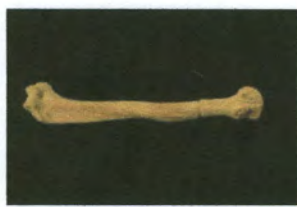10AR-00250-32.JPG



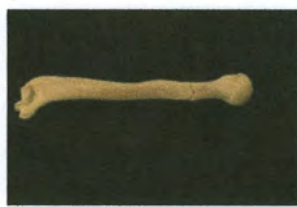
10AR-00250-33.JPG



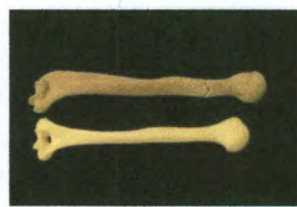10AR-00250-34.JPG



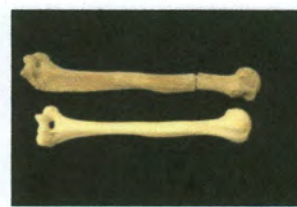10AR-00250-35.JPG



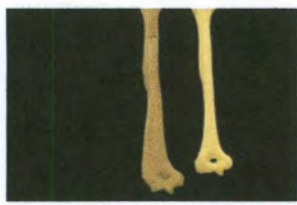
10AR-00250-36.JPG



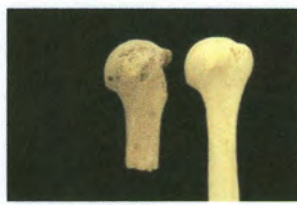10AR-00250-37.JPG



10AR-00250-38.JPG



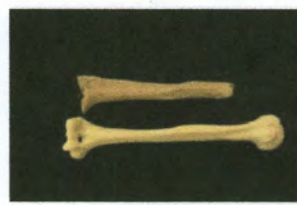10AR-00250-39.JPG



10AR-00250-40.JPG



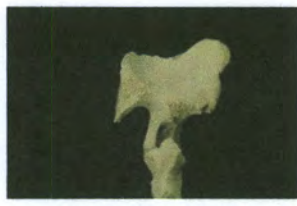10AR-00250-41.JPG



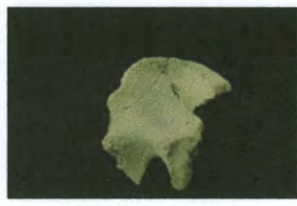
10AR-00250-42.JPG



10AR-00250-43.JPG



10AR-00250-44.JPG



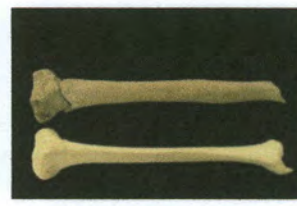
10AR-00250-45.JPG



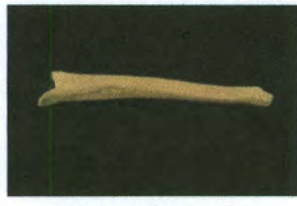
10AR-00250-46.JPG



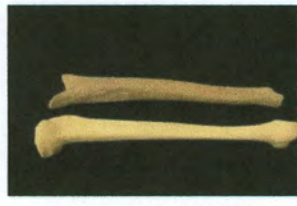10AR-00250-47.JPG



10AR-00250-48.JPG



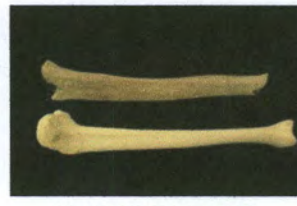
10AR-00250-49.JPG



10AR-00250-50.JPG



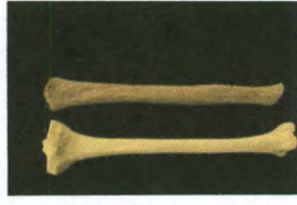10AR-00250-51.JPG



10AR-00250-52.JPG



10AR-00250-53.JPG



10AR-00250-54.JPG



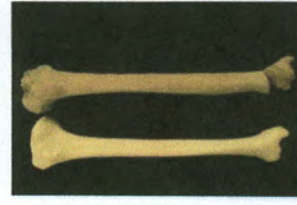
10AR-00250-55.JPG



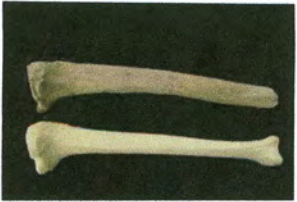
10AR-00250-56.JPG



10AR-00250-57.JPG



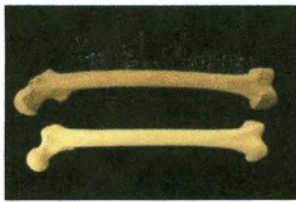
10AR-00250-58.JPG



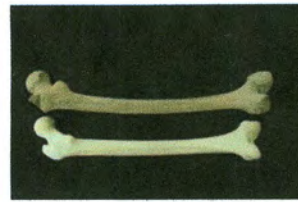
10AR-00250-59.JPG



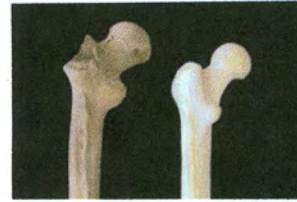
10AR-00250-60.JPG



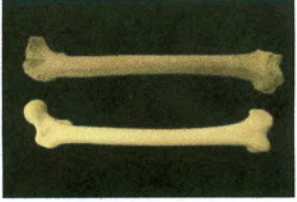
10AR-00250-61.JPG



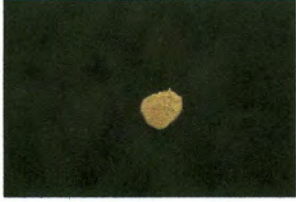10AR-00250-62.JPG



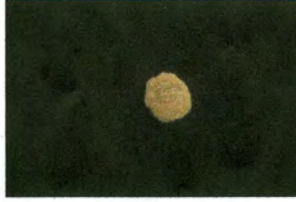10AR-00250-63.jpg



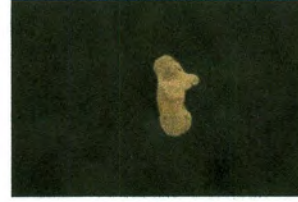10AR-00250-64.JPG



10AR-00250-65.JPG



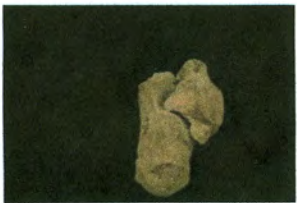10AR-00250-66.JPG



10AR-00250-67.JPG



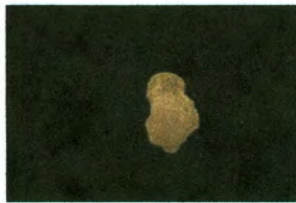10AR-00250-68.JPG



10AR-00250-69.JPG



10AR-00250-70.JPG



10AR-00250-71.JPG

Institute for Historical Biology Photo Log

Photographer: Christopher Crain

Date: 4/29-4/30 2011

Site ID: James Anderson's Public Armoury, Individual #1 (10AR--00238) and Individual #2 (10AR-00250)

Photo Number	Burial ID	Element	Side	Aspect	Comment
10AR-00238-01	Individual #1	Calvarium	n/a	Superior	Frontal, parietal, and temporal fragments
10AR-00238-02	Individual #1	Temporal	Right	Lateral	Missing mastoid process
10AR-00238-03	Individual #1	Mandible	n/a	Superior	
10AR-00238-04	Individual #1	Mandible	n/a	Inferior	
10AR-00238-05	Individual #1	Acetabulum	Left	Lateral	Micro and macroporosity
10AR-00238-06	Individual #1	Tibia	Left	Lateral	Distal third diaphyseal Fragment
10AR-00238-07	Individual #1	Tibia	Left	Medial	Distal two thirds diaphyseal fragments
10AR-00238-08	Individual #1	Femur	Right	Anterior	Proximal third diaphyseal fragment
10AR-00238-09	Individual #1	Femur	Right	Posterior	Proximal third diaphyseal fragment
10AR-00238-10	Individual #1	Femur	Left	Anterior	Proximal two thirds diaphyseal fragments
10AR-00238-11	Individual #1	Femur	Left	Posterior	Proximal two thirds diaphyseal fragments
10AR-00238-12	Individual #1	Femur	Left	Posterior	Comparison with anatomical specimen
10AR-00250-01	Individual #2	Calvarium	n/a	Posterior	Occipital with nuchal crest
10AR-00250-02	Individual #2	Calvarium	Left	Lateral	Left parietal and occipital
10AR-00250-03	Individual #2	Calvarium	Right	Lateral	Right parietal and occipital
10AR-00250-04	Individual #2	Calvarium	n/a	Superior	Left and right parietal
10AR-00250-05	Individual #2	Temporal	Left	Lateral	Temporal fragment with mastoid process
10AR-00250-06	Individual #2	Temporal	Right	Lateral	Temporal fragment with mastoid process
10AR-00250-07	Individual #2	Mandible	n/a	Superior	
10AR-00250-08	Individual #2	Mandible	n/a	Superior	Reconstructed
10AR-00250-09	Individual #2	Axis	n/a	Anterior	
10AR-00250-10	Individual #2	Axis	n/a	Posterior	
10AR-00250-11	Individual #2	Thoracic	n/a	Superior	Schmorl's node
10AR-00250-12	Individual #2	Lumbar	n/a	Superior	Osteophytic lipping
10AR-00250-13	Individual #2	Clavicle	Left	Superior	
10AR-00250-14	Individual #2	Clavicle	Left	Inferior	
10AR-00250-15	Individual #2	Clavicle	Left	Inferior	Comparison with anatomical specimen

Photo Number	Burial ID	Element	Side	Aspect	Comment
10AR-00250-16	Individual #2	Clavicle	Left	Superior	Comparison with anatomical specimen
10AR-00250-17	Individual #2	Clavicle	Right	Inferior	Enthesopathy of the conoid tubercle
10AR-00250-18	Individual #2	Clavicle	Right	Superior	
10AR-00250-19	Individual #2	Clavicle	Right	Inferior	Comparison with anatomical specimen
10AR-00250-20	Individual #2	Clavicle	Right	Superior	Comparison with anatomical specimen
10AR-00250-21	Individual #2	Clavicle	Both	Inferior	Comparison of individual #2's clavicles
10AR-00250-22	Individual #2	Scapula	Left	Anterior	
10AR-00250-23	Individual #2	Scapula	Left	Posterior	
10AR-00250-24	Individual #2	Scapula	Left	Anterior	Comparison with anatomical specimen
10AR-00250-25	Individual #2	Scapula	Left	Posterior	Comparison with anatomical specimen
10AR-00250-26	Individual #2	Radius	Left	Anterior	
10AR-00250-27	Individual #2	Radius	Left	Anterior	Comparison with anatomical specimen
10AR-00250-28	Individual #2	Radius	Left	Posterior	Comparison with anatomical specimen
10AR-00250-29	Individual #2	Radius	Right	Posterior	
10AR-00250-30	Individual #2	Radius	Right	Anterior	Comparison with anatomical specimen
10AR-00250-31	Individual #2	Ulna	Left	Lateral	
10AR-00250-32	Individual #2	Ulna	Left	Medial	
10AR-00250-33	Individual #2	Ulna	Left	Medial	Comparison with anatomical specimen
10AR-00250-34	Individual #2	Ulna	Left	Lateral	Comparison with anatomical specimen
10AR-00250-35	Individual #2	Humerus	Left	Anterior	
10AR-00250-36	Individual #2	Humerus	Left	Posterior	
10AR-00250-37	Individual #2	Humerus	Left	Posterior	Comparison with anatomical specimen
10AR-00250-38	Individual #2	Humerus	Left	Anterior	Comparison with anatomical specimen
10AR-00250-39	Individual #2	Humerus	Left	Posterior	Comparison with anatomical specimen
10AR-00250-40	Individual #2	Humerus	Left	Anterior	Comparison proximal third
10AR-00250-41	Individual #2	Humerus	Right	Anterior	
10AR-00250-42	Individual #2	Humerus	Right	Anterior	Comparison with anatomical specimen
10AR-00250-43	Individual #2	Innominate	Left	Lateral	
10AR-00250-44	Individual #2	Innominate	Left	Medial	
10AR-00250-45	Individual #2	Innominate	Right	Medial	
10AR-00250-46	Individual #2	Fibula	Left	Lateral	
10AR-00250-47	Individual #2	Fibula	Right	Lateral	

Photo Number	Burial ID	Element	Side	Aspect	Comment
10AR-00250-48	Individual #2	Tibia	Left	Anterior	Comparison with anatomical specimen
10AR-00250-49	Individual #2	Tibia	Left	Medial	
10AR-00250-50	Individual #2	Tibia	Left	Medial	Comparison with anatomical specimen
10AR-00250-51	Individual #2	Tibia	Left	Lateral	Sclerotic periostitis
10AR-00250-52	Individual #2	Tibia	Left	Lateral	Comparison with anatomical specimen
10AR-00250-53	Individual #2	Tibia	Left	Posterior	
10AR-00250-54	Individual #2	Tibia	Left	Posterior	Comparison with anatomical specimen
10AR-00250-55	Individual #2	Tibia	Left	Posterior	Hypertrophy of soleal line
10AR-00250-56	Individual #2	Tibia	Left	Lateral	Periostitis with advanced healing
10AR-00250-57	Individual #2	Tibia	Right	Anterior	
10AR-00250-58	Individual #2	Tibia	Right	Anterior	Comparison with anatomical specimen
10AR-00250-59	Individual #2	Tibia	Right	Lateral	Comparison with anatomical specimen
10AR-00250-60	Individual #2	Tibia	Right	Lateral	Distal diaphysis with healed periostitis
10AR-00250-61	Individual #2	Femur	Left	Anterior	Comparison with anatomical specimen
10AR-00250-62	Individual #2	Femur	Left	Posterior	Comparison with anatomical specimen
10AR-00250-63	Individual #2	Femur	Left	Posterior	Comparison proximal-anterior ends
10AR-00250-64	Individual #2	Femur	Right	Anterior	Comparison with anatomical specimen
10AR-00250-65	Individual #2	Patella	Left	Anterior	Enthesophyte
10AR-00250-66	Individual #2	Patella	Right	Anterior	
10AR-00250-67	Individual #2	Calcaneus	Left	Superior	
10AR-00258-68	Individual #2	Talus	Left	Superior	
10AR-00250-69	Individual #2	Calcaneus/Talus	Left	Lateral	Articulated, osteophytic activity
10AR-00250-70	Individual #2	Calcaneus	Right	Superior	
10AR-00250-71	Individual #2	Talus	Right	Superior	.