

# Ectopic Pregnancy following Interval Tubal Sterilization: Lessons Learnt

Deepak Shrestha,<sup>a,d</sup> Sebina Baniya,<sup>b,d</sup> Sudeep Regmi<sup>c,d</sup>

## ABSTRACT:

**Introduction:** Tubal sterilization is a highly effective method of permanent contraception. However, pregnancy can still occur following a successful procedure. Published literatures report a failure rate of 0.13-1.3% and 15-33% of such pregnancies are likely to be ectopic. **Case report:** A 33 years para three lady with prior history of tubal ligation presented with generalized abdominal pain and several episodes of vomiting. Bimanual examination revealed a soft and mobile mass of 2 x 3 cm in right adnexa. Urine pregnancy test was positive and ultrasonogram showed a heterogeneous mass of 3.4 x 3.3 cm in right adnexa with empty uterine cavity. Culdocentesis resulted in aspiration of frank non-clotting blood. She then underwent emergency laparotomy with bilateral salpingectomy for ruptured ectopic pregnancy. **Conclusion:** Ectopic pregnancy after tubal sterilization though rare is not entirely impossible. All women who are offered this procedure should always be educated about its failure rate. And in women presenting with acute abdomen, a prior history of tubal sterilization doesn't preclude the possibility of ectopic pregnancy.

**Keywords:** contraception • ectopic • pregnancy • salpingectomy • tubal sterilization

## INTRODUCTION:

Tubal sterilization is one of the most successful methods of contraception with an extremely low failure rate.[1] Although highly effective and considered a definitive form of contraception, pregnancy can still occur after a successful procedure. The estimated failure rate is reported to be 0.13-1.3%.[2] However, in case of failure, tubal sterilization is associated with a high risk of ectopic pregnancy, a potentially lethal condition accounting for up to 73% of early pregnancy mortality.[3,4]

Ectopic pregnancy continues to be an important cause of maternal morbidity and mortality resulting in 2-2.5% of maternal deaths.[5] More important, many of these fatalities are preventable. Here we present a rare incidence of tubal pregnancy after bilateral tubal sterilization who landed up with hemoperitoneum and was successfully managed.

## CASE REPORT:

A 33 years para three lady with previous regular cycles presented to gynecology out-patient department with complaints of amenorrhea for one and a half months and abdominal pain for three days. Her abdominal pain was initially confined to periumbilical region which later became generalized. She also had seven episodes of non-projectile vomiting in the last three days. Apart from that, she did not have any vaginal bleeding, dizziness, loss of consciousness, shoulder pain or fever.

She had an uncomplicated spontaneous abortion ten years back. She had undergone bilateral tubal ligation five years back via minilaparotomy. She had also been taking propranolol, escitalopram,

a - Lecturer, Department of Obstetric and Gynecology

b - Resident, Department of Obstetric and Gynecology

c - Lecturer, Department of Pathology

d - Lumbini Medical College Teaching Hospital, Palpa, Nepal

### Corresponding Author:

Deepak Shrestha,

e-mail: [thecups814@gmail.com](mailto:thecups814@gmail.com)

### How to cite this article:

Shrestha D, Baniya S, Regmi S. Ectopic pregnancy following interval tubal sterilization: Lessons learnt. Journal of Lumbini Medical College. 2017;5(2):77-80. Epub. 19 Nov 2017. doi: 10.22502/jlmc.v5i2.139.



and clobazam for anxiety disorder for last five years. On examination she had pallor and was hemodynamically stable. Her abdomen was soft and non-tender. Per speculum examination showed a parous os with no evidence of bleeding. Bimanual examination revealed a soft and slightly mobile mass approximately 2 x 3 cm in right adnexa. Uterus was bulky. Cervical motion tenderness was however conspicuously absent.

Her urine tested positive for pregnancy. With the suspicion of ectopic pregnancy, an ultrasonogram (USG) was ordered which reported a heterogeneous complex mass of 3.4 x 3.3 cm in right adnexa with moderate intraperitoneal collection and empty uterine cavity. Ovaries were visualized separately and were radiologically normal. Culdocentesis was carried out resulting in aspiration of around 10 ml of dark, non-clotting blood. This pinned the diagnosis of hemoperitoneum, the cause being ruptured ectopic pregnancy post sterilization. Apart from hemoglobin level of five gm%, all other blood parameters were normal.

Having counseled the patient and the attending party, an informed consent was taken for emergency laparotomy. On opening the peritoneal cavity, gross hemoperitoneum with frank blood of around 1100 ml was noted. Distal remnant of fallopian tube was reddish blue and distended. However no definite rent was identified in the tube and blood was noted dripping from the fimbrial end thus suggesting tubal abortion. The affected tube in our case showed evidence of previous ligation as fibrosed and narrowed points (Fig: 1). The contralateral tube also

showed transected portion. Both the ovaries were normal looking. Bilateral salpingectomy was then done. Interestingly, a 2 x 3 cm ulcerated bleeding area was also noted in the infracolic part of omentum which was then resected and the specimen sent for histopathological examination. A total blood loss of 1200 ml was estimated. She received a total of four pints of fresh blood transfusion. Following an uneventful recovery, she was discharged on the fifth postoperative day on oral antibiotics and hematinics.

Histopathological examination of the specimen confirmed the presence of chorionic villi lined by cytotrophoblasts and syncytiotrophoblasts in the tube. The omental biopsy merely showed areas of chronic inflammatory cell infiltrates suggesting omentitis (Fig: 2).

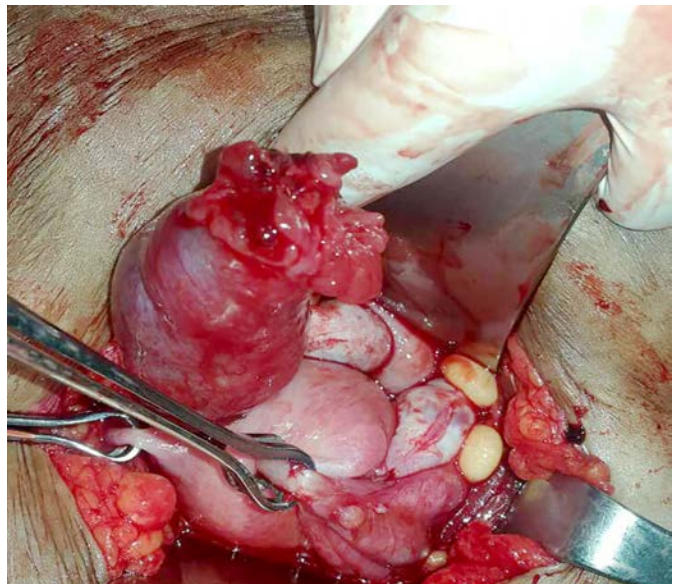


Fig 2: Omental biopsy showing omentitis

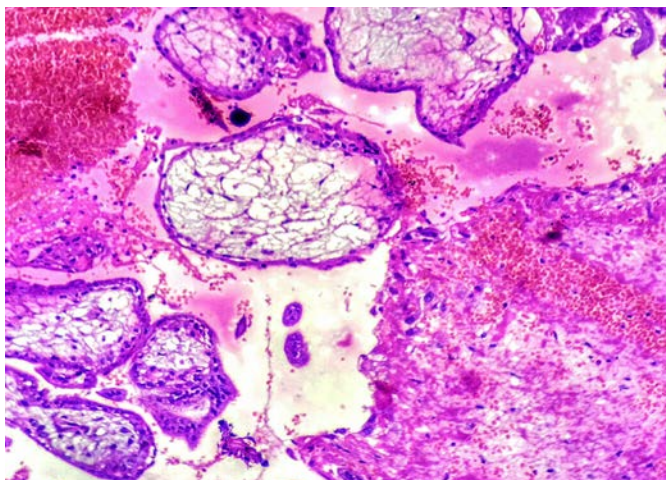


Fig 1: Fibrosis in the fallopian tube due to previous ligation.

## DISCUSSION:

The number of women resorting to elective sterilization has been increasing in Nepal. It has a very low failure rate, reported to be 1.16% in study by Takeda et al.[6] In case of failure, 15-33% of such pregnancies are ectopics.[2] However, no such studies exploring failure rate of tubal sterilization have been carried out in our country. This is the first reported case from our centre describing ectopic pregnancy in distal remnant of tube following sterilization.

The largest study done so far, the US Collaborative Review of Sterilization (CREST)

reported a 10 year cumulative pregnancy rate of 18.5/1000 women and 30 % of these were ectopic. This multicentre prospective cohort study by Peterson et al. reported two ectopic pregnancies in 1637 women (0.12%) after the postpartum salpingectomy.[7]

The CREST study suggests that the risk of pregnancy persists many years after tubal sterilization. Predominant factors believed to contribute to failure include: operator technique, type of surgical method and age of the patient at the time of the procedure.[7,8,9]

The likelihood of failure of tubal sterilization in women less than 30 years is reported to be twice than in older women thus promoting ectopic pregnancy. The probability of failure for women sterilized at ages 28–33 years is greater than 34–44 years for all methods of sterilization except interval partial salpingectomy.[7] Although our case had interval tubal sterilization, she was 28 years at the time of procedure which could be considered one of the risk factors.

Procedural technique is another critical determinant of sterilization failure. Methods employing bipolar coagulation system are proven to be more effective than those using unipolar coagulation system. Interval tubal sterilization utilizes modified Pomeroy's technique mostly which involves removing part of the fallopian tube. Among several theories behind sterilization failure, subsequent recanalisation and tuboperitoneal fistulae formation are the main explanations. Thus formed fistulae do not have a large enough opening so as to permit a fertilized ovum to pass, resulting in distal segment implantation. Another explanation is that in the process of recanalisation there is an abnormal reconstitution of the tubal lumen with the formation of blind pouches and slit like spaces and that this is responsible for the greater likelihood of ectopic implantation. The previously ligated portion of the affected tube in our case was evident as narrow fibrosed point but the two ends were continuous suggesting formation of tuboperitoneal fistula.

Adequate diathermy of the proximal ends of the resected tubes or ligation with clips may be necessary to decrease the possibility of failure of the procedure. This eventually translates to decrease in the incidence of post sterilization ectopics. This modification of proximal portion fulguration is routinely practiced in our centre. However, this case had undergone only ligation followed by resection

of the tubes in another centre. Had fulguration been performed, occurrence of the ectopic might have been avoided.

The time period between the tubal sterilization surgery and the occurrence of ectopic pregnancy varies greatly. Failure of sterilization beyond two years is more likely to result in ectopic pregnancy. This case had undergone tubal ligation five years back which again could have predisposed it to ectopic pregnancy.

From management standpoint, it is advocated that bilateral salpingectomy be performed at the time of an exploration for an ectopic pregnancy, which has occurred after a sterilization procedure. Our case underwent the same.

Often these cases are initially misdiagnosed as pelvic inflammatory disease and ruptured corpus luteal cyst. Such delay in diagnosis could increase the morbidity and sometimes lead to mortality. A prior history of bilateral tubal ligation doesn't, therefore, always preclude the possibility of ectopic pregnancy. Our case emphasizes this very fact. So a high index of suspicion for ectopic pregnancy should always be allotted when women of reproductive age, even after tubal sterilization, present with acute abdomen.

## CONCLUSION:

Ectopic pregnancy after tubal sterilization, though rare, can occur. Particularly women sterilized before the age of 30 years are at risk. All women undergoing this procedure need to be explicitly counseled regarding these failure rates and that, ectopic pregnancy may occur even long after sterilization.

Especially gynecologists as well as general medical practitioners should never forget that a prior history of sterilization does not entirely exclude the possibility of ectopic pregnancy. These women might actually be at an increased risk and an extrauterine pregnancy can still occur several years after sterilization.

## Conflict of Interest:

None

## Copyright:

Authors, 2017.

**REFERENCES:**

1. Peterson HB. Sterilization: Obstet Gynecol. 2008 Jan;111(1):189–203. DOI: 10.1097/01.aog.0000298621.98372.62 PMID: 18165410
2. Awonuga AO, Imudia AN, Shavell VI, Berman J, Diamond MP, Puscheck EE. Failed female sterilization: a review of pathogenesis and subsequent contraceptive options. J Reprod Med. 2009 Sep;54(9):541-7. PMID: 19947030
3. Drakopoulos P, Julen O, Petignat P, Dallenbach P. Spontaneous ectopic tubal pregnancy after laparoscopic tubal sterilisation by segmental isthmic partial salpingectomy. Case Reports. 2014 Mar 22;2014(mar21 1). DOI: 10.1136/bcr-2013-203131
4. Condous G. Ectopic pregnancy--risk factors and diagnosis. Aust Fam Physician. 2006 Nov;35(11):854–7. PMID: 17099802
5. Samiei-Sarir B, Diehm C. Recurrent Ectopic Pregnancy in the Tubal Remnant after Salpingectomy. Case Reports in Obstetrics and Gynecology. 2013;2013:1–3. DOI: 10.1111/j.1447-0756.2006.00385.x
6. Takeda A, Manabe S, Mitsui T and Nakamura H. Spontaneous ectopic pregnancy occurring in the isthmic portion of the remnant tube after ipsilateral adnexectomy: report of two cases. J Obstet Gynaecol Res. 2006; 32(2):190–194. DOI: 10.1111/j.1447-0756.2006.00385.x pmid: 16594923
7. Peterson HB, Xia Z, Hughes JM, Wilcox LS, Tylor LR, Trussell J. The risk of ectopic pregnancy after tubal sterilization. U.S. Collaborative Review of Sterilization Working Group. N Engl J Med. 1997 Mar 13;336(11):762–7. DOI: 10.1056/NEJM199703133361104
8. Lawrie TA, Nardin JM, Kulier R, Boulvain M. Techniques for the interruption of tubal patency for female sterilisation. In: The Cochrane Collaboration, editor. Cochrane Database of Systematic Reviews [Internet]. Chichester, UK: John Wiley & Sons, Ltd; 2011. DOI: 10.1002/14651858.CD003034.pub2
9. Ercan CM, Coksuer H, Alanbay I, Karasahin KE, Baser I. Intrauterine pregnancy after laparoscopic tubal sterilization with bipolar electrocoagulation: a case report. J Reprod Med. 2011 Aug;56(7–8):366–8. PMID: 21838172