

Open Access

CASE REPORT

Emphysematous Cystitis along with Emphysematous Pyelonephritis in Type II Diabetes: A Case Report

Awais Saeed Abbasi ¹, Zahid Nabi ²

¹Registrar, Department of Accident and Emergency, Dr. Akbar Niazi Teaching Hospital Islamabad
²Head Department of Nephrology, KRL Hospital Islamabad

ABSTRACT

Emphysematous urinary tract infections (UTIs) are infections of the lower or upper urinary tract associated with gas formation. They may manifest as cystitis, pyelitis, or pyelonephritis. Diabetes mellitus is a major risk factor for these infections. The diagnosis of gas-forming UTI is usually made by plain films of the abdomen and/or computed tomography (CT). *Escherichia coli* and *Klebsiella pneumonia* are the predominant etiologic organisms. We present a rare case of emphysematous cystitis along with emphysematous pyelonephritis in a patient with poorly controlled diabetes. This patient underwent nephrectomy and 500 ml of puss was drained before nephrectomy. Puss C/S showed growth of *Escherichia coli* which was sensitive to piperacillin/tazobactam. We conclude that all female diabetic patients more than 60 years of age presenting with urinary symptoms, abdominal pain, fever and evidence of UTI on urine routine examination should have at-least an ultrasound abdomen and kidney ureter bladder (KUB) done and if presence of air is suspected, these patients should get CT scan KUB done so that diagnosis of emphysematous UTI be made and managed accordingly.

Key Words: Cystitis, Diabetes, Emphysematous Cystitis, pyelonephritis

Address of Correspondence

Awais Saeed

Email: awais1357@yahoo.com

Article info.

Received: June 5, 2018

Accepted: September 12, 2018

Cite this case Report: Abbasi AS, Nabi Z. Emphysematous Cystitis along with emphysematous pyelonephritis in type II diabetes: A Case Report. JIMDC. 2018; 7(3):225-228

Funding Source: Nil

Conflict of Interest: Nil

Introduction

Emphysematous urinary tract infections (UTIs) are infections of the lower or upper urinary tract associated with gas formation. They may manifest as cystitis, pyelitis, or pyelonephritis. Diabetes mellitus is a major risk factor for these infections and is also associated with an increased risk of asymptomatic bacteriuria and certain symptomatic UTIs such as cystitis, renal and perinephric abscess, and *Candida* infections.¹⁻³ Elevated tissue glucose levels in diabetic patients may provide a more favorable microenvironment for gas-forming microbes. However, bacterial gas production does not fully explain the pathologic and clinical manifestations of emphysematous UTIs.^{4,5} Diabetes mellitus and urinary tract obstruction are the major risk factors for emphysematous urinary tract infections (UTIs). In different series, diabetes was present in more than 80 percent of

patients with emphysematous pyelonephritis.^{4,6} The diagnosis of a gas-forming UTI is usually made by plain films of the abdomen and/or computed tomography (CT). Such radiographs reveal air in the renal parenchyma, bladder, or surrounding tissue in 50 to 85 percent of cases. CT scanning is more sensitive than plain films and may show the extent of gas formation and any obstructing lesions in the urinary tract.^{4,5,7} *Escherichia coli* and *Klebsiella pneumoniae* are the predominant etiologic organisms.⁸ Treatment modalities include intravenous (IV) antibiotics, percutaneous drainage (PCD) and nephrectomy.

Case Report

A 64-year-old female was admitted to intensive care unit (ICU) via outpatient department (OPD) with complaint of

fever, abdominal pain, vomiting and burning micturition. Her fever was acute in onset, high grade, intermittent for last 2 days. Her abdominal pain was described as “achy,” 6/10, intermittent, and located in the right upper quadrant without radiation. She also had complaint of vomiting, 4 episodes in last 2 days, not containing blood and burning micturition along with mild dysuria. She was diagnosed Diabetes Mellitus (DM) 1 year back during a routine checkup and was started on oral hypoglycemics (OHGs). Her blood sugar control was not adequate so 6 months later, she was started on Humulin 70/30 (NPH 70%/Regular insulin 30%) with no regular follow ups. Apart from DM she had no other comorbid condition. She denied ever having any surgeries. She used regular insulin, omeprazole and diclofenac in past. Her family history was noncontributory, and she denied tobacco use. examination revealed a temperature of 100.6° F, respiratory rate of 16 breaths per minute, heart rate of 96 beats per minute, blood pressure of 110/60 mm Hg, oxygen saturation of 98% at room air, and no edema was appreciated. Her fasting capillary blood glucose was 385 mg/dL. She was oriented in time, person and place with a Glasgow coma scale (GCS) score of 15/15. Her pupils were equally reactive to light and accommodation. Rest of the neurological examination was unremarkable. The cardiac exam was normal with audible 1st and 2nd heart sound respiratory examination revealed bilateral breath sounds with reduced breath sounds and vocal resonance at right base, trachea was central. The abdomen was soft with moderate tenderness to palpation in the right hypochondrium and lumbar region. There was no guarding or rebound tenderness.

Laboratory tests revealed the following: white blood cell (WBC) count, 9,100/mm³ with 85% Neutrophils; Hemoglobin, 13.1 g/dL; Platelet count, 61,000/mm³; Urea, 161 mg/dL; Serum Creatinine, 3.3 mg/dL; Sodium, 130 mmol/L; Potassium, 3.8 mmol/L; Alanine transaminase, 10 IU/L; Prothrombin time, 15.4/10.6 seconds (INR 1.4); activated partial thromboplastin time, 37.2/29 seconds; Serum Calcium, 9 mg/dL; Serum Phosphorus, 2.8 mg/dL; Serum Bicarbonate, 15.7 mmol/L; Anti-HCV antibodies was Positive. The urinalysis revealed Protein 1+, red blood cells 10/HPF, and WBC numerous/HPF. Urine Culture/ Sensitivity (C/S) was negative for any growth. Ultrasound abdomen revealed enlarged hydronephrotic

right kidney with few calculi at lower pole and few air loculi. Irregular liver margins, right sided pleural effusion and mild ascites. Non-contrast computed tomography (CT) scan of the abdomen was ordered. The CT scan revealed significant air in the bladder wall, consistent with Emphysematous Cystitis along with air in the right renal parenchyma extending to perinephric area consistent with Emphysematous Pyelonephritis. There were few calculi found at the lower pole as well. A diagnosis of Emphysematous Cystitis along with Class 3A Emphysematous Pyelonephritis was made.

She was managed with intravenous (I/V) antibiotics including Piperacillin/Tazobactam 2.25 gm 8 hourly initially, dose adjusted according to estimated GFR and later as the renal functions improved, full 4.5 gm 8 hourly dose was administered, moxifloxacin 400 mg once a day and metronidazole 500 mg 8 hourly. I/V normal saline was started. Insulin regular was given according to sliding scale. Ranitidine was given for ulcer prophylaxis and tramadol was given for pain. After CT report, urology consult was taken and unanimous decision of right nephrectomy was made. Patient underwent nephrectomy under general anesthesia via right lumbar incision. 500 ml of puss was drained before nephrectomy. Puss C/S showed growth of Escherichia coli which was sensitive to Piperacillin/Tazobactam. Patient was again started on I/V antibiotics with a plan to discharge patient on oral antibiotics.

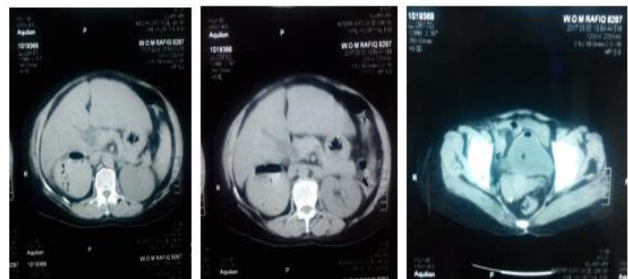


Figure 1: (a) Computed tomography (CT) image showing air level extending to right perinephric area. (b) showing air level involving right renal parenchyma. (c) CT image showing hydroaeric level and pneumobladder at the level of bladder wall.

Discussion

Emphysematous pyelonephritis (EPN) was first described in 1898, in association with pneumaturia as a result of gas forming pathogens.⁹ These bacteria ferment sugars within

the urine producing gases including nitrogen, hydrogen, carbon dioxide, and oxygen.¹⁰ EPN occurs nearly exclusively (90%) in people with diabetes.¹¹ The factors that predispose to EPN in people with diabetes may include uncontrolled diabetes, high levels of glycosylated hemoglobin, and impaired host immune mechanisms caused by local factors such as renal tract obstruction (tumours or lithiasis).¹² Renal USS can confirm the presence of EPN in approximately 80% of cases¹³, whereas CT is 100% sensitive.¹⁴ Based upon the findings seen on CT scan, two classification systems have been proposed to estimate prognosis and guide therapy. One classification system divided emphysematous pyelonephritis into two types:¹⁵

- Type I — Renal parenchymal necrosis with either absence of fluid collection or the presence of a streaky or mottled gas pattern
- Type II — Renal or perirenal fluid accompanied by a bubbly gas pattern or gas in the collecting system

Emphysematous pyelonephritis or pyelitis may be alternatively categorized into four prognostic classes based upon CT scan findings:¹¹

- Class 1: Gas in the collecting system only (ie, emphysematous pyelitis); this finding may be associated with severe obstruction at the site of the pyelitis in some patients
- Class 2: Gas in the renal parenchyma without extension to the extrarenal space
- Class 3A: Extension of gas or abscess to the perinephric space (defined as the area between the fibrous renal capsule and the renal fascia)
- Class 3B: Extension of gas or abscess to the pararenal space (defined as the space beyond the renal fascia and/or extension to adjacent tissues such as the psoas muscle)
- Class 4: Bilateral emphysematous pyelonephritis or a solitary functioning kidney with emphysematous pyelonephritis.

Treatment of these patients has always been tough and controversial as limited data has been published. Patients with class 1 disease (pyelitis) who do not have abscess formation or obstruction can be treated with antibiotics alone.¹⁶ Other patients with class 1 disease and patients with class 2 disease should be treated with antibiotics plus percutaneous catheter drainage (PCD) and, if

present, relief of urinary tract obstruction.¹⁷ Patients with class 3A or 3B disease at low risk (defined as none or one of the following risk factors: thrombocytopenia, acute renal failure, impaired consciousness, or shock) can initially be treated with antibiotics plus PCD and, if present, relief of urinary tract obstruction. However, given the lack of confirmatory evidence beyond the one study¹¹, some urologists feel that early nephrectomy is warranted in all patients with class 3 disease. Patients with class 3A or 3B disease with two or more of the above risk factors should be treated with antibiotics plus immediate nephrectomy. Patients with class 4 disease (bilateral involvement or infection is a solitary functioning kidney) should initially be treated with antibiotics plus bilateral percutaneous catheter drainage and, if present, relief of urinary tract obstruction. Nephrectomy is a last option.

Emphysematous cystitis is a lower urinary tract infection characterized by air within the bladder wall and lumen, usually occurring in elderly diabetic females, immunocompromised patients.¹⁸ Multiple gas-forming microorganisms can cause emphysematous cystitis. It was reported that various bacterial and fungal organisms were isolated in urine culture with *Escherichia coli* being the most prevalent, followed by *Klebsiella pneumoniae*.^{18,19} The treatment generally consists of antibiotics, bladder drainage, and glycemic control with correction of any underlying comorbid disorders. Broad-spectrum antibiotics are used initially. The precise regimen is then tapered to the sensitivities of the urinary pathogens.¹⁸ When treated with antibiotics alone, EPN is associated with a high mortality rate (40%).²⁰ Mortality rates were 15–20% in two case series in which nephrectomy was the treatment of choice.²¹ In case of Emphysematous cystitis, the overall mortality rate was 7%, which increased to 14% in patients who presented with combined emphysematous cystitis and pyelonephritis.²²

Conclusion

Female diabetic patients more than 60 years of age presenting with urinary symptoms, abdominal pain, fever and evidence of UTI on urine routine examination should have at-least an ultrasound abdomen and kidney ureter bladder (KUB) done and if presence of air is suspected, these patients should get CT scan KUB so that diagnosis of emphysematous UTI can be made early as the

treatment depends upon proper diagnosis. Nephrectomy in Class 3A EPN along with emphysematous cystitis is the treatment of choice.

References

1. Ronald A, Ludwig E. Urinary tract infections in adults with diabetes. *International Journal of Antimicrobial Agents*. 2001; 17(4):287-92.
2. Geerlings SE, Stolk RP, Camps MJ, Netten PM, Collet TJ, Hoepelman AI, Diabetes Women Asymptomatic Bacteriuria Utrecht Study Group. Risk factors for symptomatic urinary tract infection in women with diabetes. *Diabetes Care*. 2000; 23(12):1737-41.
3. Boyko EJ, Fihn SD, Scholes D, Chen CL, Normand EH, Yarbro P. Diabetes and the risk of acute urinary tract infection among postmenopausal women. *Diabetes care*. 2002; 25(10):1778-83.
4. Huang JJ, Tseng CC. Emphysematous pyelonephritis: clinicroadiological classification, management, prognosis, and pathogenesis. *Archives of Internal Medicine*. 2000; 160(6):797-805.
5. Grupper M, Kravtsov A, Potasman I. Emphysematous cystitis: illustrative case report and review of the literature. *Medicine*. 2007; 86(1):47-53.
6. Pontin AR, Barnes RD, Joffe J, Kahn D. Emphysematous pyelonephritis in diabetic patients. *Br J Urol* 1995; 75(1):71-74.
7. Chen MT, Huang CN, Chou YH, Huang CH, Chiang CP, Liu GC. Percutaneous drainage in the treatment of emphysematous pyelonephritis: 10-year experience. *J Urol*. 1997;157(5):1569.
8. Bos D., Patal P., DiTullio S. Emphysematous cystitis: an atypical multi-organism presentation. *Journal of the Canadian Urological Association*. 2014; 8(3-4): E210-E212.
9. Kelly HA, MacCallum WG. Pneumaturia. *JAMA*. 1898;31(8):375-81.
10. Huang JJ, Chen KW, Ruaan MK. Mixed acid fermentation of glucose as a mechanism of emphysematous urinary tract infection. *J Urol*. 1991;146(1):148-51.
11. Huang JJ, Tseng CC. Emphysematous pyelonephritis: Clinicroadiological classification, management, prognosis and pathogenesis. *Arch Intern Med*. 2000; 160(6):797-805.
12. Vollans SR, Sehjal R, Forster JA, Rogawski K. Emphysematous pyelonephritis in type II diabetes: A case report of an undiagnosed ureteric colic. *Cases J.* 2008; 1(1): 192.
13. Tang HJ, Li CM, Yen MY, Chen YS, Wann SR, Lin HH, et al. Clinical characteristic of emphysematous pyelonephritis. *J Microbiol Immunol Infect*. 2001;34(2):125-30.
14. Ahlering TC, Boyd SD, Hamilton CL, Bragin SD, Chandrasoma PT, Lieskovsky G, et al. Emphysematous pyelonephritis: a five year experience with 13 patients. *J Urol*. 1985;134(6):1086-1088.
15. Wan YL, Lee TY, Bullard MJ, Tsai CC. Acute gas-producing bacterial renal infection: correlation between imaging findings and clinical outcome. *Radiology* 1996; 198(2):433.
16. Roy C, Pfeleger DD, Tuchmann CM, Lang HH, Saussine CC, Jacqmin D. Emphysematous pyelitis: findings in five patients. *Radiology* 2001; 218(3):647.
17. Aswathaman K, Gopalakrishnan G, Gnanaraj L, Chacko NK, Kekre NS, Devasia A. Emphysematous pyelonephritis: outcome of conservative management. *Urology* 2008; 71(6):1007-1009
18. Thomas AA, Lane BR, Thomas AZ, Remer EM, Campbell SC, Shoskes DA. Emphysematous cystitis: a review of 135 cases. *British Journal of Urology*. 2007;100(1):17-20.
19. Grupper M, Kravtsov A, Potasman I. Emphysematous cystitis: illustrative case report and review of the literature. *Medicine*. 2007;86(1):47-53.
20. Wan YL, Lo SK, Bullard MJ, Chang PL, Lee TY. Predictors of outcome in emphysematous pyelonephritis. *J Urol*. 1998;159(2):369-73.
21. Shokeir AA, El-Azab M, Mohsen T, El-Diasty T. Emphysematous pyelonephritis: a 15-year experience with 20 cases. *Urology*. 1997;49(3):343-6.
22. Yoshino T, Ohara S, Moriyama H. Emphysematous Cystitis Occurred in the Case Treated with Steroid for Autoimmune Hepatitis. *Case Rep Urol*. 2013; 2013: 821780.