

Primary Adenosquamous Carcinoma of Prostate: A Rare Aggressive Tumor

Aribah Atiq¹, Noreen Akhtar², Usman Hassan³, Asif Loya⁴, Sajid Mushtaq⁵, Muhammad Azam⁶
Shaukat Khanum Memorial Cancer Hospital and Research Centre, Lahore, Pakistan

ABSTRACT

Adenosquamous carcinoma is an aggressive tumor of prostate with only 30 cases reported so far in literature. We present a case of this rare entity that was seen in our department. A 70 years old male presented with urinary outflow obstruction and slightly raised PSA levels [5mg/ml (normal; 0-4 mg/ml)]. Transurethral resection of prostate was done and specimen was sent to our department. Histologically, it composed of both malignant squamous and glandular components. Squamous component showed large tumor cells with abundant cytoplasm and nuclei with prominent nucleoli. Glandular component showed tumor cells arranged in acinar pattern, predominantly in cribriform architecture. As the current guidelines, Gleason grading is not required for adenosquamous carcinoma of prostate. The case was reported as the adenosquamous carcinoma of prostate. This rare tumor has an extremely poor prognosis with most of the patients dying within 1 year of diagnosis.

Key Words: Adenosquamous Carcinoma, Primary, Prostate

Address of Correspondence

Usman Hassan

Email: drusmanhassan256@gmail.com

Article info.

Received: August 24, 2017

Accepted: September 12, 2017

Cite this case Report: Atiq A, Akhtar N, Hassan U, Loya A, Mushtaq S, Azam M. Primary Adenosquamous Carcinoma of Prostate: A Rare Aggressive Tumor. 2017; 6(4)

Funding Source: Nil

Conflict of Interest: Nil

Introduction

Adenosquamous carcinoma of prostate is a rare, aggressive and unusual histological variant of prostatic carcinoma. Its first description was given by Thompson in 1942 and so far, less than 30 cases have been reported.¹ Although majority (two third) of the reported cases arise following hormonal or radiation therapy, approximately one third of cases arise spontaneously in patients without having any previous risk factors.² Here we present a case of adenosquamous carcinoma arising in a de novo setting without any history of radiations or hormonal therapy, which makes it even rarer.

Case Report

A 70-year-old male patient presented with a history of urinary retention. On digital rectal examination, prostate was enlarged, non-tender and felt to be extending into the bladder, occluding the lumen, thus causing urinary

retention. Serum PSA level was 5mg/ml (normal; 0-4 mg/ml). The patient had no history of radiation or hormonal therapy. Transurethral resection of prostate was done and sent to the pathology department for histopathological examination. Histological sections revealed carcinoma composed of malignant squamous and glandular component. Squamous element was composed of large foci of squamous differentiation and glandular area was showing tumor cells arranged in acinar pattern. A transitional area comprising of both the components was also noted. We reported the case as the adenosquamous carcinoma of prostate (figure 1).

Discussion

Adenosquamous carcinoma of prostate is a rare entity with an incidence of 0.03 cases/million individuals/year, which makes its prevalence even less than pure

squamous cell carcinoma of prostate, which is also a rare entity.³

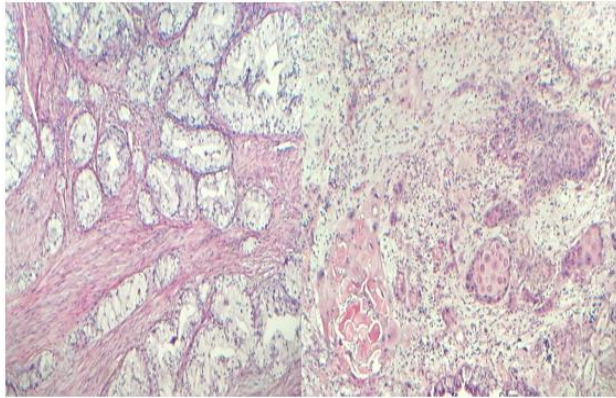


Figure1: Sections of the prostate showing malignant squamous component and acinar type adenocarcinoma.

Several explanations have been proposed so far to explain the histological features of adenosquamous carcinoma; these include the metaplastic transformation of adenocarcinomatous cells, transformation of squamous metaplastic foci ; developed after radiation/hormonal therapy or in long standing inflammation or ischemia⁴ or from the deviation of pluripotent stem cells, which are capable of multidirectional differentiation.⁴ So far, there is no well-established criteria for the diagnosis of adenosquamous carcinoma of prostate and to differentiate it microscopically from the adenocarcinoma with concomitant squamous metaplasia, because of the close resemblance of squamous metaplasia and well differentiated squamous cell carcinoma in prostate. However, squamous component in adenosquamous

carcinoma shows marked atypia pleomorphism. Regarding PSA level, there is no well-established criteria

showing association of PSA with adenosquamous carcinoma. Patients have presented with both, high and normal PSA levels. This tumor is associated with bad prognosis.⁵

Conclusion

Adenosquamous carcinoma of prostate is a rare, aggressive and unusual histological variant of prostatic carcinoma. It has an extremely poor prognosis with most of the patients dying within 1 year of diagnosis.

References

1. Thompson GJ. Transurethral resection of malignant lesions of prostate gland. JAMA 1942; 120(14):1105-9.
2. Wang J, Wang FW, LaGrange CA, et al. Clinical features and outcomes of 25 patients with primary ASC of the prostate. Rare Tumors 2010; 2(3):130-4.
3. Marcus DM, Goodman M, Jani AB, et al. A comprehensive review of incidence and survival in patients with rare histological variants of prostate cancer in the United States from 1973 to 2008. Prostate Cancer Prostatic Dis 2012; 15(3):283
4. Nicoleta C Arva and Kasturi Das.Diagnostic dilemmas of squamous differentiation in prostate carcinoma case report and review of the literature.Arva and Das diagnostic pathology 2011,6(1):46.
5. Mishra S, Goel H, Awasthi N, Puri A, Mahapatra R, D.K.PAL.Primary adenosquamous carcinoma of prostate;a rare aggressive tumor.Clinical genitourinary cancer. 2014; 12(1);e29-31.