



# A Case of Artificial Snow Foam induced Corneal Endotheliitis Followed up by Scheimpflug Densitometry

Amr MOUNIR <sup>1</sup>; Omar Fawzy ZIDAN <sup>2</sup>; Islam AWNY <sup>1</sup>; Engy Mohamed MOSTAFA <sup>1</sup>

<sup>1</sup> Department of Ophthalmology, Sohag Faculty of Medicine, Sohag University, Sohag, Egypt

<sup>2</sup> Sohag Ophthalmology Hospital, Sohag, Egypt

## ABSTRACT

The aim was to present a rare case of artificial snow foam induced corneal endotheliitis followed up by Scheimpflug Densitometry. A 15-year-old male complained of redness, tearing and reduced vision in the left eye after artificial snow foam entered his left eye 4 days before the presentation. Slit lamp examination of the same eye showed ciliary injection with corneal edema with no epithelial defect and endothelial lesion measuring 3 × 4 millimeters (mm) with large keratic precipitates (KP). Examining the left eye by the Scheimpflug densitometry of the Sirius device (CSO, Florence, Italy) showed plaque on the back of the cornea. Aqueous tap Polymerase chain reaction analysis (PCR) results for the affected eye had negative results for viral infection. Improvement of ocular symptoms occurred after treatment with topical steroid therapy. Scheimpflug densitometry showed disappearance of the saw-tooth protrusions on the back of the cornea with decreased reflectivity. Corneal endotheliitis can be triggered by chemical ocular trauma. The Scheimpflug densitometry examination may be a useful noninvasive method for reaching a clinical diagnosis of corneal endotheliitis and monitoring treatment effectiveness.

## KEYWORDS

Cornea; Scheimpflug Densitometry; Snow Foam; Polymerase Chain Reaction; Corneal Endotheliitis

Copyright © 2019, Author(s). This is an open-access article distributed under the terms of the Creative Commons Attribution-Non Commercial 4.0 International License (<http://creativecommons.org/licenses/by-nc/4.0/>) which permits copy and redistribute the material just in noncommercial usages, provided the original work is properly cited.

**Correspondence to:** Amr Mounir, MD, Sohag Faculty of Medicine, Ophthalmology Department, Sohag, Egypt. E-mail: [dramrmonir@yahoo.com](mailto:dramrmonir@yahoo.com)

**How to cite this article:** Mounir A, Zidan OF, Awny I, Mostafa EM. A Case of Artificial Snow Foam induced Corneal Endotheliitis Followed up by Scheimpflug Densitometry. *Med Hypothesis Discov Innov Ophthalmol*. 2019 Summer; 8(2): 64-68.

## INTRODUCTION

Acute corneal edema could be due to a myriad of conditions such as angle closure glaucoma, post-intraocular surgery and trauma [1]. Chemical trauma is very common especially in children with increased risk of vision compromise [2]. Chemical injury derives its bad reputation from its speedy effect and high penetrance to intraocular tissues resulting in irreversible damage [3]. While in patients without former history of surgery, trauma or noxious agents, it is known to be initiated by

infectious agents especially viruses such as Cytomegalovirus (CMV) [4], Varicella zoster [5] and Herpes simplex virus (HSV) [6]. Scheimpflug densitometry which is performed by corneal tomography by a rotating Scheimpflug camera is a simple and effective diagnostic procedure for the anterior segment of the eye especially the corneal media. This maneuver allows quantitative evaluation of the optical media as “densitometry” [7]. Many clinical studies revealed the importance of



densitometry as a new diagnostic method for evaluation of corneal opacification density in various clinical conditions [8-10]. The aim of this report was to present a rare case of artificial snow foam induced corneal endotheliitis diagnosed by Scheimpflug Densitometry.

#### CASE REPORT

A 15-year-old male presented to our outpatient clinic complaining of pain, redness, tearing and reduced vision in the left eye after artificial snow foam entered his left eye 4 days before (June 2018). The boy had a contact with this substance in a wedding ceremony.

Written informed consent was obtained from the patient to publish this case report. History taking did not reveal any medical history either systemic or ocular. His parents reported that at the time of exposure, they washed his eyes profusely with tap water for unspecified amount of time. He did not seek medical advice as he did not complain except for redness which was attributed to the snow spray. No PH measurement was available as the patient presented 4 days after presentation. On examination, the corrected distance visual acuity (CDVA)

in the right eye was 6/6 and in the affected eye was 6/24. Examination of the right eye by Slit lamp was unremarkable while the examination of the left eye showed ciliary injection with corneal edema with no epithelial defects. Yet there was a stellate shape endothelial lesion measuring 3 × 4 millimeters (mm) with large keratic precipitates (KP). The KPs were rounded, sharply margined and pigmented deposited at the center and inferior part of the cornea (Fig. 1 A). The anterior chamber showed mild cell and flare. Examination of the posterior segment of both eyes were within the normal limits. Intraocular pressure (IOP) was normal. Examining the left eye by the Scheimpflug densitometry of the Sirius device (CSO, Florence, Italy), a plaque on the back of the cornea was evident. There was a protruding mass at the posterior corneal surface with a saw-tooth appearance and the density of the structure images was high. The reflectivity of the posterior corneal surface including the endothelium was high (Fig. 2A). Corneal thickness was 691 micrometers.

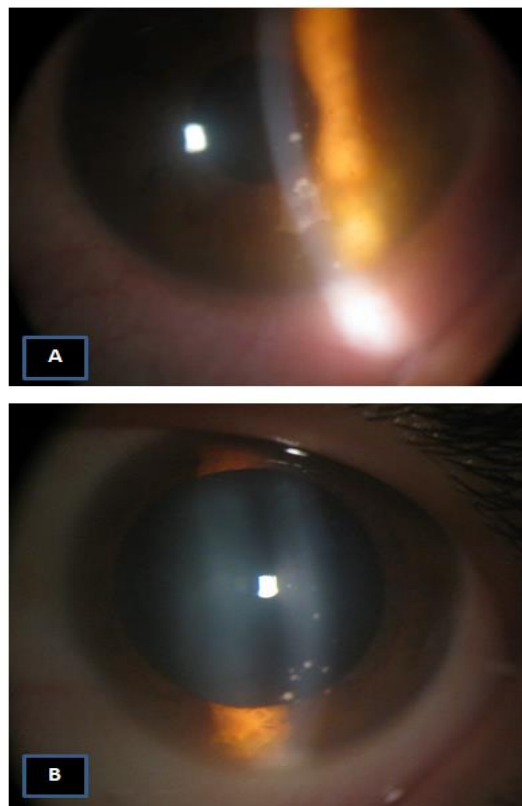
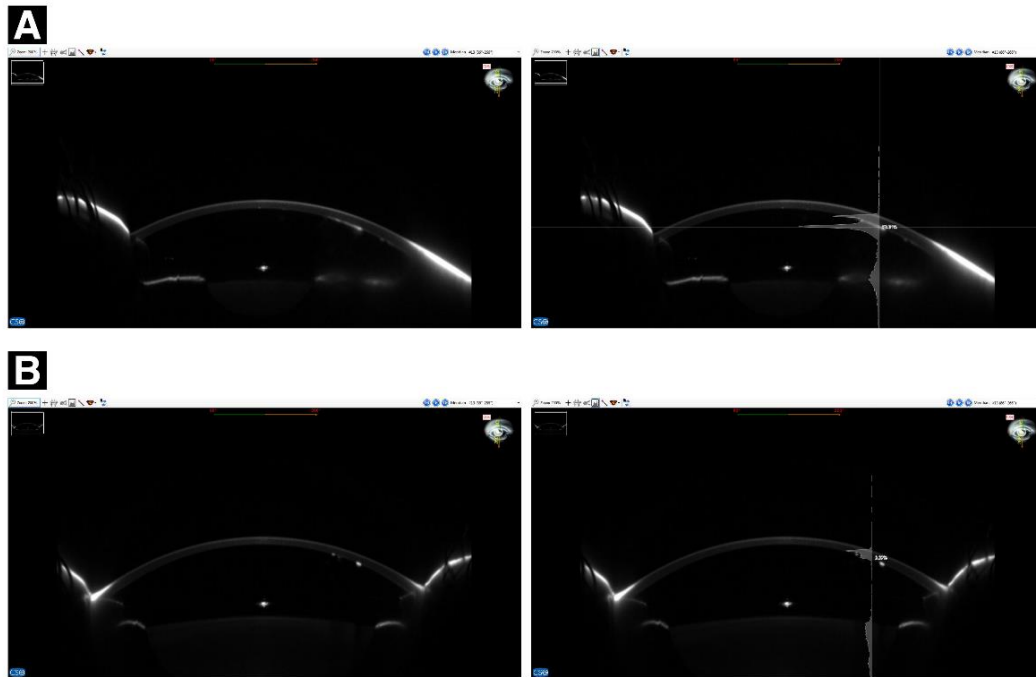


Figure 1: A) Stellate shape endothelial lesion measuring 3 × 4 mm with large keratic precipitates (KPs). B) Endothelial plaque disappeared, but fine KPs still remained.



**Figure 2:** A) Scheimpflug densitometry showing plaque on the back of the cornea with high reflectivity. B) Scheimpflug densitometry showing disappearance of the saw-tooth protrusions on the back of the cornea with decreased reflectivity. However, fine hyper-reflective dots still remained.

The patient was investigated for underlying immunosuppressive causes and was found to have normal routine investigations and negative results for human immunodeficiency virus (HIV) and the Venereal Disease Research Laboratory test (VDRL). An anterior chamber paracentesis was performed for aqueous tap for the left eye and was sent for Polymerase chain reaction analysis (PCR) of Varicella zoster virus, HSV, and CMV, which had negative results for all the three viruses. Our approach was to start with prednisolone acetate 1% (Predforte. Alcon) every two hours with cyclopentolate eyedrops (cyclopherin) 3 times daily, moxifloxacin hydrochloride ophthalmic solution 0.5% drops 4 times a day and tobramycin- prednisolone eye ointment at nights.

Within 3 days, the patient presented with rapid relieve of signs with a quiet eye. The endothelial plaque and KPs decreased in size and number. The corneal edema decreased as well (Fig. 1B). Visual acuity improved to 6/12. A week later, the eye was free of inflammation with only a few KPs present. Follow up of densitometry scans showed decrease of hyper-reflectivity of the posterior surface of the cornea and disappearance of the

saw-tooth protrusions (Fig. 2 B) and the corneal thickness was below 530 micrometers. The treatment was tapered over a month with no report of recurrence. An informed consent was acquired from the patient's parents and the ethical committee of the Sohag refractive center was acquired to report the case.

## DISCUSSION

Ocular chemical injury is common and can cause variable ocular damage based on the nature and type of chemical substance [3]. Fake snow that was the reason of injury in this patient is composed of sodium polyacrylate granules which are converted to snow-like semi-sticky matter when exposed to water causing damage to the corneal epithelium due to its acidic nature [11]. Our patient did not experience any epithelial defect or erosions which made the diagnosis of chemical keratouveitis not the first on our list. Negative aqueous tap excluded viral endotheliitis as well. Also, this led us to consider other causes of unilateral acute corneal edema without epithelial compromise such as affection of endothelial dysfunction or elevation in IOP [12]. Posterior corneal dystrophies or iridocorneal syndrome were not in the



differential diagnosis due to their chronicity [13, 14]. However, we could not exclude the liability that this chemical accident might trigger any pathology. Aqueous tap result had negative result which guided us that the cause of corneal endotheliitis was autoimmune in nature or due to chemical keratouveitis.

In the United States, herpetic disciform keratitis is considered as endotheliitis due to the presence of KPs and edema [15, 16], while in Japan, herpetic disciform keratitis is considered as stromal keratitis which is a combination of stromal keratitis and endotheliitis [17]. Cytomegalovirus corneal endotheliitis is different from CMV retinitis in that it occurs in immunocompetent healthy patients. Cytomegalovirus corneal endotheliitis can be diagnosed by detection of CMV DNA using aqueous humor PCR along with positive response to anti-CMV drugs, such as ganciclovir and valganciclovir [17]. We did not use systemic antiviral therapy or topical ganciclovir due to the negative results of anterior chamber paracentesis which supported active nature of the keratouveitis. The mechanism of corneal endotheliitis is considered to be autoimmune due to its similarity with graft rejection and its good response to topical corticosteroid therapy. Abulafia et al. [18] reported 135 eyes with similar party foam contact, yet none developed similar condition. They only reported chemical conjunctivitis in 100% of eyes and superficial punctate keratopathy in 79% of eyes, corneal erosion in 27% of eyes and finally conjunctival erosion in 5% [18]. The Scheimpflug densitometry was used for diagnosis and follow-up of our case where changes in reflectivity of the posterior surface of the cornea were the guide for us in monitoring the progress of endotheliitis. The Scheimpflug images acquired were similar to images taken by anterior segment Optical coherence tomography (OCT) in studies by Kobayashi et al [19]. in cases of CMV endotheliitis. Many studies [20-23] used the Scheimpflug densitometry as a tool for corneal optical density but our case was the first one to use this relatively available procedure to evaluate corneal endothelial lesions.

## CONCLUSIONS

Corneal endotheliitis can be triggered by chemical ocular trauma. The Scheimpflug densitometry examination may be a useful noninvasive method for reaching a clinical diagnosis of corneal endotheliitis and monitoring treatment effectiveness.

## DISCLOSURE

Ethical issues have been completely observed by the authors. All named authors meet the International

Committee of Medical Journal Editors (ICMJE) criteria for authorship of this manuscript, take responsibility for the integrity of the work as a whole, and have given final approval for the version to be published. No conflict of interest has been presented.

Funding/Support: None.

## ACKNOWLEDGMENT

We would like to extend our thanks to the Sohag Refractive and cornea center, Sohag City, Egypt for facilitating the follow-up of this case. We would like also to thank the technical team of this center for their help in this research.

## REFERENCES

1. Urrego-Díaz JA, Frías-Ordoñez JS, Figueroa-Echandía G, Durán-Silva G. Acute corneal edema without epithelium compromise. A case report and literature review. *Rev Fac Med.* 2017;65(3):513-9. doi: [10.15446/revfacmed.v65n3.56637](https://doi.org/10.15446/revfacmed.v65n3.56637)
2. Koizumi N, Suzuki T, Uno T, Chihara H, Shiraiishi A, Hara Y, et al. Cytomegalovirus as an etiologic factor in corneal endotheliitis. *Ophthalmology.* 2008;115(2):292-7 e3. doi: [10.1016/j.ophtha.2007.04.053](https://doi.org/10.1016/j.ophtha.2007.04.053) pmid: 17669498
3. Eslani M, Baradaran-Rafii A, Movahedan A, Djalilian AR. The ocular surface chemical burns. *J Ophthalmol.* 2014;2014:196827. doi: [10.1155/2014/196827](https://doi.org/10.1155/2014/196827) pmid: 25105018
4. Fish R, Davidson RS. Management of ocular thermal and chemical injuries, including amniotic membrane therapy. *Curr Opin Ophthalmol.* 2010;21(4):317-21. doi: [10.1097/ICU.0b013e32833a8da2](https://doi.org/10.1097/ICU.0b013e32833a8da2) pmid: 20467317
5. Madhavan HN, Goldsmith CS, Rao SK, Fogla R, Malathi J, Priya K. Isolation of a vesicular virus belonging to the family rhabdoviridae from the aqueous humor of a patient with bilateral corneal endotheliitis. *Cornea.* 2002;21(3):333-5. pmid: 11917189
6. Wilhelmus KR, Sugar J, Hyndiuk RA, Stulting RD. Corneal thickness changes during herpes simplex virus disciform keratitis. *Cornea.* 2004;23(2):154-7. pmid: 15075884
7. Ishikawa S, Kato N, Takeuchi M. Quantitative evaluation of corneal epithelial edema after cataract surgery using corneal densitometry: a prospective study. *BMC Ophthalmol.* 2018;18(1):334. doi: [10.1186/s12886-018-0998-5](https://doi.org/10.1186/s12886-018-0998-5) pmid: 30572855
8. Elflein HM, Hofherr T, Berisha-Ramadani F, Weyer V, Lampe C, Beck M, et al. Measuring corneal clouding in patients suffering from mucopolysaccharidosis with the Pentacam densitometry programme. *Br J Ophthalmol.* 2013;97(7):829-33. doi: [10.1136/bjophthalmol-2012-302913](https://doi.org/10.1136/bjophthalmol-2012-302913) pmid: 23685998
9. Greenstein SA, Fry KL, Bhatt J, Hersh PS. Natural history of corneal haze after collagen crosslinking for keratoconus and corneal ectasia: Scheimpflug and biomicroscopic analysis. *J Cataract Refract Surg.* 2010;36(12):2105-14. doi: [10.1016/j.jcrs.2010.06.067](https://doi.org/10.1016/j.jcrs.2010.06.067) pmid: 21111314
10. Takacs AI, Mihaltz K, Nagy ZZ. Corneal density with the Pentacam after photorefractive keratectomy. *J Refract Surg.* 2011;27(4):269-77. doi: [10.3928/1081597X-20100618-02](https://doi.org/10.3928/1081597X-20100618-02) pmid: 20672772
11. Al-Amry MA, Al-Ghadeer HA. Corneal Epitheliopathy After Trauma by Fake Snow Powder in a 7-year-old Child. *Middle East*



- Afr J Ophthalmol. 2016;23(3):274-6. doi: [10.4103/0974-9233.186157](https://doi.org/10.4103/0974-9233.186157) pmid: 27555717
12. Levenson JE. Corneal edema: cause and treatment. *Surv Ophthalmol.* 1975;20(3):190-204. doi: [10.1016/0039-6257\(75\)90002-8](https://doi.org/10.1016/0039-6257(75)90002-8) pmid: 1105846
  13. Laganowski HC, Sherrard ES, Muir MG, Buckley RJ. Distinguishing features of the iridocorneal endothelial syndrome and posterior polymorphous dystrophy: value of endothelial specular microscopy. *Br J Ophthalmol.* 1991;75(4):212-6. doi: [10.1136/bjo.75.4.212](https://doi.org/10.1136/bjo.75.4.212) pmid: 2021586
  14. Hamill CE, Schmedt T, Jurkunas U. Fuchs endothelial cornea dystrophy: a review of the genetics behind disease development. *Semin Ophthalmol.* 2013;28(5-6):281-6. doi: [10.3109/08820538.2013.825283](https://doi.org/10.3109/08820538.2013.825283) pmid: 24138036
  15. Liesegang TJ. Classification of herpes simplex virus keratitis and anterior uveitis. *Cornea.* 1999;18(2):127-43. pmid: 10090358
  16. Holland EJ, Schwartz GS. Classification of herpes simplex virus keratitis. *Cornea.* 1999;18(2):144-54. doi: [10.1097/00003226-199903000-00002](https://doi.org/10.1097/00003226-199903000-00002) pmid: 10090359
  17. Inoue Y. Review of clinical and basic approaches to corneal endotheliitis. *Cornea.* 2014;33 Suppl 11:S3-8. doi: [10.1097/ICO.0000000000000228](https://doi.org/10.1097/ICO.0000000000000228) pmid: 25170583
  18. Abulafia A, Segev F, Platner E, Ben Simon GJ. Party foam-induced eye injuries and the power of media intervention. *Cornea.* 2013;32(6):826-9. doi: [10.1097/ICO.0b013e31826cf315](https://doi.org/10.1097/ICO.0b013e31826cf315) pmid: 23132449
  19. Kobayashi R, Hashida N, Soma T, Koh S, Miki A, Usui S, et al. Clinical Findings of Anterior Segment Spectral Domain Optical Coherence Tomography Images in Cytomegalovirus Corneal Endotheliitis. *Cornea.* 2017;36(4):411-4. doi: [10.1097/ICO.0000000000001103](https://doi.org/10.1097/ICO.0000000000001103) pmid: 27941387
  20. Cennamo G, Forte R, Aufiero B, La Rana A. Computerized Scheimpflug densitometry as a measure of corneal optical density after excimer laser refractive surgery in myopic eyes. *J Cataract Refract Surg.* 2011;37(8):1502-6. doi: [10.1016/j.jcrs.2011.03.037](https://doi.org/10.1016/j.jcrs.2011.03.037) pmid: 21782093
  21. Ambrosio R, Jr., Valbon BF, Faria-Correia F, Ramos I, Luz A. Scheimpflug imaging for laser refractive surgery. *Curr Opin Ophthalmol.* 2013;24(4):310-20. doi: [10.1097/ICU.0b013e3283622a94](https://doi.org/10.1097/ICU.0b013e3283622a94) pmid: 23680761
  22. Savini G, Barboni P, Carbonelli M, Hoffer KJ. Accuracy of corneal power measurements by a new Scheimpflug camera combined with Placido-disk corneal topography for intraocular lens power calculation in unoperated eyes. *J Cataract Refract Surg.* 2012;38(5):787-92. doi: [10.1016/j.jcrs.2011.11.037](https://doi.org/10.1016/j.jcrs.2011.11.037) pmid: 22386277
  23. Peyman A, Pourazizi M. Scheimpflug-based Optical Densitometry for Assessment of Corneal Opacity: An Objective Method to Monitor Interstitial Keratitis. *J Ophthalmic Vis Res.* 2018;13(2):207-9. doi: [10.4103/jovr.jovr\\_96\\_17](https://doi.org/10.4103/jovr.jovr_96_17) pmid: 29719653