



Short-Term Results of Sutureless Scleral Tunnel Trabeculectomy Using Adjunctive Topical Bevacizumab

Mohammad ARISH¹, Omid BAGHERZADEH^{1*}, Seyed Sajad AHMADI¹, Javad SADEGHI-ALLAHABADI¹, Samira HASSANZADEH¹

¹ Department of Ophthalmology Al-Zahra Eye Hospital, Zahedan University of Medical Sciences, Zahedan, Iran

ABSTRACT

This study was performed to assess the short-term effect of sutureless scleral tunnel trabeculectomy procedure with and without topical bevacizumab. Thirty patients with Primary Open-Angle Glaucoma (POAG) were enrolled and randomly divided to two groups. Patients in the first group (15 patients) underwent sutureless trabeculectomy without topical bevacizumab and patients in the second group (15 patients) underwent sutureless trabeculectomy with 1.25 mg of topical bevacizumab. Intraocular Pressure (IOP) of both groups was measured by an expert ophthalmologist, without awareness of the patient's study group before the operation and six months post-operatively. Out of 30 patients in this study, six females (40%) and nine males (60%) underwent the sutureless trabeculectomy procedure (group A) as well as seven females (46.7%) and eight males (53.3%) underwent sutureless trabeculectomy with topical bevacizumab (group B). The mean age of the patients was not significantly different between the two groups ($P = 0.91$). A statistically significant difference in time variation of IOP was found between the two groups ($P < 0.001$). Mean IOP was 18.4 ± 4.35 mmHg in the sutureless group without bevacizumab and 11.73 ± 2.12 mmHg in the sutureless group with bevacizumab, six months post-surgically. No statistical significant differences were found in the baseline IOP between the two groups ($P = 0.28$). However, IOP changed significantly in group A and B from baseline to six months post-operatively ($P = 0.004$ and $P < 0.001$ respectively). According to the current findings, the sutureless trabeculectomy procedure is an effective surgical method for reduction of IOP. Addition of a single dose of 1.25 mg topical bevacizumab was more effective in reduction of IOP compared to sutureless trabeculectomy alone.

KEY WORDS

Bevacizumab; Glaucoma; Sutureless Scleral Tunnel Trabeculectomy

©2018, Med Hypothesis Discov Innov Ophthalmol.

This is an open-access article distributed under the terms of the Creative Commons Attribution Non-Commercial 3.0 License (CC BY-NC 3.0), which allows users to read, copy, distribute and make derivative works for non-commercial purposes from the material, as long as the author of the original work is cited properly.

Correspondence to:

Omid Bagherzadeh MD, Department of Ophthalmology Al-Zahra Eye Hospital, Zahedan University of Medical Sciences, Zahedan, Iran. E-mail: omidbagherzade@yahoo.com

How to cite this article: Arish M, Bagherzadeh O, Ahmadi SS, Sadeghi-Allahabadi J, Hassanzadeh S. Short-Term Results of Sutureless Scleral Tunnel Trabeculectomy Using Adjunctive Topical Bevacizumab. *Med Hypothesis Discov Innov Ophthalmol.* 2018 Summer; 7(2): 63-67.

INTRODUCTION

Trabeculectomy is the most important part of surgical management in Primary Open Angle Glaucoma (POAG) for the achievement of long term results [1-3]. In this

filtering surgical technique, an ostium is created in the anterior chamber from underneath the partial thickness of the scleral flap, to help the aqueous outflow. When



the aqueous flows into the subconjunctival space, it usually leads to an elevation of the conjunctiva, referred to as a filtering bleb and this procedure can control Intra Ocular Pressure (IOP) [4]. Sutureless scleral tunnel trabeculectomy is an efficient surgical technique for reduction of IOP in patients with open angle glaucoma [5-7]. Antimetabolites are usually used during trabeculectomy surgery to prevent bleb failure due to scarring by the wound healing process. The most commonly used antimetabolites are 5-fluorouracil (5-FU) or Mitomycin C (MMC) [8-13], which can be applied and placed on the scleral surgical site before or after creation of a scleral flap and prior to creation of the ostomy. In the recent years, studies have reported greater efficiency and improvement of trabeculectomy outcomes, by using anti-angiogenesis factors, such as bevacizumab and ranibizumab [14, 15]. Due to controversies, which exist in the field of bleb formation and IOP reduction by bevacizumab application at the time of trabeculectomy, this study was performed to assess short-term results of sutureless scleral tunnel trabeculectomy procedure, using adjunctive topical bevacizumab, in comparison with sutureless scleral tunnel trabeculectomy without topical bevacizumab.

MATERIALS and METHODS

This study was conducted at AL Zahra Eye Hospital glaucoma department, a university-based hospital in Zahedan, Iran, between November 2015 and August 2016. The study adhered to the declaration of Helsinki and was approved by the Ethics Committee of Ophthalmic Research Center affiliated to Zahedan University of Medical Sciences, Zahedan, Iran. Thirty phakic patients with POAG (13 females and 17 males) were selected for sutureless trabeculectomy and were randomly assigned to two groups using the random numbers table. The first group (A: 15 patients) received standard sutureless trabeculectomy, and the second group (B: 15 patients) received a standard sutureless trabeculectomy with topical bevacizumab. Inclusion criteria were having POAG and an IOP of > 21 mmHg, despite maximum tolerated medication and poor compliance. Exclusion criteria were: having history of ocular surgery, congenital glaucoma, ocular inflammation, angle closure glaucoma, secondary open angle glaucoma, and soft tissue disease (Marfan syndrome, collagen vascular diseases, etc.). Prior to the surgical procedure, all patients signed an informed consent and underwent detailed slit-lamp microscopy, gonioscopy, and dilated fundus examination. The IOP was measured by Goldman Applanation Tonometer (GAT) before the surgery by an expert ophthalmologist,

without awareness of the patient's study group. Also, all subjects were blind to the study conditions. Sutureless trabeculectomy was performed by one surgeon in both study groups. On the first postoperative day, all eyes were prescribed topical antibiotic (ciprofloxacin) and corticosteroid (betamethasone), three times daily for two weeks and the corticosteroid (betamethasone) was tapered over the following two months. All patients were fully evaluated at one and six months after the surgery and IOP was measured by GAT, six months after the surgery by an expert ophthalmologist, without awareness of the patient's study group. Normal distribution of data was determined by the Kolmogorov Smirnov test. Independent t-test was used for evaluation of IOP between groups. Paired t-test was used for pre- and post-operative IOP changes in each group. For all tests, $P < 0.05$ was considered as statistically significant.

Surgical Technique

Sutureless trabeculectomy was performed under general anesthesia. After primary preparations, in superior limbus, the conjunctiva was opened in a fornix-based manner. The Tenon capsule was shaved and a bipolar cautery homeostasis was achieved. A tangential scleral tunnel was created 3 mm posterior to the superior limbus (width: 3 mm horizontally and depth: approximately one-third of the scleral thickness), using a crescent knife. This tunnel was progressed for 0.5 mm into the clear cornea, and anterior chamber was accessed using a 2.2-mm keratome.

The anterior chamber was filled with methyl cellulose. The Kelly Descemet membrane punch (1.0 mm diameter head with 0.5 mm deep bite) was used to remove two punches of trabecular meshwork. After peripheral iridectomy, the methylcellulose was washed through the scleral tunnel incision, using an irrigation cannula and the anterior chamber was formed, using a balanced salt solution. Furthermore, 1.25 mg of topical bevacizumab (Roche Company, Basel, Switzerland) was placed on the scleral incision with a surgical sponge for one minute. The conjunctival flap was sutured with an 8-0 polyglactin suture (Vicryl; Ethicon Inc.). Subconjunctival betamethasone and cefazolin were injected and eyes were patched until the next day. Fig 1 shows a patient's eye with avascular and elevated bleb after six months of sutureless trabeculectomy with topical bevacizumab attached.

RESULTS

Out of 30 patients participating in this study, six females (40%) and nine males (60%) underwent sutureless trabeculectomy (group A) as well as seven females



(46.7%) and eight males (53.3%) underwent sutureless trabeculectomy with topical bevacizumab (group B). The mean and standard deviation of age in group A was 52.4 ± 16.11 years and in group B was 51.80 ± 12.45 years. There were no statistical significant differences regarding gender (P = 0.71), eye laterality (P = 46.7%), and age (P = 0.91) between the two groups. The IOP was checked at baseline and six months post surgically. The results showed a statistically significant change in IOP from the baseline to six months post-operatively (P = 0.004 and P < 0.001, respectively for group A and B) (Table 1).

Paired sample T-test showed an IOP reduction in both groups, six months post-operatively. The baseline IOP was not significantly different between the two groups (P = 0.28). Six months post-surgically, mean IOP was 18.4±4.35 mmHg in the sutureless group without bevacizumab and 11.73 ± 2.12 mmHg in the sutureless group with bevacizumab (Fig 2).

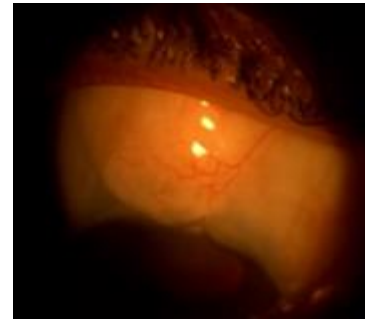


Figure 1: Photograph of the Patient's Eye with Avascular and Elevated Bleb Six Months after Sutureless Trabeculectomy with Topical Bevacizumab

The results showed that six months post- operatively, IOP was significantly lower in group B as compared to the other group (P < 0.001). Time variation of IOP was also significantly different between the two groups (P = 0.001).

Table 1: The Mean Intra-Ocular Pressure (IOP) with and without Topical Bevacizumab

	Group A Mean (SD)	Group B Mean (SD)	P (value)
Baseline IOP	25.33 (8.82) mmHg	28.66 (7.74) mmHg	0.28
IOP 6 months post- op	18.40 (4.35) mmHg	11.73 (2.12) mmHg	< 0.0001*
P- value	0.004*	< 0.0001*	

Group A (Sutureless Trabeculectomy without Topical Bevacizumab)

Group B (Sutureless Trabeculectomy with Topical Bevacizumab)

IOP: intraocular pressure, SD: Standard Deviation, mmHg: millimeters of mercury, * = P-Values less than 0.05.

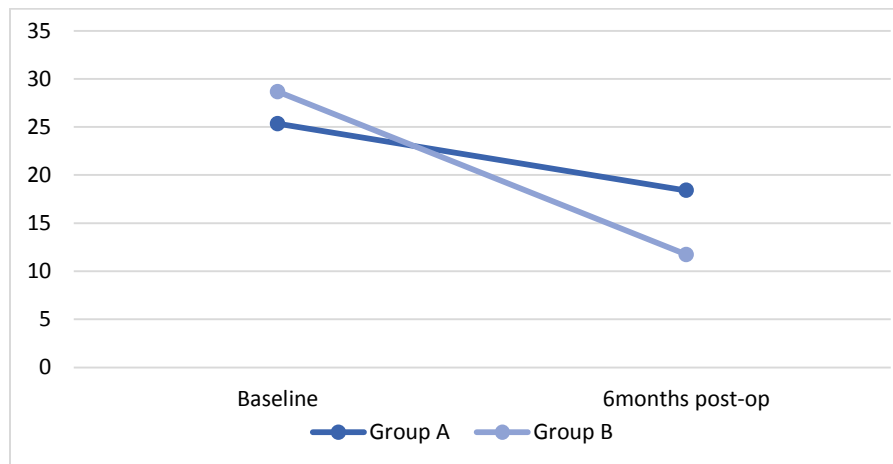


Figure 2: Comparison of Baseline Intra Ocular Pressure (IOP) Six Months post Operatively between the two Groups: Group A (sutureless trabeculectomy without Topical Bevacizumab) and Group B (Sutureless Trabeculectomy with Topical Bevacizumab).

DISCUSSION

This study evaluated the effect of sutureless scleral tunnel trabeculectomy in IOP reduction with and without topical bevacizumab. For this purpose, 15 patients

underwent sutureless trabeculectomy with 1.25 mg topical bevacizumab. According to the findings, topical bevacizumab was very effective in IOP reduction in patients with POAG. Also, overall success rate of surgery in these patients was higher than the other group. Use of



Vascular Endothelial Growth Factor (VEGF) or Vascular Permeability Factor (VPF) is a method to increase the speed of wound and scars healing. Furthermore, VEGF can speed up angiogenesis by increasing common inflammatory cells, such as fibroblasts and other cytokines and growth factors, prior to wound healing [16, 17]. Anti-VEGF drugs inhibit fibroblasts activity, which delays scar formation [18-21]. An animal trial showed that topical application of Bevacizumab on conjunctival tissue of rats has a direct effect on fibroblasts and inhibits expression of VEGF and Transforming Growth Factor beta (TGFb1, and TGFb2). These findings provide alternative mechanisms for Bevacizumab's clinical application [22]. In some studies, the effect of intracameral injection of an anti VEGF and placebo had been compared in humans [23, 24]. This study confirms the results of previous studies regarding the efficacy of adjunctive anti-VEGF in reduction of IOP [14, 15, 24, 25]. Choi et al. [15], in a case series study, used subconjunctival injection of 1.25 mg bevacizumab at completion of trabeculectomy. Similar to the results of the current study, six months post-operatively, all eyes showed functioning blebs and IOP reduction. Fakhraei et al. [24], in a similar study, found a 30% drop in IOP after subconjunctival injection of 1.25 mg bevacizumab compared with base line values in patients with POAG and pseudoexfoliation glaucoma, yet they stated that this could increase the risk of early bleb leakage. Klos-Rola et al. in 2013 assessed the effect of topical bevacizumab application on early bleb failure after trabeculectomy. Their results showed that in high risk eyes for bleb failure, post trabeculectomy, application of bevacizumab might favor functional bleb formation [25]. Kahook et al. investigated the effect of combination of intravitreal Ranibizumab and topical mitomycin c in bleb morphology and vascularity after trabeculectomy. Their results showed more diffuse blebs with less vascularity when using the combination of intravitreal Ranibizumab and topical mitomycin c at the time of trabeculectomy [26]. In the present study, topical Bevacizumab was chosen because of its lower complications and side effects [24].

On the other hand, there are reports in contrast to the current results that oppose the efficacy of adjunctive anti-VEGF [23]. Sadeghipour et al. used subconjunctival injection of 0.2 mg bevacizumab with augment trabeculectomy, on patients with POAG, and found no significant IOP reduction after six months. They concluded that the effect of bevacizumab injection on trend of IOP reduction was the same as the placebo [23]. The results of a research carried out by Suh et al. showed

that in their study, when bevacizumab was administered in combination with 5-FU, it did not have an additive effect in trabeculectomy [8]. Kaushik et al., in 2017, compared the efficacy of bevacizumab- and mitomycin c-modulated trabeculectomy in POAG. They found that adjunctive bevacizumab was comparable with MMC in reducing IOP for the first year [27]. According to the current findings, topical bevacizumab application is safe and has a significant effect in IOP reduction. In this study topical bevacizumab was used alone without adding any other anti-fibrotic and anti-metabolite agents. The current study had some limitations, including the short time follow up and the number of the cases. Studies with greater number of patients and longer duration of follow up should be designed to establish more significant long term results.

CONCLUSION

sutureless scleral tunnel trabeculectomy is an effective procedure for reduction of IOP yet a single dose of 1.25 mg of topical bevacizumab is significantly more effective in reducing IOP, as compared to the sutureless trabeculectomy alone.

DISCLOSURE

Ethical issues have been completely observed by the authors. All named authors meet the International Committee of Medical Journal Editors (ICMJE) criteria for authorship for this manuscript, take responsibility for the integrity of the work as a whole, and have given final approval for the version to be published. No conflict of interest has been presented.

REFERENCES

1. Jea SY, Francis BA, Vakili G, Filippopoulos T, Rhee DJ. Ab interno trabeculectomy versus trabeculectomy for open-angle glaucoma. *Ophthalmology*. 2012;119(1):36-42. doi: [10.1016/j.ophtha.2011.06.046](https://doi.org/10.1016/j.ophtha.2011.06.046) pmid: 21982416
2. Jampel HD, Musch DC, Gillespie BW, Lichter PR, Wright MM, Guire KE, et al. Perioperative complications of trabeculectomy in the collaborative initial glaucoma treatment study (CIGTS). *Am J Ophthalmol*. 2005;140(1):16-22. doi: [10.1016/j.ajo.2005.02.013](https://doi.org/10.1016/j.ajo.2005.02.013) pmid: 15939389
3. Ramulu PY, Corcoran KJ, Corcoran SL, Robin AL. Utilization of various glaucoma surgeries and procedures in Medicare beneficiaries from 1995 to 2004. *Ophthalmology*. 2007;114(12):2265-70. doi: [10.1016/j.ophtha.2007.02.005](https://doi.org/10.1016/j.ophtha.2007.02.005) pmid: 17466376
4. Spaeth G. *Ophthalmic Surgery: Principles and Practice*. 3rd ed. Philadelphia, PA: WB Saunders Co; 2003.
5. Eslami Y, Mohammadi M, Khodaparast M, Rahmanikhah E, Zarei R, Moghimi S, et al. Sutureless tunnel trabeculectomy without peripheral iridectomy: a new modification of the conventional trabeculectomy. *Int Ophthalmol*.



- 2012;32(5):449-54. doi: [10.1007/s10792-012-9607-4](https://doi.org/10.1007/s10792-012-9607-4) pmid: [22805881](https://pubmed.ncbi.nlm.nih.gov/22805881/)
6. Arish M, Khallaghi H, Soltani E, Akbarpour R. A comparative study of sutureless scleral tunnel trabeculectomy versus conventional trabeculectomy in the management of primary open-angle glaucoma. *Int Ophthalmol*. 2014;34(5):1055-9. doi: [10.1007/s10792-014-9908-x](https://doi.org/10.1007/s10792-014-9908-x) pmid: [24488091](https://pubmed.ncbi.nlm.nih.gov/24488091/)
 7. Lai JS, Lam DS. Trabeculectomy using a sutureless scleral tunnel technique: a preliminary study. *J Glaucoma*. 1999;8(3):188-92. pmid: [10376259](https://pubmed.ncbi.nlm.nih.gov/10376259/)
 8. Suh W, Kee C. The effect of bevacizumab on the outcome of trabeculectomy with 5-Fluorouracil. *J Ocul Pharmacol Ther*. 2013;29(7):646-51. doi: [10.1089/jop.2012.0250](https://doi.org/10.1089/jop.2012.0250) pmid: [23621628](https://pubmed.ncbi.nlm.nih.gov/23621628/)
 9. Wong MH, Husain R, Ang BC, Gazzard G, Foster PJ, Htoon HM, et al. The Singapore 5-fluorouracil trial: intraocular pressure outcomes at 8 years. *Ophthalmology*. 2013;120(6):1127-34. doi: [10.1016/j.ophtha.2012.12.004](https://doi.org/10.1016/j.ophtha.2012.12.004) pmid: [23466269](https://pubmed.ncbi.nlm.nih.gov/23466269/)
 10. Law SK, Shih K, Tran DH, Coleman AL, Caprioli J. Long-term outcomes of repeat vs initial trabeculectomy in open-angle glaucoma. *Am J Ophthalmol*. 2009;148(5):685-95 e1. doi: [10.1016/j.ajo.2009.05.032](https://doi.org/10.1016/j.ajo.2009.05.032) pmid: [19596220](https://pubmed.ncbi.nlm.nih.gov/19596220/)
 11. Fontana H, Nouri-Mahdavi K, Lumba J, Ralli M, Caprioli J. Trabeculectomy with mitomycin C: outcomes and risk factors for failure in phakic open-angle glaucoma. *Ophthalmology*. 2006;113(6):930-6. doi: [10.1016/j.ophtha.2006.01.062](https://doi.org/10.1016/j.ophtha.2006.01.062) pmid: [16647135](https://pubmed.ncbi.nlm.nih.gov/16647135/)
 12. Leung DY, Tham CC. Management of bleb complications after trabeculectomy. *Semin Ophthalmol*. 2013;28(3):144-56. doi: [10.3109/08820538.2013.771199](https://doi.org/10.3109/08820538.2013.771199) pmid: [23697617](https://pubmed.ncbi.nlm.nih.gov/23697617/)
 13. Matlach J, Panidou E, Grehn F, Klink T. Large-area versus small-area application of mitomycin C during trabeculectomy. *Eur J Ophthalmol*. 2013;23(5):670-7. doi: [10.5301/ejo.5000287](https://doi.org/10.5301/ejo.5000287) pmid: [23640510](https://pubmed.ncbi.nlm.nih.gov/23640510/)
 14. Grewal DS, Jain R, Kumar H, Grewal SP. Evaluation of subconjunctival bevacizumab as an adjunct to trabeculectomy a pilot study. *Ophthalmology*. 2008;115(12):2141-5 e2. doi: [10.1016/j.ophtha.2008.06.009](https://doi.org/10.1016/j.ophtha.2008.06.009) pmid: [18692246](https://pubmed.ncbi.nlm.nih.gov/18692246/)
 15. Choi JY, Choi J, Kim YD. Subconjunctival bevacizumab as an adjunct to trabeculectomy in eyes with refractory glaucoma: a case series. *Korean J Ophthalmol*. 2010;24(1):47-52. doi: [10.3341/kjo.2010.24.1.47](https://doi.org/10.3341/kjo.2010.24.1.47) pmid: [20157415](https://pubmed.ncbi.nlm.nih.gov/20157415/)
 16. Li J, Zhang YP, Kirsner RS. Angiogenesis in wound repair: angiogenic growth factors and the extracellular matrix. *Microsc Res Tech*. 2003;60(1):107-14. doi: [10.1002/jemt.10249](https://doi.org/10.1002/jemt.10249) pmid: [12500267](https://pubmed.ncbi.nlm.nih.gov/12500267/)
 17. Nissen NN, Polverini PJ, Koch AE, Volin MV, Gamelli RL, DiPietro LA. Vascular endothelial growth factor mediates angiogenic activity during the proliferative phase of wound healing. *Am J Pathol*. 1998;152(6):1445-52. pmid: [9626049](https://pubmed.ncbi.nlm.nih.gov/9626049/)
 18. O'Neill EC, Qin Q, Van Bergen NJ, Connell PP, Vasudevan S, Coote MA, et al. Antifibrotic activity of bevacizumab on human Tenon's fibroblasts in vitro. *Invest Ophthalmol Vis Sci*. 2010;51(12):6524-32. doi: [10.1167/iovs.10-5669](https://doi.org/10.1167/iovs.10-5669) pmid: [20574016](https://pubmed.ncbi.nlm.nih.gov/20574016/)
 19. Wilgus TA, Ferreira AM, Oberyszyn TM, Bergdall VK, DiPietro LA. Regulation of scar formation by vascular endothelial growth factor. *Lab Invest*. 2008;88(6):579-90. doi: [10.1038/labinvest.2008.36](https://doi.org/10.1038/labinvest.2008.36) pmid: [18427552](https://pubmed.ncbi.nlm.nih.gov/18427552/)
 20. Wong J, Wang N, Miller JW, Schuman JS. Modulation of human fibroblast activity by selected angiogenesis inhibitors. *Exp Eye Res*. 1994;58(4):439-51. doi: [10.1006/exer.1994.1037](https://doi.org/10.1006/exer.1994.1037) pmid: [7523160](https://pubmed.ncbi.nlm.nih.gov/7523160/)
 21. Li Z, Van Bergen T, Van de Veire S, Van de Vel I, Moreau H, Dewerchin M, et al. Inhibition of vascular endothelial growth factor reduces scar formation after glaucoma filtration surgery. *Invest Ophthalmol Vis Sci*. 2009;50(11):5217-25. doi: [10.1167/iovs.08-2662](https://doi.org/10.1167/iovs.08-2662) pmid: [19474408](https://pubmed.ncbi.nlm.nih.gov/19474408/)
 22. Cheng G, Xiang H, Yang G, Ma J, Zhao J. Direct Effects of Bevacizumab on Rat Conjunctival Fibroblast. *Cell Biochem Biophys*. 2015;73(1):45-50. doi: [10.1007/s12013-015-0565-0](https://doi.org/10.1007/s12013-015-0565-0) pmid: [25656769](https://pubmed.ncbi.nlm.nih.gov/25656769/)
 23. Sedghipour MR, Mostafaei A, Taghavi Y. Low-dose subconjunctival bevacizumab to augment trabeculectomy for glaucoma. *Clin Ophthalmol*. 2011;5:797-800. doi: [10.2147/OPHT.S17896](https://doi.org/10.2147/OPHT.S17896) pmid: [21750613](https://pubmed.ncbi.nlm.nih.gov/21750613/)
 24. Fakhraie G, Ghadimi H, Eslami Y, Zarei R, Mohammadi M, Vahedian Z, et al. Short-term Results of Trabeculectomy Using Adjunctive Intracameral Bevacizumab: A Randomized Controlled Trial. *J Glaucoma*. 2016;25(3):e182-8. doi: [10.1097/IJG.000000000000202](https://doi.org/10.1097/IJG.000000000000202) pmid: [25493621](https://pubmed.ncbi.nlm.nih.gov/25493621/)
 25. Klos-Rola J, Tulidowicz-Bielak M, Zarnowski T. Effects of topical bevacizumab application on early bleb failure after trabeculectomy: observational case series. *Clin Ophthalmol*. 2013;7:1929-35. doi: [10.2147/OPHT.S45210](https://doi.org/10.2147/OPHT.S45210) pmid: [24109173](https://pubmed.ncbi.nlm.nih.gov/24109173/)
 26. Kahook MY. Bleb morphology and vascularity after trabeculectomy with intravitreal ranibizumab: a pilot study. *Am J Ophthalmol*. 2010;150(3):399-403 e1. doi: [10.1016/j.ajo.2010.03.025](https://doi.org/10.1016/j.ajo.2010.03.025) pmid: [20570237](https://pubmed.ncbi.nlm.nih.gov/20570237/)
 27. Kaushik J, Parihar JK, Jain VK, Gupta S, Nath P, Durgapal P, et al. Efficacy of Bevacizumab Compared to Mitomycin C Modulated Trabeculectomy in Primary Open Angle Glaucoma: A One-Year Prospective Randomized Controlled Study. *Curr Eye Res*. 2017;42(2):217-24. doi: [10.3109/02713683.2016.1164188](https://doi.org/10.3109/02713683.2016.1164188) pmid: [27269279](https://pubmed.ncbi.nlm.nih.gov/27269279/)