



University of North Dakota  
UND Scholarly Commons

---

Physical Therapy Scholarly Projects

Department of Physical Therapy

---

2016

# Total Knee Arthroplasty and Iliotibial Band Syndrome: A Case Report

Brandon James Moeller  
*University of North Dakota*

Follow this and additional works at: <https://commons.und.edu/pt-grad>

 Part of the [Physical Therapy Commons](#)

---

## Recommended Citation

Moeller, Brandon James, "Total Knee Arthroplasty and Iliotibial Band Syndrome: A Case Report" (2016). *Physical Therapy Scholarly Projects*. 559.  
<https://commons.und.edu/pt-grad/559>

This Scholarly Project is brought to you for free and open access by the Department of Physical Therapy at UND Scholarly Commons. It has been accepted for inclusion in Physical Therapy Scholarly Projects by an authorized administrator of UND Scholarly Commons. For more information, please contact [zeinebyousif@library.und.edu](mailto:zeinebyousif@library.und.edu).

---

TOTAL KNEE ARTHROPLASTY AND ILIOTIBIAL BAND SYNDROME: A CASE  
REPORT

by

Brandon James Moeller  
Bachelor of Science in Exercise Science, North Dakota State University, 2013

A Scholarly Project Submitted to the Graduate Faculty of the

Department of Physical Therapy

School of Medicine

University of North Dakota

in partial fulfillment of the requirements for the degree of

Doctor of Physical Therapy

Grand Forks, North Dakota  
May, 2016




PERMISSION

**Title** Total Knee Arthroplasty and Iliotibial Band Syndrome: A Case Report

**Department** Physical Therapy

**Degree** Doctor of Physical Therapy

In presenting this Scholarly Project in partial fulfillment of the requirements for a graduate degree from the University of North Dakota, I agree that the Department of Physical Therapy shall make it freely available for inspection. I further agree that permission for extensive copying for scholarly purposes may be granted by the professor who supervised my work or, in his absence, by the Chairperson of the department. It is understood that any copying or publication or other use of this Scholarly Project or part thereof for financial gain shall not be allowed without my written permission. It is also understood that due recognition shall be given to me and the University of North Dakota in any scholarly use which may be made of any material in this Scholarly Project.

Signature 

Date 9/24/15

## TABLE OF CONTENTS

LIST OF FIGURES .....	v
LIST OF TABLES .....	vi
ACKNOWLEDGEMENTS.....	vii
ABSTRACT.....	viii
CHAPTER	
I.    BACKGROUND AND PURPOSE.....	1
II.   CASE DESCRIPTION.....	3
Examination, Evaluation and Diagnosis .....	6
Prognosis and Plan of Care.....	7
III.  INTERVENTION.....	9
IV.  OUTCOMES.....	10
V.   DISCUSSION.....	11
Reflective Practice.....	16
APPENDIX .....	18
REFERENCES .....	23

---

## LIST OF FIGURES

### Figure

1. NOBLE TEST .....	19
2. OBER TEST.....	20
3. ILIOTIBIAL BAND ANATOMY.....	21
4. ILIOTIBIAL BAND ANATOMY 2.....	22

LIST OF TABLES

1. SAMPLE INTERVENTION ..... 19

## ACKNOWLEDGEMENTS

I would like to thank my family, friends, classmates, and my clinical instructor Theresa for continually pushing me to be my best.



## ABSTRACT

*Background and Purpose:* Total Knee Arthroplasty (TKA) is one of the most common joint replacements performed in orthopedic medicine. The decision to replace a knee is made through evaluation by an orthopedic surgeon, imaging of the joint, clinical presentation, and the patient's individual needs and desires. Iliotibial band syndrome (ITBS) is a soft tissue dysfunction that can present as pain and tenderness in the hip, thigh, or knee. It primarily stems from rubbing or friction of the IT Band at the lateral femoral condyle. Pain caused by knee degeneration and pain from ITBS can have similar presentations and deserves research recognition.

*Case Description:* The patient was a 67-year-old female attending physical therapy for a standard TKA protocol rehabilitation. She had been experiencing knee pain for 9 months prior to knee replacement. Steroid injections, joint aspiration, and meniscal debridement had been performed prior, with no reduction in pain symptoms. A TKA was performed and she was referred to physical therapy. Following concern that pain remained unchanged following the arthroplasty, re-evaluation revealed symptoms consistent with ITBS.

*Outcome:* The patient was seen for 14 TKA visits, and 4 treatment visits that targeted the IT Band. Following the shift in intervention strategy, pain symptoms were reduced to nearly nonsymptomatic, a level which had not been achieved with prior treatments.

*Discussion:* Research into pain presentation comparing knee degeneration and ITBS is very limited. Correct medical diagnosis is important in functional outcomes and patient satisfaction, and the relationship between these two diagnoses deserves further attention.

## CHAPTER I

### BACKGROUND AND PURPOSE

The patient in this case report underwent a total knee arthroplasty on her right knee and, while the procedure was medically successful, the patient had no reduction in the pain symptoms that led her to the procedure. Iliotibial band friction syndrome is the second most common injury in runners, second only to patellofemoral pain syndrome,<sup>1</sup> and was significantly higher in prevalence in females versus males.<sup>2</sup> ITB syndrome is caused by increased friction at the lateral femoral epicondyle<sup>3</sup> and thus can affect any ambulatory person. While runners are more commonly<sup>4</sup> impacted, non-running walkers have also been found to present with pain proximal to the lateral femoral epicondyle,<sup>1</sup> the typical chief complaint of those with ITBS.<sup>4</sup> Hip abductor weakness is a common etiology in the development of ITBS.<sup>5</sup> Lack of control from the abductor group leads to decreased control of eccentric adduction during gait. There is a myriad of other possible contributing factors. Influences increasing pronation, such as pes planus in this case, during gait lead to altered joint mechanics, increased internal rotation moment of the thigh, and amplified adduction with poor abductor and hip extensor response.<sup>6</sup> Total knee arthroplasties involve the resurfacing of weight bearing surfaces in the knee joint, usually due to increased pain from degenerative changes, typically osteoarthritis. TKAs have become an increasingly expensive procedure, for both Medicare and

providers, with inflation outpacing Diagnostic Related Groups (DRGs) reimbursement in many hospitals nationwide.<sup>7</sup>

This case report aims to assess the relationship between a total knee arthroplasty procedure and iliotibial band syndrome in a knee that was equally painful before and after the joint replacement procedure.

## CHAPTER II

### CASE DESCRIPTION

This patient was a 67-year-old white female, who spoke English, with a high school education. She was married with three adult children that do not live at home. She was a homemaker and her husband was retired. Her husband was in good health and her children lived in the area. She enjoyed gardening, shopping, attending church, and walking in the park. The patient was right handed. The patient had never used an assistive device, except for crutches for a short time following her procedure. She lived in a one-story home with a basement. There were 15 stairs to reach the basement where the laundry is located. There was one 6-in step up to enter the house. They had no assistive equipment in the house. The bathroom had a tub/shower combo that was approximately 18-in high. Following her TKA procedure, the patient discharged home with her husband and currently resides there. She reported having no falls in recent memory. This patient was an overall healthy 67-year-old woman. She had been independent with all activities aside from activities during this procedure's recovery period. She reported sleeping throughout the night. She did have a psychosocial history of psychological jealousy and depression. She was active in her church community. The patient reported no alcohol or drug use, and has never smoked. Her level of fitness would be classified as sedentary. Her mother passed away at the age of 58 from leukemia, and also had a lung removed

when she was alive. Her father died of pancreatic cancer at the age of 68. The patient underwent a tonsillectomy in 1962, varicose vein procedure in 1966, lumpectomy in the right breast in 1996, hysterectomy in 2003, right (R) humerus fracture repair in 1954, and a breast biopsy in 2005. She had pneumonia in 2003, and also had hypothyroidism. In October of 2013, the patient saw her physician for right knee pain with an insidious onset that had been bothering her for approximately 1 month. Pain presented within 5 to 10 minutes of weight bearing, and she had trialed an unspecified knee brace, without success. She was not taking any over-the-counter meds at this time. She underwent imaging at this time. Radiology found a horizontal tear of the posterior horn and body of the medial meniscus with mild extrusion of the midbody of the medial meniscus. There was a radial tear at the posterior horn of the lateral meniscus. The ACL showed signs of degeneration but was intact. She had small to moderate joint effusion and a moderate-sized Baker's cyst at that time. There was no acute fracture seen at that time. The radiologist found partial thickness cartilage defects<sup>8</sup> of the medial femoral condyle and medial tibial plateau with underlying subchondral cysts. She underwent an aspiration at that time. She was referred to an orthopedic specialist who found tenderness at the medial and lateral joint line, increased pain with medial and lateral McMurray test, and discomfort in the interior aspect of the knee and patellofemoral joint. Range of motion (ROM) was -10 to 90 degrees, limited by pain. She had negative Lachman, anterior drawer, and posterior drawer tests. The knee was stable to valgus and varus stress at 10 and 30 degrees. Her dorsalis pedis and posterior tibial pulses were 2+ (normal). Sensory motor examination was intact at that time. She displayed

joint narrowing medially, but had 2 to 3 mm of joint space throughout. In late November of 2013 the patient underwent a partial medial and lateral meniscectomy. There were no complications with the procedure. She was seen for an inpatient 1 day physical therapy examination following the procedure, where she was educated in a home program for ankle pumps, gluteal sets, quad sets, all single sets of 10 repetitions. She was also educated on PRICE principle (protection, rest, ice, compression, elevation), edema management, and gait. Her ROM was 0 to 90 degrees at this time. At one week follow up with the orthopedist she was still having mild effusion and discomfort in the posterior region of the (R) knee. In mid-December the patient returned with continuing discomfort and pain in the (R) LE (lower extremity). Imaging was redone, and a stress fracture was inconclusively believed to be seen on the medial femoral condyle. She was referred to a rheumatologist. Rheumatoid labs were all negative, and a TKA was discussed. The following February, during a follow up, the patient noted pain in the (L) knee. Imaging was negative for stress fractures. In early July of 2014, the patient underwent a (R) TKA with no complications. She underwent standard post-op PT at that time, and continued to have pain at the (R) knee. LE strengthening and ROM returned in that time and the patient met all goals, but was still having knee pain at expiration of orders. In early September she returned to the physician with complaints of continuing knee pain. Nursing charts at this time noted that the patient claimed her pain had always been in the IT band. Patient received new PT orders and I evaluated her at this time.

## Examination, Evaluation, and Diagnosis

Upon evaluation, patient had been independent with all activities of daily living (ADLs) and instrumental activities of daily living (IADLs). Patient was taking over-the-counter nonsteroidal anti-inflammatory drugs (NSAIDs) at this time. Side effects impacting physical therapy could include increased pain tolerance beyond safe levels. I performed Ober's test on the right with leg straight, and the test was positive for ITB tightness. The patient's resting HR was 62 bpm, and respiratory rate was 20 breaths per minute. Blood pressure was 118/68, and O<sub>2</sub> saturation was 98%. I noted edema at the right (R) knee, grossly. The right knee was warm, but dry, clean, and well healed. Surgical scar was pink, unraised, and unremarkable. The patient stood with a slightly flexed posture in side view. I noticed marked valgus of the knees bilaterally in anterior and posterior view. Upper extremity (UE) ROM was grossly within functional limits (WFL). The left LE was WFL grossly, and right knee ROM was -4 to 111 (normal 0 to 135) degrees with pain at end range. UE strength was WFL grossly. I found the hip abductors to be weak, (R) 3/5 and (L) 3+/5 with manual muscle testing. All other LE strength was WFL bilaterally. The patient was 5'8" tall and weighed 187 lb. BMI was 28.5. Balance was WFL in sitting, static, and dynamic observations. The patient reported no perception of balance deficit and no falls. Gait analysis ambulating on a level surface revealed valgus at both knees, with (L) greater than (R). She had noticeable pronation at the ankles, as well as talar inversion. The patient deferred stair-testing secondary to pain. Pain was reported to be 3/10 at best, 8/10 at worst, and 5/10 at that time, all in the (R) knee. Patient was able to independently complete all bed mobility tasks, including supine to sit and sit



to stand. The patient had no communication barriers, was alert and oriented x4, and did not specify any learning preferences. The tests and measures I used included Ober's test as well as the LEFS (lower extremity functional scale). LEFS scored 37/80 (23/80 prior) for a 53.75% disability. Ober's test was chosen to rule-in/rule-out ITB and was positive, and LEFS was chosen to evaluate LE disability. (See Appendix)

Evaluation and examination of this patient led me to believe pain was being caused by IT band tightness with accompanying discomfort at the tissue insertion at that time. Impairments included pain at the (R) knee limiting ambulation, altered LE mechanics, and decreased ROM. Functional limitations limited gait distance and leisure activity duration secondary to pain. Risk reduction included proper footwear to improve LE mechanics.

The PT diagnosis was Preferred Practice Pattern 4D: Impaired Joint Mobility, Motor Function, Muscle Performance, and Range of Motion Associated With Connective Tissue Dysfunction coded, ICD-9: 728.8.

#### Prognosis and Plan of Care

The patient completed ADLs and IADLs at this time, but with pain. I treated the patient for 4 weeks as an outpatient, to return to pain-free levels of function. Short-term goals equaled long-term goals with this patient, and were to be met within 4 weeks.

#### Goals:

1. Patient was to report decreased pain to less than or equal to 3 out of 10, consistently from the beginning of the day to the end of the day without

“tightening of band” around her knee, improving the patient’s tolerance for functional tasks around the home and in the community.

2. Patient was to report and demonstrate increased improvement on LEFS by greater than or equal to 10-point change for patient to improve tolerance for community mobility.

3. Patient was to demonstrate improved right hip strength by 1 to 2 muscle grades of hip abduction and extension, decreasing patient’s muscle imbalance and improving alignment of the LE.

4. Patient was to progress and improve ROM of the right knee 0 to 115 degrees, demonstrating improved ROM for functional tasks including negotiation of steps and curbs without exacerbation of right knee pain.

5. Patient was to demonstrate and report improved community mobility tolerance with patient ability to ambulate greater than or equal to 5 city blocks without exacerbation of the knee pain as expected, status post TKA.

Discharge criteria included meeting all goals listed.

Plan of Care (POC): I continued to see patient with new orders from her physician and she was seen 2 to 3 times per week for 4 weeks for manual intervention including soft tissue mobilization, stretching of (R) IT band, passive stretching of knee, joint mobilizations, and active strengthening to improve ROM, decrease pain, and restore functional mobility. Additionally, I educated the patient on choosing appropriate footwear and proper gait mechanics.

## CHAPTER III

### INTERVENTION

I collected informed consent from the patient prior to service. Case management included acquiring additional orders to treat from the surgeon. Data collection was done face to face as well as by chart review. Instruction included verbal as well as written education materials. Therapeutic activity included passive knee extension and flexion stretching to improve ROM of the knee, ITB stretching in sidelying to reduce tension of ITB, and foam rolling of the ITB in sidelying to relax ITB tissue. Patient education included footwear recommendations with a mirror for patient feedback and education, as well as a referral for corrective shoe orthotics. Therapeutic exercise included the implementation of additional exercises to be added to her home program that focused on hip abductor and extensor strengthening. Manual therapy intervention techniques included soft tissue massage (STM) to the ITB with trigger point emphasis to gluteus medius and tensor fascia latae (TFL) in sidelying with long stroke and muscular facilitation release (MFR) techniques to relax ITB tissue, as well as hooklying proximal fibular grade 3 joint mobilizations in anterior/posterior direction to improve joint mobility and decrease adhesions at ITB insertion. (See Appendix)

## CHAPTER IV

### OUTCOMES

The patient presented to PT after a (R) TKA, but was still experiencing the same pain that was present prior to the joint replacement. Upon evaluation, the IT band was found to be tight on the right. Following intervention strategies that focused on strengthening the hip abductors and relaxing the ITB tissue, the patient achieved complete reduction of pain symptoms and resumed her prior level of activity. Impairments at evaluation included increased tension and adhesions present in the (R) ITB as well as decreased mobility at the proximal tibiofibular joint near the IT band insertion. Changes in function included decreased ambulatory tolerance due to pain. Changes in participation included decreased frequency and duration of leisure activities such as gardening, church activities, and recreational walking. Risk reduction and prevention were accomplished by completion of a home program focusing on maintaining strength in the hip abductors and stretching of the ITB daily, as well as proper footwear that reduced knee valgus. Impact on her societal resources was minimal. The patient was extremely satisfied with the results I provided, but questioned whether or not her pain was of the soft tissue origin from the onset.

## CHAPTER V

### DISCUSSION

In 1978, a researcher completing an early study of ITBS reported one subject with a very similar presentation to the one outlined here. The patient had undergone a meniscectomy in the symptomatic knee a year prior, with no change in symptoms postoperatively. This patient was diagnosed with ITBS at the time of the study, treated with local steroid injections, and had elimination of symptoms.<sup>4</sup> Continued soft tissue work of the iliotibial band and strategic strengthening in the hips reduced the knee pain in the patient described here, which can be extremely debilitating.<sup>9</sup> Current estimates place prevalence between 1.6-12% of runners<sup>10</sup>, and likely much lower among the sedentary population.

#### Anatomy

Anatomically, the iliotibial band has a primary distal attachment alluded to in its nomenclature, the tibia. More specifically, it attaches at Gerdy's tubercle. However, the fascia of the distal IT band blends with surrounding structures<sup>11</sup> as it approaches its insertion, notably the biceps femoris. The biceps femoris inserts at the fibular head, and thus guided my rationale that fibular head mobilizations may improve this patient's symptoms. Overall, the anatomical makeup of the insertion of these tissues is fairly complex.<sup>12</sup> Baker et al<sup>13</sup> went on to note that the interrelated nature of the distal attachment could cause atypical pain presentation location.

Symptoms are most common when the knee is at approximately 30 degrees of flexion, the point where the IT band crosses from anterior to posterior in respect to the lateral epicondyle.<sup>14</sup> (See Appendix)

### Biomechanics

Females, in particular, may be more likely to develop ITBS based on lower extremity alignment variations. Noehren et al<sup>15</sup> studied the biomechanical alignment of females and found greater hip adduction and internal rotation in those positive for ITBS. Taunton et al<sup>2</sup> found knee varus and valgus, as well as pes planus to be the three highest contributors to biomechanical variables in subjects with ITBS, at 33, 15, and 15%, respectively. Knee valgus causes a ground reaction force vector that is lateral to the knee, increasing adduction of the hip and a compensated Trendelenberg sign.<sup>10,16</sup> Knee valgus and pes planus were both clinically notable in this patient. However, some research directly disagrees with the belief excessive pronation and tibial rotation cause ITBS.<sup>17</sup> Lavine et al<sup>10</sup> also reference mixed opinion concerning rearfoot eversion. Overall, lower extremity biomechanical alignment is important to note and interpret correctly during the physical examination.<sup>14</sup>

### Musculature

While muscle imbalance has a back and forth cause-and-effect relationship with biomechanics, it is important to recognize the causative effect weakness can cause in the development of ITBS. Hip strength improvements have been shown to parallel symptom improvement in those suffering from ITBS.<sup>5</sup> The tensor fascia latae (TFL) has a propensity for becoming shortened and tight. Consequently, the gluteal group, both maximus and medius, are both predisposed to weakness and excessive

lengthening.<sup>11</sup> This muscular imbalance can lead to hip flexion and internal rotation tendencies, as well as Trendelenberg patterns in stance and gait. This decreases the ability of the hip to maintain the lower extremity in correct alignment and promotes excessive adduction of the hip. Gluteal strength deficits and TFL tightness were both readily apparent upon the clinical examination of this patient. Several studies support a lack of muscular balance or control as contributing factors in the development of ITBS.<sup>5,18,19</sup> These studies evaluate runners, and thus weakness likely has an amplified effect over the non-runner, but they too are affected by suboptimal muscular balance. This is evident in sedentary individuals exhibiting a Trendelenberg or compensated Trendelenberg gait pattern.

#### Other Factors

While footwear choices could be strongly tied to biomechanics, footwear education was a large part of this plan of care. Upon evaluation, I found the patient favored light shoes with minimal medial support. When in the home, she typically went barefoot, as well. Following gait and posture analysis, it was readily evident the patient had marked pes planus bilaterally and lacked terminal extension at heel strike. I felt that footwear with greater medial support and the use of an antipronation orthotic would improve her foot misalignment, in turn reducing tibial rotation and normalizing lower extremity kinematics. There is disagreement surrounding the effectiveness and benefit of shoe orthotics,<sup>2</sup> and further research is needed. Using photo comparisons in this case it was evident that shoes with greater medial support and the use of pronation orthotics improved both knee valgus and pes planus bilaterally, when the images were compared side by side. Proximal trigger points in

the lateral hip musculature may also refer symptoms distally to the knee.<sup>17</sup> This patient had no radiculopathy or symptom referral, but did present with multiple trigger points of hypersensitive contractile tissue.

### Special Tests

Ober's test<sup>10,20</sup> and Noble's test<sup>14</sup> are commonly used and widely accepted diagnostic special tests for ITBS.

### ITBS Treatment

Research supports lower extremity strengthening in a physical therapy rehabilitation program for those suffering from ITBS.<sup>5,21</sup> Stretching has been found to demonstrate significant improvements in ITB length in a study conducted by Fredricson, as well.<sup>22</sup> In other studies, such as those by Falvey et al<sup>23</sup>, and noted by Lavine et al<sup>10</sup>, there is a lack of correlation between short term stretching and long term symptom effects. Wang et al<sup>24</sup> studied the effectiveness of the Ober stretch and Modified Ober stretch in patients with ITBS and found both to be effective. In conjunction with strengthening, a systematic review by Ellis et al<sup>13</sup> compared numerous other conservative treatment options and found evidence to support several interventions. Four treatments that did show limited supportive evidence in this systematic review included deep tissue friction massage (DTFM), phonophoresis, oral NSAIDs, and local corticosteroid injections. Phonophoresis provided significant improvement against immobilization, but this study lacked a control. DTFM provided significant relief of symptoms, but the control group improved equally as well, however with groups of only 10 participants. With varied levels of improvement in symptoms and a lack of blinding and control in several of



the studies reviewed, the authors conclude that further, higher-quality research is warranted.<sup>13</sup> Support for both manual therapy techniques such as active-release techniques and adhesion relaxation via foam roller is growing in literature.<sup>14</sup> With this patient, stretching, strengthening, manual therapy techniques, education, and gait training were utilized comprehensively with good results. Therefore it would be difficult to pinpoint the intervention or interventions that had the most positive effect on this patient. A study by Falvey et al<sup>23</sup> challenges both the use of anti-inflammatory agents and stretching of the IT band. Cadaveric dissection exhibited the absence of a bursa at the lateral femoral epicondyle, and the same study examined high level athletes and discovered an inability to observe tissue stretch in the IT bands of a group of professional rugby players. They instead offer a theory of acute inflammatory response and an apparent, but not true, lengthening of the IT band during stretching, respectively. They also recommend focusing treatment, including stretching, more proximally on the gluteal group and the TFL. While the etiology, pathology, and optimal treatment commonly differ in the literature, therapists typically get good outcomes with a battery of conservative treatment.<sup>10</sup>

#### TKA and ITBS Overlap

I was able to find documented overlap in knee arthroplasties and ITBS, although clear cases of causation and correlation are speculative, at best. One study compared the revision rate of a new type of knee implant to traditional types of devices. In a total of 226 knee implants, 33 had unsuccessful outcomes. Upon follow up, six (3 control, 3 experimental) of the 33 patients were diagnosed with ITBS, for an overall prevalence of 2.6%.<sup>25</sup> Isik et al<sup>26</sup> conducted a study comparing changes in

the joint line following a TKA and lateral knee pain in 79 subjects. Statistically significant higher IT band tension was found in the test group (>8mm joint line variance) group versus control (<8mm joint line variance), 67% to 17%, respectively. Positive Ober test was significant in the test group as well, 77% to 19%, respectively. They concluded that drastic changes to the joint alignment during TKA procedures can significantly affect pain and lateral tension in the knee.<sup>26</sup> A study by Luyckx et al<sup>12</sup> observed 1102 postoperative TKA patients, and their outcomes following the procedure. In 81 knees (7.2%), symptoms presenting as ITBS were found upon follow up. They noted the average onset of symptoms following the procedure was 6.3 months. As this study was retrospective in nature, they were not able to identify the prevalence of this presentation prior to the arthroplasty procedure. Instead, they explore the possible modification of the implants in this study to reduce the posterior translation of the lateral femoral condyle and subsequent guided tibial internal rotation in knee flexion.<sup>12</sup>

### Reflective Practice

The patient in this case was initially diagnosed with a torn meniscus and degenerative changes in the knee from an orthopedic and radiologic perspective. I cannot help but wonder if the patient had sought out the advice of a physical therapist following the initial onset of symptoms or pursued more conservative management, she may have had the same outcome without undergoing a joint replacement. From my episode of care, with the treatment adjusted to address ITBS, she was able to achieve great results in symptom reduction. I am glad I had the foresight to document and describe everything I saw, heard, and felt during

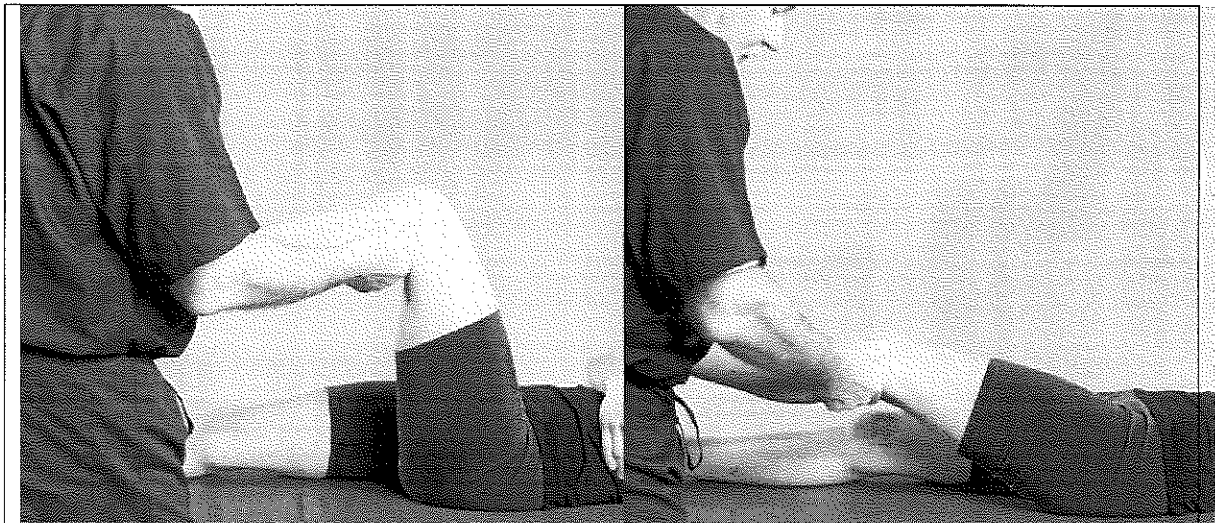
treatment sessions, before I knew I would be developing this patient's case into a report. The only regret I have in this case is that I failed to formally document a positive Noble's test during the visit in which I changed her treatment strategy.

### Conclusion

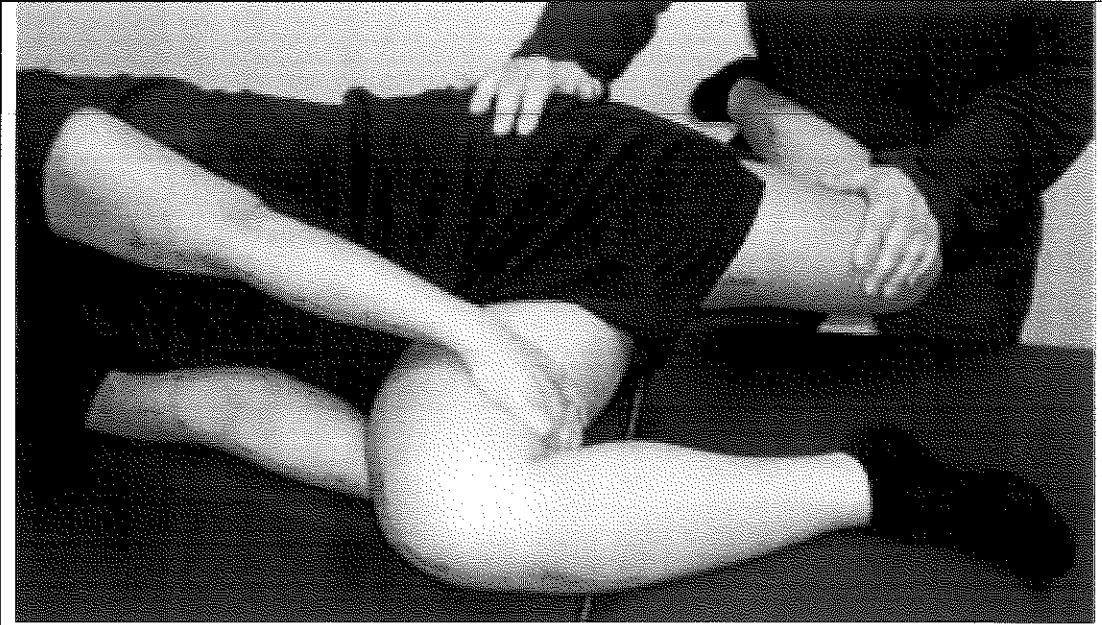Due to the retrospective nature of the case, it may be impossible to know the true cause of the patient's knee pain prior to her surgical procedures. It is likely that degenerative changes as she aged and the medial and lateral torn menisci in the knee led to the initial pain episode, and the pain experienced after the TKA may have been caused by the joint replacement itself with altered lower extremity biomechanics. The patient likely had valgus in her knees for many years, and this may have been accentuated by poor choices in footwear. Upon correction of the knee mechanics, her lateral musculature would have been subjected to increased tension and altered mechanics, and subsequently developed pain with ambulation and use. Alternative interventions outside of physical therapy include topical anti-inflammatory treatments at the site of the pain, as well as a less conservative surgical release of the iliotibial band. The literature supports the potential for causation presented in this case, but further research would be necessary to make significant correlations.

## APPENDIX

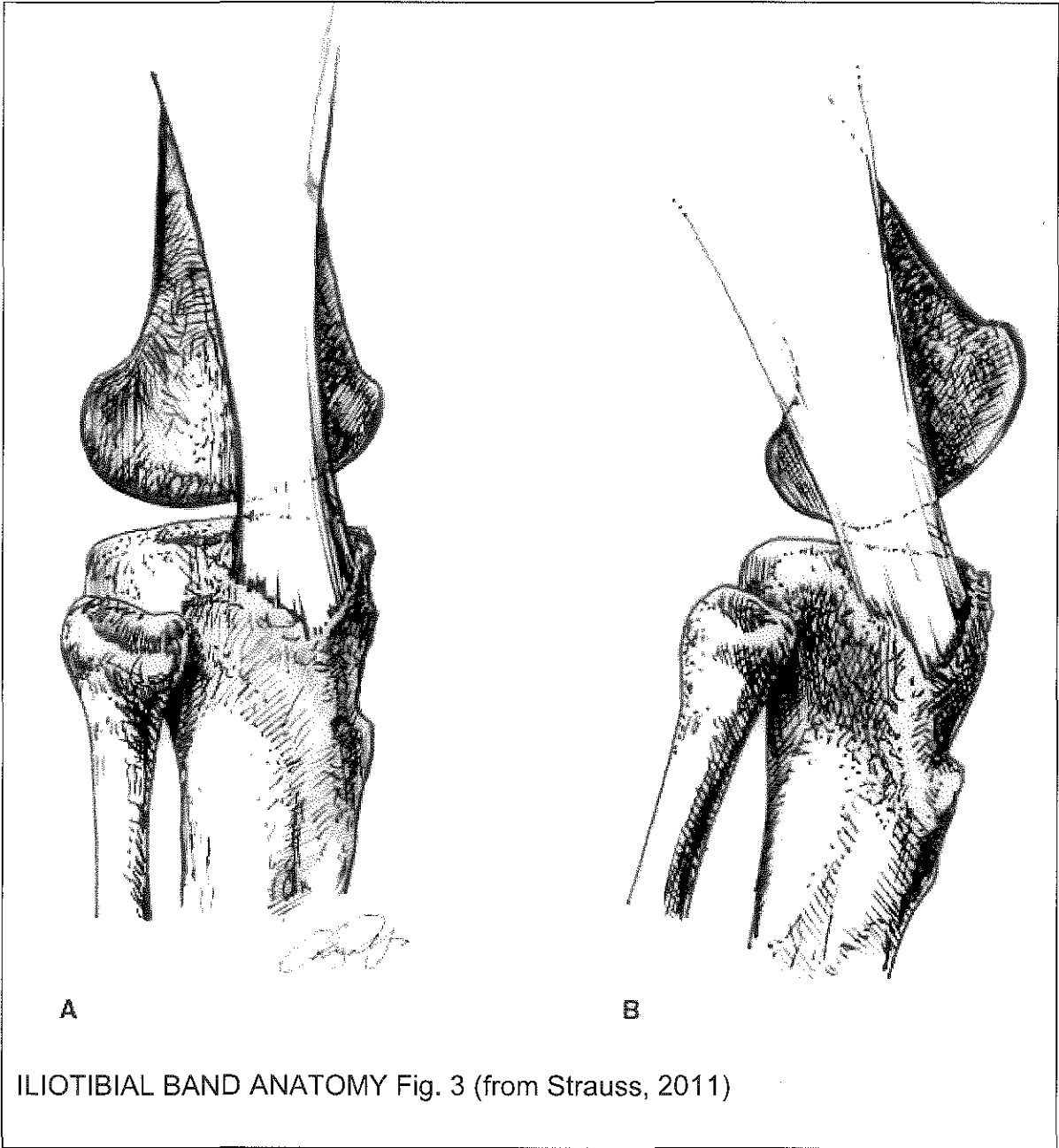
Intervention	Dose
Passive knee flexion/extension	2 sets, 5 minutes
ITB stretching, sidelying	1 set, 8 minutes
ITB foam rolling	1 set, 9 minutes
ITB STM with trigger point emphasis	1 set, 18 minutes
Tib/Fib joint mobilization	2 sets, 10 reps
Hip abductor strengthening, concentric	3 sets, 10 reps
SAMPLE INTERVENTION, Table. 1	

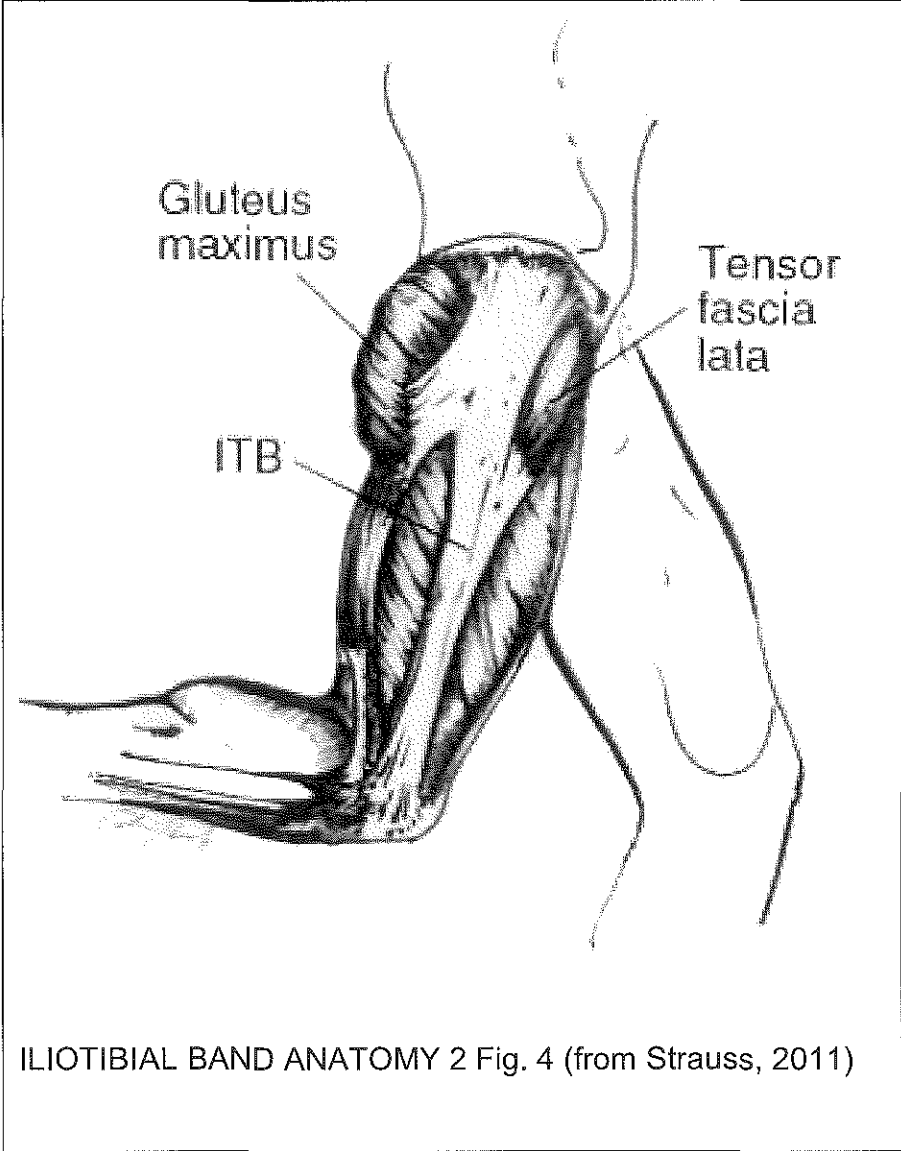


NOBLE TEST, Fig. 1 (from <http://image.frompo.com/bf26f7432c6116b3ff975f83bce0400f>)



OBER TEST, Fig. 2 (from Strauss, 2011)







## REFERENCES

1. Dixit S, Difiori JP, Burton M, Mines B. Management of patellofemoral pain syndrome. *Am Fam Physician*. 2007;75(2):194-202.
2. Taunton JE, Ryan MB, Clement DB, McKenzie DC, Lloyd-Smith DR, Zumbo BD. A retrospective case-control analysis of 2002 running injuries. *Br J Sports Med*, 2002;36(2),95-101.
3. Noble CA. Iliotibial band friction syndrome in runners. *Am J Sports Med*. 1980; 8(4):232-234.
4. Orava S. Iliotibial tract friction syndrome in athletes--an uncommon exertion syndrome on the lateral side of the knee. *Br J Sports Med*. 1978;12(2):69-73.
5. Fredericson M, Cookingham CL, Chaudhari AM, Dowdell BC, Oestreicher N, Sahrmann SA. Hip abductor weakness in distance runners with iliotibial band syndrome. *Clin J Sports Med*. 2000;10(3):169-175.
6. Fredericson M, Wolf C. Iliotibial band syndrome in runners. *J Sports Med*. 2005;35(5):451-459.
7. Healy WL, Rana AJ, Iorio R. Hospital economics of primary total knee arthroplasty at a teaching hospital. *Clin Orthop Relat Res*. 2011;469(1):87-94.
8. Noyes FR, Stabler CL. A system for grading articular cartilage lesions at arthroscopy. *Am J Sports Med*. 1989;17(4):505-513.
9. Fearon AM, Cook JL, Scarvell JM, Neeman T, Cormick W, Smith PN. Greater trochanteric pain syndrome negatively affects work, physical activity and quality of life: a case control study. *J Arthroplasty*. 2014;29(2):383-386.
10. Lavine R. Iliotibial band friction syndrome. *Curr Rev Musculoskelet Med*. 2010;3(1-4):18-22.
11. Baker RL, Souza RB, Fredericson M. Iliotibial band syndrome: soft tissue and biomechanical factors in evaluation and treatment. *PMR*. 2011;3(6):550-561.
12. Luyckx L, Luyckx T, Bellemans J, Victor J. Iliotibial band traction syndrome in guided motion TKA. A new clinical entity after TKA. *Acta Orthop Belg*. 2010;76(4):507.

13. Ellis R, Hing W, Reid D. Iliotibial band friction syndrome—a systematic review. *Man Ther.* 2007;12(3):200-208.
14. Strauss EJ, Kim S, Calcei JG, Park D. Iliotibial band syndrome: evaluation and management. *J Am Acad Ortho Surg.* 2011;19(12):728-736.
15. Noehren B, Davis I, Hamill J. ASB Clinical Biomechanics Award Winner 2006: Prospective study of the biomechanical factors associated with iliotibial band syndrome. *Clin Biomech.* 2007;22(9):951-956.
16. Powers CM. The influence of abnormal hip mechanics on knee injury: a biomechanical perspective. *J Orthop Sports Phys Ther.* 2010;40(2):42-51.
17. Khaund R, Flynn SH. Iliotibial band syndrome: a common source of knee pain. *Am Fam Physician.* 2005;71(8):1545-50.
18. Messier SP, Edwards DG, Martin DF, Lowery RB, Cannon DW, James MK, et al. Etiology of iliotibial band friction syndrome in distance runners. *Med Sci Sports Exerc.* 1995;27(7):951-960.
19. Noehren B, Schmitz A, Hempel R, Westlake C, Black W. Assessment of strength, flexibility, and running mechanics in men with iliotibial band syndrome. *J Orthop Sports Phys Ther.* 2014;44(3):217-222.
20. Reese NB, Bandy WD. Use of an inclinometer to measure flexibility of the iliotibial band using the Ober test and the modified Ober test: differences in magnitude and reliability of measurements. *J Orthop Sports Phys Ther.* 2003;33(6):326-330.
21. Beers A, Ryan M, Kasubuchi Z, Fraser S, Taunton JE. Effects of multi-modal physiotherapy, including hip abductor strengthening, in patients with iliotibial band friction syndrome. *Physiother Can.* 2008;60(2):180-188.
22. Fredericson M, White JJ, MacMahon JM, Andriacchi TP. Quantitative analysis of the relative effectiveness of 3 iliotibial band stretches. *Arch Phys Med Rehabil.* 2002;83(5):589-592.
23. Falvey EC, Clark RA, Franklyn-Miller A, Bryant AL, Briggs C, McCrory PR. Iliotibial band syndrome: an examination of the evidence behind a number of treatment options. *Scand J Med Sci Sports.* 2010;20(4):580-587.
24. Wang TG, Jan MH, Lin KH, Wang HK. Assessment of stretching of the iliotibial tract with Ober and modified Ober tests: an ultrasonographic study. *Arch Phys Med Rehabil.* 2006;87(10):1407-1411.

25. Christen B, Neukamp M, Aghayev E. Consecutive series of 226 journey bicruciate substituting total knee replacements: early complication and revision rates. *BMC Musculoskelet Disord*. 2014;15(1):395.
26. Isik C, Dasar U, Tahta M, Cay N, Akmese R, Isik D, et al. The Relationship between Incorrect Restoration of the Joint Line and Lateral Knee Pain in Patients Undergoing Total Knee Arthroplasty. *Open J Rheumatol Autoimmune Dis*, 2014.