



1997

A Physical Therapy Perspective on Rotator Cuff Disease

Tiffany R. Wirz
University of North Dakota

Follow this and additional works at: <https://commons.und.edu/pt-grad>



Part of the [Physical Therapy Commons](#)

Recommended Citation

Wirz, Tiffany R., "A Physical Therapy Perspective on Rotator Cuff Disease" (1997). *Physical Therapy Scholarly Projects*. 483.
<https://commons.und.edu/pt-grad/483>

This Scholarly Project is brought to you for free and open access by the Department of Physical Therapy at UND Scholarly Commons. It has been accepted for inclusion in Physical Therapy Scholarly Projects by an authorized administrator of UND Scholarly Commons. For more information, please contact zeinebyousif@library.und.edu.

A PHYSICAL THERAPY PERSPECTIVE ON ROTATOR CUFF DISEASE

by

Tiffany Wirz
Bachelor of Science in Physical Therapy
University of North Dakota, 1996



An Independent Study

Submitted to the Graduate Faculty of the

Department of Physical Therapy

School of Medicine

University of North Dakota

in partial fulfillment of the requirements


for the degree of

Master of Physical Therapy


Grand Forks, North Dakota

May
1997


This Independent Study, submitted by Tiffany R. Wirz in partial fulfillment of the requirements for the Degree of Master of Physical Therapy from the University of North Dakota, has been read by the Faculty Preceptor, Advisor, and Chairperson of Physical Therapy under whom the work has been done and is hereby approved.



(Faculty Preceptor)



(Graduate School Advisor)



(Chairperson, Physical Therapy)

PERMISSION

Title A Physical Therapy Perspective on Rotator Cuff Disease

Department Physical Therapy

Degree Master of Physical Therapy

In presenting this Independent Study Report in partial fulfillment of the requirements for a graduate degree from the University of North Dakota, I agree that the Department of Physical Therapy shall make it freely available for inspection. I further agree that permission for extensive copying for scholarly purposes may be granted by the professor who supervised my work or, in her absence, by the Chairperson of the department. It is understood that any copying or publication or other use of this Independent Study Report or part thereof for financial gain shall not be allowed without my written permission. It is also understood that due recognition shall be given to me and the University of North Dakota in any scholarly use which may be made of any material in my Independent Study Report.

Signature Siffany R. Witz

Date 12/18/96

TABLE OF CONTENTS

LIST OF FIGURES	vi
LIST OF TABLES	vii
ABSTRACT	viii
CHAPTER		
I	INTRODUCTION TO THE ROTATOR CUFF.....	1
II	ANATOMY AND BIOMECHANICS OF THE SHOULDER COMPLEX	3
	Joints of the Shoulder	3
	Muscles of the Shoulder	12
	Role of the Scapula	14
	Scapulohumeral Rhythm	19
III	ETIOLOGY	22
	Traumatic Injury	22
	Degenerative Processes	22
IV	DIFFERENTIAL DIAGNOSIS	27
	Bursitis	27
	Tendinitis	28
	Impingement	32
	Rotator Cuff Tears.....	33
V	REHABILITATION OF ROTATOR CUFF TEARS.....	38
	Phase I	40
	Phase II	41
	Phase III	44
	Phase IV	46

VI	CONCLUSION	48
	APPENDIX	51
	REFERENCES	53

LIST OF FIGURES

Figure		Page
1.	Sternoclavicular Ligaments	5
2.	Acromioclavicular Ligaments	7
3.	Glenohumeral Ligaments	10
4.	Coracoacromial Arch	10

LIST OF TABLES

Table		Page
1.	Muscles Involved in Scapular Motion	15
2.	Muscles Involved in Shoulder Motion	16
3.	Special Tests of the Shoulder	29
4a.	Differential Diagnosis	36
4b.	Differential Diagnosis	37
5.	Scapular Exercises	43
6.	Plyometric Exercises for the Shoulder	47

ABSTRACT

Rotator Cuff disease is one of the most common shoulder problems seen in the medical setting today. It spans all ages ranging from the young athlete who suffers from overuse syndrome to the older individual who experiences decreased function due to degenerative changes within the shoulder joint.

The chief causes of rotator cuff tears are traumatic injury and degenerative changes. Tears resulting from trauma usually occur from a lateral blow to the shoulder. Degenerative changes in the rotator cuff result from many factors. These factors include: decreased vascularity, age, shape of the acromion, repetitive trauma, scapular instability, and muscular weakness.

The shoulder is a complex joint and proper treatment relies on the physical therapist's knowledge of the anatomy and function of all of the structures involved in the shoulder complex. The therapist must also know how the structures work together to promote the smooth, coordinated movements necessary for normal arm motion.

This paper focuses on the causes of rotator cuff pathology with a presentation of the signs and symptoms of rotator cuff disease. Other problems of the shoulder will also be discussed and differential diagnosis of these problems will be presented followed by a discussion of shoulder rehabilitation programs for conservative and surgical treatment of rotator cuff tears.

CHAPTER I

INTRODUCTION TO THE ROTATOR CUFF

Rotator Cuff pathologies are one of the most common shoulder problems seen in the physical therapy setting today.^{1,2} From the elderly person experiencing degeneration of the shoulder, to the young athlete suffering from overuse syndrome as a result of a sport requiring repetitive overhead motions, shoulder problems impact all age ranges.^{3,4}

The major causes of rotator cuff tears are traumatic injury and degeneration.⁵ Tears resulting from trauma usually occur from a lateral blow to the shoulder induced from a fall or a contact injury during a sport or an automobile accident.⁶ They account for many of the rotator cuff tears seen in the physical therapy setting. Degeneration of structures in the shoulder complex result from a variety of factors. These factors include: decreased vascularity, age, shape of the undersurface of the acromion, repetitive trauma, scapular instability, and muscular weakness.^{3,6,7,8}

Rehabilitation of rotator cuff tears involve two options: 1) conservative or 2) surgical treatment.^{1,3,9} When making the decision on which approach to use, the patient's age, physical activity level, and the demands to be placed on the affected shoulder must be taken into account.⁶ A patient who requires surgery will lag behind a non-surgical patient by 4-6 weeks during treatment due to the extra soft tissue healing that must occur

after surgery.^{3,9,10} Immobilization and restrictions on active arm elevation add to the increased therapy time of a surgical patient. Disregarding time frames and active elevation restrictions of the post-surgical patient, rehabilitation of rotator cuff tears follows a four phase treatment plan that can be used for both the surgical and the conservatively managed patients.

The purpose of this paper is to discuss the causes of rotator cuff pathology with a presentation of the signs and the symptoms of rotator cuff disease. Differential diagnosis between rotator cuff tears and other shoulder problems such as bursitis, tendinitis, and impingement will be discussed and a rehabilitation program for rotator cuff tears including conservative and post-surgical management will be covered in detail.

The shoulder is considered one of the most complex joint in the human anatomy. Proper diagnosis and treatment of shoulder dysfunction requires a thorough understanding of the functional anatomy of the shoulder complex. This will be discussed in the following chapter.

CHAPTER II

SHOULDER ANATOMY AND BIOMECHANICS

The shoulder girdle consists of the scapula, clavical, and humerus. These three bones are controlled by four interdependent linkages: the sternoclavicular (SC) joint, the acromioclavicular (AC) joint, the glenohumeral (GH) joint, and a functional articulation known as the scapulothoracic (ST) joint.¹¹ Together, these four joints give the shoulder more mobility than any other joint in the body.^{3,12} Full range of motion (ROM) of the shoulder complex depends on the coordination and synchronous motion of these four joints.¹² The SC joint is unique because it represents the only boney connection between the shoulder complex and the rest of the body. This implies that the shoulder complex depends on non-boney connections such as muscles, capsules, and ligaments to maintain its integrity with the body.^{3,13} This chapter will cover the four joints and their structure and involvement in shoulder function, the muscles of the shoulder, the role of the scapula, and the concept of Scapulohumeral Rhythm (SHR).

Joints of the Shoulder

Sternoclavicular Joint. — The SC joint is a plane, synovial, saddle shaped joint that functions as a ball and socket with three degrees of freedom. Elevation/depression, protraction/retraction, and rotation occur at this joint.^{12,14,15} The medial end of the lavalical articulates with a shallow sternal socket, an articular disc, and cartilage of the first rib.^{12,14}

These articulations have incongruent surfaces which allow little contact between them.¹⁵

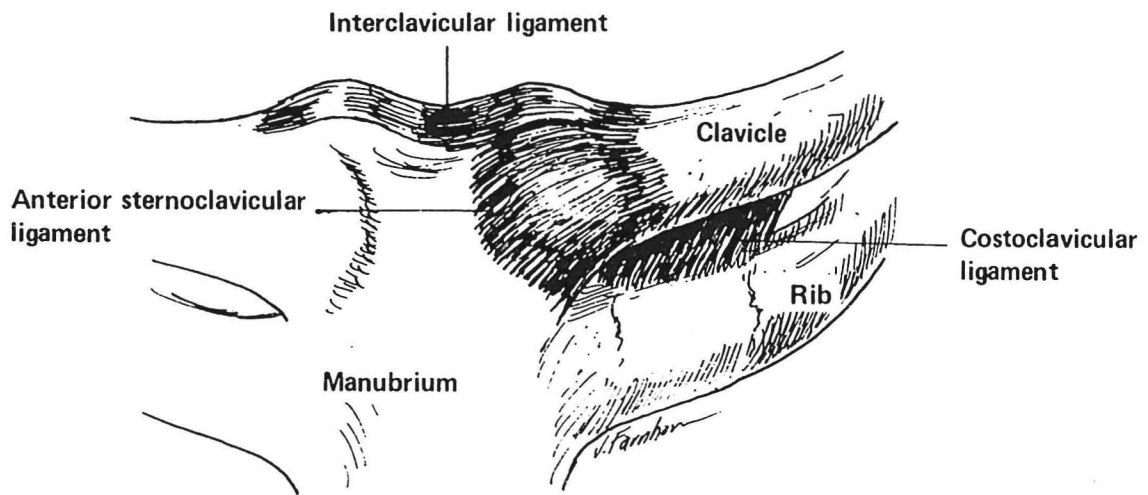
The SC joint depends on the disc, capsule, and three ligaments for stability.

The articular disc is attached to the nonarticular portion of the clavical superiorly and to the sternum and first rib inferiorly. The disc divides the joint cavity into two separate compartments and acts as a hinge or pivot point during motion.^{12,14,15} It functions to increase joint congruence, prevent medial displacement of the clavical, and is an important shock absorber of forces transmitted through the clavical from its lateral end.^{12,14,15} The ligaments of the SC joint include the anterior and posterior SC ligaments, costoclavicular ligament, and interclavicular ligament (Fig 1).

The anterior and posterior SC ligaments function to reinforce the joint capsule and help prevent anterior-posterior movement of the medial end of the clavical.^{12,15} The costoclavicular ligament extends from the inferior surface of the medial end of the clavical to the first rib and adds to the stability of the joint. It serves as a check for clavicular elevation and helps limit clavicular protraction. The interclavicular ligament connects the nonarticular portion of one clavical to the other clavical above the manubrium. It functions to limit downward gliding of the medial end of the clavical which is critical in protecting structures such as the brachial plexus and subclavian artery which pass between the clavical and first rib.^{14,15} The rarity of dislocation and degenerative changes of the SC joint attests to the strength of the supporting soft tissues.

Acromioclavicular Joint. — The AC joint is also a plane, synovial joint with three degrees of freedom. It is an articulation between the lateral end of the clavical and the acromion of the scapula.^{12,14,15} Unlike the SC joint, this joint is susceptible to trauma and

Fig 1. — Sternoclavicular Ligaments



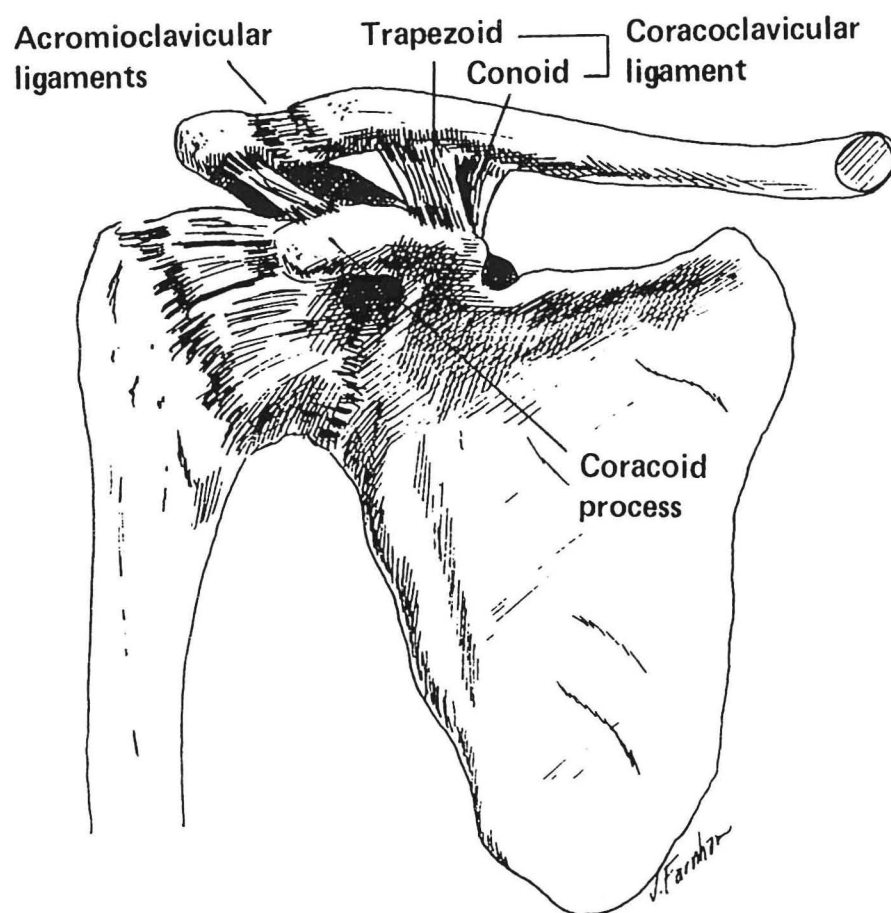
Reprinted with permission from *Joint Structure and Function: A Comprehensive Analysis*.
2nd ed. Philadelphia, Penn: F.A. Davis Co;1989:214.

degenerative changes.¹⁵ The primary function of the AC joint is to maintain the relationship between the clavical and the scapula in the early stages of arm elevation and allow the scapula additional range of rotation on the thorax in the late phase of elevation. The stability of the AC joint depends primarily on its ligaments. The ligaments include the superior and inferior AC ligaments, and the coracoclavicular ligament.(Fig 2)

The superior and inferior AC ligaments function to reinforce the weak joint capsule.¹² The superior portion of the joint is much stronger than the inferior portion because the superior AC ligament is reinforced by fibers of the trapezius and deltoid muscles.¹⁵ The coracoclavicular ligament firmly unites the clavical and the scapula and consists of two portions, the trapezoid and conoid ligaments. The trapezoid ligament runs from the coracoid process upward and laterally to the inferior surface of the clavical and prevents overriding of the clavical on the acromion.¹² It also transmits strong forces away from the weak AC joint through the clavical to the stronger SC joint.¹⁵ The conoid portion runs from the coracoid process upward and slightly posterior to attach to the undersurface of the clavical. During arm elevation, tension in the conoid ligament results in posterior rotation of the clavical about its longitudinal axis allowing for full ROM in arm elevation.¹² Motions at this joint include scapular rotation, tipping and winging.

Two motions that are less commonly described but essential to scapular movement are winging and tipping. Scapular winging is the posterior displacement of the vertebral border of the scapula. This motion is necessary to maintain contact between

Fig 2. — Acromioclavicular Ligaments



Reprinted with permission from Joint Structure and Function: A Comprehensive Analysis. 2nd ed. Philadelphia, Penn: F.A. Davis Co;1989:217.

the concave scapula and the convex thorax as the scapula slides around the thorax during protraction/retraction. Scapular tipping functions in the same way except the inferior angle of the scapula moves posteriorly and the superior angle of the scapula moves anteriorly to maintain contact between the scapula and thorax in elevation/depression and rotation.¹⁵

Glenohumeral Joint. — The GH joint is a synovial ball-and-socket joint with three degrees of freedom. Monoplane motions at the GH joint include flexion/extension, abduction/adduction in the coronal and horizontal planes, and internal/external rotation about its axis. Multiplane motion at the shoulder is called circumduction. Shoulder circumduction is the action of swinging the arm in a manner that represents a cone-shaped figure.¹⁶ The apex of the cone is formed by the proximal shoulder joint and the complete circle is formed by the free distal end of the limb.

The head of the humerus articulates with the glenoid fossa of the scapula. The glenoid fossa is shallow and much smaller than the head of the humerus which creates incongruity between the two joint surfaces causing the joint to be unstable. A rim of fibrocartilage called the glenoid labrum surrounds and attaches to the periphery of the glenoid fossa. It gives the fossa added depth but does not solve the problem of instability. Stability in the GH joint depends primarily on the capsuloligamentous structures and the musculotendinous cuff.^{12,14,15} The musculotendinous cuff includes the supraspinatus, infraspinatus, teres minor, and subscapularis muscles. They will be discussed in the section on muscles of the shoulder.

The glenohumeral joint is surrounded by a large, loose capsule that is taut superiorly and slack anteriorly and inferiorly when the arm is in a dependent position (arm at side). The capsule is twice the size of the humeral head and its laxity allows for large excursions of the joint surfaces. It provides little stability without ligamentous reinforcement.^{14,15} Ligaments of the GH joint include: the glenohumeral ligaments, the coracohumeral ligament, and the coracoacromial ligament. (Fig 3)

The glenohumeral ligaments are thickenings that form a "z" on the anterior part of the capsule. The superior, middle, and inferior glenohumeral ligaments run from the supraglenoid tubercle of the scapula to the lesser tubercle and the anatomical neck of the humerus. The superior GH ligament prevents inferior dislocation of the head of the humerus when it is in an adducted, dependent position. The middle GH ligament acts as an anterior stabilizer and limits external rotation. The inferior GH ligament prevents anterior subluxation and inferior dislocation of the head of the humerus in the upper ranges of elevation.¹⁴ The coracohumeral ligament is a broad band that passes from the lateral side of the base of the coracoid process of the scapula to the anatomical neck of the humerus. It serves to strengthen the superior part of the capsule and passively supports the arm against the force of gravity.^{14,15} The coracoacromial ligament is a strong triangular ligament that prevents superior dislocation of the head of the humerus.¹⁵ This ligament also forms the superior portion of the coracoacromial arch.

The coracoacromial arch is formed by the acromion and coracoid processes of the scapula and the coracoacromial ligament. (Fig 4) The arch serves to protect the top of the humeral head and the subacromial space which contains the rotator cuff tendons, and the

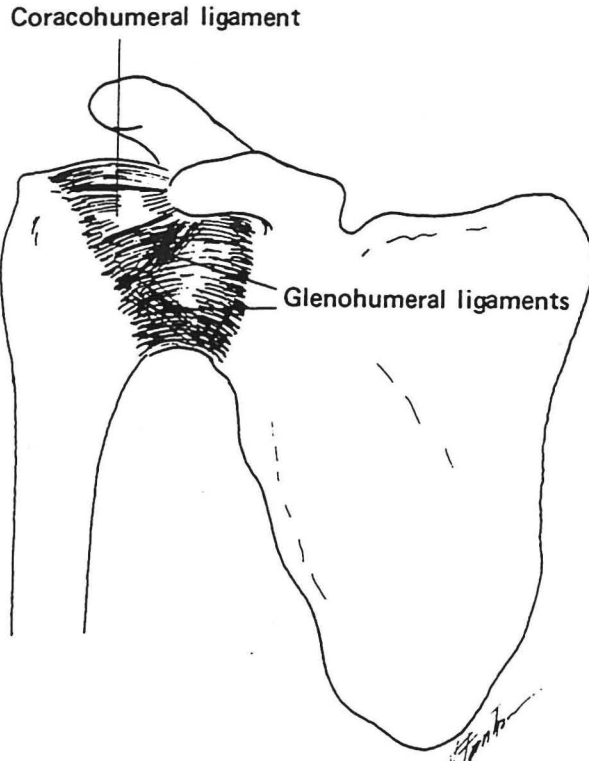


Fig 3. — Glenohumeral Ligaments

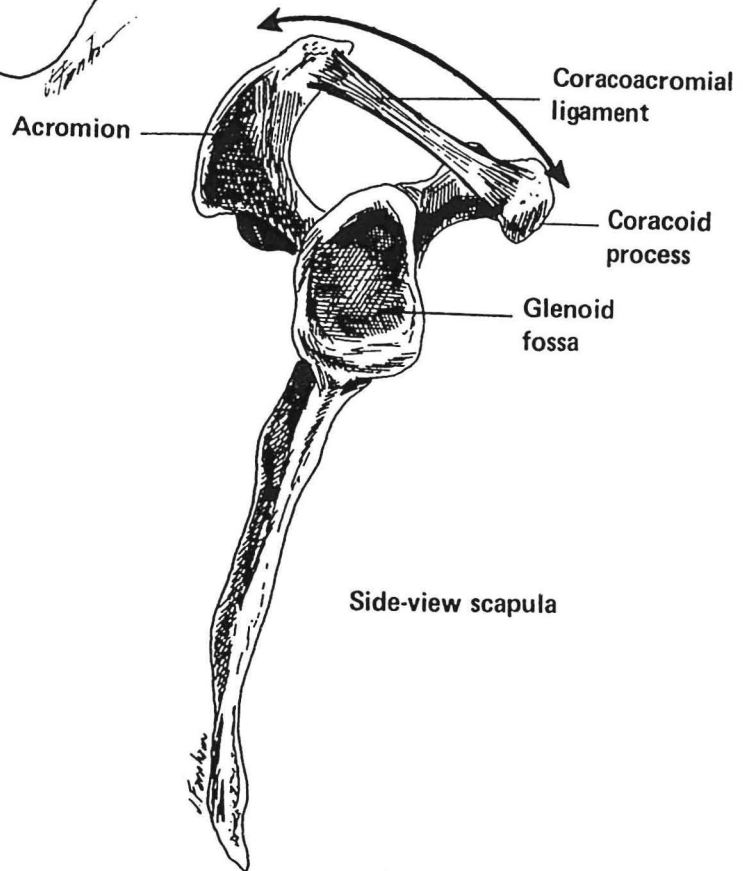


Fig 4. — Coracoacromial Arch

Reprinted with permission from Joint Structure and Function: A Comprehensive Analysis. 2nd ed. Philadelphia, Penn: F.A. Davis Co;1989:220-221.

subacromial bursa from direct trauma.^{1,12,15} A bursa is a synovial membrane found in connective tissue that permits smooth gliding between structures by reducing friction.¹⁶ The subacromial bursa separates the deltoid muscle and the arch superiorly from the rotator cuff inferiorly and protects the integrity of the rotator cuff tendons as they pass under the coracoacromial arch.¹² Interruption or failure of the smooth gliding mechanism causes pain and a loss of GH motion.¹⁴

Scapulothoracic Joint. — The ST joint consists of the articulation between the scapula and the thorax. It does not fit the definition of a synovial joint as there is no union between the two by fibrous, cartilaginous, or synovial tissues. The ST joint is considered a pseudojoint.^{1,15} The scapula's resting position on the posterior thorax is approximately 2 inches from midline, between the second and seventh ribs.^{12,15} "The plane of the scapula is approximately at right angles to the plane of the glenoid. At rest, it lies obliquely between the frontal and sagittal planes, 30-45 degrees anterior to the coronal plane."^{12-p.342} The scapula's concave surface does not directly articulate with the convex thorax. Their surfaces are separated from each other by the subscapularis and serratus anterior muscles. These muscles glide over one another during movement.¹² This articulation is important to the overall motion of the shoulder because the motion and position of the scapula directly affects the movements at the other three joints in the shoulder complex.¹ Stability at this joint is dynamic in nature since the scapula has no bony or ligamentous attachment to the rest of the body other than through the clavical. Scapular muscles including the trapezius, serratus anterior, rhomboid major and minor, and levator scapulae, in addition to atmospheric pressure, provide the scapula with the stability it needs for proper shoulder

function.^{3,12,15} Specific muscle functions will be discussed in the next section. The scapula functions to orient the glenoid fossa for optimal contact with the maneuvering arm, add range to arm elevation, and provide a stable base for the controlled rolling and gliding of the articular surface of the humeral head.¹⁵ Motions occurring at this joint are elevation/depression, protraction/retraction (abduction/adduction), upward/downward rotation, winging, and tipping of the scapula.

Muscles of the Shoulder

As stated previously, the shoulder complex trades stability for mobility. Because it has only one boney connection to the thorax, it is strongly dependent on ligaments, muscles, and the shape of the glenoid fossa for its stability. This section will concentrate on the muscles of the shoulder complex including the rotator cuff and the muscles that stabilize the scapula.

Rotator Cuff. — The Rotator Cuff muscles consist of the supraspinatus, infraspinatus, and teres minor posteriorly, and the subscapularis anteriorly. The tendons of these four muscles blend with the articular capsule of the GH joint and insert on the greater tuberosity, the intertubercular groove, and lesser tuberosity of the humerus respectively.^{3,14,17} The muscles provide a dynamic element to stability by resisting anterior/posterior and superior/inferior translation of the humeral head during arm movements. They move the joint into a position that tightens the capsuloligamentous structures adding to the stability of the joint. The rotator cuff muscles take part in additional actions about the shoulder complex. These actions include depression of the

head of the humerus, external rotation, internal rotation and abduction of the humerus, and stabilizing the arm against the force of gravity.

The subscapularis, teres minor, and infraspinatus function to depress the humeral head which prevents its superior impaction into the acromion during elevation.^{1,14,15} The infraspinatus and teres minor externally rotate the humerus during arm elevation which is necessary to prevent the greater tuberosity from impacting the acromion. The subscapularis internally rotates the shoulder, while the supraspinatus muscle assists the deltoid in abduction and helps stabilize the glenohumeral joint against the force of gravity.

Scapular Muscles. — The muscles that control the scapula and its motion are essential to the overall coordinated movement of the shoulder complex. Their proper function is vital to the normal biomechanics of the shoulder.¹ These muscles are the serratus anterior, trapezius, levator scapulae, rhomboid major and minor, latissimus dorsi, and pectoralis minor. The serratus anterior originates on the first eight ribs and inserts along the medial aspect of the scapula. The primary role of the serratus is to stabilize the scapula during elevation and assist in protraction.^{14,15,18} With decreased or absent function of the serratus anterior, winging of the scapula will occur resulting in instability.¹⁸ The trapezius originates on the medial third of the superior nuchal line, external occipital protuberance, ligamentum nuchae, and spinous processes of C7-T12 vertebrae. It inserts on the lateral third of the clavical, acromion, and the spine of the scapula. The upper fibers elevate the scapula, the middle fibers retract the scapula, and the inferior fibers depress the scapula. The superior and inferior fibers also act together to upwardly rotate the scapula.

Rhomboid major and minor originate on the spinous processes of C7-T5 vertebrae and insert onto the medial border of the scapula.^{14,15,18} They stabilize the medial border of the scapula and are very active in retraction. The levator scapulae originates on the posterior tubercles of the transverse processes of C1-C4. It inserts on the superior point of the scapula from the level of the spine to the superior angle. It functions to elevate the scapula. The latissimus dorsi originates on the spinous processes of the inferior six thoracic vertebrae, thoracolumbar fascia, iliac crest, the inferior 3 or 4 ribs, and the inferior angle of the scapula. It inserts onto the floor of the intertubercular groove of the humerus. It functions to extend, adduct, and internally rotate the humerus, it depresses and downwardly rotates the scapula, and it also raises the body towards the arms during climbing. The pectoralis minor originates on ribs 3-5 and inserts onto the coracoid process of the scapula. It stabilizes the scapula by drawing it anteriorly and inferiorly against the thorax.¹⁴ Tables 1 and 2 summarize the actions of the shoulder complex and the muscles that perform those actions. Excluding the four rotator cuff muscles, there are six other muscles that attach to the scapula adding stability and mobility to the ST joint. The muscles include: coracobrachialis, deltoid, teres major, biceps, long head of the triceps, and the omohyoid. These muscles are beyond the scope of this paper and will not be discussed in further detail.

Role of the Scapula

The scapula plays several roles both anatomically and physiologically. It is a site of muscular attachment and provides a stable base for humeral articulation. Through

Table 1. Muscles Involved in Scapular Motion

ACTION	MUSCLES
Scapular Elevation	Trapezius (upper fibers) Levator Scapulae Rhomboid Major and Minor
Scapular Depression	Trapezius (lower fibers) Pectoralis Major and Minor Latissimus Dorsi
Scapular Abduction	Serratus Anterior Pectoralis Major and Minor
Scapular Adduction	Trapezius (all fibers) Rhomboid Major and Minor
Scapular Upward Rotation	Serratus Anterior Trapezius (upper and lower fibers)
Scapular Downward Rotation	Levator Scapulae Rhomboid Major and Minor Latissimus Dorsi Pectoralis Major and Minor

Table 2. Muscles Involved in Shoulder Motion

ACTION	MUSCLES
Shoulder Flexion	Deltoid (anterior fibers) Coracobrachialis
Shoulder Extension	Latissimus Dorsi Teres Major Deltoid (posterior fibers)
Shoulder Abduction	Deltoid Supraspinatus
Shoulder Adduction	Latissimus Dorsi Pectoralis Major Teres Major
Shoulder External Rotation	Infraspinatus Teres Minor Deltoid (posterior fibers)
Shoulder Internal Rotation	Pectoralis Major Latissimus Dorsi Teres Major Subscapularis
Stability of the glenohumeral joint	Rotator Cuff Muscles

proper rotation, the scapula also allows the acromion to elevate and has the mobility to accompany GH motion.^{3,11} Each of these topics will be discussed further in the following section.

Many muscles that affect shoulder function in normal activity originate or attach to the scapula. In order for these muscles to function properly, the scapula must serve as a firm anchor.^{3,11,12,15} Because the scapula is not firmly attached to the thorax through bony structures it must rely on scapular muscles such as the trapezius, serratus anterior, levator scapulae, and the rhomboid major and minor for stability. If stability is not achieved, muscles acting on the scapula will not have a proper length-tension relationship.^{3,11} Muscles acting on the scapula have a certain length where they have the greatest mechanical advantage and create the most force. If the scapula is allowed excessive movement, this optimal length changes and decreases the efficiency of the muscles which causes alterations in the function of the shoulder complex.

The scapula must also provide proper alignment of the glenoid fossa for optimal articulation between it and the head of the humerus. During movement of the limb, the scapula must position itself so the glenoid fossa stays in line with the head of the humerus as closely as possible through full ROM.^{11,15} If this does not occur, the GH joint which is already unstable, will become even more unstable.

A key contributing factor to functional movement of the shoulder is elevation of the arm.³ In elevation, the acromion must elevate to keep the rotator cuff from impinging under the coracoacromial arch.¹¹ This is achieved by upward rotation of the scapula as it

follows the head of the humerus during elevation facilitating congruency of the GH joint and providing maximal stability.³

It has been stated by Stephen Guffy¹¹ and many other researchers that the scapula needs stability through its muscular stabilizers. It is also necessary for the scapula to have freedom to move. Protraction and retraction are an example of motions that require scapular mobility. Guffy explains this in his seminar titled Rehabilitating Shoulder Dysfunction: The importance of Scapular Stabilization. He describes the need for scapular mobility in protraction/retraction by describing the shoulder motion of an overhead throwing athlete.

In the first phase of throwing, the arm is brought into an abducted, externally rotated, and elevated position. This position is called the cocked arm position and requires maximal scapular retraction.¹¹ In the second phase of throwing, the arm accelerates forward and follows through. To keep the glenoid fossa in proper position in relation to the head of the humerus, full protraction of the scapula is necessary. It is important to emphasize that the scapula moves from a maximally retracted position to a fully protracted position during the throwing motion. While, not everyone is an overhead throwing athlete, the same forces occur to a lesser degree in activities of daily living (ADL). ADL's are repetitive in nature and added together become problematic over time by causing similar stress loads as seen in the throwing athlete. Along with the importance of scapular stabilization, the joints of the shoulder complex need to work as a single unit for proper motion to occur. This will be discussed in the next section.

Scapulohumeral Rhythm

The glenohumeral, scapulothoracic, acromioclavicular, and sternoclavicular joints must participate in shoulder movement in a coordinated, smooth pattern to achieve the greatest range of motion possible for the upper extremity. The integrated movement of these four joints is termed scapulohumeral rhythm (SHR).^{1,12,15}

Scapulohumeral rhythm serves three purposes. First, the distribution of motion between the GH and ST joints maintains the glenoid fossa in an optimal position to receive the articular surface of the humeral head during arm movements. This increases joint congruency while decreasing shear forces. Secondly, it permits the muscles acting on the humerus to maintain an optimum length-tension relationship which minimizes insufficiency of the GH muscles. Lastly, SHR allows a large amount of motion without compromising stability due to the fact that the motion comes from two joints instead of one.^{1,15} SHR is the result of movement at four joints occurring simultaneously. In this discussion SHR will be divided into GH/ST and SC/AC contributions. This division into two groups was also used by Kamkar et al¹ in their clinical commentary on nonoperative management of secondary shoulder impingement syndrome.

GH/ST contribution. — Full elevation of the upper extremity is 180° in a healthy, normal individual. The GH joint contributes 120° of this motion and the ST joint adds the other 60°.^{1,12,15} The first portion of arm elevation is termed the “setting phase.”^{1,12,15} Researchers agree that most of the motion occurring in this phase comes from the GH joint. The motion at the ST joint is inconsistent early in elevation because the scapula is

seeking a position of stability in relation to the humerus. What researchers disagree on is how much arm elevation is included in the setting phase. Numbers vary from 0-60° to 30-60°, but what is consistent is the fact that the setting phase occurs before 60° of arm elevation.^{1,13} Following the setting phase, the ST joint contribution equals that of the GH until the end ranges of arm elevation, where the GH contribution once again increases. The overall ratio of GH motion to ST motion is 2:1.

SC/AC contribution. — Motion at the ST joint inevitably produces motion at the SC/AC joints because of their involvement in a closed kinematic chain. In a closed kinetic system, movement at one joint produces predictable movements at all other joints.¹⁰ The 60° of arm elevation contributed by the ST joint is a result of movement at both the SC and AC joints. This movement is brought about through a force couple of the serratus anterior and the upper and lower portions of the trapezius. A force couple is the action of two or more forces acting in opposite directions to improve rotation about an axis. The function of the serratus/trapezius force couple is to achieve smooth arm elevation without causing impingement of inert structures and the rotator cuff tendons between the humeral head and the coracoacromial arch.³

As arm elevation occurs, the trapezius and serratus work together to upwardly rotate the scapula. However, the upward rotation is limited at the AC joint by the coracoclavicular ligament. The ligament becomes taut causing elevation of the clavical to occur at the SC joint.^{1,12,15} This occurs for the first 30° of scapular rotation, after which the costoclavicular ligament tightens and inhibits further clavicular elevation. At this

point, the serratus and trapezius continue to attempt further upward rotation of the scapula. Since the movement of the clavical stops but the forces from the serratus anterior and trapezius muscles do not, there is increased tension placed on the coracoclavicular ligament. The increased tension causes the clavical to rotate posteriorly around its longitudinal axis. The rotation will flip the lateral end of the crank-shaped clavical allowing an additional 30° of upward rotation without causing further elevation at the SC joint.

It is clear that disruption of motion in any of the four joints may affect the total motion produced by the shoulder complex. The disruption results in imbalance, weakness, or dysfunction of the force couple between the serratus and trapezius muscles which is an important contribution to shoulder motion. Once restrictions to functions are introduced, the ratio of 2:1 GH to ST movement is no longer pertinent.

Normal structure and function of the four joints of the shoulder, their muscles, capsules, and ligaments have been described. The importance of the scapula in proper shoulder functioning was also detailed. The next chapter will discuss the role of traumatic injuries and degenerative processes involved in the etiology of rotator cuff pathology.

CHAPTER III

ETIOLOGY

The chief causative factors of rotator cuff disease have been narrowed into two categories: traumatic injury and degenerative changes.^{3,5,6} These categories are important to understanding the etiology of rotator cuff disease and both will be discussed in this chapter.⁵

Traumatic Injury

Traumatic injury of the rotator cuff most often results from a lateral blow to the shoulder. It can occur when a person falls or is injured in a sport or in an automobile accident. Most tears are believed to be caused by a direct shoulder injury.⁶ Although trauma accounts for many rotator cuff tears, further discussion of this issue is not necessary due to the simplistic nature of the event. Researchers are more interested in the topic of degeneration and its effect on the rotator cuff. Since the questions lie within degenerative processes, traumatic injury will not be covered further in this chapter.

Degenerative Processes

In the 1930's, McMaster provided experimental evidence that supported the notion that normal rotator cuff tendons do not tear.³ This has also been supported in recent studies conducted by Codman¹⁹ and McLaughlin.²⁰ The idea that normal tendons do not tear brings up the issue of degeneration and its role in rotator cuff pathology. With the shoulder inherently unstable, coordination and balance between the four joints of the

shoulder complex and their muscles, capsules, and ligaments are necessary for smooth, uninhibited motion. Alterations in any of these structures can cause degeneration and eventually lead to rotator cuff disease. Processes that can lead to rotator cuff degeneration include: decreased vascularity, age, repetitive trauma, shape of the acromion, scapular instability, and weak muscles of the shoulder complex.

Vascularity. — The vascularity of the rotator cuff tendon has been studied extensively in recent years.³ There is a portion of the supraspinatus tendon that has compromised vascularity with the arm in a dependent position.^{3,7,14,15} This avascular area is called the critical zone and is located approximately one centimeter medial to the insertion of the cuff tendon.⁷ Nevaizer⁷ reported that this area of decreased vascularity is also the location of most rotator cuff tears and tendon degeneration. Studies conducted by Rathbun and Macnab²¹ and Rothman and Parke²² also support this concept. Although no direct cause-effect relationship has been proven scientifically at this point, there seems to be an anatomic relationship between the critical zone, where the tendon consistently ruptures and degenerates, and the vascular changes noted by researchers.⁷ To support the notion that a decrease in blood supply to a tendon may cause early degeneration, research by Rathbun and Macnab²¹ indicates the biceps tendon has been found to be avascular as it enters the intertubercular groove of the humerus. Degenerative changes of the tendon preceding rupture have also been found in this area of avascularity.

Aging. — An increase in frequency of rotator cuff tears had been associated with an increase in age.^{3,7} This may be attributed to nutritional changes in tendons that take

place as a normal process during aging. Daily wear and tear on the shoulder complex can no longer be balanced by the bodies intrinsic repair processes. It is likely that age in combination with other factors determines the integrity of the rotator cuff.

Repetitive Trauma. — Repeated stressful use of the arm in the overhead position seems to be particularly demanding and can lead to breakdown of the muscles, capsule, or articular surfaces of the shoulder.^{3,7} This repetitive activity resulting from occupational or athletic activities causes early degenerative changes within the shoulder and may lead to rotator cuff tearing.

Shape of Acromion. — Many studies have been done on the shape of the acromion and incidence of rotator cuff tears. There are three different acromion shapes as noted in the literature.^{3,6,9,15} In type I, the under surface of the acromion is flat, type II is curved, and in type III it is hooked. Bigliani et al³ found the incidence of rotator cuff tears to be higher in individuals with a type III acromion. In a follow up study conducted by the same authors, 80% of rotator cuff tears occurred in patients with type III acromions.

Scapular Instability. — The scapula provides a stable base from which GH mobility occurs.¹⁸ Stability at the ST joint depends upon its surrounding muscles. "When weakness is present in the scapular musculature, normal scapular positioning and mechanics may become altered"^{3-P.12} Without adequate muscle strength, the scapula is more free to move. Excessive movement alters the optimal plane of motion of the scapula. With altered scapular positioning, the glenoid fossa is no longer congruent with the head of the humerus and the length-tension relationship of the muscles change

causing them to be less efficient. This causes maximal stress to be placed on the tendons and capsuloligamentous structures of the shoulder complex.^{3,18} Scapular stability is absolutely required for proper shoulder mechanics.¹¹

Muscular weakness. — Muscular weakness causing shoulder problems occurs in two areas: the scapular stabilizers and the muscles of the rotator cuff. Since the function of the scapular stabilizers were covered in the section on scapular instability this discussion will concentrate on the muscles of the rotator cuff. The rotator cuff functions to stabilize the shoulder against actions of the deltoid while adding power during glenohumeral rotation and elevation.³ If any one of the cuff muscles becomes weak, it deprives the shoulder of its normal humeral head depression which counterbalances the upward pull of the deltoid in arm elevation. Without the proper rotator cuff mechanism, impingement of inert tissues and the rotator cuff tendons between the coracoacromial arch and the head of the humerus may occur. Pain and early degeneration of the structures involved could result.^{1,3}

In addition to all of the factors mentioned above, any change associated with a decrease in the space between the head of the humerus , rotator cuff, and coracoacromial arch may contribute to rotator cuff impingement. Impingement can lead to edema, inflammation, and bursitis and progress to rotator cuff degeneration and eventually rotator cuff tearing.⁶ Some of these "changes" that will decrease the subacromial space include: AC enlargement, prominence of the greater tuberosity, acromial slope, thickened coracoacromial ligament, and the shape of the acromion which was previously

discussed. Each has been cited as causing rotator cuff injury and attrition but will not be discussed in further detail.

The shoulder is an unstable joint. It depends on coordination of four joints and their muscles, ligaments, and capsules for stability. Alteration of any of these components results in changing normal shoulder biomechanics. With the knowledge of processes that can alter the function of the shoulder complex, the next chapter will discuss differential diagnosis between shoulder bursitis, tendinitis, rotator cuff tears, and the role they play in impingement.

CHAPTER IV

DIFFERENTIAL DIAGNOSIS

The anatomy of the shoulder complex including its four joints, their muscles, ligaments, and capsules has been detailed. The importance of the scapula and its function in scapulohumeral rhythm illustrates how the structures of the shoulder work together to attain smooth, coordinated movements necessary for proper shoulder function. In the previous chapter, the role of trauma and degeneration in the development of rotator cuff pathology was explained. The next step in this review of the rotator cuff and shoulder function is differential diagnosis. Once deficits in shoulder function exist, it is necessary to evaluate and pinpoint the causative structure(s). In the shoulder, it is important to decipher between bursitis, tendinitis, their role in impingement, and finally rotator cuff tears. This chapter will focus on the above conditions, their signs and symptoms, presentation on examination, and physical therapy management of each condition.

Bursitis

Bursitis is an inflammation of a bursa.¹⁶ The bursa in the shoulder is called the subacromial bursa. It extends between the deltoid and the tendons of the rotator cuff.^{9,12} It functions to reduce friction in the subacromial space during arm movement.^{9,15} Pain caused directly by the bursa is rare. Shoulder pain is more often associated with rotator

cuff or biceps tendon irritation or tendinitis.⁹ Although rare, bursa pain can be evident in conditions such as rheumatoid arthritis, tuberculosis, gout, pyogenic infections, and in direct trauma of the shoulder. Bursitis can be classified as either acute or chronic.^{9,23} Acute bursitis is described as having an abrupt onset with extreme pain. Persons will have difficulty with active or passive arm elevation. Chronic bursitis is almost always associated with tendinitis. It presents with a nagging, aching pain at the insertion of the deltoid on the lateral aspect of the arm. This pain often awakens a person at night. On palpation, tenderness is noted but is diffuse. The person will present with a painful arc between 70-120° of arm elevation. Resisted movements are usually painfree. The Neer's Impingement Sign may be positive. Table 3 describes special tests of the shoulder and their positive findings.

Management of bursitis is relatively simple. Rest and avoidance of overhead activities is the number one priority in treatment. Physical Therapy can be initiated to maintain PROM and increase AROM in the painfree range. Modalities can be used to decrease pain and swelling. The goal in bursitis management is to regain painfree ROM, strength, and function.⁹ It is also important to instruct the patient on activity modification to avoid reaggravation or further injury.^{9,23} Surgery may be indicated for severe cases of bursitis. Debridement of the bursa and excision of the coracoacromial ligament would be performed followed by therapy to regain ROM and strength.⁹

Tendinitis

Tendinitis is an inflammation of a tendon or tendons.¹⁶ In the shoulder, it is most commonly seen in the supraspinatus, infraspinatus, and biceps tendons.^{9,23} The causes of

Table 3. Special Tests of the Shoulder

TEST	INSTRUCTIONS	POSITIVE TEST	INDICATION
Drop Arm	Abduct patients arm and have patient slowly lower it to their side	Pain or inability to perform action slowly	Rotator cuff tear
Speeds	Patients arm is extended and supinated. Resist flexion	Pain and/or weakness	Bicipital tendinitis
Supraspinatus	Patients arm is abducted to 90° with no rotation, resist. Medially rotate arm so thumb is pointing towards the floor and angle arms forward 30° and resist	Pain and/or weakness	Supraspinatus tear
Lippman	Flex arm to 90°, palpate the biceps tendon 7-8 centimeters below the glenohumeral joint moving the tendon from side to side	Sharp pain	Bicipital tendinitis
Yergason's	Patients arm is at their side, elbow flexed to 90°, forearm pronated. Resist supination and lateral rotation	Pain and/or weakness	Bicipital tendinitis
Neer's Impingement Sign	Medially rotate arm and elevate it forcibly through flexion	Pain	Identifies inflammation of tissues within subacromial space
Kennedy-Hawkins Impingement Sign	Flex arm to 90° and internally rotate it	Pain	Identifies inflammation of tissues within the subacromial space

tendinitis are many. In the younger population, tendinitis is brought about through repetitive overuse seen in the overhead athlete. In the older population, degenerative lesions initiated by decreased vascularity, calcifications, and a decrease in the ability of the body to heal itself are the main cause of tendinitis. The supraspinatus tendon is the most common site in the shoulder for tendinitis.⁹

Tendinitis can also be classified as either acute or chronic.²³ Acute tendinitis involves extensive shoulder pain which results in a loss of sleep. Chronic tendinitis is represented by low-grade irritation occurring with certain movements. More people suffer from chronic tendinitis and therefore it will be the focus of this discussion. Usually the patient's history does not include a specific incident that can be directly related to an injury. In addition, he/she may participate in overhead activities as a part of their occupation or sport.⁹ Symptoms include complaints of a low-grade ache and increased fatigue in the area of the deltoid insertion, an inability to sleep on involved side, and there may be a catching sensation with arm flexion or internal rotation.

Physical examination will show the patient to have pain with active abduction and external rotation in the form of a painful arc between 70-120°.^{9,23} PROM will be full and painless but on occasion internal rotation and abduction will present as limited and painful. Resisted isometrics will show weakness due to pain, and resisted elbow movements may also be painful if the biceps tendon is involved in shoulder tendinitis. Palpation of the involved structures will elicit tenderness and in addition, inflammation may be present. Special tests including Neer's and Hawkins-Kennedy impingement signs

will be positive. The Speeds, Yergason's, and Lippman's tests may or may not be positive depending on involvement of the biceps tendon.

Conservative management of tendinitis should always be attempted. Only if it fails would surgery be indicated. As in bursitis management, rest and avoiding overhead activities is a priority. Nonsteroidal anti-inflammatory drugs (NSAIDS) can be administered to help with inflammation and pain as can therapeutic modalities. If the anti-inflammatory medications do not work, corticosteroid injections may be considered.⁹ It is important to use these injections with caution because of their tendency to promote degeneration in living tissue. ROM activities should be initiated and cross-fiber friction massage to the involved tendon(s) can be performed to maintain mobility and to promote healing.²³ Scapulothoracic mobilizations can also be performed if added mobility is needed. When ROM is normal, strength exercises utilizing high-repetitions with low resistance is indicated to re-establish endurance and proper muscular rhythm.²⁴ Eccentric exercises should be incorporated because they are very important in the strength program for tendinitis. Deficits in eccentric force production may be partially responsible for tendinitis and therefore is an important consideration in rehabilitation of the shoulder.⁹ Although rare, if conservative treatment fails, surgical techniques such as acromioplasty, bursectomy, or coracoacromial ligament excision can be performed to provide an increase in the subacromial space.

Impingement

Impingement is a generic term including a spectrum of rotator cuff changes ranging from edema and hemorrhage of the cuff during early stages to tendon degeneration, bony changes, and tendon ruptures in later stages.⁶ Due to the proximity of the tendon of the long head of the biceps and the subacromial bursa, they are usually affected to some extent by rotator cuff changes.

Neer describes three stages of impingement. These stages show specific involvement of the rotator cuff, inflammation, and other signs and symptoms. Stage I affects primarily younger individuals, usually less than 25 years of age.^{3,6} Physical signs include those associated with bursitis and tendinitis. The changes are reversible with rest and medication. Stage II occurs mainly in patients 25-40 years old. Patients suffer from chronic tendinitis which turns to rotator cuff fibrosis, thickening, and partial cuff tearing. Symptoms including constant shoulder aching, discomfort, and night pain are similar to those signs in stage I but are more marked and associated with shoulder stiffness.⁶ Stage III affects people over 40 years of age with a long history of shoulder pain.^{3,6} This stage includes full thickness tendon tears, bony changes, and tendon rupture. Activities of daily living (ADL's) are usually affected and PROM of the shoulder is usually greater than AROM. Neer's and Hawkins-Kennedy impingement signs will usually be positive. Depending on the stage of impingement, any of the special tests for supraspinatus or bicipital tendinitis may also be positive.^{9,25}

Rotator Cuff Tears

Disorders of the rotator cuff may be classified under Neer's three stages of progressive degeneration. Stages I and II were detailed in the above sections on impingement. This section will deal with rotator cuff disease in stage III, including classification, signs and symptoms, and physical evaluation. The treatment of rotator cuff tears will be deferred until chapter V where conservative and surgical treatment will be discussed in great detail.

The majority of rotator cuff tears occur in the supraspinatus tendon.^{3,6,9} Because of its anatomic position, it is susceptible to impingement against the coracoacromial arch.⁹ This factor added to its proven avascularity and its tendency for degeneration explains the reasons why tears are noted mostly at this location.^{3,9,12} As noted in chapter 3, excluding tears produced through direct trauma, rotator cuff tears are a result of degenerative processes. There are many factors that contribute to the degenerative process. With this in mind, consider the function of the rotator cuff tendons and the high demands placed on them in upper extremity movement. It is important to note the increased incidence of failure of these tendons and appreciate their significance to the normal function of the shoulder complex.

Rotator cuff tears are usually classified according to tear thickness and etiology.⁹ Classification terms include partial or full thickness tears caused by a traumatic injury or degenerative process. A partial thickness tear includes lesions involving only the superficial surface, midsubstance, or articular surface of a tendon. A full thickness tear extends from the articular surface through to the bursal surface of a tendon. Rotator cuff

tears can also be described according to their size. Measuring the longest diameter, a small tear is less than 1 centimeter, a medium-sized tear is less than 3 centimeters, a large tear is less than 5 centimeters, and a massive tear is greater than 5 centimeters.

Classification of rotator cuff tears is an important tool that physicians use to determine the severity of the tear and the planned course of treatment. The physical therapist may use the classification as information about the injury but must rely on the patient and the signs and symptoms he/she presents with for proper treatment.

The patient will report a persistent pain in the shoulder occurring after a specific event.⁹ Even people suffering from degenerative changes within the shoulder joint will be able to relate to an event that made the condition intolerable. Pain is usually located on the lateral aspect of the arm near the tendon of the long head of the biceps. The pain rarely progresses below the elbow and often presents itself at night which makes sleeping on the involved side uncomfortable. Symptoms of shoulder weakness and fatigue during ADL's may be reported.

On examination, the rotator cuff muscles may or may not demonstrate atrophy and tenderness may be present over the tuberosities and bicipital groove when palpated.^{6,9} The AC joint may be more prominent and tender and a full thickness tear may be palpated through the deltoid. PROM will test greater than AROM and a painful arc between 70-120° may be present. Strength should be tested but may be difficult due to pain. If external rotation demonstrates significant weakness, a rotator cuff tear should be suspected.^{3,6} Positive special tests include the drop arm test, the Neer impingement sign, and the supraspinatus test.^{3,6,9,25} To clarify whether weakness is due to pain or a cuff tear,

a physician can perform an impingement test after injecting Lidocaine into the subacromial space of the shoulder to reduce or eliminate pain.^{3,6,9} If there is no apparent weakness after the injection, it is concluded that the weakness was due to pain. If weakness persists, a rotator cuff tear is suspected.

The evaluative findings for a rotator cuff tear have been presented. Table 4a and 4b differentiate between these signs and symptoms and those of bursitis, tendinitis, and impingement. The next step is to determine the rehabilitation path that is right for the individual patient. Chapter V will discuss both conservative and surgical treatment programs for the rehabilitation of a rotator cuff tear.

Table 4a. Differential Diagnosis

	Palpation	Painful Arc	ROM	Resisted Movements	Impingement Sign
Bursitis	Tender, may have thickening of the bursa.	YES	A = P in acute. A < P in chronic	Painfree	Positive
Tendinitis	Involved structures will be tender and may be inflamed.	YES	A < P	Weak due to pain	Positive
Rotator Cuff Tear	Tenderness over tuberosities and possibly bicipital groove. Atrophy may be present.	YES	A = P or A < P depending on size of the tear	Small tear may be strong with minimal pain. Large tear weak and painful.	Positive
Impingement	Depending on what structures are involved, may have any of the above findings.	YES	A < P	Could see weakness and pain. Intensity depends on length of impingement.	Positive

A = Active, P = Passive

Table 4b. Differential Diagnosis

	Speeds	Drop Arm	Supraspinatus	Yergason's & Lippman	Hawkins-Kennedy Impingement Sign
Bursitis	Negative	Acute = Positive Chronic = Negative	Negative	Negative	Negative
Tendinitis	May be positive if in biceps tendon	Negative	May be positive with supraspinatus involvement	Positive with biceps tendon involvement	Positive for supraspinatus involvement
Rotator Cuff Tear	Negative	Positive	Positive	Negative	Negative
Impingement	Negative. May be positive in stage II Impingement involving bicipital tendinitis	Negative. May be positive in stage III Impingement involving a rotator cuff tear	Negative. May be positive in stage II Impingement involving supraspinatus tendinitis	Negative. May be positive in stage II Impingement involving bicipital tendinitis	Positive

CHAPTER V

REHABILITATION OF ROTATOR CUFF TEARS

Once a rotator cuff tear is diagnosed, the next step is to evaluate which treatment approach will best fit the individual and his/her needs. Two options exist: conservative management and surgical repair of the rotator cuff. Before making a decision whether to treat conservatively or through surgical intervention, the patient's age, physical activity level, demands to be placed on the affected shoulder, and the natural history of the patient's diagnosed condition must be taken into account.⁶ Most tears are managed conservatively but full thickness tears usually require surgical repair to decrease pain and improve upper extremity function.²³

For ease of understanding, it is best to separate the treatment of a rotator cuff tear into separate phases when describing its rehabilitation. Time frames for each phase are beyond the scope of this paper because the length of each phase depends on physician restrictions, severity of the cuff tear, patient tolerance to and compliance with the treatment program, and whether or not surgery was performed.^{3,10,26} Before the treatment program for rotator cuff tears is detailed, some fundamental information about muscles must be discussed.

To understand the progression of strength exercises throughout the course of the rehabilitation of rotator cuff tears, it is important to know the different types of muscle

contractions and their involvement in exercise. There are three types of muscle contractions: isometric, concentric, and eccentric.²⁷ An isometric contraction is defined as a muscle contraction where the length of the muscle does not change but tension is developed. A concentric contraction involves the muscle shortening under a constant load or tension.^{16,27} In an eccentric contraction, the muscle lengthens due to the resistance overcoming the force being produced and can develop more tension than either isometric or concentric contractions.¹⁰

These muscle contractions can be illustrated using a pull-up exercise. When a person grabs an overhead bar and pulls his/her body up to the bar, the shoulder and elbow musculature are concentrically contracting to perform the movement. The muscles are shortening under a constant load (weight). If he/she pulls up to the bar and stops, at the point of the pause, the muscles are no longer changing length. They do, however, continue to contract isometrically. Then, if the person slowly lowers his/her body down from the bar, the muscles lengthen causing the contraction to become eccentric in nature. These three types of contractions are used in a variety of ways during strengthening activities and all have their place in rehabilitation.

Conservative and post-surgical rehabilitation of rotator cuff tears have some differences. Typically, tears requiring surgery tend to lag 4-6 weeks behind tears managed conservatively for several reasons.¹⁰ First, there is extra soft tissue healing from the surgery. Secondly, physicians immobilize the shoulder to allow adequate tendon-bone healing after surgery. Length of immobilization varies from physician to physician

but literature states it may extend anywhere from 4-6 weeks post-operatively. Lastly, restrictions on active abduction and flexion lasting up to 6 weeks post-operatively slow the rehabilitation process.

Excluding time frames, conservative and post-surgical rehabilitation of rotator cuff tears can be discussed together in a 4 phased treatment approach.^{3,10,26} Phase I emphasizes controlling pain and inflammation, achieving near full ROM, and initiating of flexibility and strengthening exercises. Phase II focuses on full ROM and upper extremity flexibility and progressing strength exercises to shoulder level. Phase III emphasizes advanced strengthening, and functional and plyometric activities. Phase IV focuses on gradual return to prior functional levels of activity. The following sections will further detail each phase including the goals and the treatment used to meet those goals.

Phase I

The goals of this phase are 1) to reduce pain and inflammation, 2) to regain near full ROM, and 3) to initiate strengthening exercises to decrease muscle atrophy.^{3,23,26} Pain and inflammation can be decreased through the use of modalities such as ultrasound, heat, cold, and electrical stimulation. Anti-inflammatory medications and decreasing activities that aggravate the condition will also help to control pain and inflammation.^{6,23,26} ROM exercises can be initiated to regain motion lost due to pain caused by a rotator cuff tear.⁶

Passive range of motion (PROM), active assistive range of motion (AAROM) with a wand, pulley system, or finger ladder, and Codman's pendulum exercises can all be used to regain ROM.^{3,10,23} The pendulum exercises are performed passively with the patients body providing the momentum to swing the arm into flexion/extension, horizontal

abduction/adduction, and circumduction. A weight can be placed in the hand to increase the exercise intensity.¹⁰ Mobilization techniques and passive stretching may be necessary to improve joint play and flexibility.^{3,26} It is also important to remember ROM and strength activities for the elbow, wrist, and fingers of the involved upper extremity as they can be affected with stiffness and edema due to decreased use of the shoulder.

Isometric strengthening exercises for the rotator cuff and scapulothoracic musculature are initiated to facilitate stabilization of the shoulder complex. The exercises involve manual resistance from the therapist and the exercises should be performed at multiple angles.³ Research has shown that strength gains are made plus or minus 20° on either side of the angle at which the exercises occurred. Therefore, performing isometric exercises at multiple angles ensures strength gains throughout the full ROM.²⁸ External and internal rotation are very important and should be performed with the arm at the side and the elbow flexed to 90°.^{4,10,26} To progress to concentric exercise, theraband or theratube can be used for resistance. The UBE can be utilized early in rehabilitation as it promotes ROM, shoulder endurance, and increases blood supply to the healing tissues of the shoulder.^{3,10,26} The patients should begin with short duration and low intensity programs and progress as patient tolerance increases. It is important in this phase to decrease irritating activities which will allow the shoulder to heal properly.³

Phase II

The goals in phase II concentrate on attaining full painfree ROM and flexibility of the shoulder, and improving strength and endurance of the rotator cuff and other muscles acting about the scapula.³ ROM and flexibility exercises are continued as described in

Phase I. Using ice after exercise is emphasized but the use of other modalities is no longer warranted.^{3,10} Strengthening activities involve progressing the resistance in concentric exercises and focusing on strength and control through eccentric muscle contractions. The exercises will focus on the rotator cuff and scapular stabilizers in the beginning of this phase and other prime movers of the shoulder later in this phase.³ This allows the rotator cuff and scapular muscles to be strong and stabilize the shoulder before the prime movers become strong and challenge the balance of the shoulder complex. Table 5 describes exercises that strengthen the scapulothoracic musculature. Resistance using tubing and light dumbbells should be incorporated to increase the weight/resistance as the patient gets stronger. Proprioceptive Neuromuscular Facilitation (PNF) D1 flexion patterns below 90° may also be used to gain functional strength of the shoulder.¹⁰ PNF is a set of precise movement patterns that are developmentally set in the human.²⁹ The patterns involve a component of flexion or extension, abduction or adduction, and rotation. A D1 flexion pattern incorporates flexion, adduction, and external rotation. D2 flexion involves flexion, abduction, and external rotation.

Using short arc concentric exercises decreases the stress placed on the shoulder during exercise. As the muscles get stronger and are providing the proper stabilization for the shoulder joint, full arc concentric exercises in the scapular plane may be performed. At this point, flexion and scaption to 90° with thumbs up may be performed. Scaption is arm elevation in the scapular plane.

Eccentric contractions of the rotator cuff and scapular muscles play an important role in this phase since many injuries and degenerative changes occur as a result of faulty

Table 5. Scapular Exercises

Muscle	Exercises
Serratus Anterior	Serratus punch, push-up with a plus, quadruped stabilization, shrugs, abduction in the scapular plane, and prone shoulder flexion
Rhomboids	Shrugs, rowing, and scapular retraction
Pectoralis Major	Press-ups, bench press
Pectoralis Minor	Press-ups
Levator Scapulae	Rowing, shrugs, shoulder abduction
Latissimus Dorsi	Press-ups, lat pull downs
Upper Trapezius	Shrugs, abduction in the scapular plane, rowing
Middle Trapezius	Rowing, scapular retraction with arm in 90° abduction, and prone shoulder flexion and abduction
Lower Trapezius	Rowing, scapular depression and retraction, abduction in the scapular plane

eccentric muscle contractions during activities, especially overhead activities.^{3,26}

Strengthening eccentrically is very important in the success of shoulder rehabilitation and should be stressed in this phase. Eccentric strength training can be emphasized in a patient's normal exercise routine. Altering exercises to provide resistance as the muscle is lengthening using theraband, free weights, or isokinetic machines will provide the shoulder muscles with the proper firing patterns they need to prevent further injuries or degeneration from occurring with shoulder activity.

Towards the end of this phase, strengthening activities for the prime movers of the shoulder can be emphasized.^{3,26} Prime movers include the deltoid, teres major, coracobrachialis, pectoralis major, and latissimus dorsi. These exercises include progressive push-ups with a plus, rowing, latissimus pull downs, shoulder shrugs, and upright rows. PNF D2 flexion patterns with manual resistance from the therapist in the form of rhythmic stabilization and slow reversal hold techniques may also be implemented.^{3,10,30} Conditioning for the rest of the body is appropriate during this phase.^{3,26} Patients completing phase II who are returning to basic ADL's and a sedentary lifestyle will not require further supervised treatment and will be discharged with a home program at this point. Those requiring further therapy will progress into phase III.

Phase III

Phase III emphasizes goals of improved strength, coordination, and endurance for reconditioning of the shoulder muscles. Tolerance of overhead strengthening activities and plyometrics is also a focus of phase III.^{3,10,26} Continuation of the exercises for flexibility, ROM and strengthening from phase II and the addition of overhead and

plyometric activities make up the treatment program for this phase. Free weights and resistive tubing are still used to provide muscular challenges. External and internal rotation exercises, and PNF D2 flexion/extension patterns can now be performed in 90° of abduction. These activities work on more functional arm motions and prepare the shoulder for return to functional activities.

Isokinetic programs emphasizing both strength and endurance of the shoulder musculature are appropriate.²⁶ Isokinetic exercises involve muscle contractions where speed is controlled and maximal force from the muscle occurs throughout full ROM.¹⁶ A machine controls the velocity and records the torque output which can be used to evaluate the patient's strength and endurance progress.^{10,26} Using isokinetic exercises can make the transition from the intermediate exercises of phase II to the more demanding, advanced strengthening exercises of phase III easier.¹⁰ Skill retrieval or development may also begin during this phase. Specific activities related to the sport, occupation, or ADL's of the patient should begin at low intensity levels and progress with caution. If pain returns, activity should be reduced to the previous level until the pain subsides.²⁶

Plyometrics are activities that involve quick, powerful movements that cause a prestretch of the muscle activating the stretch-shortening cycle.⁹ This cycle is accomplished in three phases: eccentric, amortization, and concentric. The eccentric phase increases the activity of the muscle spindle and causes a prestretch of the muscle group being exercised.^{3,9} The amortization phase is the amount of time between the initiation of the yielding eccentric contraction and the beginning of the concentric contraction. The concentric phase is the resulting contraction from the eccentric

preloading of the muscles. Plyometrics enhance the reactivity of the neuromuscular system allowing an increase in muscular force in a minimal amount of time. The goal of plyometrics is to decrease the time the person is in the amortization phase. Plyometrics are excellent transitional components between traditional strengthening exercises and returning to full activity whether it is a specific sport or occupational.³ Table 6 describes some specific plyometric exercises utilized in shoulder rehabilitation. When the patient is returning to a strenuous occupation or sport, significant workouts for the lower extremities and trunk musculature should be included to increase overall endurance and strength of the body. This will allow the patient to gradually adapt to increased activity without further injury.

Phase IV

The goal of phase IV is to return to painfree functional activities without restrictions.^{3,10,26} This phase focuses mainly on athletes and their sport specific tasks. Continuation of exercises from the previous phases are encouraged to address any remaining strength deficits and to improve muscular strength related to the demands of the specific sport.^{1,9,10} The patient is gradually exposed to the stresses experienced with full activity. Many sports therapists require a patient to complete a functional progression program before they can return to their sport without restrictions. It includes preparation both physically and psychologically for the intense demands of their sport. This functional progression is usually included in phase IV of rotator cuff tear rehabilitation.^{3,9,10}

Table 6. Plyometric Exercises for the Shoulder

WARMUP EXERCISES	THROWING MOVEMENTS	MEDICINE BALL WALL EXERCISES
Medicine ball rotation	Medicine ball soccer throw	Soccer throw
Medicine ball side bends	Medicine ball chest pass	Chest pass
Medicine ball wood chops	Medicine ball step and pass	Side-to-side throw
Tubing ER/IR	Medicine ball side throw	Backward side-to-side throw
Tubing diagonal patterns(d2)	Tubing plyos IR/ER	Forward two hands through legs
Tubing biceps	Tubing plyos biceps	One-hand baseball throw
Push-ups	Tubing plyos diagonals	
	Plyo push-up (boxes)	
	Push-up (clappers)	

Adapted from Stretch-Shortening Drills for the Upper Extremities: Theory & Clinical Application. JOSPT. May 1993;17(5):229. Orthopedic Therapy of the Shoulder. Philadelphia, Penn: J.B. Lippincott Co; 1995:361.

CHAPTER VI

CONCLUSION

The shoulder complex is made up of four joints that work together to provide a large amount of mobility in the upper extremities. This mobility is at the cost of stability due to the incongruency of the glenohumeral joint and the fact that the only bony attachment of the shoulder complex to the axiskeleton is through the clavical. Stability of the shoulder depends on the dynamic rotator cuff and scapulothoracic muscles.

Rotator cuff tears are one of the most common shoulder problems seen today in the medical setting. The major causes of these tears are degeneration and traumatic injury. Degeneration of structures within the shoulder complex result from a variety of factors including decreased vascularity, age, shape of the acromion, repetitive trauma, scapular instability, and muscular weakness. Traumatic injury occurs from a lateral blow to the shoulder and account for many of the rotator cuff tears seen in the physical therapy setting.

Rotator cuff tears can present with similar signs and symptoms as other diagnoses of the shoulder. These conditions include bursitis, tendinitis, and impingement. It is important to distinguish between these conditions and a suspected rotator cuff tear by using special tests, palpation, and attaining information through a patient interview. Once a rotator cuff tear is diagnosed, treatment options including conservative versus surgical management need to be considered.

Conservative and surgical rehabilitation will be different in that surgical repair of the rotator cuff requires no active arm elevation for the first 4-6 weeks post-operatively. The restriction impedes the progress that normally can be made in the first phase of conservative treatment and is the reason that surgical patient's lag 4-6 weeks behind the rehabilitation of patients who were treated conservatively. Negating time frames, rehabilitation of rotator cuff tears whether surgically repaired or not can follow a four phase treatment program to progress to full recovery. Phase I concentrates on reducing pain and inflammation, regaining near full ROM, and initiating strength exercises to decrease muscle atrophy. This occurs through the use of modalities, anti-inflammatory medications, PROM and AAROM exercises, mobilization techniques, and isometric strengthening of the rotator cuff and scapulothoracic muscles.

Phase II emphasizes attaining full painfree ROM and flexibility, and improving strength and endurance of the rotator cuff and scapulothoracic muscles. Strength activities progress from isometric to concentric and eccentric contractions of the rotator cuff and scapular muscles early in this phase and includes the prime movers later in this phase. Phase III incorporates the exercises from phase II but keys in on improved strength, coordination, and endurance of the shoulder muscles. Treatment involving isokinetic and plyometric exercises, as well as progression to overhead activities is the hallmark of this phase. Phase IV focuses on return to full, painfree functional activities. This will include a functional progression program implemented by the physical therapist for athletes to meet specific demands of their individual sport, both physically and

psychologically. The patient must demonstrate full ROM, muscular strength, and adequate shoulder stability prior to return to full activity.

Once the patient successfully completes the four phases in the rehabilitation program for rotator cuff tears, they are no longer seen by a physical therapist. Although the patient has finished his/her rehabilitation program, it is essential to continue stretching and strengthening the shoulder complex independently on a regular basis. This is important in order to maintain the stability of the shoulder complex, to maximize shoulder function and to prevent reinjury.

The rotator cuff plays an important role in the stability and proper functioning of the shoulder. Rotator cuff tears resulting in pain and a decrease in function are common among all age ranges. Physical therapy rehabilitation, whether conservative or after surgical intervention, is important for full return of the patient's shoulder function.

APPENDIX

RECEIVED

September 20, 1996

Permissions Editor
F.A. Davis Company
1915 Arch Street
Philadelphia, PA 19103

Dear Permissions Editor:

I am writing to request permission to photocopy or reproduce copies of figures in the book "Joint Structure and Function: A Comprehensive Analysis." The figures listed below would be used in my Independent Study report as part of my graduate requirements for a Master of Physical Therapy degree from the University of North Dakota, Grand Forks, North Dakota.

Reprint request:

Joint Structure and Function: A Comprehensive Analysis
Second Edition, copywrite 1992.

- Figure 7-8. page 214 - SC Ligaments
- Figure 7-12. page 217 - AC Ligaments
- Figure 7-17. page 220 - GH Ligaments
- Figure 7-19. page 221 - Coracoacromial Arch

Three copies will be made for the following uses: Graduate School, Physical Therapy Library, and for my own copy of the Independent Study. The standard credit line will be used to give proper recognition for the figures used.

Thank you for your attention to this request.

Sincerely,

Tiffany R Wirz S.P.T.

Tiffany Wirz S.P.T.
921 32nd Ave. S. #9
Grand Forks, ND 58201

Approval is given to Tiffany Wirz, Physical Therapy student at the University of North Dakota, for copying the above publications for educational purposes as outlined above.

Permission Granted 9/23/96
Name of Permissions Editor

Jean-François Vilain
Publisher

REFERENCES

1. Kamkar A, Irrgang JJ, and Whitney SL. Nonoperative management of secondary shoulder impingement syndrome. *J Orthop Sports Phys Ther.* May 1993;17(5):212-223.
2. Neviasser RJ. Diagnosis and management of rotator cuff tears. *J Musculoskeletal Med.* Feb 1992;9(2):62-69.
3. Sell JD, Sallay PI, DeCarlo M, and Misamore GW. Rotator cuff disease in the athlete. SPTS Home Study Course. 1995;2-19.
4. Pink M, and Jobe FW. Shoulder injuries in athletes. *Orthopedics.* Dec 1991;11(6):39-47.
5. Post M. Complications of rotator cuff surgery. *Clin Orthop.* May 1994;254:97-104.
6. Frieman BG, Albert TJ, and Fenlin JM. Rotator cuff disease: a review of diagnosis, pathophysiology, and current trends in treatment. *Arch Phys Med Rehabil.* May 1994;75(5):604-9.
7. Neviasser RJ, and Neviasser TJ. Observations on impingement. *Clin Orthop.* May 1990;254:60-3.
8. Dalton SE. The conservative management of rotator cuff disorders. *Br J Rheumatol.* Jul 1994;33(7):663-7.
9. Kelly MJ, and Clark WA. Orthopedic Therapy of the Shoulder. Philadelphia, Penn: J.B. Lippincott Co; 1995:109-120.
10. Prentice WE. Rehabilitation Techniques in Sports Medicine. 2nd ed. Philadelphia, Penn: Mosby;1994:318-320.
11. Guffey JS. Rehabilitating Shoulder Dysfunction: The importance of scapular stabilizing. San Diego, Calif. Wahl and Associates. 1991.
12. Culham E, and Peat M. Functional anatomy of the shoulder complex. *J Orthop Sports Phys Ther.* Aug 1993;18(2):342-50.

13. Schenhman M, and Rugo De Cartaya V. Kinesiology of the shoulder complex. *J Orthop Sports Phys Ther.* 1987;8(9):438-50.
14. Morre KL. Clinically Oriented Anatomy. 3rd ed. Philadelphia, Penn: Williams & Wilkins;1992:501-541.
15. Norkin CC, and Levangie PK. Joint Structure and Function: A Comprehensive Analysis. 2nd ed. Philadelphia, Penn: F.A. Davis Co;1989:207-37.
16. Thomas CL. Taber's Cyclopedic Medical Dictionary. Philadelphia, Penn: F.A. Davis Co;1993.
17. Clark JM, and Harryman DT. Tendons, ligaments, and capsule of the rotator cuff, gross and microscopic anatomy. *J Bone Joint Surg Am.* Jun 1992;74(5):713-25.
18. Paine RM, and Voight M. The role of the scapula. *J Orthop Sports Phys Ther.* Jul 1993;18(1):386-91.
19. Codman EA. The Shoulder. 2nd ed. Boston, Mass: Thomas Todd;1934.
20. McLaughlin HL. Trauma. Philadelphia, Penn: W.B. Saunders Co;1960.
21. Rathbun JB, and Macnab I. The microvascular pattern of the rotator cuff. *J Bone Joint Surg.* 1970;52B:540.
22. Rothman RH, and Parke WW. The vascular anatomy of the rotator cuff. *Clin Orthop.* 1965;41:176-86.
23. Kisner C, and Colby LA. Therapeutic Exercise: Foundations and Techniques. 2nd ed. Philadelphia, Penn: F.A. Davis Co;1990:218-225,258-59.
24. Wolf WB. Shoulder tendinoses. *Clin Sports Med.* 1992 Mar;11(4):871-90.
25. Magee DJ. Orthopedic Physical Assessment. 2nd ed. Philadelphia, Penn: W.B. Saunders Co;1992:105-119.
26. Brewster C, and Schwab DR. Rehabilitation of the shoulder following rotator cuff injury or surgery. *J Orthop Sports Phys Ther.* 1993 Aug;18(2):449-58.
27. Mohr T. Muscle Function PT 412 Course Notes. University of North Dakota, Grand Forks, North Dakota. 1995.

28. Mohr T. Therapeutic Exercise PT 413 Course Notes. University of North Dakota, Grand Forks, North Dakota. 1995:41.
29. Hillman S. Principles and techniques of open kinetic chain rehabilitation: the upper extremity. *J Sports Rehabil.* 1994;3:319-30.
30. Voss DE, Ionta MK, and Myers BJ. Proprioceptive Neuromuscular Facilitation: Patterns and Techniques. 3rd ed. Philadelphia, Penn; Harper & Row Publishers;1985.