

## Hydatid Cyst of the Heart: Six Clinical Cases

A. Majdoub<sup>a\*</sup>, A. Daouda<sup>b</sup>, A. N. Kaled<sup>c</sup>, S. Boulmakoul<sup>d</sup>, M. Messouak<sup>e</sup>

<sup>a</sup>Department of cardiovascular surgery CHU HASSAN II FES/MAROC, Address: 113 AV ALMOHADES APPT  
12 VN postcodes: 30000/FES/MAROC

<sup>b</sup>Department of cardiovascular surgery CHU HASSAN II FES/MAROC, Address: 1, Rue Nador, Hay mal, Rte  
Séfrou, Résidence El oufir ETg 2, postcode: 30000/FES/MAROC

<sup>c</sup>Department of cardiovascular surgery CHU HASSAN II FES/MAROC, Address: Hay amal, Route Sefrou,  
Résidence Labrighi N 204, postcode: 30000/FES/MAROC

<sup>d</sup>Department of cardiovascular surgery CHU HASSAN II FES/MAROC, Address: CHU HASSAN II FES  
SERVICE CCV, postcode: 30000/FES/MAROC

<sup>e</sup>Department of cardiovascular surgery CHU HASSAN II, Address: CHU HASSAN II FES SERVICE CCV,  
postcode: 30000/FES/MAROC

<sup>a</sup>Email: aminemajdoub82@gmail.com

<sup>b</sup>Email: amadaoud@gmail.com

<sup>c</sup>Email: kaledadn1@gmail.com

<sup>d</sup>Email: salah.ddine.b@gmail.com

<sup>e</sup>Email : messouak30@hotmail.com

### Abstract

Hydatidosis is a cosmopolitan disease due to *Echinococcus granulosus*. The hydatid cyst of the heart (HCH) occurs in 0.5 to 2% of all hydatid locations. We report of six cases of HCH surgery under cardiopulmonary bypass, done in cardiovascular surgery department at Hassan II university teaching hospital in Fez, Morocco to analyze their diagnostic and therapeutic aspects. This is a retrospective study done, from January 2012 to April 2015. Six cases of hydatid cyst of the heart were collected among 760 cardiac surgery patients, with a frequency of 0.8%. The average age was 29 years, a sex ratio of 1.5 in favour of women. The hydatid cysts (HC) were in the wall and the inter septum of the right atrium in 2 cases and in the wall of the left ventricle in 4 cases. The association with other locations were noted with three patients with lung HC, one patient with liver HC, and the other one with a brain and peritoneal location.

---

\* Corresponding author.

Cardiac hydatid disease is mainly characterized by its clinical polymorphism, latency and severity of complications that are often indicative of the condition and can immediately be life-threatening. Advances in medical imaging has significantly contributed to improving its diagnosis, and echocardiography is one of the key tests for specifying the location. The CT scan, MRI contribute to the staging the disease. Hydatid serology is an important test and is necessary both for diagnostic purposes and for monitoring. Curative treatment of HCH is primarily surgical, which must be done as soon as the diagnosis is made and before the complications occur.

**Keywords:** hydatid cyst; heart; bypass; surgery.

## 1. Introduction

The *Echinococcus Granulosus* is a tapeworm that lives as an adult in the digestive tract of the dog. Larval development in humans causes a parasitic form of hydatid cyst (HC) [1]. Hydatid disease is endemic in Morocco. An incidence of about 4.55 cases per 100 000 inhabitants was mentioned in the report of Ministry of Health (MLED 2006), placing Morocco third in the Maghreb after Tunisia and Algeria [2]. The hydatid cyst of the heart (HCH) is rare, accounting for 0.5 to 2% of all hydatid locations [3]. To our knowledge, there is no data at the national level of this localization in Morocco. We collected over 3 years the HCH to analyze their diagnostic and therapeutic aspects.

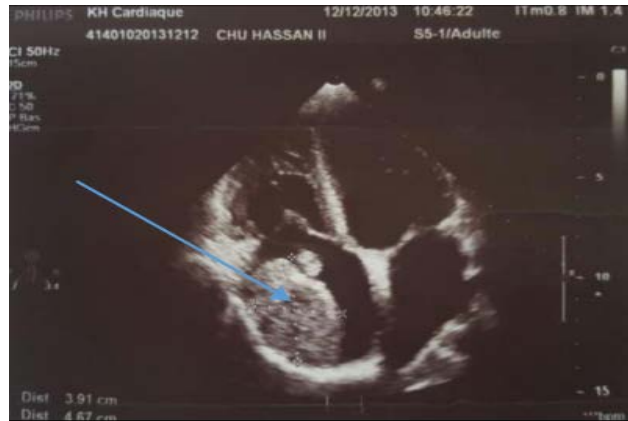## 2. Materials and Methods

This was a retrospective descriptive study of 6 cases of hydatid cyst of the heart. They were operated between 2012 and 2015 in cardiovascular surgery department of Hassan II Teaching Hospital of Fez in Morocco. This study involved all patients diagnosed and operated on for cardiac hydatid cyst. All patients were operated under coronary bypass. After aortic clamping, the heart was stopped by cold crystalloid antegrade cardioplegia. Before opening the pericyst, it was covered by gauze soaked with hypertonic saline to avoid contamination by contiguity [4, 5]. The pericyst was then opened and the daughter vesicles were removed after aspiration of their liquid contents (with a syringe). The residual cavity was swabbed using a hydrogen peroxide solution and a careful padding was then realized to the utmost extent possible [4, 5] (Figure 4). Finally, the closure of the sternum was performed on two drains including an intrapericardial and the other retrosternal. Hydatid serology was requested in all patients. Pathological examination showed daughter vesicles at the macroscopic study, yellowish cyst content and thin wall. In the histological study, the inside of the cyst contained a granular material and fragments of membrane cuticle lamellar and acellular eosinophilic PAS positive [6]. This examination confirmed the diagnosis of hydatid disease in all cases.

## 3. Results

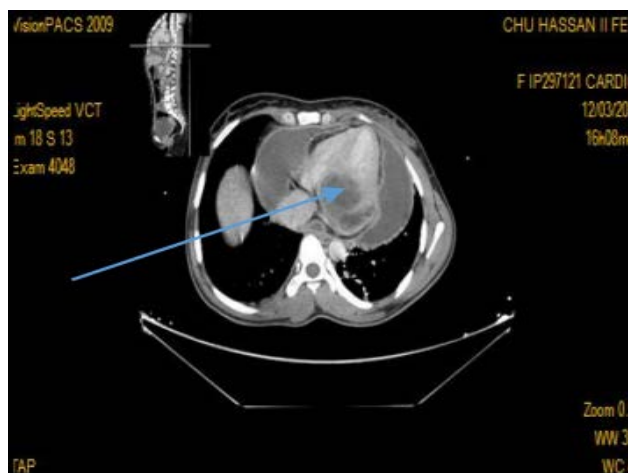
Six cases of hydatid cyst of the heart were collected among 760 cardiac surgery patients, with a frequency of 0.8% (Table I). The average age of patients was 29 years, ranging between 18 and 56 years. There were 4 women and 2 men with a sex ratio of 1.5. All six patients had a notion of contact with dogs. We found chest pain in 4 cases. There was associated dyspnea in one case, palpitation in one case, vomiting hydatid and hemoptysis in 2 patients, and influenza-like illness in one case (Table I). In 2 cases, the discovery was incidental

during a routine examination. Hydatid serology was positive in all patients. Chest radiography was performed in all patients. It showed cardiomegaly in 4 cases, and retrosternal opacity in 2 cases (Table I). The electrocardiogram did not reveal any abnormality. Echocardiography revealed the heart location of a compartmentalized fluid mass in 3 cases and a homogeneous liquid mass in 3 cases (Figure 1).



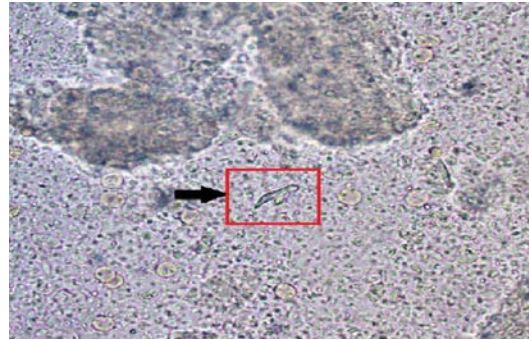
**Figure 1:** Transthoracic echocardiography showing in Cup 2 D showing a right atrial intra mass + a small thrombus alongside mass.

CT thorax found multiple liquid formations partitioned with their precise locations in all cases. Hydatid cysts were in the wall and the inter septum of the right atrium in two cases; they were in the wall of the left ventricle in four cases (Figure 2). Cardiac location cysts was associated with pulmonary hydatid cysts in three patients, another patient with additional HC to the liver, and finally one other with a cerebral and peritoneal location.



**Figure 2:** Scannographic Cup showing a hydatid cyst of the posterior wall of the left ventricle.

After the release of cardiopulmonary bypass, the immediate postoperative course was marked by a normal consciousness, hemodynamic and respiratory stability, minimal bleeding from drains and proper diuresis. The average length of stay was 8 days after the operation. All patients were started on mebendazole at a dose of 50 mg / kg / day for six months. The pathology of the surgical specimen confirmed the diagnosis of hydatid cyst in all patients (Figure 3).



**Figure 3:** View microscopic: the element of certainty for the derivative of the cyst hydatid (hooks).For patients with cardiac HC associated with other locations, the treatment was correlated with the corresponding specialists.

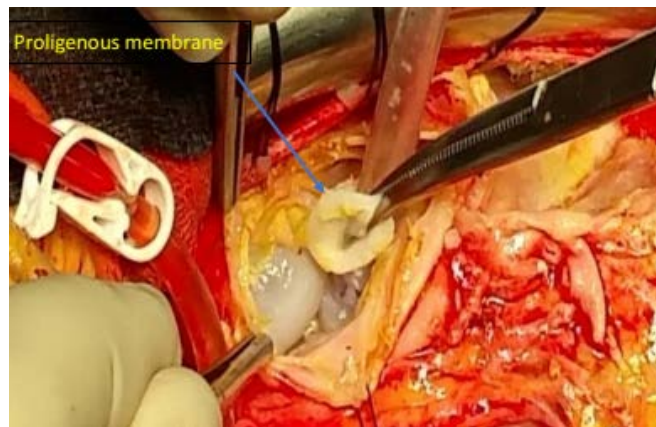
The mean follow-up was 48 months. All patients had good clinical and radiological evolution with loss of functional and morphological signs. During this period, echocardiography was performed at least annually. The latter did not reveal hydatid cyst recurrence.

**Table I:** Clinical and Paraclinical aspects

Case	Age (year)	Sex	Functional signs	Chest x-ray	Echocardiography	TDM	Heart location	Other locations
1	22	F	Chest pain Flu Syndrome	Opacity retrosternal	Fluid mass Partitioned	Multiple formations Fluid partitioned	Posterior wall of left ventricle	Pericarditis
2	56	M	Chance discovery	Cardiomegaly	Fluid mass Partitioned	Left pericardial Mediastinal cystic training	Lateral wall of left ventricle	-
3	36	F	Chest pain, Palpitation	Opacity retrosternal	Fluid mass Partitioned	Multiple formations Fluid partitioned	Sidewall and posterior left ventricle	Lung Liver
4	18	F	Chest pain, Dyspnea, Vomique, Hemoptysis	Cardiomegaly	Fluid mass Homogeneous 27/7 mm	Cystic mass Wall of the right atrium	Inter atrial septum + wall of the right atrium	Lung
5	20	M	Pain, chest, vomique, Hemoptysis	Cardiomegaly	Fluid mass Homogeneous 80 mm	Hypodense mass Homogeneous to the wall of the right atrium	Inter atrial septum + wall of the right atrium	Lung
6	22	F	Chance discovery	Cardiomegaly	Fluid mass Homogeneous	Cystic mass left in contact with the left ventricle	Anterior surface of the right ventricle and the left ventricle posterior wall	Lung, Brain, peritoneum

#### 4. Discussion

Cardio-pericardial hydatid cyst localization remains rare 0.5% -2.0% [7]. To our knowledge, there is no national data of this localization in Morocco. The clinical presentation of HCH is often atypical and polymorphic. This is what partly explains the delay in diagnosis [8]. The evolution of cardiac hydatid cyst is usually insidious. It turns out most often by complications such as rupture of the heart wall, hydatid vomiting, systemic or pulmonary embolism [8]. It can also be by disorders of rhythm or conduction, ischemic heart disease or heart failure [8]. In two of our patients, the disease was revealed by a hydatid vomica and HCH was discovered incidentally in 2 cases. HCH symptomatology varies according to the evolutionary stage, its site relative to the valvular orifices, the conduction tissue, and its location in the heart right and / or left. [9] Chest pain is the most commonly reported symptom [10] Indeed, four of our patients complained of chest pains, which agrees with the literature. The chest X ray does not provide specific evidence about the origin of hydatid cyst. The most common sign found is cardiomegaly with or without deformation of the heart contours; multiple small rounded opacities predominant in the periphery of the lung fields may be suggestive of hydatid dissemination or embolism [11]. Some opacities are arranged along the path of the pulmonary arteries [11]. In our series, the X-ray revealed cardiomegaly with cardiothoracic index greater than 0.5 centimetres. It also revealed retrosternal opacity in 2 cases. Echocardiography is the key examination for the positive diagnosis [12]. It allows visualization of the cardiac masses and clarify their appearance. The cyst has a fluid appearance with frequently daughter vesicles or trabeculations [12]. More rarely, the mass is full and corresponds to a ruptured cyst. Echocardiography should be performed in all patients operated on for hydatid cyst in order to detect an associated cardiac localization. This review has been of great contribution in our series. Indeed, it revealed a compartmentalized fluid mass in 3 patients and also a homogeneous liquid mass in 3 others [12].



**Figure 4:** operating view: resection of proligenous

The Thoracic CT scan has contributed to the diagnosis in all patients and to clarify the relationship with the cardiac structures, particularly coronary vessels. Kaplan M, cardiac hydatid cyst is localized preferably in the left ventricle (75%), followed by the right ventricle (15%) the interventricular septum (10%), the atria (5-8%), and pericardium in (4%) [13]. In 20-40% of cases, it is associated with other visceral sites. [13] While according to Jerbi S, the interventricular septum is affected in 9-20% of cases, while the right ventricle and the right atrium are affected in 4-17% of cases [14]. The auricular septum is affected in 2% of cases [15] and was the first case

described in the literature in 1964 [16]. Cevirme [17] had described a case of hydatid localization in the inter atrial septum and in the upper right lung lobe. Eylem Tuncer [18] found a single case of localization in the inter atrial septum. In our series, the hydatid cyst was located in the posterior wall of the left ventricle in 3 cases. It was associated with a location in the side wall in 2 cases, the anterior aspect of the right ventricle in one case, and finally a location in the right atrium and the atrial septum in 2 cases. MRI is also helpful if diagnostic doubt exists or there is a discrepancy between ultrasound and computed tomography [19]. In our series, we did not need to use it since we had no diagnostic doubt. The risk of progression to serious complications imposes a need for rapid diagnosis and quick surgical intervention. Surgical treatment is the only way to ensure the effective treatment of hydatid cyst.

The goal of surgery is to relieve the heart in order to ensure a satisfactory hemodynamic and prevent new emboli. Cystectomy, pericystectomy and the cavity occlusion give the best chance of recovery [13]. The cardiopulmonary bypass procedure must be performed to ensure a complete myocardial and pericardial surgery which guarantee of a permanent cure without recurrence hydatid cyst [3]. This is consistent with our series. When the cyst is in the right heart as was our case, the clamping of the pulmonary artery is recommended by some authors. This is to prevent migration of the cyst or daughter vesicles to the pulmonary bed and systemic anaphylaxis [20]. It is recommended to perform a femoral venous cannulation rather than cannulation of the vena cava. This prevents a possible pulmonary migration during cannulation of the right atrium. In case of associated pulmonary hydatid disease, surgery can be done in the same operation, on the same access, after recovery of cardiac activity [21].

The limitations of our study are small cohort, retrospective, observational, and mono centric. If the overall characteristics of the population are homogeneous, the diagnostic and management modalities are variable and do not make it possible to distinguish a significant prognostic element.

## **5. Conclusion**

Cardiac hydatid cyst is a serious and formidable disease with significant complications. It affects a relatively young population. The clinical presentations are variable and nonspecific. The diagnosis is suspected by imaging examinations and confirmed by histological study. The treatment is surgical, but preventive measures across the population should be prioritized in order to reduce its incidence. A nationwide survey or even international study on cardiac hydatid cyst is necessary.

## **References**

- [1]. Y.J. Golvan. *Éléments de parasitologie médicale* (4<sup>e</sup> éd.). Paris : Flammarion Médecine-Sciences, 1983, pp.571.
- [2]. Ministère de la Santé, Direction de l'épidémiologie et de lutte contre les Maladies (DELM). *Situation épidémiologique de l'hydatidose et activités réalisées, en 2005 et 2006 : Rapport annuel d'activité - État d'avancement des programmes de lutte contre les maladies parasitaires Années 2005 – 2006. "Rapport Annuel des maladies parasitaires"*.

Internet:[http://www.sante.gov.ma/departements/delm/maladiesparasitaires/2005-](http://www.sante.gov.ma/departements/delm/maladiesparasitaires/2005-2006.PDF)

[2006.PDF](http://www.sante.gov.ma/departements/delm/maladiesparasitaires/2005-2006.PDF)<http://www.sante.gov.ma/departements/delm/maladiesparasitaires/2005-2006.PDF>, Oct. 19, 2011.

- [3]. D. Mrad, K. Tlili, M. Ly et al. "Profil Radioclinique du kyste Cardio-Péricardique à Propos de 17 cas". *Ann Cardiol Angiol*, vol. 49, pp. 414-2, 2000.
- [4]. A. Heilbrun, F. Kittle, M. Dunn "Surgical management of echinococcal cyst of the heart and pericardium". *Circulation*, vol. 27, pp. 219–228, 1963.
- [5]. E. Brunettia, T. Junghanss. "Update on cystic hydatid disease". *Curr Opin Infect Dis*, vol. 22, pp. 497–502, 2009.
- [6]. S. Charfi et al. "Kyste hydatique du sein diagnostiqué par cytoponction". *La Revue de médecine interne*, vol. 28, pp. 336–338, 2007.
- [7]. J. Heyat, H. Mokhtari, J. Hajaliloo, J.G. Shakibi. "Surgical treatment of echinococcal cyst of the heart". *J. Thorac Cardiovasc Surg*, vol. 61, pp. 755–764, 1971.
- [8]. E. Onursal et al. "Surgical Treatment of Cardiac Echinococcosis: Report of Eight Cases". *Surgery Today*, vol. 31, pp. 325–330, 2001.
- [9]. J.A. Trigano, F. Mourot, T. Talmoudi, C. Malmejac. "Sémiologie du Kyste Hydatique du Cœur : Etude d'une Série Continue de 13 cas et Intérêt du Scanner". *Arch Mal cœur*, vol. 13, pp. 1895-9, 1985.
- [10]. A. Abid, S.B. Omrane, K. Kaouel et al. "Intracavitary cardiac hydatid Cyst". *Cardiovasc Surg*, vol. 11, pp. 521-5, 2003.
- [11]. T. Talmoudi, J.C. Jouveu, C. Malmejac, D. Roux, G. Antypas. "L'embolie Pulmonaire Hydatique : Etude de Deux Observations Personnelles et Revue de la Littérature". *Ann Chir Thorac Cardiovasc*, vol. 34, pp. 245-50, 1980.
- [12]. E. Klodas, V. Roger, F. Miller, J.P. Vitz, G.F. Danielsou, W. Edwards. "Cardiac Echinococcosis: Case Report of Unusual Echocardiographic Appearance". *Mayo Clin Proc*, vol. 70, pp. 657-61, 1995.
- [13]. M. Kaplan, M. Demirtas, S. Cimen, A. Ozler. "Cardiac Cysts with Intracavitary Expansion". *Ann Thorac Surg*, vol. 71, pp. 1587-90, 2001.
- [14]. S. Jerbi, C. Kortas, S. Dammak, N. Hamida, K. Ennabli. "Les kystes hydatiques cardio-péricardiques à propos de 19 cas". *Tunis. Medecine*, vol. 82, pp. 152-7, 2004.
- [15]. H. Yaliniz, A. Tokcan, O.K. Salih, T. Ulus. "Surgical Treatment of Cardiac Hydatid Disease : a Report of 7 cases". *Tex Heart Inst J* vol. 33, pp. 333-9, 2006.

- [16]. E. Minetto, C. Prinotti, T. Purini. "Sudden Death Due to Primary Echinococcosis of the Interatrial Septum". *Clinical and medico-legal interest. Minerva Medico legale*, vol. 84, pp. 189-94, 1964.
- [17] D. Cevirme, C. Yerebalkan, S. Bayrakatar, H. Sunar. "Cardiac Cydatid Cyst of the Interatrial Septum". *Wien Med Wochenschr*, vol. 159, pp. 17-8, 2009.
- [18]. E. Tuncer, G. Tass, I. Mataraci et al. "Surgical Treatment of Cardiac Hydatid Disease in 13 Patients". *Tex Heart Inst J*, vol. pp. 37189-93, 2010.
- [19]. A. Elmajhad, A. Lachhab, R. Cherradi, J. Srairi, N. Srairi, N. Doghmi. "Apport de L'imagerie par Résonance Magnétique (IRM) dans le Diagnostic du Kyste Hydatique cardiaque". *EMHJ*, vol. 17, pp. 996-1000, 2011.
- [20]. G. Orhan, B. Ozay, Z. Tartan, E. Kurc, B. Ketenci, M. Sargin et al. "Chirurgie des Kystes Hydatiques Cardiaques. Trente-Neuf Ans D'expérience". *Ann Cardiol Angiol*, vol. 57, pp. 58-61, 2008.
- [21]. H.B. Jmaa, M. Abdennadher, A. Dammak, S. Kallel, L. Abid, S. Msaad et al. "Traitement Chirurgical d'un Kyste Hydatique du Septum Inter-Auriculaire". *Chirurgie thoracique ET Cardio-Vasculaire*, vol. 16(2), pp. 118-120, 2012.