

Journal of Sports Medicine and Allied Health Sciences: Official Journal of the Ohio Athletic Trainers Association

Volume 4
Issue 3 *JSMaHS Spring 2019 Issue*

Article 7

March 2019

Fracture of a Heterotopic Ossification of the Syndesmosis in a Collegiate Football Player: A Case Report.

Stephen A. Cage

The University of Texas at Tyler; University of North Carolina Greensboro, sacage@uncg.edu

Brandon J. Warner

Grand Canyon University; University of North Carolina Greensboro, brandon.warner@gcu.edu

Diana M. Gallegos

University of Texas at Tyler, dgallegos@atsu.edu

Follow this and additional works at: <https://scholarworks.bgsu.edu/jsmahs>



Part of the [Rehabilitation and Therapy Commons](#), and the [Sports Medicine Commons](#)

Recommended Citation

Cage, Stephen A.; Warner, Brandon J.; and Gallegos, Diana M. (2019) "Fracture of a Heterotopic Ossification of the Syndesmosis in a Collegiate Football Player: A Case Report.," *Journal of Sports Medicine and Allied Health Sciences: Official Journal of the Ohio Athletic Trainers Association*: Vol. 4 : Iss. 3 , Article 7.

DOI: 10.25035/jsmahs.04.03.07

Available at: <https://scholarworks.bgsu.edu/jsmahs/vol4/iss3/7>

This Article is brought to you for free and open access by the Journals at ScholarWorks@BGSU. It has been accepted for inclusion in Journal of Sports Medicine and Allied Health Sciences: Official Journal of the Ohio Athletic Trainers Association by an authorized editor of ScholarWorks@BGSU.

Fracture of a Heteropic Ossification of the Syndesmosis in a Collegiate Football Player: A Case Report

Stephen A. Cage, M.Ed, LAT, ATC*; Brandon J. Warner, M.Ed, LAT, ATC‡; Diana M. Gallegos, MS, LAT, ATC*

*The University of Texas at Tyler; ‡Grand Canyon University

Objective: Present a clinical case detailing the assessment and management of a collegiate football player suffering from the fracturing of a heteropic ossification of the syndesmosis. **Background:** Heteropic ossifications are not uncommon following surgical fixation of the tibiofibular syndesmosis. Typically, properly healed fibular fractures do not result in further complications associated with heteropic ossification. **Treatment:** A 21-year-old collegiate football player (1.8 m, 77.1 kg) reported to the athletic training staff complaining of acute lateral ankle pain following a plant and twist mechanism while running receiving routes. Initial evaluation led to a diagnosis of a syndesmotic ankle sprain, with a plan to pursue conservative management. When patient was unable to participate in the following practice due to intensity of pain, the patient was referred for x-rays a revealed poorly healed Weber Type C fracture that had been mislabeled as a Maisonneuve fracture at the patient's previous university. This previous injury led to a heteropic ossification of the syndesmosis that had fractured during the more recent injury. With this new diagnosis, the patient consented to conservative treatment that allowed the patient to return to football activities the following offseason. **Uniqueness:** While heteropic ossification of the ankle syndesmosis has been reported in literature, there has yet to be extensive research on the condition. Generally, when these ossifications become symptomatic best practices involve surgical removal. In spite of presenting with symptoms, the patient was able to return to full participation following conservative treatment. **Conclusion:** When providing patient care, accurate diagnosis is crucial to optimal outcomes. Caring for patients in a collegiate setting presents a unique number of instances of patient care transfer, which may make previous misdiagnosis hard to recognize. Diligent health care practitioners should always ensure that a comprehensive medical history is obtained in order to make an accurate assessment. **Keywords:** Heteropic ossification, syndesmosis, ankle

INTRODUCTION

Injuries to the ligamentous structure of the ankle account for as much as 30% of all sport related injuries.¹ While ankle injuries are relatively common, syndesmotic ankle sprains represent as little as 1% of these injuries.² Even though these ligamentous injuries are less common, they often result in greater loss of time and increased disability.³ Early diagnosis and intervention is crucial to achieving optimal outcomes for patients suffering from syndesmotic ankle sprains.

Heteropic ossification is the abnormal formation of mature bone in non-skeletal tissues.⁴ These ossifications can be separated into two categories, dystrophic and metastatic

ossifications.⁴ Dystrophic ossifications are characterized by calcium deposits, whereas metastatic ossifications are caused by some form of pathology.⁴ There are a number of proposed causes for this condition, including: bony or soft tissue trauma, spinal trauma, head injuries, and genetic disorders.⁴

The type of heteropic ossification often dictates the course of treatment. If a patient is suffering from metastatic ossification, they are typically prescribed radiation therapy.⁴ For patients suffering from a symptomatic dystrophic ossification, oral non-steroidal anti-inflammatory drugs and therapeutic exercise are recommended with surgical

excision of the ossification serving as a last resort treatment.⁴

CASE REPORT

A 21-year-old collegiate football player (1.8 m, 77.1 kg) removed himself from practice after experiencing immediate pain along the anterior and lateral aspects of his right ankle. The patient reported the pain resulting from a plant and twist mechanism while running receiving routes, and was unable to place weight on the ankle without eliciting severe pain. At this time the patient was removed from practice and transported to the athletic training clinic.

Further evaluation revealed positive squeeze and Kleiger's test, decreased dorsiflexion, and weakness with dorsiflexion, plantarflexion, and inversion as assessed with manual muscle testing. The patient reported that his fibula on the involved leg had been fractured two years prior to the current injury, and required surgical intervention. Due to the patient's inability to recall the specifics of the injury, a note was made that medical records from his previous institution may need to be obtained. At this time, the differential diagnosis consisted of: syndesmotic ankle sprain, fibular fracture, aggravation of surgical site.

With the initial diagnosis of a syndesmotic ankle sprain, the athletic training staff drafted a conservative management plan that consisted of therapeutic exercise to correct strength and range of motion deficits in conjunction with ice, electrical stimulation, and non-steroidal anti-inflammatory medications to mitigate the symptoms of acute pain and inflammation. The day following injury, the patient underwent a therapeutic exercise program and was heavily taped and braced to assess functional capacity. Even with additional support and protection, the patient was unable to participate in practice, and was referred to the team physician the following day.

Upon evaluation, the team physician suspected a syndesmotic injury as well, but

given the severity of symptoms and previous history of fracture, x-rays were ordered. Radiographs revealed a poorly healed Weber Type C fracture, two broken syndesmotic screws, and a fractured heterotopic ossification of the syndesmosis (Figure 1). With the revelation of the poorly healed fracture, the athletic training staff reached out to the patient's previous caregivers to obtain his medical records. In the interim, the patient was placed in a walking boot and issued crutches until he could be seen by the team foot and ankle surgeon.

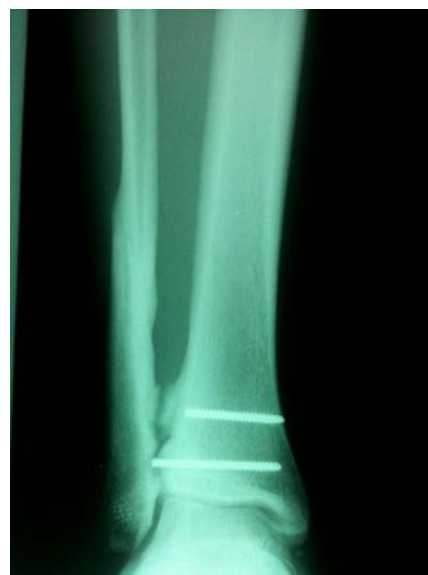

Figure 1. Radiograph revealing broken syndesmotic screws from previous surgery and fractured heterotopic ossification of the syndesmosis.

During the patient's consultation with the foot and ankle surgeon, the severity of the damage was reviewed. The surgeon stated that due to the previous fracture and failure of the previous surgery to correct the alignment of the fibula, the patient would likely require a fusion of the ankle mortise in order to experience significant symptom relief. When the patient was informed that such a surgery would likely mean his playing career would effectively be ended, he expressed a desire to attempt conservative treatment before agreeing to surgery.

After informing the patient that a second consultation with the foot and ankle surgeon could be schedule at any time, the athletic training staff set about initiating a

rehabilitation plan that focused on improving strength and increasing range of motion at the ankle. In addition to therapeutic exercise and ice and electrical stimulation for pain, the patient was also placed on a 14-week course of 800 mg ibuprofen, three times a day. The option of receiving a cortisone injection in the ankle was also discussed, but the patient elected to forego the injection at the time.

Over the next two weeks, the patient underwent therapeutic exercise twice a day consisting of: theraband exercises with traction (Figure 2), single leg balance, heel walks, toe walks, and lateral and forward jumps. By the second week post injury, the patient was walking without a discernible limp and requested an opportunity to perform functional tests. With the aid of taping and bracing, the patient was able to pass functional testing consisting of sprints, agility drills, and route running with what was described as “manageable” discomfort. Three weeks following the initial evaluation, the patient returned to limited participation in a conference game, returning a kickoff and participating in 12 offensive plays. The following day, the patient stated that he was experiencing mild soreness in his ankle but had no limiting symptoms.




Figure 2. Demonstration of theraband traction array for ankle exercises.

Throughout the remainder of the season, the patient continued with therapeutic exercise sessions twice daily utilizing the same exercise regimen the athletic training staff had been employing. The patient was able to

participate in the final eight games of the season, and only complained of minimal soreness. The patient was withheld from all contact and individual drills during practice to decrease the risk of injury in non-competition settings. At the completion of the season, the patient was seen once again by the foot and ankle surgeon. During the follow up evaluation the patient demonstrated improvements in strength and range of motion while reporting a continued decrease in pain. Given the improvements shown by the patient, he was cleared to begin participating fully in team workouts to prepare for spring offseason practices.

DISCUSSION

Heterotopic ossification following an injury to soft tissue structures is not uncommon.⁴ However, these ossifications can be difficult to detect as they can form years after injury or surgery.⁵ Often times if these ossifications become symptomatic they warrant surgical intervention to correct them.⁴ These interventions often involve removal of surgical hardware and the associated ossification.⁴

This case describes the diagnosis, and subsequent treatment and rehabilitation of a patient suffering from a fractured heterotopic ossification of the syndesmosis following a plant and twist mechanism. In this case, the patient was able to progress to full participation without recurrence of symptoms following a therapeutic exercise program designed to address strength and range of motion deficits of the ankle. When evaluated by a second foot and ankle orthopedic specialist it was determined that the patient had suffered from a Weber Type-C fracture as opposed to a Maisonneuve fracture. The previous misdiagnosis by the patient’s medical provider may have played a role in improper surgical fixation. While there is no way to retrospectively determine that this was the cause of the ossification, sub-optimal healing of the distal fibula may have predisposed the heterotopic ossification to becoming symptomatic. Additionally, it is noteworthy that the patient was able to regain

function at a competitive level in spite of a specialist recommending a surgery that would have terminated the playing career of the patient.

CONCLUSION

When assuming care of a patient with a previous history of significant injury or medical condition, it is crucial that clinicians obtain all pertinent medical documentation. When operating with inaccurate or incomplete medical records, it can be difficult to determine the nature of a patient's offending pathology. Even when presented with these records, it is important for the clinician to conduct a diligent review of the materials for discrepancies. In this case, a proper evaluation of the patient's history of ankle injuries resulted in an accurate diagnosis that allowed the patient to make an informed decision regarding their healthcare.

While the patient in this case was able to return to play following a fractured heterotopic ossification of the syndesmosis, more research needs to be conducted to determine appropriate conservative measures for such conditions. Until further research can be conducted with regards to the prevalence of heterotopic ossifications of the syndesmosis and the implications of continuing to participate even when these conditions become symptomatic, clinicians

must rely on patient reported outcomes and individual expertise when choosing the best course of management. While situations exist in which a career ending surgery may be warranted, it is paramount that clinicians exhaust all conservative interventions prior to surgical intervention. This especially holds true when caring for a young, competitive patient population.

REFERENCES

1. Waterman BR, Belmont PJ, Cameron KL, Svoboda SJ, Alitz CJ, Owens BD. Risk factors for syndesmotic and medial ankle sprain. *American Journal of Sports Medicine*. 2011; 39(5); 992-998. DOI: 10.2147/OAJSM.S41564
2. Kennedy MA, Sama AE, Sigman M. Tibiofibular syndesmosis and ossification. Case report: sequelae of ankle sprain in an adolescent football player. *Journal of Emergency Medicine*. 2008;18:233-40. DOI: 10.1016/S0736-4679(99)00201-2
3. Ferran NA, Maffulli N. Epidemiology of sprains of the lateral ankle ligament complex. *Foot and Ankle Clinics of North America*. 2006;11:659-662. DOI: 10.1016/j.fcl.2006.07.002
4. Balboni TA, Gobezie R, Mamon HJ. Heterotopic ossification: Pathophysiology, clinical features, and the role of radiotherapy for prophylaxis. *International Journal of Radiation Oncology Biology Physics*. Aug 1, 2006;65(5):1289-1299. DOI: 10.1016/j.ijrobp.2006.03.053
5. Xie Y, Cai L, Deng Z, Ran B, Hu C. Absorbable screws versus metallic screws for distal tibiofibular syndesmosis injuries: A meta-analysis. *The Journal of Foot & Ankle Surgery*. 2015;54:663-670. DOI: 10.1053/j.jfas.2015.03.010