

Journal of Sports Medicine and Allied Health Sciences: Official Journal of the Ohio Athletic Trainers Association

Volume 3 | Issue 2

Article 5

December 2017

Idiopathic Obturator Internus Strain in a Collegiate Tennis Player: A Case Report

Stephen A. Cage

The University of Texas at Tyler, sacage@uncg.edu

Brandon J. Warner

Grand Canyon University, brandon.warner@gcu.edu

Follow this and additional works at: <https://scholarworks.bgsu.edu/jsmahs>



Part of the [Rehabilitation and Therapy Commons](#), and the [Sports Medicine Commons](#)

Recommended Citation

Cage, Stephen A. and Warner, Brandon J. (2017) "Idiopathic Obturator Internus Strain in a Collegiate Tennis Player: A Case Report," *Journal of Sports Medicine and Allied Health Sciences: Official Journal of the Ohio Athletic Trainers Association*: Vol. 3 : Iss. 2 , Article 5.

DOI: 10.25035/jsmahs.03.02.05

Available at: <https://scholarworks.bgsu.edu/jsmahs/vol3/iss2/5>

This Article is brought to you for free and open access by the Journals at ScholarWorks@BGSU. It has been accepted for inclusion in Journal of Sports Medicine and Allied Health Sciences: Official Journal of the Ohio Athletic Trainers Association by an authorized editor of ScholarWorks@BGSU.

Idiopathic Obturator Internus Strain in a Collegiate Tennis Player: A Case Report

Stephen A. Cage MED, LAT, ATC^{†‡}, Brandon J. Warner MEd, LAT, ATC^{‡‡}

The University of Texas at Tyler[†], Grand Canyon University[‡], University of North Carolina at Greensboro[‡]

Objective: Present a clinical case detailing the evaluation and treatment of an idiopathic obturator internus strain in a collegiate tennis player. **Background:** Isolated injury to the obturator internus muscle is uncommon. In cases that do present, patients often report a mechanism for injury involving falling or kicking. In previously reported cases, diagnosis is confirmed by magnetic resonance imaging. **Treatment:** Patient presented to the athletic training clinic complaining of left hip external rotator tightness and pain, and was unable to recall a mechanism of injury. Following the failure of conservative treatment, final diagnosis of a grade II obturator internus strain was made via magnetic resonance imaging. Using the confirmed diagnosis, the athletic training staff was able to progress strengthening and range of motion exercises until the patient returned to competition six weeks post injury. **Conclusion:** Obturator internus strains are possible causes of posterior hip pain and tightness. Currently, there are no reliable evaluation techniques for the obturator internus that do not involve diagnostic imaging. Further research needs to be conducted to determine if there are any signs and symptoms specific to obturator internus injuries. **Key Words:** *obturator internus, hip external rotator, idiopathic muscle strain.*

INTRODUCTION

The obturator internus is one of seven muscles classified as the deep external hip rotators. The obturator internus originates from the internal surface of the obturator membrane and obturator foramen and inserts on the lateral aspect of the greater trochanter of the femur.¹ Based off of electromyography (EMG) studies, the obturator internus assists with hip abduction and external rotation.² Though initially thought to also serve as a hip stabilizer, studies have called into question this action based off of EMG readings.² Obturator internus strains are a relatively rare injury, often associated with a kicking or traumatic mechanism.³⁻⁵ In all reported cases of the injury, diagnosis has been made using magnetic resonance imaging (MRI).³⁻⁵

Following diagnosis, a treatment and rehabilitation program incorporating rest and specific strength and range of motion exercises has demonstrated positive patient outcomes.³ However; researchers have noted the importance of accurate diagnosis for

achieving successful recovery.³ As previously mentioned, this currently can only be done using MRI.³⁻⁵

The purpose of this case report is to document the evaluation and treatment of a patient suffering from a grade II obturator internus strain with no known mechanism. Upon confirmed diagnosis, the patient was able to complete a targeted rehabilitation program and return to play. This case includes background information on the anatomy and pathology of obturator internus strains, descriptions of the evaluation process, and the subsequent rehabilitation that led to successful return to participation.

CASE REPORT

A 22-year-old collegiate women's tennis player presented to the athletic training clinic complaining of left posterior hip tightness and pain. The patient could not recall a specific mechanism of injury, but did state that she had remained in a crossed-legged seated position for several hours over the past

several days. The athletic training staff initially diagnosed the patient with gluteus maximus strain based off symptoms and weakness with resisted hip extension and external rotation. Patient was then treated with self myofascial release, stretching, active release techniques, and post activity icing. Following a week of treatment, patient reported that her symptoms had begun to worsen. The patient's pain had intensified to the point of causing antalgic gait and limitations with activities of daily living.

With the athletic training staff still working off the diagnosis of a gluteus maximus strain, the patient was removed from team activities. The patient's treatment program was modified to incorporate sensory transcutaneous electrical nerve stimulation (TENS) and exercises intended to improve strength and range of motion of the gluteus maximus. Shortly after the changes to patient's treatment program, her symptoms continued to worsen prompting referral to the team physician. Due to the level of the patient's pain, the team physician placed the patient on crutches and ordered an MRI and x-rays for further evaluation. MRI revealed what was described in the imaging report as a "severe tear of the obturator internus" (Figure 1). The team physician removed the patient from therapeutic exercise in favor of rest until symptoms began to resolve.

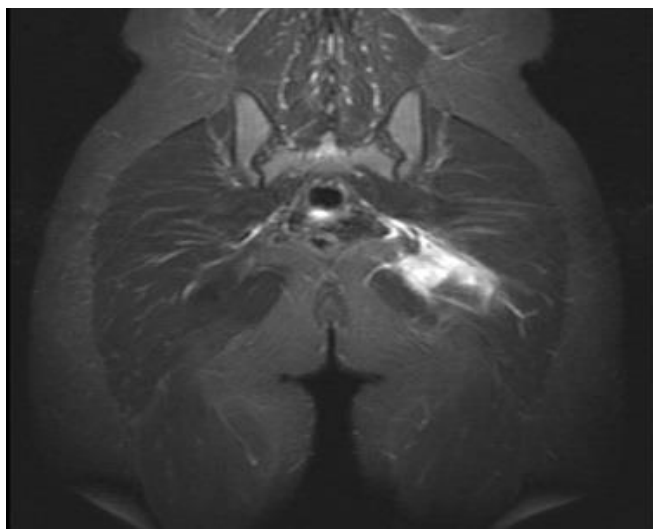


Figure 1. Magnetic resonance image of the patient's grade II obturator internus strain.

Following 10 days of rest and non-weight bearing ambulation the patient began to experience an increase in range of motion and decrease in pain. At this time, the patient was cleared to begin aquatic therapy and body weight exercises. At 22 days post diagnosis, the patient was able to begin light resisted lower body exercises incorporating resistance bands and ankle weights. By 28 days post diagnosis, the patient had discontinued crutches, and her symptoms continued to improve. At this time, she was able to initiate jogging and increase intensity of resistance exercises. 35 days after initial presentation, the patient was able to return to team practices, and the following week returned to competition. Throughout the remainder of the season, the patient was able to compete with no reported return of symptoms.

DISCUSSION

Isolated injuries to the obturator internus are rare.³⁻⁵ Generally these injuries have been the result of trauma or other sport related activity, primarily occurring in contact sports.³⁻⁵ Following these injuries, patients have had generally positive outcomes.³⁻⁵ However, targeted treatment can be delayed if MRI is not used to confirm the injured structures.

This case report describes the diagnosis, and treatment of a patient suffering from a grade II obturator internus strain. In this case, diagnosis was confound given the lack of known mechanism of injury. This delay in diagnosis may have in turn delay the patient's return to participation. However, it is unclear as to whether or not an MRI prior to the time it occurred would have been best practices given the location of pain and other related symptoms.

This patient was withheld from competition for six weeks prior to her return. This timeline is not particularly novel, but may have been shortened by earlier diagnosis.³ Upon returning to competition, the patient

experienced a lack of exacerbation of the previously reported symptoms.

CONCLUSION

Clinicians should be prepared to evaluate injuries based off signs and symptoms even if there is no known mechanism of injury. Clinicians should always monitor progress of their patients to ensure appropriate tissue healing is occurring and maintained throughout the injury continuum. In this report, the patient made a full recovery from a grade II obturator internus strain in a timeframe that was consistent with some reported cases.³ This report highlights the possibility of a deep hip external rotator strain mimicking the signs and symptoms of a gluteus maximus strain. Failure to refer for further evaluation in a timely fashion can result in multiple detrimental effects including loss of time in both sport and occupation.

While in this case the patient returned to play in a reasonable time frame given the extent of her injury, it is important to consider that the delayed diagnosis had the potential to keep the patient from returning to activity as quickly as possible. Until further research can be conducted to determine the appropriate threshold for referral of posterior hip muscle injuries, clinicians must use their expertise, experience and best judgement with regard to referring a patient with posterior hip pain for further evaluation.

REFERENCES:

1. Gray H. Muscles and fascia. In: Williams P, Warwick R, Dyson M, Bannister I. *Gray's anatomy*. Edinburgh, Churchill Livingstone; 1989.
2. Hodges PW, McLean L, Hodder J. Insight into the function of the obturator internus muscle in humans: Observations with development and validation of an electromyography recording technique. *J of Electromyography and Kins*. 2014;24:489-496.doi: <https://doi.org/10.1016/j.jelekin.2014.03.011>
3. Byrne C, Alkhatat A, O'Neill P, Eustace S, Kavanagh E. Obturator internus muscle strains. *Radiology Case Reports*. 2018;12;130-132.doi: <https://doi.org/10.1016/j.radcr.2016.10.020>
4. Khodae M, Jones D, Spittler J. Obturator internis and obturator externis strain in a high school quarterback. *Asian J of Sprt Med*. 2015;6(3):e23481.doi: <https://doi.org/10.5812/asjasm.23481>
5. Velleman MD, Jansen Van Rensburg A, Jansem Van Rensburg DC, Strauss O. Acute obturator internus muscle strain in a rugby player: a case report. *J of Sprt Med & Physical Fitness*. 2015;55(12):1544-6.