

The Dentoscope

Volume 16 | Issue 14

Article 2

5-1937

Reducing a Compound Mandibular Fracture: A Case Report

H. M. Proffitt

Follow this and additional works at: <http://dh.howard.edu/dentoscope>

 Part of the [Dentistry Commons](#)

Recommended Citation

Proffitt, H. M. (1937) "Reducing a Compound Mandibular Fracture: A Case Report," *The Dentoscope*: Vol. 16: Iss. 14, Article 2.
Available at: <http://dh.howard.edu/dentoscope/vol16/iss14/2>

This Article is brought to you for free and open access by Digital Howard @ Howard University. It has been accepted for inclusion in The Dentoscope by an authorized administrator of Digital Howard @ Howard University. For more information, please contact lopez.matthews@howard.edu.

SPECIAL ARTICLES

REDUCING A COMPOUND MANDIBULAR FRACTURE: A CASE REPORT*

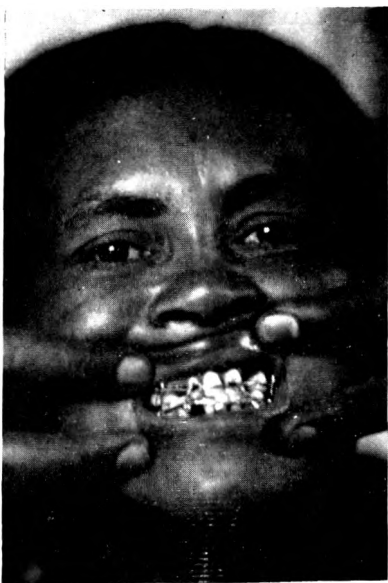
H. M. PROFFITT, D.D.S. '24

THE patient, a female, age 36, was seen first on July 5, 1935 at her home. Preliminary examination and consultation with her family physician revealed that she had suffered a compound fracture of the mandible and fracture of the clavicle near the acromio-clavicular joint. The reduction of the latter was accomplished by the physician.

Examination revealed an edema of the left side of the face, from the ear level down to the clavicular region, which was accompanied by intense pain. There was a slight swelling in the region of the chin on the left side. Crepitus was heard in the region of the fracture, which was located between the lower left canine and lateral incisor. Along the line of the fracture the tissue was lacerated both labially and lingually and by way of these lacerations, several fragments of bone were removed. No extractions were necessary, so a sedative was

administered and a saline mouth-wash prescribed until technical procedures could be completed.

Casts were made and the fracture reduced on the cast so as to reconstruct normal occlusal relationships. Anchor bands were applied to the first molars and a 23-gauge German silver wire was adapted to each dental arch, with loops arranged in the arch according to the method used by Dr. Leo Winter. These loops enable fixation of the two jaws, either by the use of elastics or wide ligatures. Although Winter recommends the elastics, I elected to use the brass wire ligatures (30 gauge).



* *Editors Comment:* We are pleased to present here an article from another of our graduates. The article expresses the personal views and experiences of the writer.

On the second day the arch wires were inserted and stabilized by ligating them to several teeth. Then by wiring the two arches together traction was exerted in such a way that complete reduction of the fracture was produced.

A liquid diet was prescribed and oral hygiene controlled as well as possible by a saline mouthwash. The swelling was reduced by application of cold compresses, and pain disappeared upon reduction of the fracture.

The appliances were removed during the seventh week with good results very apparent so far as healing, occlusion and facial contour are concerned.

Among the Practitioners as Seen on Tour

From WILLIAM J. MADISON, D.D.S.
Atlanta University
Atlanta, Ga.

To JACKSON DAVIS, D.D.S.
Howard University
Washington, D.C.

Dear Jack:

Remember I told you that I would keep in touch with you on the trip, so listen hard as I relate the happenings of the last few days.

As you know, we planned on leaving about six o'clock on the morning of November 6th, but it was raining so hard at that time that we hung around waiting for it to let up. It looked as if it had set in for the day so we finally pulled out around ten o'clock.

Our first stop was a Charlottesville, Va., with our good friend and National Secretary of the N.D.A., Dr. Jackson. He had assembled a group of high school boys at his house and we talked to them about the opportunities in the dental profession. After consuming one of Mrs. Jackson's delicious dinners, we headed for Lynchburg. We stopped there just long enough to have a conference with Dr. Wim-bush, then pushed right on through because we wanted to make Roanoke in time for a meeting which the Medical and Dental Society was having.

We arrived in Roanoke about nine o'clock and went directly to Dr. Paxton's house. We washed up and then attended a meeting at the

NOTE: These letters were written by Dr. Wm. J. Madison as he and Dean Dixon toured the South in the interest of dental education.