

5-1-1934

Wuchereria (Filaria) Bancrafti Infection in Man with an Unusual History

Hildrus A. Poindexter

Frank R. Jones

Follow this and additional works at: http://dh.howard.edu/med_fac



Part of the [Life Sciences Commons](#)

Recommended Citation

Poindexter, Hildrus A. and Jones, Frank R., "Wuchereria (Filaria) Bancrafti Infection in Man with an Unusual History" (1934). *College of Medicine Faculty Publications*. Paper 26.
http://dh.howard.edu/med_fac/26

This Article is brought to you for free and open access by the College of Medicine at Digital Howard @ Howard University. It has been accepted for inclusion in College of Medicine Faculty Publications by an authorized administrator of Digital Howard @ Howard University. For more information, please contact lopez.matthews@howard.edu.

133743

WUCHERERIA (FILARIA)
BANCROFTI INFECTION IN MAN
WITH AN UNUSUAL HISTORY

HILDRUS A. POINDEXTER, M.D., PH.D.

and

R. FRANK JONES, M.D.

Washington, D. C.

From the Department of Bacteriology, Preventive Medicine and Public Health and the Department of Surgery—Urological Section, Howard University School of Medicine and Freedman's Hospital

Reprinted from

THE JOURNAL OF LABORATORY AND
CLINICAL MEDICINE
St. Louis

Vol. 19, No. 8, Page 864, May, 1934.

(Printed in U. S. A.)

WUCHERERIA (*FILARIA*) *BANCROFTI* INFECTION IN MAN WITH
AN UNUSUAL HISTORY*

CASE REPORT

HILDRUS A. POINDEXTER, M.D., PH.D., AND R. FRANK JONES, M.D.
WASHINGTON, D. C.

THE occurrence of *Wuchereria* infection in a person who has remained within the vicinity of the District of Columbia all of his life is so unusual that we feel justified in reporting it.

We have not been able to discover all the links in the chain of circumstances leading to the infection. This, together with the usually accepted epidemiology of filariasis, while incidentally serving to remind the general practitioner of its possible occurrence in this part of the country, also serves to focus more interest of the entomologist on the way or ways in which the patient may have become infected. From an epidemiologic standpoint we thought of four possibilities: (1) a wider general distribution of species of mosquitoes generally known to serve as vector for this disease; (2) a special means of distribution by these same mosquitoes laying their eggs in the few centimeters of water frequently found in the bottom of the lifeboats on freighters coming from endemic ports with a crew, some of which may be carriers; the larvae from these eggs become mosquitoes in time to bite the crew and they, after the usual incubation period, infect persons in any subsequent port; (3) the common mosquito of this vicinity, which may assume the rôle of vector when in contact with carriers from an endemic area; (4)

*From the Department of Bacteriology, Preventive Medicine and Public Health and the Department of Surgery—Urological Section, Howard University School of Medicine and Freedman's Hospital.

Received for publication, July 24, 1933.

and lastly, some species of tick, which may serve as vectors. The last possibility is of interest chiefly because *Filaria perstans*, an organism very much like *Wuchereria bancrofti*, except that it does not have a sheath, is transmitted by a certain species of tick, and recently we have had an increase in tick (Eastern type of Rocky Mountain spotted) fever in this vicinity.

CASE REPORT

X. Y., a negro janitor, aged twenty-nine years, was admitted to Freedman's Hospital, May 15, 1933, with a chief complaint of progressive enlargement of the scrotum and right leg and foot with several areas of suppuration from the scrotal sac, one on the right buttock, and glandular enlargement and ulceration of the left axillary region.

The past history is important in that the patient has lived in Washington all of his life and has never travelled more than one hundred miles from Washington, and when he did leave the city, it was only for a short time, generally on fishing trips.

He has had measles, mumps, whooping cough, and eczema during childhood, but has otherwise enjoyed good health up to the beginning of the present illness. His appetite has remained good. He has used alcohol and tobacco in moderation, but no narcotics.

The only contacts which he can recall with the tropics or subtropical zones are: prior to the present illness he had worked as janitor for a family of Filipinos, then living in Washington; and his family at various times received packages, some of which contained plants, from relatives in Mississippi. The family history is essentially negative except for an almost complete progressive blindness in his father (cataract).

Present Illness.—About five years ago the patient, without any previous chill, fever or other symptoms of illness, began to have slight pains in the umbilical region. This continued for some time. Shortly after this he observed that his scrotum was enlarging. This continued, and about two weeks after the enlargement was noticed, two small areas of ulceration were observed where the scrotal walls rubbed against the thighs.

At this time his wife left him, accusing him of having some type of venereal disease.

He was treated by a private physician for about one year with various local and internal medications, but when the scrotum continued to enlarge, he was hospitalized for ten weeks at Gallinger Municipal Hospital. There, various studies and treatments were performed without any check of the progressive enlargement of the scrotum. They did not find microfilariae in the blood. His general condition of health was good up to the time of admission to Gallinger Hospital.

After leaving the hospital, he did not return to work because the size of the scrotum and the several areas of ulceration made walking more difficult.

For the last four years he has not worked nor received any systematic medical treatment. During this time the scrotum has continued to enlarge. Areas of suppuration have developed over the scrotum and areas of excoriation over the inner surface of the thighs where they rub against the scrotal wall. Glandular enlargement developed in the axillae with subsequent suppuration of the left axilla. About this time a small ulceration developed over the right buttock and about two years ago the right leg and foot began to enlarge and to become progressively rough.

In the light of the above progress he was advised by a member of the staff of Freedman's Hospital to come into the hospital for study. This he decided to do and was admitted May 15, 1933.

Physical Examination.—The general examination revealed a very obese negro male, weighing more than 350 pounds, without any evidence of marked discomfort or illness, who was in a jovial mood. The head and neck were normal. The chest and upper extremities, except for some glandular enlargement in each axilla and slight suppuration of the left axilla, were normal. The abdomen showed abundant adipose tissue.

Genital examination revealed a very greatly enlarged scrotum, appearing to weigh about 25 pounds. It was deeply pigmented here and there, nodular and hard in places. Other

areas reflected light due to the drying of serum which had oozed from its surface, while still others presented deep sinuses covered by a purulent exudate. Where the folds of pendulous abdominal fat met the fat on the anterior surface of the thigh on either side, the valleys of the inguinal regions presented ulcerated surfaces penetrated by tunneled sinuses. These showed a marked tendency to granulation. While the penis was completely invaginated within the overgrowth of scrotal tissue, there seemed to be a marked proliferation of prepubic tissue, which was unusually pendulous. There were areas of excoriation over the inner surface of each thigh, where the very much enlarged scrotum rubbed against them. The right buttock showed a small area of suppuration. The left leg and foot, except for the marked dryness and scales, were apparently normal. The right leg was larger around by two inches at the calf and knee than the normal leg. The right leg and foot showed scaling and pigmenta-

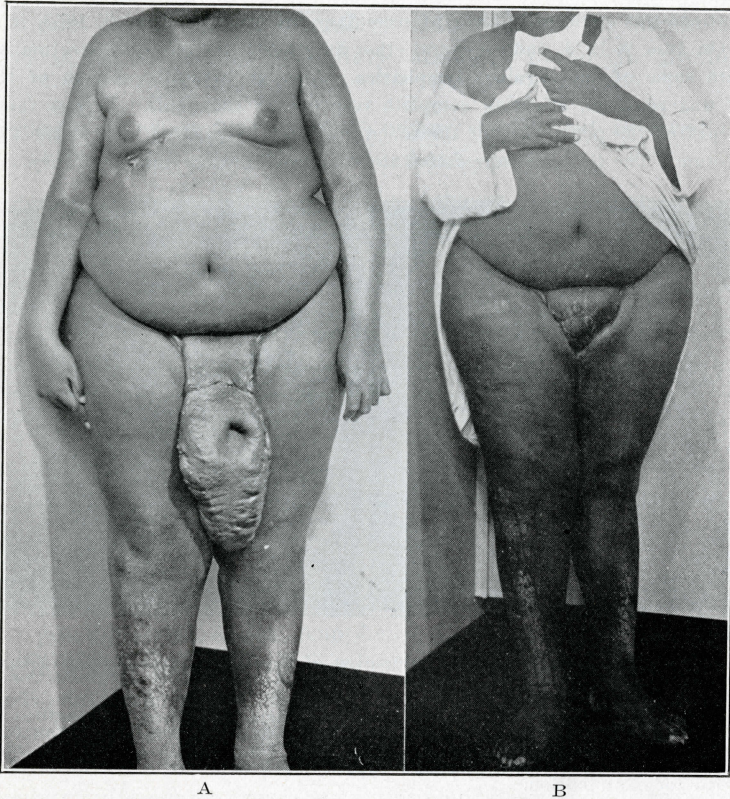


Fig. 1.—A, Before treatment. Measurements: Left, thigh 32 inches; knee 22 inches; calf $20\frac{1}{4}$ inches; ankle $14\frac{1}{2}$ inches. Right, thigh $32\frac{1}{2}$ inches; knee 24 inches; calf 22 inches; ankle 14 inches. B, After treatment.

tion together with a few shining areas in which serum appeared to be oozing. There was no definite ulceration of either limb.

A clinical diagnosis of elephantiasis was made by the staff.

Laboratory Examination.—Several thick smears of blood taken during the night, one at 9:15 P.M. and another at 10:30 P.M. on separate nights, showed microfilaria when stained by the Giemsa method. The coagulation time was five minutes. Red blood corpuscles 4,670,000; white blood cells 14,000. Differential: Small lymphocytes 36 per cent, large lymphocytes 25 per cent, large mononuclears 8 per cent, transitionals 6 per cent, polymorphonuclear neutrophils 20 per cent, eosinophiles 5 per cent. Blood Wassermann was negative. Urine showed no microfilariae, a few epithelial cells, and a positive indican test; otherwise nothing significant.

Stools were free from parasites, ova or larvae. Bacteriologic culture from several of the areas of ulceration and from some of the deep tissue removed at operation showed various micrococci, *Staphylococcus albus*, a nonhemolytic streptococcus, which fermented mannite and was considered to be *Streptococcus fecalis*; from one area there was a diphtheroid organism. The condition of the patient while in the hospital was uneventful. The earlier treatment consisted primarily of Sitz bath and mild local antiseptics in an attempt to clear up most of the secondary infection.

Attempts were made on two occasions to drain fluid from the enlarged scrotum. Several punctures with various sized needles failed to locate any definite pockets of fluid. We interpreted the enlarged scrotum to be due to chronic edema, and proliferation of the subcutaneous connective tissue secondary to this edema, the pathologic basis for which is the blocking of the lymph circulation.

The patient was sufficiently clear of secondary infection by June 2, 1933, to warrant an operation. On June 2, 1933, under general ether anesthesia, the enlarged scrotum was removed together with some of the inguinal lymphatics. Also an extensive section of the prepubic redundancy was removed, effecting complete recovery of the penis. It was found that the skin which covered the penis was not thickened, but only evaginated, due to the weight of the involved scrotum. The testicles were found to be normal in every respect. They were stripped

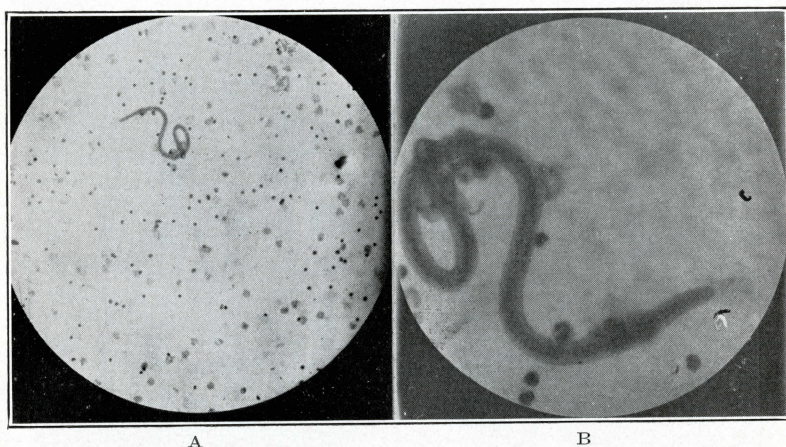


Fig. 2.—A. Shows a low-power magnification of the *Microfilaria* stained with hematoxylin as described above. B. Shows the same *Microfilaria* under a higher magnification.

The Technic of Preparation Was as Follows.—Slides were made from the centrifuged specimens of citrated blood, which had also been dehemoglobinized by distilled water. The residue was used for the smear. The smear was fixed in a solution containing equal parts of alcohol and ether for five minutes; stained with warm hematoxylin for eight minutes, decolorized for two seconds in 80 per cent alcohol to which had been added a few drops of hydrochloric acid and dried for examination.

of all of the proliferative tissue and covered in a new sac by joining the healthy skin of the perineum and inner side of the thigh to the normal skin covering the penis. For several weeks the penis was visible. Erection was noted on many occasions. Failure to remove sufficient subcutaneous tissue in the prepubic region encouraged the return of redundancy with resulting invagination of the penis. The patient had an uneventful convalescence from the operation. He was discharged from the hospital July 7, 1933, markedly improved, with instructions to return at intervals to the out-patient department for observation and further treatment.

DISCUSSION

In view of the nodular swellings under the arms and elsewhere, we were compelled to consider a probable onchocerciasis, a rare disease due to *Onchocerca volvulus*, a member of filaridae family, and transmitted by some gnat of the Simuliidae family.

The geographic distribution of the onchocerciasis, as well as the history of this case, made that solution highly improbable from the beginning, and the microscopic study of the microfilaria definitely ruled it out.

Clinically the case was one of elephantiasis. We therefore had to consider the etiology from three standpoints: infection with *Wuchereria bancrofti* and a secondary invader which some believe to be primarily responsible for the ulceration and much of the lymphatic blockage or elephantiasis of a nonparasitic type resembling the cases reported by Gager,¹ and others. While the works of O'Connor and Hulse,² and O'Connor³ seem to show that elephantiasis in *Wuchereria* infection may occur without secondary infection, we believe that this case is one in which the secondary infection by the streptococci and staphylococci is an important secondary etiologic factor in producing the syndrome.

The question of where and by what means the patient received the infection seems to be the most important consideration here.

Wuchereria bancrofti infection, while common in various areas throughout the tropics and subtropical belts, is most important as a United States menace because of its prevalence in the Islands and ports of the Caribbeans and its endemicity in Charleston, South Carolina. Man is the only proved intermediate host harboring the adult worms and the sexual phases, and the mosquito is the only proved definitive host in which complete development may take place, and is thus the vector of interest.

Since we have evidence that man cannot infect man directly, but that the microfilariae must undergo a certain period and complete certain stages of development in the mosquito before the infective form is produced and is thus ready to be transmitted to another person, the vector becomes the important problem here. There are at least four known genera of the order Diptera in which the complete development of the *Wuchereria bancrofti* is known to be possible: viz., *Aedes*, *Anopheles*, *Culex*, and *Mansonia*. There are several species under each of these genera in which the complete development of *Wuchereria* is known to be possible, but for all practical purposes in the United States only three species are important as vectors. They are *Culex fatigans*, common in the West Indies and South Carolina; *Anopheles (Nyssorhynchus) albimanus*, common in the Caribbean; and *Aedes variegatus*, common in the Pacific Islands. While such species as *Anopheles costalis* are very efficient vectors, a geographic consideration of its habitat, primarily confined to the West Coast of Africa, the small amount of travel and trade between those ports and North America and the long distance make it a vector of almost negligible consideration in this case. For many of the same reasons, *Aedes variegatus* becomes less likely as a vector in this case. Using the above methods of reasoning, we feel that the frequent contact between Baltimore and the Caribbean and Charleston, South Carolina, makes the *Culex fatigans* or *Anopheles albimanus* the most likely vector in this case.

The question of this man as a carrier and a menace is worthy of mention only to rule out the danger. As pointed out by Manson-Bahr,⁴ when fewer than one microfilaria were present in 2 c.c. of the patient's blood, the appro-

priate mosquito frequently failed to acquire infection. In this case, there was about one microfilaria per 3 c.c. of blood as averaged by our concentration method before operation and about one microfilaria per 5 c.c. of blood now. The usually accepted vectors are infrequent in this locality. We also know that some of the microfilariae are destroyed during their stay in the mosquito.

These facts together with the fact that both a male and a female must become lodged in the same area in man and then grow and develop their reproductive organs preparatory to bringing about a fecundated adult female parent before multiplication can take place, make this case insignificant as a danger. However, if the patient were more heavily infected, he would be a potentially dangerous carrier.

There is no accepted medication. Many clinics in the tropics report the trial and failure of various intravenous medications. I was impressed with the reports of success still claimed by the staff of the Municipal Hospital of Fredericksted, St. Croix, Virgin Islands, while visiting there during the summer of 1932. The other hospitals in various parts of the Caribbean did not report such results. While the surgical treatment selected in this case is primarily palliative and of no unusual significance, untold individual aid has been rendered this patient.

SUMMARY AND CONCLUSION

Wuchereria bancrofti infection may occur in persons living in the temperate zones who have not had any obvious contact with the commonly accepted vector. Such a case is here reported.

We wish to express our appreciation to Doctors William H. Taliaferro and Clay G. Huff of the Department of Parasitology, University of Chicago, for their opinion in regard to this species of *Microfilaria*, and to Dr. Porter B. Lennox of the Department of Pathology, School of Medicine, Howard University, for taking and developing the photomicrographs.

REFERENCES

1. Gager, L. T.: Lymphatic Obstruction: Non-parasitic Elephantiasis, *Am. J. M. Sc.* **166**: 200, 1923.
2. O'Connor, F. W., and Hulse, C. R.: Some Pathological Changes Associated With *Wuchereria Bancrofti* Infection, *Trans. Royal Soc. Trop. Med. & Hyg.* **25**: 445, 1932.
3. O'Connor, F. W.: The Etiology of the Disease Syndrome in *Wuchereria Bancrofti* Infections, *Trans. Royal Soc. Trop. Med. & Hyg.* **26**: 13, 1932.
4. Manson-Bahr, P. H.: Filariasis Due to *Filaria Bancrofti*. *Manson's Tropical Disease*, 506. 1925.