

A Study of 100 Cases of Acute Scrotum in Pediatric Age Group

Mohammed Jabbar Kadhem
 M. B. Ch. B. - F.I.C.M.S
 Al-Karama Teaching Hospital \ Kut –Iraq
 Iraq – Wasit Province \ Zubaidiya city

DR.HUSSEIN ALI ABED AHMAD
 (M.B.CH.B.F.I.C.M.S)
 Alkarama teaching hospital, Iraq –wasit province

Abstract

Introduction: acute scrotum swelling refers to condition of acute scrotum with or without pain

Aim of study: analysis of 100 cases of acute scrotal swelling regarding to age, causes, treatment.

Patient and method: prospective study of 100 cases of acute scrotal swelling in Alkarama teaching hospital in Alkut from pathology from the 1st of April 2015 till the 1st of August 2016.

Results: Age of incidence from birth to 10 years. 93% of cases are obstructed inguinal hernia.

Conclusion: Most common cause is inguinal hernia before one year. You should do surgery to emergent conditions at first 6 hours.

Keywords: acute scrotum, obstructed inguinal hernia, testicular torsion

1. INTRODUCTION

The term *acute scrotum* refers to acute scrotal pain with or without swelling and erythema. This presentation should always be treated as an emergency because of the possibility of testicular torsion and permanent ischemic damage to the testis. The etiology is generally age dependent. Most conditions are non-emergent, but prompt differentiation between testicular torsion and other causes is critical. Torsion of the appendix testis/epididymis is most common in prepubertal boys, whereas testicular torsion most commonly presents in neonates and adolescents.^{1*}

1.1 Differential Diagnosis of the Acute Scrotum

- 1- Torsion of the testis. 2- Torsion of the appendix testis/epididymis.
- 3- Epididymitis/orchitis.
- 4- Hernia/hydrocele. 5-Trauma/sexual abuse. 6-Tumor.
- 7- Idiopathic scrotal edema (dermatitis, insect bite).
- 8- Cellulitis. 9- Vasculitis (Henoch-Schönlein purpura).^{1*}

1.2 INCIDENCE AND ASSOCIATIONS

Hernia and hydrocele occur in approximately (1–3%) of full-term infants but are three times more common in premature infants.^{2,3} With regards to hernia, the male to female ratio is (5 to 1). A hernia/hydrocele occurs more often on the right than left (2:1).^{1**} Ten percent of children with a hernia/hydrocele will have a positive family history. Approximately one-third of the children with a hernia/hydrocele will be diagnosed before 6 months of age. An increased incidence of hernia/hydrocele is seen in patients with cystic fibrosis (15%),⁴ connective tissue disease such as Ehlers–Danlos syndrome and Hunter–Hurler syndrome,^{5,6} and congenital hip dislocation.⁷ Children with a ventriculoperitoneal (VP) shunt or on continuous ambulatory peritoneal dialysis (CAPD) are also at higher risk of developing a hernia/hydrocele.⁸

1.3 Embryology and pathophysiology: -

- In the male fetus, the testes develop from the cranial end of the mesonephros. The gubernaculum forms from a band of condensed mesenchyme, connecting to the lower pole of each testis.⁹
- The passage through the inguinal canal takes approximately 3 days and appears to be regulated by the genitofemoral nerve and the release of the calcitonin gene-related peptide (CGRP).^{13,14}
- The testes enter the scrotum between the (32nd and 38th) weeks of gestation; in some patients, this process may be delayed up to the 40th week of gestation. After the descent of the testes, the entrance to the inguinal canal, the internal ring, closes and the lumen of the PV is obliterated. Progressive fibrous obliteration of the PV occurs in a cephalad direction, beginning above the epididymis.¹⁵

Presentation and Diagnosis: -

Children with a hernia/hydrocele often present with:

- A history of a painless lump or bulge in the groin, scrotum. In younger children, this bulge may be

- more obvious while the child is crying, straining. In older children, the hernia/hydrocele often gets larger during the day and smaller at night or during time of recumbency.
- Occasionally, a child may present with symptoms similar to that of acute testicular torsion, resulting from torsion of the hernia sac.^{21,22}
 - Approximately 10% of patients with an inguinal hernia present to medical attention with symptoms of bowel obstruction such as nausea, vomiting, abdominal distention, or localized or generalized abdominal tenderness.²³ Physical examination
 - Bowel can be palpated or heard during manipulation of the inguinal or scrotal bulge in patients with a hernia.
 - A silk glove sign can be detected on examination, as the layers of PV can be felt around the spermatic cord, feeling like silk rubbing on silk.²³ Unfortunately, this physical finding is very inaccurate in the absence of finding an obvious hernia/hydrocele.²⁴
 - The diagnosis can be made by clinical history and physical examination. In those few patients in whom the diagnosis cannot be well established, further radiologic examination may be helpful.
 - Ultrasonography (US) is widely used in evaluating inguinal and scrotal pathology. In patients with a hernia, fluid- or air-filled loops of bowel may be identified in the inguinal canal or scrotum. When there is omental herniation, a hyperechoic mass can be seen.
 - Herniography has been utilized in the diagnosis of a hernia.²⁸ Iothalamate solution (60%) is injected into the peritoneum. a KUB or a computed tomography (CT) scan is obtained to identify contrast lining the patent PV/hernia sac.^{29,30} Because of potentially serious complications such as bowel injury, contrast reaction, and peritoneal irritation, its use is limited to special circumstances such as in evaluating chronic groin pain.^{31,32}

Hydroceles: -

A frequent issue is whether the presence of a hydrocele in an asymptomatic infant indicates an inguinal hernia. If the hydrocele was not present at birth, or dramatically changes in size (communicating hydrocele), a PPV is present. Massive hydroceles and those extending along the length of the inguinal canal may also require operation. Static hydroceles that fail to reabsorb also indicate a PPV. Our practice is to observe these hydroceles until the child is 1 year of age. Excision of the hydrocele sac is not necessary. The fluid is evacuated, and the distal sac is opened widely. Large or thick sacs may be everted behind the cord (Bottle procedure) if necessary.^{1**}

Testicular and appendiceal torsion: -

Definition and incidence: -

- **Torsion of the testis** results from twisting of the spermatic cord, which leads to a compromised testicular blood supply and subsequent testicular infarction. The consequent ischemic damage affects long-term testicular morphology and sperm formation. However, there is generally a (4 - 8) hour window before significant damage occurs.^{1*}
- More commonly in adolescents, testicular torsion involves torsion of the spermatic cord within the tunica vaginalis (**intravaginal torsion**). Owing to abnormal fixation of the testis and epididymis, the testis is freely suspended within the tunical cavity. This (**bell clapper deformity**) allows the testis to adopt a horizontal position in the scrotum It is found in (12%) of testes at postmortem, and frequently occurs bilaterally.⁴⁴ It is the most common etiology of torsion in adolescents, in whom rapidly increasing testicular mass associated with puberty increases the chance of the testis rotation. Intravaginal testicular torsion can also occur intermittently, spontaneously twisting and untwisting.⁴⁵

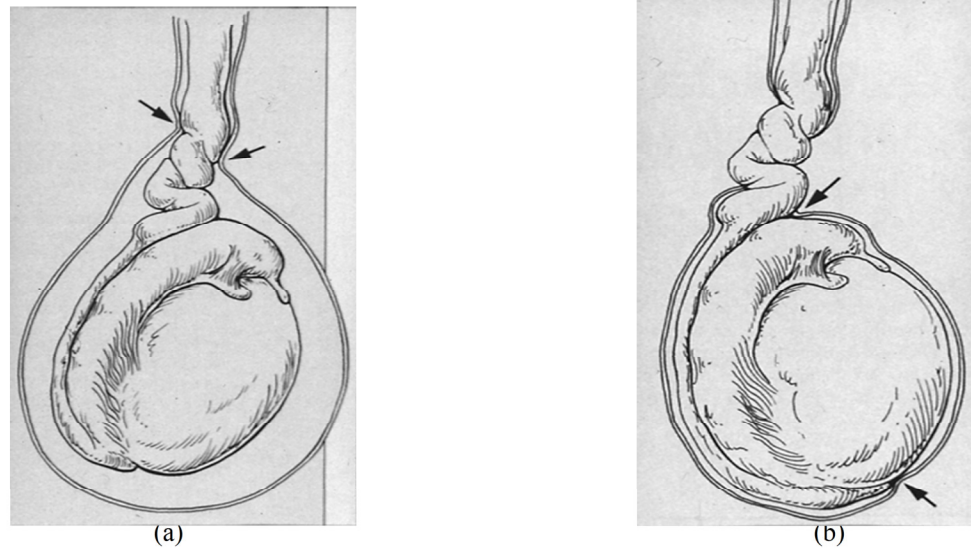


Figure 1: Testicular torsion; a- Intra vaginal and b- Extra vaginal.

Presentation and diagnosis: -

- Typically, **adolescents with intravaginal testicular torsion** will present with acute onset of severe scrotal pain. In a series of 670 patients with acute testicular torsion, 89% of the patients presented with a complaint of acute-onset ipsilateral testicular pain.⁴⁸ The remaining patients presented only with pain referred to the ipsilateral lower abdomen, groin, or thigh. The majority of these patients were later found to have torsion in the undescended testis. Associated trauma and recent exercise was seen in 4% and 10% of the patients, respectively. About 11% of the patients were awakened from sleep with pain. Nausea and vomiting were associated with testicular torsion in 39% of the patients, whereas urinary symptoms such as dysuria and urgency were usually absent (<5%). Interestingly, 36% of the patients had a previous history of testicular pain or swelling. A prior history of ipsilateral orchiopexy does not exclude the diagnosis of testicular torsion. Inadequate fixation or the development of single adhesions forming an axis for the testis to twist has been observed in patients with a prior history of orchiopexy who presented with a recurrent testicular torsion.⁴⁹

Physical examination of the torsed testis is often very difficult due to the severity of the pain. Important signs of testicular torsion include a firm testicle high-riding in the scrotum, an abnormal transverse orientation of the testis, and the absence of a cremasteric reflex.⁵⁰

Intermittent testicular torsion has a similar presentation to that of intravaginal torsion, except that the episode is self-limited with resolution of symptoms after the cord spontaneously untwists

Patients with **extravaginal neonatal torsion** typically present with painless swelling and scrotal discoloration. A firm testis with an associated hydrocele is often noted incidentally on newborn examination or during diaper change. Patients with **appendiceal torsion** can also present with pain similar to those with intravaginal testicular torsion. However, the presentation for appendiceal torsion can be quite variable, from an insidious onset of scrotal discomfort to acute severe scrotal pain. At the earlier stages, the pain may be localized to the upper pole of the testis or epididymis, and a firm nodule can sometimes be palpated in this region of the scrotum. The pain is more often of a gradual onset rather than developing acutely, and associated symptoms such as nausea, vomiting, and abdominal pain are unusual.

- **Color or power Doppler US** or **99mTc-radioisotope scintigraphy** may be obtained to evaluate testicular blood flow. Both of these tests depend on the availability of equipment and personnel. False-negative results can occur with any of the above modalities. Color Doppler US studies can assess the anatomy of the scrotum and its content, while determining the presence or absence of testicular blood flow (as measured by velocity). The sensitivity of color Doppler US is reported to be as high as 90%, with a specificity of 99%.⁵¹
- **Radionuclide imaging** was originally the study of choice for ruling out testicular torsion. However, it only allows for the assessment of blood flow. Its positive predictive value has been reported to be around 75%, with a sensitivity of 90% and a specificity of 89%.⁵⁴

Treatment: -

When we suspect testicular torsion in a patient, surgery should be done without delay. **Manual detorsion** may be tried if surgical intervention cannot be done for a period of time. The testis should be turned caudal to cranial, and medial to lateral. Consequently, **surgical intervention** is still required

following manual detorsion.⁵⁶ **Fixation** can be accomplished by securing the testis to the septum or placement into a dartos pouch. For **trans-septal fixation**, the scrotum is opened through an incision in the median raphe. For the **pouch fixation**, the incision is made transversely following the skin creases of the scrotum. **Exploration of the contralateral testis** should also be performed and, in all cases, the contralateral testis must be fixed.

- **The treatment of neonatal torsion** is controversial. Some clinicians suggest that surgical exploration is unnecessary, whereas others advocate immediate surgical exploration and fixation of the contralateral side. It is rare to salvage the affected testis in a patient with unilateral neonatal torsion; out of more than 30 cases of bilateral neonatal torsion reported in the literature, only two testicles have been successfully salvaged.⁵⁶ Important reasons for exploration are to exclude tumor and to prevent possible unilateral torsion from becoming bilateral anorchia.⁴⁵
- In the rare case of bilateral **neonatal torsion**, a more conservative approach can be taken. The newborn's general condition and anesthetic considerations should be evaluated to determine whether or not to proceed with surgical intervention.⁵⁷
- The treatment of **twisted testicular appendages** is non-surgical if the diagnosis is certain. Conservative therapy with limitation of activity, scrotal elevation, and administration of non-steroidal analgesics is highly effective. Most of the symptoms will dissipate once the acute changes of acute necrosis resolve. In rare instances, surgical exploration may be undertaken if conservative management fails. Simple excision of the torsed appendage is curative.

2. Aim of the study: -

The aim of our work is to analyze one hundred case of acute scrotum in pediatric age group (Birth-10 years) regarding a specific objective, which include: -

- 1- Age at presentation, the clinical features the patient presented with, the duration of symptoms before admission and the laterality.
- 2- Different etiologies of acute scrotum.
- 3- The treatment (operative or conservative), the specific surgical approach and complications.

3. PATIENTS & METHODS: -

- We record 100 patients in pediatric age group, from (Birth- 10 years) who were admitted to ALkarama Teaching Hospital with a diagnosis of acute scrotal/testicular pathology from the 1st of April 2015 till the 1st of August 2016. The case notes were examined in detail, recording the age of the patient; etiologies; presenting symptoms; duration of symptoms before seeking medical attention management and complications. in addition to the history of irritability, scrotal swelling, abdominal pain, fever, vomiting, and dysuria. The physical examination findings reviewed were the presence of an inguinal mass ; scrotal erythema, edema or ecchymosis ; tenderness localized to the affected hemiscrotum ;contra lateral undescended testis; Blue dot sign and orientation of the testicle within the scrotum. Laboratory and radiographic data included results of a urinalysis, blood samples for white blood cell count, Doppler US, erect abdominal XR and the pathological diagnosis (if performed). All patients underwent surgery that used a transverse inguinal incision entering the symptomatic hemiscrotum for exploration.
- In **patients with Testicular Torsion:-** the torsion was relieved and the testicle was placed in warm, moist sponges for (15 to 20) minutes; if the testis was obviously nonviable, it was removed. If the testis was reperfused or fresh bleeding can be seen from the cut surface, it was re placed in the scrotum and fixed with an non absorbable suture. The contralateral testis fixation was performed also(dartos pouch fixation).
- In **an obstructed inguinal hernia:-** Manual reduction was tried if short duration of obstruction; if long duration of obstruction or manual reduction failed so surgery is the choice. Through an inguinal incision the hernial sac opened and the hernial neck was laterally released , the content examined and if bowel present it was placed in warm , moist sponges for (15 to 20) minutes ; if gangrenous bowel present resection with end to end anastomosis was done ; if reperfusion occur reduction was performed, and the testis examination and management had done as above.
- In **encysted hydrocele**; evacuation with ligation of an obliterated tunica vaginalis was done.
- In cases of **Epididymitis/orchitis** and **Hematocele** conservative treatment was used(scrotal elevation, antibiotics and analgesia) .

4. RESULTS: -

I-Clinical Assessment: -

a-Causes of acute scrotum: -

Our study included 100 case of acute scrotum, the vast majority of them are diagnosed as obstructed inguinal hernia, epididymitis/orchitis = , encysted hydrocele , testicular torsion ,and hematocele as illustrated in (Table1).

TABLE(1): CAUSES OF ACUTE SCROTUM.

Causes of acute scrotum	NO. (%)
Obstructed inguinal hernia	93(93%)
Epididymitis / Orchitis	3(3%)
Encysted hydrocele	2(2%)
Testicular torsion	1(1%)
Hematocele	1(1%)

Total No. =100

b-Age distribution:-

The majority of cases that admitted and operated on, were in their 1st year of life = 76 % (24% in the 1st month and 52% in the other eleven months), etc... as summarized in (Figure 2).

The age ranged = (5 days – 8.4 years) .

The Mean age = 12.1 months .

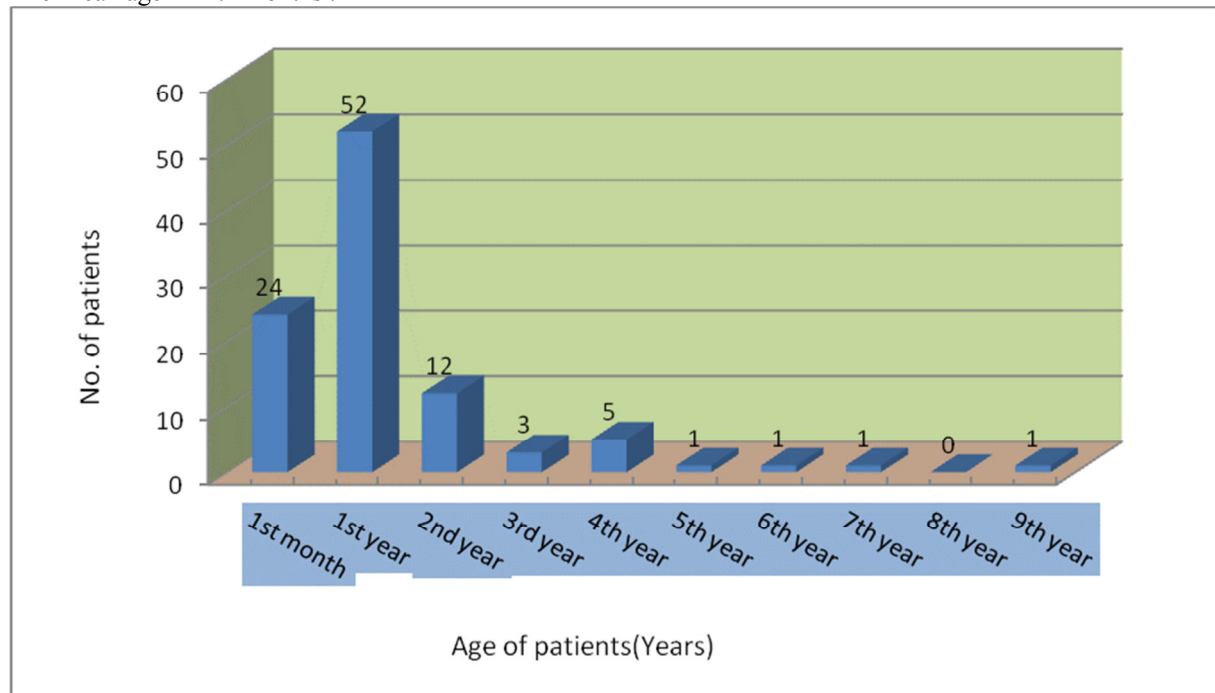


Figure 2: AGE AT PRESENTATION.

II-TREATMENT:-

The conservative treatment to an obstructed inguinal hernia was slightly higher than the operative approach (surgical exploration) as illustrated in (Figure 3).

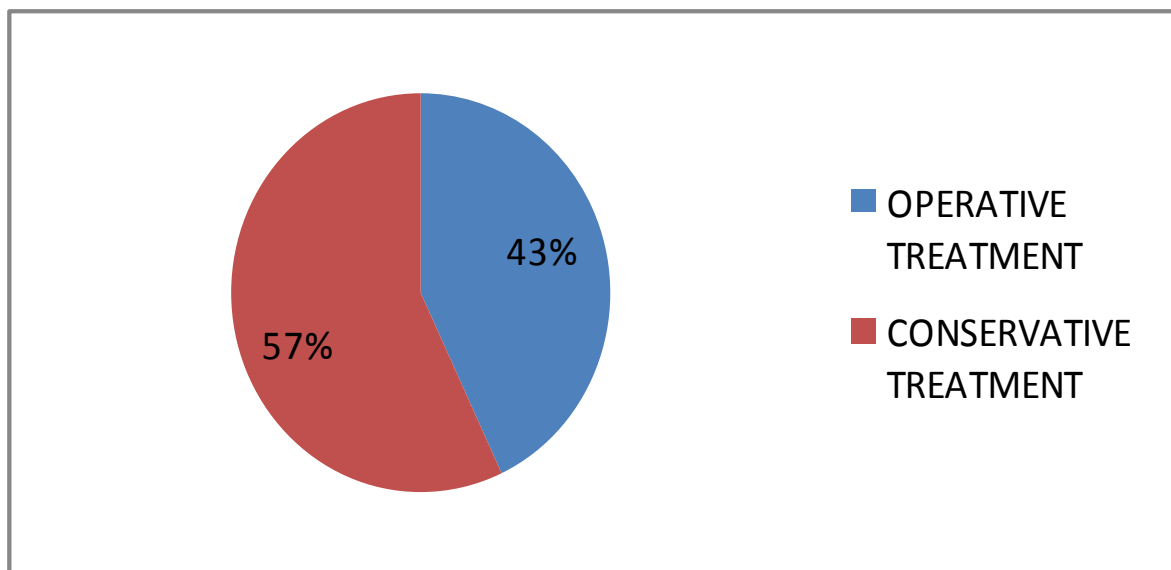


Figure 3: TREATMENT APPROACH.

III-COMPLICATIONS:-

Most commonly postoperative hematoma and hydrocele followed by gangrenous testis, gangrenous bowel, and wound infection as illustrated in (Figure 4).

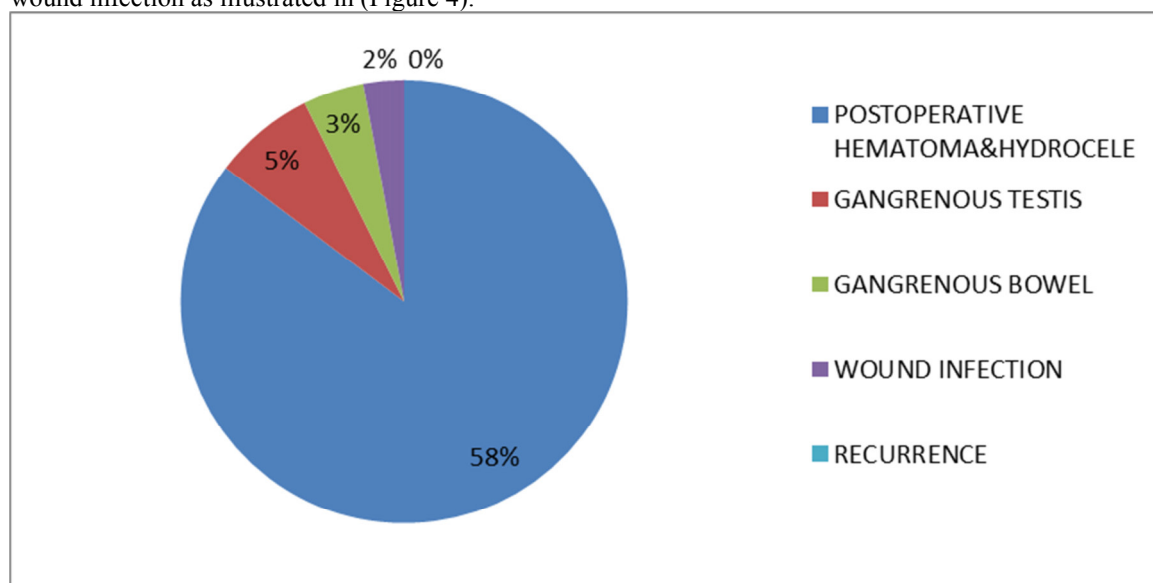


Figure 4: COMPLICATIONS OF ACUTE SCROTUM.

5. DISCUSSION

In children, acute scrotal pain and swelling is a common reason for surgical consultation in the emergency department.⁵⁸ Although obstruction of inguinal hernias may occur at any age in childhood, this complication is most common in the first six months of life, particularly in babies born preterm, even if the hernia presents in later years. In infancy, it is estimated that up to 50 per cent of hernias may present with an episode of incarceration. Regrettably, nearly half of such cases could have been prevented by expeditious surgery.⁵⁹

In our study the majority of cases were diagnosed and treated as obstructed inguinal hernia = (93%) as a cause of acute scrotum which is followed by epididymitis/orchitis=(3%), encysted hydrocele=(2%), testicular torsion=(1%) and hematocele=(1%), which is differ from other series as in a study done by Ahmad Khaleghnejad-Tabari, et al 2010⁽⁶⁰⁾ which give us the results below:-

Torsion of testis = (31%), obstructed inguinal hernia =(30%) Torsion of testicular appendages=(27%), Epididymitis/ orchitis=(7%), Idiopathic scrotal edema = (4%), Hematocele =(1%).

Where the most common cause is the testicular torsion followed by obstructed inguinal hernia, torsion of testicular appendages. This difference (in Testicular torsion cases number) is may be due to the referral of the testicular torsion directly to the urosurgery department within the medical city complex without our consultation.

The age prevalence was mostly in the 1st year of life followed by the 2nd year, 4th year, 3rd year etc..., and The age range = (5 days – 8.4 years). The mean age = (12.1) months, which is similar to other series in the high prevalence of cases of acute scrotum in the 1st year and specifically in the 1st six months of life, As seen in E. Mäkelä, T, et al 2007⁽⁶¹⁾.

The **affected side** was mainly the right side cases and this is well known fact in that In the first decade of life, inguinal hernia is more common on the right side in the male, there is no doubt associated with the later descent of the right testis and a higher incidence of failure of closure of the processus vaginalis⁽⁶²⁾. The **delay in presentation** was obvious in our series which can lead to the complications as testicular loss and/or bowel gangrene. And this results is similar to the work of the Chao Yang, et al 2011⁽⁶³⁾. The most frequent **clinical presentation** are the irritability, scrotal swelling, vomiting, abdominal pain, fever, tenderness and inguinal mass, so careful history and precise physical examination were needed for correct diagnosis and optimal management of such critical problem.

As a **treatment approach** In our study we found that the successful conservative management to an obstructed inguinal hernia (manual reduction + iv fluid + antibiotics + near date for surgery etc...) is slightly more than the operative treatment (surgical exploration) which used for unrelieved cases, in spite of this we should not delay the operative treatment if no possibility of reduction or a delay of presentation more than 6 hours to avoid the loss of the testes and/or bowel. The most frequent **complications** are postoperative hematoma & hydrocele followed by gangrenous testis, gangrenous bowel and wound infection; so some studies suggest early surgical exploration^(64,65), as we did for the indicated patients in our study; for the purpose of salvage the testes and/or bowel. And our results are better than other series such as the work of Imran Mushtaq, Mary Fung And Martin j. Glasson 2003 were the gangrenous testis(orchietomy)= 12%.⁽⁶⁶⁾

In addition, the postoperative wound infection is low and the recurrence of an inguinal hernia was nil in our study due to the meticulous surgical technique practiced in our center.

6. Conclusions

- 1-The most frequent cause of acute scrotum in our department is an obstructed inguinal hernia in infancy.
- 2-The cases of acute scrotum should be explored as early as possible as an emergency if the presentation of the patient to the hospital is delayed or in doubtful diagnosis for the purpose of testicular and bowel salvage within or even beyond the golden 6 hours.

7. Recommendations

- 1- Special programs for public society teaching about the problem and the necessity of early medical consultation.
- 2- Teaching courses should be arranged for the general practitioners and pediatricians who are first see the patient and deal with him about the correct diagnosis of this problem and early referral to avoid the disastrous complications.
- 3- The inguinal hernia (and other etiologies) in infancy and childhood should be operated on as early as possible to avoid the risk of obstruction and other complications so urgent and proper managements of the cases by the specialized pediatric surgery centers and avoidance of any unnecessary delay.

References

- 1*. Charles M., John M. Acute scrotum. IN George W., Patric Murphy J. Ashcraft Pediatric surgery. 5th edition, 2010; 687-691.
- 1**. Charles L. Inguinal hernia and hydroceles. IN George W., Patric Murphy J. Ashcraft Pediatric surgery. 5th edition, 2010; 669-675.
2. Rowe MI, Marchildon MB. Inguinal hernia and hydrocele in infants and children. Surg Clin North Am 1981; 61(5):1137-45.
3. Boocock GR, Todd PJ. Inguinal hernias are common in preterm infants. Arch Dis Child 1985; 60(7):669-70.
4. Holsclaw DS, Shwachman H. Increased incidence of inguinal hernia, hydrocele, and undescended testicle in males with cystic fibrosis. Pediatrics 1971; 48(3):442-5.
5. McEntyre RL, Raffensperger JG. Surgical complications of Ehlers-Danlos syndrome in children. J Pediatr Surg 1977; 12(4):531-5.
6. Reed WB, Horowitz RE, Beighton P. Acquired cutis laxa. Primary generalized elastolysis. Arch Dermatol 1971; 103(6):661-9.
7. Uden A, Lindhagen T. Inguinal hernia in patients with congenital dislocation of the hip. A sign of general connective tissue disorder. Acta Orthop Scand 1988; 59(6):667-8.
8. Grosfeld JL, Minnick K, Shedd F et al. Inguinal hernia in children: factors affecting recurrence in 62 cases. J Pediatr Surg 1991; 26(3):2837.
9. Taylor GP. Pathology of the pediatric regio inguinalis: mysteries of the hernia sac exposed. Pediatr Dev Pathol

2000; 3(6):513–24.

10. Rosai J, Dehner LP. Nodular mesothelial hyperplasia in hernia sacs: a benign reactive condition simulating a neoplastic process. *Cancer* 1975; 35(1):165–75.
11. Heyns CF. The gubernaculum during testicular descent in the human fetus. *J Anat* 1987; 153:93–112.
12. Tanyel FC, Dagdeviren A, Muftuoglu S et al. Inguinal hernia revisited through comparative evaluation of peritoneum, processus vaginalis, and sacs obtained from children with hernia, hydrocele, and undescended testis. *J Pediatr Surg* 1999; 34(4):552–5.
13. Clarnette TD, Hutson JM. Exogenous calcitonin gene-related peptide can change the direction of gubernacular migration in the mutant trans-scrotal rat. *J Pediatr Surg* 1999; 34(8):1208–12.
14. Cook BJ, Hasthorpe S, Hutson JM. Fusion of childhood inguinal hernia induced by HGF and CGRP via an epithelial transition. *J Pediatr Surg* 2000; 35(1):77–81.
15. Momoh JT. Obliteration of processus vaginalis and inguinal hernial sacs in children. *Can J Surg* 1982; 25(5):483–5.
16. Barthold JS, Redman JF. Association of epididymal anomalies with patent processus vaginalis in hernia, hydrocele and cryptorchidism. *J Urol* 1996; 156(6):2054–6.
17. Tanyel FC, Muftuoglu S, Dagdeviren A, Kaymaz FF, Buyukpamukcu N. Myofibroblasts defined by electron microscopy suggest the dedifferentiation of smooth muscle within the sac walls associated with congenital inguinal hernia. *BJU Int* 2001; 87(3):251–5.
18. Tanyel FC, Erdem S, Buyukpamukcu N, Tan E. Smooth muscle within incomplete obliterations of processus vaginalis lacks apoptotic nuclei. *Urol Int* 2002; 69(1):42–5.
19. Tanyel FC, Ulusu NN, Tezcan EF, Buyukpamukcu N. Total calcium content of sacs associated with inguinal hernia, hydrocele or undescended testis reflects differences dictated by programmed cell death. *Urol Int* 2003; 70(3):211–15.
20. Tanyel FC, Okur HD. Autonomic nervous system appears to play a role in obliteration of processus vaginalis. *Hernia* 2004; 8(2):149–54.
21. Matsumoto A, Nagatomi Y, Sakai M, Oshi M. Torsion of the hernia sac within a hydrocele of the scrotum in a child. *Int J Urol* 2004; 11(9):789–91.
22. Myers JB, Lovell MA, Lee RS, Furness PD 3rd, Koyle M. Torsion of an indirect hernia sac causing acute scrotum. *J Pediatr Surg* 2004; 39(1):122–3.
23. Brisson P, Patel H, Feins N. Cremasteric muscle hypertrophy accompanies inguinal hernias in children. *J Pediatr Surg* 1999; 34(9):1320–1.
24. Gilbert M, Clatworthy HW Jr. Bilateral operations for inguinal hernia and hydrocele in infancy and childhood. *Am J Surg* 1959; 97(3):255–9.
25. Rathaus V, Konen O, Shapiro M et al. Ultrasound features of spermatic cord hydrocele in children. *Br J Radiol* 2001; 74(885):818–20.
26. Ring KS, Axelrod SL, Burbige KA, Hensle TW. Meconium hydrocele: an unusual etiology of a scrotal mass in the newborn. *J Urol* 1989; 141(5):1172–3.
27. Erez I, Rathaus V, Vacian I et al. Preoperative ultrasound and intraoperative findings of inguinal hernias in children: a prospective study of 642 children. *J Pediatr Surg* 2002; 37(6):865–8.
28. Swischuk LE, Stacy TM. Herniography: radiologic investigation of inguinal hernia. *Radiology* 1971; 101(1):139–46.
29. Nadkarni S, Brown PW, van Beek EJ, Collins MC. Herniography: a prospective, randomized study between midline and left iliac fossa puncture techniques. *Clin Radiol* 2001; 56(5):389–92.
30. Markos V, Brown EF. CT herniography in the diagnosis of occult groin hernias. *Clin Radiol* 2005; 60(2):251–6.
31. Calder F, Evans R, Neilson D, Hurley P. Value of herniography in the management of occult hernia and chronic groin pain in adults. *Br J Surg* 2000; 87(6):824–5.
32. Heise CP, Sproat IA, Starling JR. Peritoneography (herniography) for detecting occult inguinal hernia in patients with inguinodynia. *Ann Surg* 2002; 235(1):140–4.
33. Burd RS, Heffington SH, Teague JL. The optimal approach for management of metachronous hernias in children: a decision analysis. *J Pediatr Surg* 2001; 36(8):1190–5.
34. Shimbori H, Ono K, Miwa T et al. Comparison of the LMA-ProSeal and LMA-Classic in children. *Br J Anaesth* 2004; 93(4):528–31.
35. Passariello M, Almenrader N, Canneti A et al. Caudal analgesia in children: S(+)-ketamine vs S(+)-ketamine plus clonidine. *Paediatr Anaesth* 2004; 14(10):851–5.
36. Broadman LM. Use of spinal or continuous caudal anesthesia for inguinal hernia repair in premature infants: are there advantages? *Reg Anesth* 1996; 21(6 Suppl):108–13.
37. Surana R, Puri P. Iatrogenic ascent of the testis: an under-recognized complication of inguinal hernia operation in children. *Br J Urol* 1994; 73(5):580–1.

38. Imamoglu M, Cay A, Sarihan H, Ahmetoglu A, Ozdemir O. Paravesical abscess as an unusual late complication of inguinal hernia repair in children. *J Urol* 2004; 171(3):1268–70.
39. Johnstone MS. Inguinal hernia repair. In: Stringer MD, Oldham KT, Mouriquand PDE, Howard ER, eds. *Pediatric Surgery and Urology: Long Term Outcomes*. Philadelphia: WB Saunders, 1998: 257–63.
40. Kurkchubasche AG, Tracy TFJ. Unique features of groin hernia repair in infants and children. In: Fitzgibbons RJJ, Greenburg AG, eds. *Nyhus and Condon's Hernia*, 5th edn. Philadelphia: Lippincott, 2002: 435–51.
41. Read RC. Recent advances in the repair of groin herniation. *Curr Probl Surg* 2003; 40(1):13–79.
42. Schier F, Montupet P, Esposito C. Laparoscopic inguinal herniorrhaphy in children: a three-center experience with 933 repairs. *J Pediatr Surg* 2002; 37(3):395–7.
43. Shalaby R, Desoky A. Needlescopic inguinal hernia repair in children. *Pediatr Surg Int* 2002; 18(2–3):153–6.
44. Caesar RE, Kaplan GW. Incidence of the bell-clapper deformity in an autopsy series. *Urology* 1994; 44(1):114–16.
45. Das S, Singer A. Controversies of perinatal torsion of the spermatic cord: a review, survey and recommendations. *J Urol* 1990; 143(2):231–3.
46. Barca PR, Dargallo T, Jardon JA et al. Bilateral testicular torsion in the neonatal period. *J Urol* 1997; 158:1957–9.
47. Melekos MD, Asbach HW, Markou SA. Etiology of acute scrotum in 100 boys with regard to age distribution. *J Urol* 1988; 139(5):1023–5.
48. Anderson JB, Williamson RC. Testicular torsion in Bristol: a 25-year review. *Br J Surg* 1988; 75(10):988–92.
49. Thurston A, Whitaker R. Torsion of testis after previous testicular surgery. *Br J Surg* 1983; 70(4):217.
50. Rabinowitz R. The importance of the cremasteric reflex in acute scrotal swelling in children. *J Urol* 1984; 132:89–90.
51. Baker LA, Sigman D, Mathews RI, Benson J, Docimo SG. An analysis of clinical outcomes using color Doppler testicular ultrasound for testicular torsion. *Pediatrics* 2000; 105(3):604–7.
52. Bader TR, Kammerhuber F, Herneth AM. Testicular blood flow in boys as assessed at color Doppler and power Doppler sonography. *Radiology* 1997; 202:559–64.
53. Lee FT Jr, Winter DB, Madsen FA et al. Conventional color Doppler velocity sonography versus color Doppler energy sonography for the diagnosis of acute experimental torsion of the spermatic cord. *AJR Am J Roentgenol* 1996; 167:785–90.
54. Levy OM, Gittelman MC, Strashun AM, Cohen EL, Fine EJ. Diagnosis of acute testicular torsion using radionuclide scanning. *J Urol* 1983; 129(5):975–7.
55. Kiesling VJ Jr, Schroeder DE, Pauljev P, Hull J. Spermatic cord block and manual reduction: primary treatment for spermatic cord torsion. *J Urol* 1984; 132(5):921–3.
56. Cooper CS, Snyder OB, Hawtrey CE. Bilateral neonatal testicular torsion. *Clin Pediatr* 1997; 36:653–6.
57. Cuckow PM, Frank JD. Torsion of the testis. *BJU Int* 2000; 86(3):349–53.
58. Kass EJ, Lundak B. The acute scrotum. *Pediatr Clin North Am*. 1997;44(5):1251Y1266.
59. Ewen A, Mac Kinnon. *Herniae and Hydroceles*. IN. David M., Mervyn D., Henric A. *Pediatric surgery* 2nd edition, 2005 ;303.
60. Khaleghnejad-Tabari A., Mirshermirani A. and Rouzrokh M. Early Exploration in the Management of Acute Scrotum in Children . *Iranian Journal of Pediatrics*, Volume 20 (Number 4), December 2010, Pages: 466-470
61. Mäkelä E., Lahdes-Vasama T., Rajakorpi H.. *A 19-year review of paediatric patients with acute scrotum*. *Scandinavian Journal of Surgery* 96: 62–66, 2007.
62. Andrew N., Giorgi G., and David H. , *Hernias, umbilicus and abdominal wall*. IN Norman S., Christopher J. and Ronan P. , *Baily & Love Short practice of surgery*. 25th , 2008, 971.
63. Yang C. , Song B. , Liu X. et al. Acute Scrotum in children. *Pediatric surgery care*. April 2011; 27(4) :270-274.
64. Varga J, Zivkovic D, Somer D, et al. Acute scrotal pain in children– ten years experience. *Urol Int* 2007;78(1):73-7.
65. Mirshemirani AR, Ghorobi J, Roozroukh M, et al. Urogenital tract abnormalities associated with congenital anorectal malformation. *Iran J Pediatr*. 2008;18(1):171-4.
66. Mushtaq I. , Fung M. AND Martin J. Glasson. RETROSPECTIVE REVIEW OF PAEDIATRIC PATIENTS WITH ACUTE SCROTUM. *ANZ J. Surg*. 2003; 73 : 55–58.