

## Role of Echo Doppler in Diagnosing the Testicular Torsion-Retrospective Study

Baton Kelmendi<sup>1\*</sup> Hysni Jashari<sup>1</sup> Fisnik Kurshumliu<sup>2</sup> Doruntina Bunjaku<sup>3</sup> Sokol Buba<sup>4</sup>  
 Marinela Kumaraku<sup>5</sup>

1. Pediatric Surgeon-Department of Pediatric Surgery/University Clinical Center of Kosova
2. Pathologist-Institute of Pathology. Medical School/University Clinical Center of Kosova
3. Anesthesiologist-Department of Anesthesia and Intensive Care/University Clinical Center of Kosova
4. Pediatric Surgeon, Mother Teresa University Hospital Centre and Professor at U. of Medicine Tirana
5. Pediatrician, Mother Teresa University Hospital Centre, Tirana, Albania

### Abstract

**Introduction:** Acute scrotum is a wide term that is used for cases that presenting with scrotal swelling and pain. Etiology can be infectious or strangulation from torsion of the testis, depending on its clinical diagnosis, requires surgical intervention or medical treatment. **Aim of study:** Aim of this study was to determine the rate of accuracy of the Echo Doppler scanning in the diagnosis of the testicular torsion. Considering that there are different protocols in diagnosis, some suggest surgical exploration, while some Hospitals report 100% accuracy in diagnosis of testicular torsion with Doppler ultrasound. **Materials and methods:** We retrospectively evaluated 4 year period, from 2011-2014, during this time all the patients that were admitted as acute scrotum where evaluated excluding the cases that were incarcerated hernias. In all admitted patients, physical examination, lab analysis and Echo Doppler study were performed. **Results:** In total, there were 83 patients, based on physical examination, lab and Echo Doppler scan, 50 cases were diagnosed as epididymo-orchitis, 21 cases were patients with testicular torsion and 12 cases were torqued hydatid of Morgagni. In 3 patients false positive blood circulation in affected testis was detected with Echo Doppler scan. In following days they were operated and gangrene of testis was found. **Discussion:** Complete absence of intratesticular blood flow and normal extratesticular blood flow on color Doppler images is diagnostic, if the flow is normal in the contra lateral testis. Color Doppler has a very high accuracy in detecting the obstacles in blood flow, but as with other diagnostic techniques, this should be not taken as granted. **Conclusion:** Testicular torsion is real urological emergency. Delay in diagnosis and management can lead to the loss of the testis. If there any doubts are present, urgent surgical exploration is indicated.

**Keywords:** Testicular torsion, acute scrotum, echo Doppler, diagnostic techniques, management

### Introduction

Acute Scrotum is a potentially emergency condition and is characterized with pain, redness and testicular edema. The term acute scrotum in Urology is analog with the term acute abdomen that is used in General Surgery. Scrotal pain and edema could arise from different pathologies like: Ischemic, traumatic, Infection and hernias. Twisting or torsion of the testis results in occlusion of the gonadal blood supply, which, if unrelieved, leads to necrosis. Torsion of the testis was first described in 1840 by Delasieve[1]. Torsion of a testicular appendage was first described by Cole [2]. Although it is not the most common cause of the acute scrotum in childhood, it is certainly the most important. Torsion of testis usually occurs in a fully descended testis and is surgical emergency because of the high incidence of gonadal necrosis. Extratunical or extravaginal torsion is less common and is confined to the perinatal period, beyond the newborn period, testicular torsion is almost always associated with the bell-clapper deformity. Trauma and physical activity may be important, as may action of the cremaster muscle[3]. Clinical presentation of testicular torsion is usually heralded by the sudden onset of pain in the testis, lower abdomen, or groin, associated with nausea and vomiting. A horizontal lie of the testis when the boy stands indicates high investment of the spermatic cord. Unless the testis and epididymis are necrotic, local palpation is exquisitely painful.

Proper anamnesis and physical examination are crucial and usually determining treatment, whether conservative or surgical.

Imagery studies usually supplement the clinical diagnosis. With Doppler scan being the first choice, it's quick, cheap and accurate.

Low percentage of surgical exploration is acceptable for minimizing critical misdiagnosis.

### Results and Discussion

Main challenge in pediatric surgery is differentiation between ischemic and infective pathology. Anamnesis and physical examination have important role in diagnosing, and for the imagery study in general is Echo Doppler scan. With high degree of suspicion, surgical exploration is mandatory.

Epididymo-orchitis which as a pathology is commonly encountered usually is consequence of infection

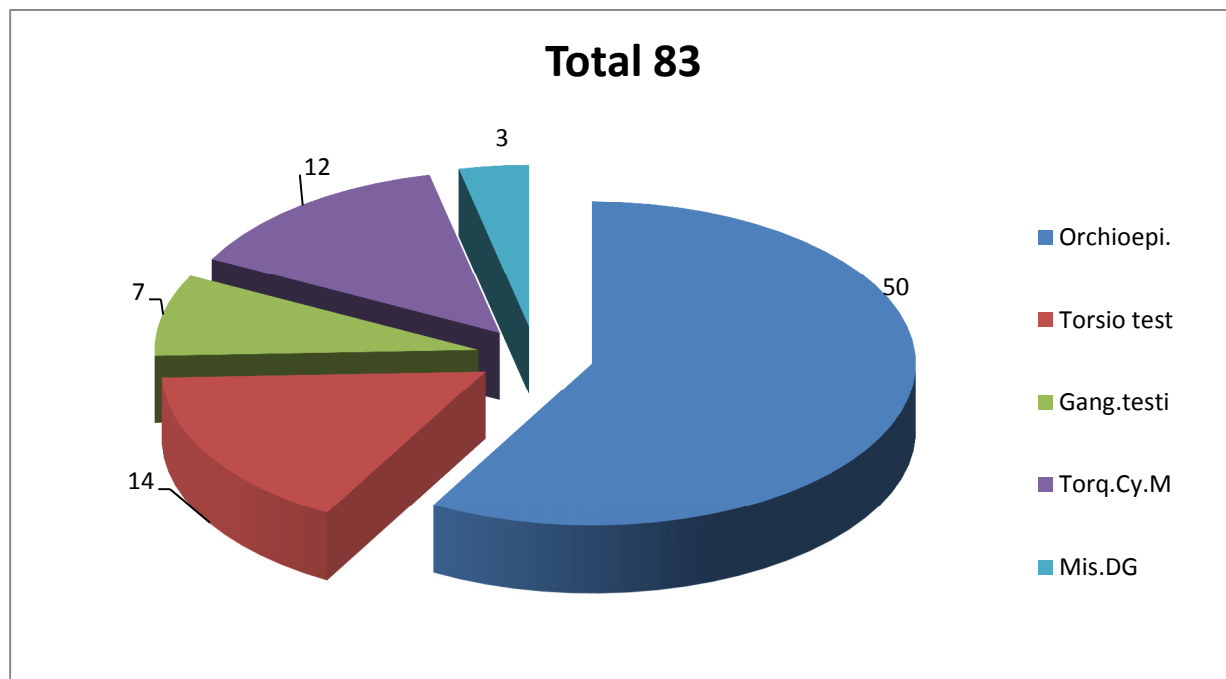
and it is presented with pain, edema, and redness due to superficial hyperthermia, while the testicular torsion (figure 1) has lower incidence but is potentially much more serious condition, with symptoms: sharp pain that can first occur in lower abdomen or groin, and later on can be localized in affected testis, all this can be accompanied by nausea or vomiting. In cases where acute ischemia is present, delay in diagnosis and intervention can lead to a testicular gangrene. Depending on the number of twists, necrosis may occur after as little as 2 hours [4]. Careful anamnesis, especially type of pain, localization, intensity and if it is accompanied by nausea helps in diagnosis, while from the imagery studies in our clinic we prefer Doppler scan.

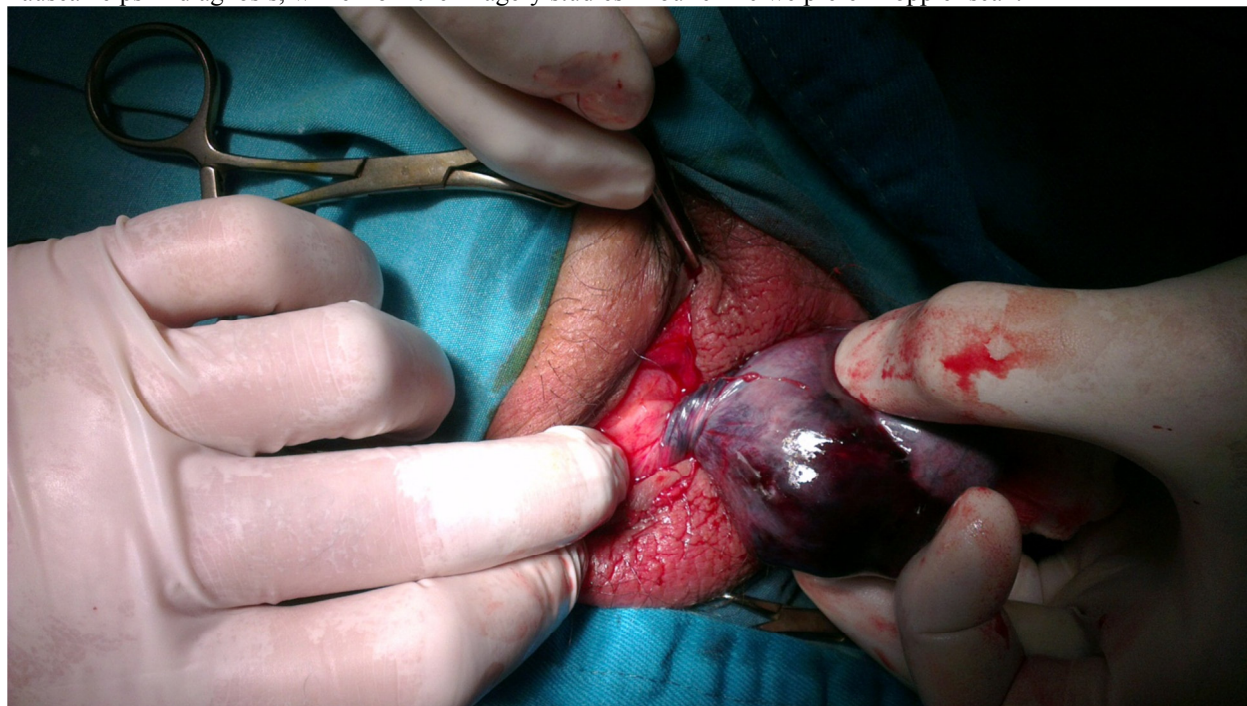

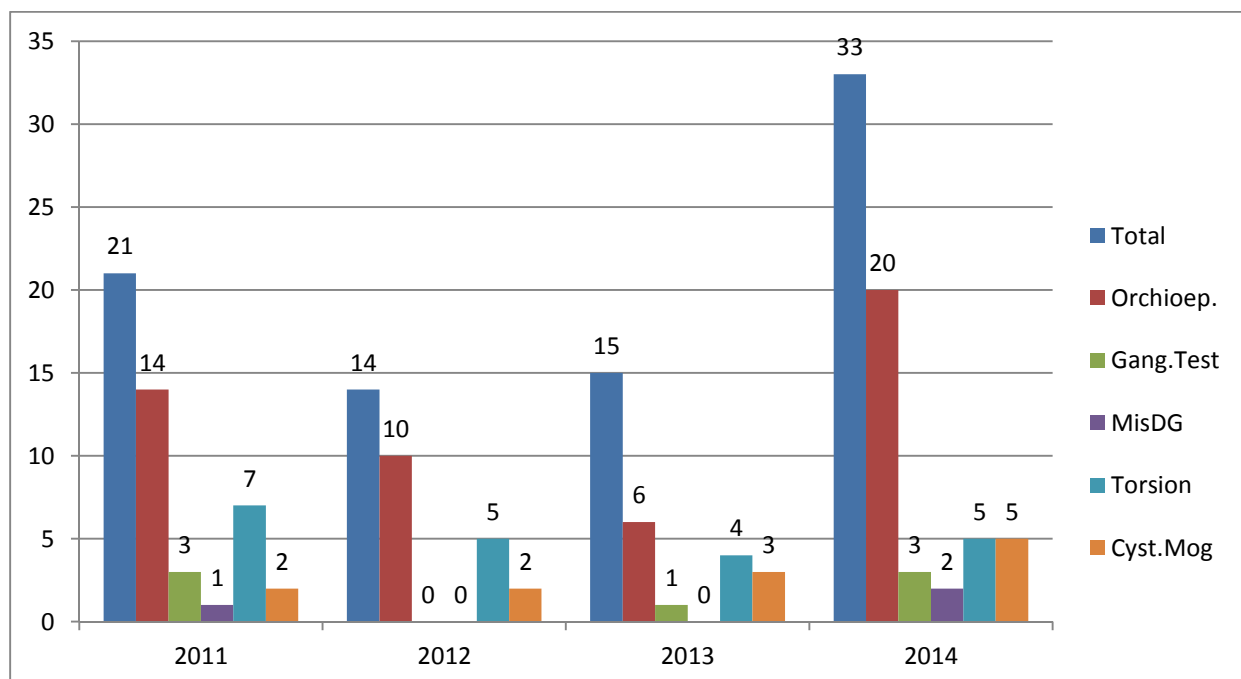
Figure 1. Testicular torsion with subsequent Testicular gangrene (Department of Pediatric Surgery-University Clinical Center of Kosova)

Treatment of testicular torsion is operative. A midline incision is made in the scrotum, and the hemiscrotum is opened with diathermy. The testis is delivered through the incision if there is evidence of torsion of the gonad itself. If the testis is twisted, this is untwisted and the viability assessed. In prepubertal child, this maneuver is usually easy, and circulation returns within few minutes. In the postpubertal testis, particularly when there has been some secondary hemorrhage, viability may be difficult to determine, in this cases it may be better to observe testis for several minutes. The contralateral hemiscrotum should always be explored and fixated when torsion of the testis has been found because the anomaly usually is bilateral. Inadequate fixation with absorbable sutures may result in recurrent torsion [5], [6]. If necrotic testis is encountered, orchiectomy is performed. There is good evidence that testicular ischemia damages the blood-testis barrier and exposes the child older than 10 years of age to the potential risk of autoimmunization against his own spermatogonia [7].

In our clinic during the period of 2011-2014, 83 patients were admitted with primary diagnosis of acute scrotum, data showed in graph 1 and 2. After the physical examination, lab analysis and imagery studies, 50 patients were treated as epididymo-orchitis, 21 were diagnosed as testicular torsion and underwent surgery, in 7 cases we encountered testicular gangrene, 3 due to miss diagnosis with Doppler scan and 4 patient visited doctor 24 hours or more after the symptoms started, 12 cases were torsion of hydatid of Morgagni.



Graph 1. Total cased showed in this graph, and cases of each diagnosis.



Graph 2. This graph shows respective diagnoses for respective years.

Our favorite imaging method for diagnosis was Doppler scan and the results are as following: from 83 patients, orchietomy due to gangrene was performed in 7 patients, 3 were as a result of misdiagnosis (false positive blood circulation detected with Doppler), and 4 patients presented in Emergency Department 24 hours after the symptoms started, one was neonate.

According to the literature and statistics from the well-known pediatric surgery centers around the world the accuracy of the Doppler scan can be as 100% in cases with testicular torsion and 70.6% in epididimo-orchitis [8]. From our data we confirm sensitivity and specificity of 96% for testicular torsion. The experience of radiologist is crucial in detecting the ischemic events.

**Conclusion:**

In our experience and after collecting data during the four year period, we conclude that despite a better

diagnostic and imagery opportunities, despite the low number of miss diagnoses, having in mind grave consequences in the cases where the operation is delayed, demand that when any doubts are present, gold standard is surgical exploration.

### References

1. Delasiauve L J F: Descent tardive du testicule gauche, prisé pour une hernie étranglée. Rev Med Fr Etrang 1840;1:363.
2. Colt GH: Torsion of hydatid of Morgagni. Br J Surg 1922;9:464.
3. LrHorhi H, Manunta A, Rodriquez A, lobel B: Trauma induced testicular torsion. J Urol 2002;168:2548.
4. Sonda LP, Lapidés J: Experimental torsion of the spermatic cord. Surg Forum 1961;12:502.
5. May RE, Thomas WEG: Recurrent torsion of the testis following previous surgical fixation. Br J Surg 1980;67:129.
6. Thurston A, Whitaker R: torsion of the testis after previous testicular surgery. Br J Surg 1983;70:217.
7. Puri P, Barton D, O'Donnell B: Prepubertal testicular torsion: subsequent fertility. J Pediatr Surg 1985;20:598.
8. Agrawal et al: Role of the Ultrasound with color Doppler in acute scrotum management. L family Med Prim Care (2014), Oct-Dec;3(4):409-12.