

# Hepatoprotective Effect of Royal Jelly Against Cisplatin-Induced Biochemical, Oxidative Stress, Anti-Oxidants And Histopathological Abnormalities

Hanan Abdelhamid Abdelhafiz<sup>1</sup>, Attalla Farag El-kott<sup>2,3\*</sup> and Mohamed Rabea Elesh<sup>1</sup>

1. Biochemistry Dept., Faculty Of Science, Beni-Suef University, Egypt

2. Deanship Of Scientific Reseaech, King Khalid University, KSA

3. Zoology Dept., Faculty Of Science, Damanhour University, Egypt

\* E-mail of the corresponding author: [elkottaf@yahoo.com](mailto:elkottaf@yahoo.com), [elkottaf@kku.edu.sa](mailto:elkottaf@kku.edu.sa)

## Abstract

The study aimed to evaluate the changes of liver functions, oxidative stress, anti-oxidants and histopathological investigations in Cisplatin-induced hepatotoxicity and the royal jelly ameliorative effects. The forty male mice were divided into 4 groups. The first group was control, Group II: animals were received royal jelly (150 mg/kg), Group III: animals were received cisplatin (3.5 mg/kg body weight of Cisplatin once every 2 days), group IV: animals were received the royal jelly + Cisplatin, for 10 days. At the end of experiment Blood was collected and analyzed for blood alanine aminotransferase (ALT), aspartate aminotransferase (AST), Albumin. The Liver samples were stored for the measurement of malondialdehyde (MDA), total antioxidant and catalase (CAT) activities and another hepatic tissues were processed for histopathology. Cisplatin given to mice induced a marked hepatic injuries, characterized with a significant increase in serum ALT, AST and MDA and lower albumin, total antioxidant, and CAT activities. In the groups that were administered royal jelly in association with cisplatin, improvement was observed in oxidative stress parameter (MDA), other hepatic biochemical parameters, and histopathological examinations with royal jelly being more effective. The results obtained suggested that royal jelly significantly attenuated the cisplatin-hepatotoxicity, because it act as free radical scavenger and lipid peroxidation inhibitor.

**Keywords:** Cisplatin; Royal jelly; Antioxidants; Hepatotoxicity

## 1. Introduction

Drugs Cytotoxic used in chemotherapy cause side-effects for normal cells in addition to the devastation and prevention of proliferation of cancer cells (Mihelic, 2005). In addition to its therapeutic effects, also chemotherapy produces pain, vomiting, nausea, anorexia, alopecia, cachexia, mucositis, depression, impaired taste, dehydration, and anxiety (Coates et al., 1983; Giordano & Jatoi, 2005). These side-effects are mostly temporary and are preventable or can be minimized with appropriate treatment and care (Coates et al., 1983). Lack of suitability rule of side-effects causes patients to give up the chemotherapy (Mollaoğlu & Erdoğan, 2014).

Cisplatin is a platinum-coordinated complex-based anticancer chemotherapy drug used against several human cancers (Adams, 1996). Despite the fact of its effective anti-cancer action, it exerts many unwanted adverse effects including hepatotoxicity, ototoxicity, nephrotoxicity, spermiotoxicity myelo-suppression, and emetogenesis (Hassan, Chibber, & Naseem, 2010). The renal toxicity of cisplatin has been known but little is known about Cisplatin-induced liver injury. Hepatic toxicity is not considered as a dose limiting toxicity for cisplatin, but hepatic toxicity can occur when the anti-cancer drug is administered at high doses (Zicca et al., 2002). Some studies have reported the importance of oxidative stress in cisplatin-induced toxicity including liver (Yousef, Saad, & El-Shennawy, 2009). Studies have suggested that oxidative stress might be generated in the pathogenesis of Cisplatin-induced toxicity (Mansour, Hafez, & Fahmy, 2006). The free radicals especially oxygen species (OS) have been suggested as a causative agent for death of the cell in many different pathological phases and in different models of toxic liver failure including cisplatin (Ahmed, Omar, Ragb, & Nasser, 2011).

Several natural products occurring antioxidants influence the antioxidant enzymes and provide protection against oxidative stress for free radical-induced cell damage, thereby causing hepatic diseases (Waseem, Pandey, Tomar, Raisuddin, & Parvez, 2014). Royal Jelly (RJ) is a secretion of mandibular and hypopharyngeal glands of Honey bees workers. Royal jelly is used to feed temporarily the brood of workers and drones but it is a unique food of the bee queen for both her larval and adult life span. Royal jelly for years has been widely used in Asia and Europe as healthy food, folkish cosmetic or medical product to promote longevity. It has been manifested to have many pharmaceutical activities such as: antimicrobial, disinfectant action, anti-hypercholesterolemic, antioxidant, anti-inflammatory, anti-hyperglycemic and anti-tumor activity that may be responsible for assisting the health welfare through aging. Royal jelly (RJ) also has hepatoprotective effects (Kanbur et al., 2009) and anti-oxidant (El-Nekeety et al., 2007). Royal jelly has been designed to contain the glycoprotein (57-kDa) which is considered to stimulate hepatic tissues regeneration and hepatocyte development (Zimmermann, 2002). The present study was done to assess the effects of administration of royal jelly in mice with cisplatin-induced hepatic toxicity.

## **2. Materials and Methods**

### **2.1. Experimental animals**

Forty healthy adult male Swiss albino mice, weighing  $25.0 \pm 2.0$  g, 50 – 60 days old, were obtained from the animal house of the National Cancer Institute (NCI), Cairo University, Egypt. The animals were kept under standard environmental conditions on 12 hours light/dark cycle under a constant temperature of  $(25 \pm 1)^{\circ}\text{C}$ , and a relative 50–60% humidity. Free access to water and food was allowed at experimental period. Mice were acclimatized to conditions of laboratory for one week prior to experiments. Mice were housed five/cage in the sterilized plastic cages.

### **2.2. Experimental design**

The forty mice were randomized and divided into four groups as follows:

Group I: Control group was injected once every 2 days from day 1 to 10 with 0.2 mL saline solution intraperitoneally.

**Group II:** Royal jelly group was given orally once daily at royal jelly doses at 150 mg/kg (Inoue et al., 2008).

**Group III:** Cisplatin mice group was injected intraperitoneally by 3.5 mg/kg body weight with cisplatin once every 2 days (Liao et al., 2008).

**Group IV:** Royal jelly + Cisplatin mice group was given orally once daily at royal jelly doses of 150 mg/kg for 10 consecutive days from day 1 to 10, then 3.5 mg/kg body weight of Cisplatin was inoculated intraperitoneally once every 2 days in the same period.

### **2.3. Chemicals (Reagents)**

All reagents used in this study were analytical of the purest grades. All glasses and plastic wares were washed with acid and detergent, and washed with distilled water.

#### **2.3.1. Cisplatin**

Cis-platinum (II)-diammine dichloride (CIS, lot. No. 1028, batch #3400956225392, Mylan, Germany) 1 mg/ml was obtained from Oncotec pharma production GmbH Am pharmapark 06861 Dessau-RoBlau-Germany.

#### **2.3.2 Royal Jelly**

Soft Gelatinous Capsules (1000 mg/Capsule) was obtained from pharco pharmaceuticals Company, Alexandria-Egypt, and kept at temperature not exceeding 30°C until use. Each capsule contains lyophilized Royal Jelly (6%) 10-HAD 340 mg (equivalent to 1000 mg Crude Royal Jelly). 150 mg/kg RJ aliquots were dissolved in distilled water and administered orally for 10 consecutive days to groups of royal jelly, Cisplatin+Royal jelly mice.

### **5- Weight**

Animal weight was calculated and evaluated at the first day of Cisplatin administration and the final day of the experiment.

### **2.4. Dissection of animals**

At the end of the study, the animals were fasted overnight and maintained under light ether anesthesia, sacrificed by cervical dislocation, and samples were collected from each animal into tubes both with and without anticoagulants. The liver dissected out, part of the liver tissue was transferred into 10% buffered formalin for histopathology, and the another part of hepatic tissue was used for the analysis of antioxidant and oxidative stress markers.

### **2.5 Blood and tissue samples collection**

Blood was drawn from all 10 animals in each group and centrifuged at 3000 rpm for 10 minutes. Plasma and Serum samples were stored at 0°C until biochemical analysis liver functions (AST, ALT and Albumin). Liver was removed, cleared from adhering connective tissue; and homogenized for 10 sec in a Polytron, after being mixed with phosphate buffer, pH 7.0, in an ice-containing medium. The homogenates were centrifuged at 19,000 rpm at 4°C for 30 min and the supernatants obtained were transferred into eppendorf tubes, and preserved at -80°C in a deep freezer until used for lipid peroxidation Malondialdehyde (MDA) and antioxidant enzymes (Total antioxidants and catalase) analysis (Maldonado et al., 2003). The another part of liver was fixed in 10% formalin for histopathological examination (Barrera et al., 2003).

### **2.6 Statistical Analysis**

The data were analyzed using one-way analysis of variance (ANOVA) followed by LSD computers to compare various groups. Results were expressed as  $\text{mean} \pm \text{SD}$ .

### 3. The results

#### 3.1. Toxicity symptoms

The Cisplatin toxicity symptoms were observed on the first day showed slight toxic symptoms. These include inactiveness, loss of appetite, slow movement, all these lead to decrease in the body weight. After the cisplatin administration, variety of clinical signs were observed such as decrease food and water intake, diarries nerves, brittleness of skin hair and, after that highly decrease in body weight, the highly significant difference in body weight was observed between different groups when compared with control group as shown in table 1.

**Table (1): The animal weight changes in different experimental animals**

Groups	1 <sup>st</sup> weight (g)	Final weight (g)
Control	22.50 $\pm$ 1.29	21.50 $\pm$ 3.87
RJ	22.60 $\pm$ 1.67	22.60 $\pm$ 3.36
CP	25.75 $\pm$ 4.34	14.75 $\pm$ 0.50*
RJ+Cp	22.60 $\pm$ 1.51	18.00 $\pm$ 1.00

The data were expressed as Mean $\pm$ SD, \* =  $P < 0.05$

#### 3.2. Biochemical investigations

**Liver functions** there were differences in the hepatic enzyme activities among the different treatment groups. The ALT, AST and the albumin (ALB) concentrations were significant increasing in Cisplatin mice group except RJ and control groups as shown table (2).

**Table 2: the liver functions in different experimental animals**

Groups	ALT (U/L)	AST (U/L)	ALB (g/dl)
Control	38.40 $\pm$ 1.94	42.50 $\pm$ 3.54459	4.2150 $\pm$ .25
RJ	27.04 $\pm$ 6.08	33.22 $\pm$ 6.63	4.0560 $\pm$ .36
CP	377.00 $\pm$ 95.82**	849.00 $\pm$ 272.74**	2.6075 $\pm$ .50**
RJ+Cp	164.28 $\pm$ 41.14*	345.78 $\pm$ 112.43*	2.4260 $\pm$ .406**

The data were expressed as Mean $\pm$ SD, \* =  $P < 0.05$  and \*\* =  $P < 0.001$

#### 3.3. The antioxidants and oxidative stress observations

In the table (3), the total antioxidants were highly significant decreasing in CP and cisplatin treated with RJ groups, but the animals injected with RJ were no differences when compared with control one. The catalase was highly significant decreasing in CP, but the catalase was highly significant increasing in RJ group when compared with control group. The MDA was highly significant increasing in CP and RJ injected by CP group, there was a slightly increasing when compared with control group. While the MDA was highly significant decreasing in RJ group.

**Table (3): The antioxidants and oxidative stress in different experimental animals**

Groups	Total Antioxidants (mM/L)	Catalase (U/L)	MDA (mM/L)
Control	1.92±.03	218.33±21.97	7.69±.15
RJ	1.88±.02	482.04±21.67**	6.85±.12
CP	1.43±.16**	47.10±13.11**	17.88±.25**
RJ+Cp	1.72±.24*	208.60±83.98	10.37±.87**

The data were expressed as Mean±SD, \* =  $P < 0.05$  and \*\* =  $P < 0.001$

### 3.4. Histopathological observations.

There were no histological observations differences between mice administrated with Royal jelly group and control ones which received no any treated. The hepatic cells or hepatocytes are polyhedral in shape with a relatively large sizes and a noticeable granular cytoplasm. Each cell is embodying a prominent centrally located nucleus with one or two nucleoli in addition to a number of chromatin particles (**Fig. 1A & 1B**).

Microscopic examination of liver sections taken from mice of cisplatin mice group showed different signs of injury in the hepatocytes where most of them were hypertrophied and possessed faintly stained and vacuolated cytoplasm. In addition, groups of necrotic hepatocytes could be seen in different areas of the liver tissue. binucleated hepatocytes were more frequent as compared with the control and some degenerated binucleate cells were observed with faint eosinophilic cytoplasm and chromatolytic nuclei. Cisplatin appeared to have different effects on the nuclei of hepatocytes, where some nuclei were swollen with clumped chromatin at their periphery. Few hepatocytes appeared to have nuclei with signs of karyorrhexis. Severe damages were observed in the liver architecture; the normal arrangement of the hepatocytes wasn't easily recognized and some hepatic strands were dissociated. This is probably due to dilatation of the central veins and hepatic sinusoids. Particularly, leucocytic inflammatory cells were observed all over the liver tissue (**Fig. 1C**).

Microscopic examination of the liver sections taken from mice i.p injection of cisplatin and treated with royal jelly showed the hepatocytes were little severe effects of cisplatin on the hepatic tissues than observed in other cases injected with cisplatin only (**Fig.1D**).

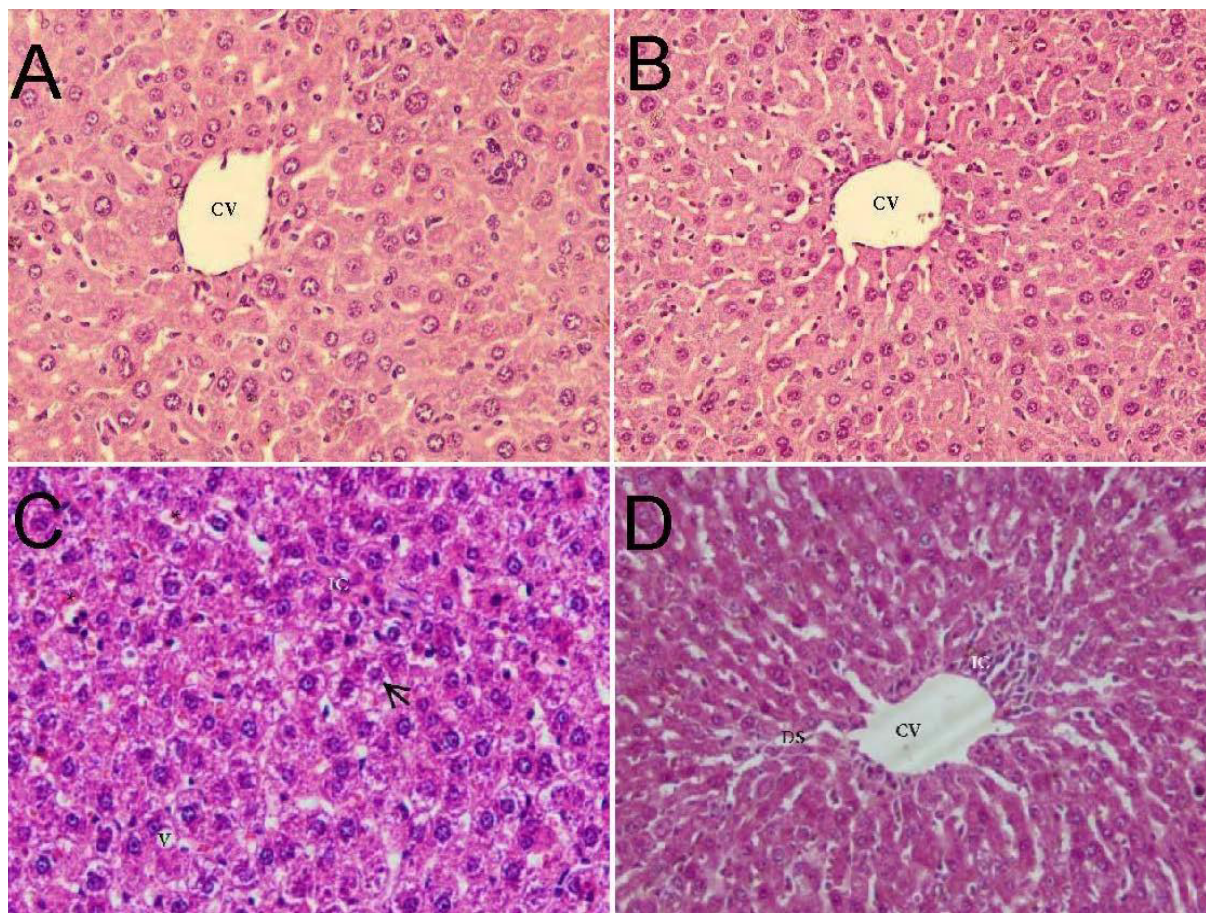


Figure (1): Histological sections of control and royal jelly mice groups: the tissues were organized into lobules which are roughly hexagonal in shape, with a central vein (CV) in the middle. Within each lobule, hepatocytes are arranged into hepatic cords running radiantly from the central vein and are separated by adjacent sinusoids. Hepatic sections of cisplatin injected mice group: showing a sinusoid blood congestion (\*). Accumulation of mononuclear cells inflammatory cells (IC), binucleated hepatic cells and vacuoles (V) were present. Hepatic sections of cisplatin injected mice treated with royal jelly: showing normal architectural except accumulation of Inflammatory cells (IC) and dilated blood sinusoids (DS).

#### 4. Discussion

At the beginning of last century, the only treatment available for patients with solid tumors was surgery, associated with high morbidity and mortality. Over the past 40 years, chemotherapy resulted in a progressive improvement in survival rates of patients with malignant neoplasm. Chemotherapy is one of the most widely used interventions for treatment of cancer (Klareskog et al., 2004).

Cisplatin is one of the most potent anticancer drugs used in chemotherapy (Van Basten et al., 1997). Also, Cisplatin is a kind of platinum coordinated complex-based anti-cancer drug, which is widely used in anti-cancer chemotherapy, including oral, lung, metastatic tumors of head, testis, ovaries and neck cancer, advanced bladder cancer, and many other solid tumors (Kumar et al., 2014).

In spite of its significant anti-cancer activity, the clinical use of cisplatin is often limited by its undesirable side effects such as nephrotoxicity (Madias & Harrington, 1978). Hepatic toxicity can also happen when cisplatin is administered at high doses (Cersosimo, 1993). The liver is known to accumulate significant

amounts of CP, second only to the kidney (El-Sayyad et al., 2009); thus hepatic toxicity can be related with cisplatin treatment (Liao et al., 2008).

Recent studies suggest that using plant-derived chemo-preventive agents in combination with chemotherapy can enhance the efficacy of chemotherapeutic agents and lower their toxicity to normal tissues (Ma et al., 2014; Silici, Ekmekcioglu, Kanbur, & Deniz, 2011). This study investigates the effects of royal jelly on cisplatin-induced liver damages. Animals that received cisplatin showed severe biochemical and histological changes. On the other hand, treatment with royal jelly caused a significant improvement in tested parameters, which were significantly altered by cisplatin administration. Among biochemical parameters, the increase in AST and ALT activities in the cisplatin mice group was found to be related to damage in the liver and change in liver functions. The elevation in levels of serum AST and ALT has been attributed to the damaged structural integrity of the liver, because these enzymes are normally found in the cytoplasm and are released into the circulation after hepatic damage (Sallie, Michael Tredger, & Williams, 1991). Mora et al. (Mora, Antunes, Francescato, & Bianchi, 2003) have also described the increasing effects of cisplatin on changes in serum AST and ALT activities and decrease of albumin level. On the other hand, treatment with the royal jelly remarkably inhibited cisplatin-induced liver damage as evidenced by decreased serum activities of AST and ALT and increase of albumin level. Similar results were obtained by Uzbekova et al., (Uzbekova, Chugunova, Makarova, Ryabkov, & Mirgorodskaya, 1998) and these researchers have reported royal jelly may protect the liver from damage because serum parameters such as AST, ALT, and albumin content have shown a pronounced tendency to normalization on thyroxin-induced liver damage (Uzbekova et al., 1998). In the present study, the royal jelly significantly restores the changes of ALT, AST and albumin due to its antioxidant effect and its ability to act as a free radical scavenger in case the cisplatin hepatotoxicity, thereby protecting membrane permeability (Ashry & Elkady, 2014).

Cisplatin increases lipid peroxidation in the treated tissue of mice. The drug is also involved in altering the thiol status of the tissue with concomitant alterations in the enzymatic antioxidants (Kunworarath, Muangnil, Itharat, & Hiranyachattada, 2014). In the present study, total antioxidants and catalase levels were significantly decreased after cisplatin therapy. This effect may be a secondary event following the cisplatin-induced increase in free radical generation and/or decrease in lipid peroxidation protecting enzymes. Cisplatin can cause the generation of oxygen free radicals, such as superoxide, hydrogen peroxide anions and hydroxyl radicals. The hydroxyl radical is capable of abstracting a hydrogen atom from polyunsaturated fatty acids in membrane lipids to initiate lipid peroxidation. These radicals can evoke extensive cell damage, reacting with proteins, membrane lipids, and nucleic acids (Emerit, Beaumont, & Trivin, 2001). Moreover, depletion of glutathione and catalase may contribute to CP-induced lipid peroxidation (GREGGI ANTUNES, D'ARC C DARIN, & BIANCHI, 2000). Thus, an alteration in enzymatic antioxidant status with increase in lipid peroxidation and nitric oxide indicates that the enzymes play an important role in combating free radical induced oxidative stress on the tissue. This speculation agreed with previous studies which have demonstrated the involvement of lipid peroxidation, oxidative stress, and mitochondria dysfunction in cisplatin-induced liver toxicity (Yilmaz et al., 2005).

The present study showed many histopathological and biochemical abnormalities in the liver of cisplatin-injected animals with single dose, which is inconsistent with the previous results (El-Sayyad et al., 2009; Kart, Cigremis, Karaman, & Ozen, 2010). Moreover, the treatment with RJ ameliorated CP-induced liver

damages associated with free radical production by enhancing the enzyme activity to normal values and preserving the liver parenchyma; where the appearance of the hepatic cells, Von Kupffer cells, sinusoids and the portal triad was similar to the control rats; these results are inconsistent with the previous studies (Dorababu, Joshi, Kumar, Chaturvedi, & Goel, 2006; Kupradinun et al., 2011).

El-Sayyad et al. (El-Sayyad et al., 2009) reported that light microscopic observations revealed that cisplatin caused hepatic toxicity, including disintegration of hepatic cords, necrotic tissues and focal inflammation, peri-portal fibrosis and increased apoptosis. It is well known that cisplatin induces oxidative stress (Srivastava et al., 1996).

In the present study, compared with groups royal jelly, cisplatin and cisplatin treated with royal jelly groups with control mice, the histopathological abnormalities in liver tissues were becoming less prominent, which referred to inflammatory infiltration, periportal extravasation, marked disruption of hepatic cords and dilated blood sinusoids in cisplatin mice group. Moreover, the histological analysis revealed that mice cisplatin injected and treated with royal jelly led to reduced hepatotoxicity in both experimental animal models. Most likely, the reduction of the hepatic tissue alteration observed for RJ-CP- treated mice is due to the ability of liposomes to modify the bio-distribution of the entrapped drug (de Carvalho Maroni et al., 2012).

**Conclusion:** The results obtained suggested that royal jelly significantly attenuated the hepatotoxicity caused by cisplatin. The protective effect of royal jelly is associated with its anti-oxidant properties because it act as lipid peroxidation inhibitor and free radical scavenger. The cisplatin-induced changes in histopathologic findings of liver were partially reversed by treatment with royal jelly.

## 5. References

- Adams, R. (1996). Qualified nurses lack adequate knowledge related to oral health, resulting in inadequate oral care of patients on medical wards. *Journal of advanced nursing*, 24(3), 552-560.
- Ahmed, E. A., Omar, H. M., Ragb, S. M., & Nasser, A. Y. (2011). The antioxidant activity of vitamin C, DPPD and L-cysteine against cisplatin-induced testicular oxidative damage in rats. *Food and Chemical Toxicology*, 49(5), 1115-1121.
- Ashry, K., & Elkady, A. (2014). Royal Jelly Modulates Hepatotoxic Effect of Rats Treated with Cisplatin.
- Barrera, D., Maldonado, P. D., Medina-Campos, O. N., Hernández-Pando, R., Ibarra-Rubio, M. E., & Pedraza-Chaverrí, J. (2003). HO-1 induction attenuates renal damage and oxidative stress induced by  $K_2Cr_2O_7$ . *Free Radical Biology and Medicine*, 34(11), 1390-1398.
- Cersosimo, R. J. (1993). Hepatotoxicity associated with cisplatin chemotherapy. *Annals of Pharmacotherapy*, 27(4), 438-441.
- Coates, A., Abraham, S., Kaye, S. B., Sowerbutts, T., Frewin, C., Fox, R., & Tattersall, M. (1983). On the receiving end—patient perception of the side-effects of cancer chemotherapy. *European Journal of Cancer and Clinical Oncology*, 19(2), 203-208.
- de Carvalho Maroni, L., de Oliveira Silveira, A. C., Leite, E. A., Melo, M. M., de Carvalho Ribeiro, A. F., Cassali, G. D., . . . Araújo, M. S. S. (2012). Antitumor effectiveness and toxicity of cisplatin-loaded long-circulating and pH-sensitive liposomes against Ehrlich ascitic tumor. *Experimental Biology and Medicine*, 237(8), 973-984.



- Dorababu, D., Joshi, M., Kumar, B., Chaturvedi, A., & Goel, R. (2006). Effect of aqueous extract of neem (*Azadirachta indica*) leaves on offensive and defensive gastric mucosal factors in rats. *Indian journal of physiology and pharmacology*, 50(3), 241.
- El-Nekeety, A. A., El-Kholy, W., Abbas, N. F., Ebaid, A., Amra, H. A., & Abdel-Wahhab, M. A. (2007). Efficacy of royal jelly against the oxidative stress of fumonisin in rats. *Toxicon*, 50(2), 256-269.
- El-Sayyad, H. I., Ismail, M. F., Shalaby, F., Abou-El-Magd, R., Gaur, R. L., Fernando, A., . . . Ouhtit, A. (2009). Histopathological effects of cisplatin, doxorubicin and 5-fluorouracil (5-FU) on the liver of male albino rats. *International journal of biological sciences*, 5(5), 466.
- Emerit, J., Beaumont, C., & Trivin, F. (2001). Iron metabolism, free radicals, and oxidative injury. *Biomedicine & pharmacotherapy*, 55(6), 333-339.
- Giordano, K. F., & Jatoi, A. (2005). The cancer anorexia/weight loss syndrome: therapeutic challenges. *Current oncology reports*, 7(4), 271-276.
- GREGGI ANTUNES, L. M., D'ARC C DARIN, J., & BIANCHI, M. D. L. P. (2000). Protective effects of vitamin C against cisplatin-induced nephrotoxicity and lipid peroxidation in adult rats: a dose-dependent study. *Pharmacological research*, 41(4), 405-411.
- Hassan, I., Chibber, S., & Naseem, I. (2010). Ameliorative effect of riboflavin on the cisplatin induced nephrotoxicity and hepatotoxicity under photoillumination. *Food and Chemical Toxicology*, 48(8), 2052-2058.
- Inoue, K., Saito, M., Kanai, T., Kawata, T., Shigematsu, N., Uno, T., . . . Ito, H. (2008). Anti-tumor effects of water-soluble propolis on a mouse sarcoma cell line in vivo and in vitro. *The American journal of Chinese medicine*, 36(03), 625-634.
- Kanbur, M., Eraslan, G., Beyaz, L., Silici, S., Liman, B. C., Altinordulu, Ş., & Atasever, A. (2009). The effects of royal jelly on liver damage induced by paracetamol in mice. *Experimental and Toxicologic Pathology*, 61(2), 123-132.
- Kart, A., Cigremis, Y., Karaman, M., & Ozen, H. (2010). Caffeic acid phenethyl ester (CAPE) ameliorates cisplatin-induced hepatotoxicity in rabbit. *Experimental and Toxicologic Pathology*, 62(1), 45-52.
- Klareskog, L., van der Heijde, D., de Jager, J. P., Gough, A., Kalden, J., Malaise, M., . . . Settas, L. (2004). Therapeutic effect of the combination of etanercept and methotrexate compared with each treatment alone in patients with rheumatoid arthritis: double-blind randomised controlled trial. *The Lancet*, 363(9410), 675-681.
- Kumar, A., Huo, S., Zhang, X., Liu, J., Tan, A., Li, S., . . . Ji, T. (2014). Neuropilin-1-Targeted Gold Nanoparticles Enhance Therapeutic Efficacy of Platinum (IV) Drug for Prostate Cancer Treatment. *ACS nano*.
- Kunworarath, N., Muangnil, P., Itharat, A., & Hiranyachattada, S. (2014). Acute and Subchronic Treatment of Hibiscus sabdariffa Linn. Extract on Renal Function and Lipid Peroxidation in Cisplatin-Induced Acute Renal Failure Rats. *J Physiol*, 27(1), 5-12.
- Kupradinun, P., Tepsuwan, A., Tantasi, N., Meesiripun, N., Rungsipipat, A., & Kusamran, W. R. (2011). Anticlastogenic and anticarcinogenic potential of Thai bitter: gourd fruits. *Asian Pacific Journal of Cancer Prevention*, 12(5), 1299-1305.

- Liao, Y., Lu, X., Lu, C., Li, G., Jin, Y., & Tang, H. (2008). Selection of agents for prevention of cisplatin-induced hepatotoxicity. *Pharmacological Research*, 57(2), 125-131.
- Ma, Y., Chapman, J., Levine, M., Polireddy, K., Drisko, J., & Chen, Q. (2014). High-dose parenteral ascorbate enhanced chemosensitivity of ovarian cancer and reduced toxicity of chemotherapy. *Science translational medicine*, 6(222), 222ra218-222ra218.
- Madias, N. E., & Harrington, J. T. (1978). Platinum nephrotoxicity. *The American journal of medicine*, 65(2), 307-314.
- Maldonado, P. D., Barrera, D., Rivero, I., Mata, R., Medina-Campos, O. N., Hernández-Pando, R., & Pedraza-Chaverrí, J. (2003). Antioxidant S-allylcysteine prevents gentamicin-induced oxidative stress and renal damage. *Free Radical Biology and Medicine*, 35(3), 317-324.
- Mansour, H. H., Hafez, H. F., & Fahmy, N. M. (2006). Silymarin modulates cisplatin-induced oxidative stress and hepatotoxicity in rats. *Journal of biochemistry and molecular biology*, 39(6), 656.
- Mihelic, R. A. (2005). *Pharmacology of palliative medicine*. Paper presented at the Seminars in oncology nursing.
- Mollaoğlu, M., & Erdoğan, G. (2014). Effect on symptom control of structured information given to patients receiving chemotherapy. *European Journal of Oncology Nursing*, 18(1), 78-84.
- Mora, L. d. O., Antunes, L. M. G., Francescato, H. s. D. C., & Bianchi, M. d. L. P. (2003). The effects of oral glutamine on cisplatin-induced nephrotoxicity in rats. *Pharmacological research*, 47(6), 517-522.
- Sallie, R., Michael Tredger, J., & Williams, R. (1991). Drugs and the liver Part 1: Testing liver function. *Biopharmaceutics & drug disposition*, 12(4), 251-259.
- Silici, S., Ekmekcioglu, O., Kanbur, M., & Deniz, K. (2011). The protective effect of royal jelly against cisplatin-induced renal oxidative stress in rats. *World journal of urology*, 29(1), 127-132.
- Srivastava, R., Farookh, A., Ahmad, N., Misra, M., Hasan, S., & Husain, M. (1996). Evidence for the involvement of nitric oxide in cisplatin-induced toxicity in rats. *Biometals*, 9(2), 139-142.
- Uzbekova, D., Chugunova, L., Makarova, V., Ryabkov, A., & Mirgorodskaya, L. (1998). Efficacy of royal jelly and lactulose on thyroxin-induced liver damage in rats. *Journal of Hepatology*, 28, 157.
- Van Basten, J., Schraffordt Koops, H., Sleijfer, D. T., Pras, E., Van Driel, M., & Hoekstra, H. (1997). Current concepts about testicular cancer. *European Journal of Surgical Oncology (EJSO)*, 23(4), 354-360.
- Waseem, M., Pandey, P., Tomar, B., Raisuddin, S., & Parvez, S. (2014). Ameliorative Action of Curcumin in Cisplatin-mediated Hepatotoxicity: An In Vivo Study in Wistar Rats. *Archives of medical research*, 45(6), 462-468.
- Yilmaz, H. R., Sogut, S., Ozyurt, B., Ozugurlu, F., Sahin, S., Isik, B., . . . Ozyurt, H. (2005). The activities of liver adenosine deaminase, xanthine oxidase, catalase, superoxide dismutase enzymes and the levels of malondialdehyde and nitric oxide after cisplatin toxicity in rats: protective effect of caffeic acid phenethyl ester. *Toxicology and industrial health*, 21(1-2), 67-73.
- Yousef, M., Saad, A., & El-Shennawy, L. (2009). Protective effect of grape seed proanthocyanidin extract against oxidative stress induced by cisplatin in rats. *Food and Chemical Toxicology*, 47(6), 1176-1183.

- 
- Zicca, A., Cafaggi, S., Mariggì, M. A., Vannozzi, M. O., Ottone, M., Bocchini, V., . . . Viale, M. (2002). Reduction of cisplatin hepatotoxicity by procainamide hydrochloride in rats. *European journal of pharmacology*, 442(3), 265-272.
- Zimmermann, A. (2002). Liver regeneration: the emergence of new pathways. *Medical Science Monitor*, 8(3), RA53-RA63.

The IISTE is a pioneer in the Open-Access hosting service and academic event management. The aim of the firm is Accelerating Global Knowledge Sharing.

More information about the firm can be found on the homepage:

<http://www.iiste.org>

## CALL FOR JOURNAL PAPERS

There are more than 30 peer-reviewed academic journals hosted under the hosting platform.

**Prospective authors of journals can find the submission instruction on the following page:** <http://www.iiste.org/journals/> All the journals articles are available online to the readers all over the world without financial, legal, or technical barriers other than those inseparable from gaining access to the internet itself. Paper version of the journals is also available upon request of readers and authors.

## MORE RESOURCES

Book publication information: <http://www.iiste.org/book/>

Academic conference: <http://www.iiste.org/conference/upcoming-conferences-call-for-paper/>

## IISTE Knowledge Sharing Partners

EBSCO, Index Copernicus, Ulrich's Periodicals Directory, JournalTOCS, PKP Open Archives Harvester, Bielefeld Academic Search Engine, Elektronische Zeitschriftenbibliothek EZB, Open J-Gate, OCLC WorldCat, Universe Digital Library, NewJour, Google Scholar

