

Combined Methanolic Leaf Extracts of *Vernonia amygdalina* and *Gongronema latifolium* Improves Sperm Parameter Impairment and Testicular Damage in STZ Induced Diabetic Wistar Rats

Akpaso, M. I* Igiri, A. O. Fischer, V. A Fischer, C. E Asuquo, O.R
Department of Human Anatomy, University of Calabar, P.M.B 1115, Calabar, Nigeria

Abstract

The effects of methanolic leaf extracts of *Vernonia amygdalina* (VA) and *Gongronema latifolium* (GL) on the histology and DNA of the testes, and the sperm parameters of streptozocin (STZ) induced diabetic rats were investigated in this study. 18 male albino rats which were divided into three groups of six rats each were used for this work: A (Normal control) and B (Diabetic control) received tap water, C received combined extract of VA and GL, (400mg/kg twice daily, 200mg/kg each extract). Groups B & C animals were induced for diabetes by intraperitoneal injection of 45mg/kg of Streptozocin, reconstituted in 0.1M sodium citrate buffer. Following sacrifice, the testes and semen were collected for histopathological studies and semen analysis respectively. The results revealed normal testes with prominent seminiferous tubules, containing germ cells at various stages of development and spermatozoa in group A. In group B, there were signs of degeneration in the seminiferous tubules (STs), destruction of germ cells, spermatozoa and Leydig cells. In group C, the testes showed normal STs with Sertoli cells, Leydig cells, germ cells and spermatozoa, suggestive of a possible regeneration. Feulgen's reaction showed damage to the DNA of the testes in group B which was almost completely reversed in group C. Semen analysis revealed reduced sperm count, high percentage of abnormal forms and high percentage of spermatozoa with retarded motility in group B compared to group A. In group C, there was marked improvement in all the parameters.

Keywords: Diabetes mellitus, sperm parameters, testicular damage, *Vernonia amygdalina*, *Gongronema latifolium*

1. Introduction

Diabetes Mellitus is a metabolic disorder having the characteristics feature of hyperglycaemia, which is usually due to an absolute or relative lack of insulin, impaired effectiveness of insulin action or tissue insensitivity to insulin (American Diabetes Association, 2014). Despite the type of diabetes, poorly managed diabetes is associated with debilitating complications such as microangiopathy, nephropathy, retinopathy, cardiovascular diseases (Cotran *et al.*, 1999), infertility and problems with conception.

Diabetes mellitus is reported to be one of the causes of sub-fertility/infertility especially among men. In a study by Jiang (1996), it was discovered that 90% of men with diabetes have some form of dysfunction in their sexual life such as erectile dysfunction, reduced libido and infertility. Penson and Wessells (2004) posit that over 71% of diabetic men suffer from erectile dysfunction. Some diabetic men are also said to have normal semen parameters but high levels of nuclear and mitochondrial DNA damage in the sperm cells thus increasing their vulnerability to infertility (Agbaje *et al.*, 2007).

The impact of diabetes mellitus in male reproductive function is due to its effect on the endocrine control of spermatogenesis, spermatogenesis itself or by an impairment of penile erection and ejaculation (Sexton and Jarrow, 1997). Factors responsible for alterations in sperm parameters in diabetic men are endocrine disorders, neuropathy and oxidative stress.

Male reproductive function is adversely affected by diabetes mellitus. Type 1 diabetes is associated with sub fertility/infertility and poor sperm quality (Agbaje *et al.*, 2007; Mulholland *et al.*, 2011). Experiments carried out with rodents have implicated mechanisms such as oxidative stress mediated damage to sperm DNA, altered hormonal profiles and abnormalities in the process of spermatogenesis, in diabetic male infertility (Izumi *et al.*, 2003; Agbaje *et al.*, 2008).

It has been reported that the use of plant derived extracts may actually result in the treatment of diabetes mellitus. These plants are said to contain various herbal and non-herbal properties such as phytonutrients and phytochemicals which can act on several targets through diverse modes and mechanisms (Tiwari and Rao, 2002). Whereas, some of these plants are very rich in antioxidants, thus providing antioxidant defense (Bnouham *et al.*, 2006), some delay gastric emptying rate while some enhance insulin secretion.

A lot of Africans are still patronizing traditional medicine. In addition, evidence has shown that some herbal remedies are highly efficacious, potent with minimal side effects and highly affordable, thus the need to explore and carryout researches in this area (Odugbemi, 2008). Although the hypoglycaemic effects of *Vernonia amygdalina* (Gyang, 2004) and *Gongronema latifolium* (Ugochukwu and Babady, 2003) have been reported, a gap still exists with respect to the use of these plants and other continental plants for the reversal of

infertility secondary to diabetes mellitus.

This study therefore was set up to investigate the histopathological changes in the testes and sperm parameters of STZ induced diabetic Wistar rats on administration of the leaf extracts of *Vernonia amygdalina* (VA) and *Gongronema latifolium* (GL)

2. Materials and methods

2.1 Preparation of plant materials

Fresh leaves of *Gongronema latifolia* and *Vernonia amygdalina* were purchased in Calabar municipality of Cross River State, Nigeria. The leaves were rinsed with distilled water and air dried under shade in the Department of Biochemistry, University of Calabar under ambient temperature. The dried leaves were homogenized into powder form using an electric blender. The powdered plant materials were respectively soaked in plastic buckets and ethanol added; the solvent to solute ratio being 2:1 for 48 hours with intermittent agitation. The mixture was filtered first using a chess cloth followed by the filtrate being filtered again through whattman No1 filter paper of pore size 0.45micrometer. The filtrate was placed in beakers and allowed to concentrate in a water bath by evaporation at 40°C to complete dryness yielding 93g of crude extract each.

2.2 Study design

Table 1 Study design

GROUP	AGENT ADMINISTERED	QUANTITY
Normal control (A)	Normal tap water	Ad. Libitum
Diabetic control (B)	STZ	45mg/kg
C	VA + GL	400mg/kg (200mg/kg each extract)

Eighteen (18) male Wistar rats were used for the study. The animals were divided into three (3) groups of 6 rats each. The first group (A) was the Normal control (NC) group which was given tap water. The second group (B) was the Diabetic control (DC) group. The animals in this group were induced for diabetes and were given normal feed and water. They received no treatment. Group C animals were induced for diabetes and were treated with the combined extracts of VA and GL (400mg/kg twice daily). Plant extracts were administered through orogastric tube.

Diabetes was induced in overnight fasted experimental animals by a single dose of intraperitoneal injection of freshly prepared streptozocin (STZ) 45mg/kg body weight reconstituted in 0.1M sodium citrate buffer (pH4.5-5.0) as solvent. The experiment lasted for 28 days, after which the semen and organs were collected for histological assessments and semen analysis.

3. Results

Table 2: Sperm count (10⁶) and motility of the different experimental groups

GROUP	SPERM COUNT (10 ⁶)	NORMAL MOTILITY			RETARDED MOTILITY		
		G1	G2	TOTAL	G3	G4	TOTAL
A	26.3	32.5	57.1	89.6	1.4	9.0	10.4
B	12.9	10.4	5.4	15.8	69.4	14.8	84.2
C	25.6	31.3	57.2	88.5	3.5	8.0	11.5

Values are expressed in absolute mean values for sperm count and mean (%) for sperm motility

3.1 Sperm count

Table 2 below represents data obtained from caudal epididymal sperm count (10⁶) in the different experimental groups. In the DC group, the sperm count was markedly reduced compared to the normal control (12.9 and 26.3). There was also a marked increase in the sperm count of the treatment group (25.6)

3.2 Sperm motility

Table 2 also shows the mean percentage of sperm cells with normal (Grade 1 = Spermatozoa moving at high speed with straight line forward progression and G2 = Spermatozoa moving at moderate speed with forward progression) and retarded motility (G3 = Spermatozoa moving aimlessly with slow forward progression and G4 = Spermatozoa moving but no forward progression). Percentage of sperm cells with retarded motility was highest in the DC group (84.24%). In the treatment group, the percentage of sperm cells with retarded motility was markedly reduced (15.6%) compared to the DC group. Also, there was an increase in the percentage of sperm cells with normal motility in the groups that received the treatment (88.5%).

Table 3: Sperm Morphology of the different experimental groups

GROUPS	NORMAL FORMS		DEFECTIVE FORMS				
	NHAT		IH	HOD	TD	FS	TOTAL
A	93.8		1.8	2.0	2.2	0.2	6.2
B	29.8		16.8	12.5	20.8	20.1	70.2
C	85.6		3.0	2.6	4.2	4.6	14.4

NHAT – Normal head and tail, IH – Isolated head, HOD – Head only defect, TD – Tail defect, FS – Fused sperm. Values are expressed as mean percentage

3.3 Sperm morphology

Table 3 shows the mean percentage morphology (normal and abnormal forms) of the animals in the various experimental groups. Percentage of the normal forms (NHAT – Normal head and tail) in the DC group (29.8%) was reduced remarkably compared to the NC (93.8%) and the treatment group - 85.6%. Percentage of the abnormal forms, IH (Isolated head), HOD (Head only defect), TD (Tail defect) and FS (Fused sperm) was markedly increased in the DC group (70.2%) compared to the normal control (6.22%). Also, percentage of the normal forms was increased (85.6%) while that of the defective sperms was decreased in the treatment group at the end of the experiment (14.4%)

4. Histological observations

4.1 Haematoxylin and eosin stain and Feulgen's reaction

The testes showed normal histological features in the normal control group. The seminiferous tubules were prominent with germ cells at various stages of development and spermatozoa in the lumen of the seminiferous tubules. Sertoli cells were present on the basal lamina and interstitial tissues containing blood vessels and interstitial cells of Leydig were seen intervening between the seminiferous tubules. The cells were prominent and strongly positive to Feulgen's reaction (Plate 1).

In the diabetic control group, the seminiferous tubules appeared swollen and edematous with narrowed, almost obliterated lumen, showing early signs of degeneration. Some of the seminiferous tubules however had wide lumina due to the absence of spermatozoa and germ cells which were destroyed resulting in reduced germ cell population. The Leydig cells were reduced and the interstitial tissues also appeared reduced. In some of the testicular tissues from the diabetic control, there was complete absence of interstitial tissues between the seminiferous tubules. Shrinkage of some seminiferous tubules resulted in their detachment from the germinal epithelium. With Feulgen's test, the cells were necrotic, pyknotic with karyolysis and were negative to the reaction (Plate 2).

For the group that received the combined extracts of VA and GL, there seemed to be a complete reversal of the diabetic insult on the histology of the testis. There were prominent seminiferous tubules which appeared normal and germ cells in their various stages of development, spermatozoa, Leydig cells and Sertoli cells were also present in the specimen. On Feulgen's reaction, there was an obvious proliferation / regeneration of the cells evidenced by the numerous cells in the specimen most of which had prominent nuclei that were strongly positive to the reaction (Plate 3).

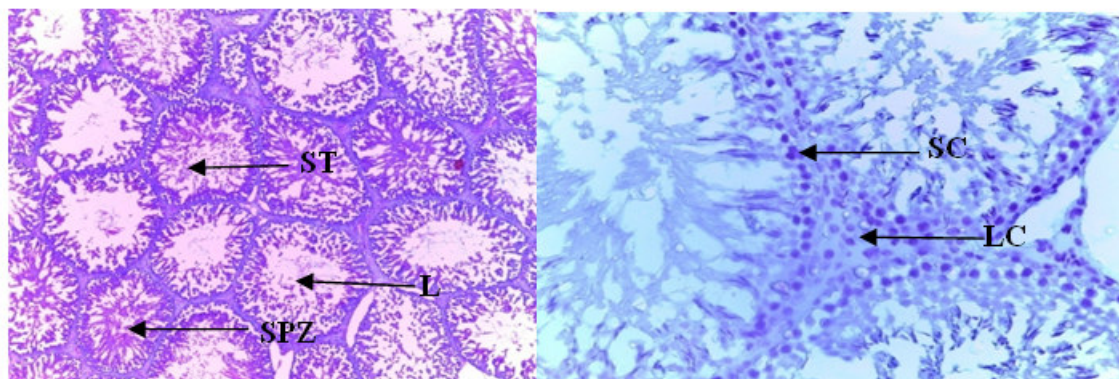


Plate 1: Photomicrograph of testis of normal control animals, stained with H & E X400 and Feulgen's reaction X1000. Showing normal seminiferous tubules containing germ cells at different stages of development and spermatozoa in their lumen and prominent cells with positively stained nuclei. SC – Sertoli cell, ST- seminiferous tubule, LC- Leydig cell, L- lumen, SPZ- spermatozoa

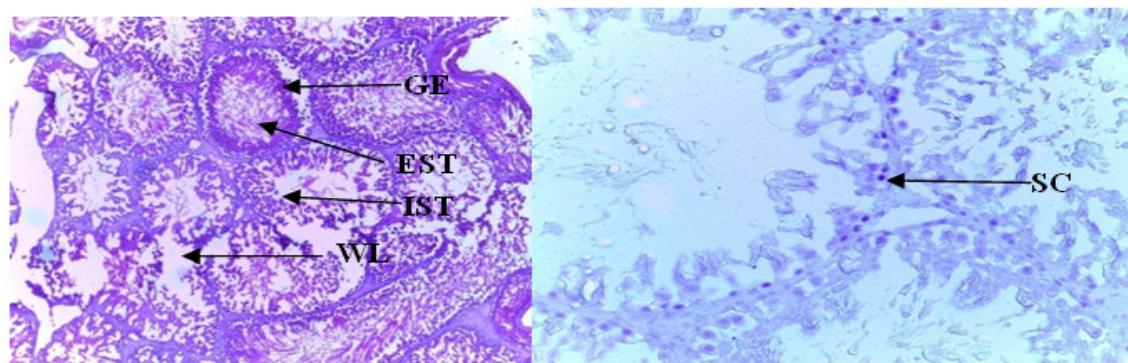


Plate 2: Photomicrograph of testis of diabetic control animals stained with H&E X400 and Feulgen's reaction X1000. Showing widened lumina of seminiferous tubules and early signs of degeneration, reduced interstitial tissues and detachment of STs from germinal epithelium. Feulgen's reaction shows pyknotic cells, karyolysis and cells that are negative for Feulgen's reaction GE- germinal epithelium, IST- interstitial tissues, EST – Edematous seminiferous tubule, WL- widened lumen

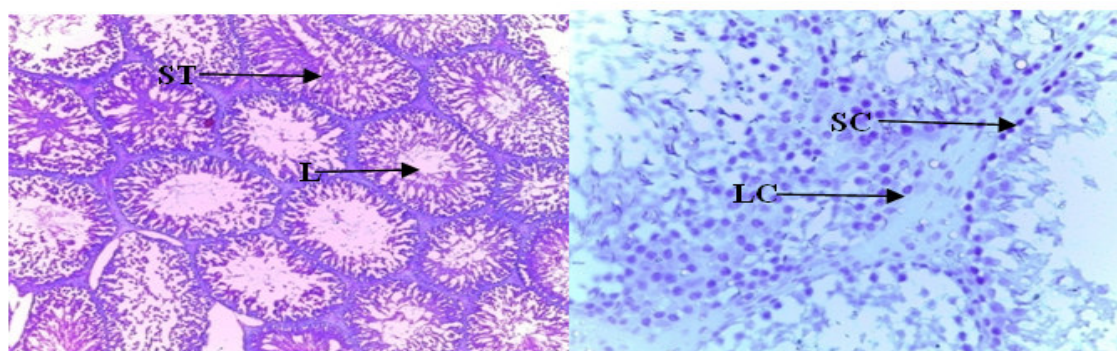


Plate 3: Photomicrograph of group C animals treated with 400mg/kg of combined extracts of VA + GL, stained with H&E X400 and Feulgen's reaction X1000. Showing normal seminiferous tubules and lumina and prominent cells with nuclei that are positive to Feulgen's test

5. Discussion

The results obtained in this study revealed alterations in the sperm parameters of the DC group. The sperm count was markedly reduced compared to the group that received the treatment and the normal control, the percentage of the abnormal forms was remarkably higher than the percentage of the normal forms and the percentage of the cells with retarded motility was remarkably higher than in normal control and the treatment group. In a research by Amaral *et al.* (2008), it was found out that diabetes mellitus impairs sexual function especially in males.. Semen analyses in diabetic men have shown a high quantity of spermatozoa with sluggish motility, increase in amount of those with altered morphology and increased semen parameter abnormalities (Agbaje *et al.*, 2007). Diabetes mellitus has been reported to have adverse effects on sexual and reproductive functions in adolescent boys and men in forms of impairment in spermatogenesis, reduced sperm count, reduced serum levels of reproductive hormones, reduced seminal fluid volume, impotence and loss of libido (Agarwal *et al.*, 2005). As was observed in this study, diabetes mellitus is significantly associated with poor sperm quality including increase in abnormal forms for instance double head, impaired sperm motility and reduced sperm count (Omu *et al.*, 2014). The impairment in sperm morphology in diabetes is said to be due to dysregulation of the process of spermiation in which mature spermatozoa are normally released into the adluminal compartment of the seminiferous tubules (Omu *et al.*, 2014). The pathogenesis of impaired sperm quality in diabetic men is due to hyperglycaemic-induced oxidative stress. Reactive oxygen species (ROS) impair sperm motility as well as sperm viability by altering sperm membrane integrity. It causes sperm DNA damage through sperm membrane lipid peroxidation (Forbes *et al.*, 2008). In the group that was treated with the plant extract there was a significant improvement in sperm parameters. The sperm count was markedly increased, the percentage of abnormal forms was reduced and the percentage of sperm with normal motility was markedly increased. Plant extracts are said to be rich in antioxidants. According to Omu *et al.* (2014), antioxidants are reported to improve spermatogenesis, intercept and prevent effect of oxidative stress on spermatozoa, thus preventing impairment of sperm motility and morphology by scavenging free radicals. Antioxidants prevent sperm damage (Ziessel, 2004; Agarwal and

Said, s2005) reduce oxidative stress and improve insulin sensitivity (Omu *et al.*, 2014).

Histological observations (Haematoxylin & Eosin)

In the diabetic control, the seminiferous tubules appeared edematous showing signs of degeneration. In some of the seminiferous tubules, spermatozoa and other sperm cells were completely absent, Leydig cells were also reduced. In line with this study, Ozturk *et al* (2002) reported that STZ induced diabetes is associated with atrophy of seminiferous tubules, destruction of spermatogenic cells, preservation of Sertoli cells and thickening of basal membranes. According to them, the Sertoli cells are preserved because they are more resistant to diabetes than the spermatogenic cells and the thickening of the basal membranes hinders the nourishment of the already impaired seminiferous tubules thereby resulting in impaired spermatogenesis. In a study carried out by Baries *et al* (2009), on alloxan induced diabetic rats, it was observed that in the testis of the diabetic animals, there was germ cell degeneration, vacuolation of seminiferous tubules, damaged and atrophied seminiferous tubules with intertubular spaces filled with edema fluid.

In the groups that received the plant extracts, there was marked improvement in the histology of the testis, the histological features of the cells was almost similar to that of the normal control. The cytoarchitecture of the testis appeared normal with Leydig cells, Sertoli cells and germ cells at different stages of development. Spermatozoa were present in the lumen of the seminiferous tubules and interstitial tissues appeared normal. This suggests a possible regeneration of the testicular cells and a reversal of the diabetic insults on the cells by the extracts. This observation agrees with previous studies which reported on the potentials of extracts of *Vernonia amygdalina*, *Gongronema latifolium* and *Azadirachta indica* to cause a regeneration of pancreatic beta cells of STZ induced diabetic rats. (Ebong *et al.*, 2006; Akpaso *et al.*, 2011).

Feulgen's reaction for DNA

For the Feulgen's test for DNA, it was observed that most of the cells in the DC group were negative for the reaction (the cells did not pick up the stain) in the testis suggesting damage to the DNA in the nuclei of the cells with consequent cellular damage.

According to Szkudelski (2001), Streptozocin (STZ) which was used to induce diabetes in this work is known to exert its toxic effect on cells primarily by damaging the cell's DNA. STZ selectively damages the beta cells of the pancreas due to its similarity to glucose molecules which causes it to be transported into the cells by the glucose transporter, GLUT 2, resulting in hypoinsulinemia and consequent hyperglycaemia. STZ also causes the release of glutamic acid decarboxylase autoantigens which induces immune and inflammatory reactions in tissues. Besides STZ, the DNA damage observed in this study may have also been due to hyperglycaemia. In a study by Ghiraldini *et al* (2013), it was discovered that hyperglycaemia induces chromatin remodeling in mouse hepatocytes. It also affects the action and expression of sirtuins which further promotes chromatin remodeling and consequently, DNA damage. Another mechanism of DNA damage secondary to hyperglycaemia is excessive production of free radicals. It has been found out that hyperglycaemic- induced mitochondrial ROS production is one of the key factors in the development of diabetic complications (Sayyed *et al.*, 2006). It has also been reported that increased ROS generation and the simultaneous decrease in antioxidant defense mechanism in diabetic patients may be responsible for the organ damage associated with diabetes (Sharma *et al.*, 2013). In the groups that received the treatments, most of the testicular cells were strongly positive for Feulgen's reaction indicating the presence of viable DNAs in the cells, possible regeneration of the testicular cells and a reversal of DNA damage caused by streptozocin.

Conclusion

Several plants including *Vernonia amygdalina* and *Gongronema latifolium* have been employed in the management of diabetes mellitus and indeed there are claims that these plant extracts may be useful in the actual treatment of the condition especially when used in combination due to their antidiabetic properties. Plants exert their antidiabetic effects through various modes and mechanisms including stimulation of insulin release, regeneration of insulin secreting cells of the pancreas and composition of phytochemicals which are rich in antioxidants. Insulin release regulates the male reproductive axis and is critical in male fertility whereas antioxidants improve spermatogenesis, intercept and prevent effect of oxidative stress on spermatozoa thus ameliorating sperm damage. The impact of diabetes on sperm quality is a function of glycaemic control, the poorer the glycaemic control, the poorer the sperm quality. Due to the fact that extracts of VA and GL have been used to provide adequate glycaemic control, these extracts can be useful in reversing diabetic insults on the structure of the testis and improving sperm parameters and consequently male fertility as was discovered in this study.

References

- Agarwal, A & Said, T. M (2005) Oxidative stress, DNA damage and apoptosis in male infertility: a clinical approach. *British Journal of Urology International*, 95: 503-507
- Agbaje, I. M., Rogers, D. A & McVicar, C. M (2007). Insulin dependant diabetes mellitus: implications for male

- reproductive function. *Human Reproduction*, 22:1871-1877.
- Agbaje, I. M., McVicar, C. M & Schock, B. C (2008). Increased concentrations of the oxidative DNA adduct 7,8-dihydro-8-oxo-2-deoxyguanosine in the germ-line of men with type 1 diabetes. *Reproduction Biomedical Online*, 16:401-409
- Akpaso, M. I., Atangwho, I. J., Akpantah, A., Fischer, V., A, Igiri, A.O & Ebong, P. E (2011). Effect of combined leaf extracts of VA and GL on the pancreatic beta-cells of STZ induced Diabetic wistar rats. *British Journal of Medicine and medical research*, 1(1) 22-34
- Amaral, S., Oliveira, P. J & Ramalho-Santos, J (2008). Diabetes and impairment of reproductive function: possible role of mitochondria and reactive oxygen species. *Current Diabetes Review*, 4: 46-54.
- American Diabetes Association (2014). Diagnosis and classification of diabetes mellitus. *Diabetes Care*. 37: (Supplement 1)
- Baris, A. U., Fatma, I., Fetih, G., Mehmet, K & Ahmet, C. O (2009). Assessment of the Histopathological Changes Occurring in the Testis of the Mice Suffering from Experimental Diabetes Induced Using Alloxan. *Journal of Animal and Veterinary Advances*, Vol 8 (10): 1929-1935
- Bnouham, M., Ziyat, A., Mekhfi, H., Tahri, A & Legssyer, A (2006). Medicinal plants with potential antidiabetic activity- A review of ten years of herbal medicine research (1990-2000). *International Journal of Diabetes & Metabolism*, 14: 1-25.
- Cotran, R. S., Kumar, V. & Collins, T. (1999) *Robbins Pathologic basis of disease*. New York: WB Saunders
- Ebong, P. E., I. J Atangwho., E. U. Eyong., C. Ukere & A. U. Obi (2006): Pancreatic Beta cell regeneration. A probable parallel mechanism of hypoglycaemic action of *vernonia amygdalina* and *Azadirachta Indica*. *Proceedings of International neem conference, Kuming China*. Nov, 11-12, pp. 83-89
- Forbes, J. M., Coughlan, M. T & Cooper, M. E (2008) Oxidative stress as a major culprit in kidney disease. *Diabetes* 57: 1446-1454
- Ghiraldini, F. G., Crispim, A. C & Mello, M (2013). Effects of hyperglycaemia and aging on nuclear sirtuins and DNA damage on mouse hepatocytes. *Molecular Biology of the Cell Journal*, 24 (15) 2476-76
- Gyang, S. S., David, D. N. & Elijah, N. S. (2004). Hypoglycaemic activities of *vernonia amygdalina* (chloroform extracts) in normoglycaemic and alloxan induced hyperglycaemic rats. *Journal of pharmacy and Bioresources*. 1(1): 61-66.
- Izumi, T., Yokota-Hashimoto, H., Zhao S., Wang J., Halban, P. A & Takeuchi, T (2003). Dominant negative pathogenesis by mutant proinsulin in the Akita diabetic mouse. *Diabetes*, 52:409-41
- Jiang, G. Y (1996). Practical Diabetes. In Beijing People's Health Publishing House: Pp. 295
- Mulholland, J., Mallidis, C., Agbaje, I & McClure, N (2011). Male diabetes mellitus and assisted reproduction treatment outcome. *Reproductive Biomedicine Online*, 22: 215-219
- Odugbemi, T (2008). *A textbook of Medicinal plants from Nigeria*. Lagos: University of Lagos Press. Pp 542 - 612
- Omu, A. E., Al-Bader, M. D., Al-Jassar, W. F., Al-Azemi, M. K & Omu, F. E (2014) Antioxidants Attenuates the Effects of Insulin Dependent Diabetes Mellitus on Sperm Quality. *Bioenergetics* 3:113
- Ozturk, F., Gul, M., Agkadir, M & Yagmurca, M (2002). Histological alteration of rat testes in experimental diabetes. *T klin. Tip Bilimleri*, 22: 22-178
- Penson, D.F & Wessells, H (2004). Erectile dysfunction in diabetic patients. *Diabetes spectrum*, 17(4): 225-230
- Sharma, B., Kumar, S., Siddiqui, S., Ram, G & Chaudhary, M (2013). Ameliorative effects of aqueous leaf extracts of *aloe arborescens* on antihyperglycaemia and antihyperlipidaemia alterations in alloxan-induced diabetic mice. *Journal of Investigational Biochemistry*, 2(2): 71-76
- Szkudelski, T. (2001). The mechanism of alloxan and streptozocin action in Beta cells of the rat pancreas. *Physiology Research*, 50. 536-546
- Tiwari, A. K & Rao J.M. (2002). Diabetes Mellitus and multiple therapeutic approaches of phytochemicals: present status and future prospects. *Current science*. 83(1) 30-37.
- Sexton, W.J & Jarow, J P (1997). Effect of diabetes mellitus upon male reproductive function. *Urology*, 49:508-513.
- Ugochukwu, N. H & Babady, N. E (2003) Antihyperglycaemic effect of aqueous and ethanolic extracts of *Gongronema latifolium* leaves on glucose and glycogen metabolism in livers of normal and streptozocin induced diabetic rats. *Life science*. 73(150). 1925-1938.
- Zeisel, S.H (2004) Antioxidant Suppress Apoptosis. *Journal of Nutrition* 134: 3179-3180

Dr. Akpaso (MBBch, M.Sc, Ph.D) is a senior Lecturer in the Department of Human Anatomy, University of Calabar. She graduated as a Medical doctor in the same University in 1997 and has recently obtained her Ph.D in cellular and Molecular Biology. She has been lecturing in Anatomy department of about fourteen (14) years now