

Evaluation of *Calvatia Craniformis* Mushroom Activity in Treatment of Ringworm Disease on Cattle

Ghassan H. Jameel¹ Hadi Alwan Mohammed Al-Saidy² Amaar A. Sultan³

1. Department of Microbiology. College of Veterinary Medicine. University of Diyala. Iraq

E. mail: ghassan_immune@yahoo.com

2. Department of Animal Resources. College of Agriculture University of Diyala Iraq

E-mail: drh.alsaidy@yahoo.com

3. College of Education for Pure Science. University of Diyala. Iraq

ABSTRACT

In order to determine and treatment of the dermatophytosis, that infections in cattle, skin scraping samples were collected from thirty cattle which showed clinical signs of skin diseases from some farms in different areas in Diyala governorate. The isolation results in cattle samples showed that (90%) were positive for fungal isolation. The main fungal species that isolated included *Trichophyton verrucosum*. Three different concentration of *Calvatia craniformis* mushroom ointment are prepared to obtain (0.25%, 0.50% and 1%) of the mushroom ointment respectively and then applied topically to lesion once daily. Sixty infected cattles in different age and sex were involved in our study and divided into two groups; the first is treatment group and, the second is the control group. The treatment group includes thirty patients were treated by one of the three concentrations (Ten patients 0.25%, Ten patients 0.50%, Ten patients 1% concentrations). The control group included thirty patients was treated by 1% sulphur ointment. The 1% mushroom ointment significantly reduce clearance time ($P < 0.05$) in comparison with the control group, while other concentration produce non significant changes in clearance time, therefore this substance in all preparations is effective in the treatment of ringworm.

Keywords: ringworm, dermatophytosis, *Calvatia craniformis*

INTRODUCTION

Dermatophytosis (ringworm) is a zoonotic skin infection of keratinized tissues caused by a specialized group of fungi named dermatophytes. The disease has worldwide distribution and it has been considered as a public health problem all over the world (Kane *et al.*, 1997). Animal dermatophytosis is responsible for high economical losses especially in cattle farming due to skin damages and decrease in milk and meat production (Radostits *et al.*, 2000). Dermatophytes include geophilic, anthropophilic and zoophilic species living in soil, human beings and animals respectively (Weitzman and Summerbell, 1995).

The animal age and trauma are important predisposing factors of disease (Oborilova and Rybnikar, 2005). Cattle ringworm mainly occurs in young animals (calves) and is rapidly spread in the herd via infected propagates, example hyphae, and specialized fungal spores named arthrospores. The disease occurs worldwide and *T. verrucosum* is the almost exclusive etiologic agent (Kirmizigul *et al.*, 2012; Weber, 2000; Pier *et al.*, 1994). Spores may survive in the environment for 2 to 3 years (Gudding and Lund, 1995). Besides cattle, it has been reported as the major agent of dermatophytosis in ruminants such as goat, sheep and camel (Pier *et al.*, 1994; Fadlelmula *et al.*, 1994). Aside from animal involvement, several human outbreaks of *T. verrucosum* infection have been reported so far by direct contact with infected animals or indirect contact with infectious propagates in the environment and also be spread to the hands of handlers (Ming *et al.*, 2006; Scott, 2007), and the figure (1) reveals the shape of the lesion in the hand of the owner.

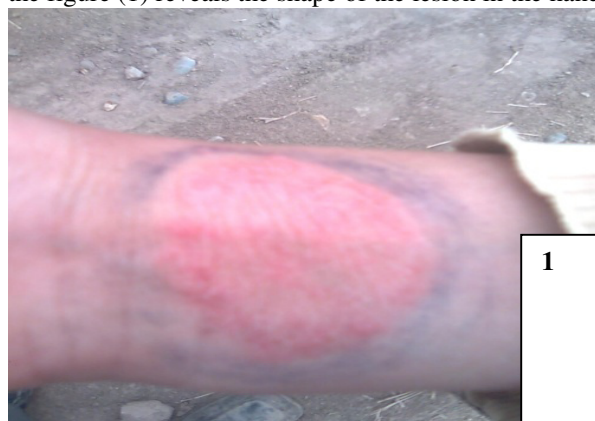

figure 1. reveals the shape of the lesion in the hand of the owner.

Human cases of *T. verrucosum* infection have been successfully treated by different antifungal agents such as azole compounds, but therapy for cattle is more difficult (Ming *et al.*,2006). It has been reported that animals housed in close proximity to each other for long periods and the presence of infected debris in buildings considered as the main causes of the infection (Dehghan *et al.*,2009). The initial lesions are discrete, grayish-white, crusty dry areas with a few brittle hairs. Some areas may become suppurative and thickly crusted. Lesions resembling light brown scabs may also be seen; when these scabs fall off, they leave an area of alopecia. The lesions usually resolve spontaneously in 2 to 4 months (Acha and Szyfres,2003). The aims of the present study are to evaluate activity of *Calvatia craniformis* mushroom in treatment of ringworm disease in native dairy farms of Iraq for first time, and to prevent reverse infection to the animals and humans.

The figure (2a) reveals the *Calvatia craniformis* mushroom has been classified nationally and, the figure (2b) reveals the discovered mushroom in Jadidat Al-shat village in Hibhib city and Bani saad city- Diyala province for first time in Iraq according to the diagnosis of laboratory of fungus researches and plant disease in the college of Agriculture- Baghdad university.




Figure 2a. represent the mushroom in the world .
2b: represent the mushroom in the Iraq.

Materials and Methods

Identification of the fungi

Thirty samples were collected from the cattle which showed clinical signs of skin disease for isolation and identification of the causative agent. The specimens is treated with 10% KOH to dissolve tissue material, leaving the alkali-resistant fungi intact, or stained with special fungal stains (Siegmund *et al.*,1979). Each sample was cultured directly on tow Sabouraud Dextrose Agar media which incubated in the incubator at 30C° to assist growth of moulds for (1-4) weeks.

2-Preparation of topical antifungal agent

Calvatia craniformis mushroom:

Fruiting body is dried and crushed in sterile Petri dish to obtain a yellow- brown powder. By using a balance weigh, three weights (0.25,0.50,1 gm) each one singly alone. Each weight is completed to 100gms of Vaseline to reach 0.25%, 0.50% and 1% concentrations.

3-The patients:

The number of patients is sixty, divided to two groups, each group consist of thirty patients. The first group was the tested group which include thirty patients was divided into three subgroup; each subgroup consist of ten patients treated by different concentrations of topical mushroom ointment one time daily for one month, while the second group was control group which include thirty patients treated by 1% sulphur applied topical one time daily for one month.

Statistical analysis

The differences are compared by using (F-Test) at $p < 0.05$ (Zar,1984).

Results

The figure(3a,b) were represents the longitudinal section of the mushroom in the world and in Iraq respectively .




Figure 3a. represent the longitudinal section of the mushroom in the world.

3b. represent the longitudinal section of the mushroom in the Iraq.

Most of the isolates are revealed the presence of *T. verrucosum* chlamydo spores in chain ; rare macroconidia after culturing and examination. These results makes us to say , the *T. verrucosum* is the usual cause of ringworm in cattle, and is in agreement with previous studies (Al-Ani *et al.*,2002; Cam *et al.*,2007; Quinn *et al.*,2011; Levinson,2012). Ellis *et al.*(2007) demonstrates , that *T. verrucosum* is the cause of ringworm in cattle, also refers to the infections in humans, result from direct contact with infected cattle or infected fomites. Invaded hairs show an ectothrix infection. So preferable treatment of this infection is applied therapy , and were shows good results.

Table1. revealed the patients and the concentrations of the mushroom ointment with other drug as comparison and the clearance time.

Patients group	Ointment concentration	Period of clearance
10 Patients	0.25%	35-38 Days
10Patients	0.50%	23-27 Days
10 Patients	1%*	10-13 Days
30 Patients	1% sulphur	30-60Days

(p<0.05) *

The table 1 is revealed the response of the patients to a different concentrations of the mushroom ointment as indicated by their disease clearance time and hair regrowing.

Discussion

These results reflects the medical importance of the *Calvatia craniformis* mushroom. The medical analysis of this mushroom proved the presence of three components; the first is calvatic acid which has chemical formation P-carboxyphenyl-azoxycarbonitrile(Okuda and Fujiwara,1982). This calvatic acid reveals strong antimicrobial activity against the Gram- positive bacteria, and weak action against the Gram- negative bacteria and against the yeast and fungi like *Saccharomyces cerevisiae* and some *Candida* species and *Trichophyton asteroides* (Hamao *et al.*,1976).

The second component from chemical analysis and spectroscopic means of the mushroom is hydroxyphenylazoformamide derivatives which has three chemical compounds, 4-hydroxyphenyl-lazoformamid, 4-hydroxyphenyl-ONN-azoformamid and 2-methylsulfonyl-4-hydroxy-6-methylthiophenyl-1-azoformamid, which we named it craniformin (phenolic tautomer of rubroflavin) (Bouaziz *et al.*,2008). The hydroxyphenylazoformamide derivatives or craniformin have phenolics in its formation which are endowed with interesting biological activities as a broad spectrum bactericidal and fungicidal effect represented by *Candida albicans*, *Aspergillus niger*. Also the craniformin has azol compound which acts as antifungal azol derivatives for example Fluconazol and Itrakanzol (Fugmann *et al.*,2001). They inhibits the synthesis of ergosterol by blocking the action of 14-alpha-demethylase and stop proliferation of the fungus (Lewis, 2006). The action of azol compounds reveals inhibition fungal mRNA transcription and treating fungal infections in human and animal subjects and fungal infestations in plants (Wobbe *et al.*,2000).

The third component which resulted from chemical analysis is steroid compounds which includes ; ergosta-4,6,8 (14), 22-tetraene- 3-one, ergosta-7,22-diene-3-01 and ergosterol peroxide (Takaishi *et al.*,1997). These are lipophilic and this character facilitates entry into the cells. Also the specific binding proteins which are present in any animal cells may facilitate steroids entry into target tissues (Jhonson and Eviritt, 1980). Foiani *et al.*, (1994) proved that the B subunit of the DNA polymerase alpha- primase complex in *Saccharomyces*

cerevisiae has essential function at initial stage of DNA replication and this should be inhibited by ergosterol peroxidase which results in inhibition of the proliferation of the yeasts and fungus.

Also the chemical analysis of mushroom powder which is done in White Fields Company for Chemical and Engineering Studies and Consultations in Baghdad – Iraq proved the presence of different materials as ergothioneine and gallic acid. The ergothioneine (ET) which is an unusual sulfur-containing derivative of the amino acid, histidine. It may be represent a new vitamin whose physiologic roles include antioxidant cytoprotectant (Paul and Snyder,2010) .

The results are coming in agreement with Ghosh,(2004) who is elicits many essential amino acids and vitamins like A,D,C,K and B-complex from *Calvatia craniformis* mushroom.

The last material termed gallic acid ; it is a trihydroxybenzoic acid, a type of phenolic acid. Gallic acid is found both free and as part of tannins . Gallic acid seems to have anti-fungal and anti-viral properties. Gallic acid act as an antioxidant and help to protect human and animal cells against oxidative damage (Jeremy and Nuansri,2007) . The synergistic action of all components of the mushroom are shared in treatment of the lesion and display in (figure-4 a,b and figure-5 a,b) in less time and without side effect.

Statistical analysis reveals significant difference at $p < 0.05$ when we are used our preparation in treating the disease with less time in comparison with topical preparation of 1% sulphur which needs more time for clearance between 30-60 days, while our preparation needs less time between 10-20 days.

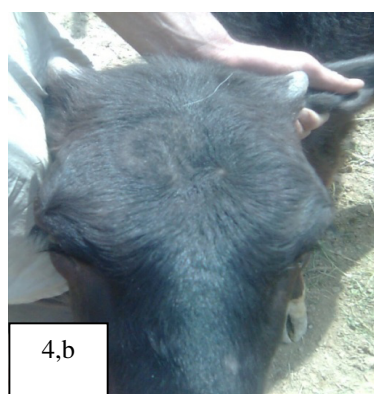
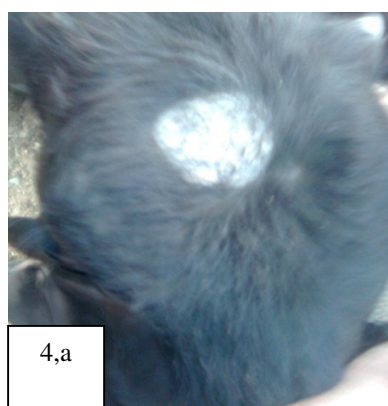


Figure 4a. represent the lesion before application of the ointment.
4b. represent the clearance of the lesion and appearance of the hair.

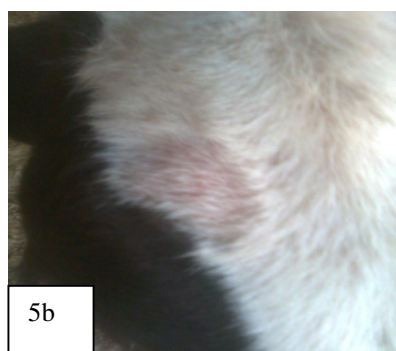
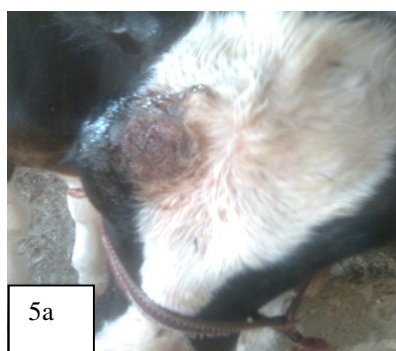

Figure 5a. represent the lesion before application of the ointment.
5b. represent the clearance of the lesion and appearance of the hair.

References

- Acha, P.N. and Szyfres B. 2003 . Zoonoses and communicable diseases common to man and animals. Bacterioses and mycoses. (3rd) ed. Washington DC: PAHO; Scientific and Technical Publication No. 580: 332-339.
- Al-Ani, F.K.; Younes F.A. and Al-Rawashdeh O.F. 2002. Ringworm infection in cattle and horses in Jordan. *Acta Vet Brno*, 71. 55-60.
- Bouaziz, M.; Lassoued, S.; Bouallagui, Z.; Smaoui, S.; Gargoubi, A.; Dhouib, A. and Sayadi, S.2008. Synthesis recovery of high bioactive phenolics from table- olive brine process wastewater. *Bioorg . Med .Chem.*; 1(20):9238-46.

- Cam, Y.; Gummusoy K.S. ; Kibar M.; Apaydin N. and Atalay O.2007. Efficacy of ethylenediamine dihydriodide for the treatment of ringworm in young cattle . *Vet Rec*, 24: 408-410.
- Dehghan, M.; Haiian S., Alborzi N., Borgheyee A. and Noohi A.H .2009. Clinico –mycological profiles of dermatophytosis in Gorgan, North of Iran. *Iran.J. Dermatol.*,12(1): 13-15.
- Ellis, D.; Davis S., Alexiou H., Handke R. and Bartley R. 2007. Description of Medical Fungi. (2) ed. P:167-168. Adelaide Australia.
- Fadlelmula, A., Agab H., Le Horgne J.M., Abbas B., Abdalla A.E. 1994. First isolation of *Trichophyton verrucosum* as the etiology of ringworm in the Sudanese camels (*Camelus dromedarius*). *Rev d'élev Méd Vét Pays Trop*; 47: 184-187.
- Foiani, M.; Marini, F.; Gamba, D.; Luchini, G. and Plevani, P. 1994. *Mol.Cell Biol.*14(2):923-933.
- Fugmann, B.; Arnold, S.; Steglich, W.; Fleischhauer, J.; Repges, C.; Koslowski, and Raabe, G. 2001. Pigments from the Puffball *Calvatia rubro -flava-* Isolation, structural Elucidation and synthesis Euro. *J .of organic chemistry*. Vol.2001, (16):3097-3104.
- Ghosh, D. 2004. Algae and Fungi as food . *Resonance*, 9(4).
- Gudding, R. and Lund A .1995. Immunoprophylaxis of bovine dermatophytosis. *Can Vet.J.* 36: 302-306.
- Hamao, U.; Tomio, T. Hironobu, L. and Osamu, T. 1976. Production of a new antibiotic, calvatic acid . Assignee: Zaidan, Hojin Biseibutsu Kagaku Kenkya Kai (Tokyo, JA).
- Jeremy, D.K. and Nuansri R.2007. Antimicrobial gallic acid from *Caesalpiniamimosoides* Lamk . *Food Chemistry*, 100(3): 1044-1048.
- Jhonson, M. and Eviritt, B. 1980. Essential Reproduction. Blackwell Scientific Publications, Oxford.
- Kane J., Summerbell R., Sigler L., Krajden S. and Land G . 1997. Laboratory Handbook of Dermatophytes. Star Publishing Company, Belmont, CA ,USA.
- Kirmizigul A.H., Gokce E., Sahin M., Kiziltepe S., Buyuk F. and Erkilic E.E. 2012. Clinical Effectiveness of Ivermectin on Bovine Dermatophytosis. *Kafkas Univ Vet Fak Derg* 18(3): 523-526.
- Levinson, W.2012. Laboratory Diagnosis of ringworm in cattle. Review of Medical Microbiology and Immunology, (12TH) ed. P: 375-376, Mc Graw Hill, Lange.
- Lewis, R.E. 2006. Managing drug interactions in the patients with aspergillosis. *Medical Mycology*, 4(1): 349-356.
- Ming, P.X.; Ti Y.L. and Bulmer G.S. 2006. Outbreak of *Trichophyton verrucosum* in China transmitted from cows to humans. *Mycopathologia*; 161: 225-22.
- Oborilova, E. and Rybnikar A. 2005. Experimental dermatophytosis in calves caused by *Trichophyton verrucosum* culture. *Mycoses*; 48: 187–191.
- Okuda, T. and Fujiwara A.1982. Calvatic acid and product by the Lycoperdeceae 2. Distribution among the Gasteromycetes. *Trans.Mycol.Soc.Jpn-23*:235-239.
- Paul, B.D. and Snyder S.H. 2010. The unusual amino acid L- ergothioneine cytoprotectant . *Cell Death and Differentiation* 17: 1134-1140.
- Pie,r A.C., Smith J.M.B., Alexiou H., Ellis D.H., Lund A. and Pritchard RC. 1994. Animal ringworm – its etiology, public health significance and control. *J. Me Vet Mycol*; 32: 133–150.
- Quinn, P.J., Markey B.K, Leonard F.C., FitzPatrick E.S., Fanning S. and Hartigan P.J.2011. Dermatophytosis in Cattle. *Veterinary Microbiology and Microbial Disease*. (2nd) ed. P: 423-424. Wiley- Blackwell.
- Radostits, G.M., Gay C.C. , Blood D.C. and Hinchcliff K.W. 2000. *Veterinary medicine. A textbook of the disease of cattle, sheep, pigs, goat and horses*. (9th) ed. ; 1282-1284pp.
- Scott, D.W.,2007. *Color Atlas of Animal Dermatology*. Blackwell ISBN 978-0- 8138.
- Siegmund, O.H., Fraser C.M. , Archibald J., Henderson J.A., Blood D.C., Newberne P.M., Snoeyenbos G.H. and Weipers W. 1979. Ringworm in Cattle .The MERCK Veterinary Manual. (5th) ed. P: 932-933.
- Smith, A.H.1951. Puffballs and their allies in Michigan Am. Arbor. University of Michigan press. 131p. Takaishi, Y.; Murakami Y.; Uda M.; Ohashi T.; Hamamura N.; Kidota M. and Kadota S.1997. *Phytochemistry* .45 (5).997-1001.
- Wobbe, R.C.; Bradley, J.D. and Li, Z. 2000. Antifungal agents- United States Patent 6165998. Scriptgen Pharmaceuticals, Inc.(Waltham, M.A. Weitzman, I. and Summerbell R.C. The dermatophytes. 1995. *Clin Microbiol. Rev*; 8: 240-259.
- Weber, A. 2000. Mycozoonoses with special regard to ringworm of cattle. *Mycoses*; 43: 20–22.
- Zar, J.H. 1984. *Biostatistical analysis*, 2nd ed., prentice Hall Inc., Englewood, N.J.s.