

Journal of Biology, Agriculture and Healthcare
ISSN 2224-3208 (Paper) ISSN 2225-093X (Online)
Vol 1, No.2, 2011

www.iiste.org



The Invader of the Maxillary Sinus

Barnali Ghosh (Pal)* Aparajita Mishra

Department of Oral and Maxillofacial Surgery, Awadh Dental College and Hospital, PO Bhilai pahari,
Jamshedpur, Jharkhand, 831 012, India

* E-mail of the corresponding author: barnali.olivia@gmail.com

Abstract

This report aims to present the case of a 21 year old boy with oroantral communication associated with sinonasal symptom. The aetiology was the presence of ectopic third molar in the sinus. Closure of the communication and surgical removal of the tooth via Caldwell-Luc procedure resulted in resolution of the symptoms. The oroantral communication was surprisingly caused by the chronic sinusitis resulting from the presence of the tooth in the maxillary sinus.

Keywords: oroantral communication, maxillary sinus, ectopic maxillary third molar

1. Introduction

The oroantral perforation is an unnatural communication between the oral cavity and the maxillary sinus while the oroantral fistula is an epithelialized, pathological, unnatural communication between these two cavities (Malik 2008).

The anatomical relationship shows close proximity between the maxillary sinus and the dentoalveolar portion of maxilla. The posteriors specially the molars show close proximity with the maxillary sinus which favors the establishment of the communication which is either due to faulty extraction technique or pathology of the tooth but in this case the condition is reversed. The aetiology of the oroantral communication in this case is due to the persistent infection of the maxillary sinus.

On referring to ectopic third molar teeth, we refer to those that are impacted in unusual positions, or those that are displaced and that are at a distance from their normal anatomic site (ascending mandibular ramus, condyle, coronoid apophysis, maxillary sinus-infraorbital region, etc.). No anatomic boundaries have been established for defining an impacted third molar tooth as ectopic (Garcia *et al.* 2007).

The oral epithelium and the underlying mesenchymal tissues undergo multistep interaction which results in tooth development. During this development any abnormal tissue interactions may lead to ectopic tooth development and eruption (Goh 2001). Ectopic eruption can be associated with developmental disturbances, pathological processes or iatrogenic activity. The etiology of an ectopic tooth is not always known. Ectopic eruption of tooth is common in dental location. It is rarely found in other sites, among which maxillary sinus is the one (Bodner *et al.* 1997). This may result in sinusitis.

The case here presents the oroantral communication associated with sinonasal symptoms and ectopic eruption of the left upper 3rd molar in the maxillary sinus.

2. Case Report

The case was referred by an ENT specialist to the department of Oral and Maxillofacial Surgery. A 21 year old boy reported with the complaint of water coming out of the nose while rinsing and occasional mucopurulent rhinorrhoea.

Clinical examination of the patient revealed the presence of oroantral communication and the absence of

the left upper third molar. Detailed history revealed an episode of bleeding from upper left quadrant but there was no history of extraction.

The radiological assessment included orthopantomograph (Figure 1) and Water's view (Figure 2) showing the presence of radiopacity resembling a tooth (left upper third molar) in the maxillary sinus.

The patient underwent removal of the ectopic tooth under general anesthesia via a Caldwell-Luc procedure where a semilunar incision was made in the buccal vestibule from canine to second molar area just above the gingival attachment. A mucoperiosteal flap was elevated with the help of periosteal elevator till the infraorbital ridge. After identifying the infraorbital nerve, adequate measure was taken to avoid stretching or any injury to it. A window was created in the anterior wall of the maxillary sinus with round bur, and the opening was enlarged with Rongeur forceps. The tooth was lying in a mass of dense soft tissue with pus but attached to the posterior wall of the sinus with the crown facing the surgical window. Left maxillary sinus content was cleared and the tooth was removed. Hemostasis was achieved and the wound was closed with 3.0 vicryl suture. Subsequently the closure of oroantral communication was also carried out with buccal advancement flap procedure. The histopathological examination of the sinus contents confirmed infected granulation tissue and no unusual pathology.

The patient had undergone uneventful healing and was recalled fortnightly for first two months and was recalled after six months. A post operative radiograph (Figure 3) after two months showed the normal looking left maxillary sinus and the patient confirmed the absence of any discharge from his nose.

3. Discussion

In the sixth week of intrauterine life, the process of tooth development begins with the formation of maxillary and mandibular dental laminae in the future alveolar process region. Proliferation of ectodermal derivative form twenty tooth germs for primary teeth between sixth and eighth prenatal week and thirtytwo additional tooth germs which differentiate to form the permanent dentition between fifth and tenth months (Avery 1994). Abnormal tissue interaction during development may potentially result in the ectopic tooth development and eruption.

Though rare but cases have been reported of ectopic eruption of teeth in places other than the oral cavity. In literature, it has been confirmed the presence of tooth in the palate (Pracy *et al.* 1992), coronoid process (Toranzo & Terrones 1992), mandibular condyle (Yusuf & Quayle 1989) and the nasal septum (el -Sayed 1995). Such ectopic eruption in the maxillary sinus may present with local sinonasal symptoms attributed to recurrent or chronic sinusitis (Srinivas *et al.* 2007).

The diagnosis of this condition can be made radiographically with orthopantomograph, OM view or Water's view, CT scans in axial and coronal sections (Srinivas *et al.* 2007) which reveal the presence of radiopacity in the antrum region.

Caldwell-Luc procedure was considered as opposed to nasoendoscopic removal of the tooth because of its location in the posterior wall of the sinus. Trans nasal extradition of tooth may be attempted if the tooth is small and sited near the maxillary ostium.

The Caldwell-Luc operation was first described by Caldwell and Luc in the year 1893 as a technique to remove infection and diseased mucosa from the maxillary sinus via the canine fossa, while creating intranasal counter drainage through the inferior meatus. This operation has been time tested, but it has come under increased scrutiny within the last two-three decades. Improvement in endoscopic sinus surgery techniques has made it a safe and effective alternative in the vast majority of patients requiring surgical management. In addition, several retrospective studies have shown high complication rates with the Caldwell- Luc operation. However it is still the safe and effective surgical procedure when complete removal of diseased mucosa from the sinus is required (Matheny & Duncavage 2003).

Surgical approach through the oro-antral communication was not done considering the size of the tooth and the access would have been more difficult as the location of the communication was the distal aspect of left maxillary second molar.

Complete removal of diseased antral tissues and thorough histopathological assessment of all the soft tissues was mandatory (Goh 2001) as certain diseases such as presence of cyst or malignancy may co-exist

with ectopic molar.

Presence of oroantral communication without history of any extraction questions its aetiology. Literature says infection in the maxillary sinus can also be instrumental in establishment of oroantral fistula (Moore 2001).

4. Conclusion

An ectopic eruption of third molar tooth was described in the left maxillary sinus associated with oroantral communication in a 21 year old boy. The tooth was surgically removed, and the closure of the communication was carried out. The patient is kept on every six months follow up.

References

- Malik, N.A. (2008), "Textbook of Oral and Maxillofacial Surgery" (2nd edition), New Delhi: Jaypee Brothers, 563-584.
- Garcia, C.M., López, J.C., Gil, F. M., Gil, H.S., Sánchez, A.J.M., Arias, J. M., Vázquez, J.C.M., Laza, L.R., Cristóbal, B.N., Álvarez, P.Q. (2007), "Ectopic Third Molar of the Maxillary Sinus - Infraorbital Region", *Revista Espanola de Cirugia Oral y Maxilofacial* **29**(3), Elsevier, 173-177.
- Goh, Y.H. (2001), "Ectopic Eruption of Maxillary Molar Tooth – an Unusual Cause of Recurrent Sinusitis", *Singapore Medical Journal* **42**(2), Singapore Medical Association, 80-81.
- Bodner, L., Tovi, F. & Bar-Ziv, J. (1997), "Teeth in the Maxillary Sinus - Imaging and Management", *Journal of Laryngology & Otolaryngology* **111**(9), Cambridge University Press, 820-824.
- Avery, J.K. (1994), "Oral Development and Histology" (2nd edition), Germany: Theime Medical Publisher, 70-92.
- Pracy, J.P.M., Williams, H.O.L. & Montgomery, P.Q. (1992), "Nasal Teeth", *Journal of Laryngology & Otolaryngology* **106**, Cambridge University Press, 366-367.
- Toranzo, F.M. & Terrones, M.M.A. (1992), "Infected Cyst in the Coronoid Process", *Oral Surgery Oral Medicine Oral Pathology* **73**(6), Elsevier, 768.
- Yusuf, H. & Quayle, A.A. (1989), "Intracondylar Tooth", *International Journal of Oral and Maxillofacial Surgery* **18**(6), 323.
- el –Sayed, Y. (1995), "Sinonasal Teeth", *The Journal of Otolaryngology* **24**(3), Canadian Society of Otolaryngology, 180-183.
- Srinivas, P.T., Sujatha, G., Niazi, T.M. & Rajesh, P. (2007), "Dentigerous Cyst Associated with an Ectopic Third Molar in Maxillary Sinus: A Rare Entity", *Indian Journal of Dental Research* **18**(3), Medknow Publications, 141-143.
- Matheny, K.E. & Duncavage, J.A. (2003), "Contemporary Indications for the Caldwell-Luc Procedure", *Current Opinion in Otolaryngology - Head & Neck Surgery* **11** (1), Wolters Kluwer, 23-26.

Moore, U.J. (2001), “Complications of Tooth Extraction”, in Moore, U.J. (Ed). Principles of Oral and Maxillofacial Surgery,. United Kingdom: Wiley-Blackwell, pp. 156-174.

Barnali Ghosh (Pal) was born in Howrah (WB, India) on 16th July 1973. She has obtained her BDS from Dr R. Ahmed Dental College and Hospital (Kolkata, WB, India, 1997), and FDSRCS in Oral Surgery from Royal College of Surgeons (England, UK, 2000). Dr Ghosh (Pal) is currently a Professor and the Head of the Department of Oral Surgery in Awadh Dental College and Hospital (Jamshedpur, Jharkhand, India). Her research interest is in the field of Oral Surgery.

Aparajita Mishra was born in Surda (Jharkhand, India) on 2nd October, 1988. She is an outgoing final year student of BDS studies from Awadh Dental College and Hospital (Jamshedpur, Jharkhand, India).

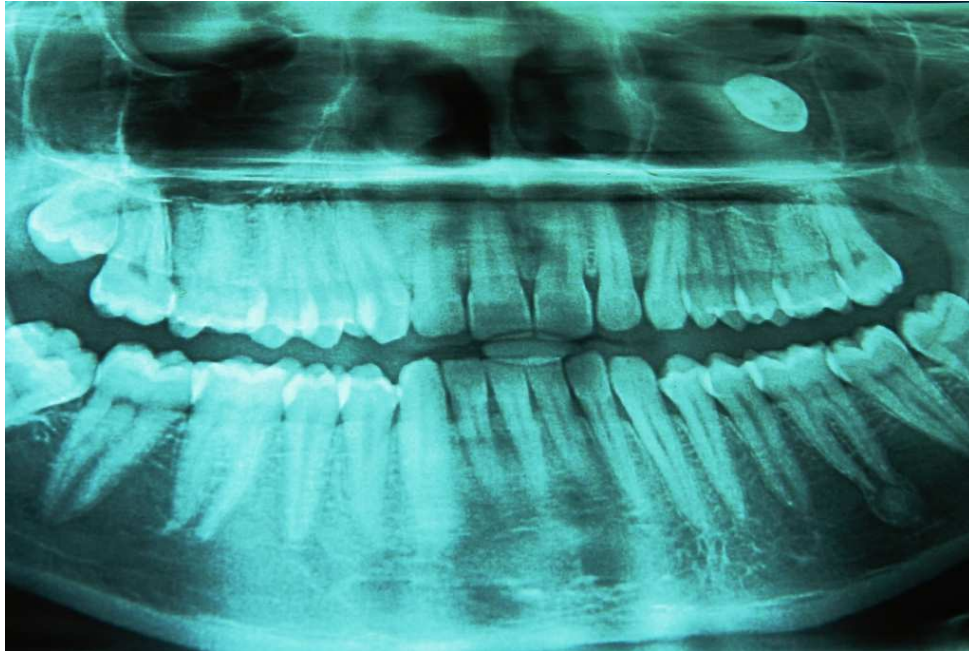


Figure 1. Orthopantomograph Showing Presence of a Tooth in the Left Maxillary Sinus

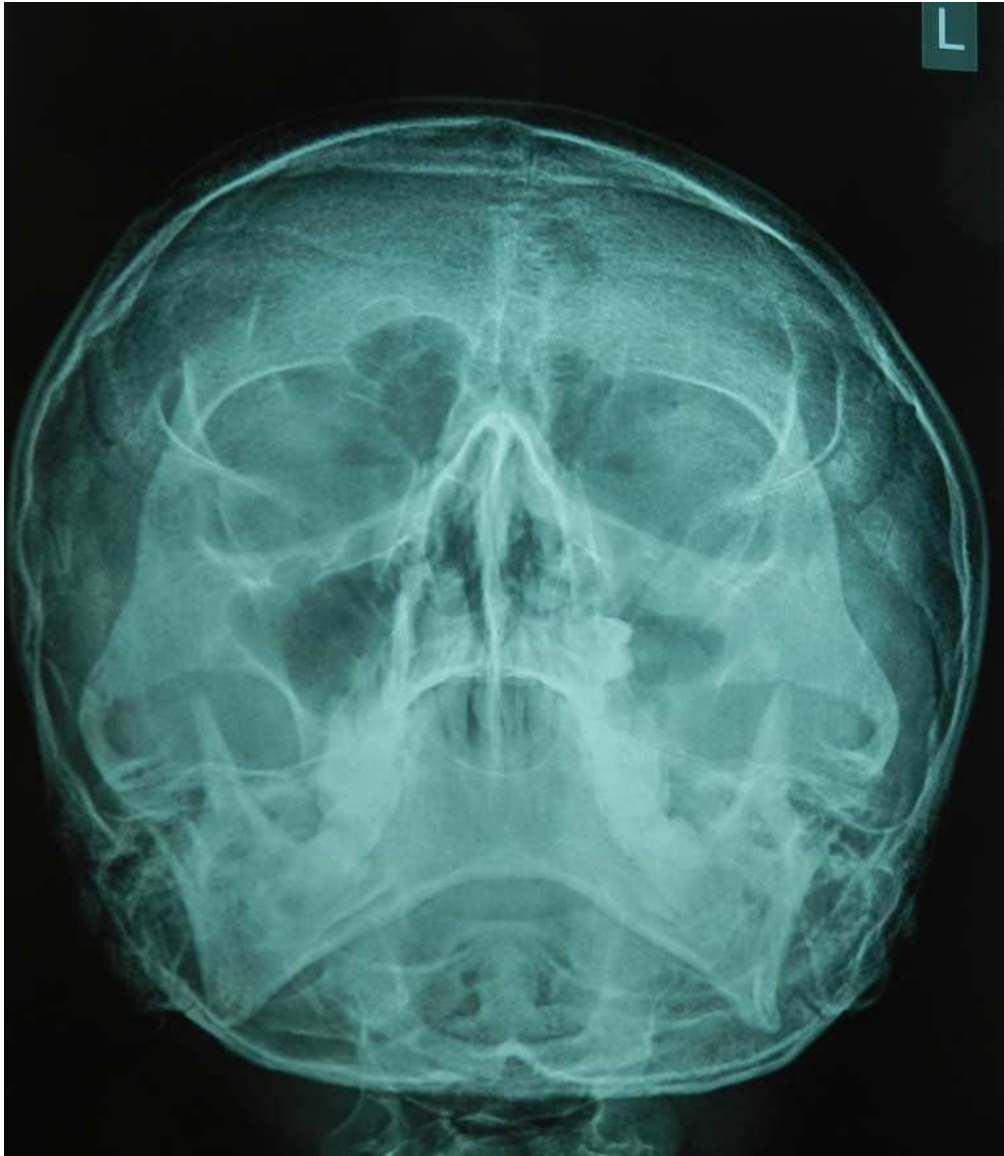


Figure 2. Water's View Confirming Third Molar in the Left Maxillary Sinus and Decreased Radiolucency

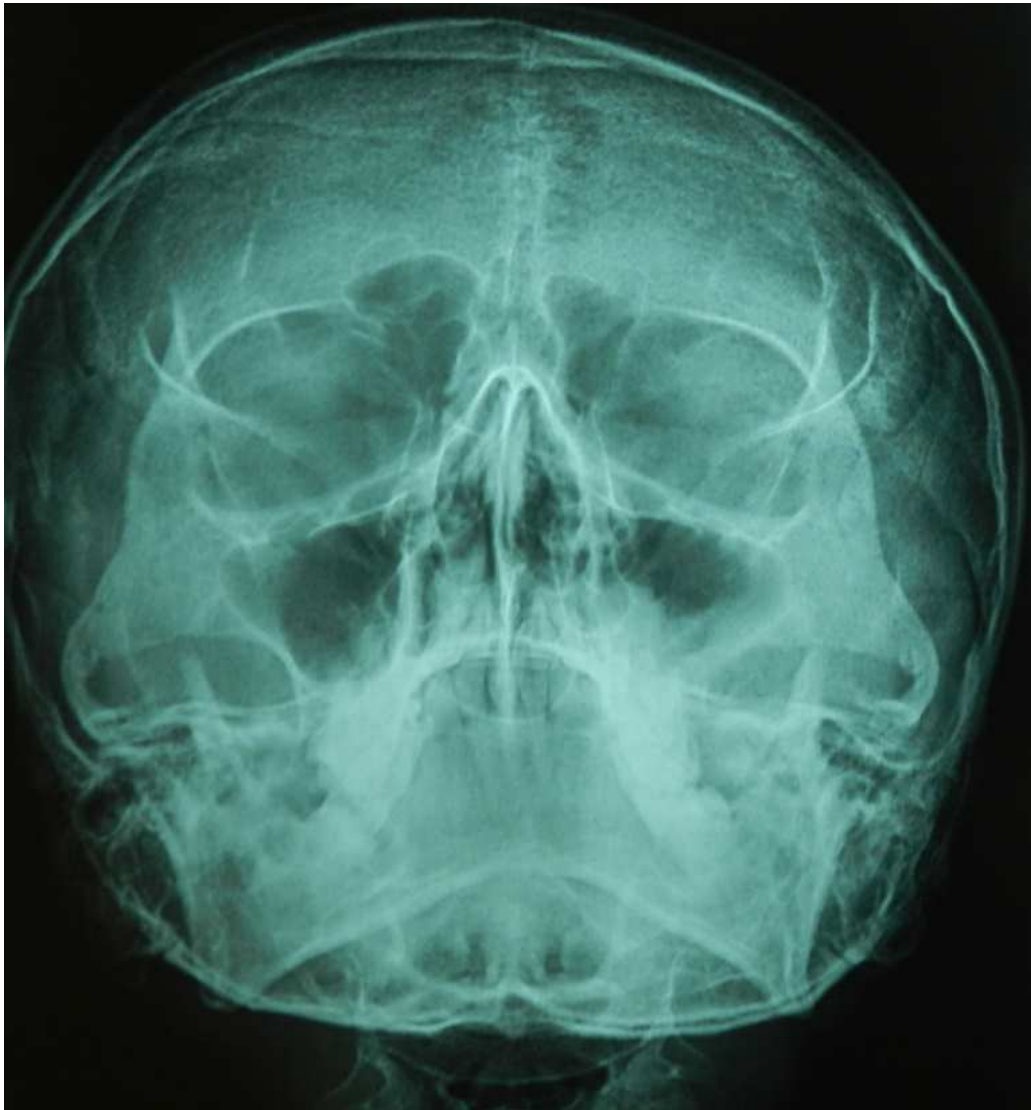

Figure 3. One and Half Months' Post-operative Radiograph Showing the Normal Radiolucency in the Left Maxillary Sinus

This academic article was published by The International Institute for Science, Technology and Education (IISTE). The IISTE is a pioneer in the Open Access Publishing service based in the U.S. and Europe. The aim of the institute is Accelerating Global Knowledge Sharing.

More information about the publisher can be found in the IISTE's homepage:

<http://www.iiste.org>

The IISTE is currently hosting more than 30 peer-reviewed academic journals and collaborating with academic institutions around the world. **Prospective authors of IISTE journals can find the submission instruction on the following page:**

<http://www.iiste.org/Journals/>

The IISTE editorial team promises to review and publish all the qualified submissions in a fast manner. All the journals articles are available online to the readers all over the world without financial, legal, or technical barriers other than those inseparable from gaining access to the internet itself. Printed version of the journals is also available upon request of readers and authors.

IISTE Knowledge Sharing Partners

EBSCO, Index Copernicus, Ulrich's Periodicals Directory, JournalTOCS, PKP Open Archives Harvester, Bielefeld Academic Search Engine, Elektronische Zeitschriftenbibliothek EZB, Open J-Gate, OCLC WorldCat, Universe Digital Library, NewJour, Google Scholar

