

## Aluminum Intoxication Induced Biochemical and Histopathological Alterations in Male Wistar Albino Rats Hepotocytes

P.N. Ogueche<sup>1</sup> C.E. Ugwu<sup>1</sup> D.N. Ezejindu<sup>2</sup> M. Omeje<sup>3</sup> C.C. Dike<sup>1</sup> C.O. Okonkwo<sup>4</sup>  
 H.C.C Maduka<sup>1</sup> Obidoa<sup>5</sup>

1.Department of Human Biochemistry, Faculty of Basic Medical Sciences, College of Health Sciences, Nnamdi Azikiwe University P.M.B 5001, Nnewi Campus, Anambra State, Nigeria. Postal code: 435001

2.Department of Human Anatomy, Faculty of Basic Medical Sciences, College of Health Sciences, Nnamdi Azikiwe University P.M.B 5001, Nnewi Campus, Anambra State, Nigeria. Postal code: 435001

3.Department of Human Physiology, Faculty of Basic Medical Sciences, College of Health Sciences, Nnamdi Azikiwe University P.M.B 5001, Nnewi Campus, Anambra State, Nigeria. Postal code: 435001

4.Department of Medical Biochemistry, Faculty of Natural Sciences, Cross-River State University of Technology, Ogoja Campus

5.Department of Biochemistry, Faculty of Biological Sciences, University of Nigeria, Nigeria

Corresponding author: e-mail: [pn.ogueche@unizik.edu.ng](mailto:pn.ogueche@unizik.edu.ng)

### Abstract

Aluminum is released into the environment both by natural and anthropogenic processes and its neurological effects are well documented but this effect is on the hepatocytes is poorly studied. This study evaluates the biochemical and histopathological alterations in hepatocytes of aluminum intoxicated rats. A total of sixteen (24) rats of eight (8) each in a group were given 3.8mg/kg and 38mg/kg body weight of aluminum (treated groups) and 0.2ml normal saline (control) respectively for days 7 and 14. The protein and aluminum levels, and histopathological examination were determined using standard methods. The weight of aluminum exposed rats differed significantly ( $p < 0.05$ ) after days 7, 10 and 14. The results showed significant increase ( $p < 0.05$ ) in aluminum levels in liver homogenate of the group given 38mg/kg, 3.8mg/kg and 38mg/kg after days 7 and 14 respectively. However, the protein level in liver homogenate decreased significantly ( $p < 0.05$ ) for the aluminum test group given 38mg/kg after days 7 and 14, as compared to the control. The results from this study showed that the liver sections collected from test animals showed proliferation of cells around the portal tract (PT) but the liver sections of control animals were normal with well preserved hepatic cells (H). This result suggests that aluminum ingestion induced accumulation, biochemical and histopathological alterations in aluminum exposed rats.

**Keywords:** Aluminum Intoxication, Histopathology, Cellular Proliferation.

### INTRODUCTION

Toxic metals are widely found in our environment and humans are exposed to them via water, contaminated air, food and soil. Aluminum (AL) belongs to this group of toxic metals. It is the third most common element in the earth's crust and is ubiquitous in the environment (Yao, 1994, Zatta, 1994, Domingo, 1995, Shafer, 1995) yet, its biological and biochemical functions still remain unknown (Yokel, 2002). The major contributors to aluminum exposure are water, air, foods with aluminum-containing food additives, grain products and processed cheese (Pennington and Schoen, 1995, Kumar and Gill, 2009) and drugs.

The availability and use of aluminum has elicited very many research interests in its toxicity. Aluminum is a constituent of cooking utensils, medicines such as antacids, deodorants, perspirants, food additives<sup>3</sup>, packaging foil, drying agent (e.g. sodium silico-aluminate- a fine powder), used to dry cocoa, salt and other products, flocculating agent in most municipal water supply (Kandiah and Kies, 1994) and this contributes to the aluminum burden of the human system via the gastrointestinal and the respiratory tracts. Target tissues for aluminum burden are bone, brain, kidney and liver. Signs and symptoms include: colic, dementia, esophagitis, gastro enteritis, kidney and liver damage (Rutter and Russel – Jones (eds), 1983, Yost, 1984, Pennington, 1987 and Greger, 1992).

Aluminum has been associated with several neurodegenerative diseases, such as Alzheimer's disease, Parkinson's disease, dialysis encephalopathy, amyotrophic lateral sclerosis and Guam-Parkinson's dementia (Kawahara, 2005, Bondy, 2010, Walton, 2011 and, Crisponi, Nurchi, Bertolasi and et al., 2012). The mechanisms underlying aluminum neurotoxicity are poorly understood, however it appears that the metal contributes to oxidative damage

(Nehru and Anand, 2005, Kumar et al., 2009, Kumar et al., 2009, Kumar et al., 2009), disruption of calcium homeostasis (Julka and Gill, 1996, Guo, and Liang, 2001 and, Kaur and Gill, 2005) and impairment of intracellular signal transduction pathways (Haug et al., 1994, Shi et al., 1993 and, Shafer and

Mundy,1995) .Aluminum as a neurotoxin has been numerously studied but the effects of aluminum on hepatocytes is poorly studied. Since, liver is one of the target tissues of aluminum burden and it is involved in the metabolism and detoxification of toxic metals, it may be vulnerable to attack and dysfunction. And this is the essence of this study. Specifically, to evaluate the biochemical and histopathological alteration in rats exposed to aluminum.

## **MATERIALS AND METHODS.**

Animals used for this work were male Wistar albino rats aged between 8-10 weeks with body weight range of 150-205g. They were obtained from the animal house of the Faculty of Biological Sciences University of Nigeria, Nsukka (UNN). The housing and handling of animals were in accordance with guidelines of our Institution's Animal ethics . All Chemicals used in this study were of analytical grade and were obtained from reputable companies (Merck, Germany; BDH Chemicals Ltd, Proole, England and May and Baker Ltd England).

## **EXPERIMENTAL DESIGN**

Twenty-four male rats (24) were housed in three separate cages of eight rats each and acclimatized for five days. The three groups viz: **Group 1** labeled Control administered 0.2ml of normal saline whereas **Group 2** and 3 were labeled treated groups administered 3.8mg/kg and 38mg/kg body weight of aluminum in the form of aluminum chloride. The route of administration was per oral (p/o). All groups were fed with commercial feed (grower's mash) and water *ad libitum* for seven and fourteen (14) days respectively. The animals were weighed on days 0, 3, 7, 10, and 14 for the determination of mean body weight and were later sacrificed and dissected on days 7 and 14 respectively. The liver was removed, weighed and washed with normal saline and homogenized in 25% Tris HCl (50mM) buffer pH 7.4. The homogenate was centrifuged at 10,000xg for 10 minutes and supernatant collected. This was stored in the refrigerator (0-4oC) and used for subsequent analysis within 48 hours, aluminum and protein levels were assayed by the methods of Taylor and Walker,1992, and Lowry et al., 1951 respectively . Histopathology examination of the liver were carried out by the methods of Disbrey and Rack, 1970; and Drury *et al.*, 1967 respectively.

## **RESULTS.**

### **MEAN BODY WEIGHT GAIN/ LOSS OF RATS**

The results from this study Table 1, show no significant difference ( $p>0.05$ ) between the body weight gain of control and all the test animals given 3.8 and 38mg/kg per kilogram body weight of  $AlCl_3$  after three days of aluminum exposure. However, the aluminum exposed groups showed significant decrease ( $p<0.05$ ) in the mean body weight after days 7,10 and 14 as compared to the control.

### **RELATIVE LIVER WEIGHT (AS A PERCENTAGE OF BODY WEIGHT)**

From Table 2, the results show no significant difference ( $p>0.05$ ) in the relative liver weight between the test groups and that of the control after seventh day of treatment. However, the relative liver weight of aluminum exposed animals decreased significantly ( $p<0.05$ ) when compared with the control after the fourteenth day of exposure.

### **ALUMINUM LEVEL IN LIVER HOMOGENATE ( $\mu g/l$ )**

From table 3.0 there was no significant increase ( $p>0.05$ ) in the aluminum level of the liver homogenate for the test group given 3.8mg/kg body weight while the test group given 38mg/kg showed a significant increase ( $P<0.05$ ) in aluminum level in liver homogenate after seven days respectively, relative to the control group.

However, aluminum level in the liver homogenate of the test groups given 3.8mg/kg and 38mg/kg were significantly higher ( $P<0.05$ ) as compared to the control group.

### **EFFECT OF ALUMINUM ON PROTEIN CONCENTRATION IN LIVER HOMOGENATE (mg/ml)**

Results in Table 4.0 showed significant decrease ( $P<0.05$ ) in protein concentration in the liver homogenate of the aluminum exposed group given 38mg/kg after seven and fourteen days respectively relative to the control. However, after seven and fourteen days, the aluminum exposed group given 3.8mg/kg showed a decrease in the mean body weight but were not statistically significant ( $p>0.05$ ) as compared with the control.

Histopathology of the liver cells of rats exposed to aluminum (38mg /kg body weight of  $AlCl_3$ ) after 14 days were examined.

Plates 3a-3c below depict photomicrographs of the H & E stained section of the liver cells of control and experimental rats. Our observations reveal that liver sections of aluminum-treated rats given 38mg/kg  $AlCl_3$  showed proliferation of cells around the portal tract (PT). These cellular proliferation around the portal tract were severe at fourteen days than at seven days of post-treatment. The control examined showed normal and well preserved portal tract (PT).

## **DISCUSSION.**

In the present study, we evaluated aluminum intoxication induced biochemical and histopathological alterations

in rats. The results of this work reveal that exposure to aluminum by oral intubation to rats produced some signs of toxicity such as reduction in the body and visceral organ weight and as well as protein concentration. The effect of aluminum on body weight gain was progressively decreased during the experimental period. The body weight of intoxicated rats (Table 1.0) with aluminum was significantly reduced than that of the control group. Similarly, the visceral organ (liver) weight as measured by percentage body weight was found to be reduced significantly relative to the control. Our result is contrary to the reports of Nayak and Chatterjee (1998). They had a different response on body weight. The difference in the body weight in the two studies may be attributed to either the difference in the route of administration (i.p) or dose (5mg) of aluminum given to the rats. However, Paternain *et al.*, (1988) reported that administration of aluminum as  $AlNO_3$  caused weight loss. The observed loss in weight for the rats exposed to aluminum thus suggests that aluminum probably interferes with normal metabolic (biosynthetic) processes. The growth of an organism integrates a range of physiological, biochemical and cellular processes. Thus, loss in body weight should be a sensitive indicator of a toxic impact. Body weights of the rats exposed to aluminum decreased with increase in concentration of aluminum. This is in line with the observation made by Donkin and Widdows, 1986, who stated that body weights of exposed organisms, decline in a predictable way with respect to the concentration of toxicant and duration.

Our results also indicate that aluminum administration leads to a significant increase ( $P < 0.05$ ) tissue (liver) aluminum concentrations. This elevation depends on the concentration and duration of exposure. Sampson *et al.*, (1989) found that serum aluminum level in renal patients maintained on hemodialysis was high and correlates with the intake and duration of aluminum consumption ( $Al(OH)_3$ ) in chronic renal failure.

Results from our work reveal significant reduction in liver protein concentrations of the aluminum exposed groups compared to the control group. The reduction in liver proteins observed in this work increased with increasing concentration and duration of the toxicant exposure, suggesting that aluminum exposure may interfere with protein synthesis. This interference may also have exposed proteins to a wide range of free radical species capable of oxidizing protein thiols, thus promoting the formation of disulphide bridges and even induction of protein fragmentation and catabolism. These will affect normal protein metabolism and growth, thus leading to the observed body weight loss. The present study shows that aluminum exposure to rats potentiates oxidative stress and cause protein carbonylation in the liver cells. May be in this way, aluminum promotes the formation of amyloid- $\beta$  protein plaques as reported by (Deloncle and Guillard, 1990, Kawahara *et al.*, 1994) by aggregating tau proteins in Alzheimer's disease Savory *et al.*, 1998.

In another work, Abubakar *et al.*, (2004), reported decreases in serum, liver and brain proteins during aluminum administration. However, this work is contrary to the report of Bondy *et al.*, (1998) who reported an increase in protein after aluminum administration. He placed the rats on a special food, selenium supplement, however. Similarly, the antibiotic known as puromycin inhibits protein synthesis and thus causes a fatty liver and marked reduction in the concentration of very low density lipoprotein (VLDL) in rats. Other substances that act similarly include ethionine ( $\alpha$ -amino-mercaptobutyric acid),  $CCL_4$ , chloroform, phosphorous, lead, aluminum, and arsenic (Konat and Wiggins, 1985).

Results of our histopathological studies (H&E) have revealed that aluminum affects the architectural and normal cell division of hepatocytes of aluminum exposed rats after day 14. Proliferation of cells around the portal tract (PT) of the liver of test animals (rats), which is one of the lesions found in cases of intoxication suggest that aluminum exposure to rats disrupts its normal cell division probably as a result of aluminum accumulation and inhibition of protein synthesis hence, potentiates oxidative stress. These observations reveal that aluminum induces hepatotoxicity.

## CONCLUSION.

It is suggestive that the reduction in bodyweight and protein concentration as well as proliferation of cells in hepatocytes indicates that aluminum induces hepatotoxicity and the mechanism may be due to its accumulation in hepatocytes.

**Conflict of Interest:** None Declared.

**Ethical approval:** This experiment was approved by the Institution's Laboratory Care and Use of Animal Committee.

## REFERENCES.

- Abbasali, K.M., Zhila, T. and Farshad, N. (2005). Developmental toxicity of aluminium from high doses of  $AlCl_3$  in Mice. *J of Appl Res.* 5: 4.
- Abubakar, M.G., Taylor, A. and Ferns, G.A. (2004). The effects of aluminium and selenium supplementation on brain and liver antioxidant status in the rat. *Afr. J. of Biotechnol.* 3 (1): 88-93.
- Agrawal, S.K, Ayyash, L., Gourley, C.S., Levey, J., Faber, K. and Haghies, C.L. (Jr). (1996). Evaluation of developmental Neuroendocrine and reproductive toxicology of aluminium. *Food Chem. Toxicol.* 34: 49-53.

- Bondy, S.C.(2010) The neurotoxicity of environmental aluminum is still an issue. *Neurotoxicology*. 31(5):575–581. [PMC free article] [PubMed]
- Crisponi, G, Nurchi, V.M., Bertolasi, V and et al.(2012). Chelating agents for human diseases related to aluminium overload. *Coord Chem Rev*.256:89–104.
- Dominigo, J.L. (1995). Reproductive and developmental toxicity of aluminium: a review. *Neurotoxicol Teratol*. 17: 515-521.
- Donkin, P. and Widdows, J. (1986). Scope for growth as a measure of environmental pollution and its interpretation using structure-activity relationships *Chem. Ind*. 21: 732-735.
- Disbrey, R.D. and Rack, J.H. (1970). *Histological laboratory methods E and S Livingston, Edinburgh and London*. Pp 1-40.
- Drury, R.A., Wallington, A. and Cameroon, S.R. (1967). In Carleton's *Histological techniques*. Oxford University Press. New York. Pp 1-420.
- Guo, G.W. and Liang, Y.X. (2001). Aluminum-induced apoptosis in cultured astrocytes and its effect on calcium homeostasis. *Brain Res*. 888(2):221–226. [PubMed]
- Haug, A., Shi, B. and Vitorello, V.(1994). Aluminum interaction with phosphoinositide-associated signal transduction. *Arch Toxicol*.68(1):1–7. [PubMed]
- Julka, D., and Gill, K.D.(1996). Altered calcium homeostasis: a possible mechanisms of aluminium-induced neurotoxicity. *Biochim Biophys Acta*.1315(1):47–54. [PubMed]
- Kandiah, J. and Kies, C. (1994). Aluminium concentration in tissues of rats: effect of soft drink packaging. *Biometals*: 7(1): 57-60.
- Kaur, A, and Gill,K.D.(2005) Disruption of neuronal calcium homeostasis after chronic aluminium toxicity in rats. *Basic Clin Pharmacol Toxicol*. 96(2):118–122. [PubMed]
- Kawahara, M.(2005) Effects of aluminum on the nervous system and its possible link with neurodegenerative diseases. *J Alzheimers Dis*. 8(2):171–182. discussion 209-215. [PubMed]
- Kumar, V and Gill, K.D. (2009) Aluminium neurotoxicity: neurobehavioural and oxidative aspects. *Arch Toxicol*. 83(11):965–978. [PubMed]
- Kumar, V., Bal, A and Gill, K.D.(2009) Aluminium-induced oxidative DNA damage recognition and cell-cycle disruption in different regions of rat brain. *Toxicology*. 264(3):137–144. [PubMed]
- Kumar, V., Bal, A and Gill KD.(2009). Susceptibility of mitochondrial superoxide dismutase to aluminium induced oxidative damage. *Toxicology*.255(3):117–123. [PubMed].
- Kumar, A., Dogra, S.and Prakash, A.(2009). Protective effect of curcumin (*Curcuma longa*), against aluminium toxicity: Possible behavioral and biochemical alterations in rats. *Behav Brain Res*. 205(2):384–390. [PubMed]
- Nayak, P. and Chatterjee, A.K. (1998). Impact of protein malnutrition on subcellular nucleic acid and protein status of brain of aluminium--exposed rats. *J. Toxicol. Sci*. 23: 1-14.
- Nehru, B and Anand, P.(2005). Oxidative damage following chronic aluminium exposure in adult and pup rat brains. *J Trace Elem Med Biol*.19(2-3):203–208. [PubMed]
- Nicholls, D.M. Spears, G.M., Asina, S., Miller A.C.M. (1995). Brain mRNA from infants of aluminium-exposed lactating rabbits. *Int. J. Biochem. Cell Biol*. 27: 365-370.
- Paternain, J.L., Domingo, J.L., Liobet, J.M. and Corbella, J. (1988). Embryotoxic and teratogenic effects of aluminium nitrate in rats upon oral administration. *Teratology*. 38: 253-257.
- Pennington, J.A and Schoen, S.A.(1995).Estimates of dietary exposure to aluminium. *Food Addit Contam*. 12(1):119–128. [PubMed]
- Pennington, J.A.T. (1987). Aluminium content of foods and diets. *Food Add. Contam*. 5: 161-232.
- Rutter, M. and Russell-Jones, R. (1983). Lead versus health: Sources and effects of low level lead exposure. *New York. John Wiley Publishers* New York .Pp 210-235.
- Shafer, T.J.and Mundy, W.R.(1995). Effects of aluminum on neuronal signal transduction: mechanisms underlying disruption of phosphoinositide hydrolysis. *Gen Pharmacol*. 26(5):889–895. [PubMed].
- Shi, B., Chou, K. and Haug, A.(1993). Aluminum impacts elements of the phosphoinositide signalling pathway in neuroblastoma cells. *Mol Cell Biochem*. 121(2):109–118. [PubMed]
- Walton, J.R.(2011) Bioavailable Aluminum: Its Effects on Human Health. *Encyclopedia of Environmental Health*. 331–342.
- Yao, X.L., Jenkins, E.C.,and Wisniewski, H.M.(1994). Effect of aluminum chloride on mitogenesis, mitosis, and cell cycle in human short-term whole blood cultures: lower concentrations enhance mitosis. *J Cell Biochem*. 54(4):473–477. [PubMed]
- Yokel, R.A.(2002). Aluminum chelation principles and recent advances. *Coord Chem Rev*. 228:97–113.
- Yost, K. J. (1984). Cadmium, the environment and human health. *An overview* . *Experientia* 40: 157-164.
- Yumoto, S., Nagai, H., Matsuzaki, H. (2001) Aluminium incorporation into the brain of rat fetuses and sucklings. *Brain Res Bull*. 55: 229-234.
- Zatta, P.F., Zambenedetti, P. and Masiero, S.(1994). Effects of aluminum lactate on murine neuroblastoma cells.

Neurotoxicology. 15(4):789–797. [PubMed]

5. Deloncle R, Guillard O. Mechanism of Alzheimer’s disease: arguments for a neurotransmitter-aluminium complex implication. *Neurochem Res.* 1990;15(12):1239–45. [PubMed]
6. Kawahara M, Muramoto K, Kobayashi K. et al. Aluminum promotes the aggregation of Alzheimer’s amyloid beta-protein in vitro. *Biochem-Biophys Res Commun.* 1994;28: 198(2):531–535. [PubMed]
7. Savory J, Huang Y, Wills MR. et al. Reversal by desferrioxamine of tau protein aggregates following two days of treatment in aluminum-induced neurofibrillary degeneration in rabbit: implications for clinical trials in Alzheimer’s disease. *Neurotoxicology.* 1998;19(2):209–14. [PubMed]

Table 1.0 Mean Body Weight (g).

DAYS/GROUPS	3	7	10	14
Control	18.23±5.85	35.72±4.22	44.60±6.07	41.43±8.60
3.8mg/kg	20.08±4.40	18.33±2.56*	16.77±2.40*	15.53±2.97*
38mg/kg	16.40±1.30	12.08±1.92*	9.80±3.50*	9.53±3.01*

Table 2.0 Relative Visceral Organ (Liver) Weight (Percentage body weight).

DAYS/GROUPS	Control	3.8mg/kg	38mg/kg
7	3.85±0.31	3.82±0.23	3.80±0.06
14	4.27±0.13	3.91±0.21	3.04±0.14


Table 3.0 Aluminum levels in liver.

DAYS/GROUPS	Control	3.8mg/kg	38mg/kg
7	0.97±0.15	4.20±2.96	6.02±1.18*
14	1.26±0.38	3.98±0.45*	6.59±1.25*

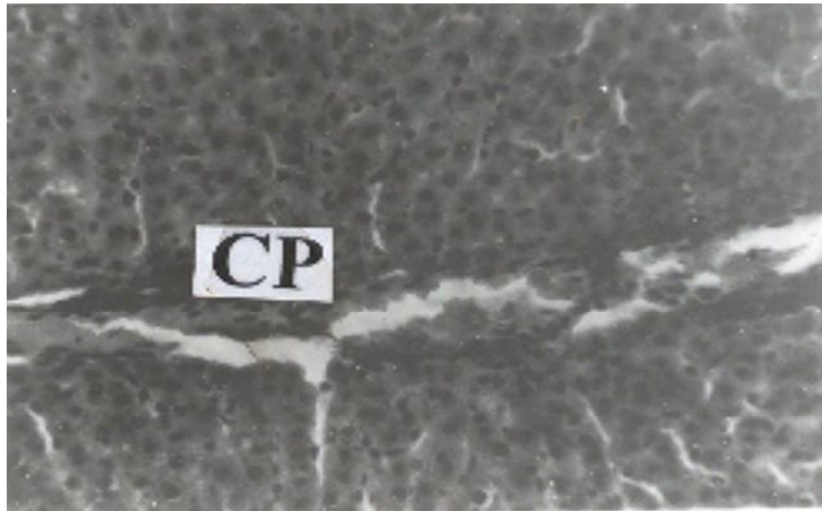
Table 4.0 Liver Protein concentration (mg/ml).

DAYS/GROUPS	Control	3.8mg/kg	38mg/kg
7	1.59±0.21	1.47±0.15	1.30±0.13*
14	1.63±0.16	1.50±0.29	1.40±0.10*

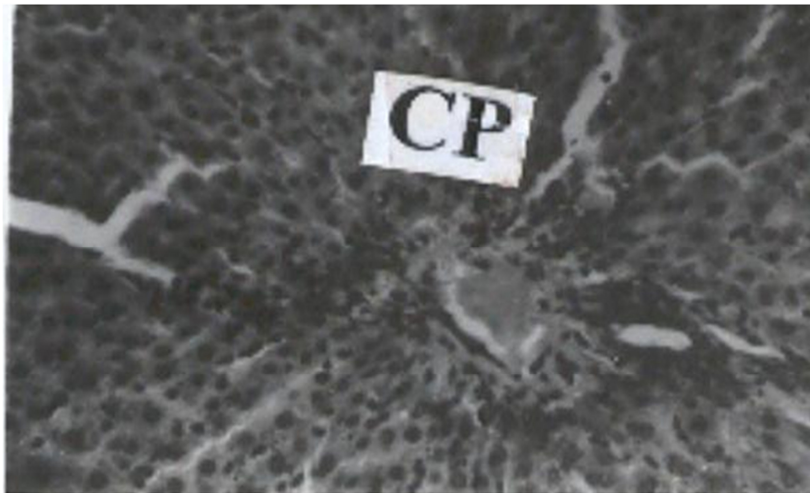
\*Significant difference between the control and Al exposed groups



**Plate 3a:** Liver section of a control rat showing well preserved hepatic cells (H). (H and E stain x 400).



**Plate 3b:** Liver section of a rat given 38 mg/kg body weight  $\text{AlCl}_3$  for seven days showing cellular proliferation (CP) at the portal tract. (H and E stain x 400).



**Plate 3c:** Liver section of a rat given 38 mg/kg body weight  $\text{AlCl}_3$  for fourteen days showing severe cellular proliferation (CP) at the portal tract. (H and E stain x 400).

The IISTE is a pioneer in the Open-Access hosting service and academic event management. The aim of the firm is Accelerating Global Knowledge Sharing.

More information about the firm can be found on the homepage:

<http://www.iiste.org>

## CALL FOR JOURNAL PAPERS

There are more than 30 peer-reviewed academic journals hosted under the hosting platform.

**Prospective authors of journals can find the submission instruction on the following page:** <http://www.iiste.org/journals/> All the journals articles are available online to the readers all over the world without financial, legal, or technical barriers other than those inseparable from gaining access to the internet itself. Paper version of the journals is also available upon request of readers and authors.

## MORE RESOURCES

Book publication information: <http://www.iiste.org/book/>

Academic conference: <http://www.iiste.org/conference/upcoming-conferences-call-for-paper/>

## IISTE Knowledge Sharing Partners

EBSCO, Index Copernicus, Ulrich's Periodicals Directory, JournalTOCS, PKP Open Archives Harvester, Bielefeld Academic Search Engine, Elektronische Zeitschriftenbibliothek EZB, Open J-Gate, OCLC WorldCat, Universe Digital Library, NewJour, Google Scholar

