

Pathological alterations in the liver of post-juvenile African Catfish (*Clarias gariepinus*) exposed to sublethal concentrations of the herbicide Glyphosate.

*¹ Nosakhare Osazee Erhunmwunse ²Alohan, F.I., ³, Alex Enuneku ⁴ Isioma Tongo ⁵ Martins Ainerua
⁶Stefano Idugboe,

¹ Ecophysiology, ¹⁻⁶ Ecotoxicology and ^{1,3-6} Pathophysiology Laboratory
 Animal and Environmental Biology, faculty of Life Sciences, University
 of Benin, P.M.B 1154, Benin City. Nigeria

*Corresponding Author's Email: donsazy@yahoo.co.uk

The research was financed by:

The National Centre for Energy and Environment (NCEE), Energy Commission of Nigeria, University of Benin

ABSTRACT

The use of histopathological techniques allows investigators to examine specific target organs and cells to determine how they are affected by exposure to environmental chemicals like pesticides. Moreover, it offers a means of detecting acute and chronic harmful effects of exposure in the tissues and organs of individual animals. In this study, histopathological alterations in the liver of post-juvenile African catfish *Clarias gariepinus* exposed to varying concentration of the commonly used herbicide glyphosate (IPA 360g/L) were used as biomarkers of effect, and alterations were both concentration and time specific. Cellular rupture, aggregation of inflammatory cells, vacuolar degeneration in the hepatocytes, focal areas of necrosis, and rupture of blood vessels that resulted in haemorrhage were characteristic of Glyphosate-exposed liver. The observed alterations in the liver of *C. gariepinus* further provide evidence to support the use of pathological change in fish as an indicator for monitoring the effect of exposure to low levels of toxicants, which are capable of altering the physiological profile of an organism.

Keywords: Pathology, Toxicity, Liver, Health, Glyphosate, Biomarker.

1.0 INTRODUCTION

Histopathological changes have been widely used as biomarkers in the evaluation of the health of fish exposed to contaminants, both in the laboratory (Wester and Canton, 1991; Thophon *et al.*, 2003) and field studies (Hinton *et al.*, 1992; Schwaiger *et al.*, 1997; Teh *et al.*, 1997). One of the great advantages of using Histopathological biomarkers in environmental monitoring is that this category of biomarkers allows examining specific target organs, including gills, kidney and liver, that are responsible for vital functions, such as respiration, excretion and the accumulation and biotransformation of xenobiotics in the fish (Gernhofer *et al.*, 2001). The liver carries out essential body functions including regulation of metabolism, synthesis of plasma proteins, energy storage, storage of certain vitamins and trace metals and transformation and excretion of steroids and detoxification of xenobiotics. In general, the liver is a target organ due to its large blood supply that causes significant toxicant exposure and accumulation, as well as its major roles in toxicant metabolism and clearance (Mohamed, (2009). The organ most associated with the detoxification and biotransformation process is the liver, and due to its function, position and blood supply (Van der Oost *et al.*, 2003) it is also one of the organs most affected by contaminants in the water (Rodrigues and Fanta, 1998). Numerous categories of liver pathology are present as reliable biomarkers of toxic damage (Kohler, 1990; Stentiford, *et al.*, 2003), therefore studies on liver histopathology in fish have increasingly been incorporated in national marine biological effects monitoring programs in both Europe and the USA (Lang, T., 2002; Feist *et al.*, 2004). Myers *et al.*, (1987), generally classified flatfish hepatic alterations into several distinct groups and it could be possible to rank them according to their relative importance as indicators of toxicant exposure. Specific nonneoplastic proliferative lesions including hepatocellular regeneration, bile duct hyperplasia and hepatic fibrosis, in addition to general or non-specific degenerative alterations such as cellular necrosis, hyaline inclusion bodies comprise a second group of hepatic lesions. Inflammatory changes comprise a third group of liver alterations. Ultimately, inflammatory changes consists a third group of liver alterations, which is considered as minimal significant indicator of pollutant exposure group can offer more information on the general health status and condition of the fish. According to Negin and Mehdi (2012), liver histopathological lesions are not specific to pollutants. Fanta *et al.*, (2003) reported abnormalities such as irregular shaped hepatocytes, cytoplasmic vacuolation and nucleus in a lateral position in the siluriform *Corydoras paleatus* exposed to organophosphate pesticides. Camargo and Martinez, (2007) observed signs of degeneration (cytoplasmic and nuclear degeneration and nuclear vacuolation) and focal necrosis in the liver parenchyma of fishes exposed to the water of the Cambe River, lesions which are more commonly associated with the exposure to metals (Please provide a reference here). Lesions including hepatocellular cytoplasmic vacuolization, leucocytic infiltrates, vascular congestion, necrosis and fatty

infiltrations were found in the liver of catfish *Clarias gariepinus* treated with fenvalerate (Sakr *et al.*, 2001)

1.1.0 Materials and Methods

1.1.1 Experimental fish specimen and chemicals

One hundred and twenty healthy post juvenile *Clarias gariepinus* of both sexes with a mean weight of 135.44 ± 1.99 g and mean length of 28.32 ± 0.844 cm were purchased from Osayi farms in Benin City, Edo state. They were kept in 60 l aquaria at 27.5 ± 0.4 °C, pH 7.3, with 12:12 h photoperiod. They were left unfed in the first 2 days to adapt to a change in environment before feeding them with the fish diet. Laboratory aquaria were well aerated and provided with external filtration and a layer of gravel on the bottom. Fish were normally fed once a day with pelleted commercial food (Durante Aquaculture fish concentration-2mm). They were allowed to acclimate to captivity conditions for three weeks prior to the start of the experiment. Careful netting and handling was implemented to minimize stress.

The commercial formulation of glyphosate (360 g/l-41 w.wt IPA) at four nominal concentrations 72, 54, 32 and 18 mg/L were used for sub-lethal test and two replicates test each was done along-side the main experiment. These concentrations were defined taking into account the result of the range finding test. This was done in a static renewal assay.

1.1.2 Histological Procedure

Fishes were harvested after 28 days of exposure from the four nominal concentrations and the control sacrificed. The target organ (Liver) was removed immediately and washed in saline water to remove blood and fixed in aqueous Bouin's fixative for 24 hours. They were then dehydrated through graded series of ethanol and embedded in paraffin wax (M.P. 58-68°C). Blocks were prepared and sectioned at a thickness of 6-7 microns. The sections were deparaffinized in xylene and stained with haematoxylin-eosin (HE). Changes induced by glyphosate exposure in the tissue of organs were analyzed and photographed under photomicroscope along with control group (Humason, 1979).

1.1.3 Results and Discussion.

Histopathology alteration has been increasingly recognized as a valuable tool for the assessment of the impact of environmental pollutants on fishes (Heath, 1995; Teh *et al.*, 1997). Liver tissues of post Juvenile African catfish *C. gariepinus* exposed to different concentrations of Glyphosate herbicides showed extensive degeneration of histological structure (Plate 1b-e) compared to the control (Plate 1a). Morphological changes in the liver were more evident in exposed animals than the control. Photomicrograph of the control liver (1a) showed a normal hepatic lobule showing hepatocytes and the hepatic sinusoids between the hepatocyte. Histological changes appear as a medium term response to sub-lethal stressors, and histology provides a rapid method to detect effects of irritant, especially chronic ones, in various tissue and organs (Johnson, 1993). Results of this study revealed that post juvenile *C. gariepinus* exposed to sublethal concentration of glyphosate manifested histological alteration in Liver and was dose and time dependent.

The liver of post juvenile *C. gariepinus* exposed to varying concentration of glyphosate herbicide in this study showed cellular rupture, aggregation of inflammatory cells, vacuolar degeneration in the hepatocytes, focal areas of necrosis, rupture of blood vessel that resulted in haemorrhage. The nature of the liver damage was concentration dependent. The alterations observed may be attributed to direct effect of herbicide on hepatocytes, since the liver is the site of detoxification of all chemicals and toxins (Soufy *et al.*, 2007). These results also indicate that *C. gariepinus* may be more sensitive species to the environmental changes because it presented higher incidence of liver anomalies compared with the control. The rupture of blood cells may be responsible for the cellular degeneration and necrosis in the liver (Mohamed, 2001). The findings of this study is also similar with that of Gill *et al.*, (1991) who reported hepatic lesion including hypertrophy, vacuolization, nuclear pycnosis, fatty degeneration of hepatocytes in fresh water, *Punctius conchoniis*.

Fanta *et al.*, (2003) reported abnormalities such as irregular shaped hepatocytes, cytoplasmic vacuolation and nucleus in a lateral position in the siluriform *Corydoras paleatus* exposed to organophosphate pesticides. Pacheco and Santos (2002) observed increased vacuolation of the hepatocytes as a sign of metabolic damage, perhaps correlated to exposure to polluted water. Camargo and Martinez (2007) observed signs of degeneration (cytoplasmic and nuclear degeneration and nuclear vacuolation) and the focal necrosis in the liver parenchyma of fishes exposed to the water of the Cambe River. Olojo *et al.*, (2005) observed degeneration of the hepatocytes and focal necrosis in the liver of *Clarias gariepinus* exposed to lead. Anomalies such as irregular shaped

hepatocytes, cytoplasmic vacuolation and nucleus in a lateral position, close to the cell membrane, were also described in the siluriform *Corydoras paleatus* contaminated by organophosphate pesticides (Fanta *et al.*, 2003). Pacheco and Santos (2002) described increased vacuolisation of the hepatocytes as a signal of degenerative process that suggests metabolic damage, possibly related to exposure to contaminated water.

The histological changes observed in the liver of the *C. gariepinus* in the present study indicate that the fish were responding to the direct effects of the contaminant, glyphosate (360g/L) as much as to the secondary effects caused by stress

References

- Camargo, M. M. P. and Martinez, C. B. R. (2006). Biochemical and physiological biomarkers in *Prochilodus lineatus* submitted to *in situ* tests in an urban stream in southern Brazil. *Environmental Toxicology and Pharmacology*, **21**: 61-69.
<http://dx.doi.org/10.1016/j.etap.2005.07.016>
- Fanta, E., Rios, F. S., Romão, S., Vianna, A. C. C. and Freiberger, S. (2003). Histopathology of the fish *Corydoras paleatus* contaminated with sublethal levels of organophosphorus in water and food. *Ecotoxicology and Environmental Safety*, **54**: 119-130.
[http://dx.doi.org/10.1016/S0147-6513\(02\)00044-1](http://dx.doi.org/10.1016/S0147-6513(02)00044-1)
- Feist, S.W., Lang, T., Stentiford, G.D and Kohler, A. (2004). Biological effects of contaminants: use of liver pathology of the European flatfish dab (*Limanda limanda* L.) and flounder (*Platichthys flesus* L.) for monitoring. ICES Techniques in Marine Environmental Sciences No. 38, ICES, Copenhagen.
- Gernhofer, M., Pawet, M., Schramm, M., Müller, E and Triebkorn, R. (2001). Ultrastructural biomarkers as tools to characterize the health status of fish in contaminated streams. *Journal of Aquatic Ecosystem, Stress and Recovery*, **8**: 241-260.
10.1023/A:1012958804442
- Heath, A.C. (1995). Water pollution and fish physiology. (2nd Edn) Lewis Publishers Boca Raton. pp. 125-140.
- Hinton, D. E., Baumann, P.C., Gardner, G.R., Hawkins, W. E., Hendricks, J. D., Murchelano, R. A and Okihiro, M. S. (1992). Histopathologic biomarkers. In: Hugget, R., R. Kimerle, P. Mehrle and H. Bergman (Eds.). Biomarkers – biochemical, physiological and histological markers of anthropogenic stress. Boca Raton, Lewis Publishers. pp.155-195.
- Johnson, L.L., Stehr, C.M., Olson, O.p., Myers, M.S., Plerce, S.M., Wigren, C.A., McCain, B.B & Varanasi, U. (1993). Chemical contaminants and hepatic lesions in winter flounder (*Pleuronectes americanus*) from the northeast coast of the United States. *Environ. Science Technol.*, **27**: 2759-2771.
- Kohler, A. (1990). Identification of contaminant-induced cellular and subcellular lesions in the liver of flounder (*Platichthys flesus* L.) caught at differently polluted estuaries. *Aquatic Toxicol.*, **16**: 271- 294.
- Lang, T. (2002). Fish disease surveys in environmental monitoring: the role of ICES. *ICES Marine Science Symposia*, **215**: 202-212.
- Mohamed, F.A.S. (2009). Histopathological Studies on *Tilapia zillii* and *Solea vulgaris* from Lake Qarun, Egypt. *World J. Fish and Marine Sciences*, **1(1)**: 29-3.
- Myers, M.S., Rhodes, L.D & McCain, B.B. (1987). Pathologic anatomy and patterns of occurrence of hepatic neoplasms, putative preneoplastic lesions and other idiopathic hepatic conditions in English sole (*Parophrys vetulus*) from Puget Sound, Washington, USA. *J. Natl. Cancer Inst*, **78**: 333-363.
- Negin, S & Mehdi, Z. (2012). Using of Fish Pathological Alterations to Assess Aquatic Pollution: A Review. *World Journal of Fish and Marine Sciences*, **4 (3)**: 223-231.
- Olojo, E. A. A., Olurin, K. B., Mbaka, G. & Oluwemimo, A. D (2005). Histopathology of gills and liver tissues of the African catfish *Clarias gariepinus* exposed to lead. *Afr. J. of Biotech.*, **4 (1)**:117-122.

- Pacheco, M. & Santos, M.A. (2002). Biotransformation, genotoxic and histopathological effects of environmental contaminants in European eel (*Anguilla anguilla* L.). *Ecotoxicology and Environmental Safety*, **53**: 331-347.
[http://dx.doi.org/10.1016/S0147-6513\(02\)00006-4](http://dx.doi.org/10.1016/S0147-6513(02)00006-4)
- Rodrigues, E. L. & Fanta, E. (1998). Liver histopathology of the fish *Brachydanio rerio* after acute exposure to sublethal levels of the organophosphate Dimetoato 500. *Revista Brasileira de Zoologia*, **15**: 441-450.
<http://dx.doi.org/10.1590/S0101-81751998000200014>
- Sakr, S.A., Hanafy, S.M & El-Desouky, N. E (2001). Histopathological, histochemical and physiological studies on the effect of the insecticide, hostathion, on the liver of the catfish *Clarias gariepinus*. *Egyptian J. Aquatic Biology Fish*, **6(2)**: 103-124
- Schwaiger, J., Wanke, R., Adam, S., Pawert, M., Honnen, W & Triebkorn, R. (1997). The use of histopathological indicators to evaluate contaminant-related stress in fish. *Journal of Aquatic Ecosystem, Stress and Recovery*, **6**:75-86.
10.1023/A:1008212000208
- Stentiford, G.D., Longshaw, M., Lyons, B.P., Jones, G., Green, M & Feist, S.W. (2003). Histopathological biomarkers in estuarine fish species for the assessment of biological effects of contaminants. *Marine Environmental Res.*, **55**: 137-159.
- Teh, S. J., Adams, S. M & Hinton, D. E. (1997). Histopathological biomarkers in feral freshwater fish populations exposed to different types of contaminant stress. *Aquatic Toxicology*, **37**: 51-70.
[http://dx.doi.org/10.1016/S0166-445X\(96\)00808-9](http://dx.doi.org/10.1016/S0166-445X(96)00808-9)
- Thophon, S., Kruatrachue, M., Upathan, E. S., Pokethitiyook, P., Sahaphong, S & Jarikhuan, S. (2003). Histopathological alterations of white seabass, *Lates calcarifer* in acute and subchronic cadmium exposure. *Environmental Pollution*, **121**: 307-320.
[http://dx.doi.org/10.1016/S0269-7491\(02\)00270-1](http://dx.doi.org/10.1016/S0269-7491(02)00270-1)
- Van der Oost, R., Beber, J & Vermeulen, N. P.E. (2003). Fish bioaccumulation and biomarkers in environmental risk assessment: a review. *Environmental Toxicology and Pharmacology*, **13**: 57-149.
[http://dx.doi.org/10.1016/S1382-6689\(02\)00126-6](http://dx.doi.org/10.1016/S1382-6689(02)00126-6)
- Wester, P. W. & Canton, J. H. (1991). The usefulness of histopathology in aquatic toxicity studies. *Comparative Biochemistry and Physiology (C)*, **100**: 115-117.
[http://dx.doi.org/10.1016/0742-8413\(91\)90135-G](http://dx.doi.org/10.1016/0742-8413(91)90135-G)

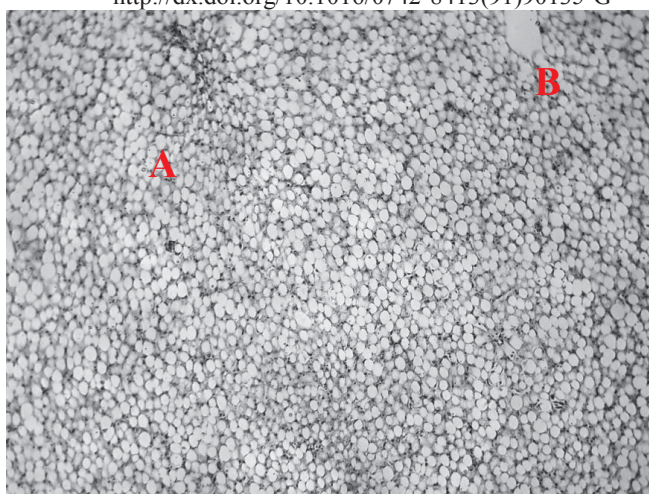


Plate 1a: Photomicrograph of Liver of Controlled *C. gariepinus* showing normal histological structure. Hepatocytes are showed as (A) and (B). No visible lesion was observed in the control sample. (H & E stain x100).

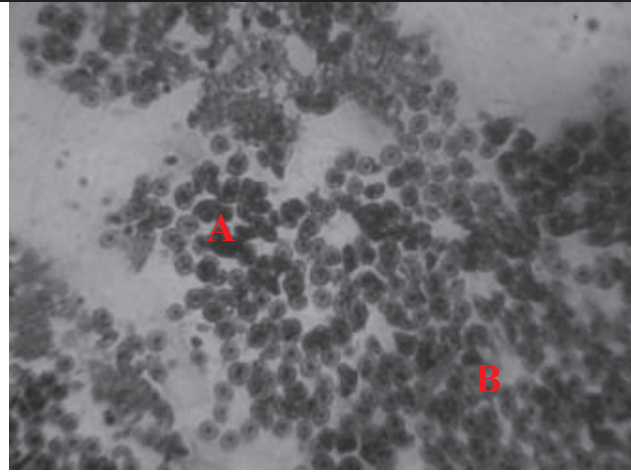


Fig 1b: Photomicrograph of liver of *C. gariepinus* exposed to 72 mg/L glyphosate. Necrosis (A), degeneration of cells (B), Cell vacuolization and degeneration of hepatocyte (C) (H & E stain x100)

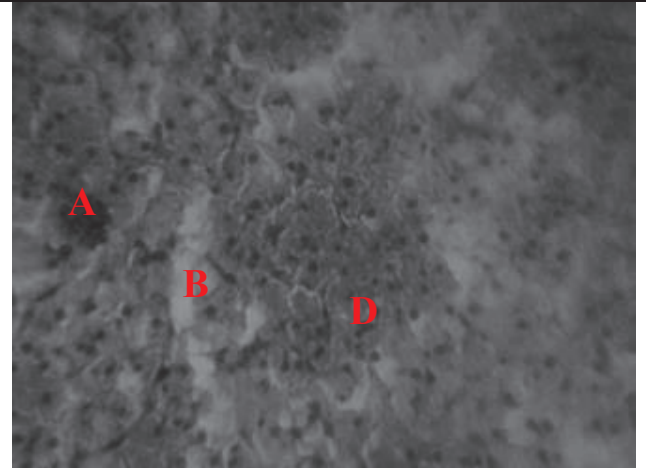


Fig1 c: Photomicrograph of liver of *C. gariepinus* exposed to 54 mg/L glyphosate. Severe dilation of liver structure associated with necrosis (A), cellular vacuolization (B) and degeneration of hepatocyte (D) (H & E stain x100)




Fig 1d: Photomicrograph of liver of *C. gariepinus* exposed to 32 mg/L glyphosate. High cellular vacuolization (A) and degeneration of hepatocyte (B) (H & E stain x100)

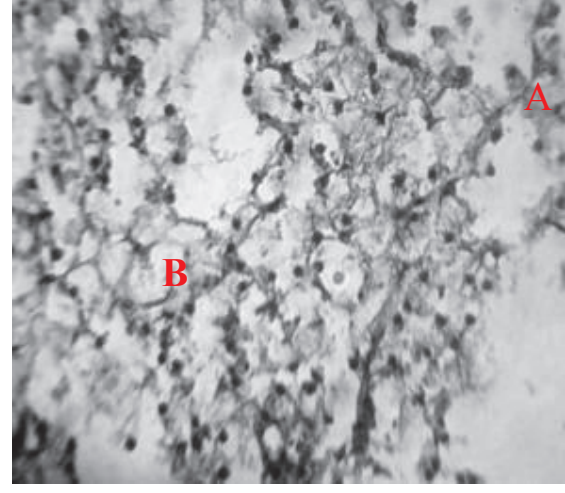


Fig Plate 1d: Photomicrograph of liver of *C. gariepinus* exposed to 18 mg/L glyphosate. Cell vacuolization (A) and degeneration of hepatocyte (B) (H & E stain x100)

This academic article was published by The International Institute for Science, Technology and Education (IISTE). The IISTE is a pioneer in the Open Access Publishing service based in the U.S. and Europe. The aim of the institute is Accelerating Global Knowledge Sharing.

More information about the publisher can be found in the IISTE's homepage:

<http://www.iiste.org>

CALL FOR JOURNAL PAPERS

The IISTE is currently hosting more than 30 peer-reviewed academic journals and collaborating with academic institutions around the world. There's no deadline for submission. **Prospective authors of IISTE journals can find the submission instruction on the following page:** <http://www.iiste.org/journals/> The IISTE editorial team promises to review and publish all the qualified submissions in a **fast** manner. All the journals articles are available online to the readers all over the world without financial, legal, or technical barriers other than those inseparable from gaining access to the internet itself. Printed version of the journals is also available upon request of readers and authors.

MORE RESOURCES

Book publication information: <http://www.iiste.org/book/>

Recent conferences: <http://www.iiste.org/conference/>

IISTE Knowledge Sharing Partners

EBSCO, Index Copernicus, Ulrich's Periodicals Directory, JournalTOCS, PKP Open Archives Harvester, Bielefeld Academic Search Engine, Elektronische Zeitschriftenbibliothek EZB, Open J-Gate, OCLC WorldCat, Universe Digital Library, NewJour, Google Scholar

