

## The Wound Healing Effects of Aqueous Leave Extracts of *Azadirachta Indica* on Wistar Rats.

\*Osunwoke Emeka A (PhD-Corresponding author)

Department of Human Anatomy, Faculty of Basic Medical Sciences, College of Health Sciences, University of Port Harcourt, PMB 5323 Port Harcourt- Nigeria.

E-mail: [aeosunwoke@yahoo.com](mailto:aeosunwoke@yahoo.com). Tel: +2348055160338.

Olotu Emamoke J (PhD)

Department of Human Anatomy, Faculty of Basic Medical Sciences, College of Health Sciences, University of Port Harcourt, PMB 5323 Port Harcourt- Nigeria.

E-mail: [olotujoy@yahoo.com](mailto:olotujoy@yahoo.com). Tel: +2348037752394.

Allison Theodore A (MBBS)

Department of Human Anatomy, Faculty of Basic Medical Sciences, College of Health Sciences, University of Port Harcourt, PMB 5323 Port Harcourt- Nigeria.

E-mail: [doctheo4real@gmail.com](mailto:doctheo4real@gmail.com). Tel: +2348096027053.

Onyekwere Julius C (B.Sc)

Department of Human Anatomy, Faculty of Basic Medical Sciences, College of Health Sciences, University of Port Harcourt, PMB 5323 Port Harcourt- Nigeria.

E-mail: [Julio2k2001@yahoo.com](mailto:Julio2k2001@yahoo.com). Tel: +2348063576208.

### ABSTRACT

The wound healing effect of the aqueous leave extracts of *Azadirachta indica* (neem tree) was investigated on adult male wistar rats. The aim of this study is to scientifically determine if the aqueous leave extracts of *Azadirachta indica* has wound healing abilities. Twenty male wistar rats (two groups of 10 control and 10 experimental rats) of average weight 150-200g were used for this study. A 2cm by 2cm<sup>2</sup> area of wound was made at the dorsolateral aspect of the rats and an aqueous leave extract of *Azadirachta indica* was applied on the wound of experimental rats while normal saline was used on the control rats. All animals had their wound dressed every three days, wound dimension measured and morphometry assessed. Wound biopsy was collected by random selection in each group on day 9 and on the day of complete reepithelialization. Tissue processing was done using paraffin wax method. Slides were stained with haematoxylin and eosin for histological assessment of fibroblast, neovascularization, granulation and end scar tissue profile. Results showed significant wound contraction at day 6 ( $p < 0.05$ ). The mean percentage wound contraction for experimental rats was  $72.34 \pm 2.49$  while the control group was  $62.39 \pm 7.94$ . Mean percentage wound contraction for experimental group at day 9 was  $92.20 \pm 6.66$  while that of the control group was  $85.19 \pm 7.84$ . The mean of the percentage wound contraction on day 9 was insignificant ( $p > 0.05$ ). The extracts of *Azadirachta indica* significantly increased ( $p < 0.05$ ) the day of complete wound closure in experimental group compared to control group. Aqueous leave extracts of *Azadirachta indica* promotes wound healing activity through increased inflammatory response and neovascularization.

**KEY WORDS:** *Azadirachta indica*, wistar rats, wound healing.

### INTRODUCTION

*Azadirachta indica* (Neem tree) is a native of Asia but has now naturalized in West Africa. The plant is commonly known as Dalbejia or Dogon-yaro in Hausa language, it is widely cultivated throughout Nigeria as an ornamental plant. (Oliver, 1959). The therapeutic efficacies of many indigenous plants (vegetables, fruits and herbs) for various diseases have been described by traditional herbal medicine practitioners (Natarajan, *et al.*, 2003). The presence of various life sustaining constituents in plants has urged scientists to examine these plants with a view to determine potential wound healing properties. Phytochemical investigations of neem have established that all part of the plant contain bitter principles, composed of azadirachtin, azadirone, meliacin, nimbin, nimbidin, nimbinin, tiglic acids and fatty acids.

In 1992, Wolinsky *et al.* reported that Neem stick extract can reduce the ability of some streptococci to colonize tooth surfaces. Also, Talwar *et al.*, (1996) revealed that *Azadirachta indica* (neem) seed and leaf extracts have spermicidal, anti-microbial, anti-fungal and anti-viral properties. Almas, (1999) recommended *azadirachta indica* chewing sticks as oral hygiene tools for health promotion in developing countries. Das *et al.*, (1999) showed that Neem (*Azadirachta indica*) extract is an antibacterial agent against fish pathogenic bacteria. Baswa *et al.*, (2000) revealed that *Azadirachta indica* (Neem) killed more pathogens rapidly at 4 degrees C than 37 degrees C and that this activity was mainly due to the inhibition of cell-membrane synthesis in the bacteria. Subapriya & Nagini (2001) in a review on the medicinal properties of *Azadirachta indica* (neem) leaves reported that Neem leaf and its constituents have been demonstrated to exhibit immuno-modulatory, anti-inflammatory, anti-hyperglycaemic, anti-ulcer, anti-malarial, antifungal, antibacterial, antiviral, anti-oxidant, anti-mutagenic and anti-carcinogenic properties. Vanka *et al.*, (2001) proved the effects of *azadirachta indica* in inhibiting *S. mutans* and reversing incipient carious lesions. Roop *et al.*, (2005) reported that *A. indica* and *M. azedarach* seed extracts reduced follicular development in cyclic female albino rats. Thakurta *et al.*, (2007) reported that *Azadirachta indica* (neem) extract possesses anti-bacterial and anti-secretory activity against *Vibrio cholera*. Hoque *et al.*, (2007) reported that neem extracts possess compounds containing anti-bacterial properties that can be potentially useful to control foodborne pathogens and spoilage organisms. Prashant *et al.*, (2007) revealed that neem extracts inhibit the growth of the following four organisms causing dental caries: *Streptococcus mutans*, *Streptococcus salivarius*, *Streptococcus mitis*, and *Streptococcus sanguis*. Katsayal *et al.*, (2008) demonstrated that methanol extract of *azadirachta indica* leaves causes liver and kidney histopathological damage on wistar rats. Raja *et al.*, (2009) showed that water and acetone extract of *Azadirachta indica* and *Acalypha indica* inhibit the anti-microbial activities of *Staphylococcus aureus* and *Pseudomonas aeruginosa*.

The aim of this study is to investigate the effectiveness of the leaf extract of *Azadirachta indica* as a wound healing agent.

## MATERIALS AND METHODS

A total number of 20 male adult wistar rats with average weight 150-200g were used for this study. The rats were divided into two equal groups referred to as control group A, and experimental groups B each containing ten animals. All animals were selected on the basis of non-presence of any pre-existing skin lesion, kept in the laboratory for two weeks for acclimatization, and fed with standard rat cubes and water ad libitum. The animals were then weighed and anaesthetized using combinations of ketamine and diazepam (0.2ml/kg). Each animal was then shaved on the right dorso-lateral aspect of the thoracic wall and wiped with 70% methylated spirit soaked in gauze. Thereafter, a 2cm x 2cm area of skin was measured and excised, care taken to remove the panniculus carnosus.

The wounds were then dressed with gauze soaked with appropriate agent for each group and then secured with zinc oxide plaster taped circumferentially round the animals. Wound dressing was done every three days till re-epithelization was complete. Measurements were taken before each dressing while the animal was under anaesthesia using a sterile transparency to trace the wound. The outline was then traced on a graph paper in order to determine the percentage wound contraction. On day 9 the wound was macroscopically evaluated to determine if granulation tissue had formed. A random biopsy of the wound was taken from each group on day 9 and another sample for completely healed wound (end scar) for histology.

The data was analyzed statistically using a student's t-test.

## RESULTS

The result of this study is presented in the table below. Table 1 shows the Percentage (%) Wound Contraction Rates, Mean and Standard Deviation of Control and Experimental Groups at Day 6, 9 and end scar. The mean value for control rats was  $62.39 \pm 7.94$  and experimental group was  $72.34 \pm 2.49$ . The difference in mean of the experimental animals is statistically significant when compared to the control group. ( $p < 0.05$ ). At Day 9, the mean value for control rats was  $85.19 \pm 7.84$  and experimental group was  $92.20 \pm 6.66$ . The difference in mean of the experimental animals is statistically insignificant when compared to the control group. ( $p > 0.05$ ). While for the days of complete wound healing (end scar), the mean value for control rats was  $5.8 \pm 0.84$  and experimental group was  $15.0 \pm 0.00$ . The difference in mean of the experimental animals is statistically insignificant when compared to the control group. ( $p > 0.05$ ).

Figure 1 & 3. Figure showing photomicrograph of granulation tissues in both control and experimental rats at day 9. H & E x400. Figure 2 & 4 shows photomicrograph of end scar tissue profile in both control and experimental animals. The sections of skin show an ulcer with mild to moderate fibrosis, marked neutrophilic infiltration with moderate infiltration of macrophages and neovascularization in both the experimental and control groups. The

sections of the end scar show an atrophic epidermis with decreased keratinization, a markedly fibrous dermis and absence of inflammatory cells. The skin appendages (hair follicles and sebaceous glands) are present. There was also hyperkeratosis - increased of the stratum corneum (i.e. increased keratinization) (white arrow), Hypergranulosis –increased quantity of keratohyalin granules in the cells of the stratum granulosum (arrow), and acanthosis - hyperplasia of the epithelium. In the dermis is seen fibrosis (arrow head) numerous hair follicles, and some sebaceous glands. Neutrophils and macrophages are absent. This was observed in experimental and control animals respectively.

## DISCUSSION

This study has showed a significant percentage wound contraction, fibroblast and blood vessels count and the microscopic appearance of granulations and end scar tissues of the wounds dressed with the extracts of *Azadirachta indica*. At the end of the experiment, there were no hypertrophic scars in the wounds generated. There was intense infiltration by neutrophils and macrophages. Hence, promotion of neovascularization is considered as one of the factors which accelerate wound healing by *Azadirachta indica* leave, this is in line with Falanga, (2005) who reported that neovascularization is a crucial step in wound healing process. Szabo *et al.*, (1995) also revealed that angiogenesis in granulation tissues improves circulation to the wound site thus providing oxygen and nutrients essential for the healing process. Habibipour *et al.*, (2003) showed that histological analysis of the treated healed wound group contained a large amount of fibroblast proliferation, collagen synthesis, and neovascularization, which resulted in an increased wound tensile strength and accelerated healing.

Also, wounds treated with the extracts of *azadirachta indica* showed the presence of fibrosis in the dermis and hyperkeratosis (increased thickness of the stratum corneum). This suggests that collagen formation may be necessary for wound healing and thus agrees with the postulations of Trabucchi *et al.*, (1986); Shukla *et al.*, (1999) that all, attributed enhanced wound healing activity to collagen formation and angiogenesis. Cohen and Burns, (2002) reported that collagen played a central role in the healing of wounds.

## CONCLUSION

In conclusion it will be worthwhile to further carry out a concentration based study to evaluate the effects of the extracts of *azadirachta indica*. This research has showed that the aqueous extracts of the leave of *Azadirachta indica* promotes wound healing activity through increased inflammatory response and neovascularization. Further studies with isolated constituents are required to understand the complete mechanism of wound healing activity of *Azadirachta indica*.

## ACKNOWLEDGEMENT

We wish to thank the laboratory technologists and other technical staff who contributed their expertise in the handling of rats to this study.

## REFERENCES

- Almas K. (1999): The antimicrobial effects of extracts of *Azadirachta indica* (Neem) and *Salvadora persica* (Arak) chewing sticks. *Indian J Exp Biol.* 37(11):1097-100.
- Baswa M., Rath C. C., Dash S. K., Mishra R. K. (2000): Antibacterial activity of Karanj (*Pongamia pinnata*) and Neem (*Azadirachta indica*) seed oil: a preliminary report. *J. Ethnopharmacol.* 71(3):377-82.
- Cohen S., Burns R. C. (2002): *Pathways of the Pulp*; 8<sup>th</sup> Edition. St. Louis: Mosby Inc. Pg. 465.
- Das B. K., Mukherjee S. C., Sahu B. B., Murjani G. (1999): Neem (*Azadirachta indica*) extract as an antibacterial agent against fish pathogenic bacteria. *Vet Parasitol.* 30; 83(3-4):177-85.
- Falanga V. (2005); Wound healing and its impairment in the diabetic foot. *Lancet*; 366:1736-1743.
- Habibipour S., Oswald T. M., Zhang F., Joshi P., Zhou X. C., Dorsett-Martin W., Lineaweaver W. C. (2003): Effect of sodium diphenylhydantoin on skin wound healing in rats. *Plast Reconstr. Surg.*, 112: 1620-1627.
- Hoque M.D., Bari M.L., Inatsu Y., Juneja V.K., Kawamoto S. (2007): Antibacterial activity of guava (*Psidium guajava* L.) and Neem (*Azadirachta indica* A. Juss.) extracts against foodborne pathogens and spoilage bacteria. *Indian Journal of Dental Research.* (4): Pg.148-51.

- Martin A. (1996): The use of antioxidants in wound healing. *Dermatol.Surg.*, 22: 156-160.
- Kagbo H. D. & Ejebe D. E. (2010): Phytochemistry And Preliminary Toxicity Studies Of The Methanol Extract Of The Stem Bark Of *Garcinia kola* (Heckel). *The Internet Journal of Toxicology*. (7): 2.
- Katsayal, U. A., Nadabo, Y. A. and Isiorho, V. J. (2008): Effects of Methanol Extract Of *Azadirachta Indica* Leaves On The Histology Of Liver And Kidney Of Wistar Rats; *Nigerian Journal of Pharmaceutical Sciences*; (7):1.
- Natarajan E., Saeb M., Crum C., Woo S. B., McKee P. H., Rheinwald J. G.(2003): Co-expression of p16INK4A and laminin 52 by micro invasive and superficial squamous cell carcinomas in vivo and by migrating wound and senescent keratinocytes in culture. *American Journal of Pathology*.; 163(2): 477-91.
- Prashant G.M., Chandu G.N., Murulikrishna K.S., Shafiulla M.D. (2007): The effect of mango and neem extract on four organisms causing dental caries: *Streptococcus mutans*, *Streptococcus salivarius*, *Streptococcus mitis*, and *Streptococcus sanguis*: an in vitro study. *Journal of Ethnopharmacol* (Vol. 3): Pg. 607-12.
- Raja R.V, Ramanathan T., Savitha T. (2009): Studies on wound healing property of coastal medicinal plants *J Biosci Tech*. (1): 39-44.
- Roop J. K., Dhaliwal P. K., Guraya S.S. (2005): Extracts of *Azadirachta indica* and *Melia azedarach* seeds inhibit folliculogenesis in albino rats. *Curr Med Chem Anticancer Agents*. (2):149-6.
- Shukla A., Rasik A. M., Dhawan B. N. (1999): Asiaticoside-induced elevation of antioxidant levels in healing wounds. *Phytotherapy. Res.*, 13(1): 50-54.
- Subapriya R., Nagini S. (2001): Medicinal properties of neem leaves: a review. *Indian J Dent Res*. 12(3):133-44.
- Szabo S., Kusstatscher S., Sakoulas G., Sandor Z., Vincze A., Jadus M. (1995): Growth factors: New “endogeneous drug” for ulcer healing. *Scandinavian. J. Gastroenterol.*, 210: 15-18.
- Talwar G.P, Raghuvanshi P., Misra R., Mukherjee S., Shah S. (1996): Plant immunomodulators for termination of unwanted pregnancy and for contraception and reproductive health. *J Dent Res*. 75(2):816-22.
- Thakurta P., Bhowmik P., Mukherjee S., Hajra T. K., Patra A., Bag P. K. (2007): Antibacterial, antisecretory and antihemorrhagic activity of *Azadirachta indica* used to treat cholera and diarrhea in India. *J.Ethnopharmacol*. 111(3):607-12.
- Trabucchi E., Preis-Baruffaldi F., Baratti C., Montorsi W. (1986): Topical treatment of experimental skin lesions in rats: macroscopic, microscopic and scanning electron-microscopic evaluation of the healing process. *Int. J. Tissue. React.*, 8: 533-544.
- Vanka A, Tandon S, Rao SR, Udupa N, Ramkumar P. (2001): The effect of indigenous Neem *Azadirachta indica* [correction of (*Adirachta indica*)] mouth wash on *Streptococcus mutans* and lactobacilli growth. *Microbios.*; 105(412):183-9.
- Wolinsky L.E., Mania S., Nachnani S., Ling S. (1992): The inhibiting effect of aqueous *Azadirachta indica* (Neem) extract upon bacterial properties influencing in vitro plaque formation. *J. Nat Prod*. 55(3):303-10.

**Table 1: Showing the Percentage (%) Wound Contraction Rates, Mean and Standard Deviation of Control and Experimental Groups at Day 6.**

	% Wound Contraction for Control Group	% Wound Contraction for Experimental Group
<b>Day 6</b>		
<b>Mean±SD</b>	62.39±7.94	72.34±2.49
$t = 3.78, p = 2.10 (p < 0.05).$		
<b>Day 9</b>		
<b>Mean±SD</b>	85.19± 7.84	92.20± 6.66
$t = 0.66, p = 2.10 (p > 0.05)$		
<b>End Scar</b>		
<b>Mean ± SD</b>	15.8±0.84	15.0±0.00
$t = 2.10, p = 2.31 (p > 0.05)$		

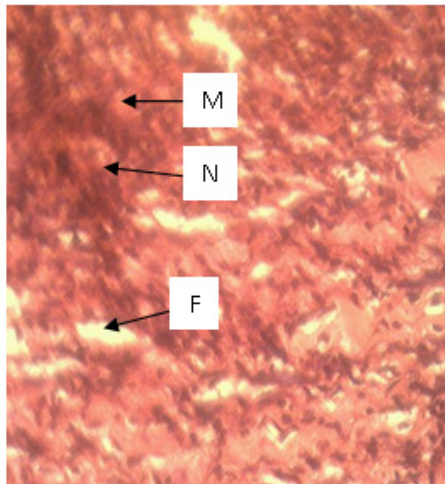


Fig 1. Photomicrograph showing granulation tissue Of Control rats at Day 9. H & E X400.

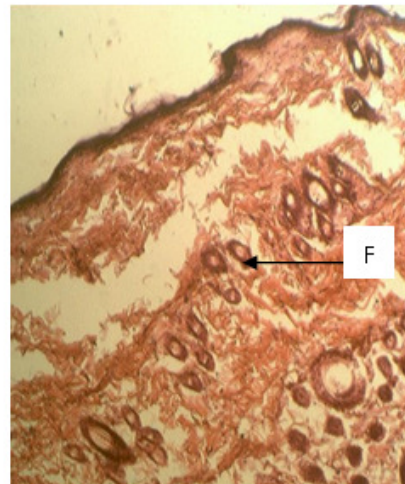


Fig2. Photomicrograph Showing wound Healing Activity on end scar tissue of control rats. H & E X400.

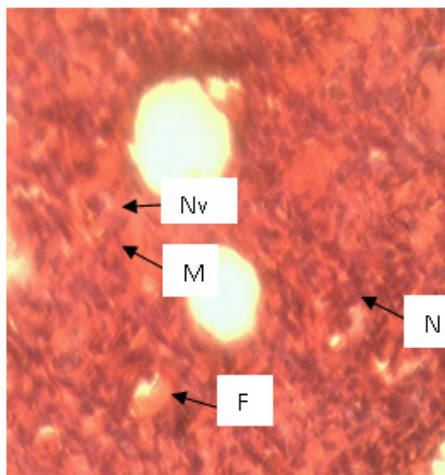


Fig 3. Photomicrograph Showing granulation tissue of Experimental rats at Day 9 H & E X400.

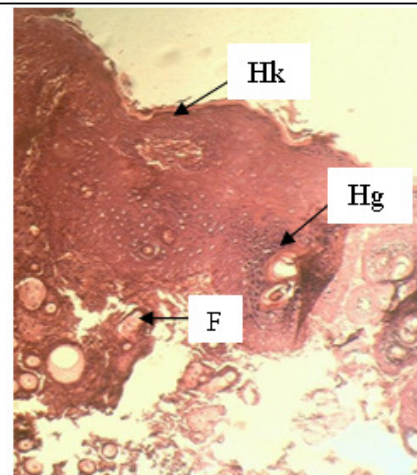


Fig 4. Photomicrograph showing wound healing activity on end scar tissue of experimental rats H&E X400

**Key.** F – Fibrosis, Hk – Hyperkeratosis, Hg – Hypergranulosis, N – Neutrophils, M – Macrophages, Nv – Neovascularisation.