

The Effect of Aqueous Leave Extract of *Nicotiana Tabacum* (Tobacco) On Some Reproductive Parameters and Micro-Anatomical Architecture Of The Testis In Male Albino Wistar Rats

Ibraheem M. Gambo^{1*}, Nanyak Z. Galam¹, Glory Adamu¹, Ayaka louis O¹, Ali A. Habeeb², Mohammed M. Bello³, Najimuddeen Bello⁴, Ahmed M. Rabi¹, Samuel O. Odeh¹

¹Department of human physiology, university of Jos

²Department of human physiology, university of Maiduguri

³Department of anatomy, university of Jos

⁴Department of science laboratory technology, university of Jos.

*Corresponding author: ibroabs@yahoo.com

ABSTRACT

The tobacco plant (*Nicotiana tabacum*) has been in used for several years irrespective of the location of human races. Tobacco is used in different ways but cigarettes constitute the largest share of manufactured tobacco products in the world, accounting for 96% of total sales. The present study was undertaken to investigate the effect of aqueous extract of *Nicotiana tabacum* leaves on some reproductive parameters. 20 male young wistar rats weighing between 160 to 190g were used for the study. The extract was administered orogastrically in doses of 30, 20 and 10mg/kg body weight per day in 0.5ml of distilled water for 21 days and the control group was given equal volume of distilled water as well. The results showed that at the dose of 20 and 30mg/kg the extract decreased significantly the percentage motility ($P<0.01$) and ($P<0.001$) to 21.8 ± 1.0 and 15.6 ± 0.8 respectively, while the sperm concentration was significantly decreased ($P<0.01$) to $55.7 \times 10^6 \pm 2038480$ at the dose of 30mg/kg. The testicular histology showed decrease spermatogenic cells at doses of 20mg/kg and 30mg/kg respectively. It is concluded that nicotine could adversely affect fertility by sperm count, motility and testicular spermatogenesis in a dose- and time-dependent manner.

Keywords *Nicotiana tabacum*, reproductive parameters, testicular histology

Background

Cigarette smoking is a widely recognized health hazard, yet despite worldwide antismoking campaigns, some people continue to consume cigarettes on a regular basis, and the highest prevalence of smoking is observed in young adult males during their reproductive period (Langgassner, 1999). A consistent number of studies have claimed that cigarette smoking is correlated with alterations in sperm quality such as semen volume, sperm concentration, motility, and morphology (Vine et al, 1994; Zavos et al, 1998a,b; Ozgur et al, 2005; Guo et al, 2006; Pasqualotto et al, 2006, 2008; Ramlau-Hansen, 2007a), concomitant with a reduced concentration mainly of citrate and also of fructose (Kunzle et al, 2003). The effects of any drug (including tobacco) vary from person to person. How tobacco affects a person depends on many things including their size, weight and health, also whether the person is used to taking it. The effects of tobacco, as with any drug, also depend on the amount taken (Collins & Lapsley, 2008). Male reproductive toxicity includes altered sperm parameters, such as lower density, decreased motility or abnormal morphology, and effects on fertility. Infertility is common among couples of child bearing age. Approximately half of known causes of primary infertility are attributable to male factor (Yales et al, 1989 and Yeşilli et al, 2005). However the etiology of male factors infertility is poorly understood. While some individuals may be genetically predisposed to be sub-fertile (Reijo et al, 1996), there are major epigenetic factors which are implicated as potential causes of male infertility. The male reproductive system is known to be highly sensitive to many chemicals and drugs which have been found to pose adverse effects on male reproductive capacity under certain conditions (Bonde et al, 1996).

The health consequences of cigarette smoking and the use of tobacco products are well known. These are an important cause of increased mortality and morbidity in the developed countries and the prevalence is increasing in the developing world as well (Kapoor et al, 2005). There are more than 4000 chemicals in tobacco smoke. Many of these chemicals are poisonous and at least 43 of them are carcinogenic (cause cancer).

The three major chemicals in tobacco smoke are:

- Nicotine—the chemical on which smokers become dependent.
- Tar—which is released when a cigarette burns.
- Carbon monoxide (CO)—a colourless, odourless and very toxic gas. Smokers typically have high levels of CO in the blood.

Many plants contain nicotine, a powerful neurotoxin to insects. However, tobaccos contain a higher concentration of nicotine than most other plants. Smoking tobacco in cigars and pipes is less popular. When

tobacco is smoked, nicotine is absorbed through the membranes of the mouth and upper respiratory tract. When tobacco is chewed (as chewing tobacco or wet snuff), the nicotine is absorbed through the membranes in the mouth. It can also be sniffed (dry snuff) and the nicotine is then absorbed through the lining of the nose. Cigarette smoking is not only a potent cause of lung cancer but also has been associated with low birth weight, preterm delivery and abortion in women who are addicted to it. It also causes menstrual irregularities, pregnancy complications, and decreased fertility in women (Weisberg *et al*, 1985) Moreover, cigarette smoking inhibits spermatogenesis and causes decreased steroidogenesis in men (Aydos *et al*, 2001, Mlynarcikova *et al*, 2005). Cigarette smoking has also been shown to have anti-estrogenic effects in women (Tankó *et al*, 2004). In males, the effects of smoking on androgen is important, given the recent interest in the association between low androgen levels, the metabolic syndrome and coronary heart disease (Jones *et al*, 2003). Other adverse effects of smoking include premature ejaculation and reduced penile erection; however, these depend on individual sensitivity or susceptibility (Jones *et al*, 2003). It has been previously demonstrated that exposure to reference cigarette smoke resulted in reduced birth weight in rats under experimental condition (Carmines *et al*, 2003, Gaworski *et al*, 2004) while oral administration of nicotine have been associated with testicular degeneration, disorganization of the cytoarchitecture and decreased serum testosterone levels (Oyeyipo *et al*, 2010). In addition, nicotine has been shown to have adverse effects on fertility potentials of female albino rats by reducing the weight and disorganizing the histology of some vital visceral and reproductive organs (Iranloye *et al*, 2009). In spite of the growing knowledge on the adverse reproductive effects of smoking, it is relatively unclear whether or not, nicotine has the same effects on male reproductive activities as it relates to its effects on sperm cells and male fertility indices. It has been suggested that cigarette smoking increases the percentage of morphologically altered spermatozoa (Evans *et al*, 1981; Elshal *et al*, 2008), especially in men who are heavy smokers or who have smoked for many years (Gaur *et al*, 2007); however, the extent and the localization of the morphological damage is still being debated (Mak *et al*, 2000; Guo *et al*, 2006). The present study was, therefore, designed to investigate or evaluate the aqueous extract of leave of *Nicotiana tabacum* (TOBACCO) for possible toxicological effect on some reproductive parameters in male albino wistar rats. And to determine if it has any effect on the micro-anatomical architecture of the testis

Methods

100grams of the plant material was extract by maceration in 1000ml of distilled water with intermittent agitation (8hrs day) for 3days using mechanical shake. Afterwards the mixture was filtered using filter paper (whatman) and the filtrate concentrate by rotary evaporation to dryness and yield 23.5g (23.5) of solid residue was obtained. The residue in form of pest dark brown product was transferred to an airtight bottle and stored in the refrigerator at -4°C until use. The concentration of the extract was determined using this formula

$$\text{Concentration} = \frac{\text{Weight of leaves(g)}}{\text{Quantity of water (ml)}}$$

Concentration = Quantity of water (ml)

And the actual dose to be administered was obtained using this formula:

$$\text{Dose (ml)} = \frac{\text{Dosage (mg)/ Body weight (kg)}}{\text{Concentration (mg/ml)}}$$

Dose (ml) = Concentration (mg/ml)

CHEMICALS AND REAGENT

- Stock solution of crude extract
- Formalin (BDH chemical, England)
- Distilled water
- Xylene
- Normal saline (0.9g of sodium chloride to 100ml of D.1 HO)

Twenty sexually active male albino rats (Wister strains) weighing between 110g-160g obtained from animal house, university of jos, Nigeria were used for this study. The rats were kept in the animal house for the period of study. The rats were fed *ad libitum* with commercially prepared rat feeds made up of 21% protein, 3.5% fat, 6% fiber, 0.8% phosphorus (Top Feeds Limited, Jos, Nigeria) and given fresh water. They were kept in cages which have wood shaven as bedding and cleaned twice a week. The feeds and water was provided *ad libitum* in earthen troughs. Their cages were used and each measured about 19 by 12 inches. To be able to monitor, observe and record their individual weight daily. The rats were in groups of five (N= 5) in each cage marked A, B, C and

D respectively under the same environmental and management conditions. The experiment was conducted in accordance with the Guidelines of the U.S. National Institute of Health (NIH) on the care and use of laboratory animals.

After 3 weeks of stabilization the rats in groups B, C and D were given aqueous extract of *Nicotiana tabacum* leaf at 10 mg/kg, 20mg/kg body weight and 30mg/kg" body weight respectively for a period of 21 days using needle and canular to introduce the extract directly into the stomach through the oesophagus (orogastrically) per day, the dose are in 0.5ml of distilled water. Group A rats were the control with no administration of *Nicotiana tabacum* extract but given equal volume of distilled water as well (0.5ml).

SEMEN COLLECTION: The rats were then anaesthetized by placing them into a glass chamber(dessicator) containing cotton wool soaked in chloroform till they lost consciousness. The testicles were then removed through a lower abdominal incision. The testes were then separated from the epididymis with the scalped blade. Sperm cells were sucked into a pre-warmed (37°C) Pasteur pipette from the caudal epididymis. It was flushed with 2-3 drops of 2.9% sodium citrate solf kept at 37°C. Half of the spermatozoal samples collected were mixed with 0.5 ml of 2.9% sodium citrate solution (7.C) for head forward unidirectional progressive motility. These were studied at x40 magnifications of the microscope .The mean percentages and standard error of mean were calculated for motility, live/dead ratio and Sperm concentration. ANOVA (Analysis of variance) was used to establish any significant difference in all these parameters using the Graphpad instat statistical tool (July 2009). Results are presented as mean \pm standard error of mean.

Semen analysis; The semen samples were analysed by method described by Zemjanis (1977).

STATISTICAL ANALYSIS : Kruskal-Wallis Test (Nonparametric ANOVA) was used to analyze the sperm motility .The P value is 0.0005, considered extremely significant.

Variation among column medians is significantly greater than expected by chance. The P value is approximate (from chi-square distribution) because at least one column has two or more identical values. While one way ANOVA was used to analyze the sperm count.

RESULTS

Table 1: Group A(control)

S/NO	% motility	Concentration $\times 10^6$ /ml
1	67	69.4
2	77	70.5
3	66	62.4
4	78	65.0
5	60	65.0

Table 2: Group B (10mg/kg)

S/NO	% motility	Concentration $\times 10^6$ /ml
1	31	51.1
2	38	60.5
3	42	62.0
4	32	60.0
5	31	71.3

Table 3: Group C (20mg/kg)

S/NO	% motility	Concentration $\times 10^6/ml$
1	21	62.9
2	20	61.7
3	25	60.0
4	20	62.3
5	23	57.2

Table 4: Group D

S/NO	% motility	Concentration $\times 10^6/ml$
1	14	53.8
2	18	53.3
3	15	58.6
4	14	52.0
5	17	45.9

Table 5

The average percentage motility and sperm concentration

It was observed that the groups of rats that had the higher doses of the aqueous extract (30mg/kg and 20mg/kg body weight had their percentage motility 15.6 \pm 0.8, and 21.8 \pm 1.0 respectively) significantly lower ($P < 0.01$ and

S/NO	% Motility	Sperm Concentration $\times 10^6/ml$
Control(A)	69.6 \pm 3.4	66.5 \pm 1511820
Group1(B)	34.8 \pm 2.2	61.0 \pm 3212071
Group2(C)	21.8 \pm 1.0**	60.8 \pm 1026353
Group3(D)	15.6 \pm 0.8***	55.7 \pm 2038480**
*P<0.05 significant	**P<0.01 highly significant	***P<0.001 extremely significant

$P < 0.001$) when compared to the control group (69.6 \pm 3.4%). This shows that there was a dose dependent decrease in motility. There was also a highly significant decrease in sperm count at the dose of 30mg/kg.

HISTOLOGY

The histological plates shows the transverse section of testicular histology of the rats, fig I being the control (group A) and fig II,III and IV represents group B,C, and D given 10mg, 20, and 30mg/kg respectively. In fig.I, the seminiferous tubules, which are the sites of sperm production, have no abnormalities. It also showed germ cells at different levels of development. Fig III and IV shows the transverse section of testicular histology of the rats as Fig I and II respectively. In Fig. III and IV the seminiferous tubules, which are sites of sperm production have no abnormalities. But the spermatozoans in fig.III and IV shows much scanty developing cells in their various stages as evidenced by the decreased thickness of spermatogenic cells when compared to the control.

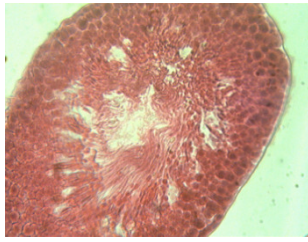


Fig I(control)

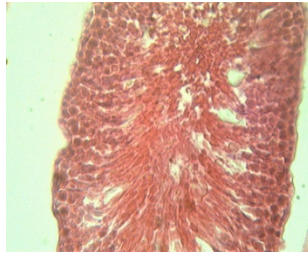


fig II(10mg/kg)

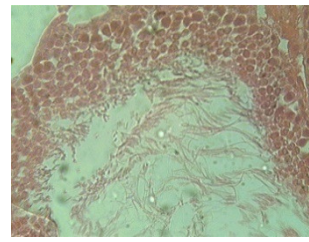


fig III(20mg/kg)

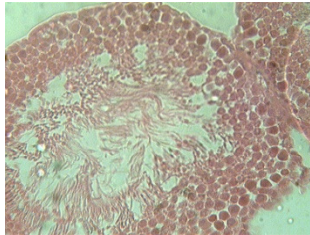


Fig IV(30mg/kg)

Discussion

Sperm motility, sperm concentration and morphology are important sperm parameter in determine male fertility. Also the testicular histology too is used to shed more light on the indices in male fertility. This study shows a dose dependent decrease in sperm count and motility as well as a decrease in the spermatogenic cell layers on histology of the testis, this is in agreement with other studies that have examined the effects of cigarette smoking on male fertility, and the results have suggested a substantial negative effect on sperm production, motility, and morphology (Weber et al, 2002; Kunzle et al, 2003; Ramlau-Hansen, 2007a). Sperm concentration less than 10×10^6 /ml show a significant reduction in fertilization (De-Geyter el al 1992). The attainment of significant oligospermia cause failure of conception. Sperm motility also affects fertilization (Aitken *et al* 1989), Sperm motility of 50% and above consisting of rapid forward progression movement is essential for conception in human (WHO, 1987). Sperm motility less than 50% is known to result in failure of conception. The slight decrease in motility of sperm in this study is in agreement with the work carried out by Horimoto *et al.*, 2000 on spermatozoan abnormalities and male infertility in the rats following sulfasalazine treatment, the work revealed that on administering the drug orally reduces motility of sperm and fertility of animals. It is also in agreement with the work carried out by Raji *et al* 2006 on the effect of methanol extract of *Ricinus Communis* seeds on sperm parameters. The study also revealed that there was decreases in motility are the cause of conception motility of sperm. The slight low concentration and motility are the cause of conception which result in the epididymis sperm cell that is cause by the effect of the extract on the testis are specifically of the spermatogenic process can be seen by the production of sperm cells. The testis is the male reproduction organ and consists of seminiferous tubules, which are the sites of sperm production. A cross section of the testis shows spermatogenic cells at various stages of development as well as other Histological component of the testis. In the growing rats treated rats have scanty developing cells in the seminiferous tubules but not in control. Also in the histological structure of adult testis both the seminiferous tubules and the spermatozoans are scanty, but normal in the control. Also the immature spermatogenic cells are arranged in the lumen of the seminiferous tubules. Though there was a relatively lower decrease in sperm count when compared with other studies it was significant when compared with control. This may suggest that higher doses of the tobacco extract be used in future studies and perhaps for a longer period of time.

Conclusion

In conclusion the aqueous extract of *nicotiana tabacum* at doses of 20mg/kg and 30mg/kg when administered for a period of 21 days showed a significant decrease in sperm motility and concentration as well as decreased spermatogenic cells in the histology of the testis.

References

- Langgassner J. Rauchgewohnheiten der osterreichischen Bevolkerung. *Satistische Nachr.* 1999;5:319–326.
- Vine MF, Margolin BH, Morrison HI, Hulka BS. Cigarette smoking and sperm density: a meta-analysis. *Fertil Steril.* 1994;61:35–43.
- Zavos P, Correa J, Antypas S, Zarmakoupis-Zavos P, Costantinos N. Effects of seminal plasma from cigarette smokers on sperm viability and longevity. *Fertil Steril.* 1998a;69:425–429.
- Ozgun K, Isikoglu M, Seleker M, Donmez L. Semen quality of smoking and non-smoking men in infertile couples in a Turkish population. *Arch Gynecol Obstet.* 2005;271:109–112.
- Guo H, Zhang HG, Xue BG, Sha YW, Liu Y, Liu RZ. Effects of cigarette, alcohol consumption and sauna on sperm morphology. *Zhonghua Nan Ke Xue.* 2006;12:215–217, 221
- Pasqualotto F, Sobreiro B, Hallak J, Pasqualotto E, Lucon A. Cigarette smoking is related to a decrease in semen volume in a population of fertile men. *BJU Int.* 2006;97:324–326.
- Ramlau-Hansen CH, Thulstrup AM, Aggerholm AS, Jensen MS, Toft G, Bonde JP. Is smoking a risk factor for decreased semen quality? A cross-sectional analysis. *Hum Reprod.* 2007a;22:188–196.
- Kunzle R, Mueller M, Ha¨nggi W, Birkha¨user M, Drescher H, Bersinger N. Semen quality of male smokers and nonsmokers in infertile couples. *Fertil Steril.* 2003;79:287–291.
- Collins & Lapsley, 2008 Effect of tobacco
- Yales CA, Thomas C, Kovacs GT, De Krestler DM. Androgen, male factor, infertility and IVF. In: Wood C, Trouson A, editors. *Clinical in vitro fertilization.* USA: Springer-Verlag; 1989. pp. 95-111.
- Yeilli C, Mungan G, Sekiner I, Akduman B, Aikgz S, Altan K, et al. Effect of varicocele on sperm creatine kinase, HspA2 chaperone protein (creatine kinase-M type), LDH, LDH-X, and lipid peroxidation product levels in infertile men with varicocele. *Urology.*
- Zemjanis R (1977). Collection and evaluation of semen. In: *Diagnostic and Therapeutic Techniques in Animal Reproduction.* William and Wilkins Company, Baltimore, USA. p. 242.
- Reijo R, Alagappan RK, Patrizio P, Page DC. Severe oligozoospermia resulting from deletions of azoospermia factor gene on Y chromosome. *Lancet.* 1996;347(9011):1290-3.
- Bonde JP. Male fertility. In: Comhaire FM, editor. *Chapman and Hall Medicals.* New York: Chapman and Hall; 1996. p. 266-84.
- Kapoor D, Jones TH. Smoking and hormones in health and endocrine disorders. *Eur J Endocrinol.* 2005;152(4):491-9.
- Weisberg E. Smoking and reproductive health. *Clin Reprod Fertil.* (1985) 3(3):175-86
- Aydos K, Gven MC, Can B, Ergn A. Nicotine toxicity to the ultrastructure of the testis in rats. *BJU Int.* 2001;88(6):622-6.
- Mlynarcikova A, Fickova M, Scsukova S. Ovarian intrafollicular processes as a target for cigarette smoke components and selected environmental reproductive disruptors. *Endocr Regul.* 2005;39(1): 21-32.
- Tank LB, Christiansen C. An update on the antiestrogenic effect of smoking: a literature review with implications for researchers and practitioners. *Menopause.* 2004;11(1):104-9.
- Jones TH, Jones RD, Channer KS. Testosterone and its beneficial actions on cardiovascular disorders. In: Plotsky PM, Hunzicker-Dunne M, Rose JC, Brenner RM, editors. *Recent research developments in endocrinology & metabolism, Volume 1.* USA: Transworld research network; 2003. p. 143-68.
- Carmines EL, Gaworski CL, Faqi AS, Rajendran N. In utero exposure to 1R4F reference cigarette smoke: evaluation of developmental toxicity. *Toxicol Sci.* 2003;75(1):134-47.
- Gaworski CL, Carmines EL, Faqi AS, Rajendran N. In utero and lactation exposure of rats to 1R4F reference cigarette mainstream smoke: effect on prenatal and postnatal development. *Toxicol Sci.* 2004;79(1):157-69.
- Oyeyipo IP, Raji Y, Emikpe BO, Bolarinwa AF. Effects of oral administration of nicotine on organ weight, serum testosterone level and testicular pathology in adult male rats. *Niger J Psychol Sci.* 2010;25(1):81-86.
- Iranloye BO, Bolarinwa AF. Effect of nicotine administration on weight and histology of some vital visceral organs in female albino rats. *Niger J Physiol Sci.* 2009;24(1):7-12.
- Evans HJ, Fletcher J, Torrance M, Hargreave TB. Sperm abnormalities and cigarette smoking. *Lancet.* 1981;21:627–629.
- Elshal MF, El-Sayed IH, Elsaied MA, El-Masry SA, Kumosani TA. Sperm head defects and disturbances in spermatozoal chromatin and DNA integrities in idiopathic infertile subjects: association with cigarette smoking. *Clin Biochem.* 2008;Dec 6. [Epub ahead of print]
- Gaur DS, Talekar M, Pathak VP. Effect of cigarette smoking on semen quality of infertile men. *Singap Med J.* 2007;48:119–123.
- Mak V, Jarvi K, Buckspan M, Freeman M, Hechter S, Zini A. Smoking is associated with the retention of cytoplasm by human spermatozoa. *Urology.* 2000;56:463–466.

De Geyter , 1992 evaluation of sperm motility

Aitken RJ, Clarkson JS and Fishel S (1989) Generation of reactive oxygen species, lipid peroxidation and human sperm function *Biology of reproduction* **40** 183-197.

World Health Organization (1987)WHO Laboratory Manual for the Examination of Human Semen and Semen-Cervical Mucus Interaction.2nd edn. Cambridge University Press,Cambridge

Raji Y, Oloyo AK, Morakinyo AO(2006) effect of methanol extract of Ricinus communis seed on reproduction of male rats. *Asian J Androl.*;8(1):115-21

Horimoto et al(2000) Rat epididymal sperm motion changes induced by ethylene glycol monoethyl ether, sulfasalazine, and 2,5-hexandione *Reprod Toxicol*;14(1):55-63.

This academic article was published by The International Institute for Science, Technology and Education (IISTE). The IISTE is a pioneer in the Open Access Publishing service based in the U.S. and Europe. The aim of the institute is Accelerating Global Knowledge Sharing.

More information about the publisher can be found in the IISTE's homepage:

<http://www.iiste.org>

CALL FOR PAPERS

The IISTE is currently hosting more than 30 peer-reviewed academic journals and collaborating with academic institutions around the world. There's no deadline for submission. **Prospective authors of IISTE journals can find the submission instruction on the following page:** <http://www.iiste.org/Journals/>

The IISTE editorial team promises to review and publish all the qualified submissions in a **fast** manner. All the journals articles are available online to the readers all over the world without financial, legal, or technical barriers other than those inseparable from gaining access to the internet itself. Printed version of the journals is also available upon request of readers and authors.

IISTE Knowledge Sharing Partners

EBSCO, Index Copernicus, Ulrich's Periodicals Directory, JournalTOCS, PKP Open Archives Harvester, Bielefeld Academic Search Engine, Elektronische Zeitschriftenbibliothek EZB, Open J-Gate, OCLC WorldCat, Universe Digital Library, NewJour, Google Scholar

