

Influence of Aqueous Extract of Red Chillis Pepper as Curative for Gastric Ulcer in Albino Rats

AbdulJawad, Soha H¹ Hasanein, Manal A^{1*} Header Eslam A²

1. Department of Human Nutrition, Faculty of Family Science, Taibah University, PO. Box 344, Madinah Munawarah ,KSA.
2. Department of Clinical Nutrition, Faculty of Applied Medical Sciences, Umm al Qura University, Makkah, KSA.

* Corresponding Author: Tel: 00966-507633084 E-mail: drmanal.hasanin@yahoo.com

Abstract

The present study was carried out elucidate the effect of aqueous extracts of red chillis pepper (*Capsicum frutescence*) at three doses on the length of gastric ulcer induced by aspirin in rats. Thirty adult male albino rats (Sprague Dawley Strain) weight $175\pm 5g$ were used and divided into 5 groups, each of 6 rats. The first group was used as a control negative (-ve) and fed on the basal ration only, other groups had given aspirin orally (200 mg/kg B.Wt.), one of these groups left as control +ve (ulcerated rats) and other groups administrated with aqueous extract of red chillis pepper (RCP) at doses of 250, 500 and 750 mg/kg B.Wt. for seven days. The length of gastric ulcer, volume of gastric juice, pH value and histopathological changes of gastric were examined. The results revealed that oral administration of RCP extract at 250, 500 and 750mg/kg B.Wt. reduced the length of gastric ulcer. On the other hand, all extracts increased pH value of gastric juice compared to control (-ve) group, meanwhile the volume of gastric juice decreased by plant extracts specially for rats feed on RCP at dose 750 mg/Kg B.Wt. Oral administration of water plant extracts decreased histopathological changes in the stomach layers and mucosa. The present study suggests that, *Capsicum frutescence* could be used for healing acute gastric ulcer disease and implemented for gastric ulcer patients.

Key words: aqueous extracts, *Capsicum frutezens*, aspirin ulcer, stomach, histopathological changes, pH value and gastric juice.

1. Introduction

Chillis pepper is perhaps the world's most widely consumed spice (Rozin et al., 1980) and spicy/hot is reported to be among the most appealing flavors in the United States (Sloan, 2010). Peptic ulcer disease (PUD), encompassing gastric and duodenal ulcers is the most prevalent gastrointestinal disorder. The pathophysiology of PUD involves an imbalance between offensive factors like acid, pepsin and defensive factors like nitric oxide and growth factors. The clinical evaluation of antiulcer drugs showed tolerance, incidence of relapses and side-effects that make their efficacy arguable. An indigenous drug like *Musa sapientum* possessing fewer side-effects is the major thrust area of present day research, aiming at a better and safer approach for the management of PUD (Prabha et al., 2011).

Capsicum contains approximately 1.5% of the irritant oleoresin. Indirect evidence suggests that hot spices may interact with epithelial cells of the gastrointestinal tract to modulate their transport properties (Erika et al., 1998). The major component of the oil is capsaicin (0.02%), a very pungent phenolic chemical. Along with several closely related compounds, it is responsible for the pungency of the fruit. The structure of capsaicin (8-methyl-N-vanillyl-6-nonenamide) is similar to that of eugenol, the active principle in oil of cloves, which can also induce long-lasting local analgesia (Gonzalez, 1998). Hot spices are used widely due to their taste and digestive properties associated with their pungent principles. These are predominantly piperine (6%) in black pepper (*Piper nigrum*) and capsaicinoidic compounds in paprika (*Capsicum anuum*: 0.01–0.22%), chillis or cayenne pepper (*C. frutescence*: 0.3– 1%). (Ganesh Bhat & Chandrasekhara, 1987). The pungency appears to be related to the presence of a 4-hydroxy-3-methoxyphenyl substituent (Alevizos et al., 2007). It has been noted that the more tropical the climate in which the plant originates, the more pungent the fruit; however, extremely pungent peppers can be grown in any climate (Tyler et al., 1981).

Red pepper is a more variable component of diets in the United States (e.g., daily consumption of peppers of any kind = 10.5% (Smiciklas-Wright, et al., 2002) and mean preference in our study population = ~ 1 g/meal). It is well established that there are individual differences in the sensitivity to the burn of spicy foods and to the affective interpretation of that sensation (e.g., regular spicy food users rate capsaicin's burn

as less intense and more pleasant than non-users) (Lawless et al., 1985 and Yoshioka et al., 2001). Pepper, *Capsicum* spp., is a worldwide crop valued for heat, nutrition, and rich pigment content. Carotenoids, the largest group of plant pigments, function as antioxidants and as vitamin A precursors. The most abundant carotenoids in ripe pepper fruits are β -carotene, capsanthin, and capsorubin (Ivette et al., 2010). *Capsicum* species uniquely have capsanthin-capsorubin synthase (CCS) that synthesizes two red pigments, capsanthin and capsorubin (Davies et al., 1970 and Thorup et al., 2000).

Previous studies suggest consumption of red pepper (RP) promotes negative energy balance (Mary-Jon and Richard, 2011). Animal studies suggest capsaicin exerts varying effects on gastric motility and is protectant against mucosal lesions induced by aspirin, ethanol, or hydrochloric acid (Ericson et al., 2009 and Rodriguez-Stanley et al., 2000). Clinical trials have had varying results, possibly because of the design of the studies. One study found no difference in the healing rate of duodenal ulcers among patients who ingested 3 g of *Capsicum* daily compared with untreated controls (Kumar et al., 1984). Red chillis ingested daily over 3 weeks resulted in an increased secretion of gastric, while a chillis -rich diet lowered gastric secretion.

On the other hand, other scientists found that some spices especially red chillis pepper and black pepper have a good medicinal effect on healing ulcers. They found that red chillis pepper involves functional substances called capsaicin which has a gastro-protective effect against experimental gastric mucosal injury in animals (Yeoh et al., 1995 and Cruz et al., 1999). Also, they found that black pepper contains functional substance called piperine which has anti-inflammatory activity against ulcers (Mujumdar et al., 1990; Ononiwu et al., 2002 and Reddy et al., 2004). On the contrary, Alasdair et al., (1981) remarked that hot and spicy food as long use of aspirin is the main cause of chronic gastritis leading to ulcer disease. In this respect, red and black pepper incriminated in the increase of acid secretion (Vasudevan et al., 2000 and Ononiwu et al., 2002).

For as much as this clash, this study carried out to elucidate the anti-ulcerogenic activity using aqueous extracts of red chillis pepper, as investigated on rats.

2. Materials and Methods

2.1-Materials and rats

- a- Aspirin: Aspegic (Mmiriya Pharmaceutical Industries, Cairo) injection was prepared by dissolving one vial in 25ml distilled water to obtain solution. A volume of 1ml of this solution was orally given (at the level 200mg/kg body weight) for one day to induce acute gastric ulcer in male albino rats.
- b- Plants: Red chillis pepper (*Capsicum frutescence*), family solanaceae, this plant was purchased from local market of KSA.
- c- Diet: The rats were fed on ration (a basal diet devoid from starch) composed of wheat bran, soya bean powder 44%, fish meal, molasses, fibers 3.3%, sodium chloride, calcium carbonate, calcium phosphate, methionine and ash (net protein 22% and fats 4.7%). The diet was fed and water was provided ad libitum for the experimental period.
- d- Rats: thirty adult male albino rats (175 ± 5 g B.Wt., each) of Sprague Dawley Strain were obtained from animal house of the faculty of medicine, Um Al Qura University.

2.2-Methods

- a- Preparation of aqueous extracts: The clean RCP (*Capsicum frutescence*), was ground using porcelain grinder to pass through sieve-mesh pores of 1mm diameter. The extract of red chillis was prepared by mixing 1gm powdered leaves with 100 ml distilled water. The mixture was boiled for 10 minutes and left to cool for 15 minutes. The aqueous extract was filtered using filter paper to remove the particulate matter (0.2mm) then the filtrate was freely dried (Lyophilized) and reconstituted in 1.5 ml of distilled water (100 mg/kg body weight).
- b- Grouping design and feeding of rats: The experiment was performed in animal house of the faculty of medicine, Um Al Qura University. Rats were housed in wire cages in a room maintained at 25 ± 2 °C and kept under normal healthy conditions for two weeks. All rats were fed for one week on basal diet before starting the experiment for acclimatization. After one week period, rats were divided into two main groups. The first group (n= 6rats) was fed on the basal diet only as a control negative (healthy rats). Group 1: Control negative -ve group was fed on ration (non treated rats).

All rats in the second main group (n= 24 rats) were given orally aspirin at a dose of 200mg/kg B.Wt., for induction of acute gastric ulcer according to Agrawal et al., (2000). Rats with (aspirin-induced gastric ulcer) were disparted into four groups (n= 6rats for each group) as the following:

Group 2: Control positive +ve group fed on basal ration +Aspirin (Asp) 200mg/kg B.Wt.

Group 3: positive rats fed on basal ration + oral RCP extract at doses of 250 mg/kg B.Wt.

Group 4: positive rats fed on basal ration + oral RCP extract at doses of 500 mg/kg B.Wt.

Group 5: positive rats fed on basal ration + oral RCP extract at doses of 750 mg/kg B.Wt.

The rats remained without food for one day prior to ether anesthesia (except for water) to avoid mixing of food with gastric secretions

c- Measurement the length of gastric ulcer: At the last day of experimental period, all rats were fasted for 12-14hrs and only allowed for drinking water. In the morning of the next day, all rats were sacrificed, and their stomachs were tied around both openings (cardiac & pyloric sphincters) and injected by distilled water (3ml). The gastric juice was then collected in sterilized tube. The stomachs were opened longitudinally, washed with saline and examined under dissecting microscope for ulcer. The length of gastric ulcer was measured and expressed as mean±SE for each group. The curative ratio was then calculated for each treated group according to the method described by Akhtar and Ahmad (1995) using the following equation: Curative ratio (CR) = $(LC - LT / LC) \times 100$.

LC = length of ulcer in control positive group.

LT = length of ulcer in treated group

d- Measurement the volume of gastric juice: Gastric juice was collected according to the methods of Niida et al., 1991 (abdomen was incised and both the stomach and duodenum was exposed and a fistula made by a poly ethane tube inserted into the stomach from a small incision made in the duodenum and held in place by a ligature around pylorus also esophagus was clamped to prevent reflux and loss of the gastric mucosa) in tubes and centrifuged at 500 R.P.M., for 5minutes. The volume of gastric juice was measured by graduated cylinder and expressed as ml.

e- Histopathological method: Specimens from stomachs were collected from rats of all experimental groups at the end of the experimental period, fixed in 10% neutral buffered formalin (pH=7.0), dehydrated in ethyl alcohol, then cleared in xylol and embedded in paraffin; 4-6 microns thickness sections prepared and stained with heamtoxylin and eosin for examining both for and glandular parts of the stomach (Bancroft and Gamble, 2008).

f- Statistical packaging spreadsheet software (SPSS, 2008) Ver. 16.0 was used for statistical analysis. Mean±SE (range) and An paired-sample t-test was used to compare the parameters between controls positive group and other rats groups. The results were reported as mean (95%). P<0.05 was considered significant.

3. Results

The present study was carried out elucidate the effect of feeding the extracts of aqueous plants: RCP (Capsicum frutescence) at three doses on the length of gastric ulcer induced by aspirin in rats. The tested parameters, in this study were the length of gastric ulcer, volume, PH of gastric juice and histopathological examination of glandular parts of stomachs.

3.1-Effect of aqueous extract of RCP on the length of gastric ulcer in rats:

The obtained results showed that a single oral administration of aspirin (200 mg\Kg) to rats induced gastric ulceration. The mean length of gastric ulcer in control (+ve) group was 7.48 ± 0.196 (mm) compared to zero in normal of the control (-ve) group, as dedicated in table 1. Oral administration of RCP extract at 250 mg\Kg B.Wt for 7 days after aspirin caused a significant decrease in the aspirin induced gastric ulcer. Rats orally given the water extra of RCP at doses of 500 and 750 mg\ Kg B.Wt for 7 days after aspirin significantly decrease the length gastric ulcer, as shown in table 1. The curative ratio from aspirin induced gastric ulcer in rats following administration of RCP at three tested doses were 63.9%, 75.66% and 83.28% respectively. The highest curative ratio for gastric ulcer was obtained by a dose of 750 mg\ Kg B.Wt of RCP (table1).

3.2-Effect of aqueous extract of RCP on the volume of gastric juice of rats

As shown in table (2) the volume of gastric juice obtained from rats given aspirin (control +ve group) at doses

(200 mg\Kg) was 0.73 ± 0.044 ml compared to 0.202 ± 0.009 ml in the control (-ve) group. Oral administration of water extracts of RCP at three tested doses for 7 days after aspirin significantly decrease the volume of gastric juice, compared to control (+ve) group. From the result shown in table (2), it could be noticed that RCP extract reduced of volume gastric juice secretion. The results indicated that oral administration of RCP at single doses 750 mg\Kg daily reduced the content to normal content of control (-ve) group. However, the acid content of the stomach was significantly increased by oral of RCP at a single doses 250 mg\Kg.

3.3-Effect of aqueous extract of RCP at three doses on the PH of gastric juice of rats

The Effect of aqueous extract on the PH of gastric juice listed in table(3). It's clear from table 3 that, a single oral administration of aspirin at 200mg\Kg to rats (control +ve group) caused a significantly increased for PH of gastric juice, compared to control (-ve) group. Rats orally given a single dose of aspirin followed by oral administration of RCP extract at two tested doses 500 and 750 mg\Kg for 7 days caused a significant increased of the PH of gastric juice, compared to control (+ve) group. There was non-significant differences in the PH of gastric juice for tested doses 250 mg\Kg of RCP extract compared with control (+ve) group. The highest increased in the PH of gastric juice was obtained by oral administration of 750 mg\Kg extract (table 3).

3.4-Histopathological examination of for and glandular parts of rats stomachs

Oral administration of a single dose (200 mg\Kg) of aspirin to rats caused, edema in lamina propria with mononuclear cells infiltration of the stomach (figure 3&4) compared to the normal histological structure in the control-ve group as illustrated in figure (1&2).

Stomach of rat rats treated with RCP extract at 250 mg\ Kg for 7 days following as aspirin administration showing slightly decreased the cell reaction in lamina propria glandular stomachs shown in figure (5&6) compared to control +ve group figure (3&4). Stomach of rat received RCP extract at 500 mg\Kg for 7 days following as aspirin administration showing normal histological structure in gastric glands lamina propria figure (7) but normal histological structure and edema in lamina propria shown in figure (8) compared to control +ve. The high dose of RCP extract (750 mg\Kg) for 7 days following as aspirin administration showing normal histological structure in gastric glands shown in figure (9&10) compared to control +ve group figure (3&4). As for figure (9&10), it could be noticed that the effect RCP extract on histopathological changes could be obtained.

4.Discussion

The results indicated that oral administration of *Capsicum frutescense* at single doses 750 mg\Kg daily reduced the content to normal content of control (-ve) and (+ve) group.

These results were in agreement with other studies, capsaicin decreased gastric liquid emptying, 18 and low-dose capsaicin was suggested to stimulate the swallowing reflex (Ebihara, et al., 1993). Yeoh et al., (1995) found that capsaicin, the pungent ingredient of chilli, has a gastro-protective effect against experimental gastric mucosal injury in animals. Such an effect has not, however, been documented in humans to date, demonstrating a gastro-protective effect of chilli in humans subjects.

Capsaicin is found to have gastroprotective effect against experimental gastric injury when given intragastrically. Previous epidemiological and clinical data suggested that chillis ingestion may have a beneficial effect on human peptic ulcer disease. Increased gastric mucus production has been suggested as one mechanism by which capsaicin and chilli exert their gastroprotective effect, and reduction in mucosal mucus depletion which has been found to act as secondary protective effect of capsaicin and chillis (Holzer & Sametz, 1986).

However, -sensitive afferent neurons have been to participate in gastric mucosal protection against ulcerogenic factors (Ito et al., 2004).

Stimulation of afferent neurons by intragastric capsaicin was therefore suggested to offer protection of the experimental animals against ethanol-induced gastric mucosa damage (Ito et al., 2004).

Ericson et al., (2009) repeated exposure of the esophageal mucosa to red chillis pepper sauce initially increased heartburn, but subsequently exerted an analgesic effect, Bortolotti et al., (2002-a) and 2.5 g of red pepper daily over 5 weeks resulted in a decrease in the intensity of dyspepsia after 3 weeks. A mechanism of initial sensitization, followed by desensitization of gastric nociceptive C-fibers, has been suggested Bortolotti, et al., (2002-b). A clinical trial evaluated the safety of 6 mg/day of capsaicinoids over 12 weeks for weight loss (Snitker et al., 2009), while another used 30 g/day of fresh chillis containing approximately 55% cayenne chillis for 4 weeks (Ahuja and Ball, 2006); weight loss was not achieved in either trial. Loss of abdominal fat was achieved in the 12-week trial (Snitker et al., 2009). A further clinical trial resulted in increased symptoms of pain and

burning, but not pruritus, in patients with acute anal fissures consuming 3 g/day of dried chillis powder over 2 weeks (Gupta, 2008). Although capsaicin has shown inhibitory action on *Helicobacter pylori* in vitro, an in vivo study does not support this action (Graham et al., 1999). The validity of the study has been questioned because of the small number of subjects and the short study duration (Mahady, and Pendland, 2000) and Calvet et al., 2000). Capsicum has been used for weight reduction, although clinical evidence is insufficient to support this use (Alevizos et al., 2007 and Kang et al., 2007).

A study of the effects of red chillis consumption following hemorrhoidectomy concluded that in the postoperative period, the increased extent and duration of typical postoperative symptoms (pain anal burning and bleeding) warranted chillis consumption as a contraindication (Gupta, 2007). However, a single-dose randomized clinical trial found no effect on hemorrhoidal symptoms (Altomare et al., 2006).

Capsaicin (8-methyl-N-vanillyl-6-nonenamide), the pungent component of the various species of *Capsicum* (red pepper), can impair selectively the activity of nociceptive C-type fibers carrying pain sensations to the central nervous system (Lynn, 1990 and Mayer & Gebhart, 1994). The analgesic properties of capsaicin have been known for more than a century, and a rich harvest of studies have demonstrated that the topical application of capsaicin is able to relieve post-herpetic neuralgia of the skin and oral cavity, trigeminal neuralgia and cluster headache (Watson, et al., 1993 and Sicuteri, et al., 1989), as well as painful diabetic neuropathy and vesical neuropathic pain (C.S.G. 1991 and Barbanti, et al., 1993). In addition, recent experiments have demonstrated that repeated exposures of the oesophageal mucosa to capsaicin containing red pepper sauce ingested by patients suffering from heartburn produces an analgesic effect after an initial phase of symptom worsening, suggesting the induction of sensitization followed by desensitization of the oesophageal mucosa by capsaicin (Rodriguez-Stanley, et al., 2000).

Capsaicin (8-methyl-N-vanillyl-6-nonenamide,) is the major pungent ingredient in red pepper. Recently, capsaicin was shown to induce apoptosis in several tumor cells. For example, capsaicin induced apoptosis through Bcl-2 down-regulation and caspase-3 activation in hepatocarcinoma cells (Jung et al., 2001), and through increased intracellular reactive oxygen species (ROS) and calcium levels in glioblastoma cells (Lee et al., 2000). In addition, capsaicin induced apoptosis in pancreatic cancer cells via ROS generation and persistent disruption of mitochondrial membrane potential (Zhang, et al., 2008). Due to the antiapoptotic function of Protein kinase CKII, we chose to examine whether capsaicin would inhibit CKII activity. Unexpectedly, capsaicin actually stimulated the catalytic activity of CKII holoenzyme, but not CKII α , suggesting that CKII β is necessary for this activation. In addition, capsaicin enhanced the autophosphorylation of CKII α and CKII β . To our knowledge, this is the first paper reporting a non-basic CKII activator.

5. Conclusion

Oral administration of aqueous extracts of red chillis pepper decreased histopathological changes in the stomach layers and mucosa as well as inhibited gastric acid secretion and ameliorate ulcers. Patients with ulcers can use red chillis pepper for healing the disease, which might be used as a medicinal herbs or add to food with the same percentage. The RCP extract had been experimented for rats can also be used for patients with ulcer in hospitals and evaluate their nutritional status

6. Acknowledgments

The authors are appreciated to the Deanship of Scientific Research, Taibah University.KSA for financially support to execute this research work, Project no. 1433/1251.

References:

- Agrawal, A.K., Rao, C.V., Sairman, K., Joshi, V.K. & Goel, R.K. (2000). "Effect of Piper longum linn, Zingiber officianails linn and Ferula species on gastric ulceration and secretion in rats". J. of Exp. Biol., 38 (10): 994-998.
- Ahmed, H.M. (2009). "Obesity, fast food manufacture, and regulation: revisiting opportunities for reform". Food Drug Law J.,64(3):565-575.
- Ahuja, K.D., &Ball, M.J. (2006). "Effects of daily ingestion of chillis on serum lipoprotein oxidation in adult men and women". Br J Nutr.,96(2):239-242.
- Akhtar, A.H. & Ahmed, K.U. (1995). "Anti-ulcerogenic evaluation of the methanolic extracts of some

- indigenous medicinal plants in Pakistan on aspirin-ulcerated rats". *J. of Ethnopharmacol*, 46(1):1-6.
- Alasdair, G., TPeters, M. & Robin, C. (1981). "Pathology Illustrated", Printed in Hong Kong by Shek Wah Tong Printing Press L. Td. P.278-388.
- Alevizos, A., Mihas, C., Mariolis, A. & Larios, G. (2007). "Insulin secretion and capsaicin", *Am J Clin Nutr.*,85(4):1165-1166.
- Altomare, D.F., Rinaldi, M. & Torre, F. La. (2006). "Red hot Chillis pepper and hemorrhoids: the explosion of a myth: results of a prospective, randomized, placebo-controlled, crossover trial", *Dis Colon Rectum.*,49(7):1018-1023.
- Bancroft, J.D. & Gamble, M. (2008), "Theory and Practice of Histological Techniques", 6th. ed. Pub. by Churchill Livingstone, Elsevier, USA.
- Barbanti, G., Maggi, C.A., Beneforti, P. Baroldi, P.& Turini, D. (1993). "Relief of pain following intravesical capsaicin in patients with hypersensitive disorders of the lower urinary tract", *Br J Urol*, 71: 686-91.
- Bortolotti, M., Coccia, G., Grossi, G. & Miglioli, M. (2002-a), "The treatment of functional dyspepsia with red pepper", *Aliment Pharmacol Ther.*,16(6):1075-1082.
- Bortolotti, M., Coccia, G. & Grossi, G. (2002^b). "Red pepper and functional dyspepsia", *N Engl J Med* . ,346(12):947-948.
- C.S.G. (1991), "Treatment of painful diabetic neuropathy with topical capsaicin. A multicenter, doubleblind, vehicle-controlled study", *Arch Intern Med.*,151: 2225-9.
- Calvet, X., Carod, C.& Gene, E. (2000). "Peppers at treatment of Helicobacter pylori infection", *Am J Gastroenterol.*,95(3):820-821.
- Cruz, L., Castaneda, H.G. & Navarrete, A. (1999). "Ingestion of chilli pepper (*Capsicum annum*) reduces salicylate bio-availability after aspirin administration in the rat", *J. of Physiol. Pharmacol.*, 77 (6): 441-446.
- Davies, B.H., Matthews, S. & Kirk, J. (1970). "The nature and biosynthesis of the carotenoids of different colour varieties of *Capsicum annum*", *Phytochem.*,9:797-805.
- Ebihara, T., Sekizawa, K., Nakazawa, H.& Sasaki, H. (1993). "Capsaicin and swallowing reflex". *Lancet*,341(8842):432.
- Ericson, A., Nur, E.M. Petersson, F. & Kechagias, S.(2009). "The effects of capsaicin on gastrin secretion in isolated human antral glands: before and after ingestion of red chilli", *Dig Dis Sci* .,54(3):491-498.
- Erika, J., Leszek, G., Ines, H., Dietrich, K., Otto, S. & Jurg, G. (1998). "Hot Spices Influence Permeability of Human Intestinal Epithelial Monolayers1", *American Society for Nutritional Sciences. J. Nutr.*, 128: 577-581.
- Ganesh Bhat, B.& Chandrasekhara, N. (1987). "Effect of black pepper and piperine on bile secretion and composition in rats", *J. Nahrung*, 31: 913-916
- Gonzalez, R. (1998). "Effect of capsaicin-containing red pepper sauce suspension on upper gastrointestinal motility in healthy volunteers", *Dig Dis Sci* .,43(6):1165-1171.
- Graham, D.Y., Anderson, S.Y. & Lang, T. (1999). "Garlic or jalapeño peppers for treatment of Helicobacter pylori infection" , *Am J Gastroenterol* .,94(5):1200-1202.
- Gupta, P.J. (2007). "Effect of red chilli consumption on postoperative symptoms during the post-hemorrhoidectomy period: randomized, double-blind, controlled study", *World J Surg.*,31(9):1822-1826.
- Gupta, P.J. (2008) "Consumption of red-hot chillis pepper increases symptoms in patients with acute anal fissures. A prospective, randomized, placebo-controlled, double blind, crossover trial", *Arq Gastroenterol* .,45(2):124-127.
- Holzer ,P. & Sametz, W. (1986) "Gastric mucosal protection against ulcerogenic factors in the rat mediated by capsaicin-sensitive afferent neurons", *Gastroenterology*, 91:975-81.
- Ito, K., Nakazato, T. , Yamato, K., Miyakawa, Y. , Yamada, T., Hozumi, N. et al., (2004), "Induction of apoptosis in lenvemic cells by homova nillic acid derivation, capsaicin, through oxidative", *Cancer Res.*,64:1071-8.
- Ivette, G., Shane, H. Joslynn, R. Paul, W.B & Mary, A.O. (2010) "Variability of Carotenoid Biosynthesis in Orange Colored *Capsicum spp*" , *J. Plant Sci.* , 179(1-2): 49-59.
- Jung, M.Y., Kang, H.J. & Moon, A. (2001). "Capsaicininduced apoptosis in SK-Hep-1 hepatocarcinoma cells involves Bcl-2 down-regulation and caspase-3 activation", *Cancer Lett.*, 165, 139-145.
- Kang, J.H., Kim, C.S. Han, I.S. Kawada, T. & Yu, R. (2007). "Capsaicin, a spicy component of hot peppers, modulates adipokine gene expression and protein release from obese-mouse adipose tissues and isolated adipocytes, and suppresses the inflammatory responses of adipose tissue macrophages",

- FEBS Lett., 581(23):4389-4396.
- Kumar, N., Vij, J.C. Sarin, S.K. & Anand, B.S. (1984). "Do chillies influence healing of duodenal ulcer?" *BMJ*, 288(6433):1803-1804.
- Lawless, H., Rozin, P. & Shenker, J. (1985). "Effects of oral capsaicin on gustatory, olfactory, and irritant sensations and flavor identification in humans who regularly or rarely consume Chilli pepper", *Chem Senses.*, 10:579–89.
- Lee, Y. S., Nam, D.H. & Kim, J. A. (2000). "Induction of apoptosis by capsaicin in A172 human glioblastoma cells", *Cancer Lett.*, 161, 121-130.
- Lynn, B. (1990). "Capsaicin actions on nociceptive C-fibres and therapeutic potential", *Pain.*, 41: 61–9.
- Mahady, G.B & Pendland, S. (2000). "Garlic and *Helicobacter pylori*", *Am J. Gastroenterol.*, 95(1):309.
- Mary-Jon, L. & Richard, D.M. (2011), "The effects of hedonically acceptable red pepper doses on thermogenesis and appetite", *J. Physiol Behav.* 1, 102(3-4): 251–258.
- Mayer, E.A. & Gebhart, G.F. (1994). "Basic and clinical aspects of visceral hyperalgesia", *Gastroenterology*, 107: 271–93.
- Mujumdar, A. M., Dhuley, J. N. Deshmukh, V.K., Raman, P.H. & Naik, S.R. (1990). "Anti-inflammatory activity of piperine", *J. of Med. Sci. Biol.*, 43 (3): 95-100.
- Niida, H., Takenchi, K and Okabe, S. (1991), "Role of thyrotropin releasing hormone in acid secretory response in rats", *Eur. J. Pharmacol.*, 198:137-142.
- Ononiwu, I.M., Ibeneme, C.E. & Ebong, O.O. (2002). "Effect of Piperine on gastric acid secretion in albino rats", *Afr. J. of Med. Sci.*, 31 (4): 293-295.
- Prabha, P., Karpagam, T., Varalakshmi, B. & Packiavathy A.S. (2011). "Indigenous anti-ulcer activity of *Musa sapientum* on peptic ulcer", *J. Pharmacognosy Res.*, 3(4):232-8.
- Reddy, P.S., Kaiser, J., Medhusudhan, P., Anjani, G., Das, B. & Tamil, K. (2001). "Anti-bacterial activity of isolates from *Piper longum* and *Taxus baccata*. Pharmaceutical", *Biology*, 39 (3):236-238.
- Rodriguez-Stanley, S., Collings, K.L., Robinson, M., Owen, W. & Miner, P.B. (2000). "The effects of capsaicin on reflux, gastric emptying and dyspepsia", *Aliment Pharmacol Ther.*, 14(1):129-134.
- Rozin, P. & Schiller, D. (1980). "The nature and acquisition of a preference for chillis pepper by humans", *Motiv Emotion.*, 4:77–101.
- Sicuteri, F., Fusco, B.B.M. & Marabini, S. (1989). "Beneficial effect of capsaicin application to the nasal mucosa in cluster headache", *Clin J Pain*, 5: 49–53.
- Sloan, A. (2010). "What, when, and where America eats", *Food Technol.*, 64:19–27.
- Smiciklas-Wright, H., Mitchell, D.C., Mickle, S.J., Cook, A.J. & Goldman, J.D. (2002). "Foods commonly eaten in the United States: quantities consumed per eating occasion and in a day", *US Department of Agriculture NFS Report No. 96–5, 1994–1996.*
- Snitker, S., Fujishima, Y. & Shen, H. (2009). "Effects of novel capsinoid treatment on fatness and energy metabolism in humans: possible pharmacogenetic implications". *Am J Clin Nutr.*, 89(1):45-50.
- SPSS (2008). "Statistical Package for Social Science, Computer Software, IBM, SPSS Ver. 16.0 in 2008., SPSS Company, London, UK..
- Thorup, T.A., Tanyolac, B., Livingstone, K.D., Popovsky, S., Paran, I. & Jahn, M. (2000). "Candidate gene analysis of organ pigmentation loci in the Solanaceae", *Proc. Natl. Acad. Sci. USA*, 97:11192–11197.
- Tyler, V.E., Brady, L.R. & Robbers, J.E. (1981). "Pharmacognosy", 8th ed. Philadelphia, PA: Lea & Febiger.
- Vasudevan, K., Vembar, S., Veeraraghavan, K. & Haranth, P.S. (2000). "Influence of intra-gastric perfusion of aqueous spice extracts on acid secretion in anesthetized albino rats", *Indian J. of Gastroenterol.*, 19 (2): 53-56.
- Watson, C.P., Tyler, K.L., Bickers, D.R., Millikan, L.E., Smith, S. & Coleman, E.A. (1993) "randomized vehicle-controlled trial of topical capsaicin in the treatment of postherpetic neuralgia", *Clin Ther.*, 15: 510–25.
- Yeoh, K.G., Kang, J.Y. Yap, I., Guan, R., Tan, C.C., Wee, A. & Teng, C.H. (1995) "Chilli protects against aspirin-induced gastro-duodenal mucosal injury in humans", *Singapore, J. of Dig. Dis. Sci.*, 40 (3): 580-583.
- Yoshioka, M., Doucet, E., Drapeau, V., Dionne, I. & Tremblay, A. (2001). "Combined effects of red pepper and caffeine consumption on 24 h energy balance in subjects given free access to foods", *Brit J Nutr.*, 85:203–11.
- Zhang, R., Humphreys, I., Sahu, R.P., Shi, Y. & Srivastava, S.K. (2008). "In vitro and in vivo induction of apoptosis by capsaicin in pancreatic cancer cells is mediated through ROS generation and mitochondrial death pathway", *Apoptosis*, 13: 1465-1478.

Table (1): Effect of aqueous extract of RCP (*Capsium frutescens*) at three doses on the length of gastric ulcer in rats.

Groups		Aspirin, diet and extracts	Doses (mg/kg B.Wt.)	Gastric ulcer length (mm.) Mean±SE	CR (%)
Control -ve	1	-	-	0.00±0.00***	-
Control +ve	2	Aspirin (Asp.)	200	7.48±0.196	-
	3	(Asp.) + RCP	250	2.7±0.187***	63.9
	4	(Asp.) + RCP	500	1.82±0.051***	75.66
	5	(Asp.) + RCP	750	1.25±0.043***	83.28

CR: Curative Ratio with +ve.

*Differences are significant at 5% compared

**Differences are significant at 1% compared with +ve. with +ve.

***Differences are significant at 0.1% compared

Table (2): Effect of aqueous extract of RCP (*Capsium frutescens*) at three doses on the volume of gastric juice collected from stomachs of rats.

Groups		Aspirin, diet and extracts	Doses (mg/kg B.Wt.)	Volume of gastric juice (mL.) Mean±SE	DR (%)
Control -ve	1	-	-	0.20±0.009***	-
Control +ve	2	Aspirin (Asp.)	200	0.73±0.044	-
	3	(Asp.) + RCP	250	0.38±0.014**	47.945
	4	(Asp.) + RCP	500	0.28±0.025***	61.64
	5	(Asp.) + RCP	750	0.22±0.01633***	69.86

DR: Decrease Ratio with +ve.

*Differences are significant at 5% compared

**Differences are significant at 1% compared with +ve. with +ve.

***Differences are significant at 0.1% compared

Table (3): Effect of aqueous extract of RCP (*Capsium frutescens*) at three doses on the PH of gastric juice collected from stomachs of rats.

Groups		Aspirin, diet and extracts	Doses (mg/kg B.Wt.)	PH of gastric juice Mean±SE	IR (%)
Control -ve	1	-	-	4.48±0.151**	-
Control +ve	2	Aspirin (Asp.)	200	2.85±0.195	-
	3	(Asp.) + RCP	250	3.52±0.152 ^{NS}	23.5
	4	(Asp.) + RCP	500	3.83±0.138**	34.38
	5	(Asp.) + RCP	750	4.08±0.101**	43.15

IR: Increase Ratio with +ve.

*Differences are significant at 5% compared

**Differences are significant at 1% compared with +ve. with +ve.

***Differences are significant at 0.1% compared

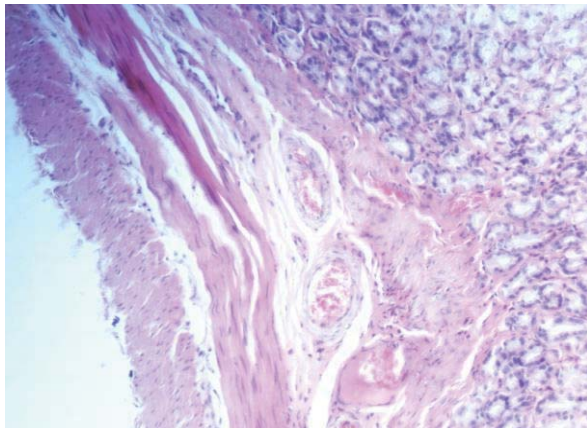


Figure 1. Stomach of rat form group 1 (control-ve) showing the normal histological structure. (H & E x200).

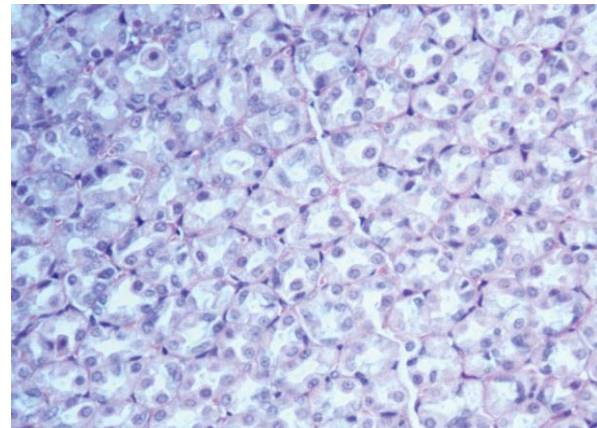


Figure 2. Stomach of rat form group 1 (control -ve) showing the normal histological structure. (H & E x200)

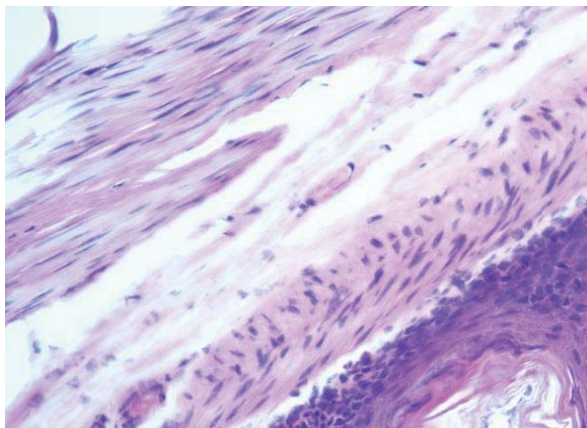


Figure 3. Stomach of rat from group 2 (control +ve) showing mononuclear cells infiltration. (H and E x 200).

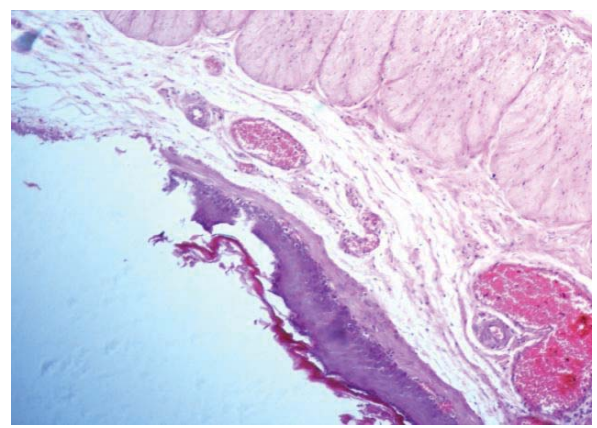


Figure 4. Stomach of rat from group 2 (control +ve) showing destruction of gastric glands, edema in lamina propria as well as mononuclear cells infiltration. (H & E x 200).

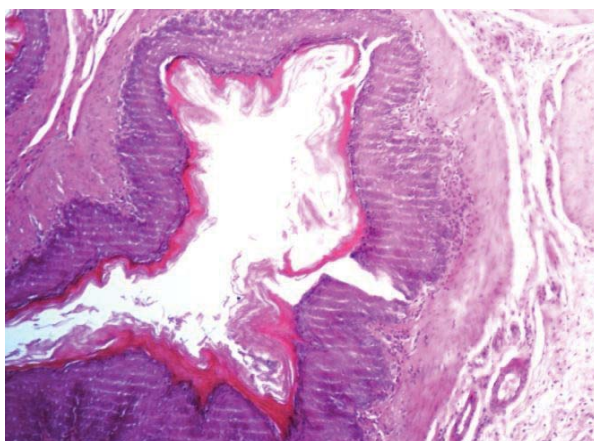


Figure 5. Stomach of rat form group 3 (Asp.) + RCP 250 showing the abnormal histological structure in gastric glands.(H and E x200)

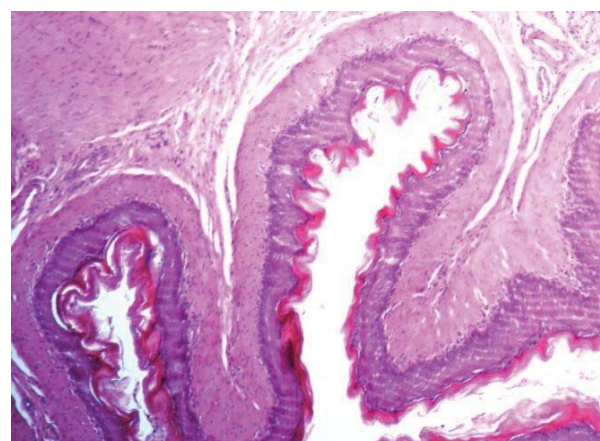


Figure 6. Stomach of rat form group 3 (Asp.) + RCP 250 showing the abnormal histological structure in gastric glands.(H and E x200)

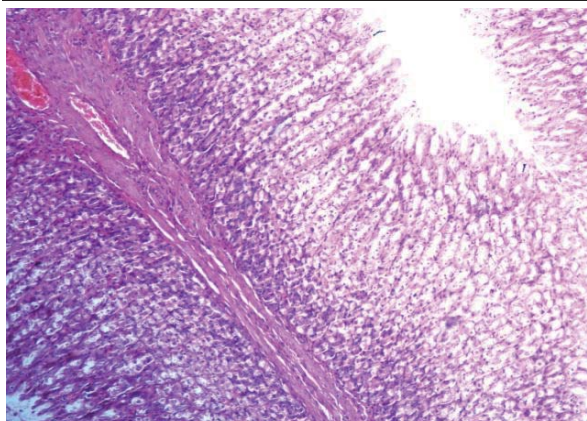


Figure 7. Stomach of rat form group 4 (Asp.) + RCP 500 showing the normal histological structure in gastric glands. (H and E x200)

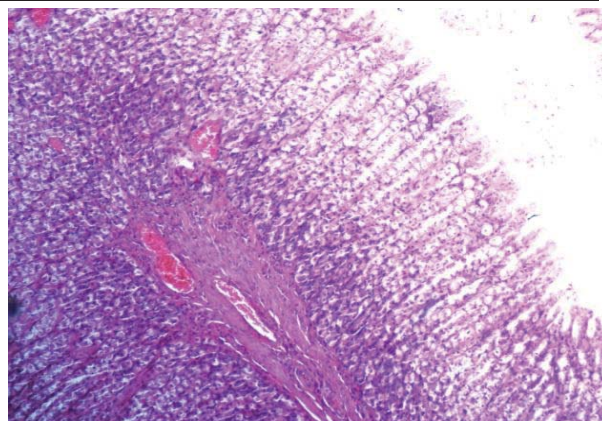


Figure 8. Stomach of rat form group 4 (Asp.) + RCP 500 showing the normal histological structure and edema in lamina propria. (H& E x200)

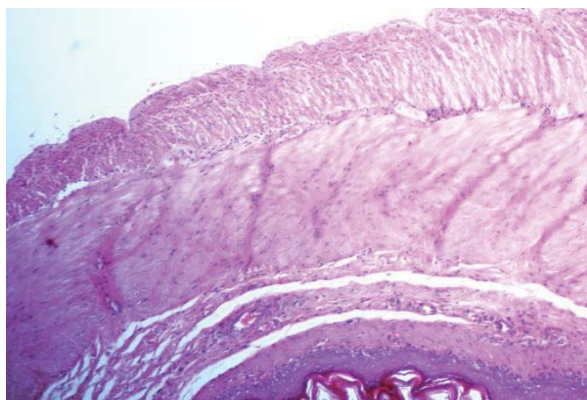


Figure 9. Stomach of rat form group 5 (Asp.) + RCP 750 showing the normal histological structure in gastric glands. (H & E x200)

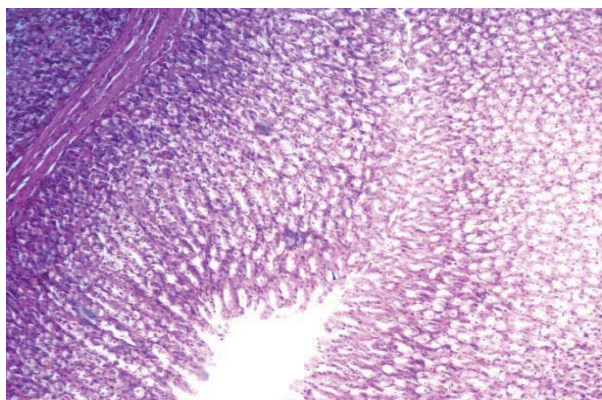


Figure 10. Stomach of rat form group 5 (Asp.) + RCP 750 showing the normal histological structure. (H & E x200)

This academic article was published by The International Institute for Science, Technology and Education (IISTE). The IISTE is a pioneer in the Open Access Publishing service based in the U.S. and Europe. The aim of the institute is Accelerating Global Knowledge Sharing.

More information about the publisher can be found in the IISTE's homepage:

<http://www.iiste.org>

CALL FOR PAPERS

The IISTE is currently hosting more than 30 peer-reviewed academic journals and collaborating with academic institutions around the world. There's no deadline for submission. **Prospective authors of IISTE journals can find the submission instruction on the following page:** <http://www.iiste.org/Journals/>

The IISTE editorial team promises to review and publish all the qualified submissions in a **fast** manner. All the journals articles are available online to the readers all over the world without financial, legal, or technical barriers other than those inseparable from gaining access to the internet itself. Printed version of the journals is also available upon request of readers and authors.

IISTE Knowledge Sharing Partners

EBSCO, Index Copernicus, Ulrich's Periodicals Directory, JournalTOCS, PKP Open Archives Harvester, Bielefeld Academic Search Engine, Elektronische Zeitschriftenbibliothek EZB, Open J-Gate, OCLC WorldCat, Universe Digital Library, NewJour, Google Scholar

