

A Case of polypoid skin carcinoma with saromatous appearance

著者	Okabe Hidetoshi, Ochi Yukio, Imokawa Minoru, Takeoka Osamu
journal or publication title	滋賀医科大学雑誌
volume	1
page range	75-80
year	1986-05
その他の言語のタイトル	肉腫様所見を伴ったポリープ状皮膚癌の1例 ニクシュヨウ ショケン ヲ トモナッタ ポリープジ ヨウ ヒフガン ノ イチレイ
URL	http://hdl.handle.net/10422/3134

A Case of Polypoid Skin Carcinoma with Sarcomatous Appearance

Hidetoshi OKABE, Yukio OCHI, Minoru IMOKAWA and

Osamu TAKEOKA*

Department of Laboratory Medicine
*First Department of Pathology
Shiga University of Medical Science

A polypoid tumor with tiny foci of prickle cell carcinoma and large areas with a malignant fibrous histiocytoma-like appearance was developed on the right cheek of a 75 year-old male. By use of keratin immunohistochemistry, the tumor was revealed to be a carcinoma. The large storiform areas were shown to be formed by abundant reactive fibrous components around sparsely distributed carcinoma cells.

Key words : immunohistochemistry, keratin, malignant fibrous histiocytoma, squamous cell carcinoma

Introduction

Recently, immunohistochemical methods have been introduced into daily surgical pathological examinations. Among them, keratin immunohistochemistry has been demonstrated to be useful for differentiation between carcinomas and sarcomas (1). We report here a case of carcinoma with a sarcoma-like appearance in which keratin immunohistochemistry was useful for the diagnosis, and discuss some pathological characteristics of this tumor.

Case Report

A 75 year-old man who had been suffering from a rapidly growing tumor on the right cheek for three months was admitted to the hospital of the Shiga University of Medical Science. At the time of admission, the tumor had a pedunculated hemispherical appearance with a maximum diameter of 2.5cm (Fig.1). The top was ulcerated and had hemorrhagic discoloration. The consistency was elastic hard. No regional lymph node swelling or satellite nodule formation was detected. On the contralateral cheek, several tiny senile keratoses were seen. There was no significant familial or past history related to this condi-

Accepted for publication January 19, 1986

岡部英俊, 越智幸男, 芋川実, 竹岡成

Shiga University of Medical Science, Otsu, Shiga, 520-21, JAPAN

tion.

On the first day of admission, the tumor was excised under local anesthesia. The cut surface of this tumor exhibited the appearance of a mixture of watery myxoid and grayish white fibrous substance. Downward invasion was minimum and seemed to be restricted within the reticular dermis. No apparent connection between the tumor and the epidermis was noted.

Based on the pathological diagnosis described below, postoperative irradiation (3,000 rad) was given from the twentieth day of admission. The patient was discharged on the 44th day without any serious complications. Since then, no tumor recurrence has been detected during 6 months.

Preparation for Histopathological Studies

Following the fixation in 10% neutral formalin, representative portions of the tumor were embedded in paraffin and processed for light microscopic observation, using H & E, azan, and elastica van Gieson stainings. In addition, keratin immunohistochemistry was carried out, using a

DAKO PAP kit.

Histopathological Findings

The surface epidermis was hyperkeratotic. Acanthotic areas were seen sporadically. Just beneath the surface epithelium, small nests of neoplastic sheets composed of large eosinophilic polygonal cells were seen. In such sheets, the tumor cells had a tight cohesiveness. Pearl formations were seen distinctly (Fig 2) and so the squamous cell differentiation of such portions was evident. However, most of the superficial areas showed a myxoid appearance where pleomorphic large polygonal to bipolar cells were sparsely dispersed (Fig 3a). These tumor cells had oxyphilic cytoplasm and irregular nuclei with coarse chromatin textures. Multinucleated cells were abundant and the nuclear number exceeded five in some cells. Marked nuclear lobulations or cytoplasmic vacuolations were also seen. In some parts, these tumor cells adhered to each other and

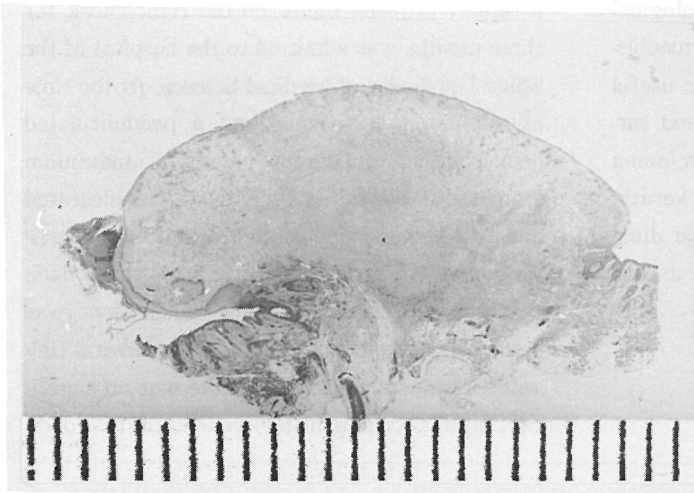


Fig 1. Pedunculated polypoid appearance of the tumor.

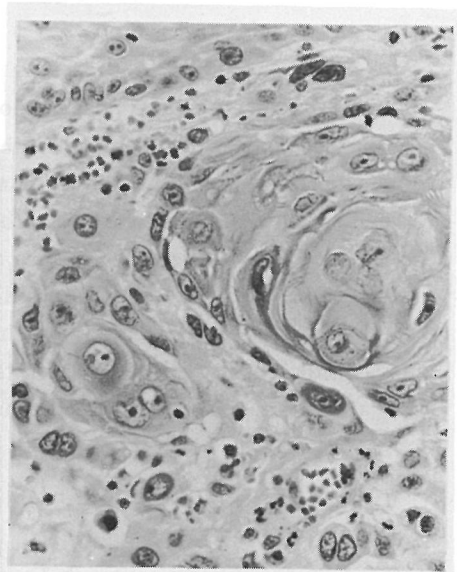


Fig 2. Foci of the differentiated squamous cell carcinoma. Distinct pearl formation can be seen. H & E ($\times 200$)

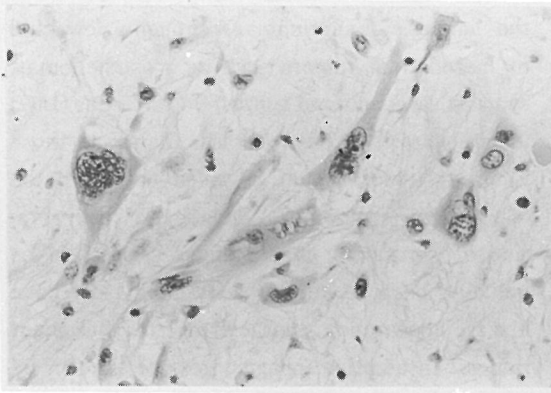


Fig 3a. Myxoid areas of the tumor. Large polygonal cells are randomly dispersed. Multinucleation is found in some tumor cells. No organoid arrangement H & E ($\times 200$)

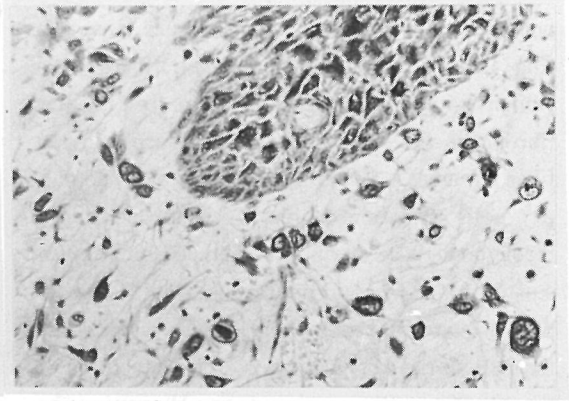


Fig 3b. Carcinomatous nature demonstrated by keratin immunohistochemistry. Intensity of the staining is comparable with that of the epidermal cells. ($\times 120$)

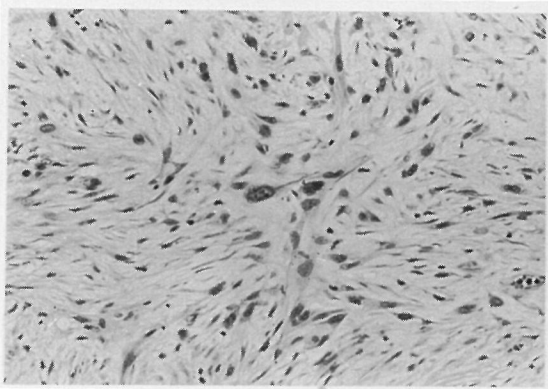


Fig 4a. Storiform appearance resembling to malignant fibrous histiocytoma. H & E ($\times 120$)

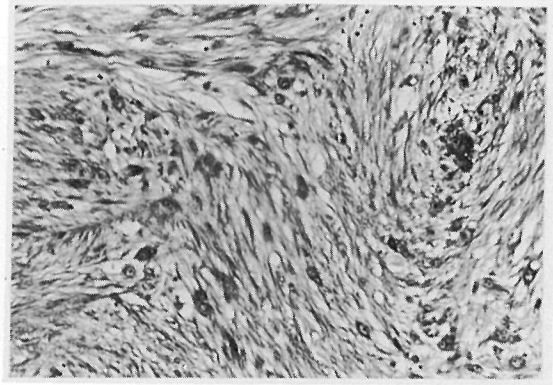


Fig 4b. Abundance of collagen fibers. Azan ($\times 120$)

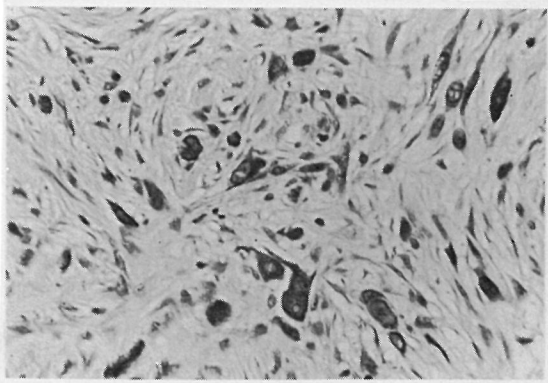


Fig 4c. Carcinoma cells demonstrated by keratin staining. Strength of the staining is almost comparable with epidermal squamous cells. ($\times 150$)

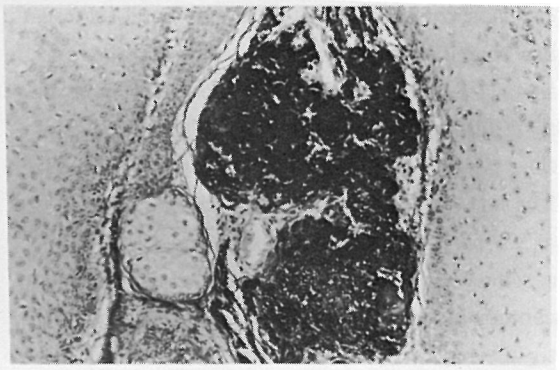


Fig 5. Solar elastosis in the vicinity of the tumor. EVG ($\times 50$)

formed short strands or tiny sheets. In the deeper portions, a prominent storiform figure was seen (Fig 4a). There, abundant collagen fibers were demonstrated by azan stain (Fig 4b). Bipolar fibroblasts were seen abundantly in such collagen fiber streams. A few number of the large neoplastic cells mentioned above were scattered throughout these areas also. The combination of storiform and myxoid appearances in this tumor had an apparent resemblance to the histological features of the malignant fibrous histiocytoma of the storiform-pleomorphic type. However, the large polygonal cells and most of the atypical bipolar neoplastic cells in such portions were revealed to have keratin (Fig 3b, 4c), and could be regarded as an anaplastic population of the squamous cell carcinoma. In conclusion, the tumor could be diagnosed as a poorly differentiated squamous cell carcinoma. As had been suggested from the macroscopic finding, the tumor invasion was restricted to the reticular dermis.

Besides the neoplastic lesion, solar elastosis was seen in the vicinity of the tumor (Fig 5).

Discussion

It has been clarified that most of the so-called carcinosaromas were not true compound tumors, but merely carcinomas with sarcoma-like portions (2), except for special tumors arising from the Müllerian ducts (3). In skin malignancies also, this general rule has been adopted in most instances (4, 5). Accordingly, the sarcoma-like areas of this tumor had been supposed to be carcinomatous when tiny nests of squamous cell carcinoma were detected through routine histopathological study. However, substantial evidence was required to eliminate a rare combination of squamous cell carcinoma and malignant fibrous histiocytoma (6). In this case, keratin could be demonstrated in the pleomorphic cells in

the sarcomatous areas, giving strong support for the diagnosis of carcinoma. Although a few kind of mesodermal tumors such as mesotheliomas, synovial sarcomas and epithelioid sarcomas (1) (7) (8) are known to form keratin filaments, those kinds of tumors could be ruled out from the histological appearance. Phagocytic incorporation of keratin by macrophages seemed to be unlikely, because keratin containing cells have bizarre appearances characteristic for malignant tumors. In addition, phagocytosis of keratin by the tumor cells also seemed to be unlikely since no other phagocytic signs such as erythrophagocytosis or hemosiderin accumulation could be seen. Therefore, the keratin seen in these tumor cells could be regarded as an epithelial marker formed by the tumor cells themselves. Furthermore, in this immunohistochemical study, myxoid or storiform portions were never seen without accompanying keratin positive cells. Although fibroblastic cells were abundant in such portions, they were not so pleomorphic as keratin positive cells. Thus, the abundant mesenchymal components could be regarded as reactive ones rather than true sarcomatous components. As shown in this case, keratin immunohistochemistry is quite useful for the diagnosis of carcinomas, though some limitations have been pointed out which should be taken into consideration (1) (7) (8).

In this tumor, the storiform appearance was largely constituted of reactive mesenchymal components around the carcinoma cells. This pattern of storiform formation is quite different from that of some kinds of undifferentiated carcinomas such as spindle cell carcinomas of the thyroid in which a curlicue texture is almost entirely formed by the tumor cells themselves (9).

In this patient, a solar elastosis was seen near the tumor nest, suggesting accumulated solar or ultraviolet effects on the corresponding areas. This finding seems to support the idea that development of this kind of poorly differentiated

carcinoma has close correlation with solar or ultraviolet damage (5).

References

1. Schlegel R., Banks-Schlegel S., McLeod J. A. and Pinkus G. S. (1980) : Immunoperoxidase localization of keratin in human neoplasms. *Am. J. Pathol.* **101**: 41-47.
2. Aschley D. B. J. (1978) : Mixed connective tumours in "Histological appearances of tumours", 153-154. Churchill-Livingston, Edinburgh.
3. Barwick K. W. & LiVolsi V. A. (1979) : Malignant mixed Müllerian tumor of the uterus. *Am. J. Surg. Pathol.* **3**, 125-135.
4. Evans H. L & Smith J. L. (1980) : Spindle cell squamous cell carcinoma and sarcoma-like tumor of the skin. *Cancer.* **45**: 2687-2697.
5. Lever W. F. & Schaumberg-Lever G. (1983) : Squamous cell carcinoma in "Histopathology of the skin", 6th ed. 499-502. Lippincott, N. Y.
6. Ohara A., Arata J. & Yamamoto Y. (1984) : Co-existence of squamous cell carcinoma and malignant fibrous histiocytoma. *Jpn. J. Clin. Dermatol.* **38**, 443-446.
7. Mukai M., Torikata C., Iri H., Mikata A., Kawai T., Hanaoka H., Yakumaru K and Kageyama K. (1984) : Histogenesis of clear cell sarcoma of tendons and aponeuroses. *Am. J. Pathol.* **114**, 264-272
8. Chase D. R., Enzinger F. M., Langloss J. M. and Weiss S. W. (1984) : Keratin in epithelioid sarcoma, *Am. J. Surg. Pathol.* **8**, 435-441.
9. Aschley D. B. J. (1978) : Tumours of thyroid in "Histological appearances of tumours", 263-164. Churchill-Livingstone, Edinburgh.

肉腫様所見を伴ったポリープ状皮膚癌の1例

岡部英俊, 越智幸男, 芋川 実, 竹岡 成*

滋賀医科大学附属病院検査部, *病理学第一講座

75才男性の右頬部に, 悪性線維性組織球腫と類似の所見を主体とし, ごく一部に扁平上皮癌としての分化を示す腫瘍を認めた. 通常の光学顕微鏡的検索では, 肉腫の併発を除外しきれなかったが, 抗ケラチン抗体を用いた酵素抗体法による染色を併用する

ことにより, 肉腫様部分も癌種であることが同定できた. また, 肉腫とまぎらわしかった storiform pattern の形成には, 豊富な反応性の間葉成分の関与が示唆された.